

Disclosures

February 6, 2023

Dr. Harris Goodman has disclosed a relevant financial relationship as a stockholder of Pfizer. The planners have determined that this relationship is not relevant to the clinical diagnostic case being presented. The remaining activity planners and faculty listed below have no relevant financial relationship(s) to disclose with ineligible companies whose primary business is producing, marketing, selling, re-selling, or distributing healthcare products used by or on patients.

Presenters/Faculty:

Kevin Lu, MD
Emily Chan, MD
Cynthia Gasper, MD
Eric Ollila, MD
Megan Troxell, MD, PhD
Ruth Zhang, MD
Nancy Joseph, MD
Ankur Sangoi, MD

Activity Planners/Moderator:

Kristin Jensen, MD
Megan Troxell, MD, PhD
Ankur Sangoi, MD

EVALUATION QR CODE!

Hold smartphone camera on code

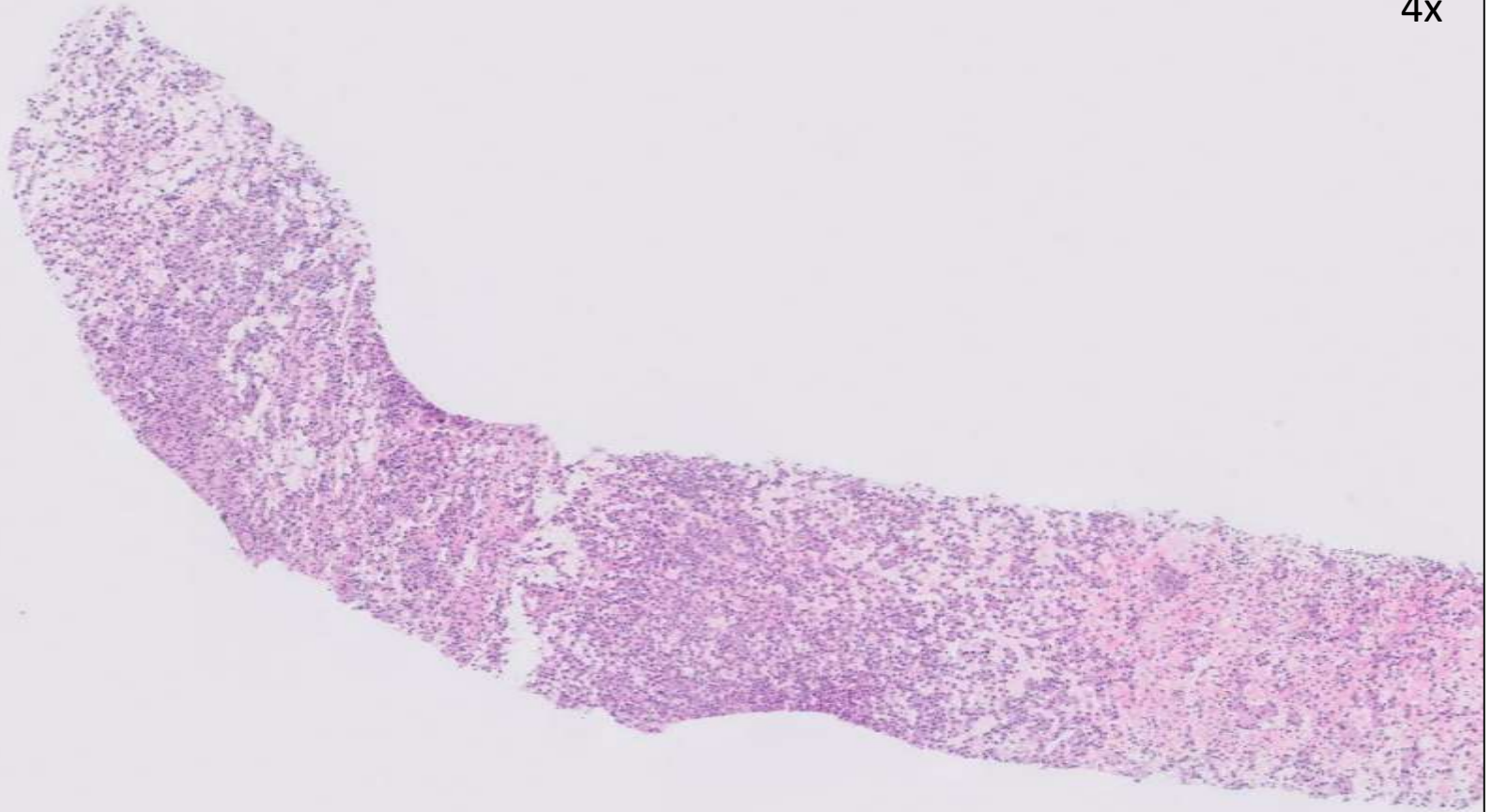


23-0201

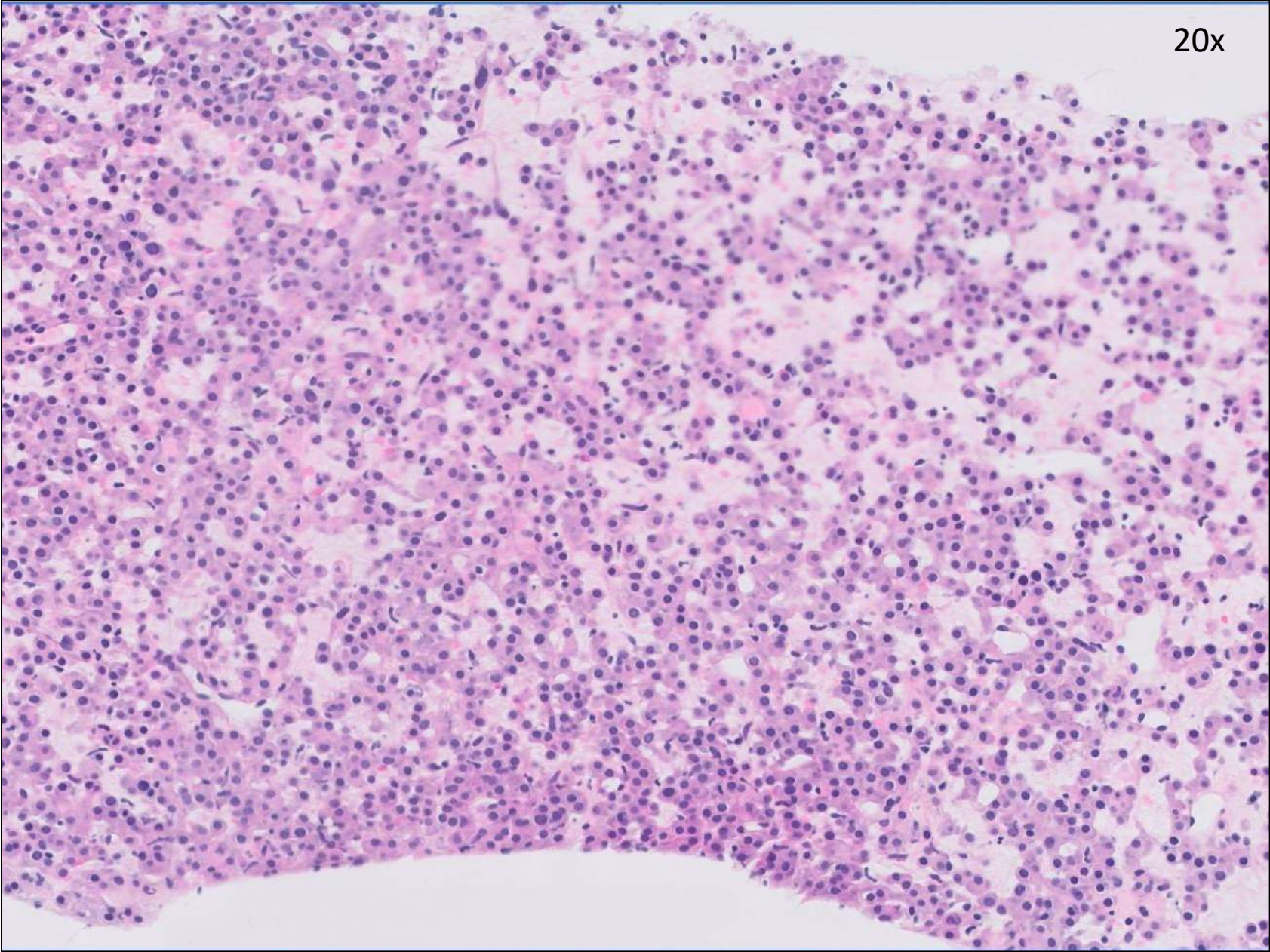
Kevin Lu/Emily Chan; UCSF

30ish F with 4cm left renal mass, biopsy performed.

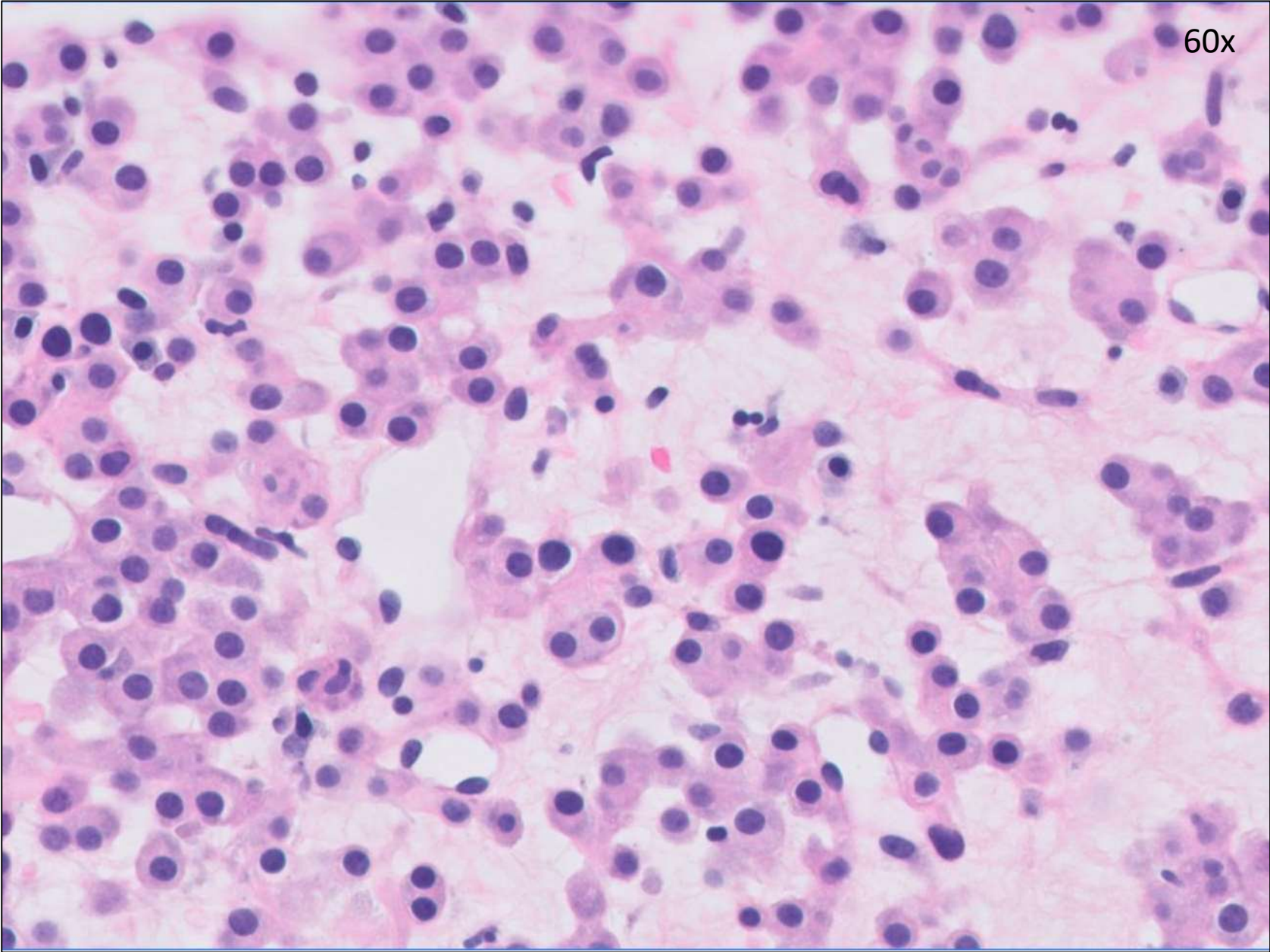
4x



20x



60x



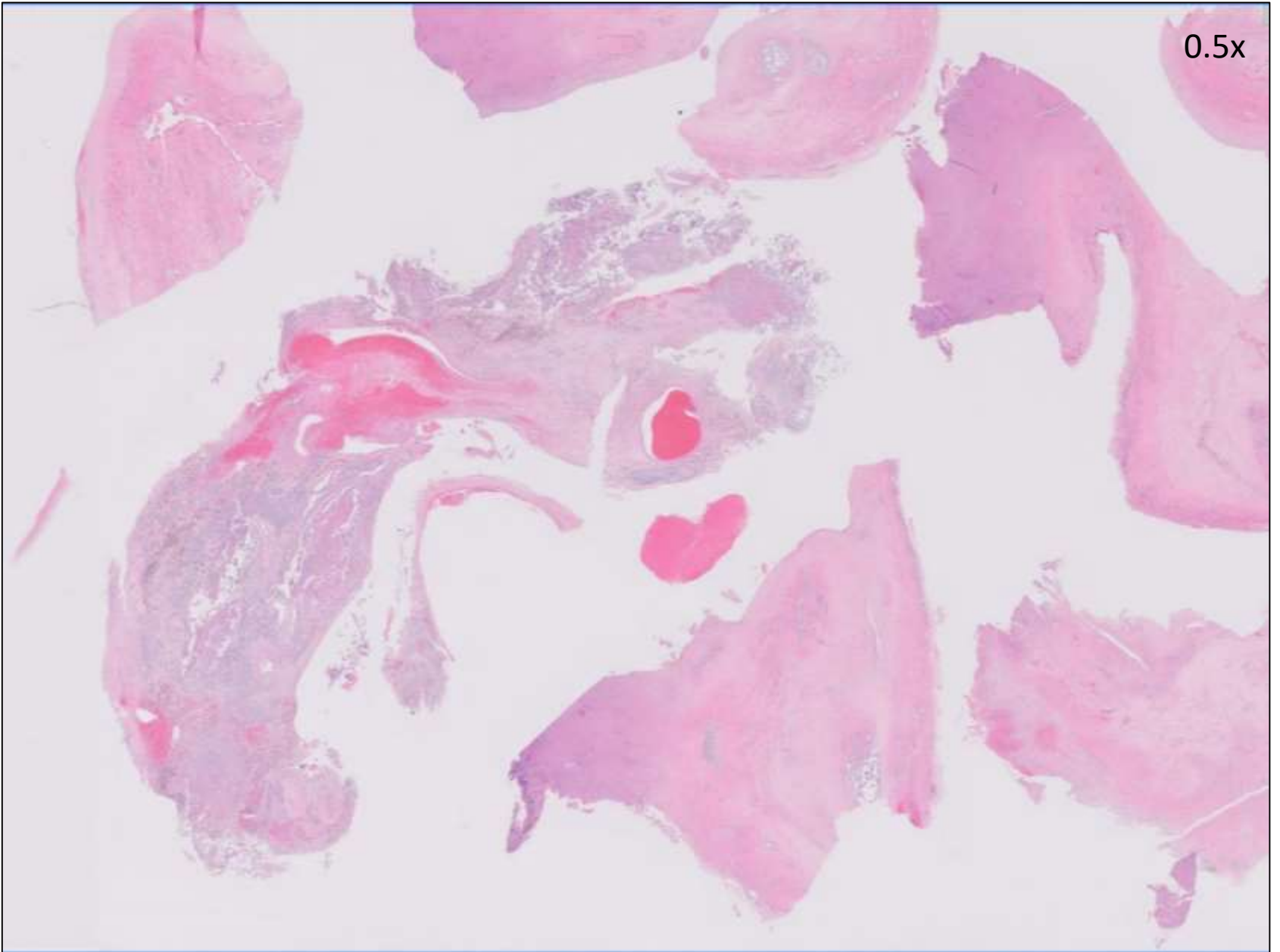
DIAGNOSIS?



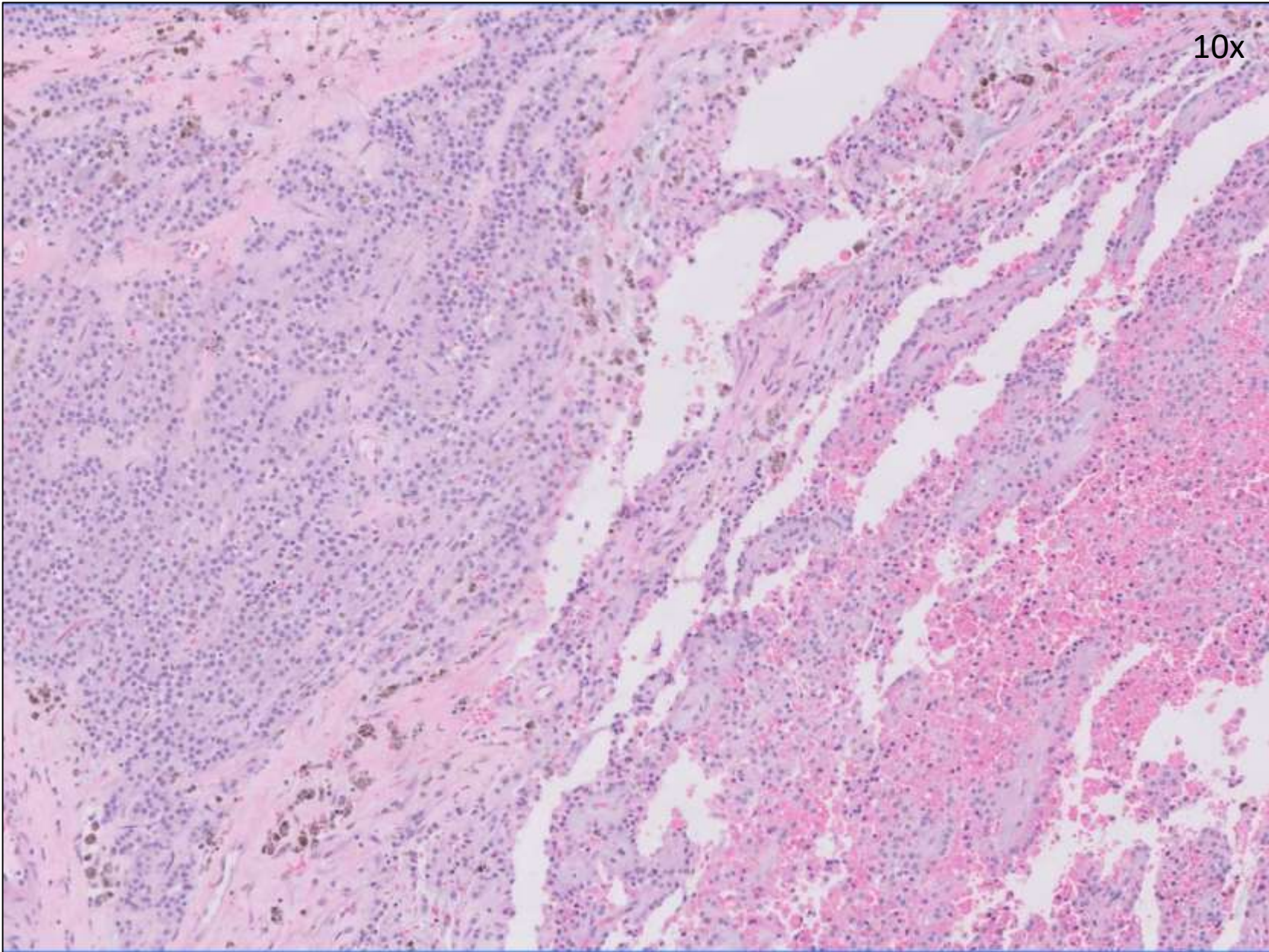
23-0202

Kevin Lu/Cynthia Gasper; UCSF
Teenage F with left ovarian cyst.

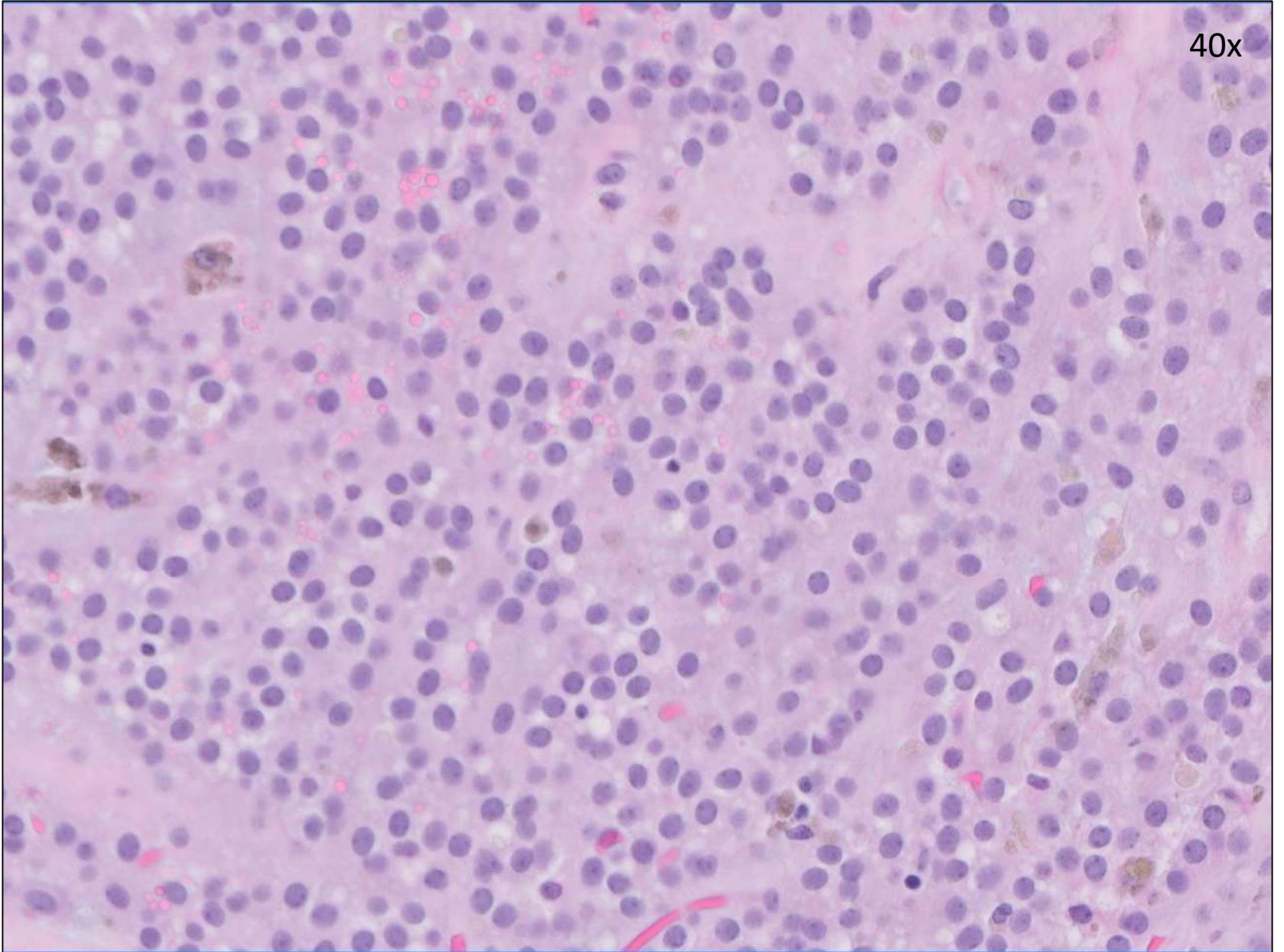
0.5x



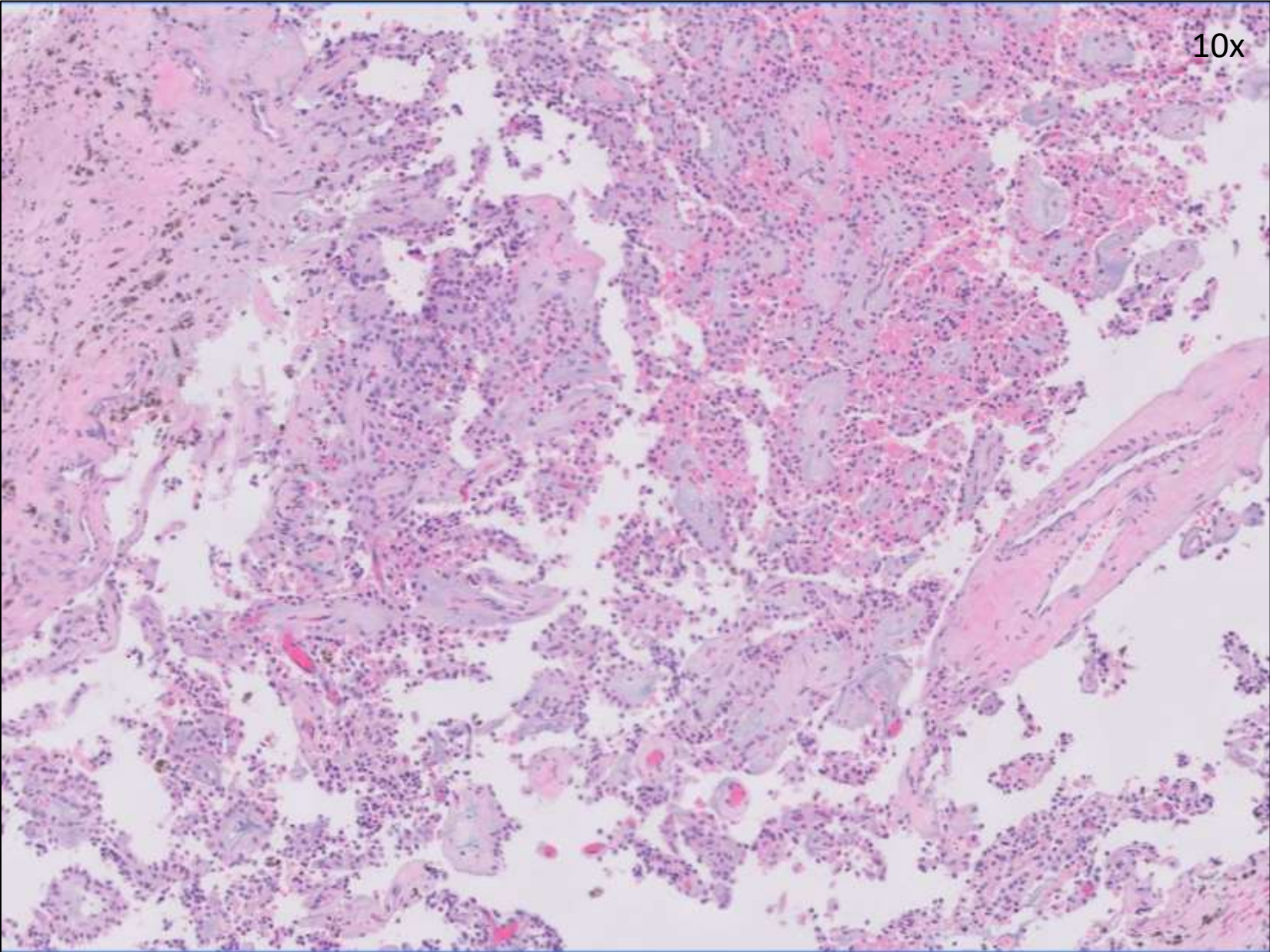
10x



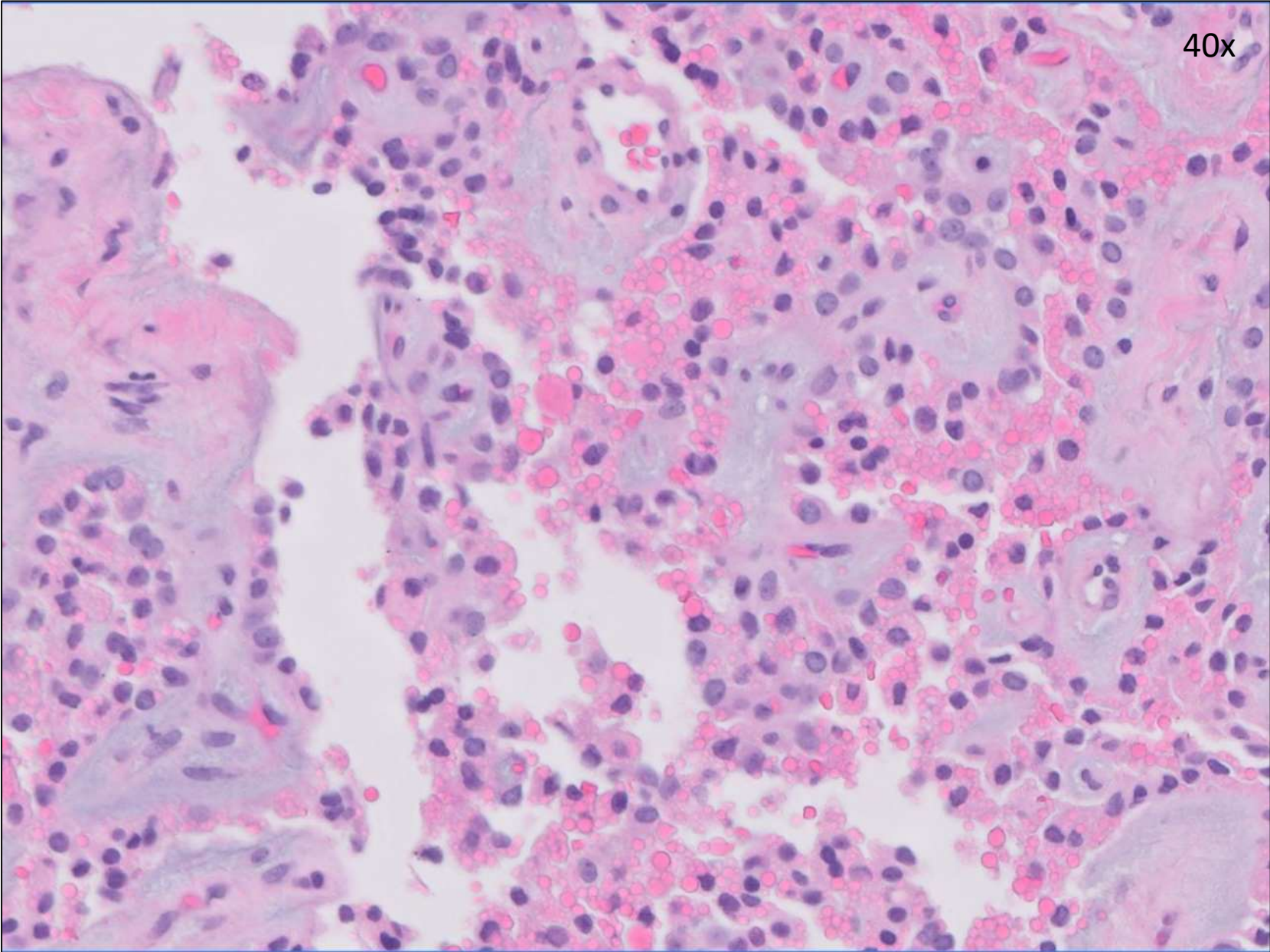
40x



10x



40x



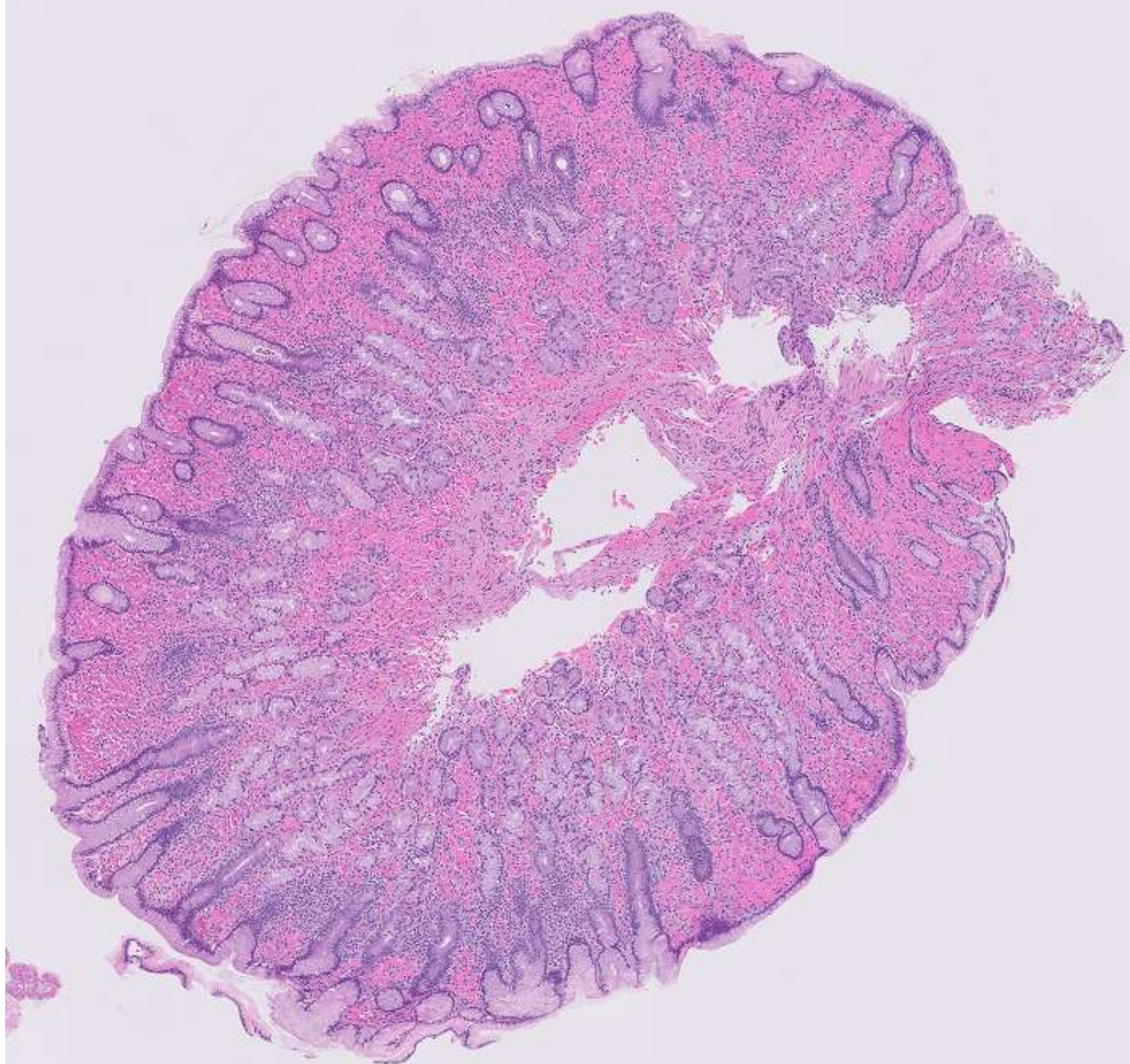
DIAGNOSIS?



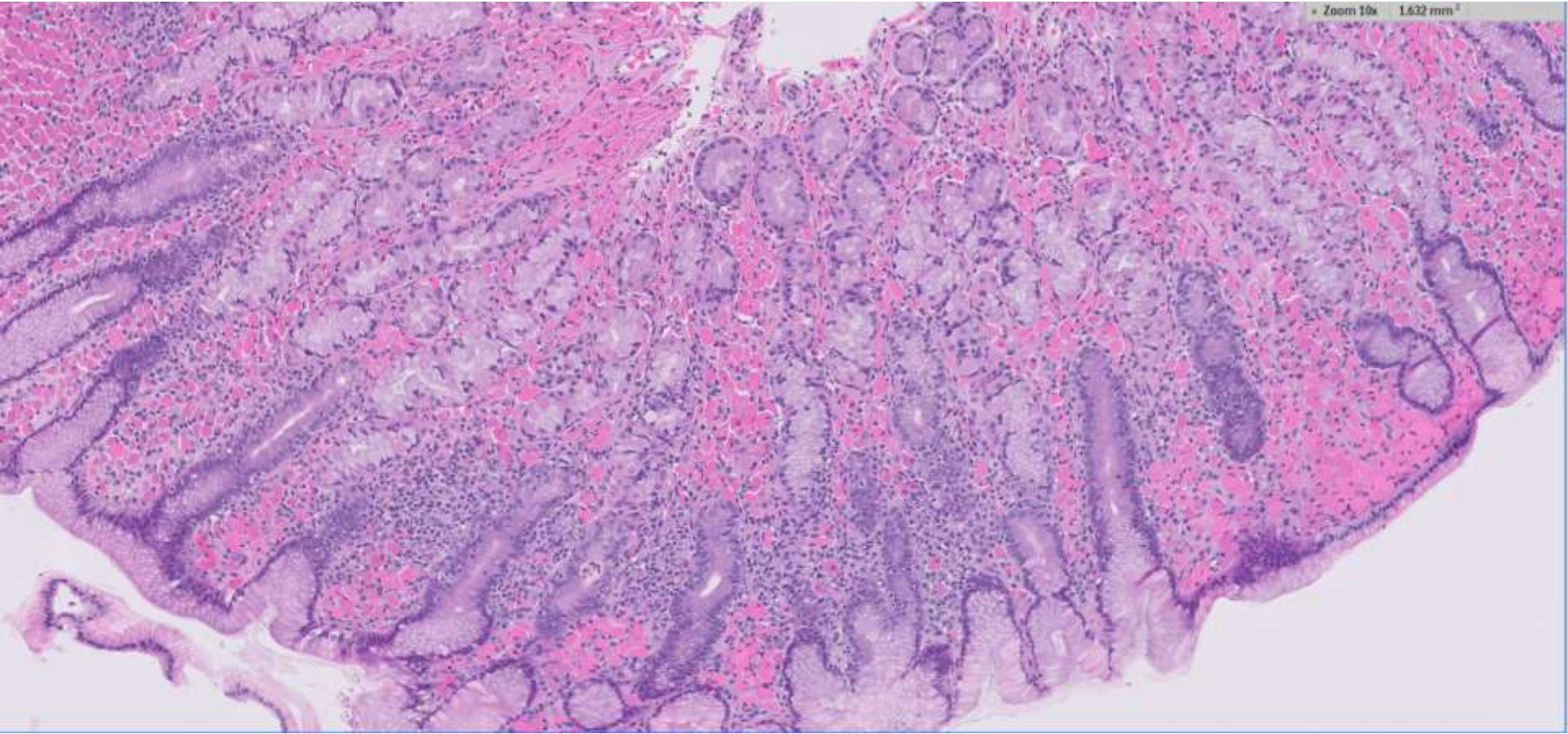
23-0203

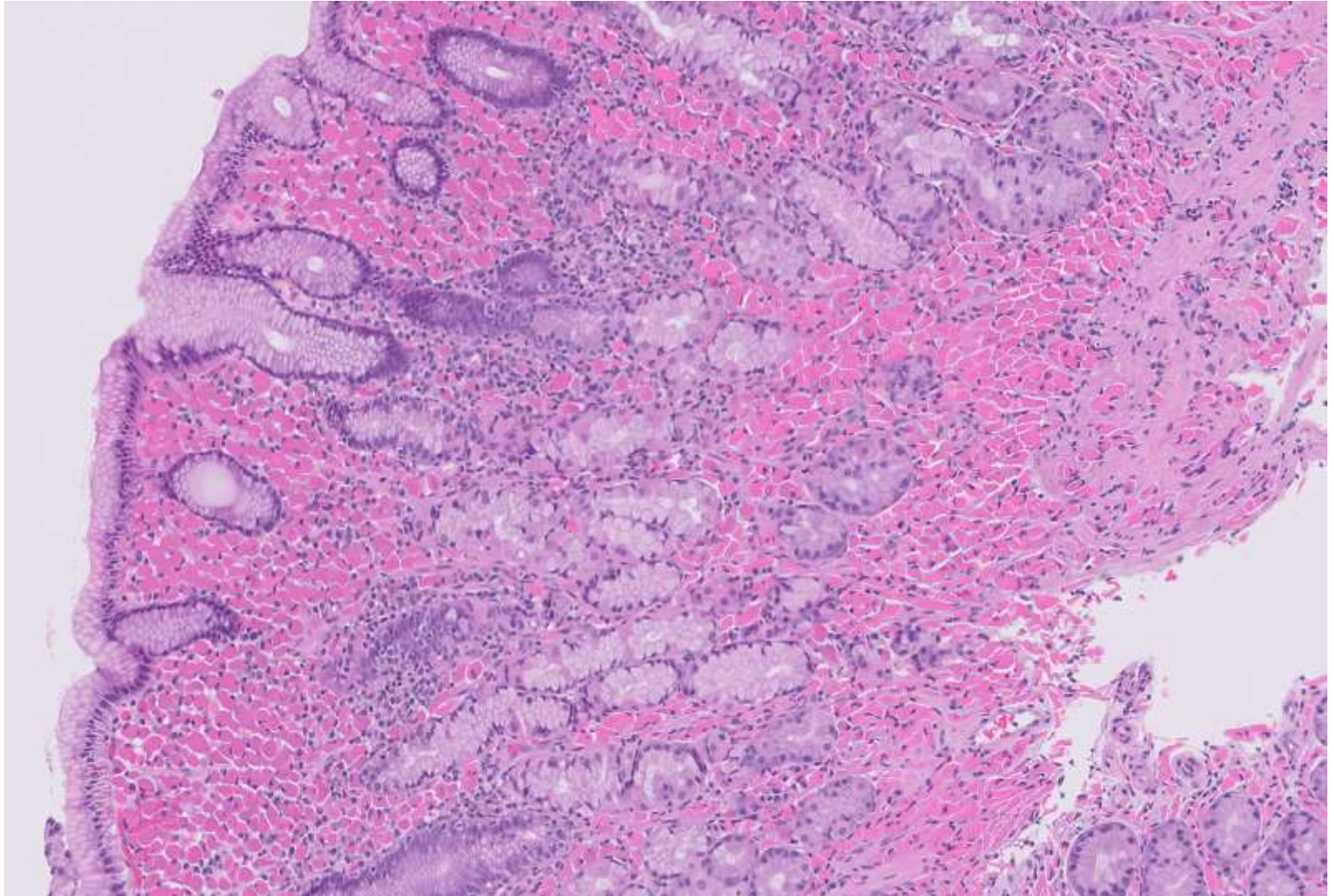
Eric Ollila/Megan Troxell; Stanford

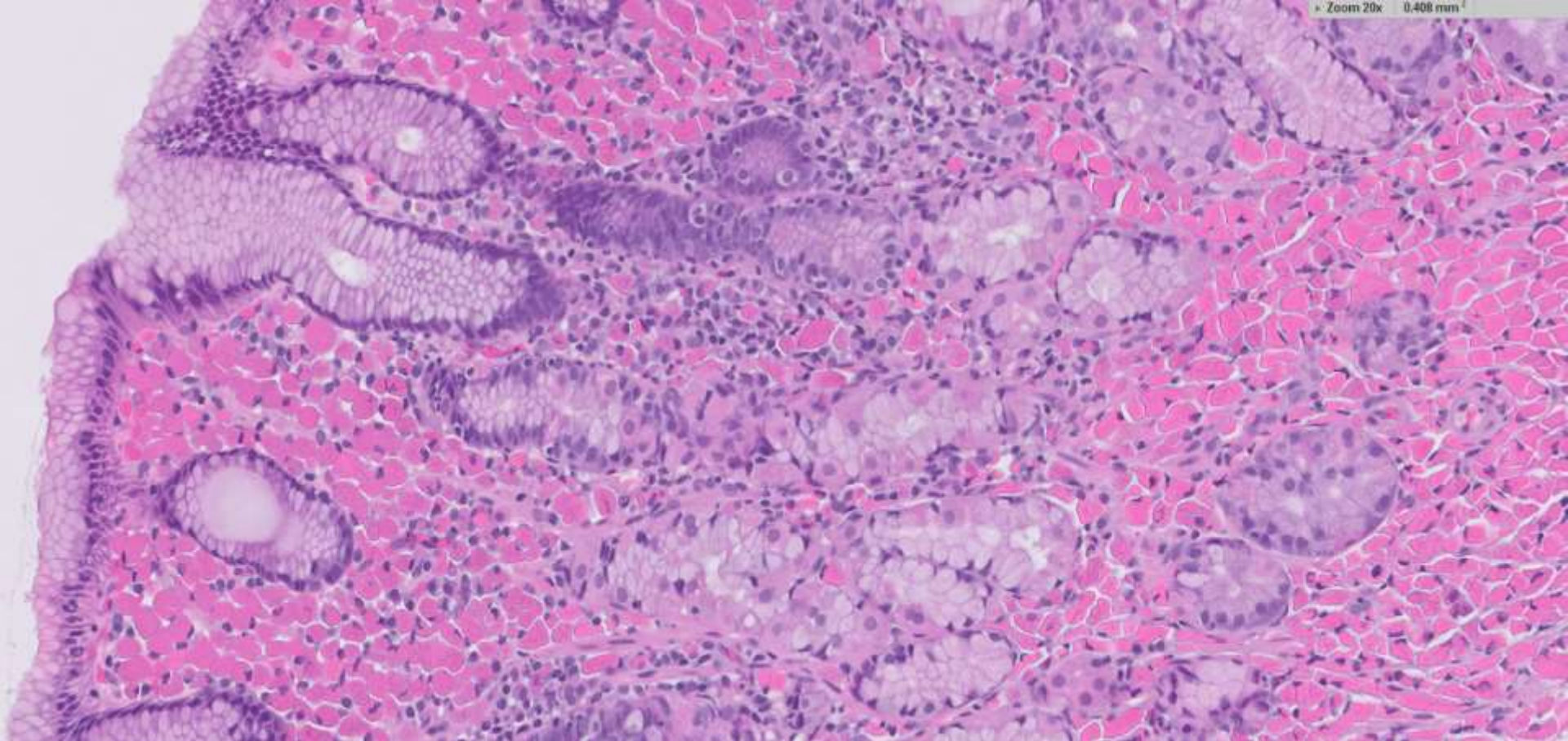
70ish M with h/o intrahepatic cholangiocarcinoma. EGD showed erosive gastritis in the antrum, incisura, and body.

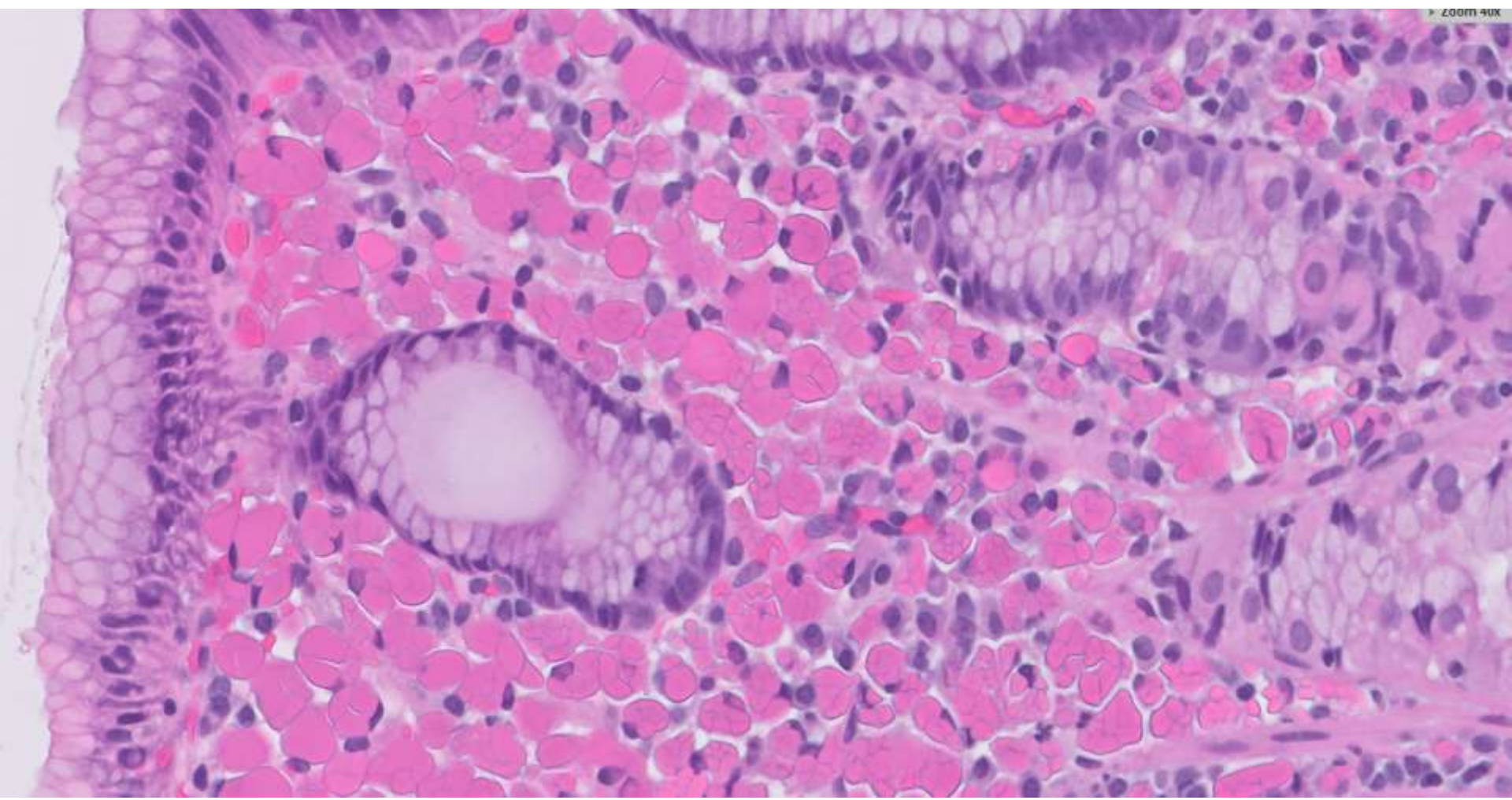


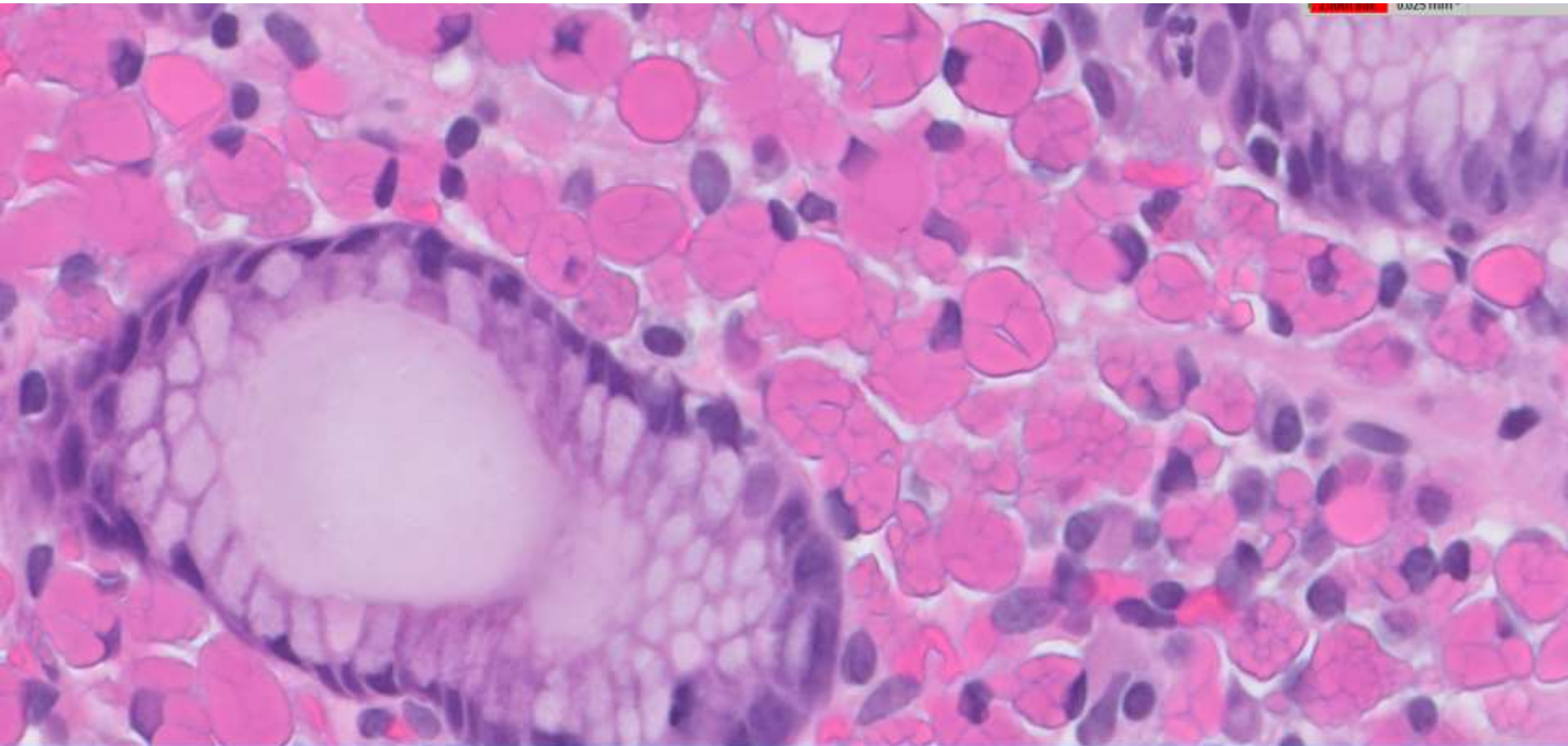
• Zoom 10x 1.632 mm²











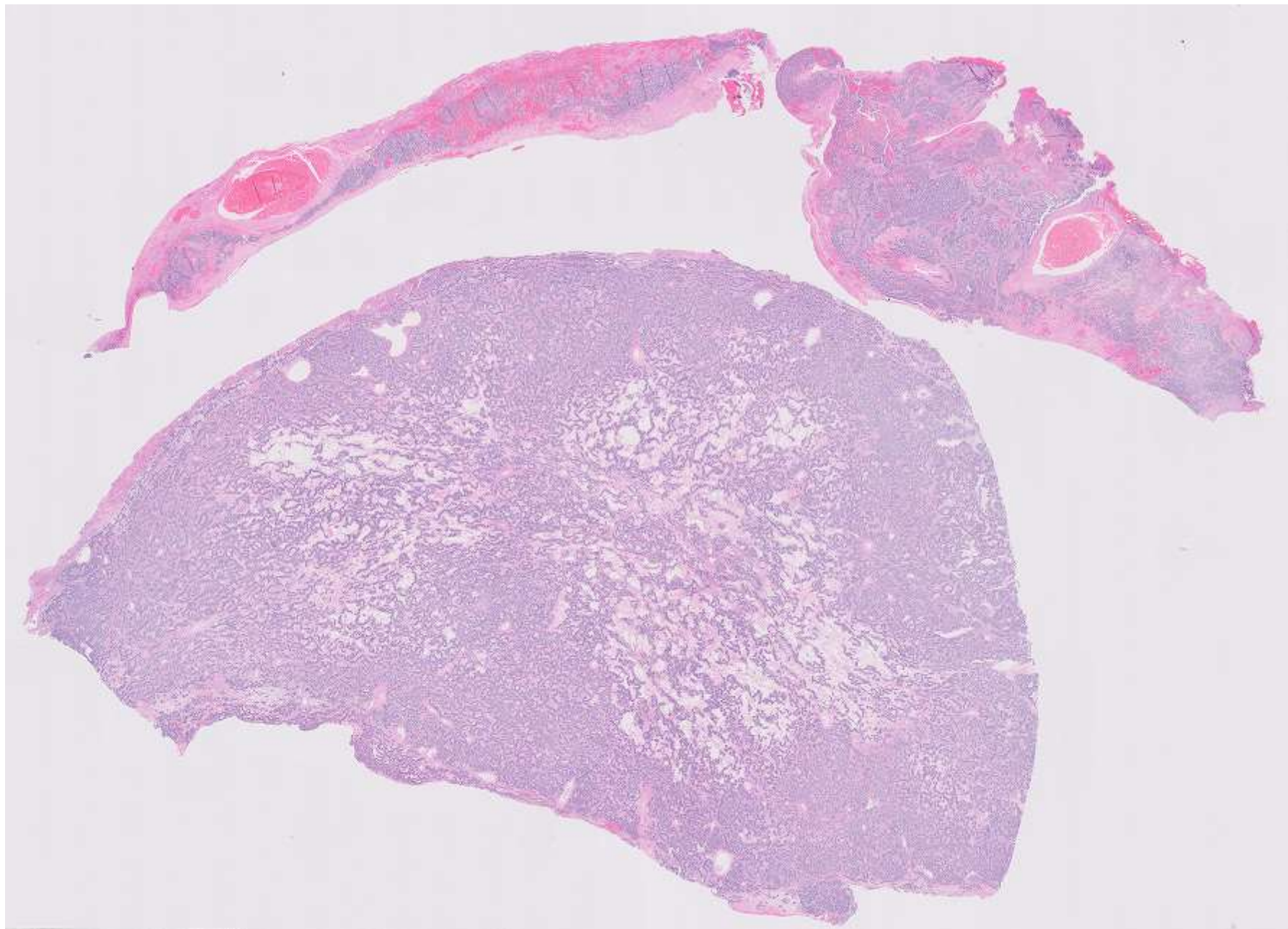
DIAGNOSIS?

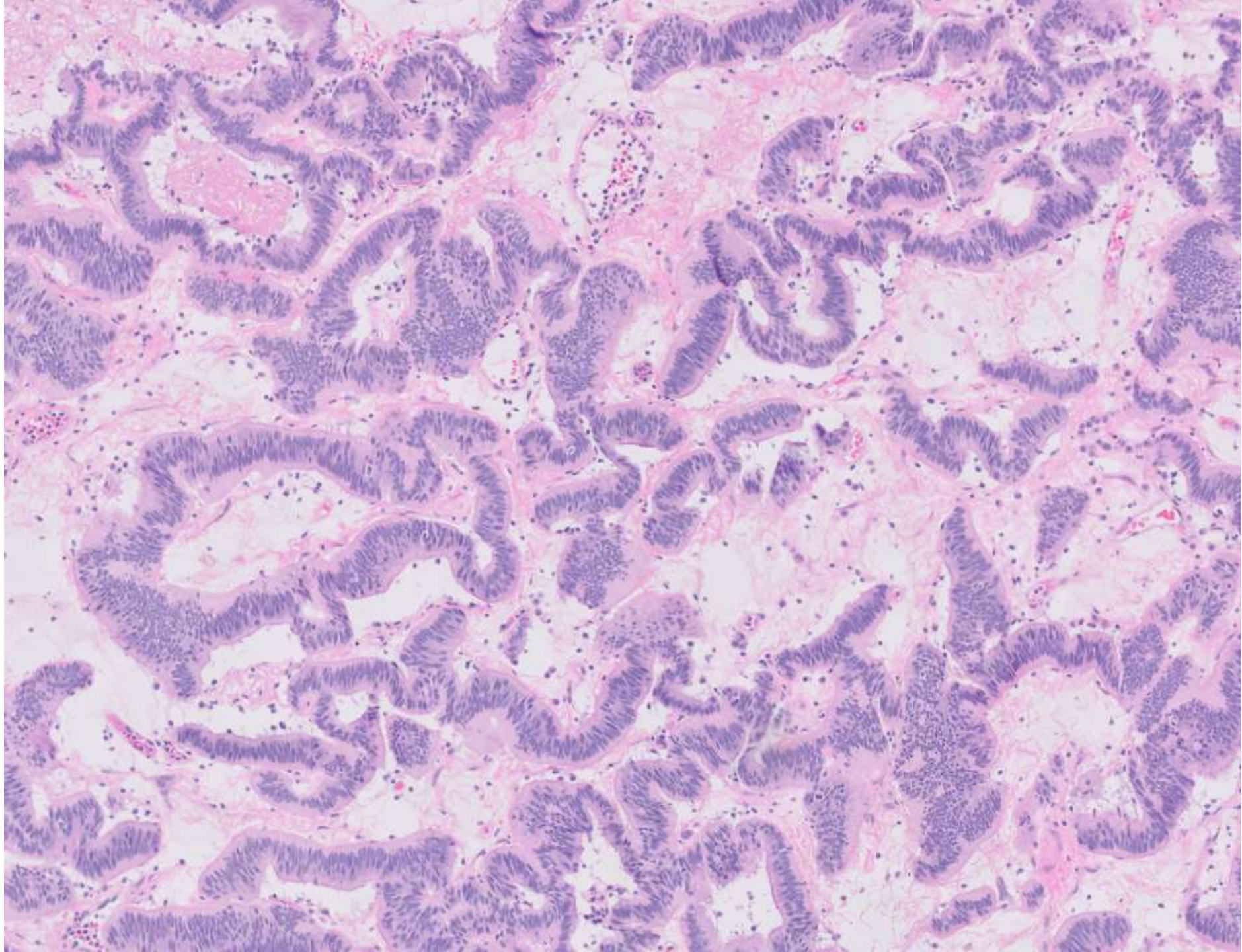


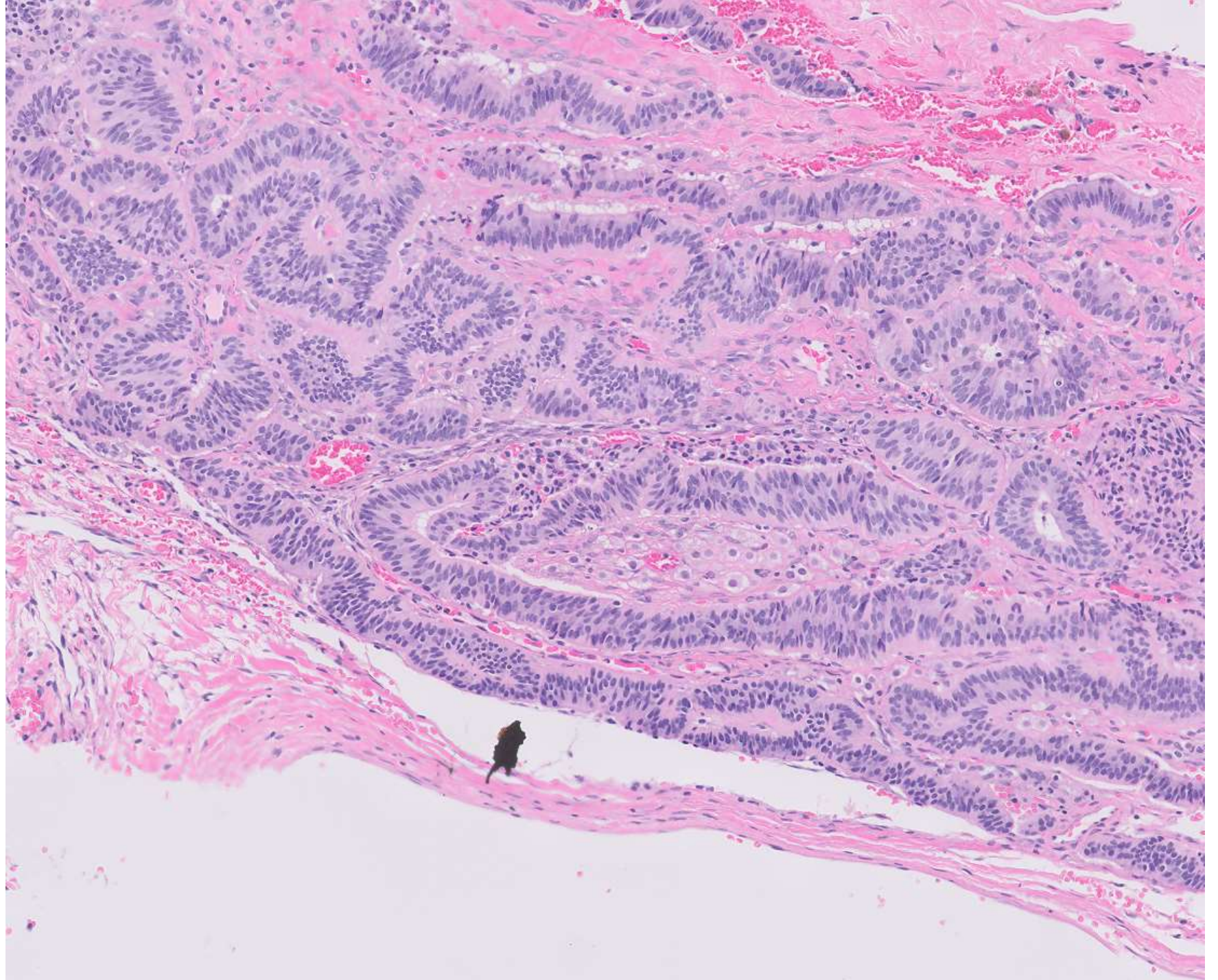
23-0204

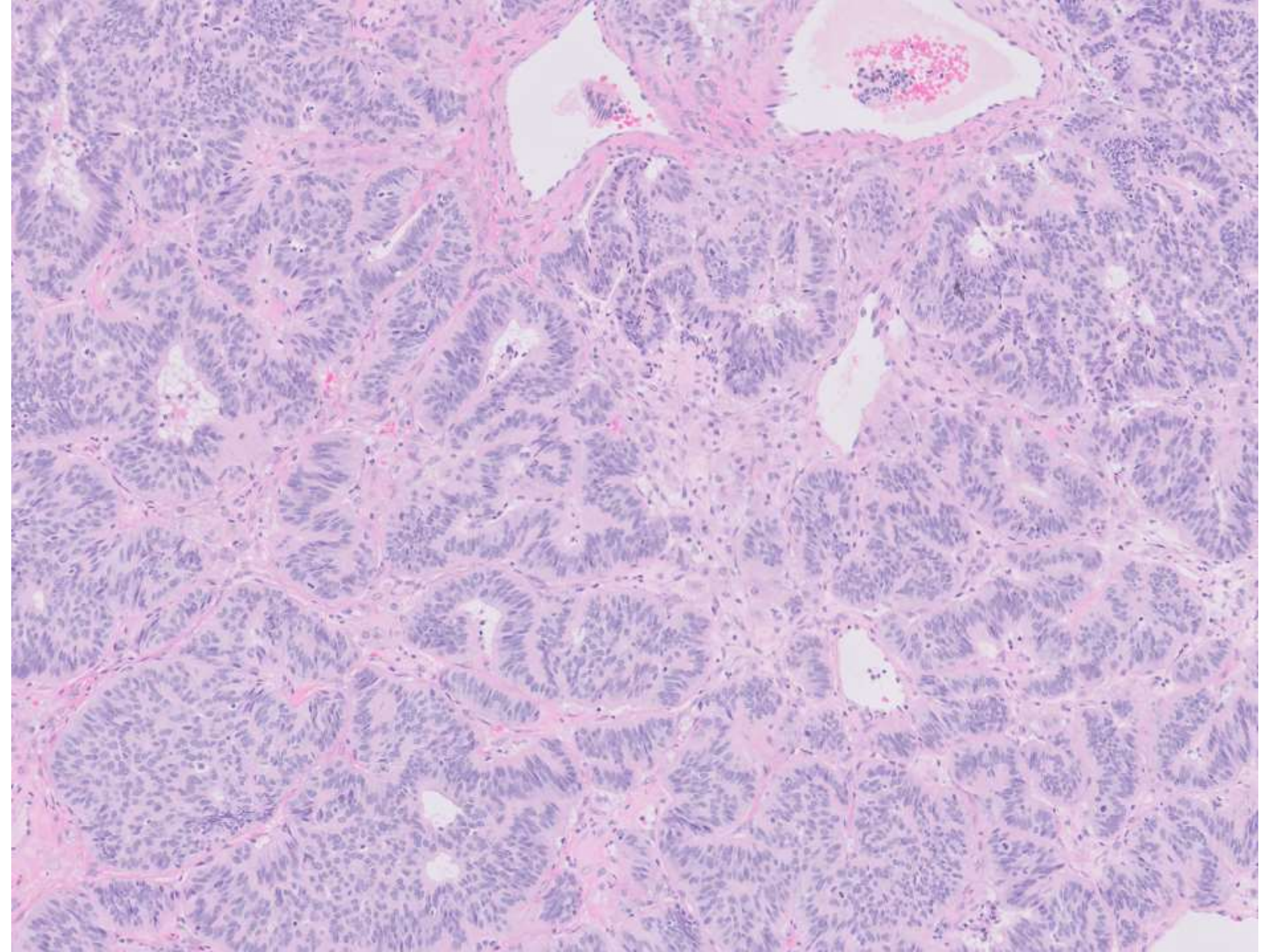
Ruth Zhang/Cynthia Gasper; UCSF

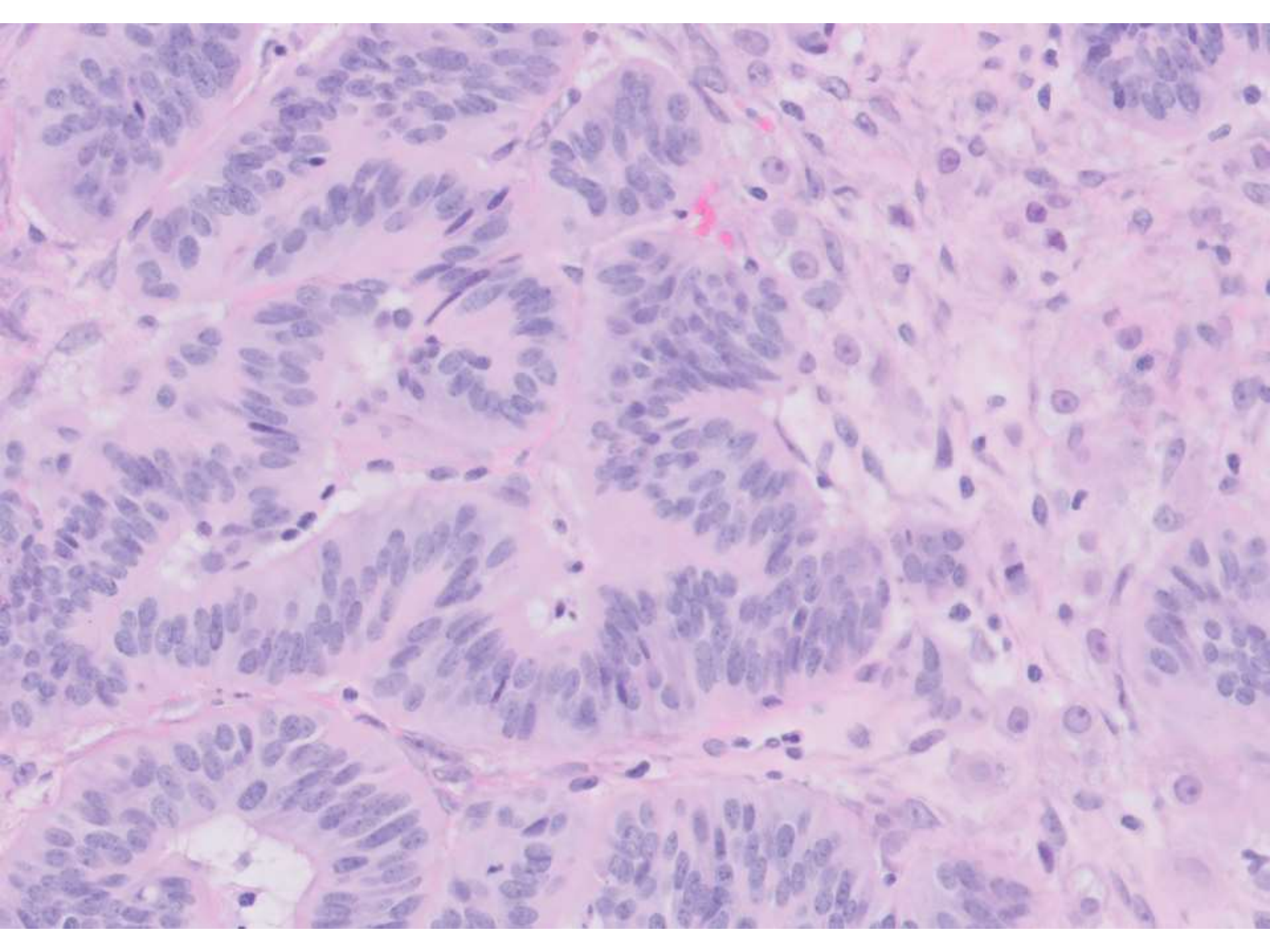
30ish F with left ovarian cyst, clinically thought to be dermoid cyst.











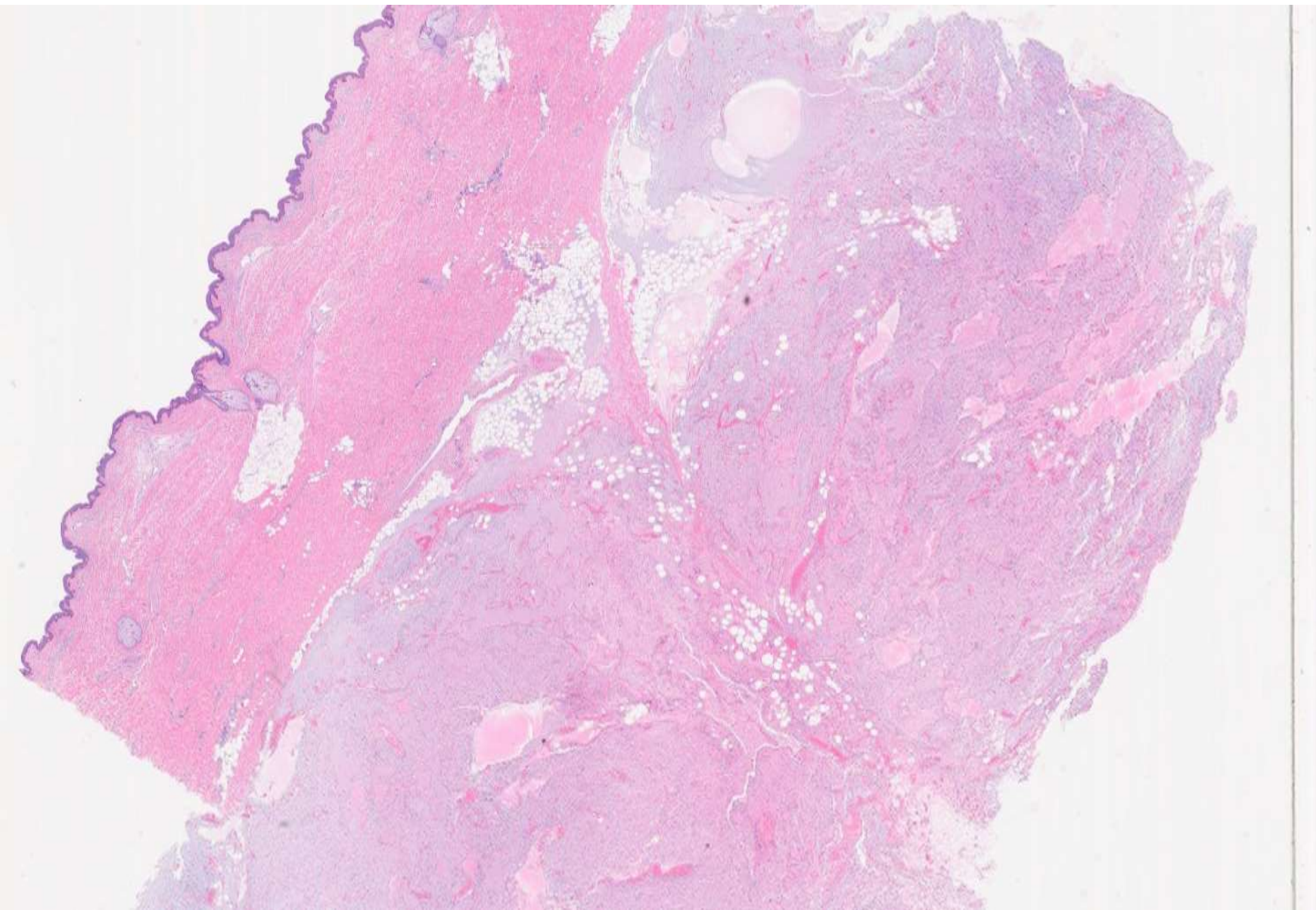
DIAGNOSIS?

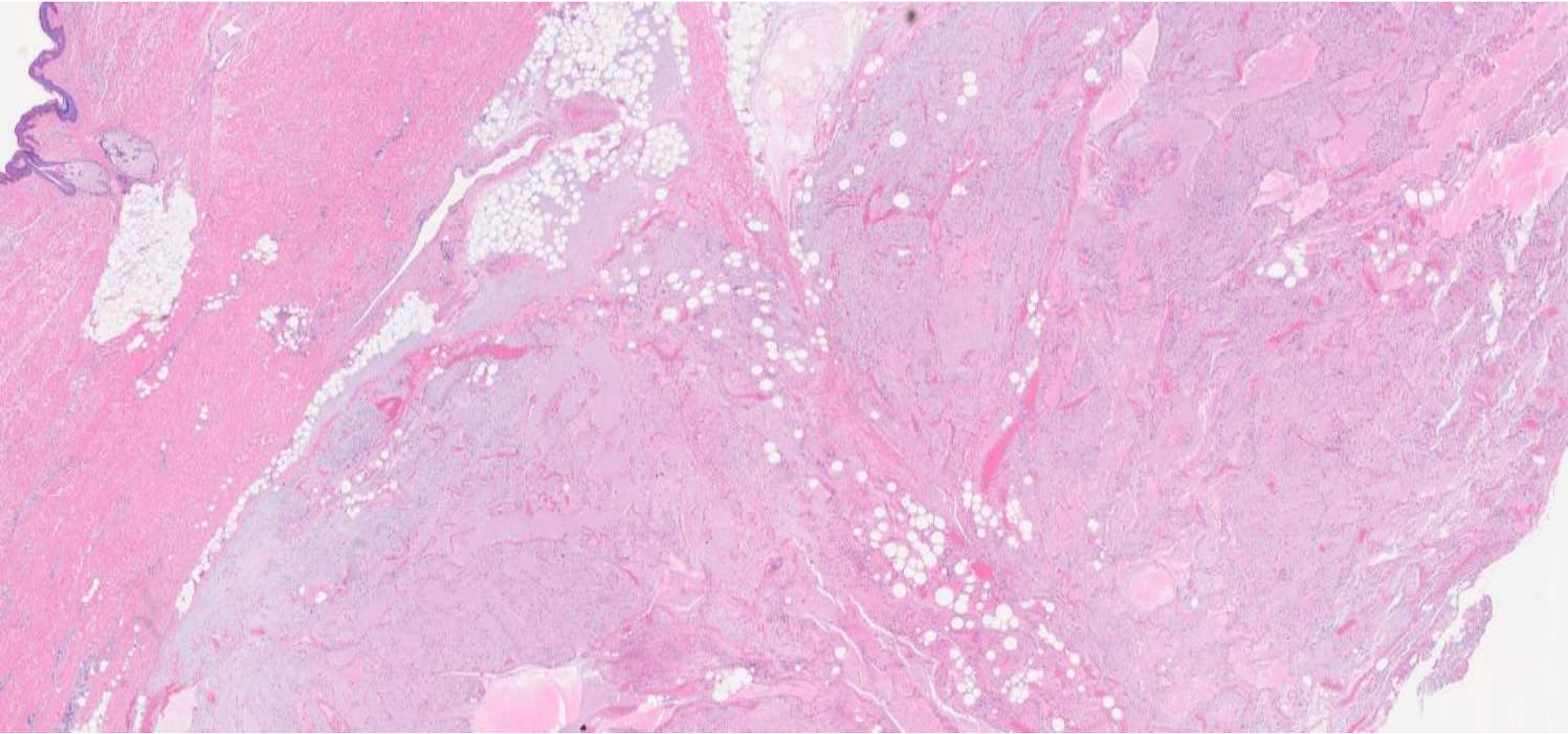


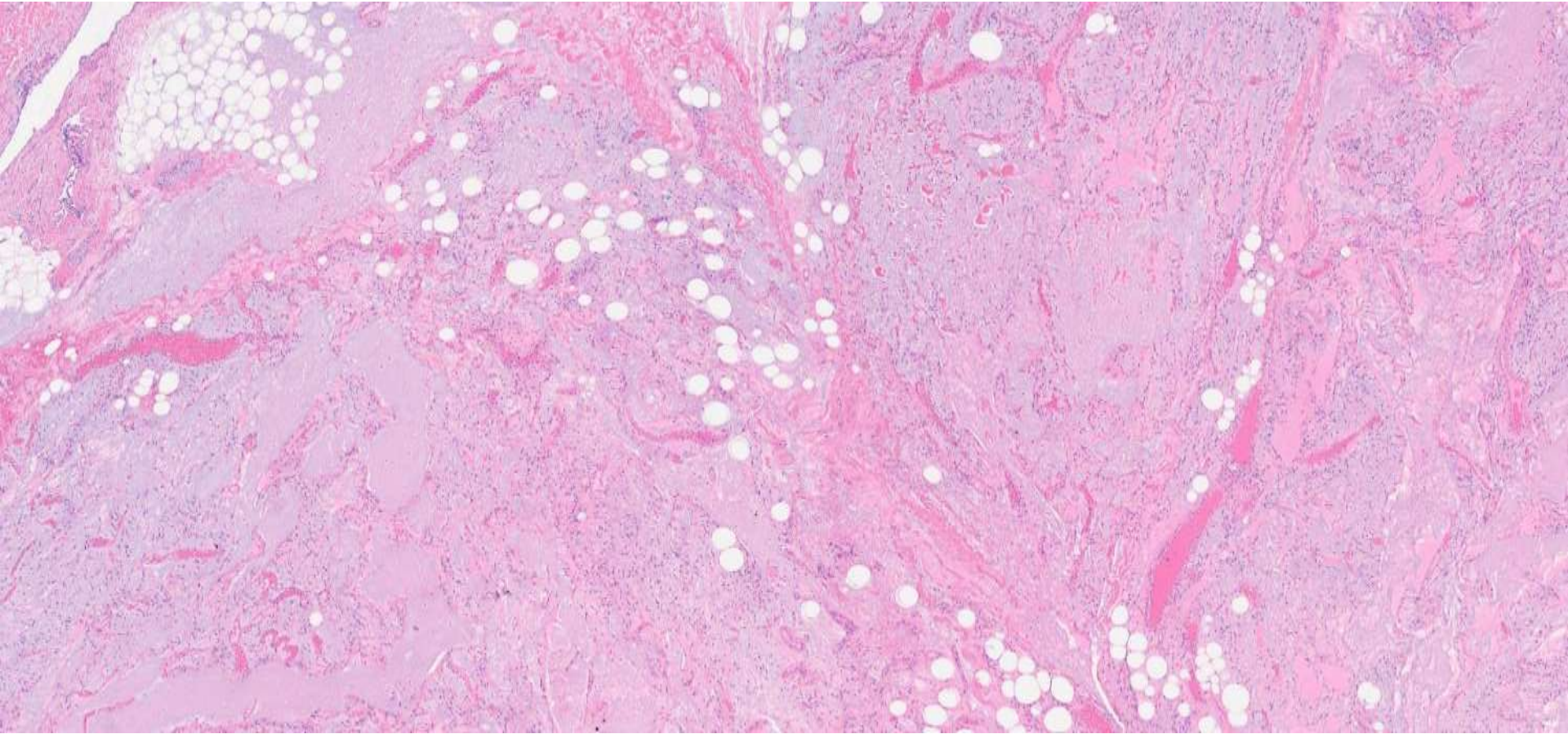
23-1205

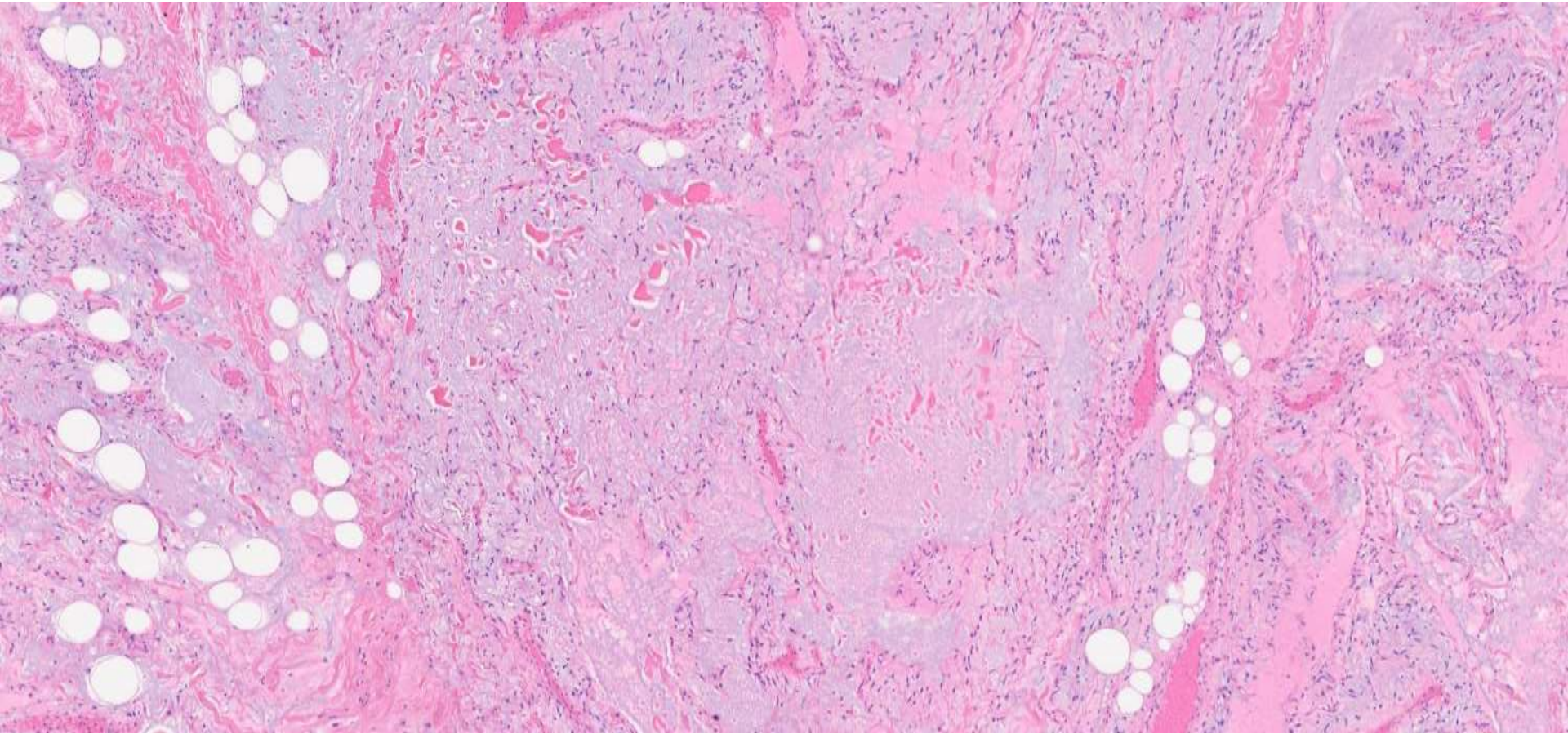
Harris Goodman; Alameda Health

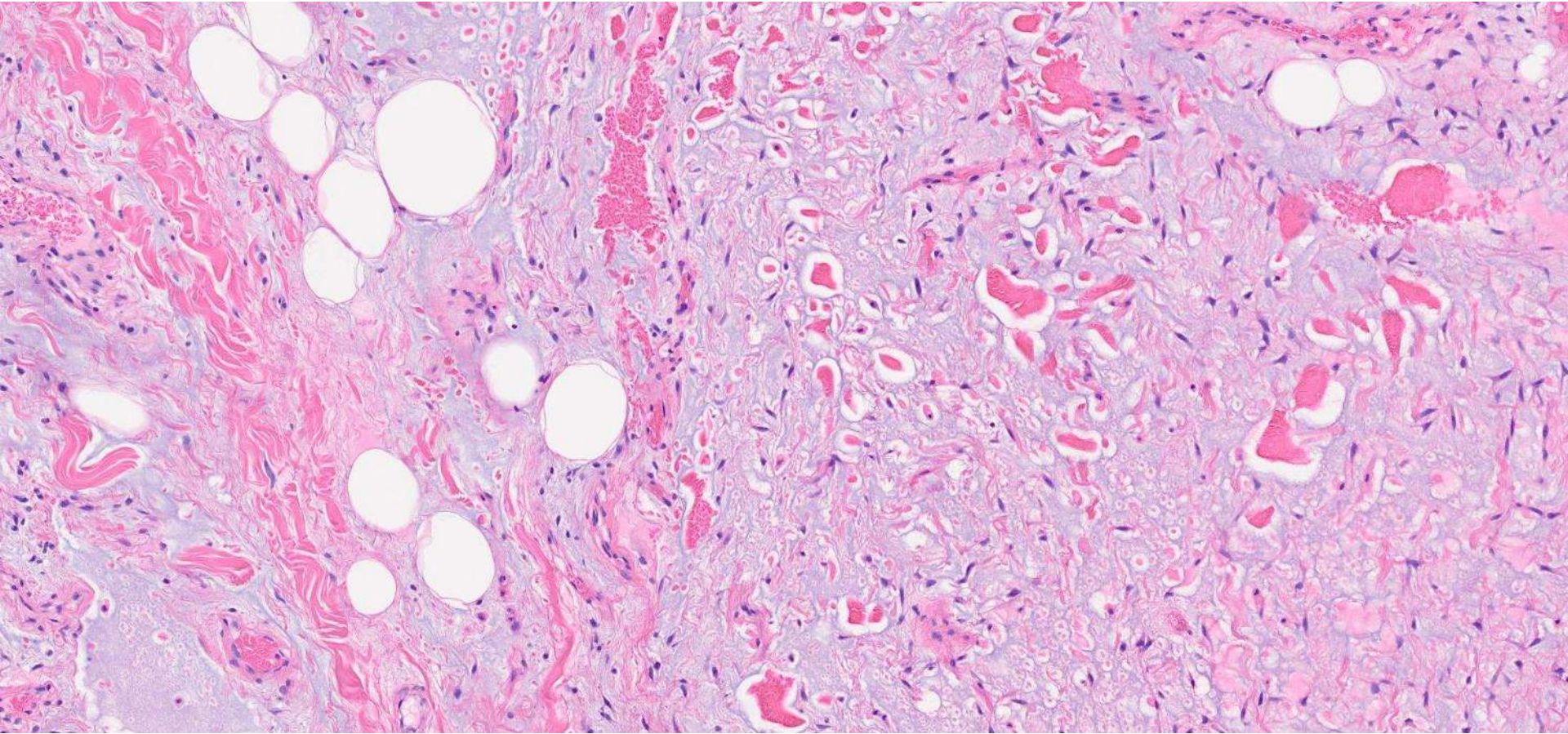
40ish M with right shoulder mass noticed 6 months ago. He thought it arose from a spider bite. MRI showed a multilobulated mass.

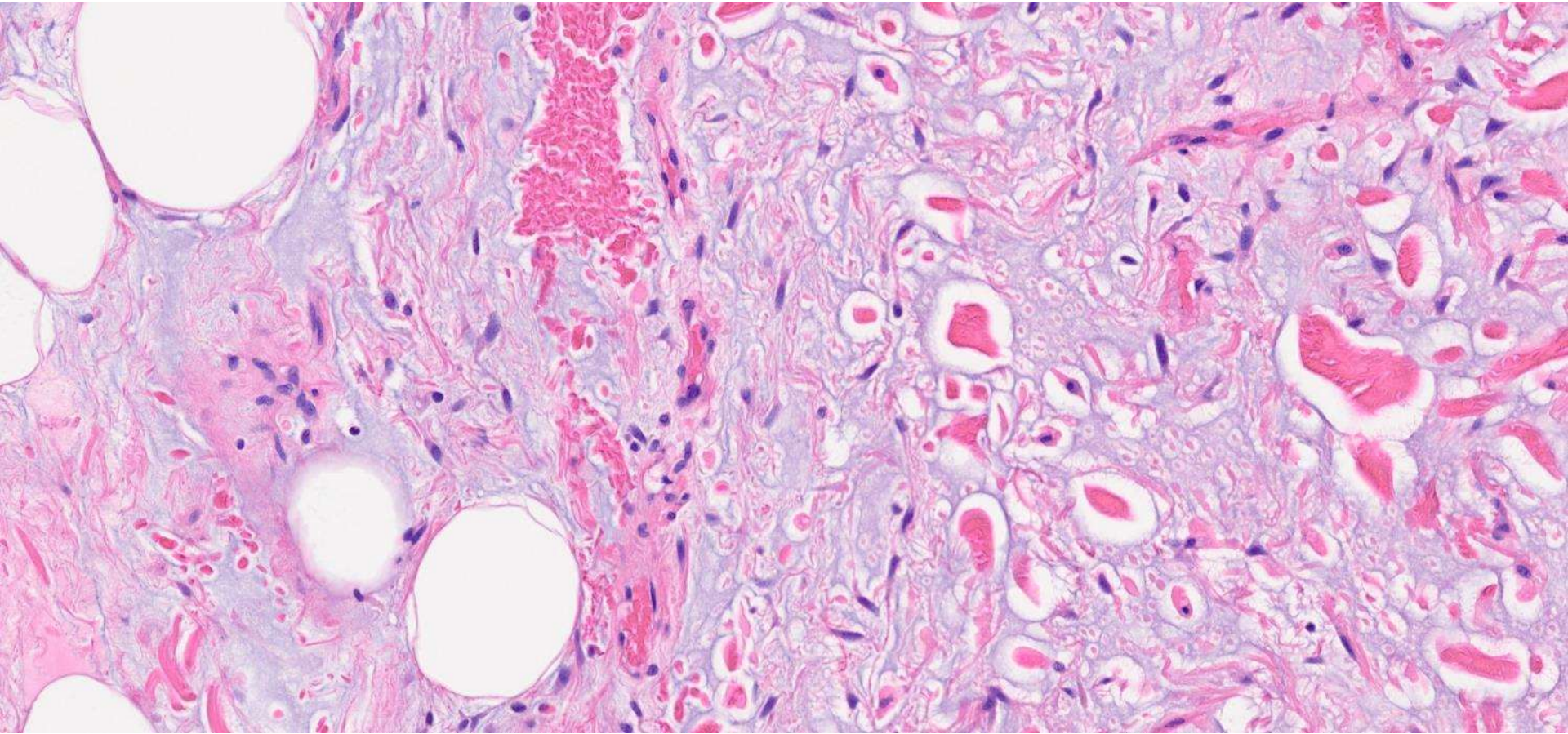


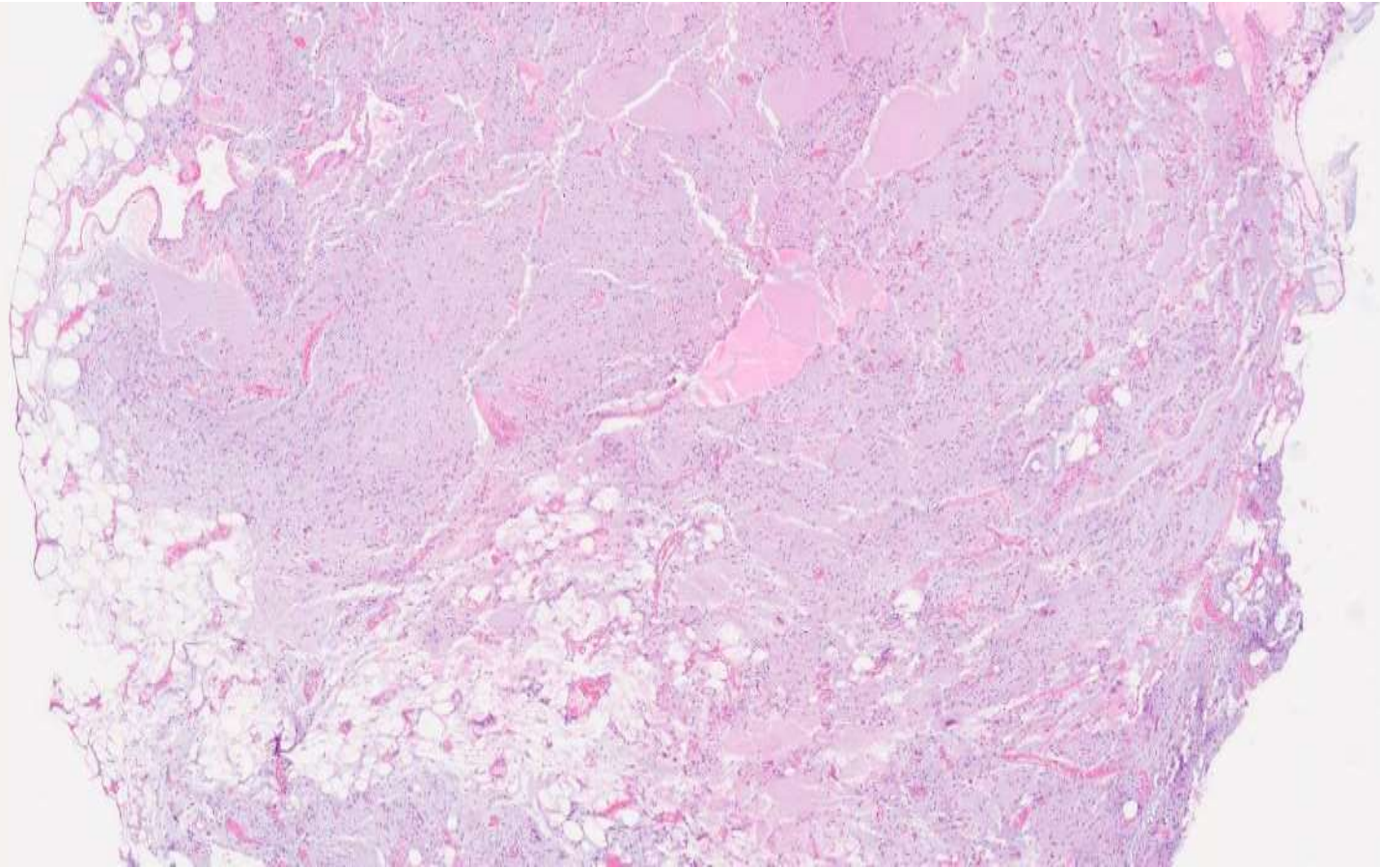


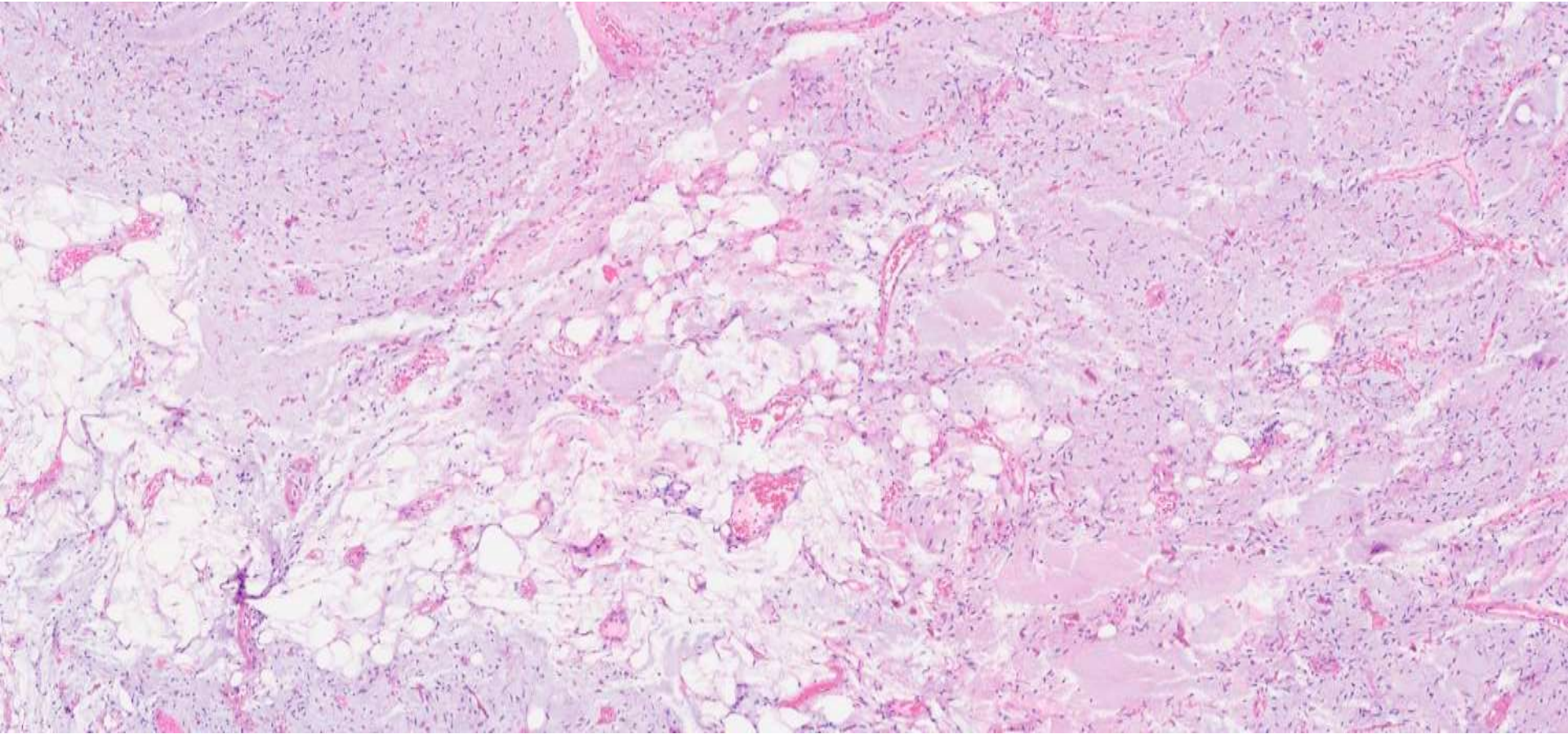


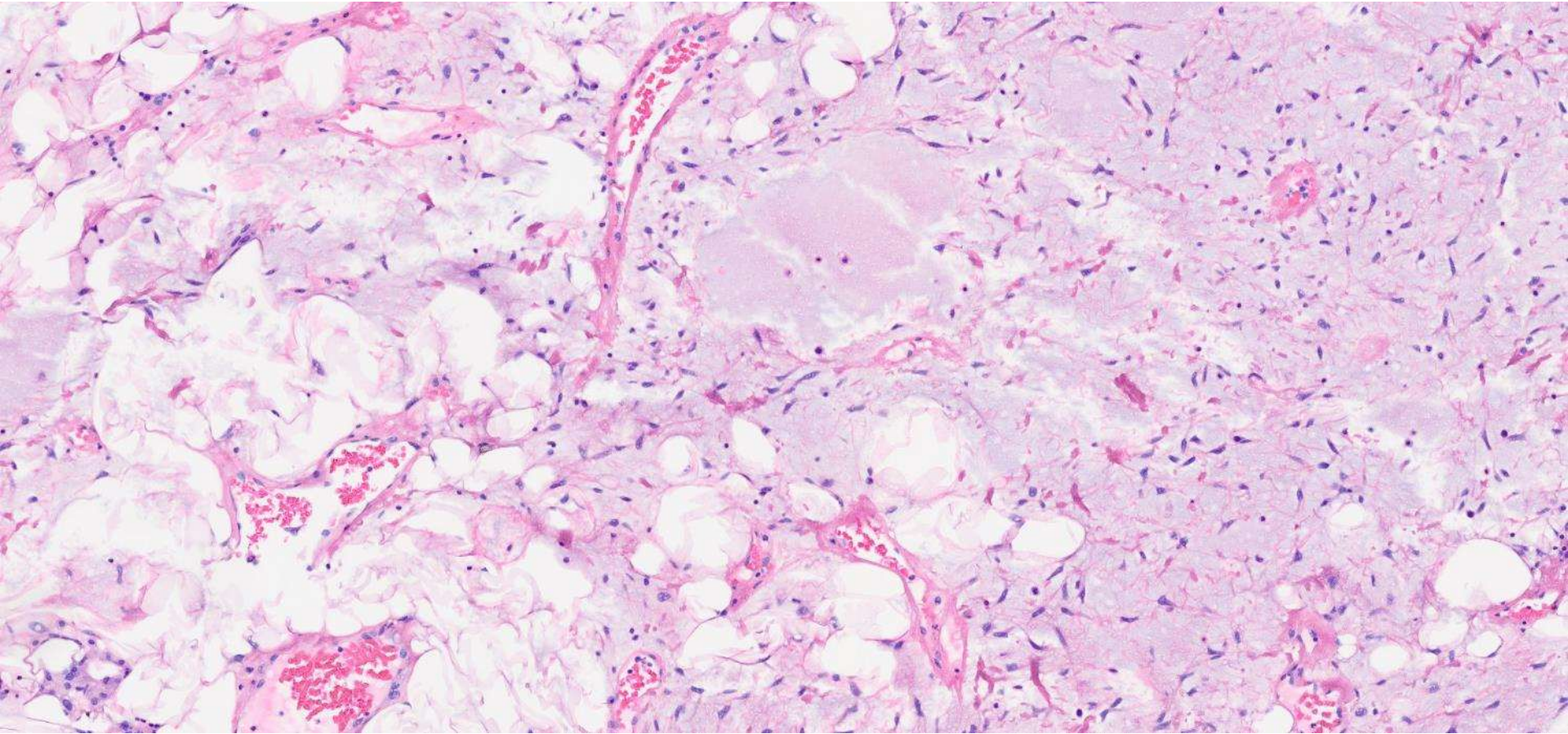












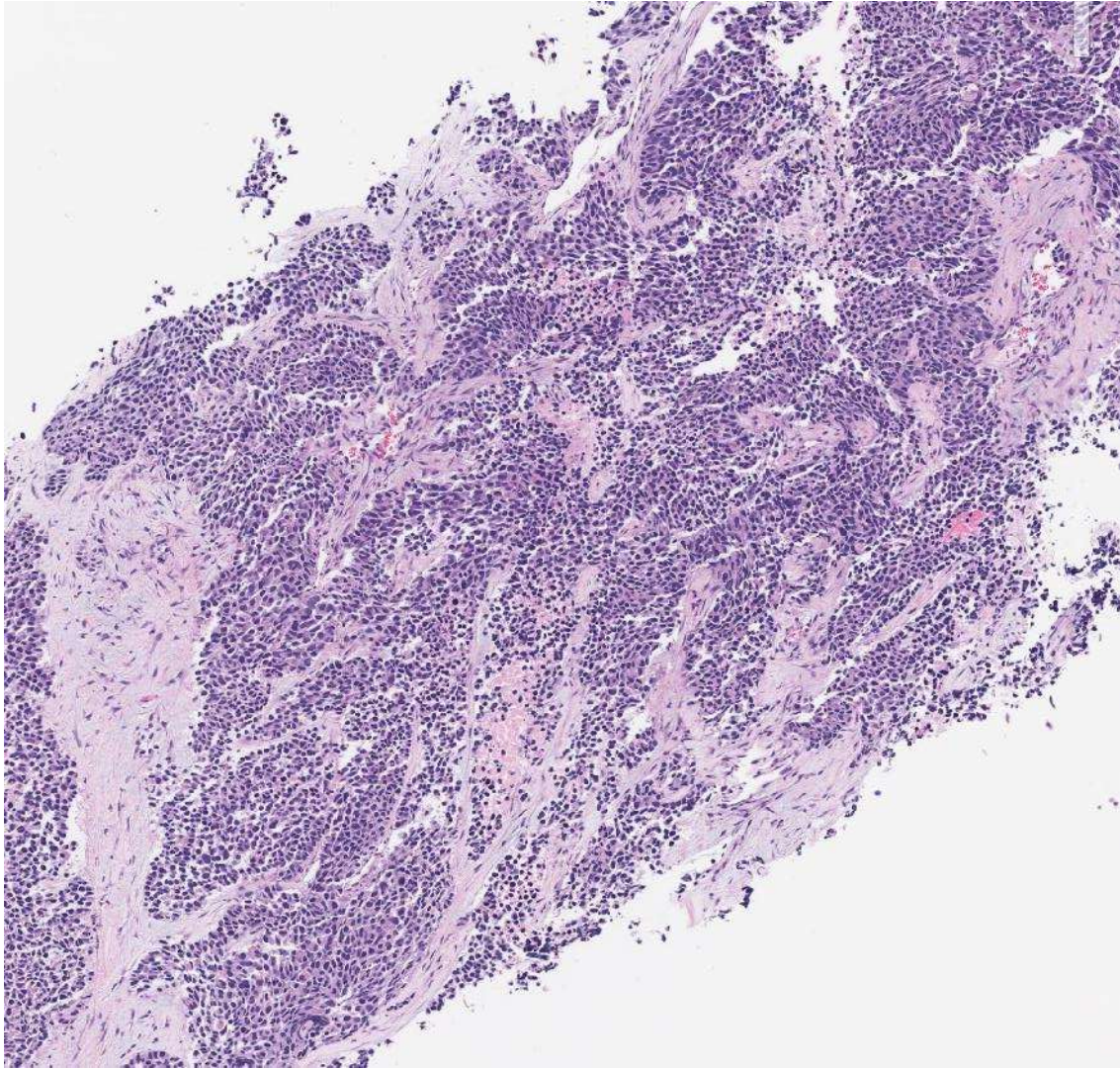
DIAGNOSIS?

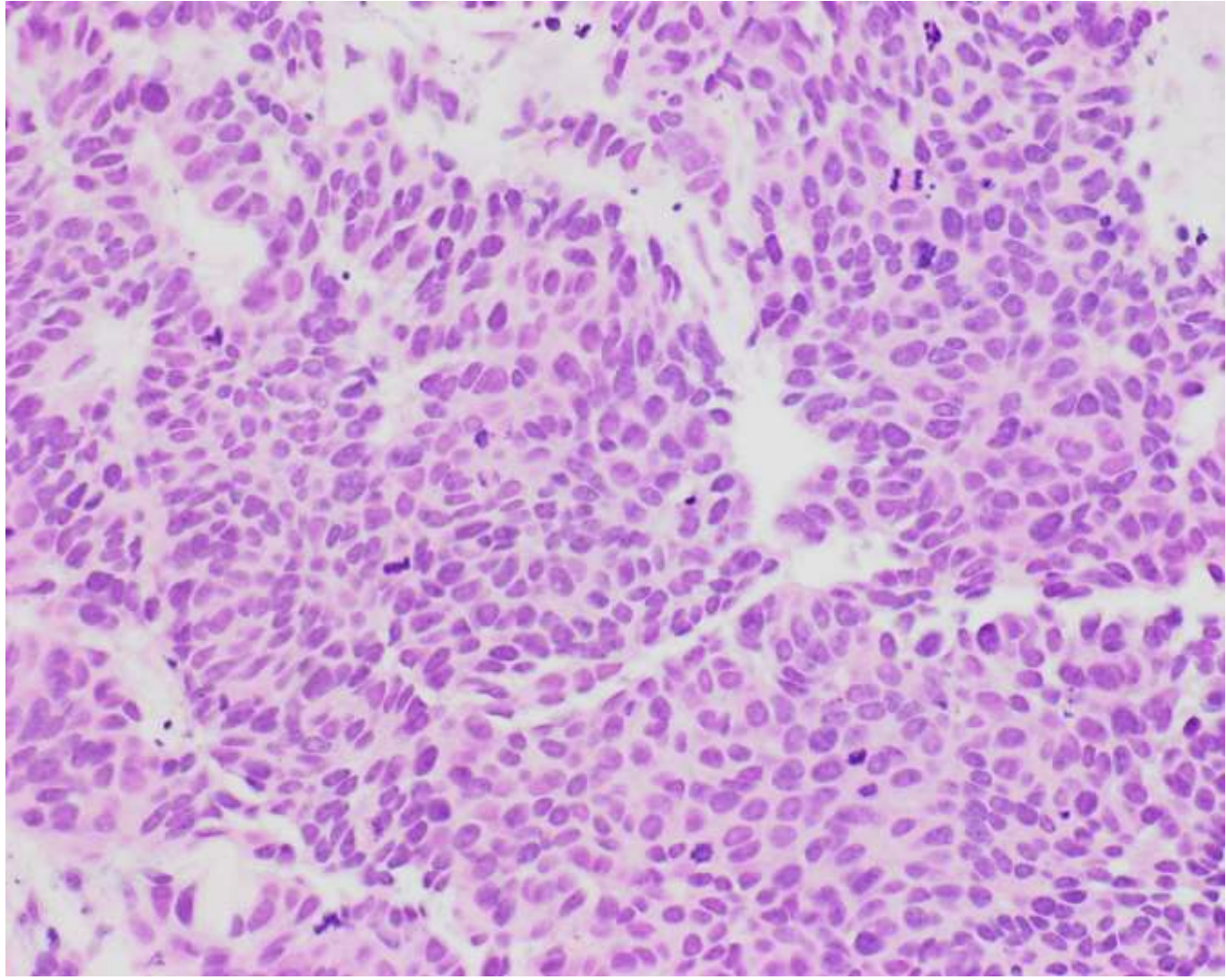


23-0206

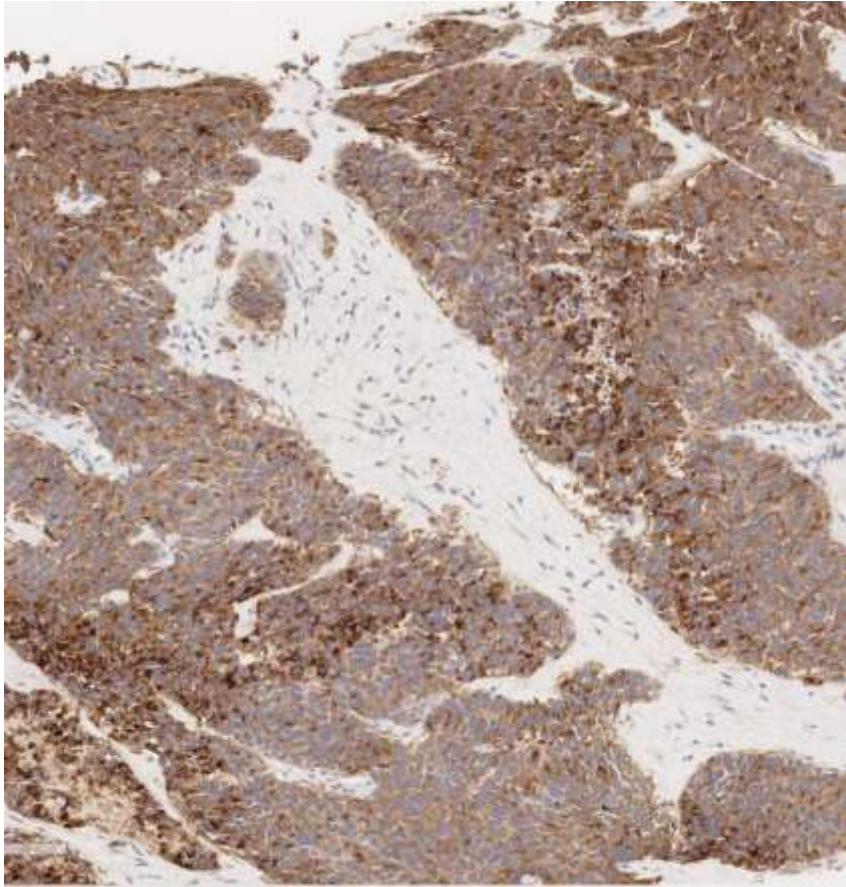
Nancy Joseph, UCSF

60ish F with pancreatic and liver masses. Undergoes liver mass biopsy.

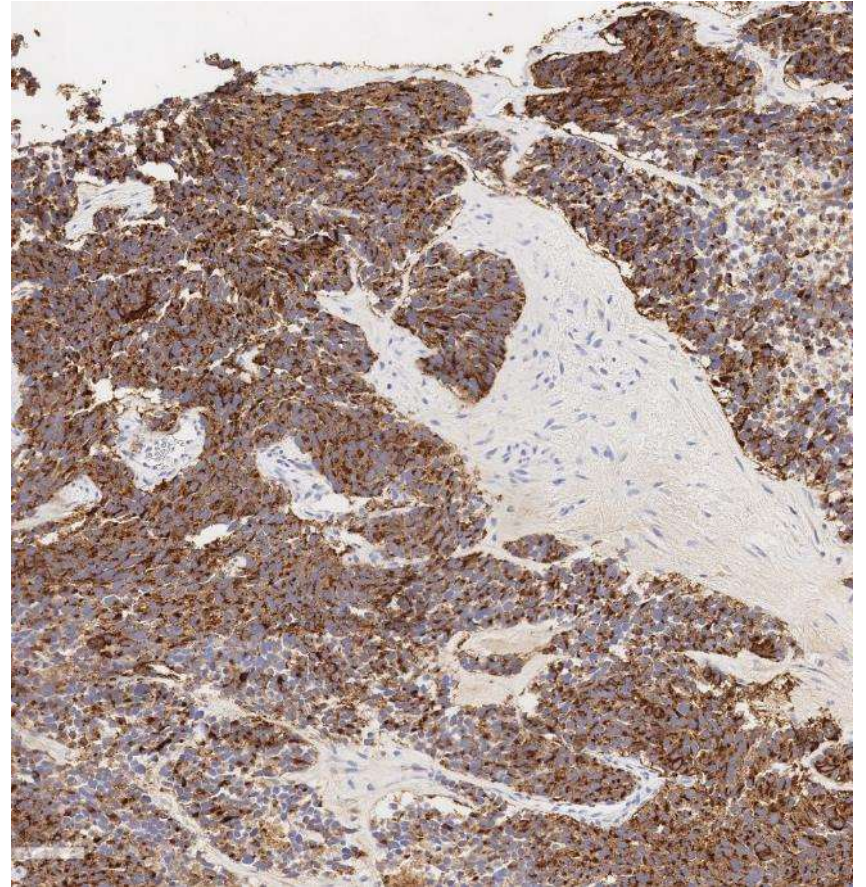




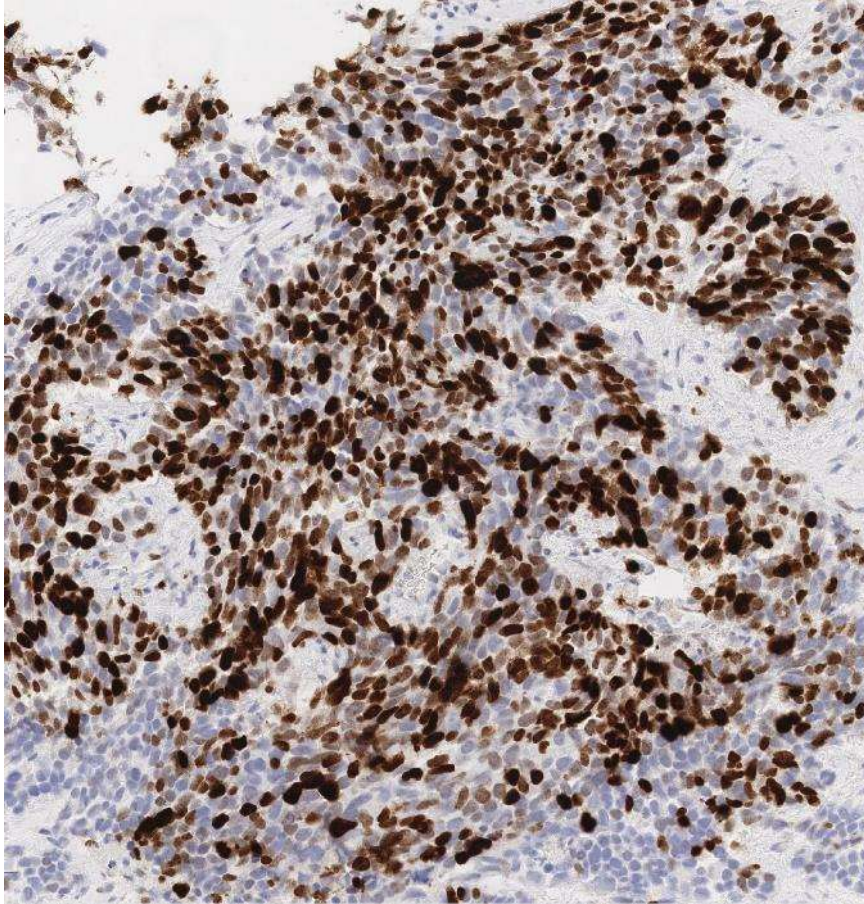
Synaptophysin



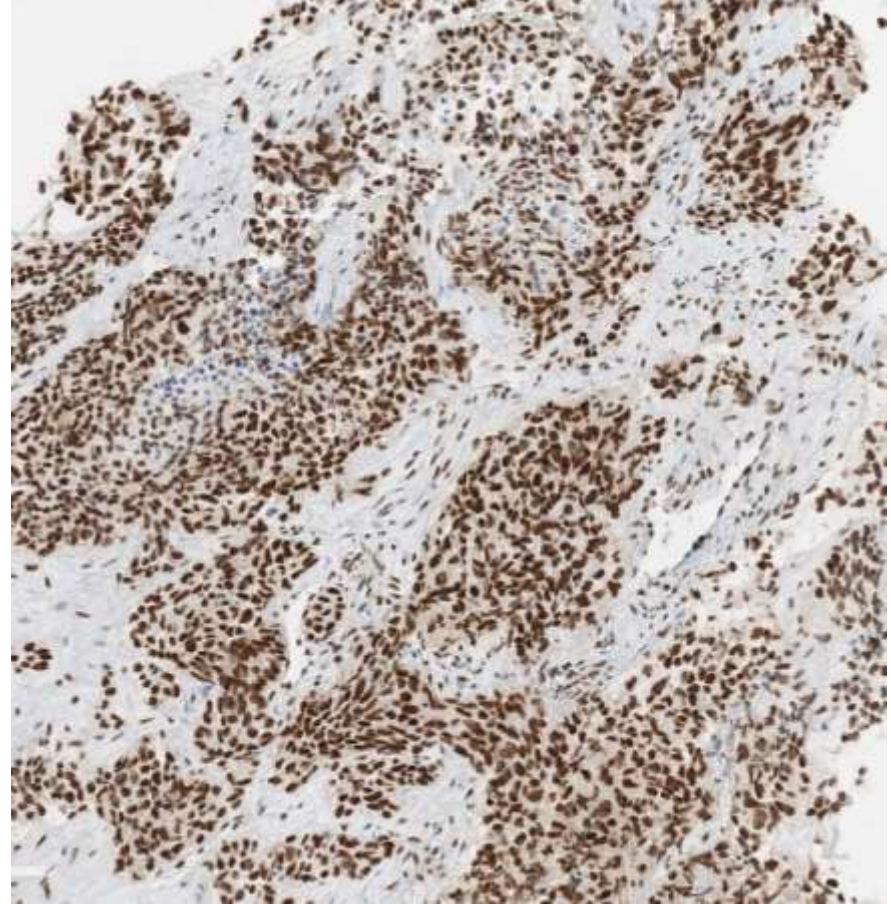
Chromogranin



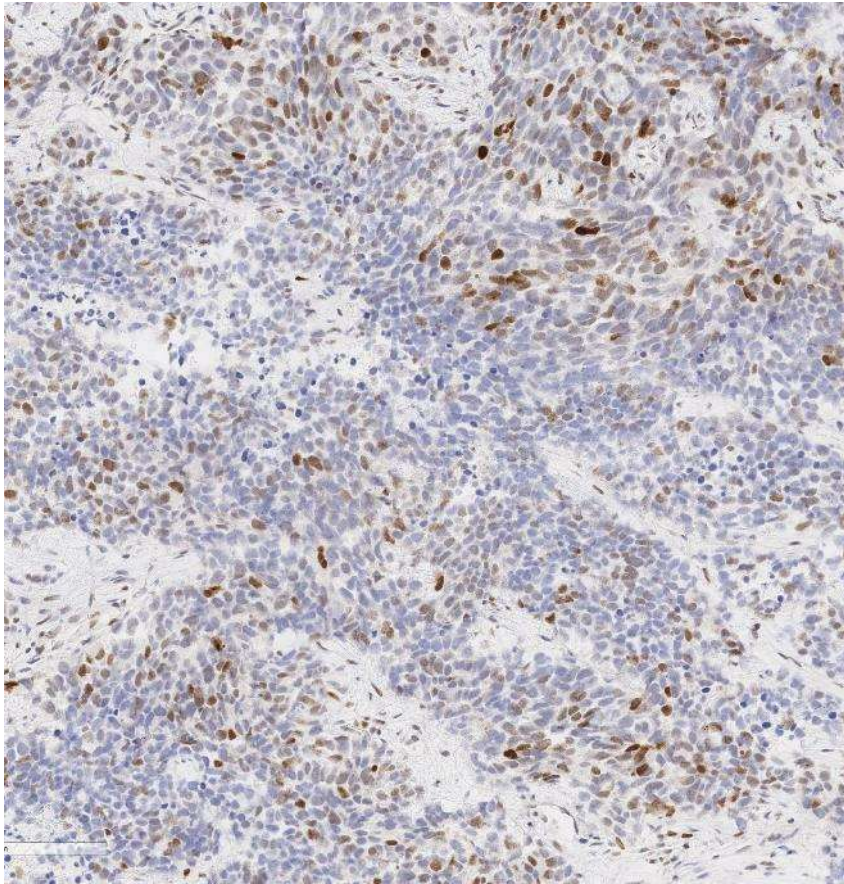
Ki-67



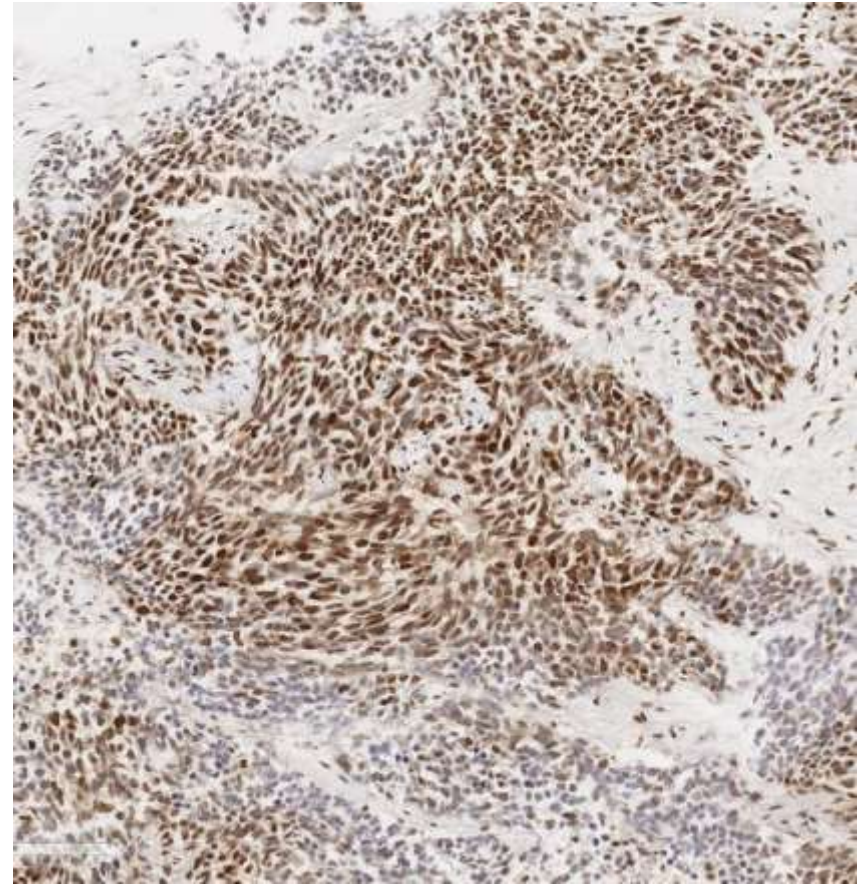
ATRX



p53



Rb



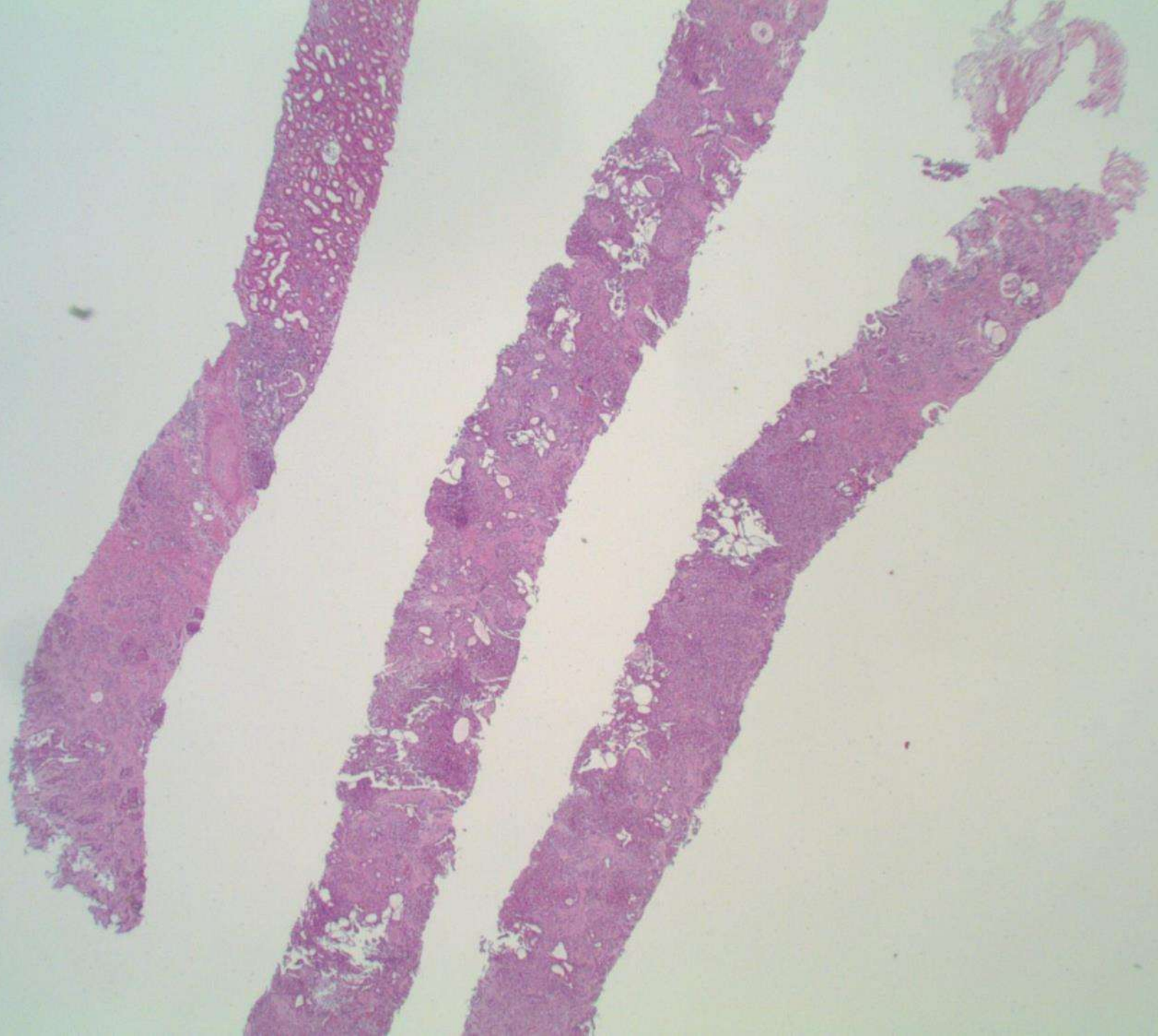
DIAGNOSIS?

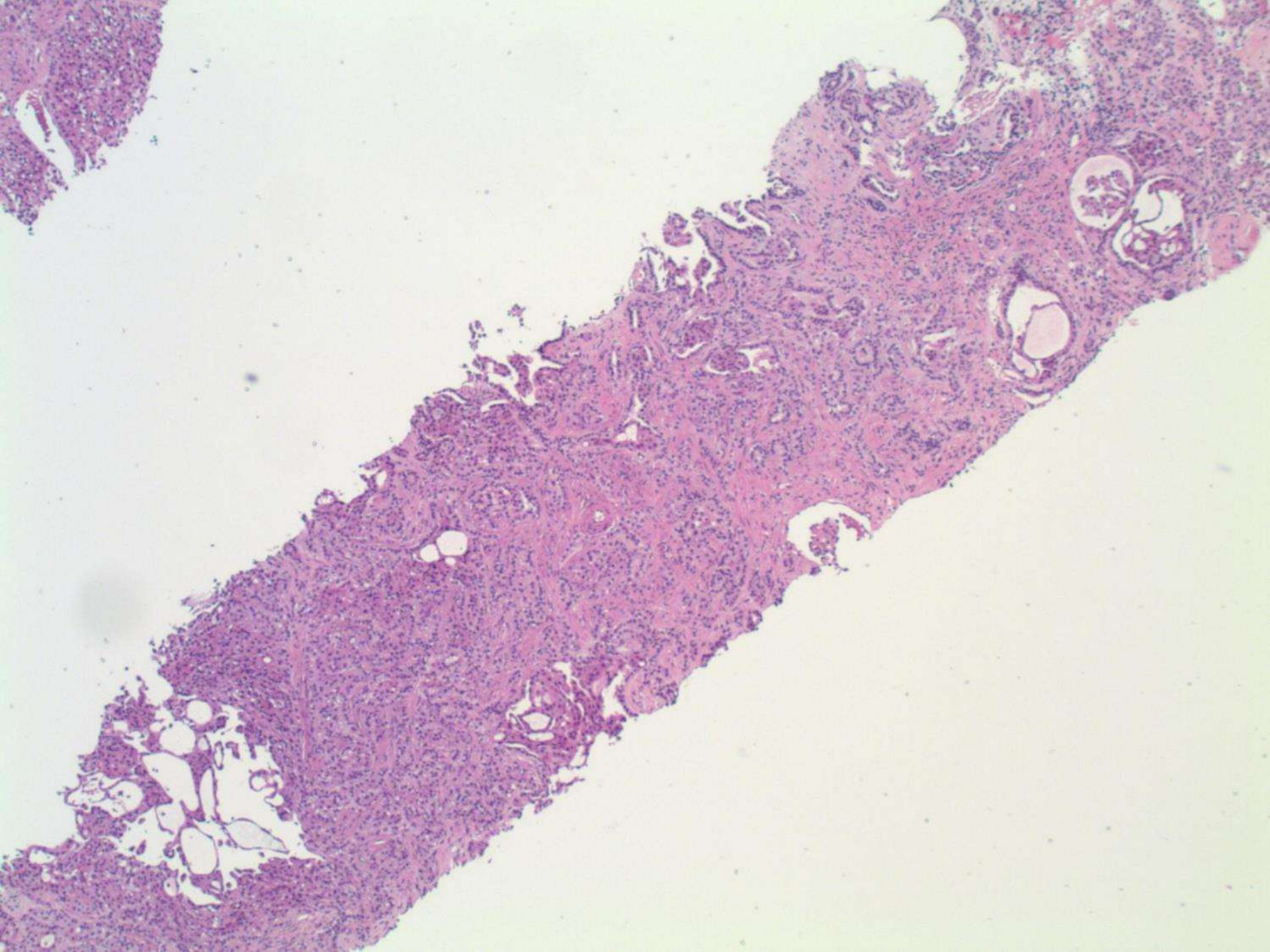


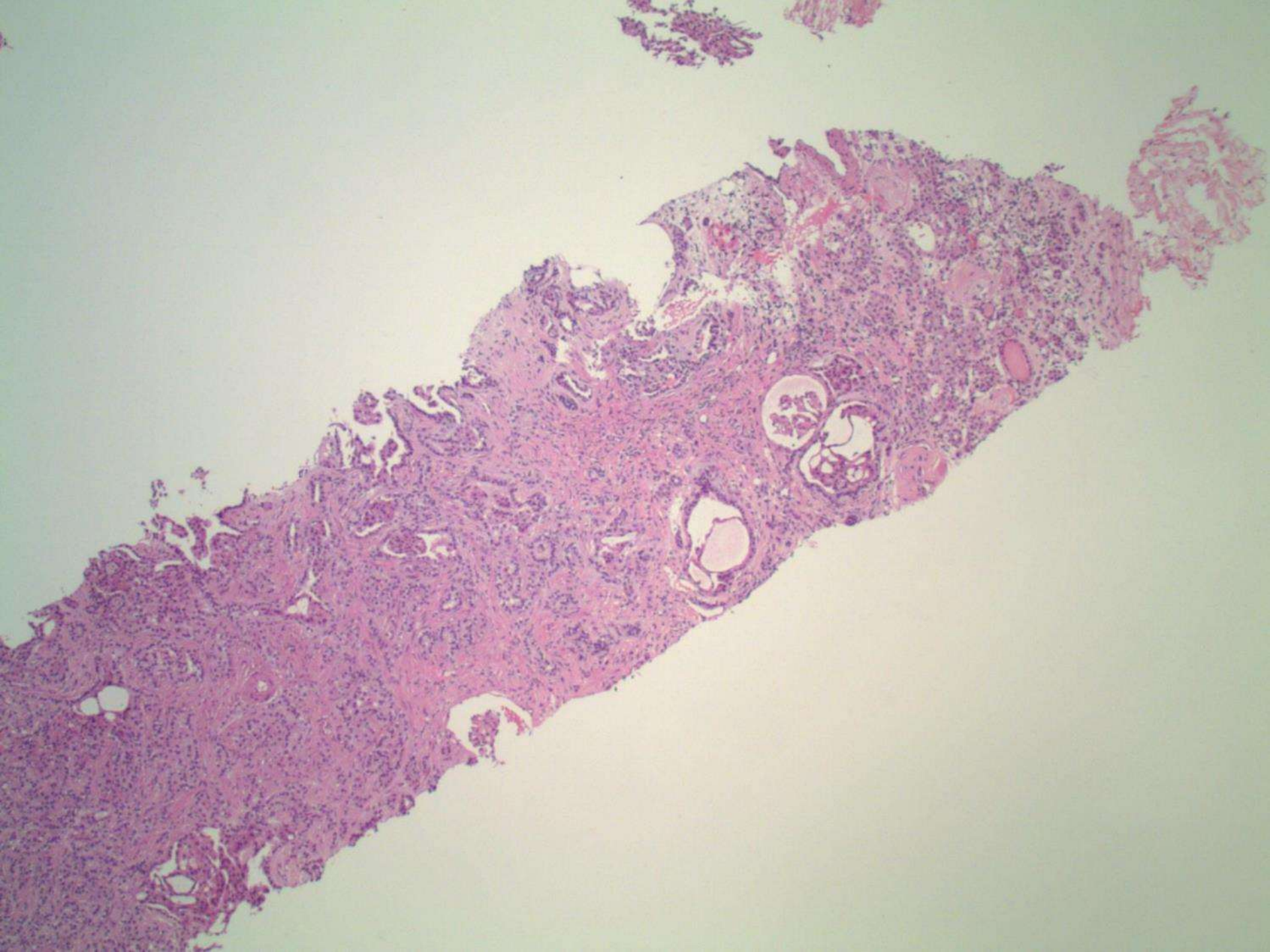
23-1207

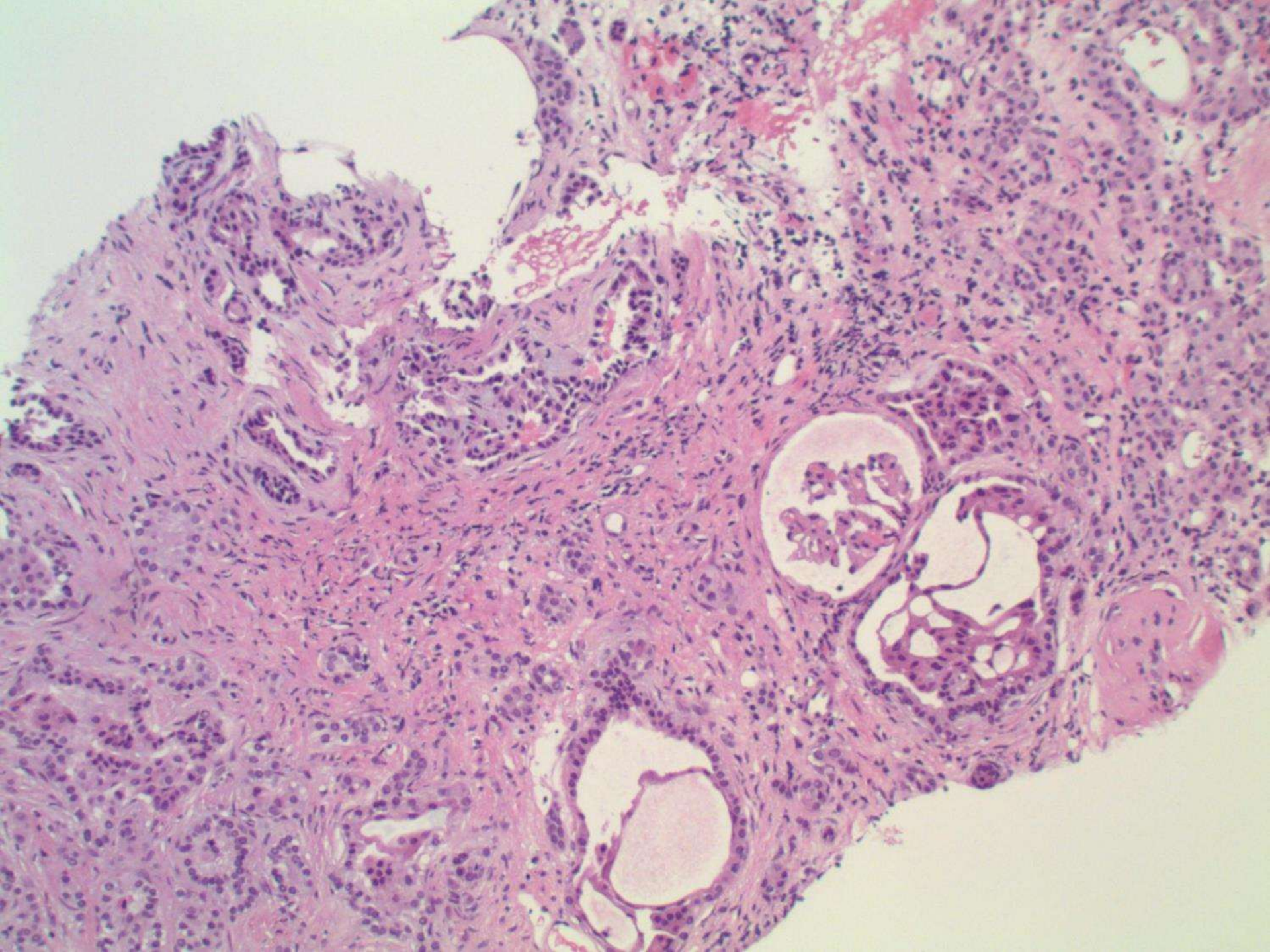
Ankur Sangoi; El Camino Hospital

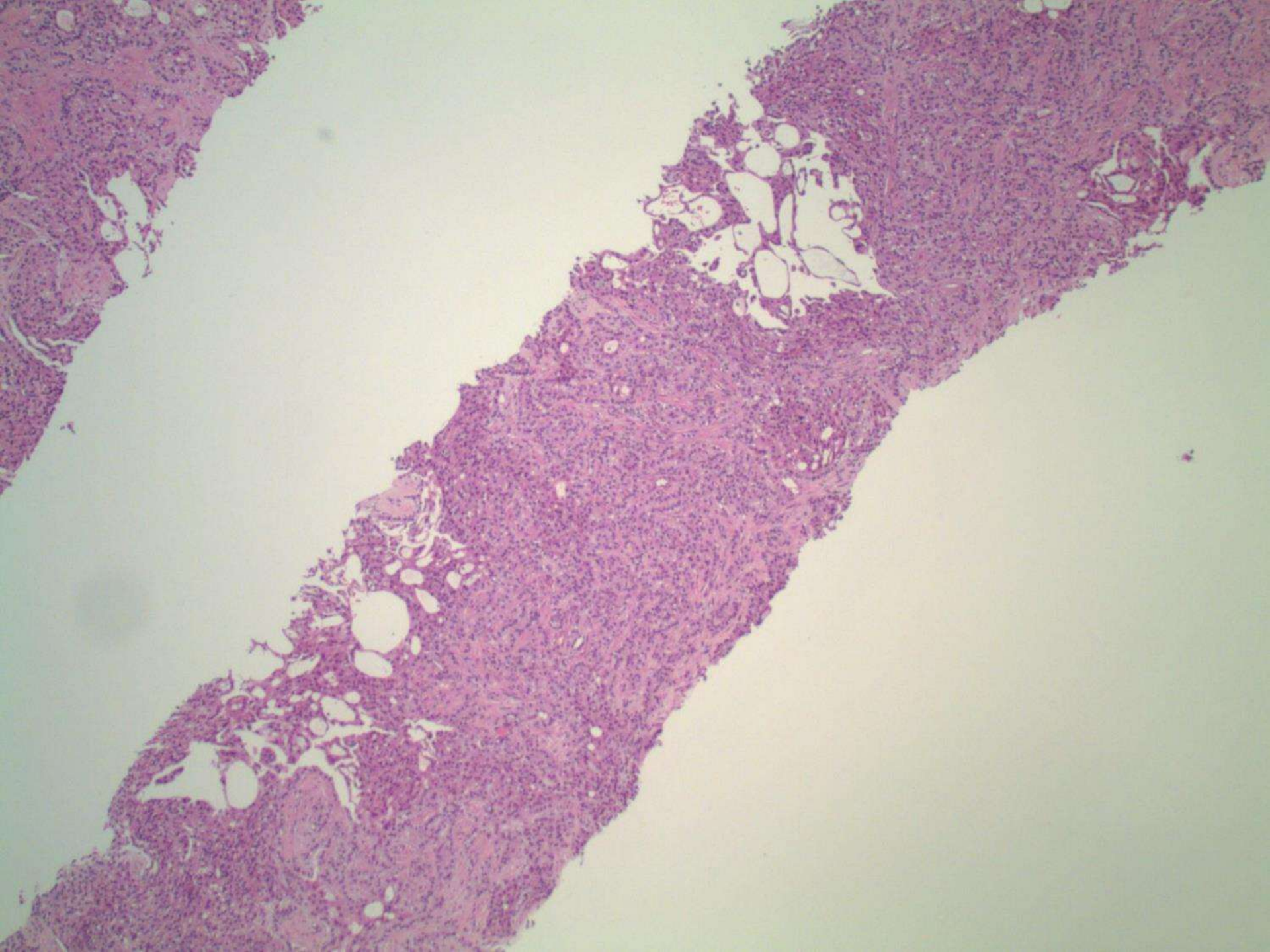
60ish MF presenting with 4.5cm renal mass, undergoes biopsy.

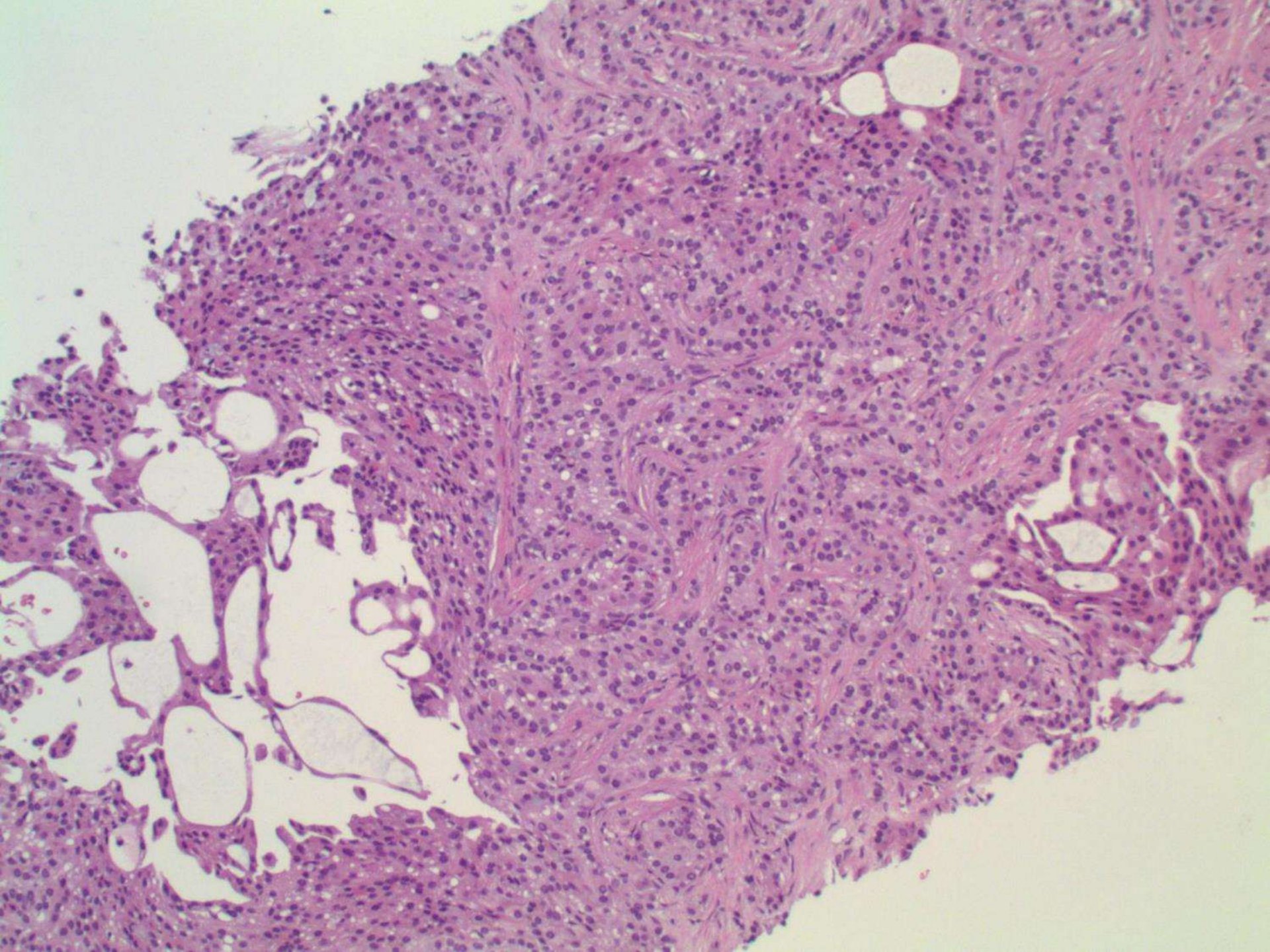


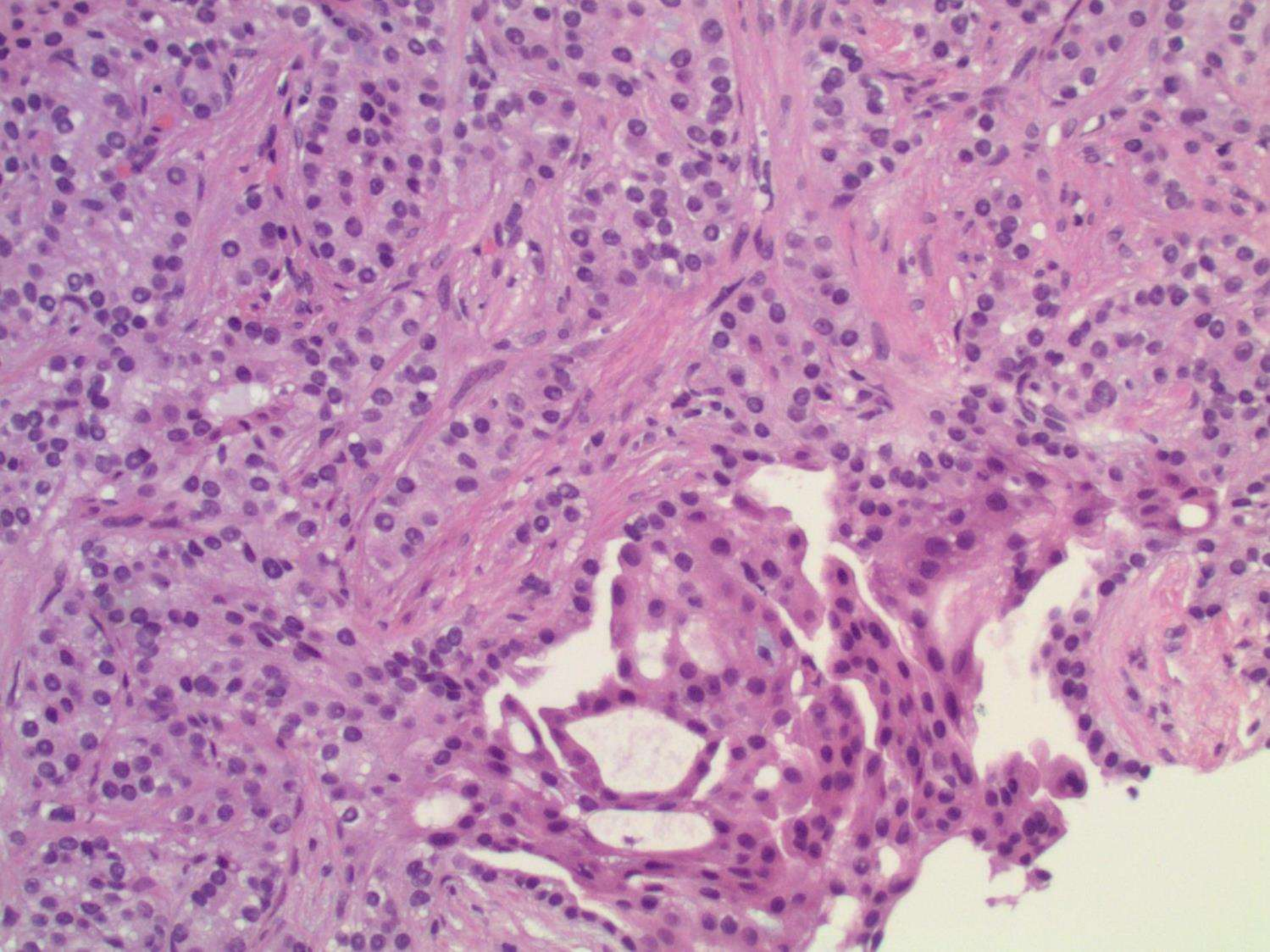


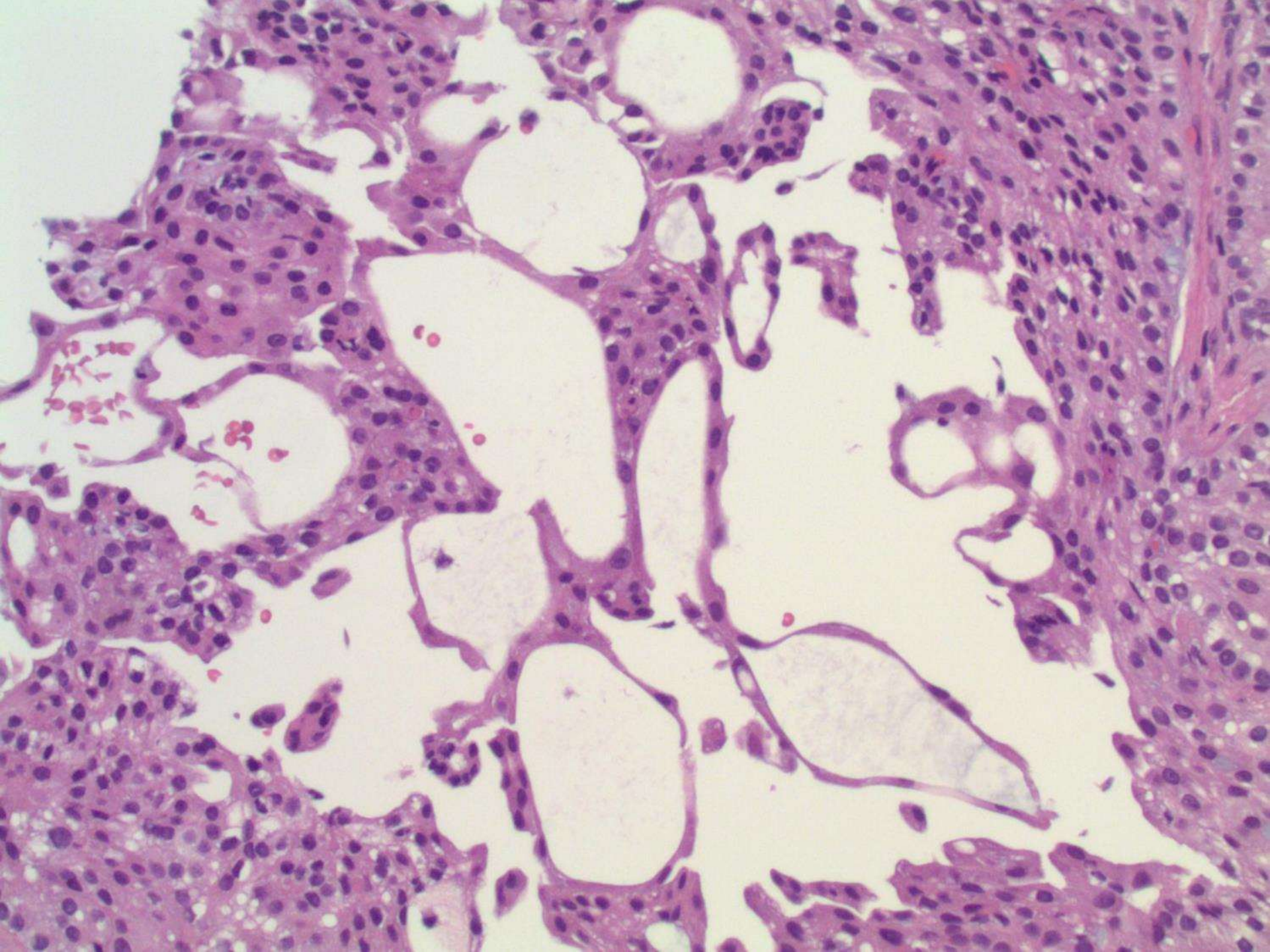


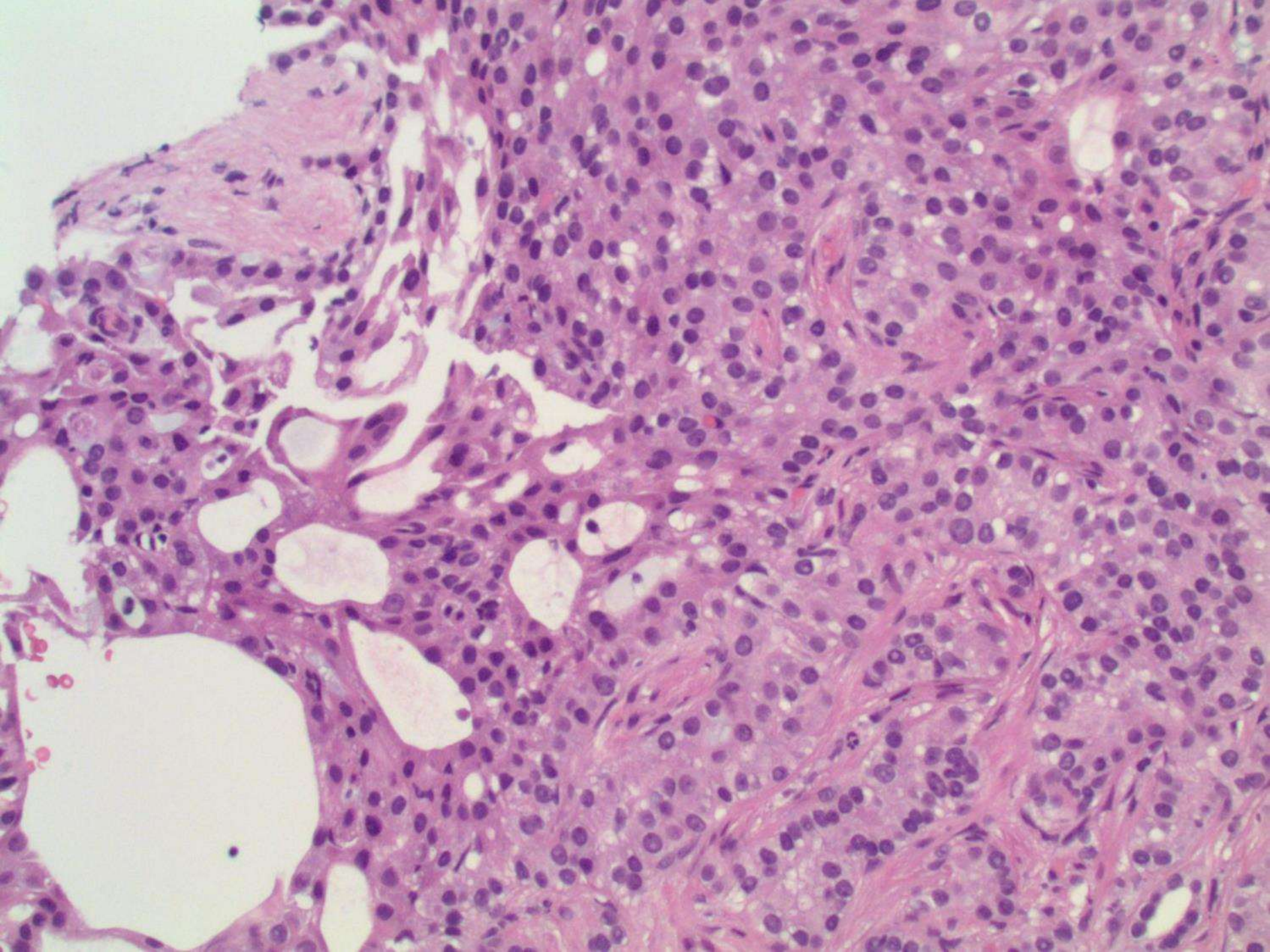


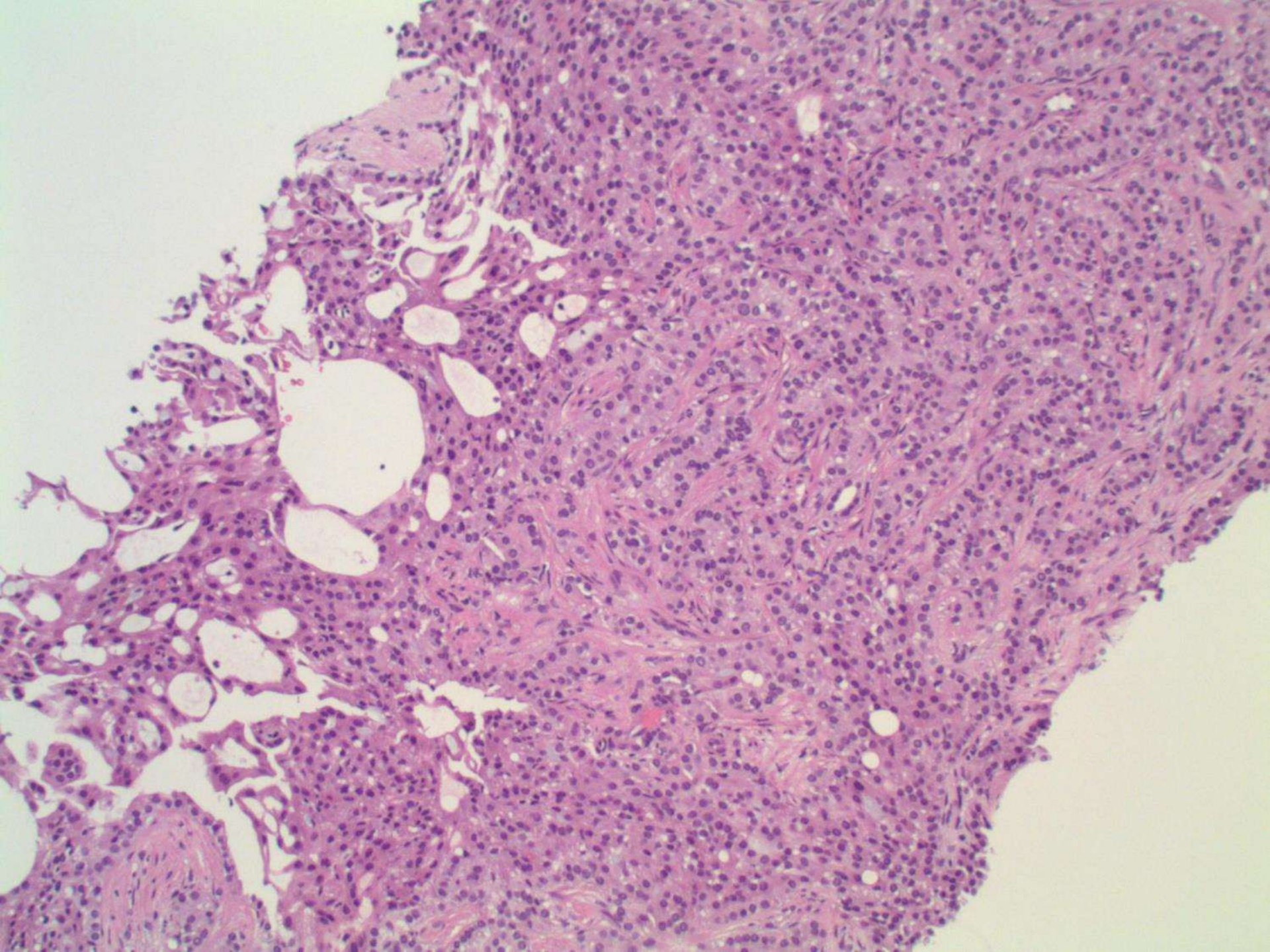


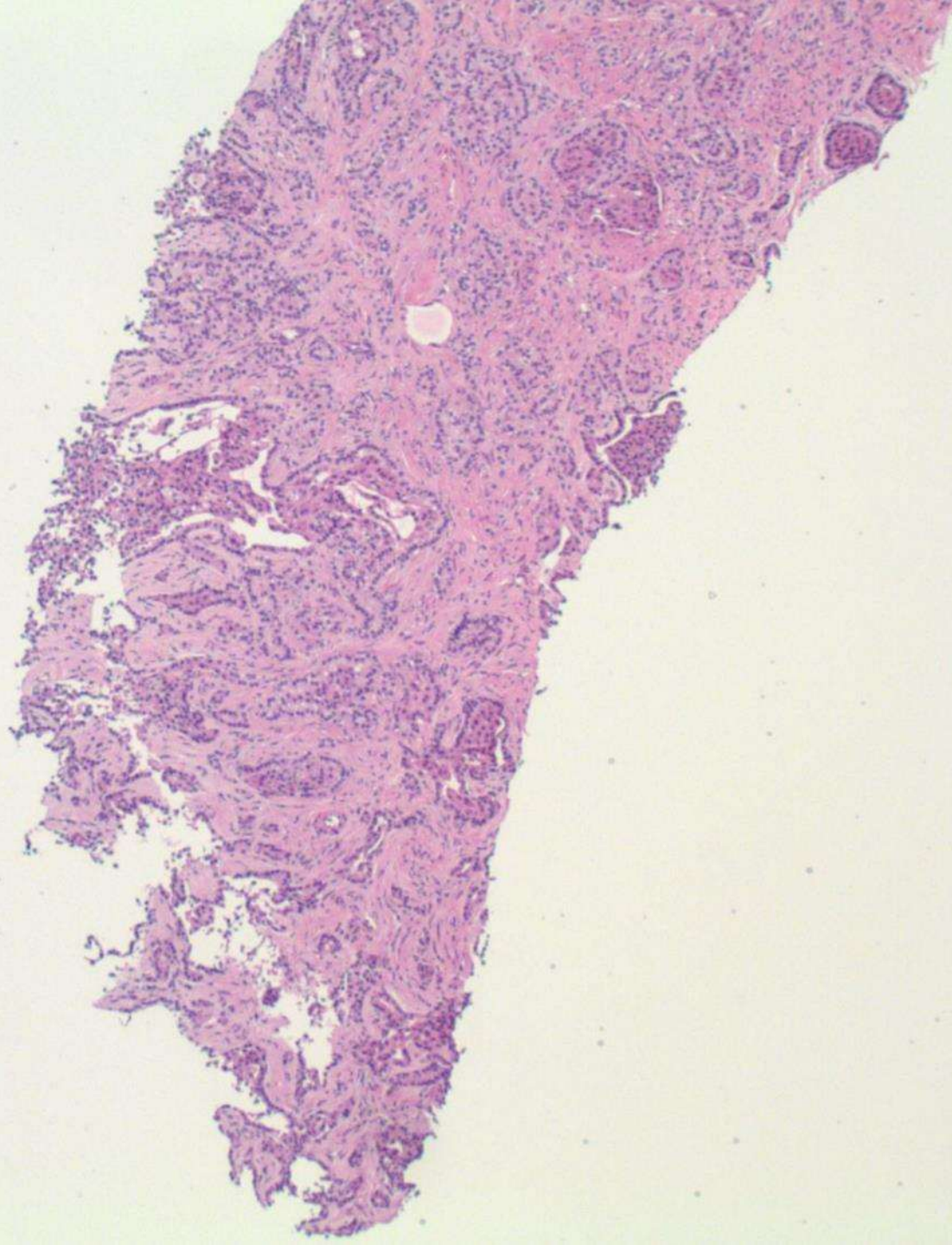


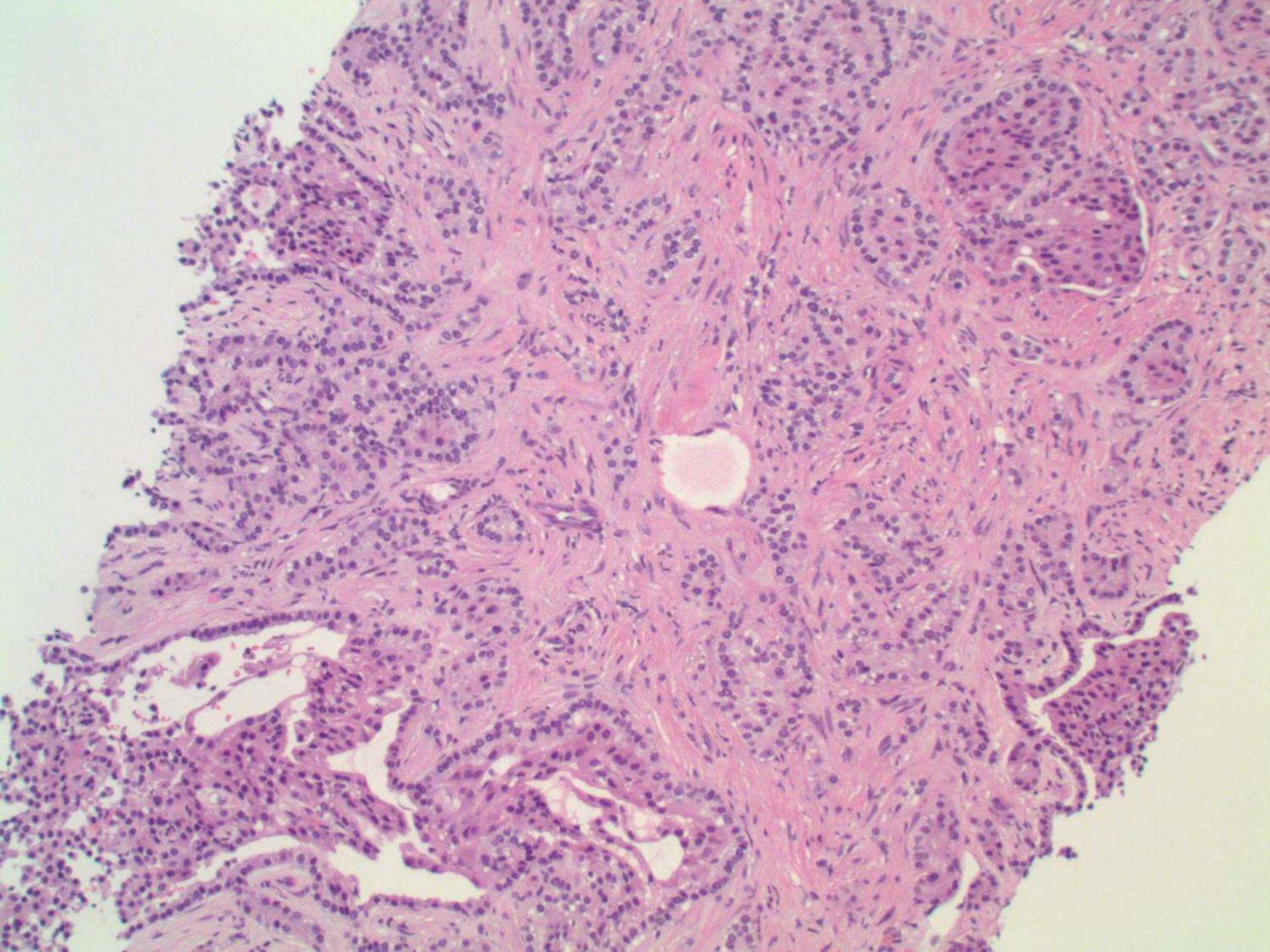


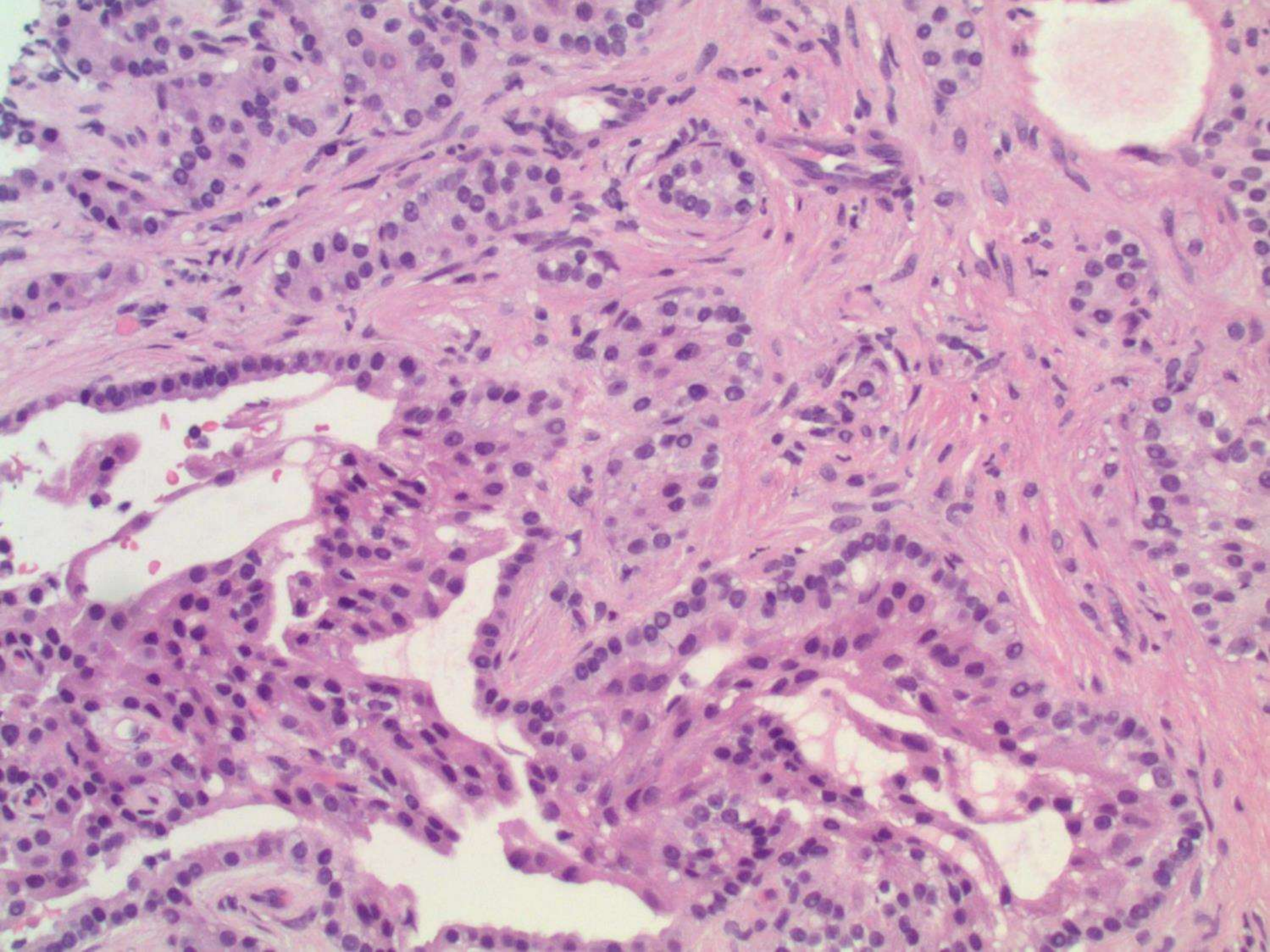












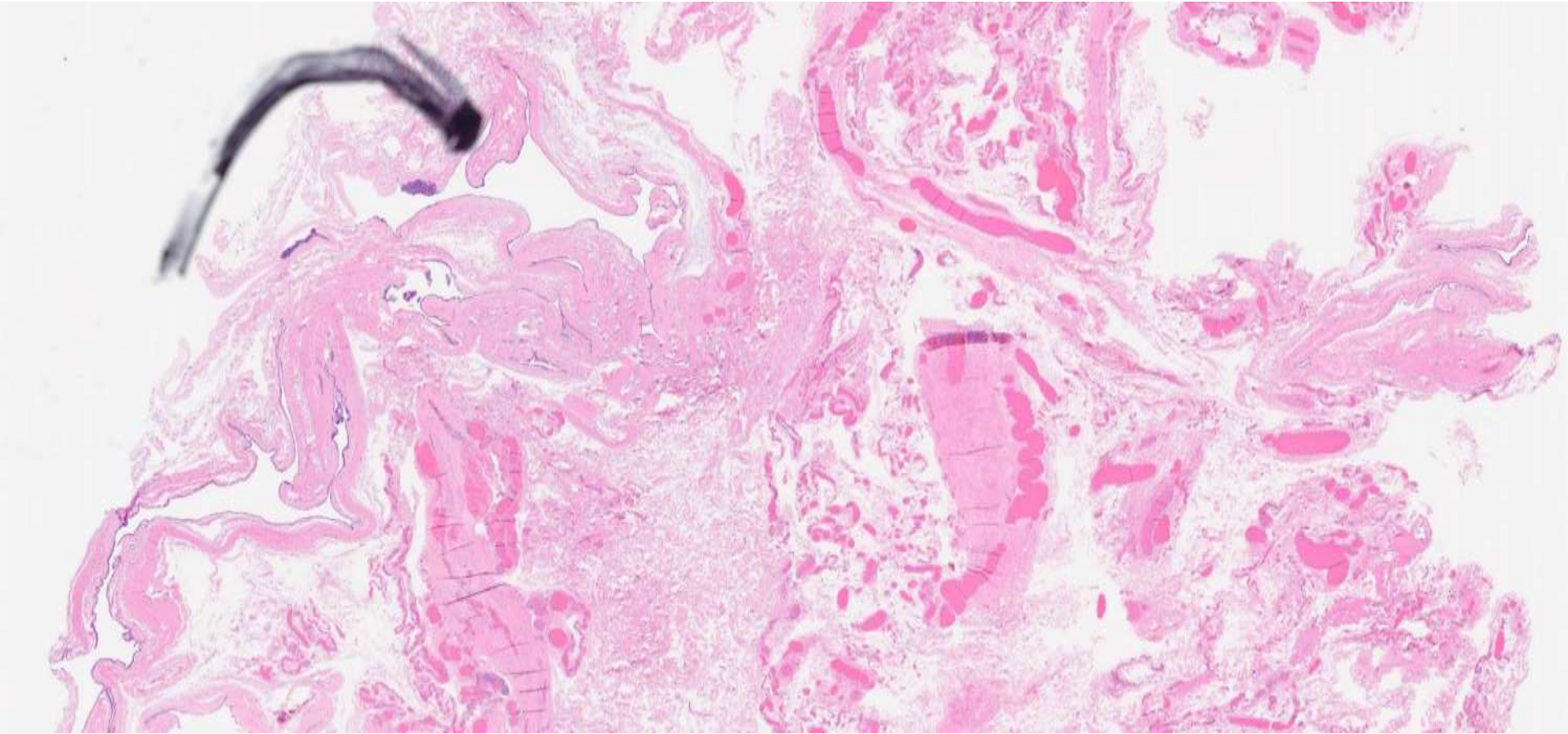
DIAGNOSIS?

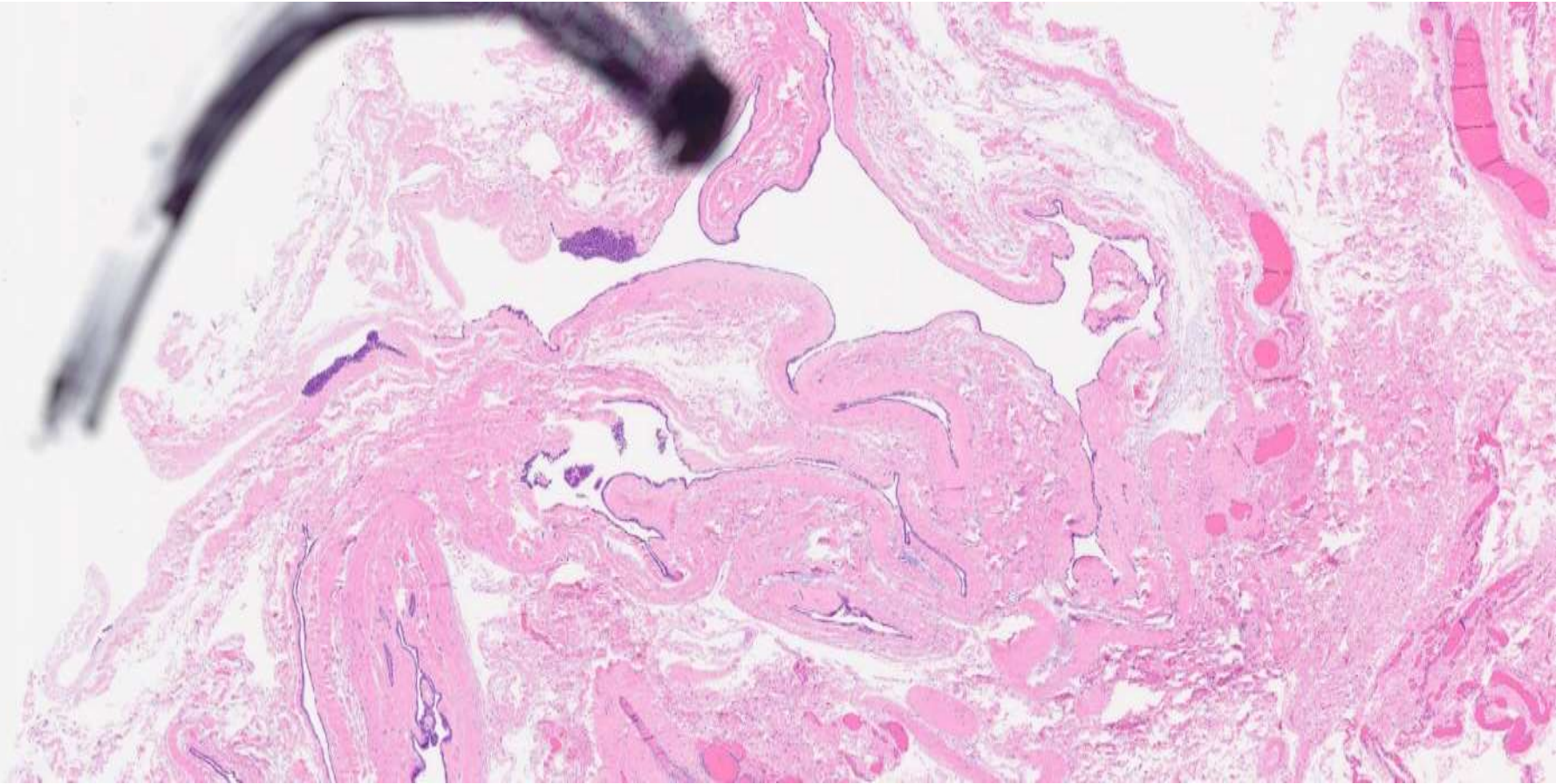


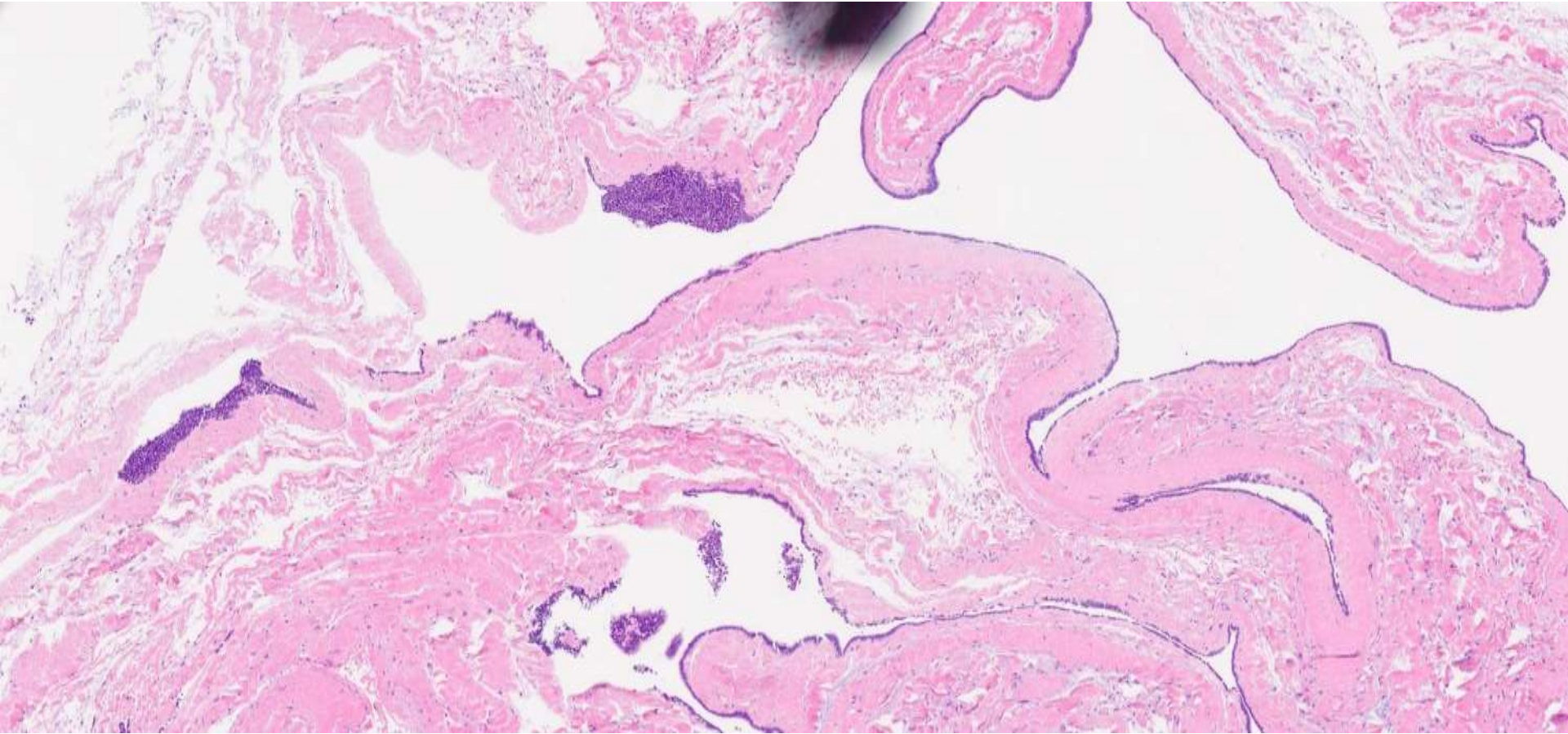
23-0208

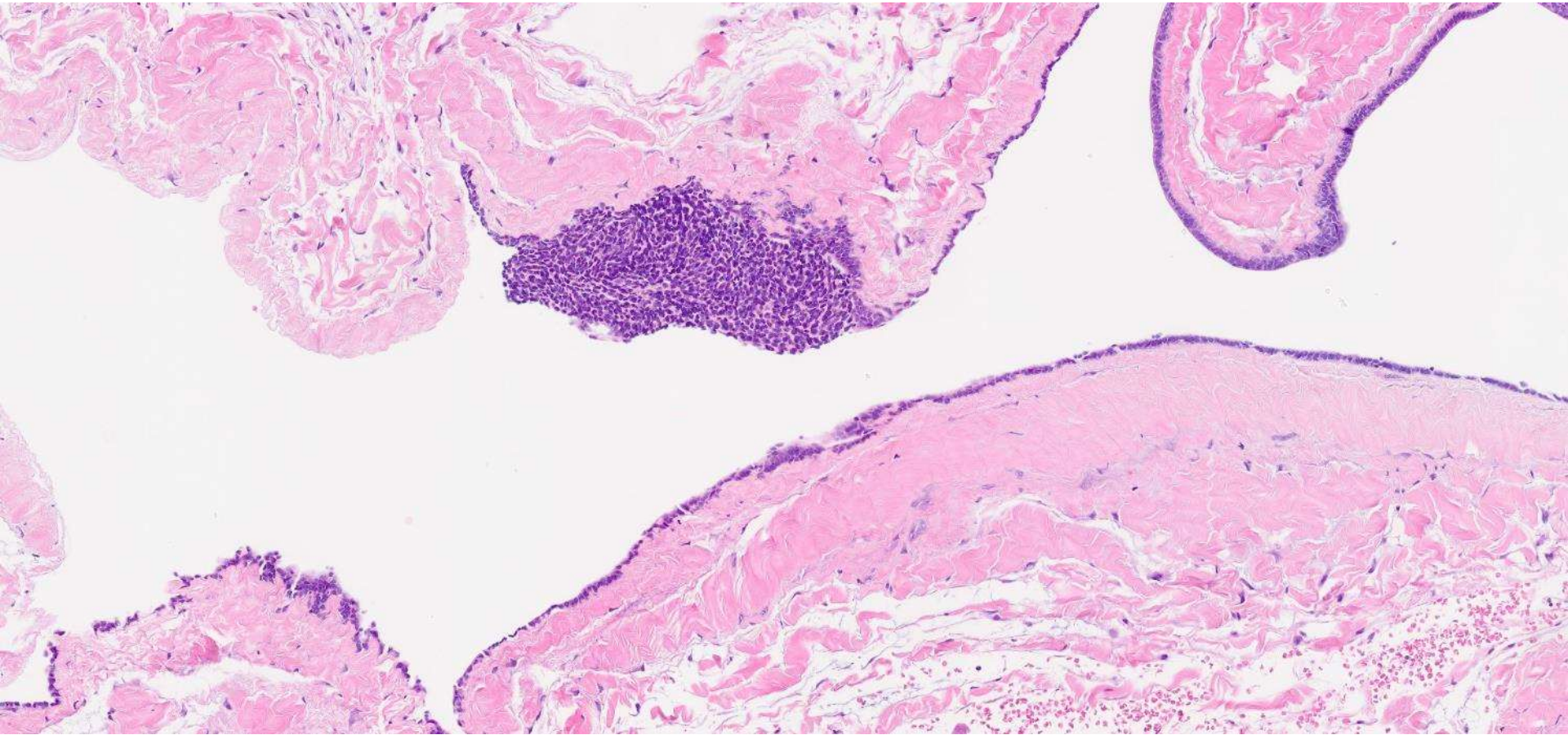
Ankur Sangoi; El Camino Hospital

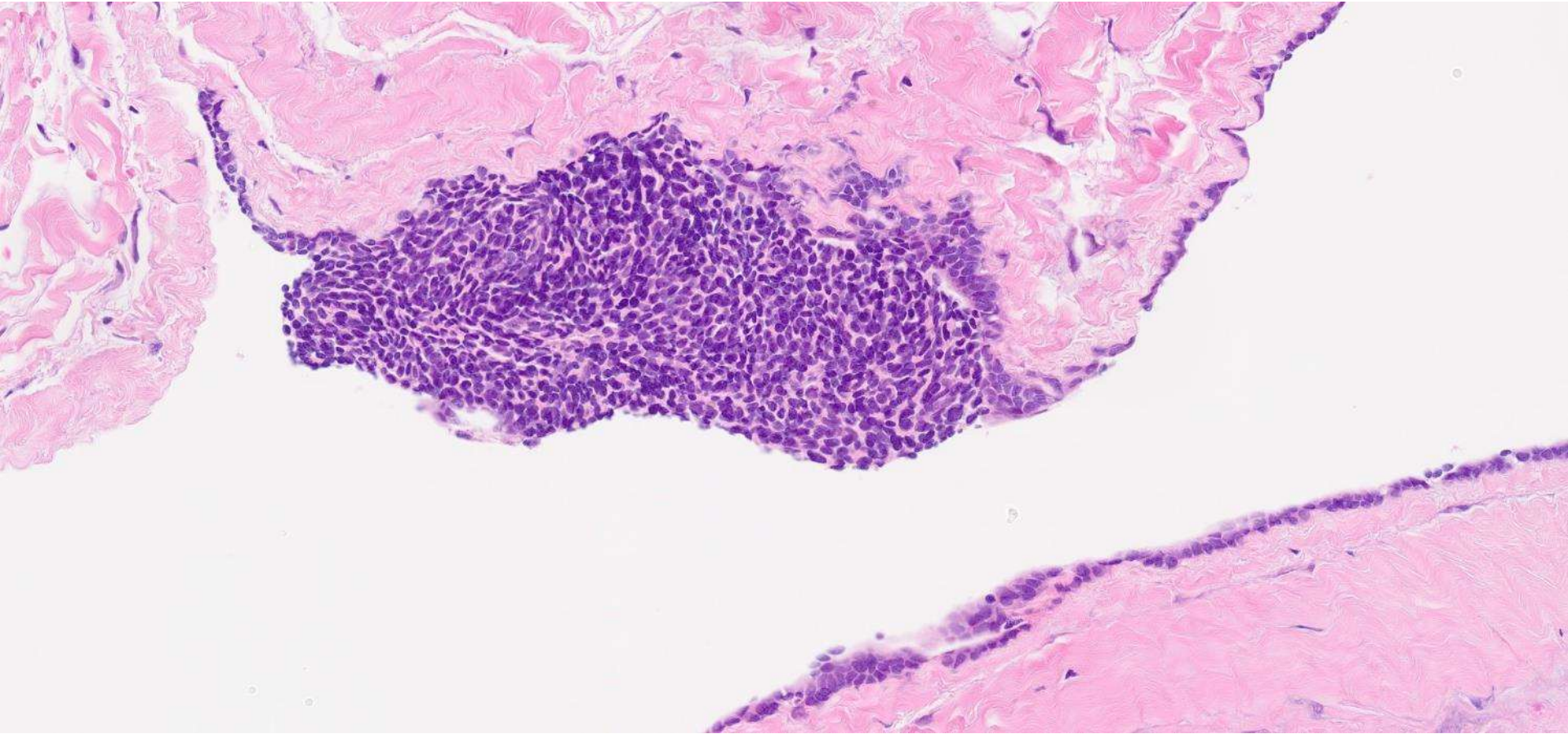
50ish M with h/o lung mass, now presents with spermatocele and undergoes spermatocelectomy.

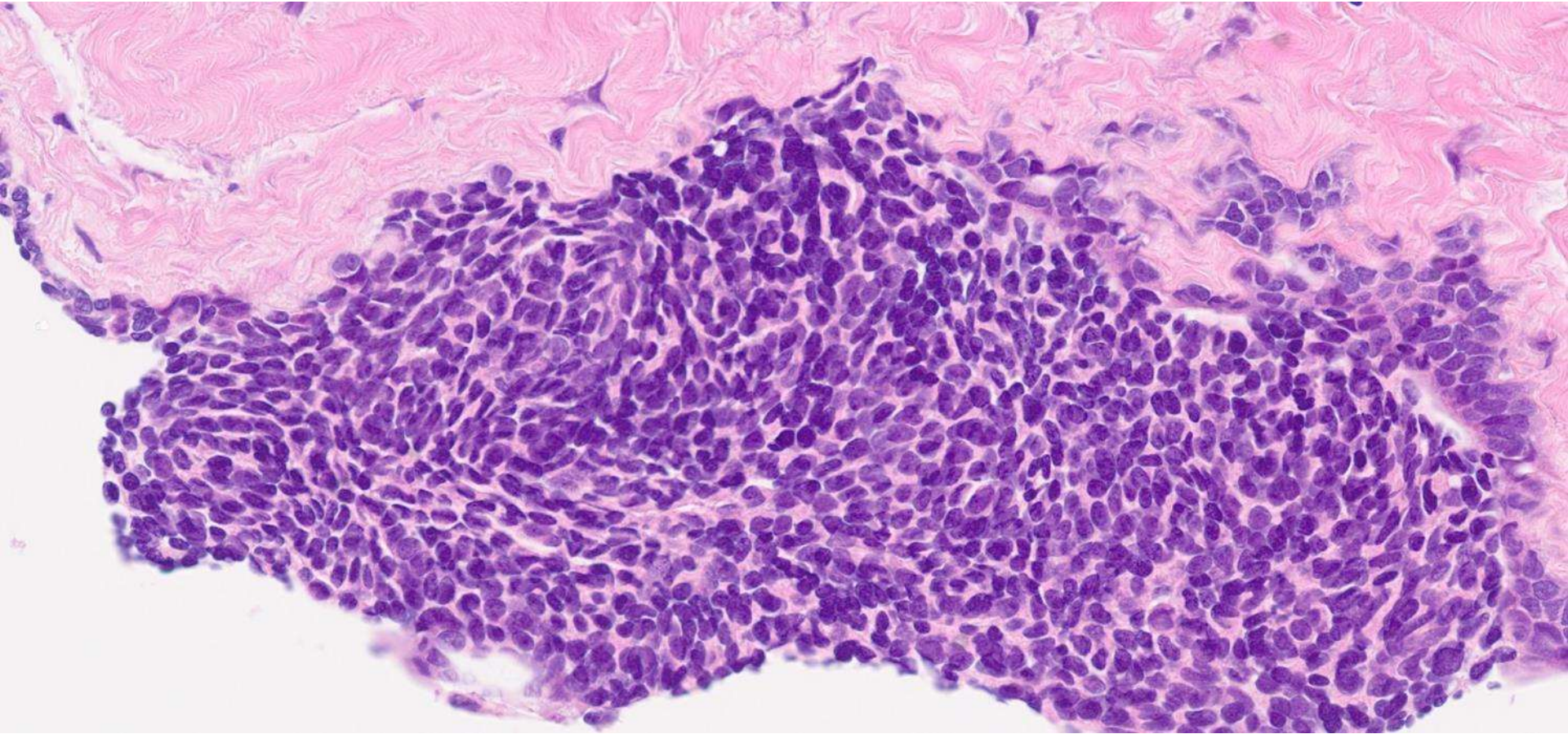


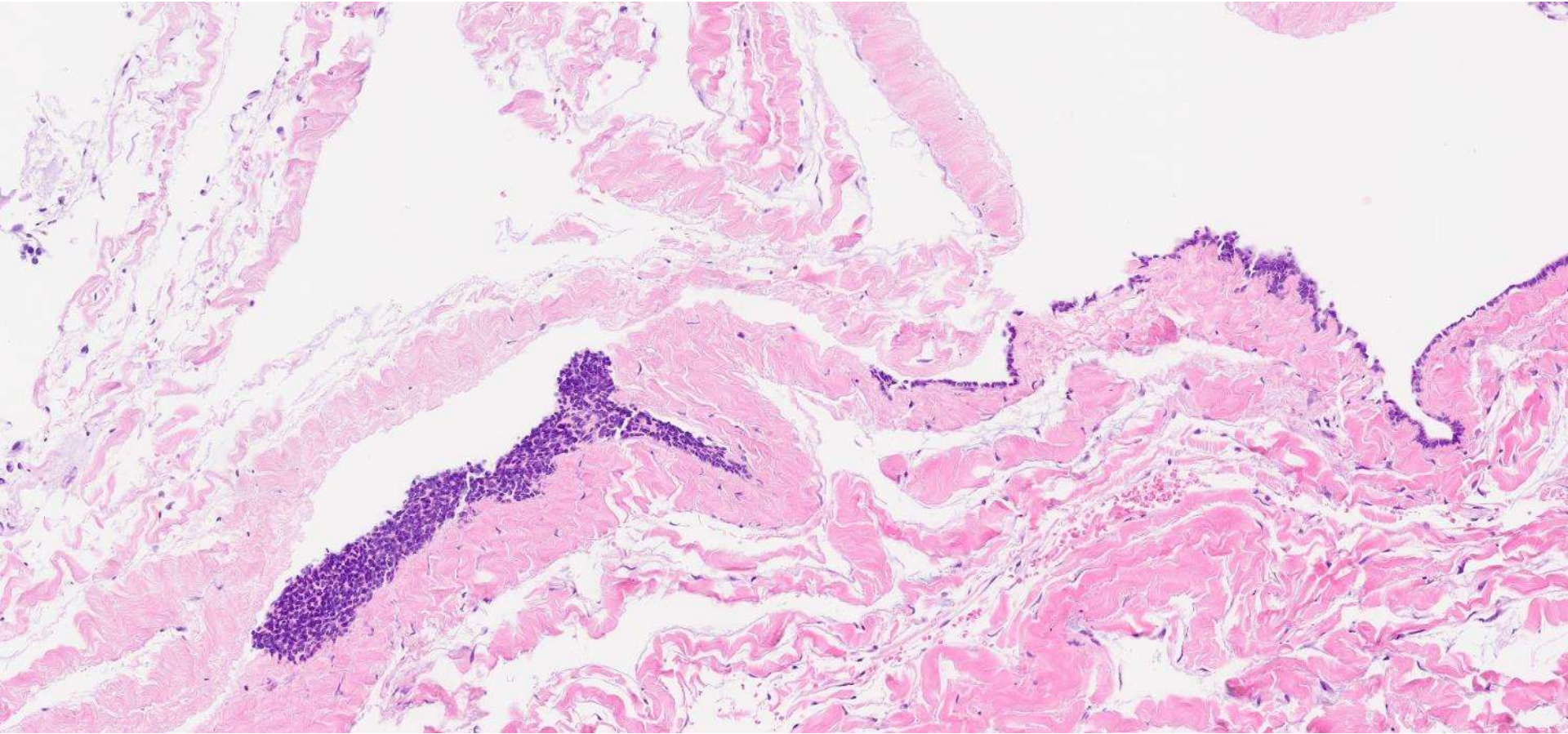


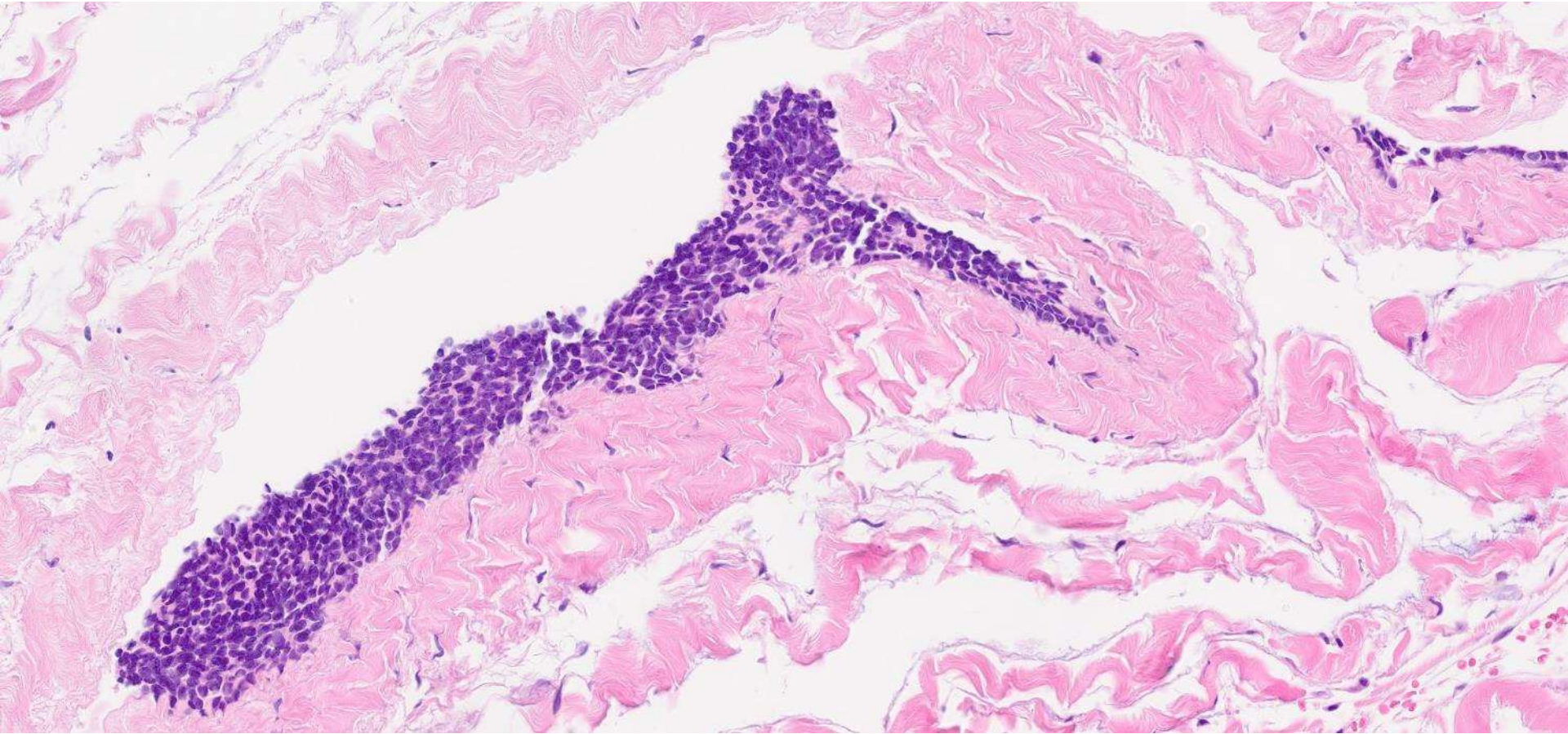


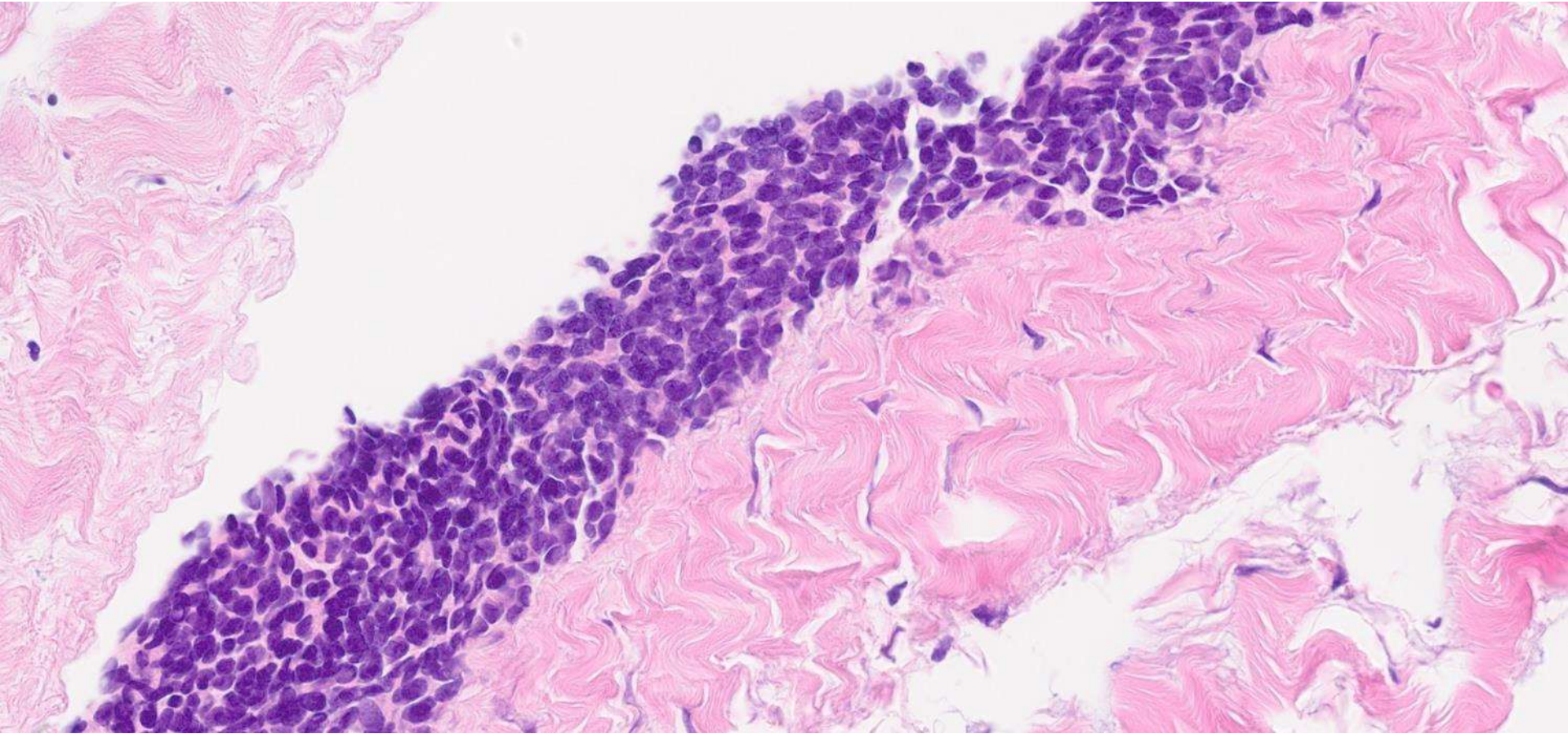




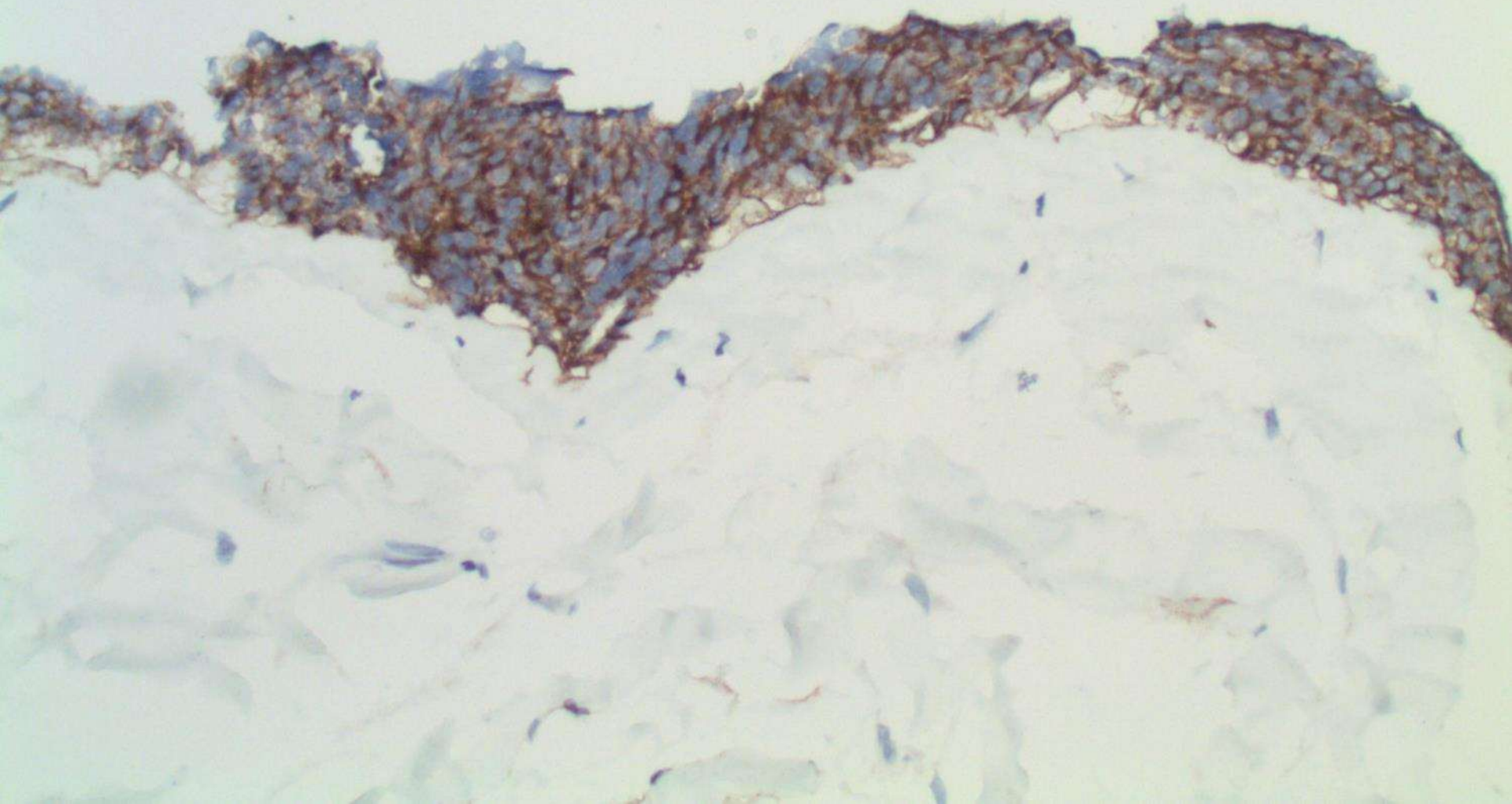








CD56



DIAGNOSIS?



EVALUATION QR CODE!
Hold smartphone camera on code

