

21-1201

Phoebe Hammer/Dita Gratzinger/Brent Tan; Stanford

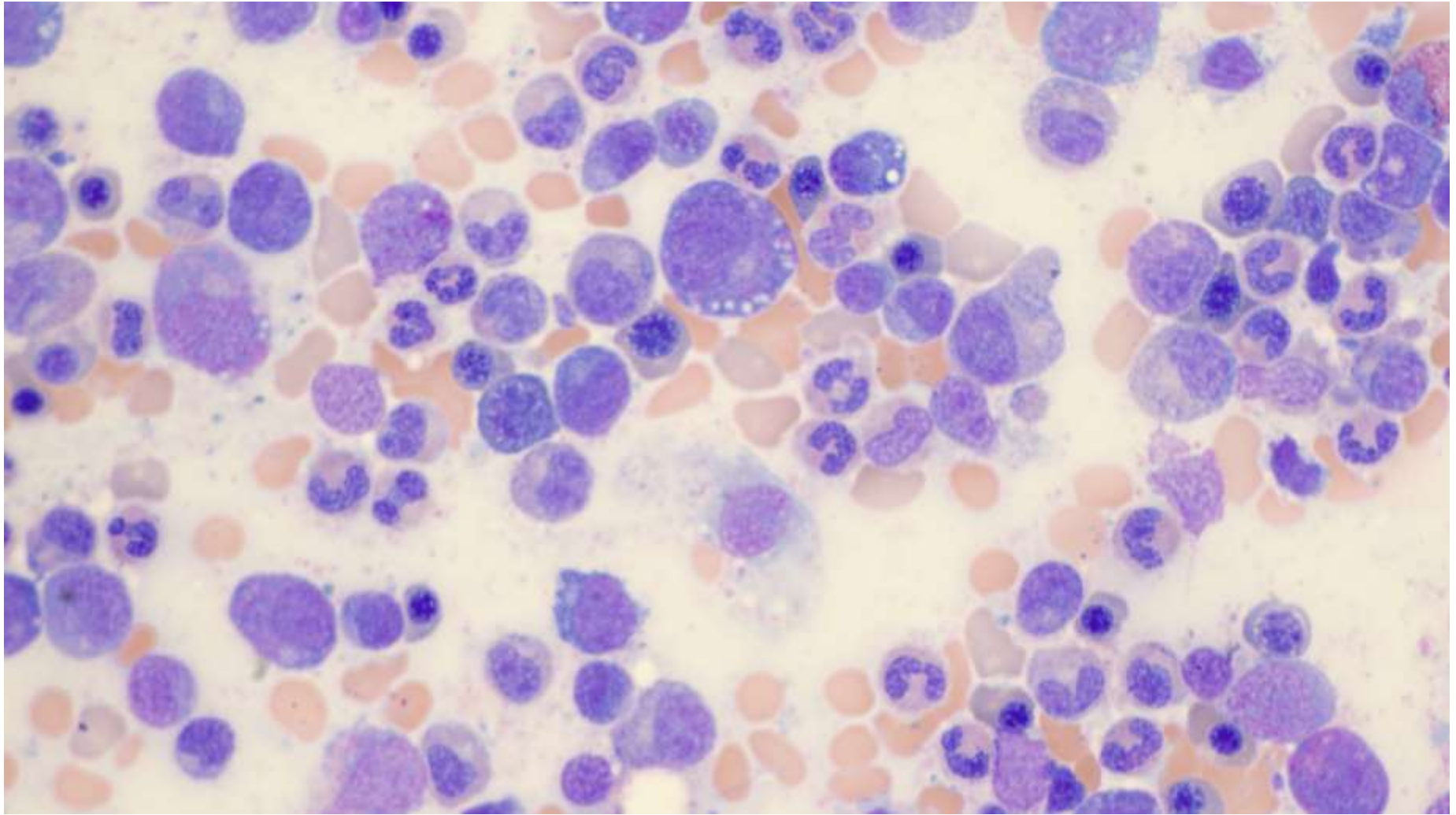
69-year-old M presenting with a 10-year history of worsening episodic fevers, night sweats, extreme fatigue, joint pain, pulmonary nodules, and painful skin rash. Biopsy of rash showed neutrophilic dermatosis, favor Sweet Syndrome. Symptoms improve with high-dose prednisone but return after taper of steroids.

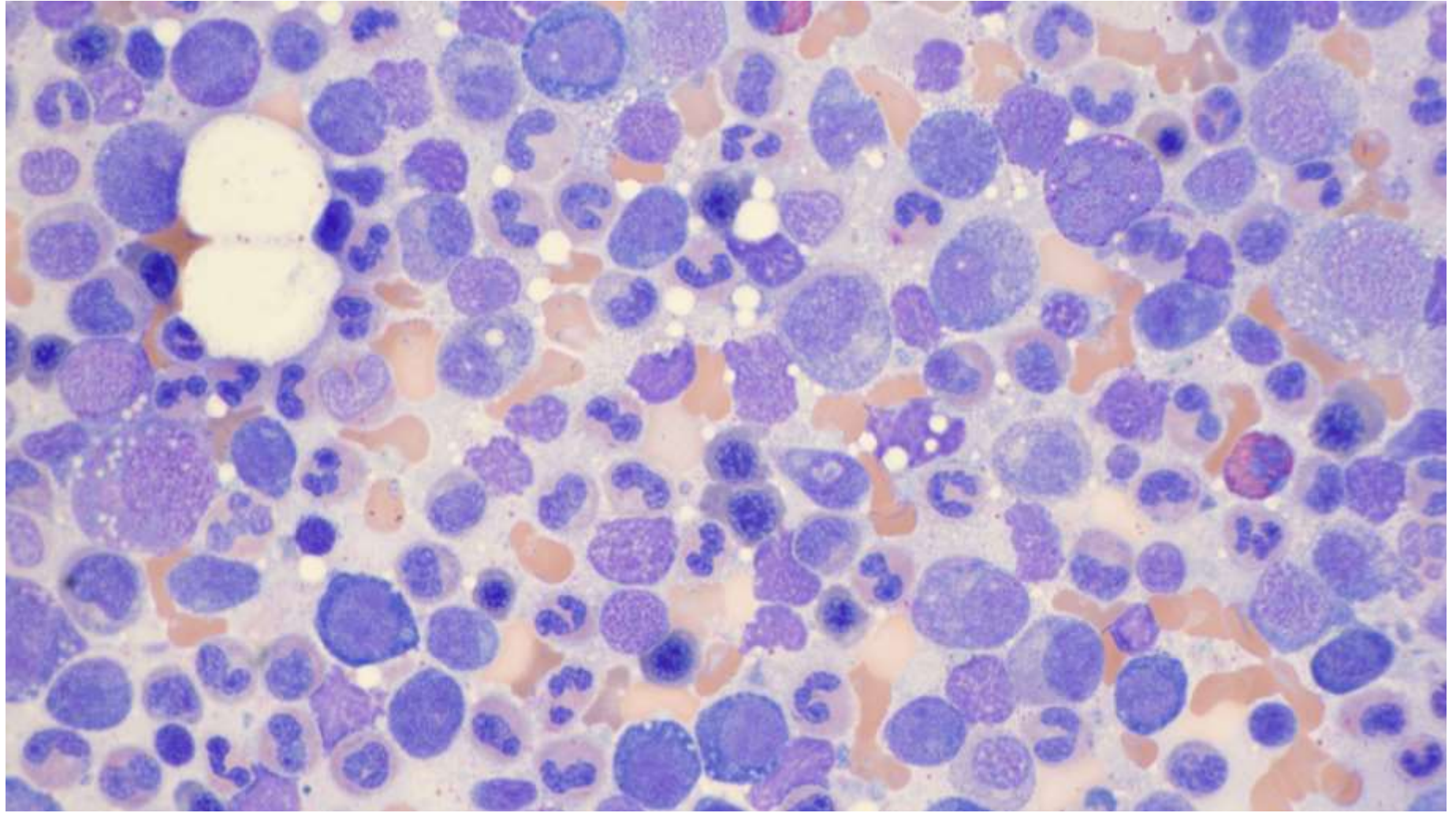
Labs

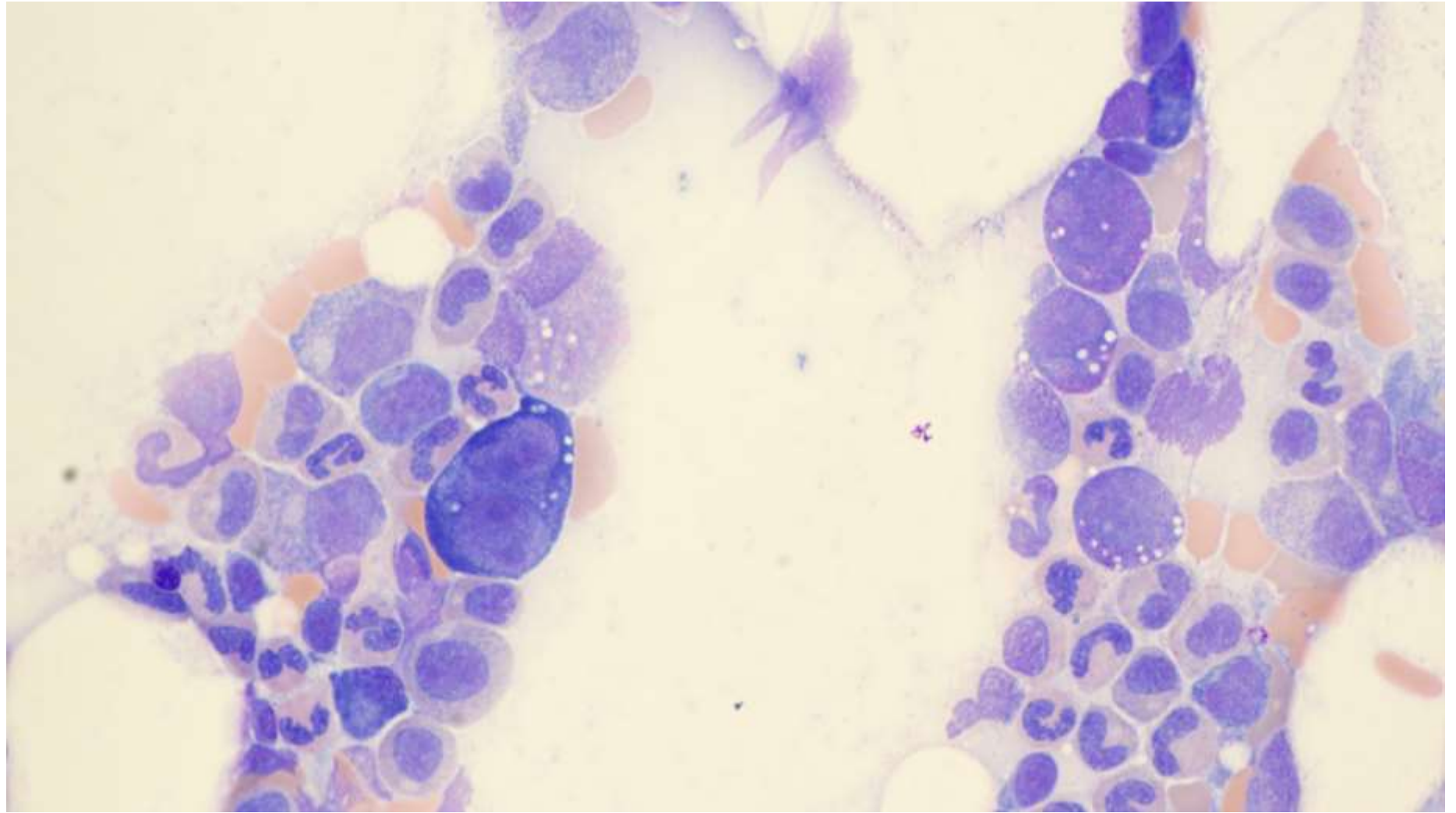
WBC	3.3 (L)
Hemoglobin	13.3 (L)
Hematocrit	40.0
Platelet count	128 (L)
MCV	114.3 (H)
RDW	13.4
RBC	3.5 (L)
MCH	38.0 (H)
MCHC	33.3
Lymphocytes, ABS	0.58 (L)
Monocytes, ABS	0.0 (L)

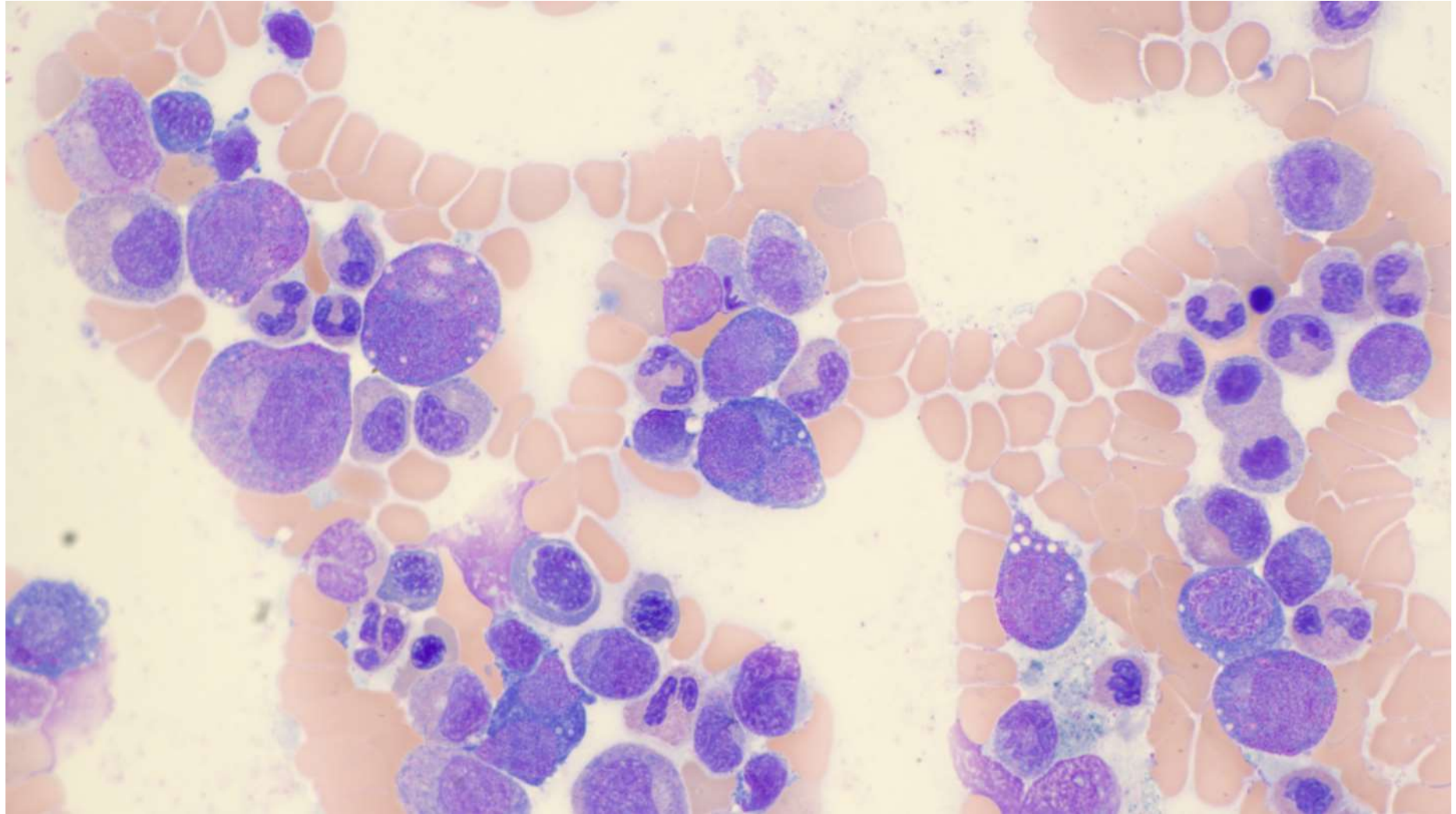
Normochromic macrocytic anemia
Mild thrombocytopenia
Lymphopenia
Monocytopenia

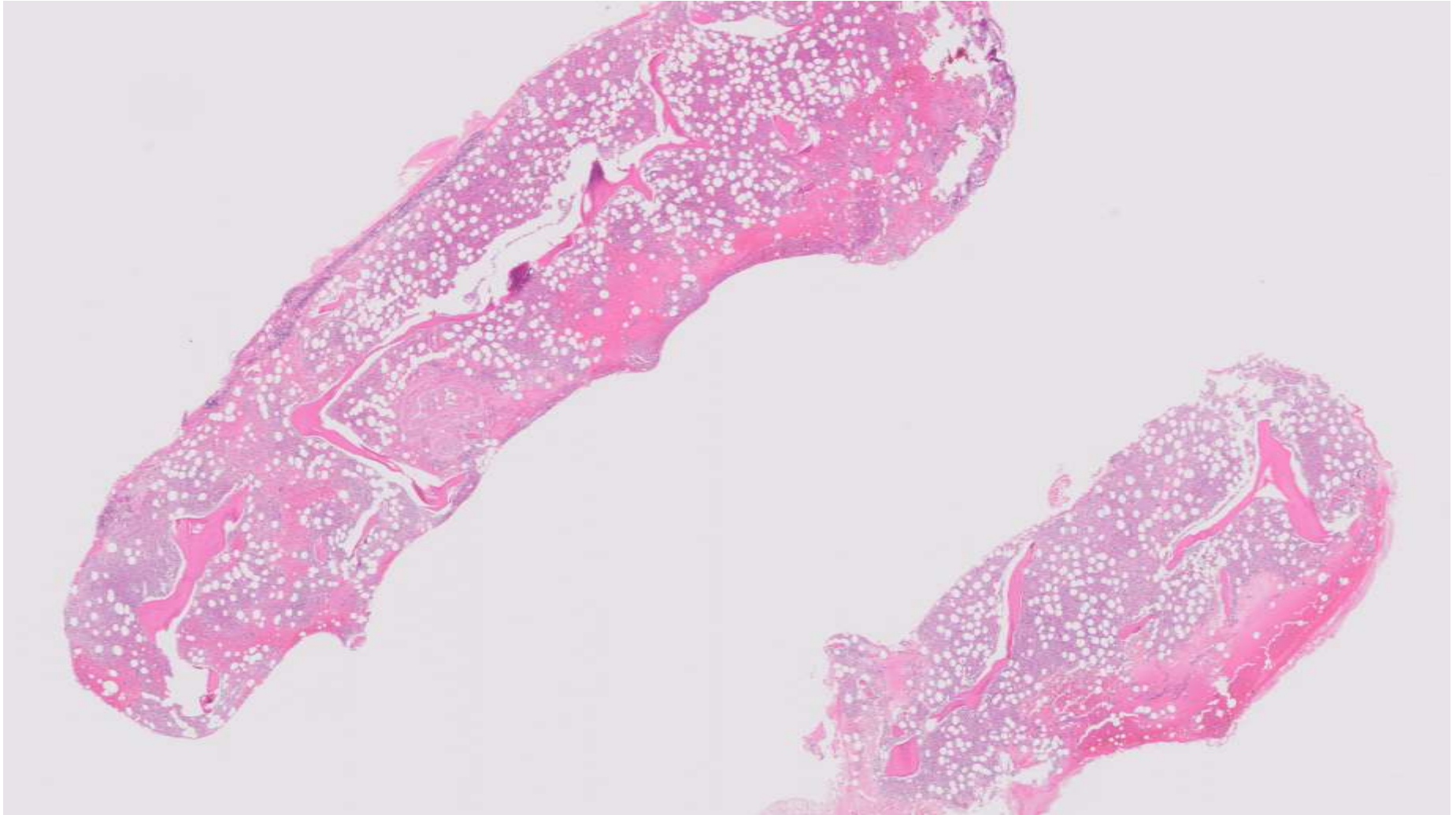
Bone marrow biopsy performed

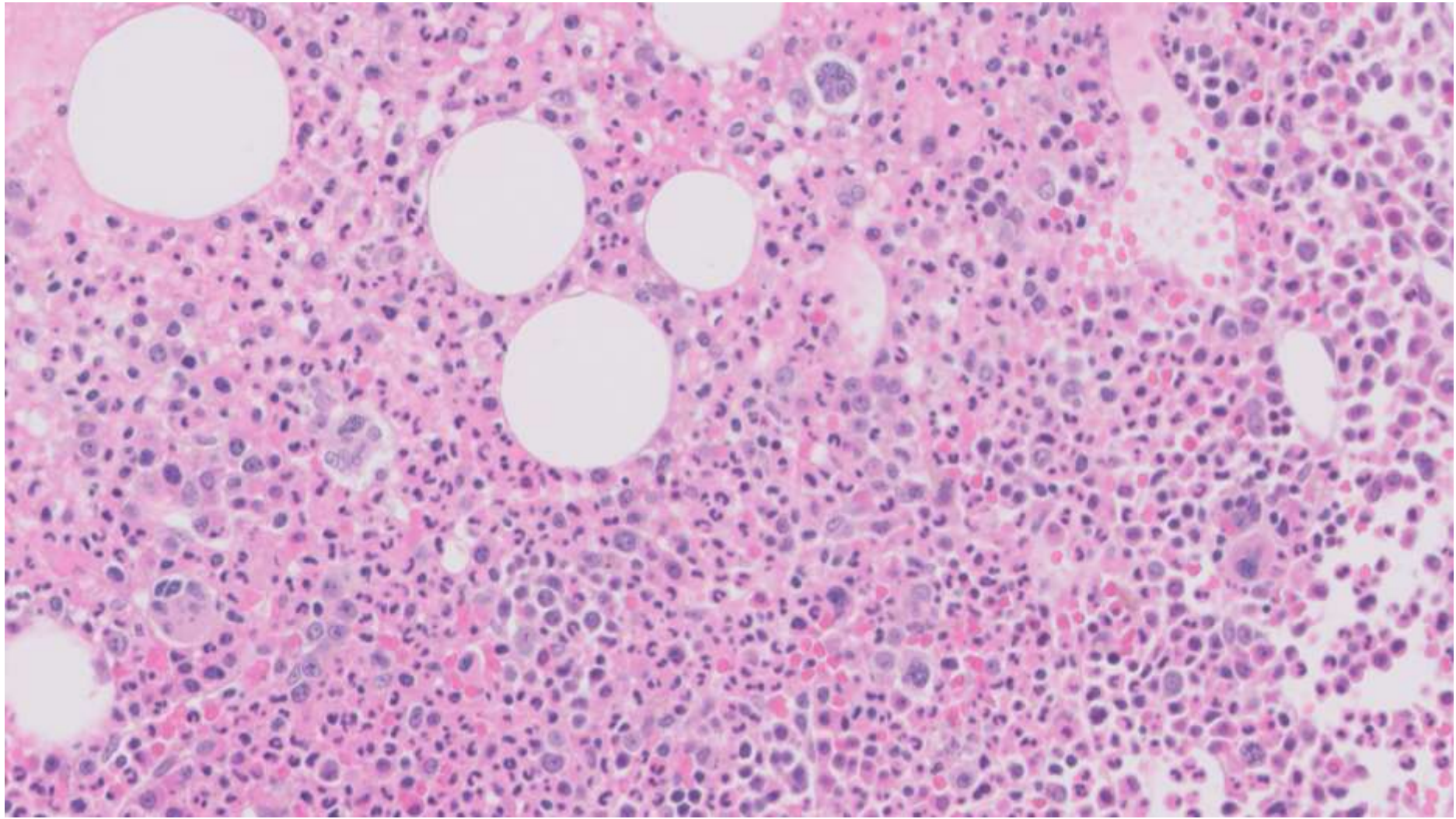










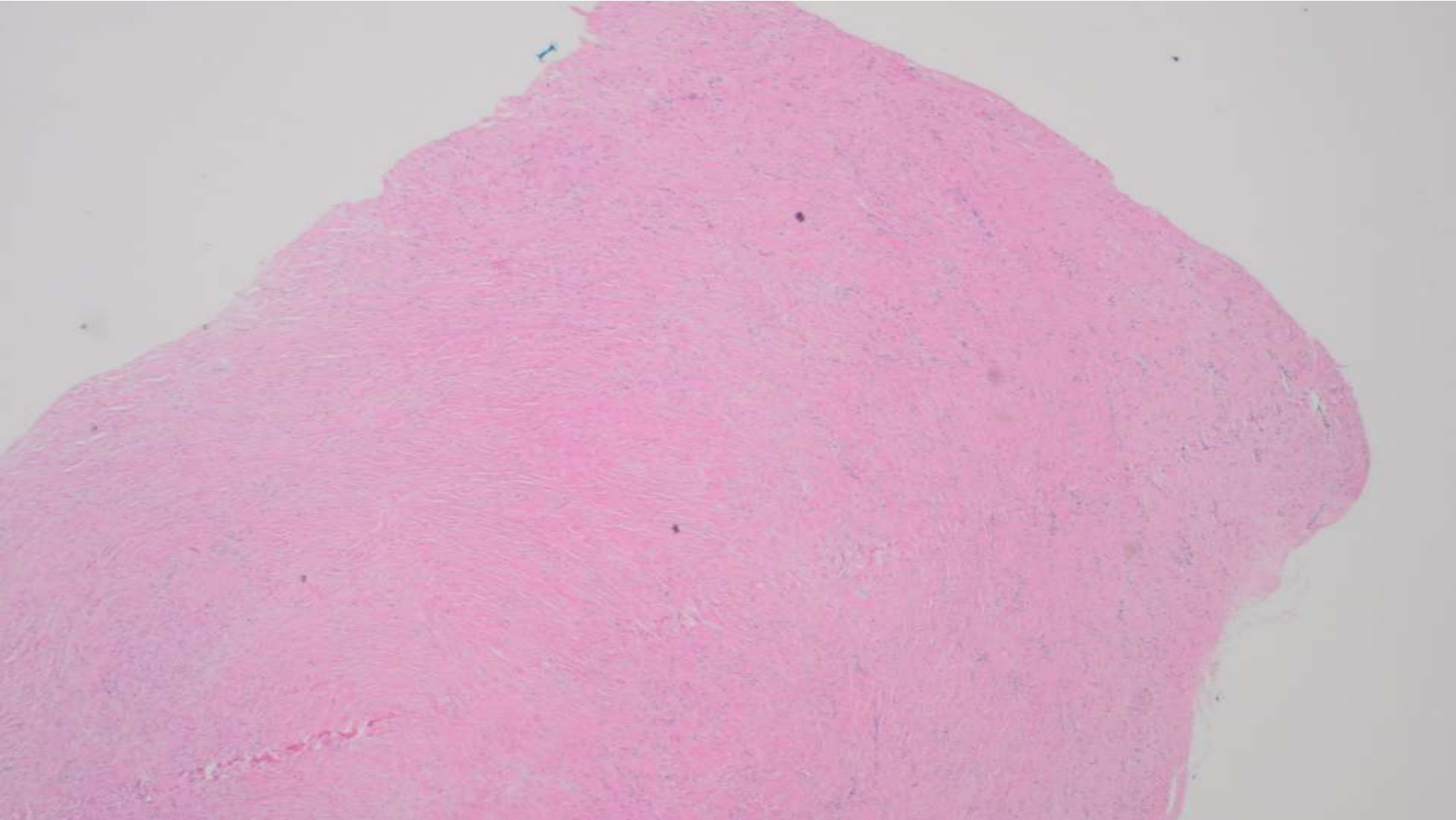


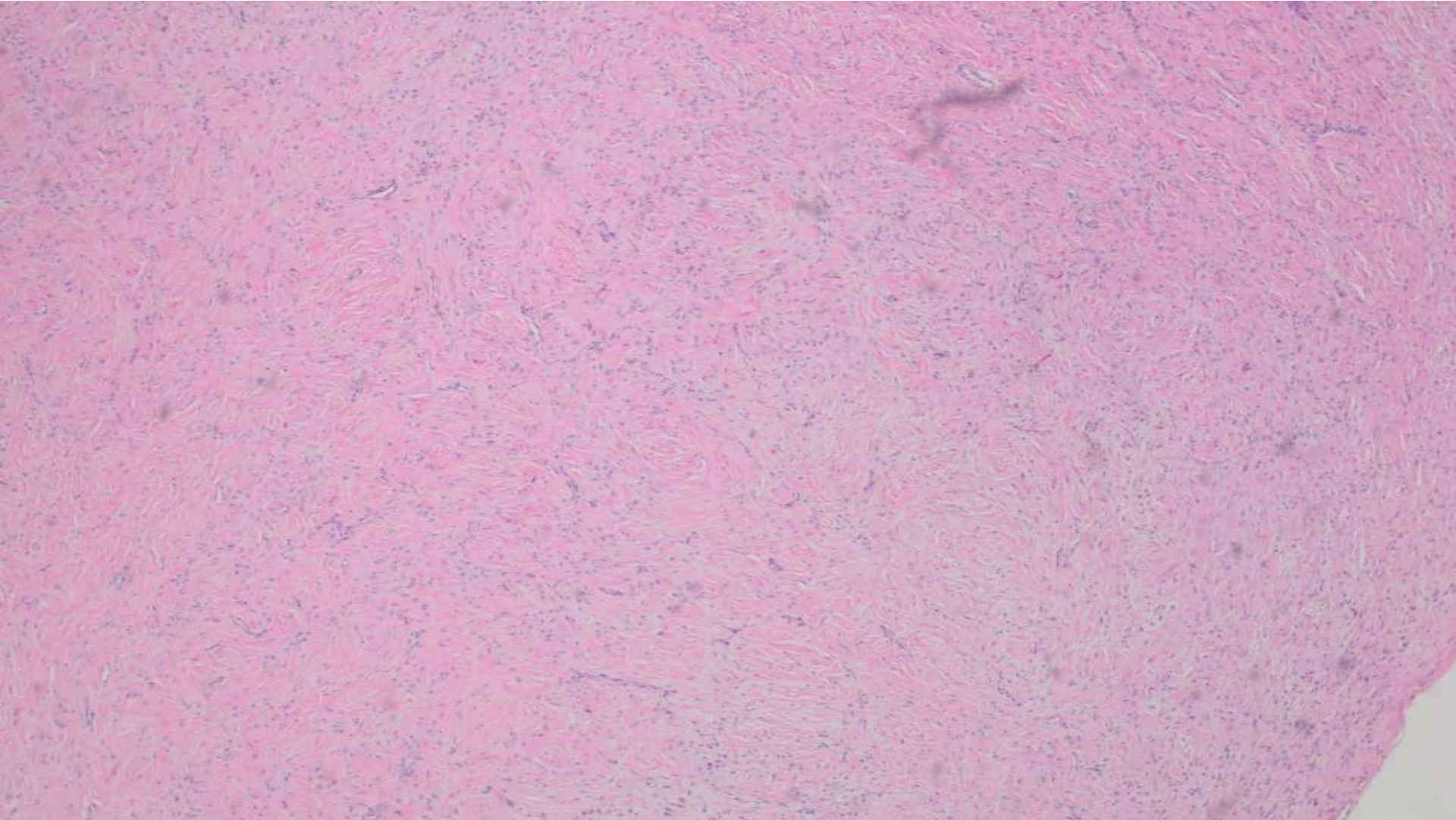


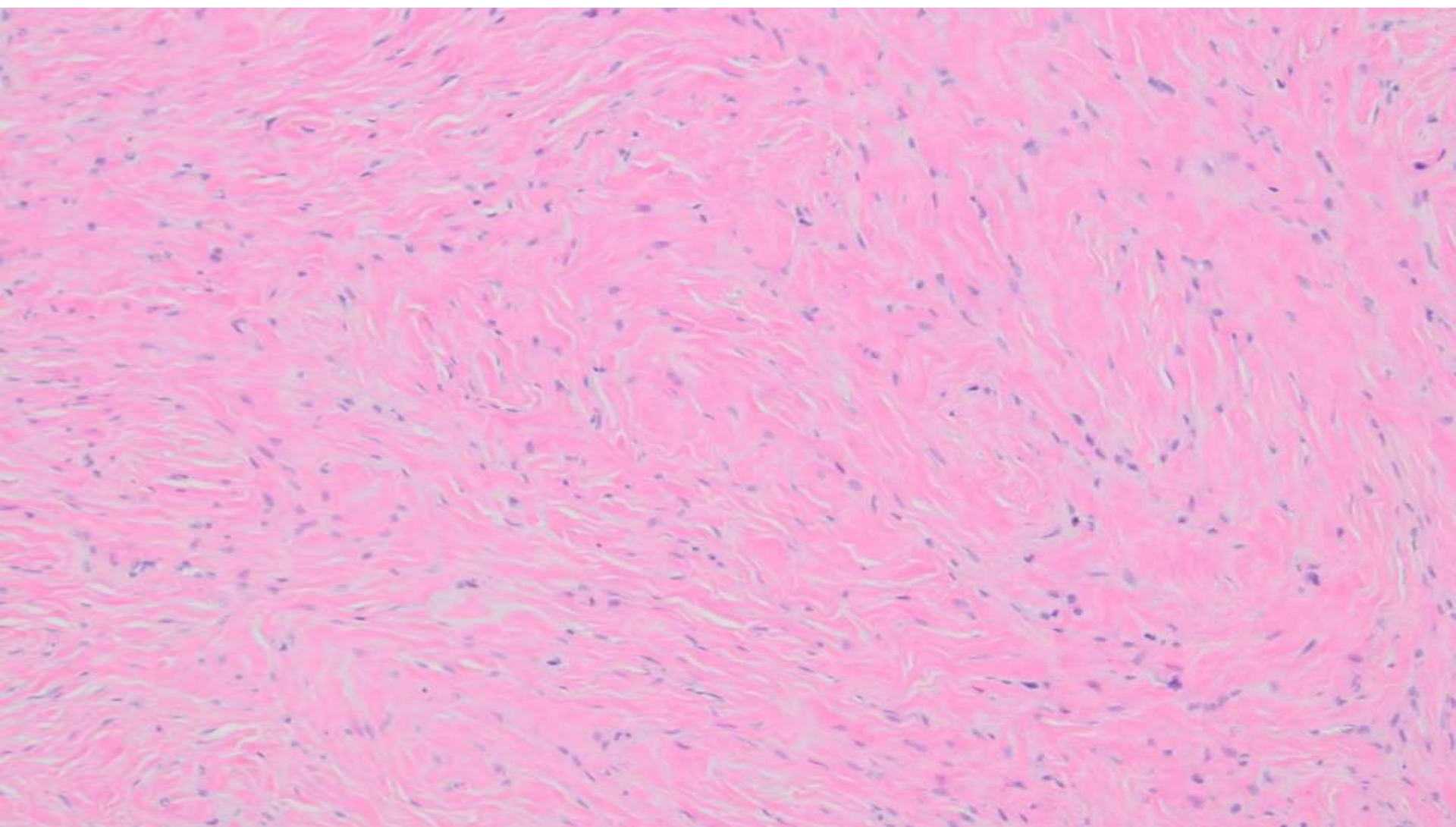
21-1202

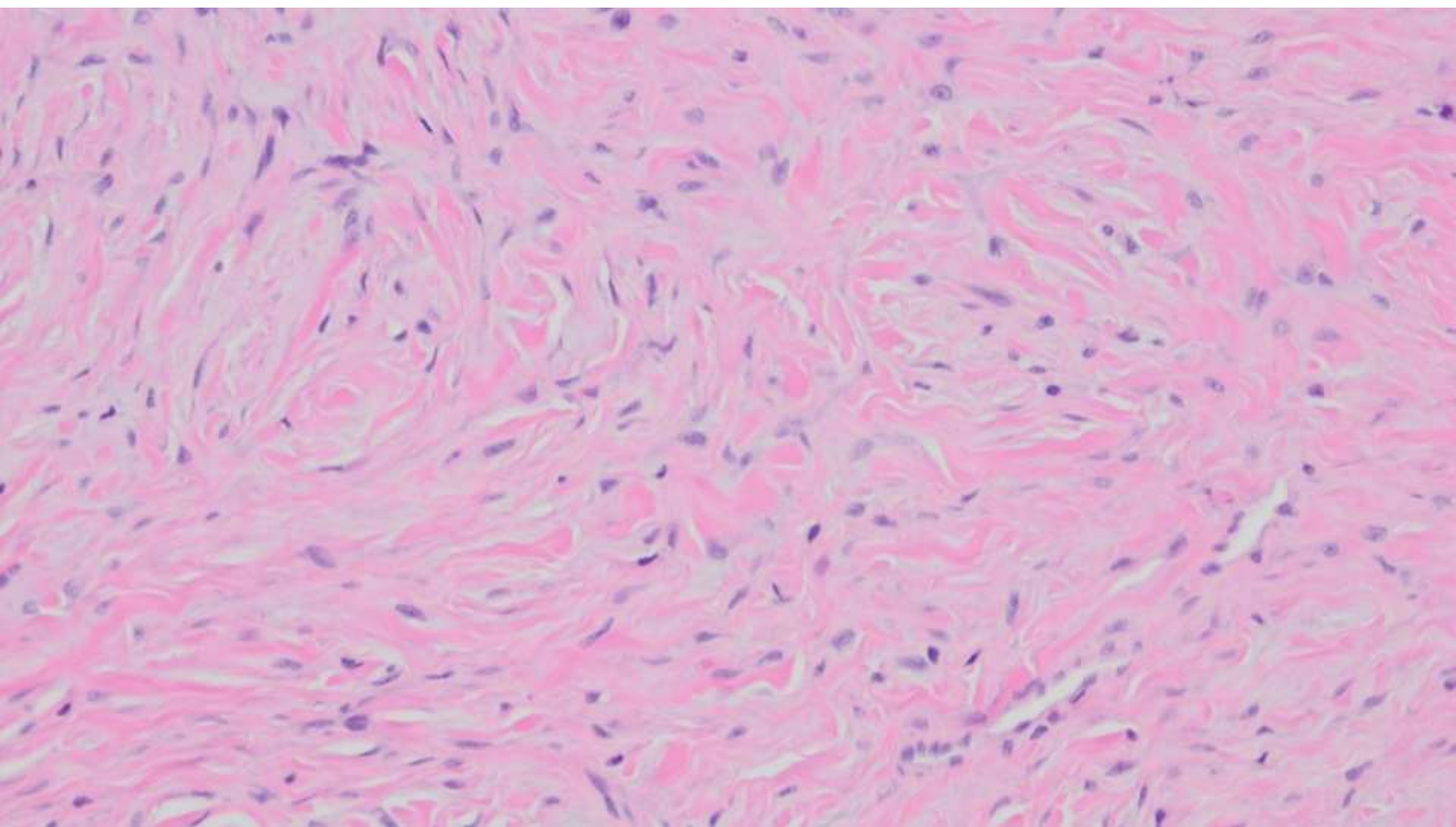
Andrew Bandy; CPMC

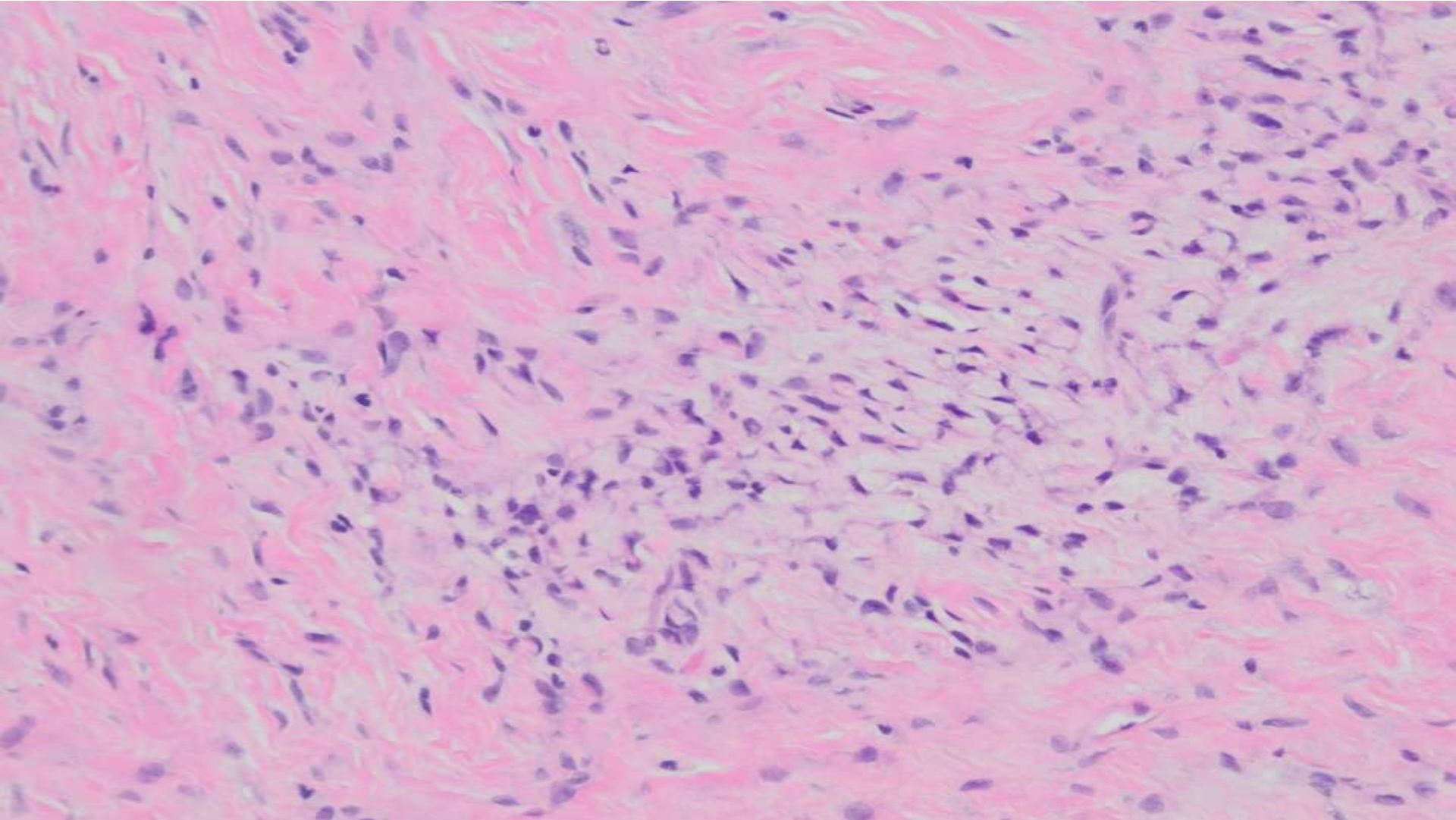
27-year-old F with 1.2cm well-circumscribed painless right long finger mass. Present for unknown period of time.









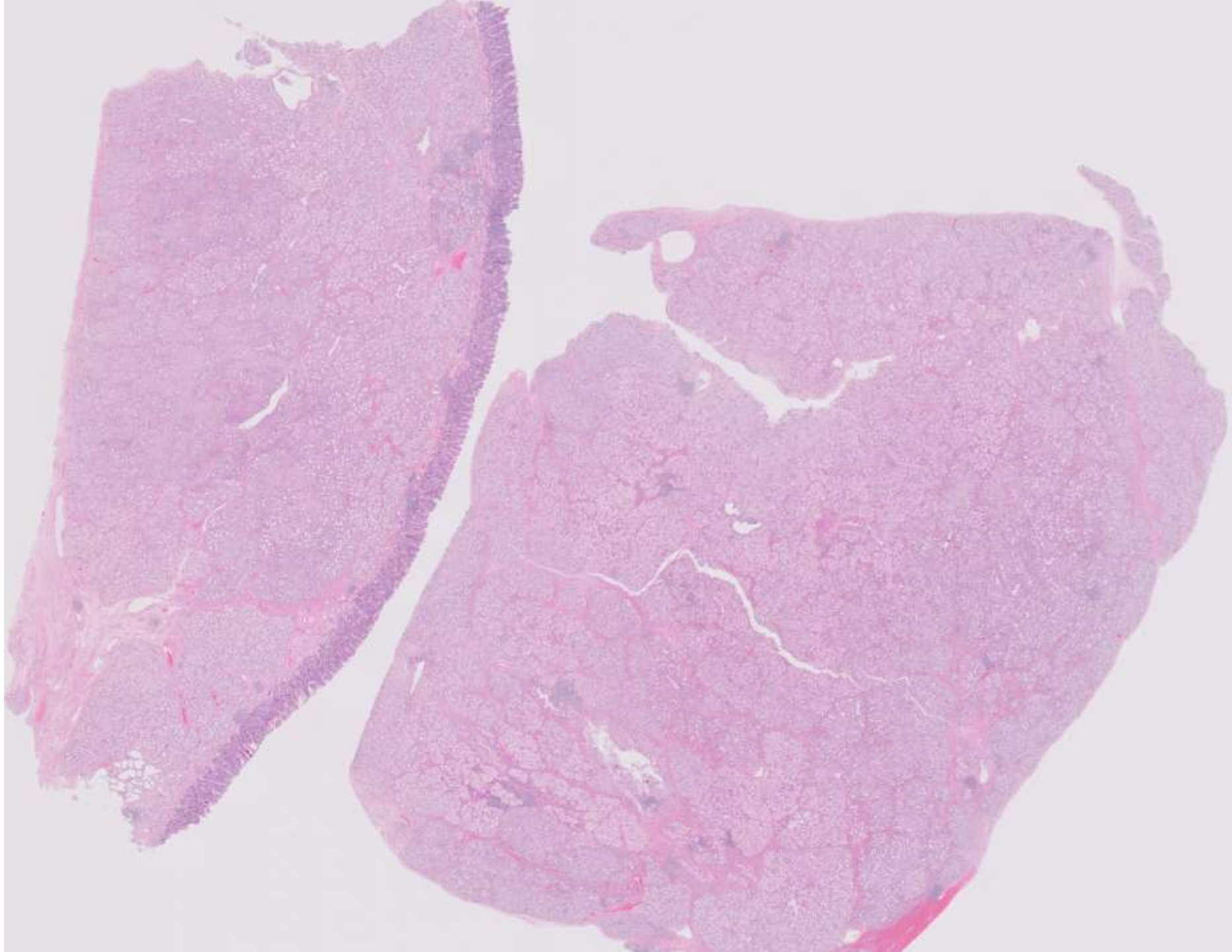


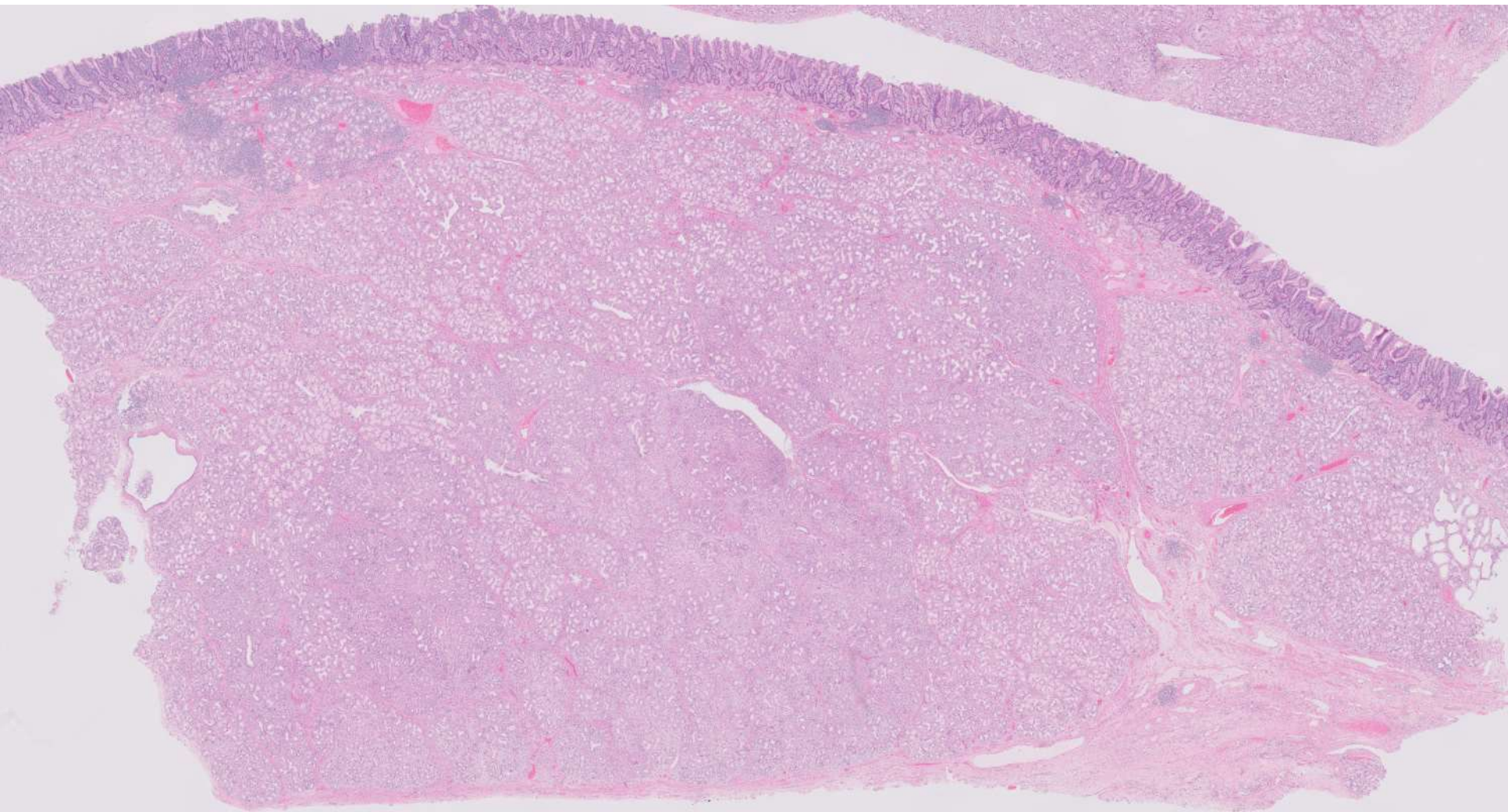


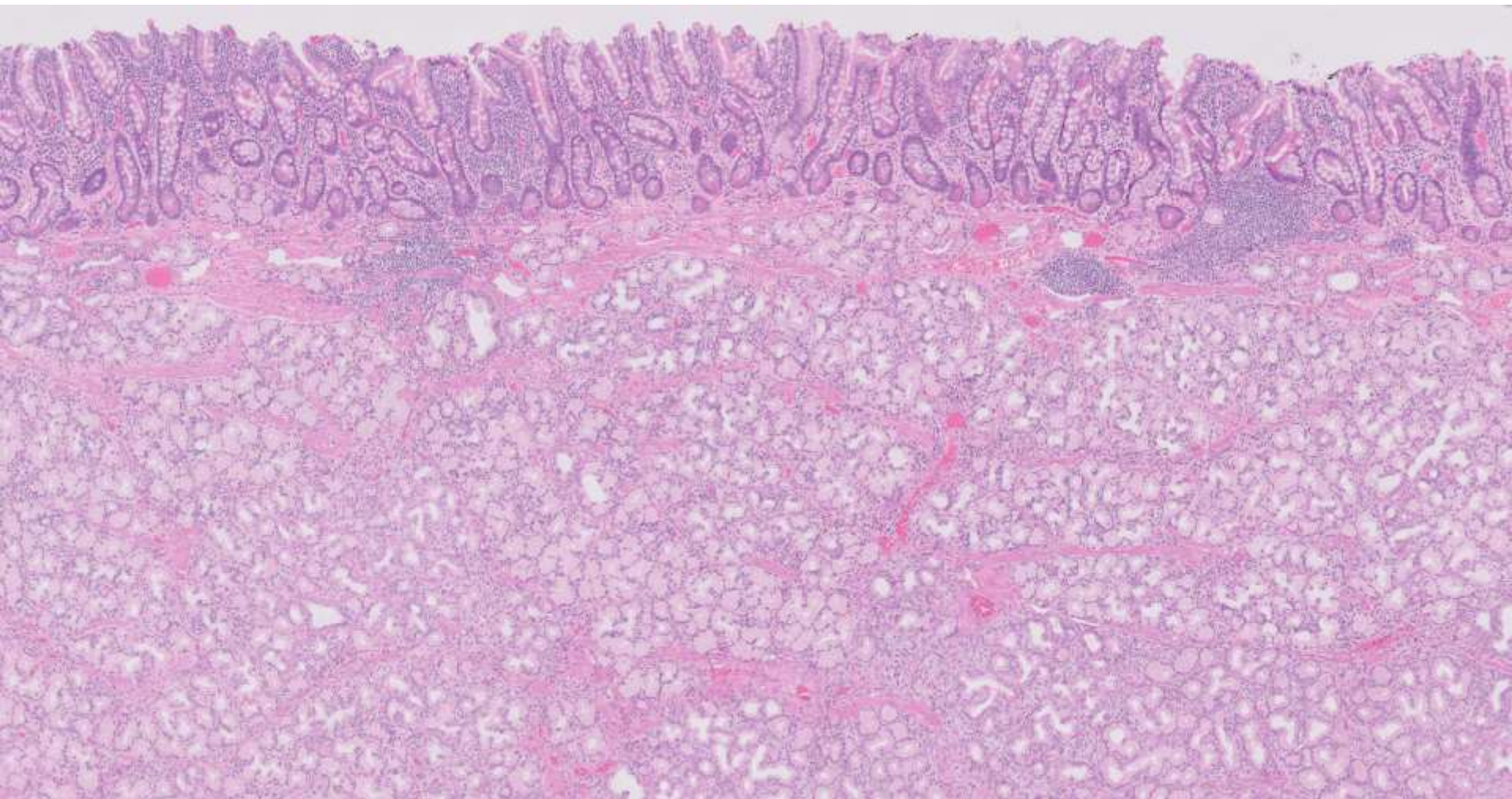
21-1203

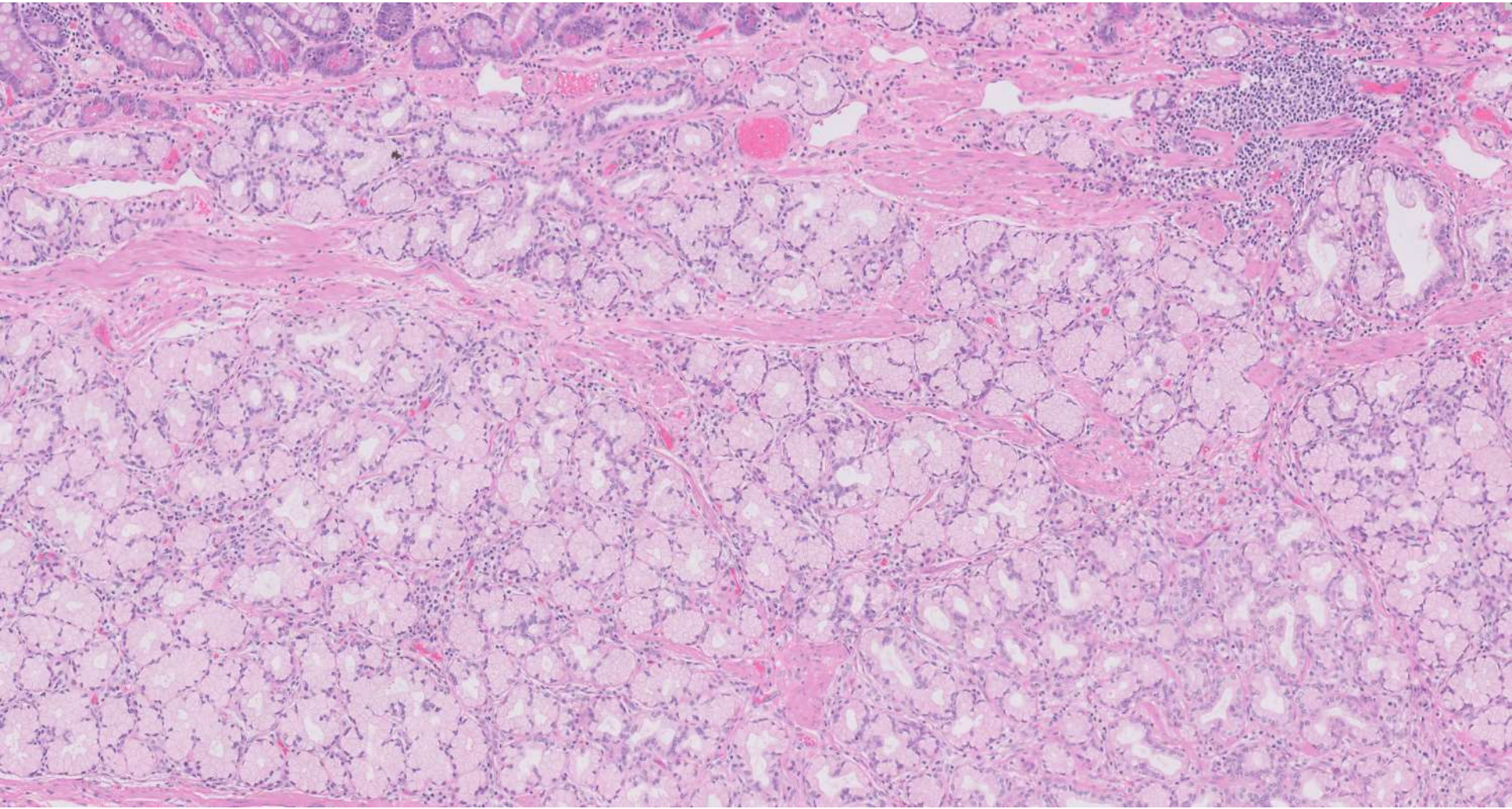
Diane Libert/David Bingham; Stanford

63-year-old F with 7.5cm mass arising in pylorus/1st
portion of duodenum.







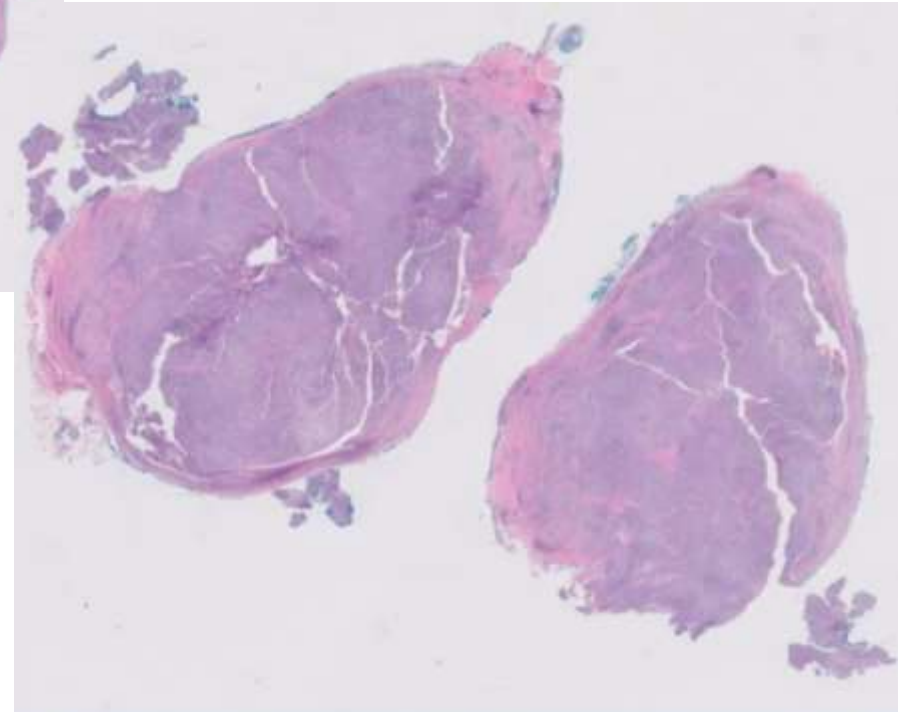
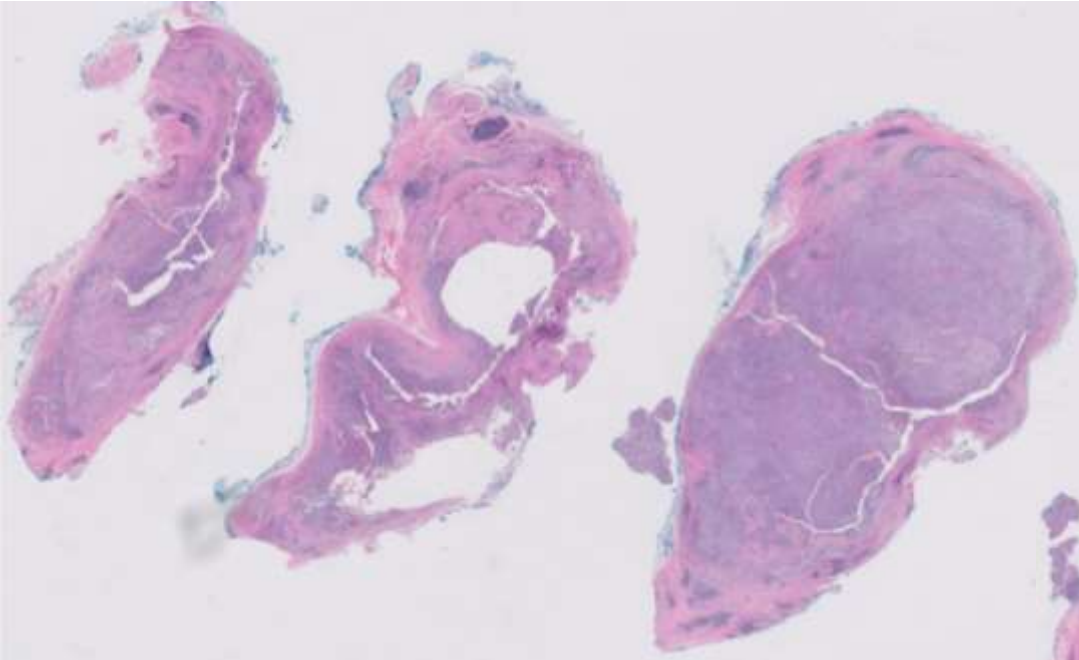


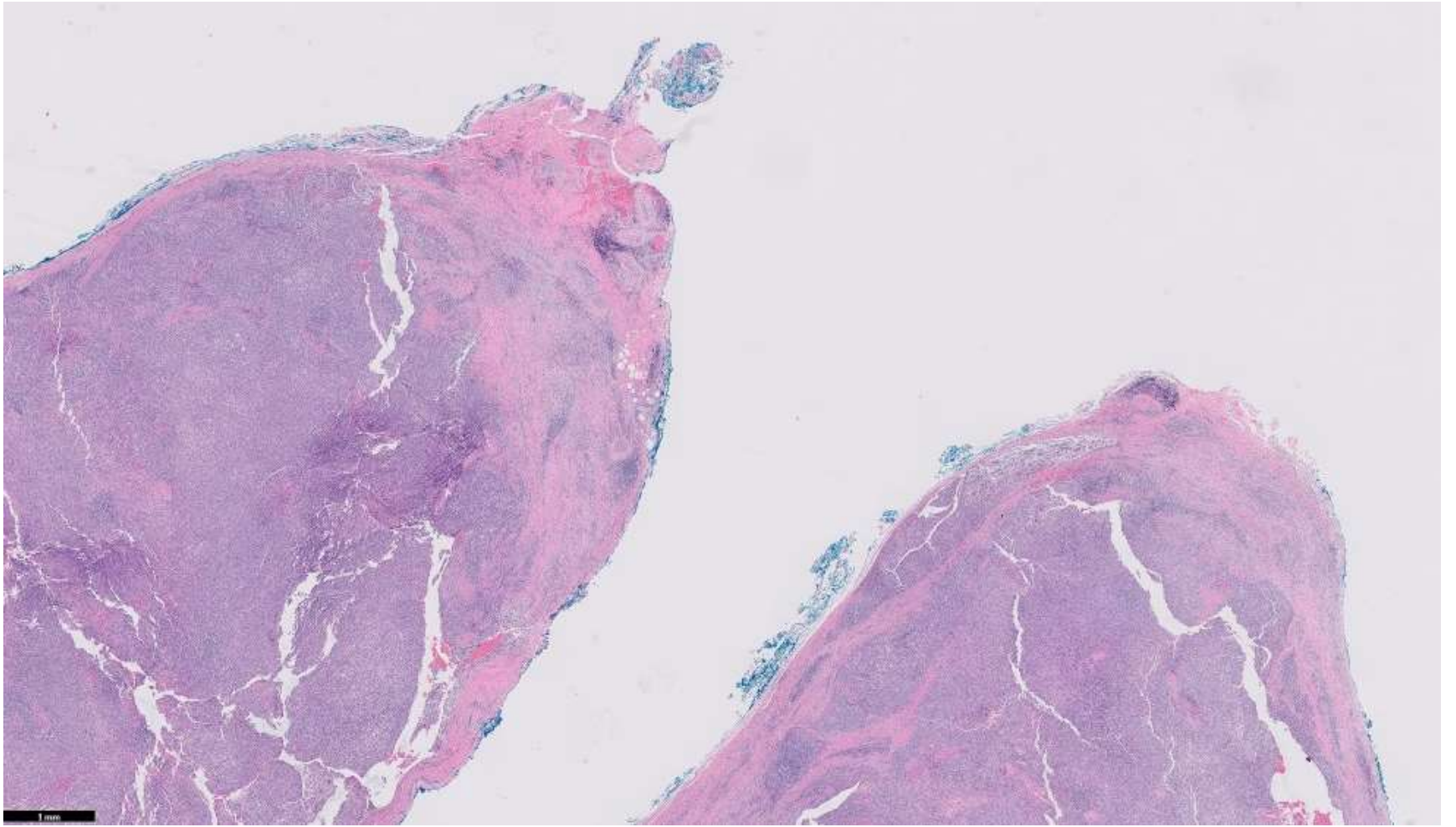


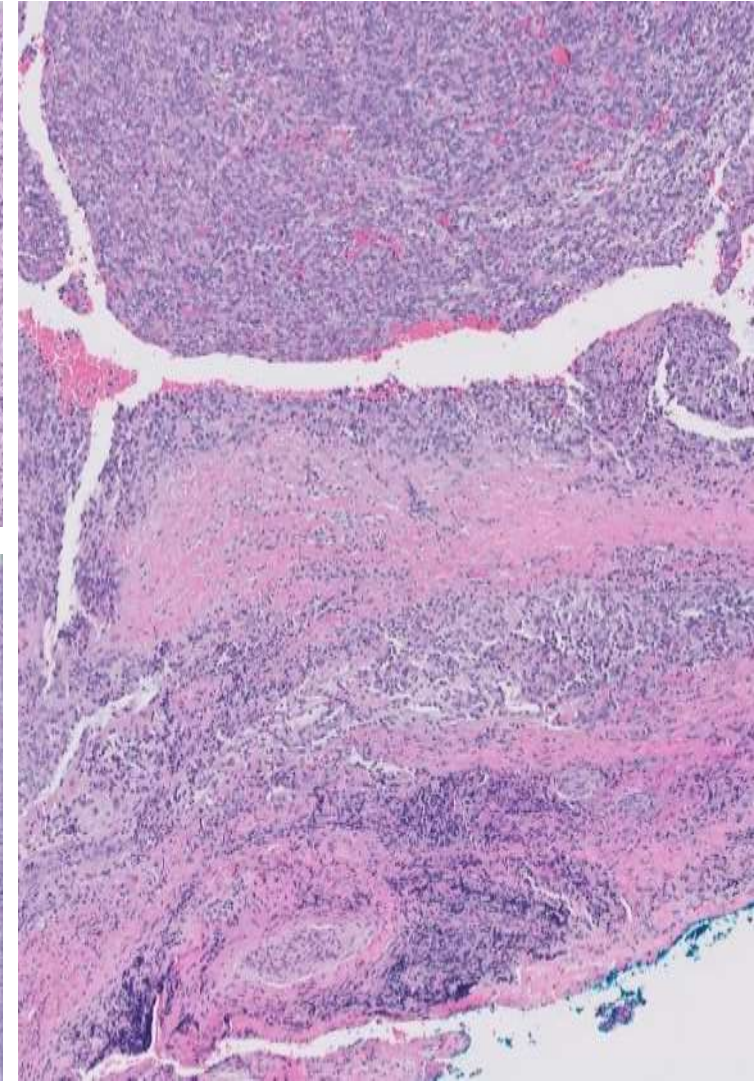
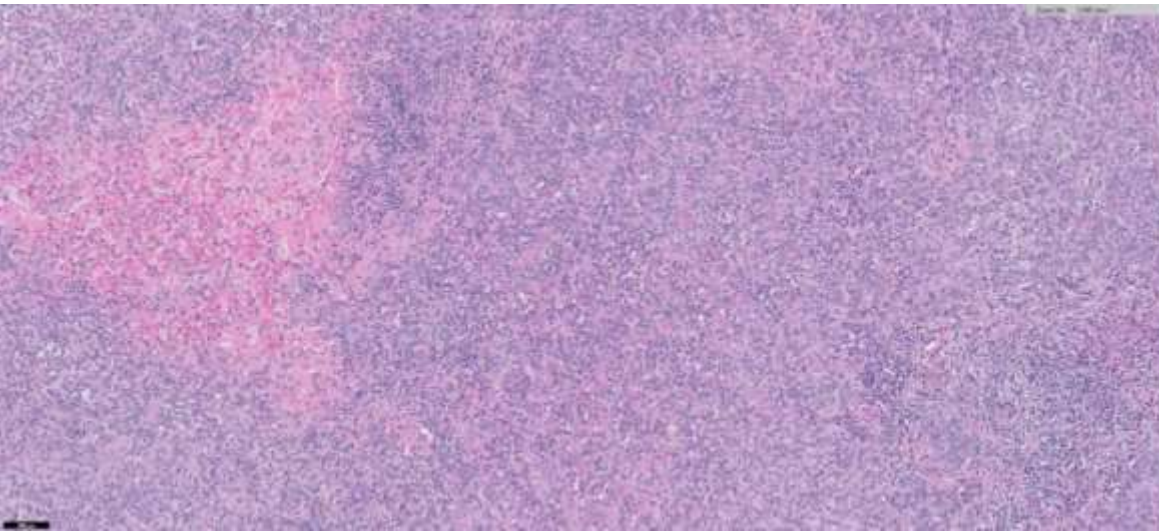
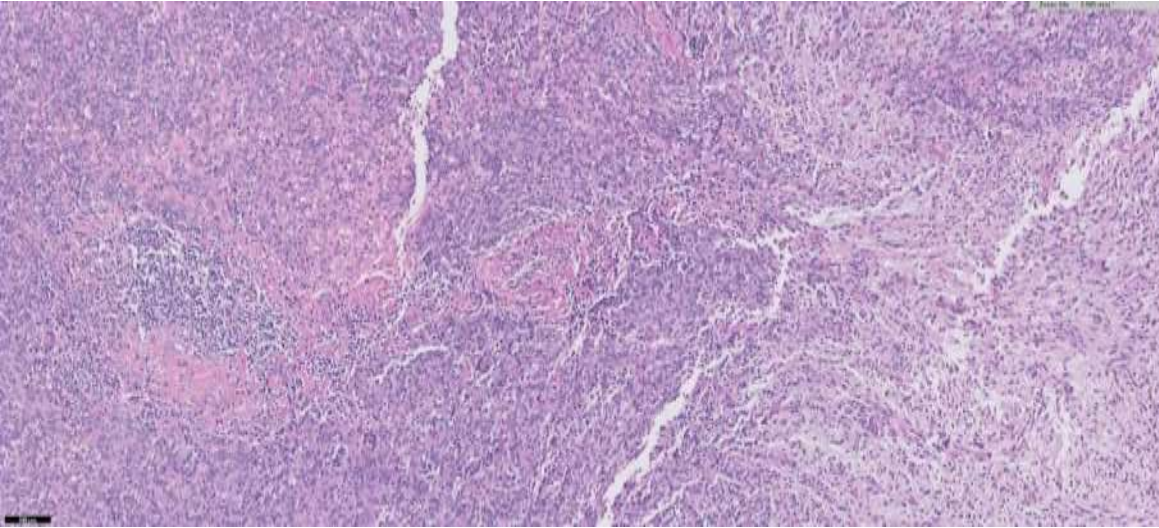
21-1204

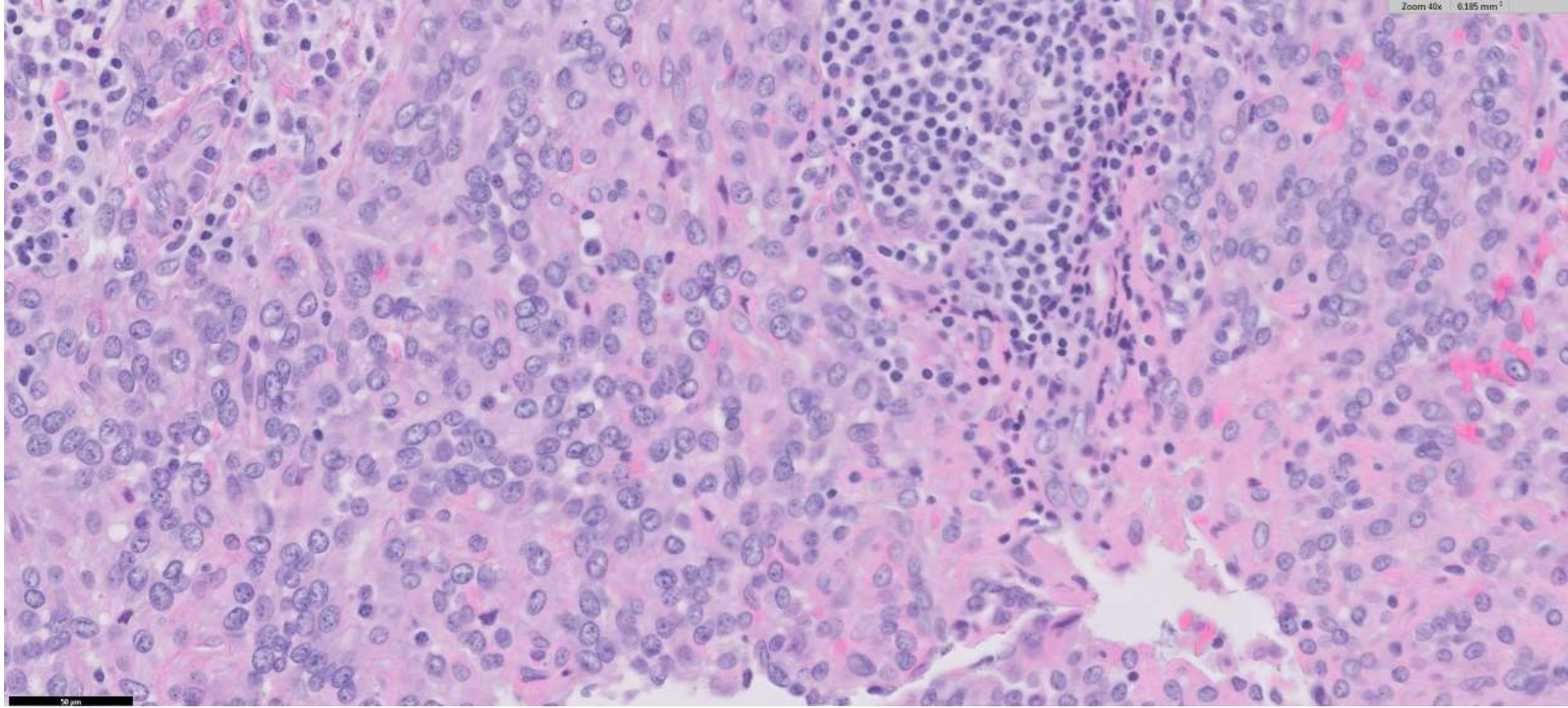
Amanda Borgen/Yue Peng; VA San Francisco; UCSF

31-year-old M with 2.5cm firm, mobile, nontender subcutaneous forehead nodule present for 10 months.

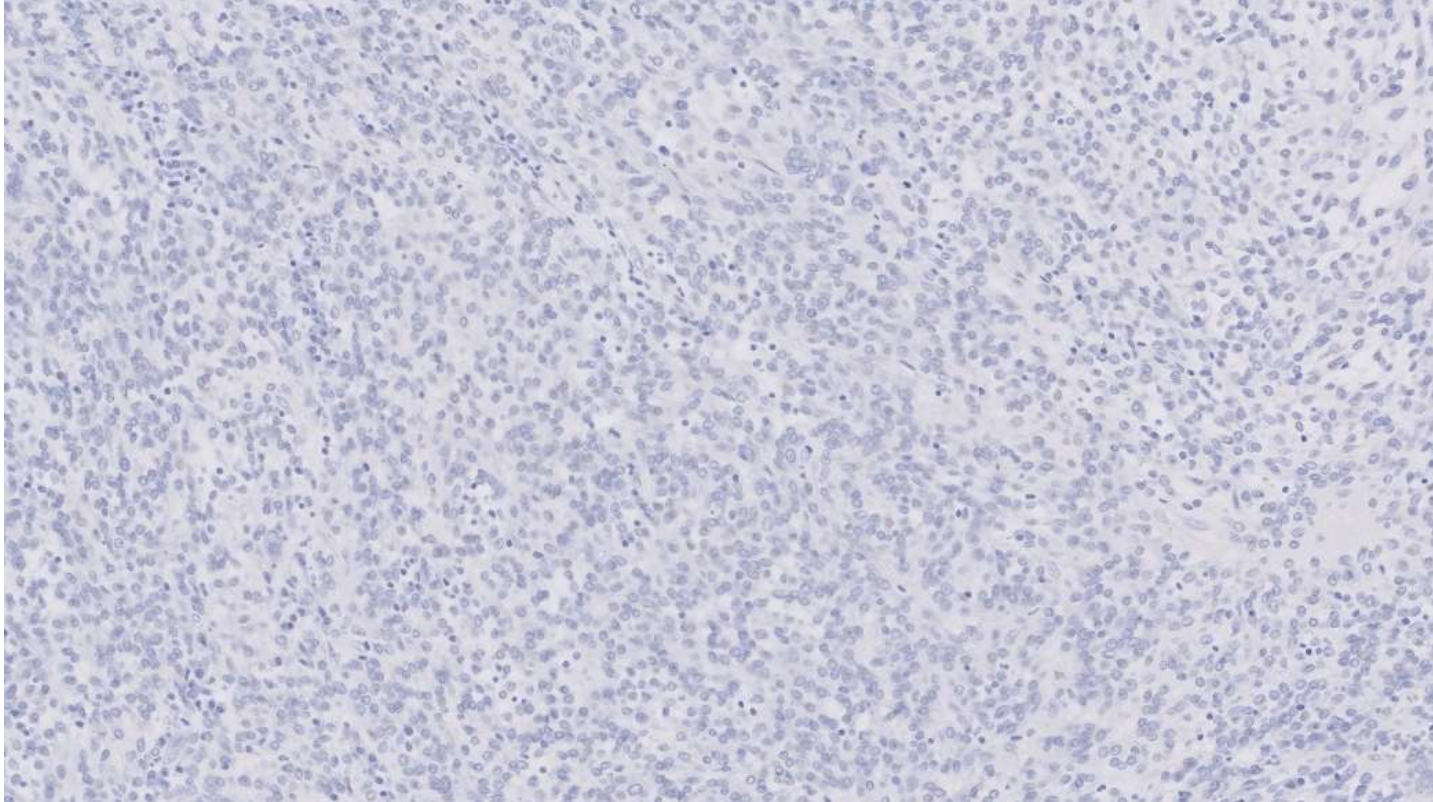




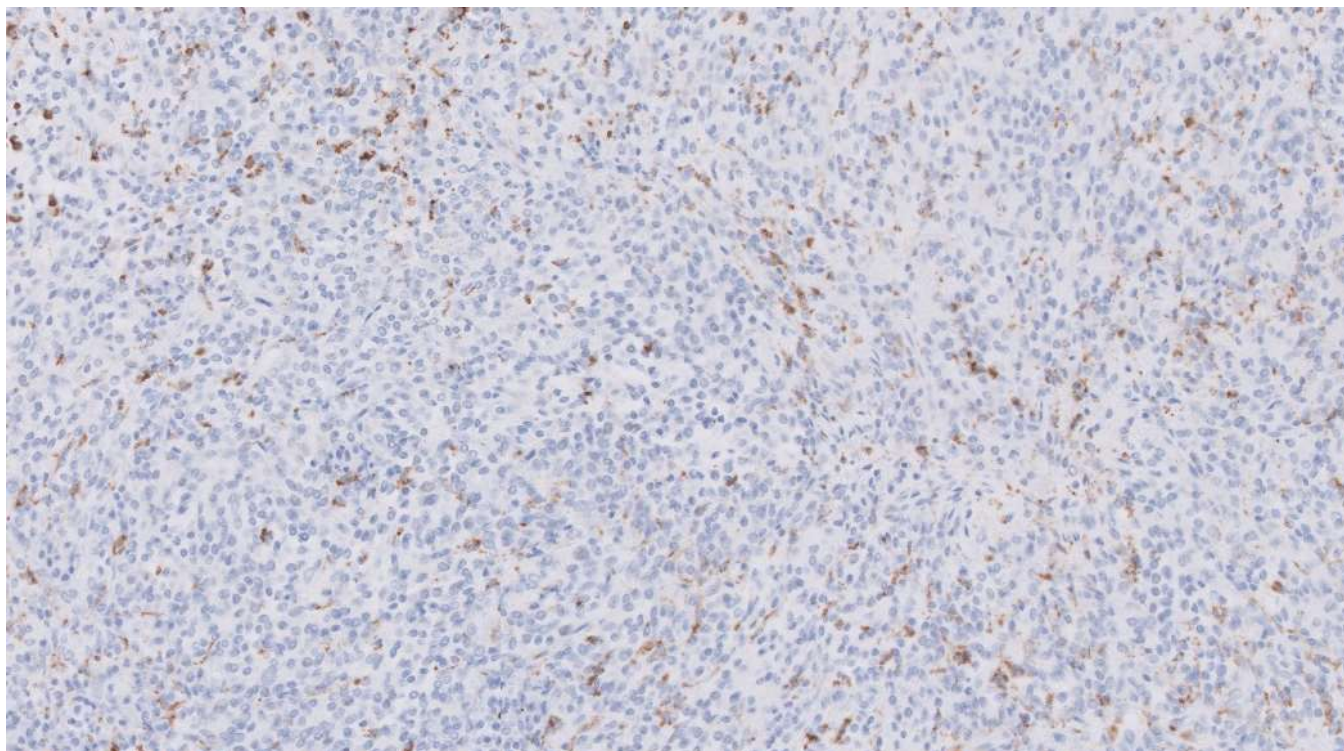




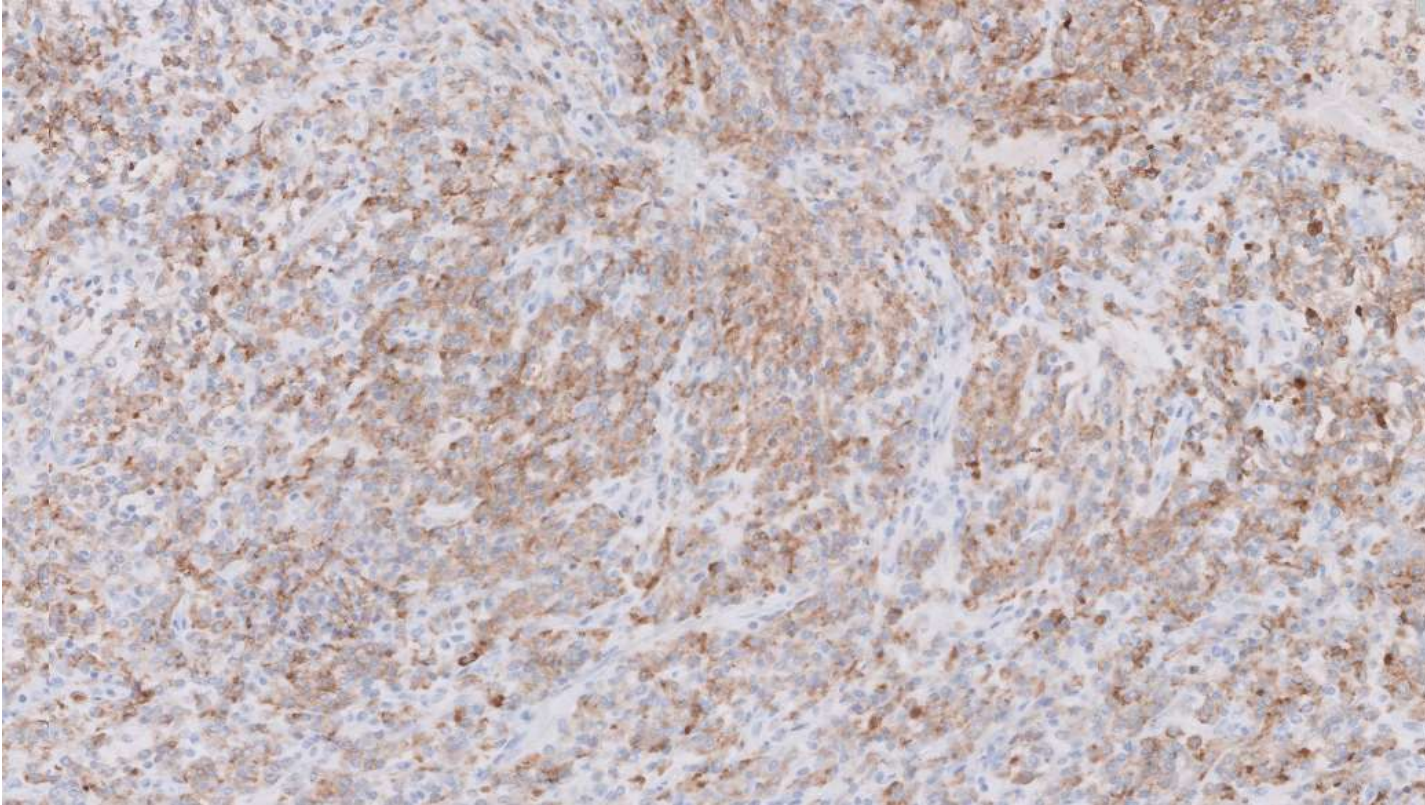
CK AE1/AE3



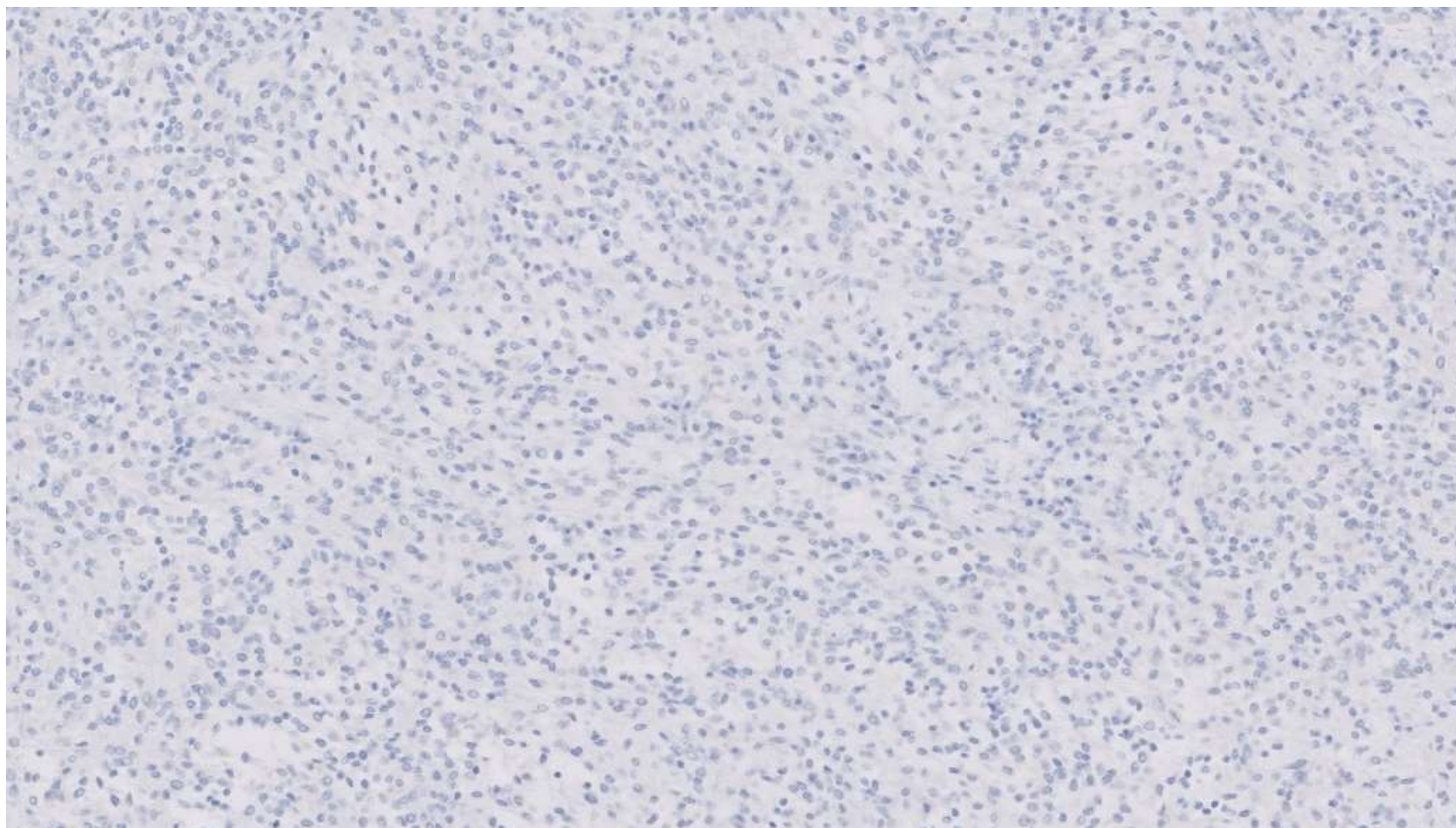
CD68



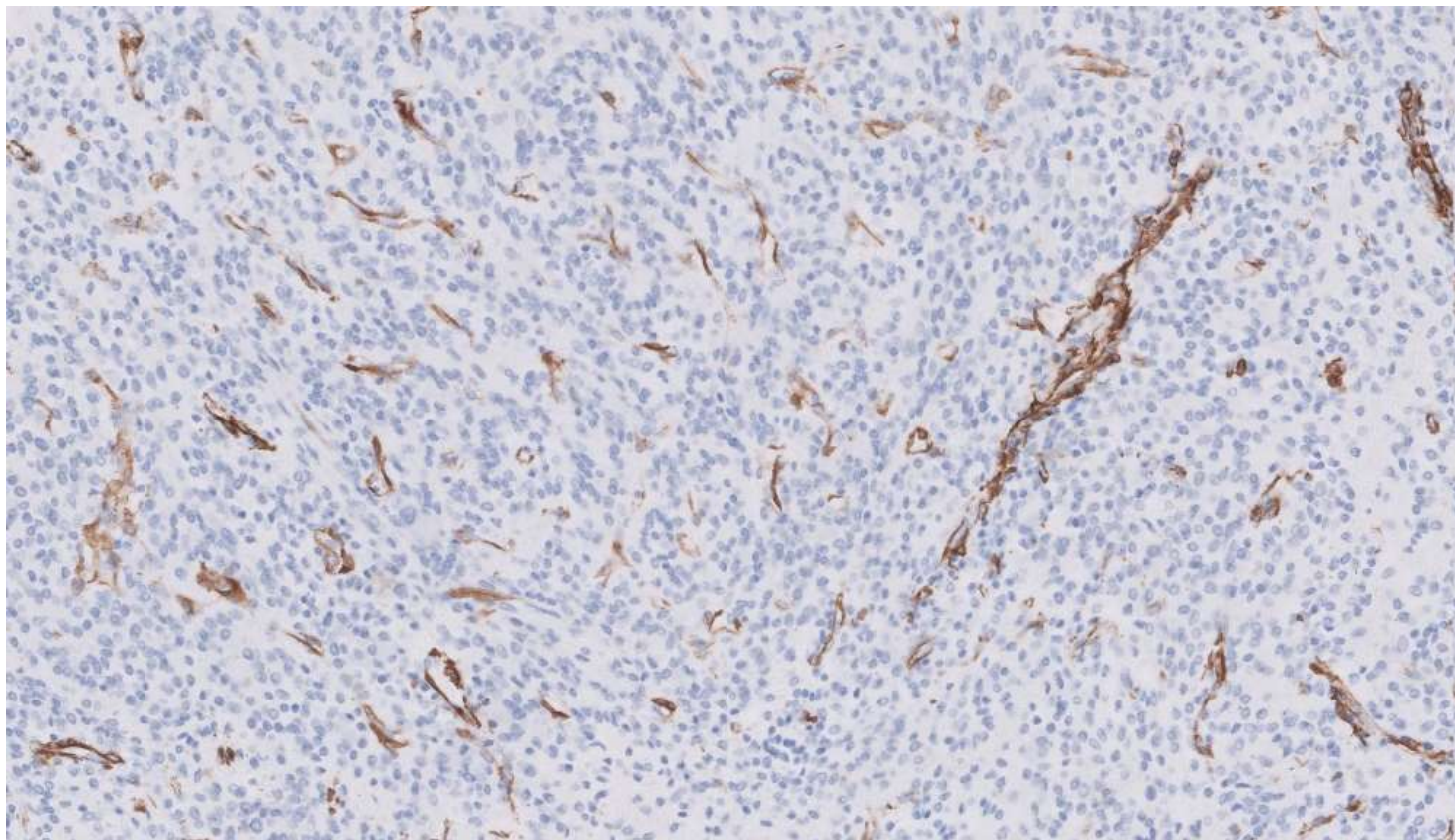
EMA



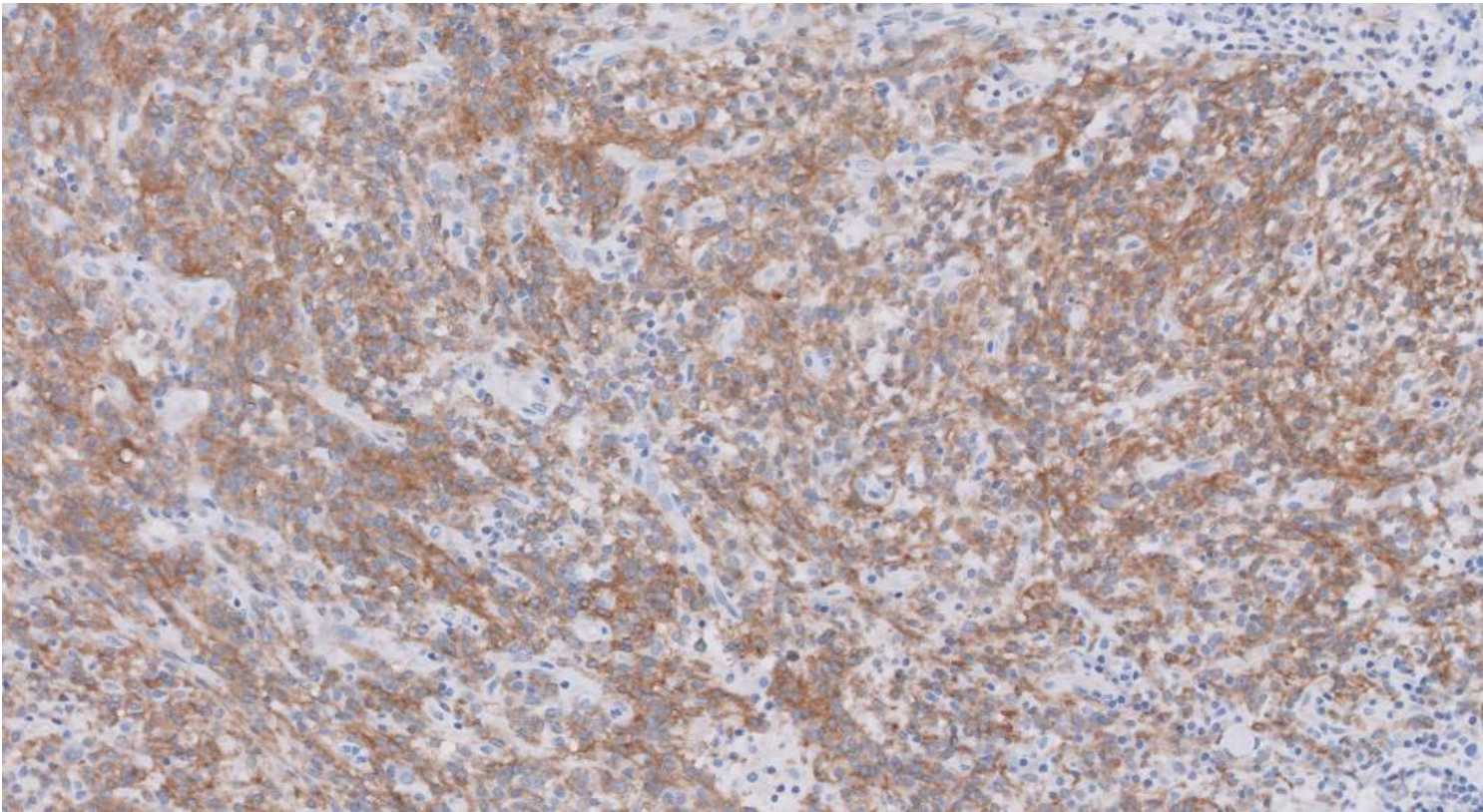
Desmin



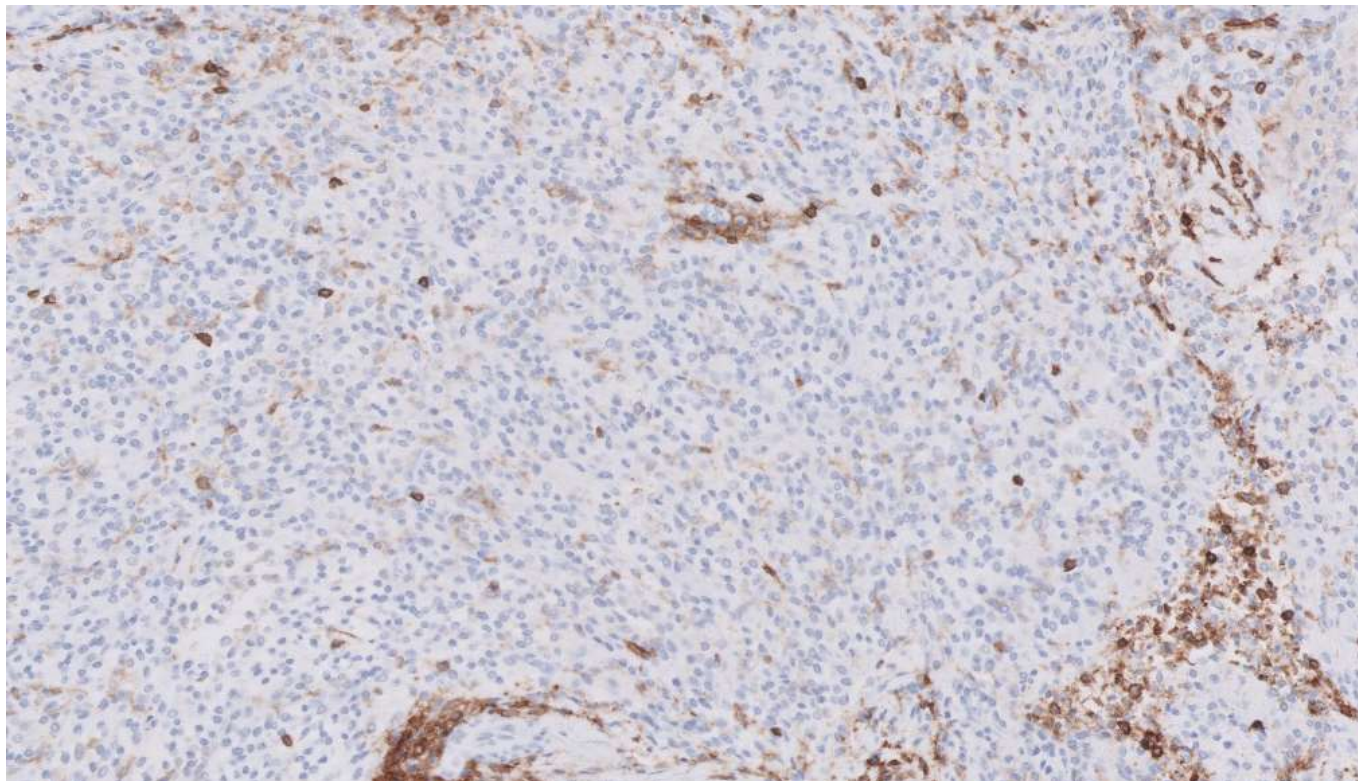
SMA



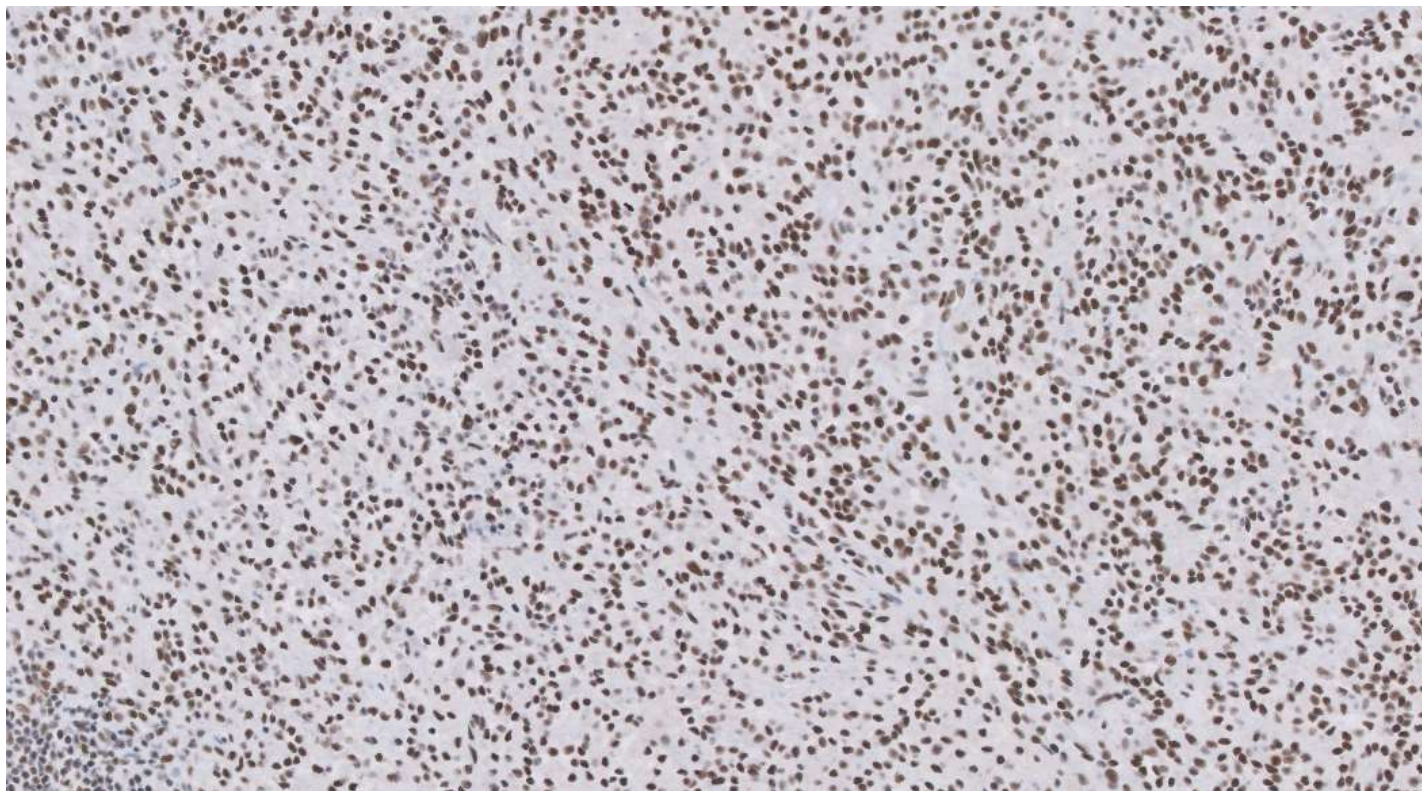CD99



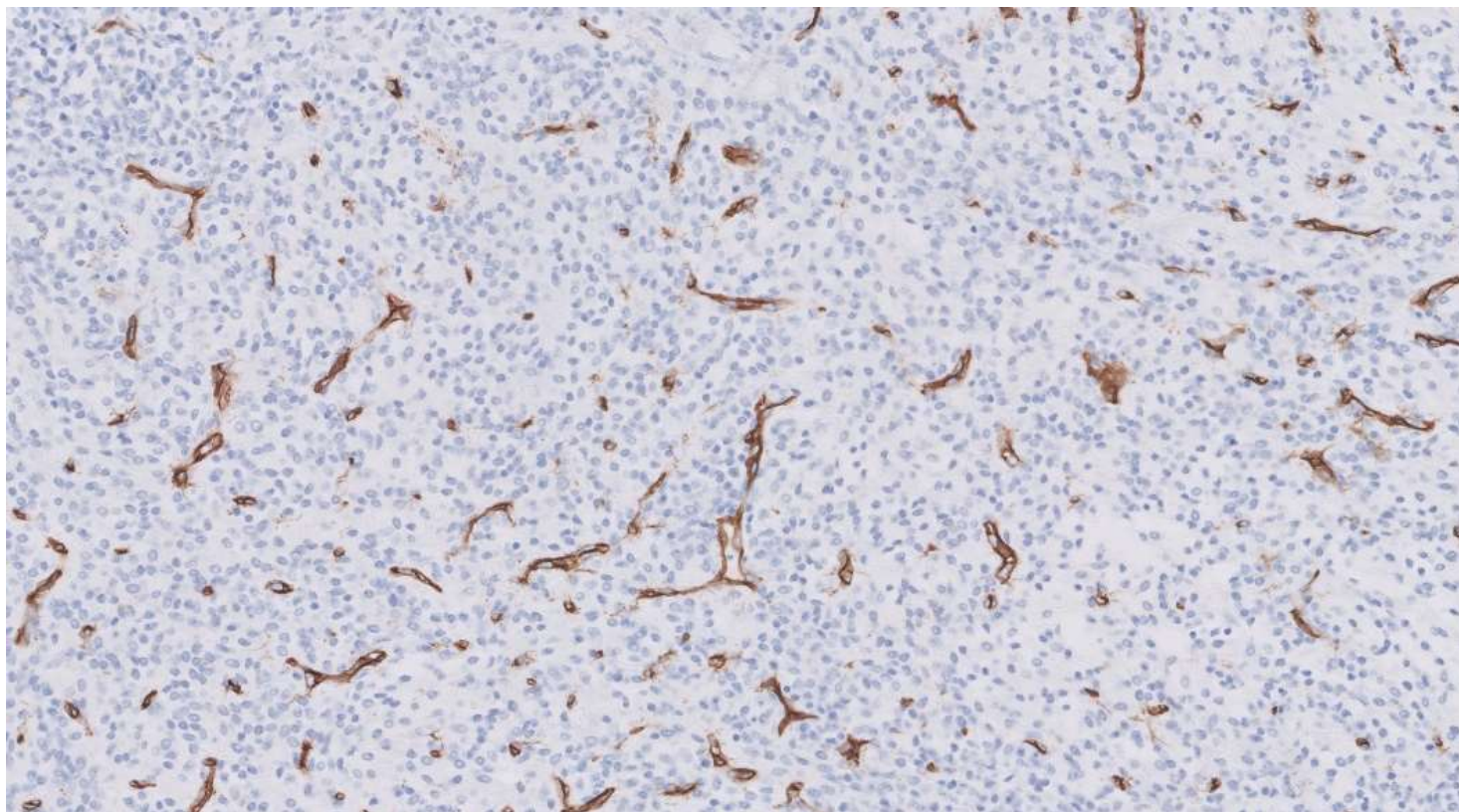
CD45



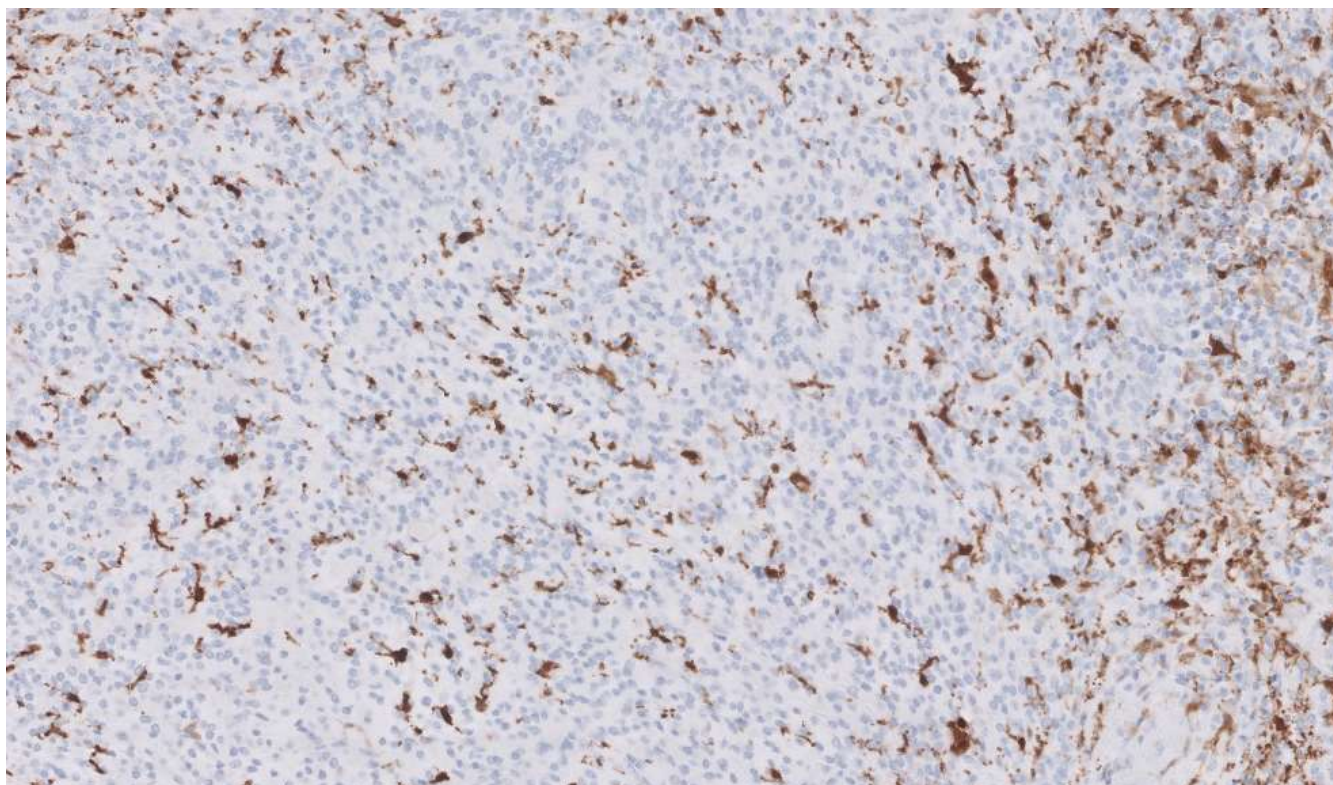
INI-1



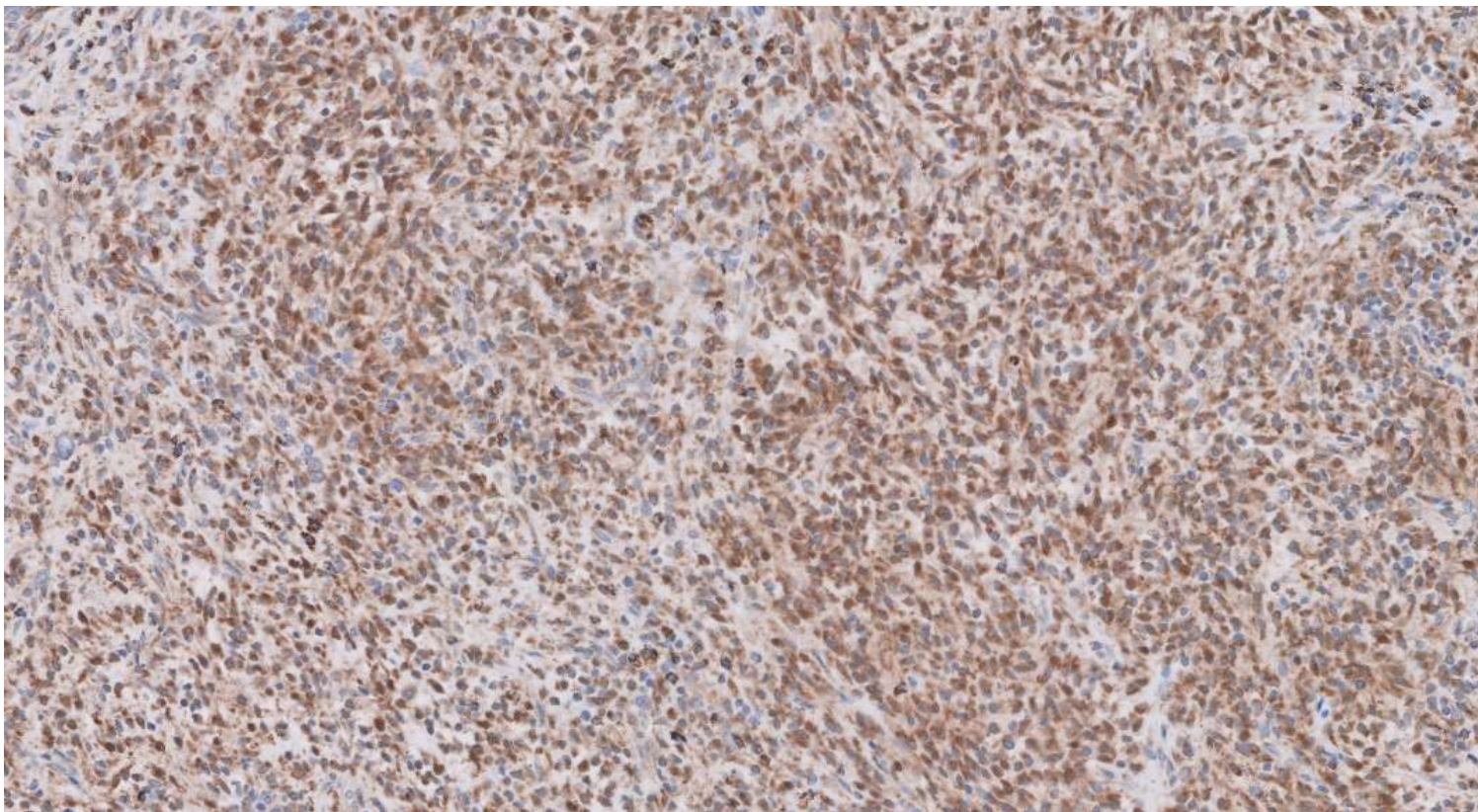
CD34



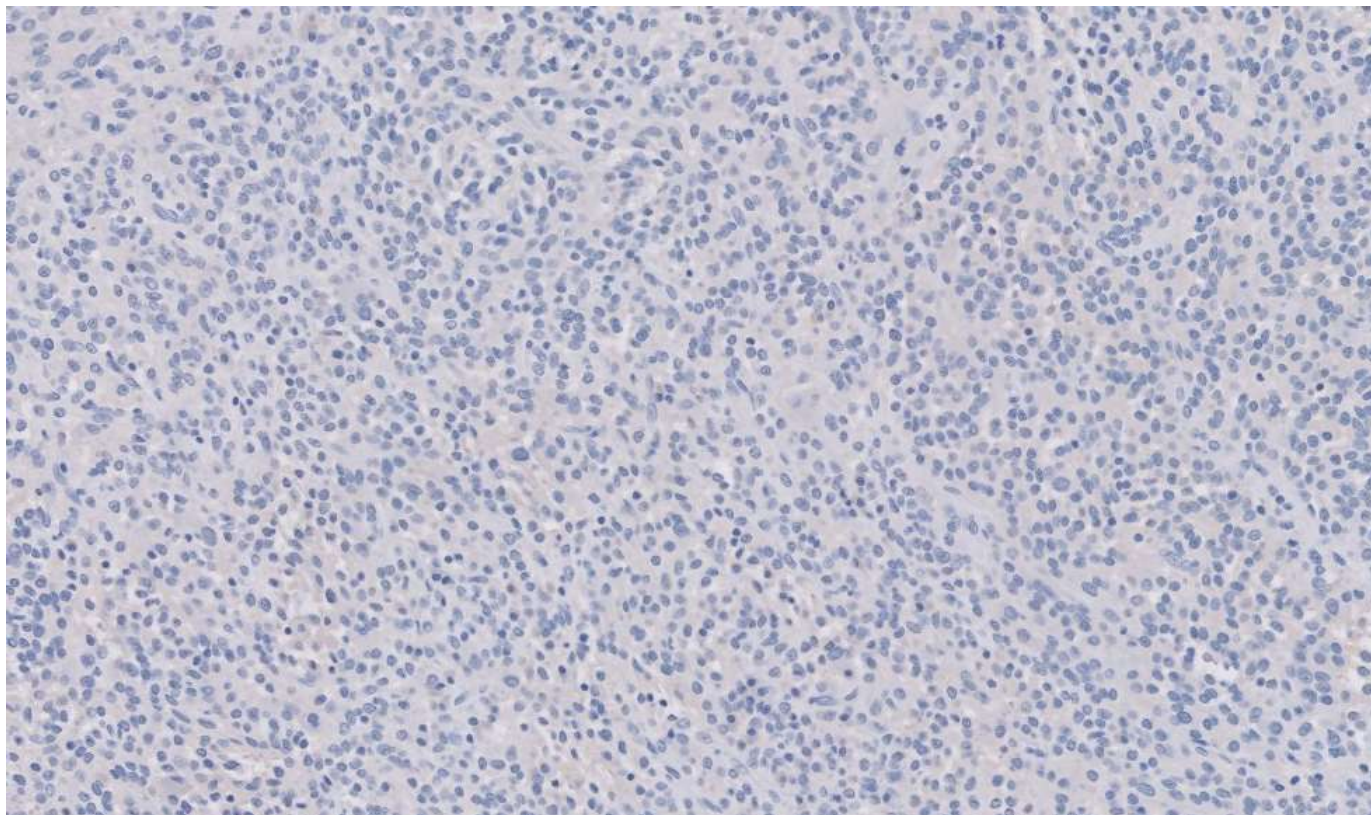
Factor 13a



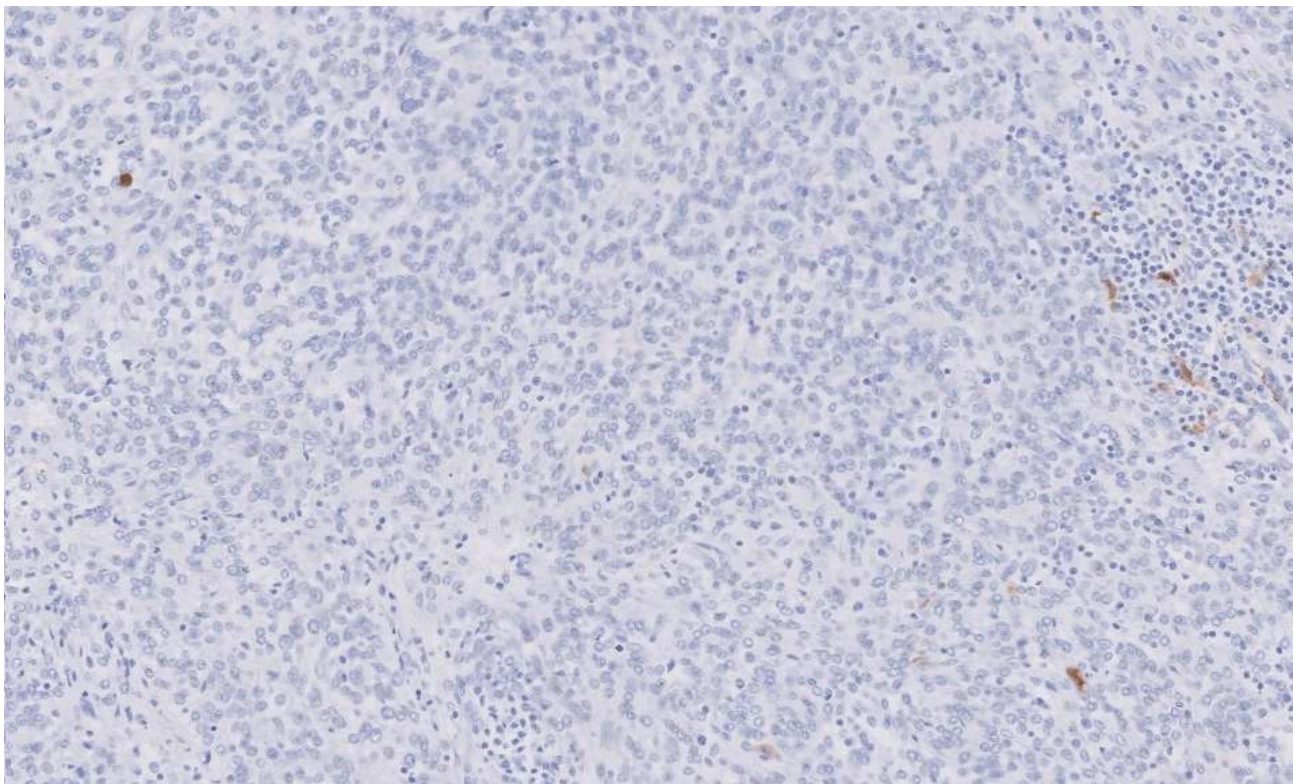
STAT6



MyoD1



S100

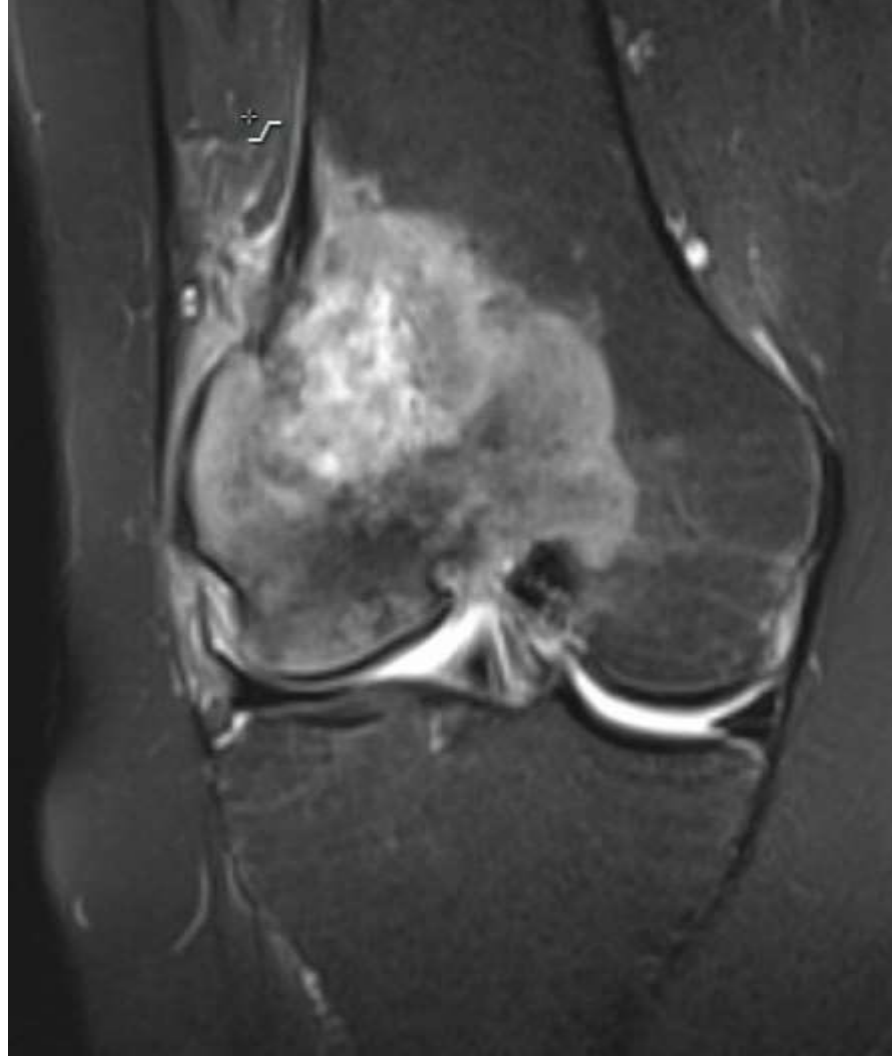
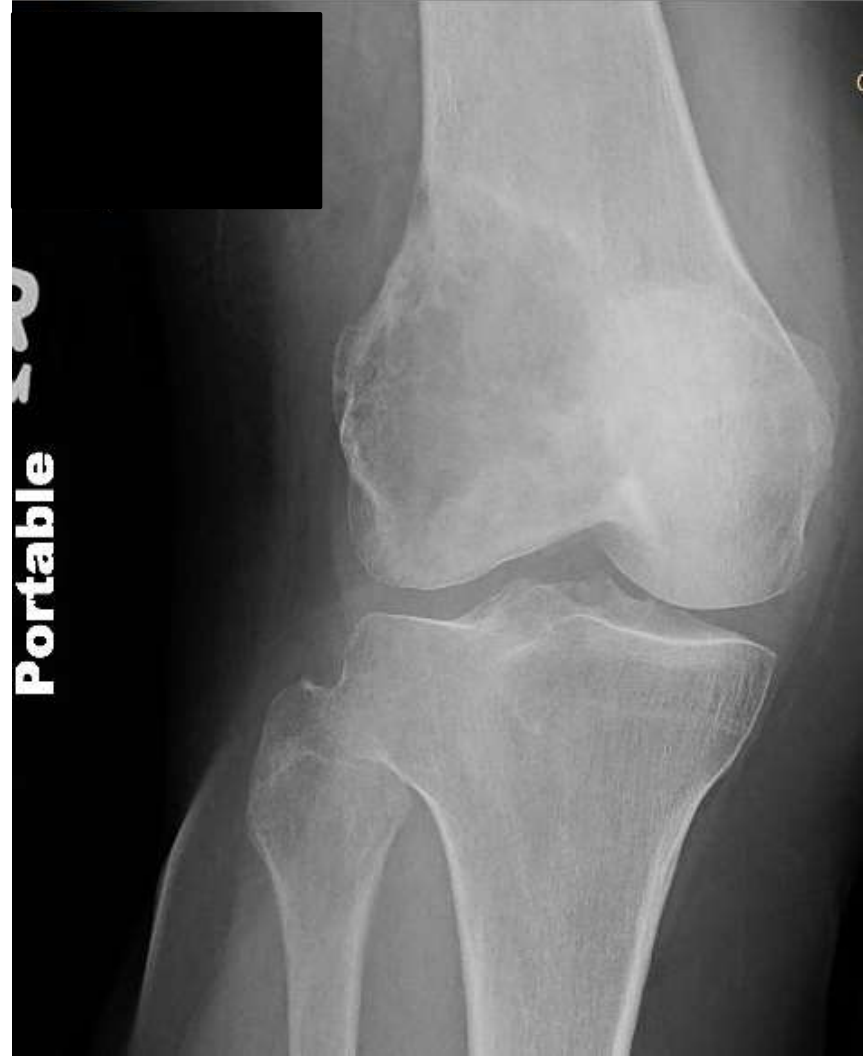

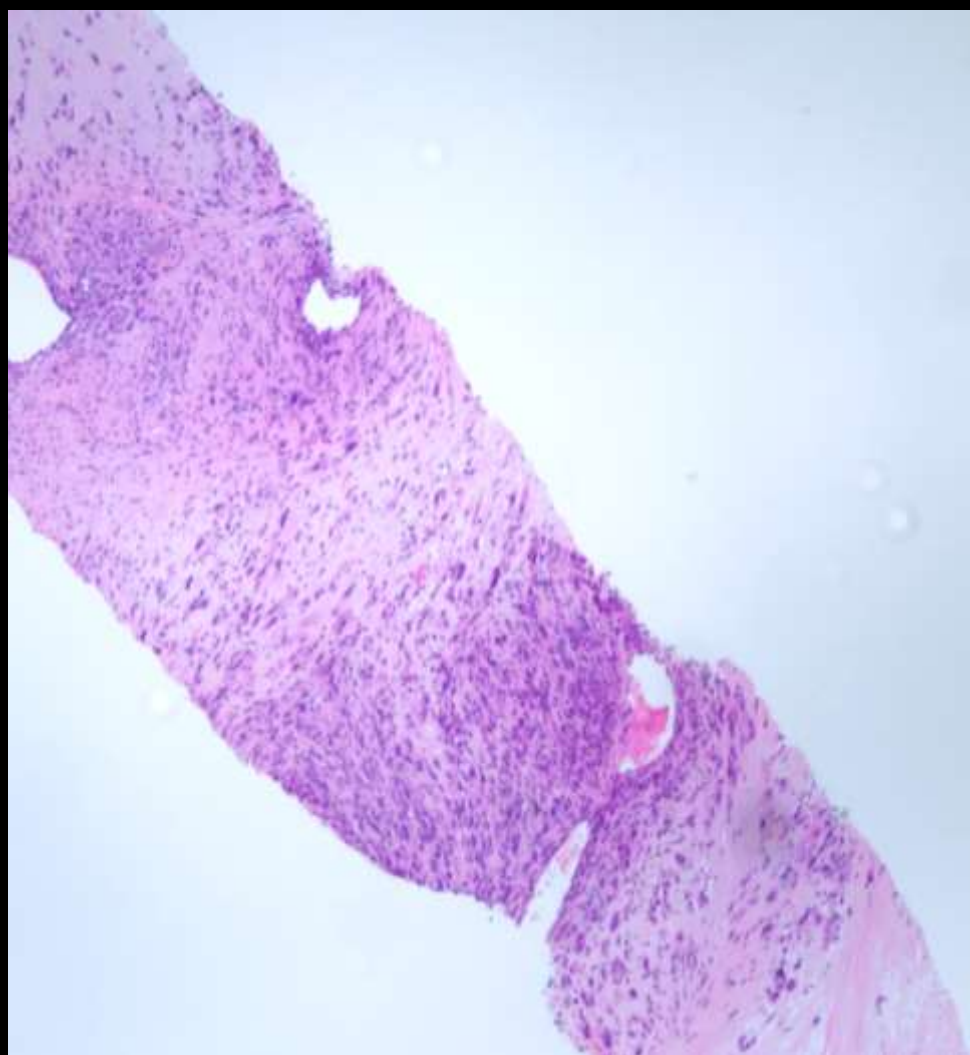
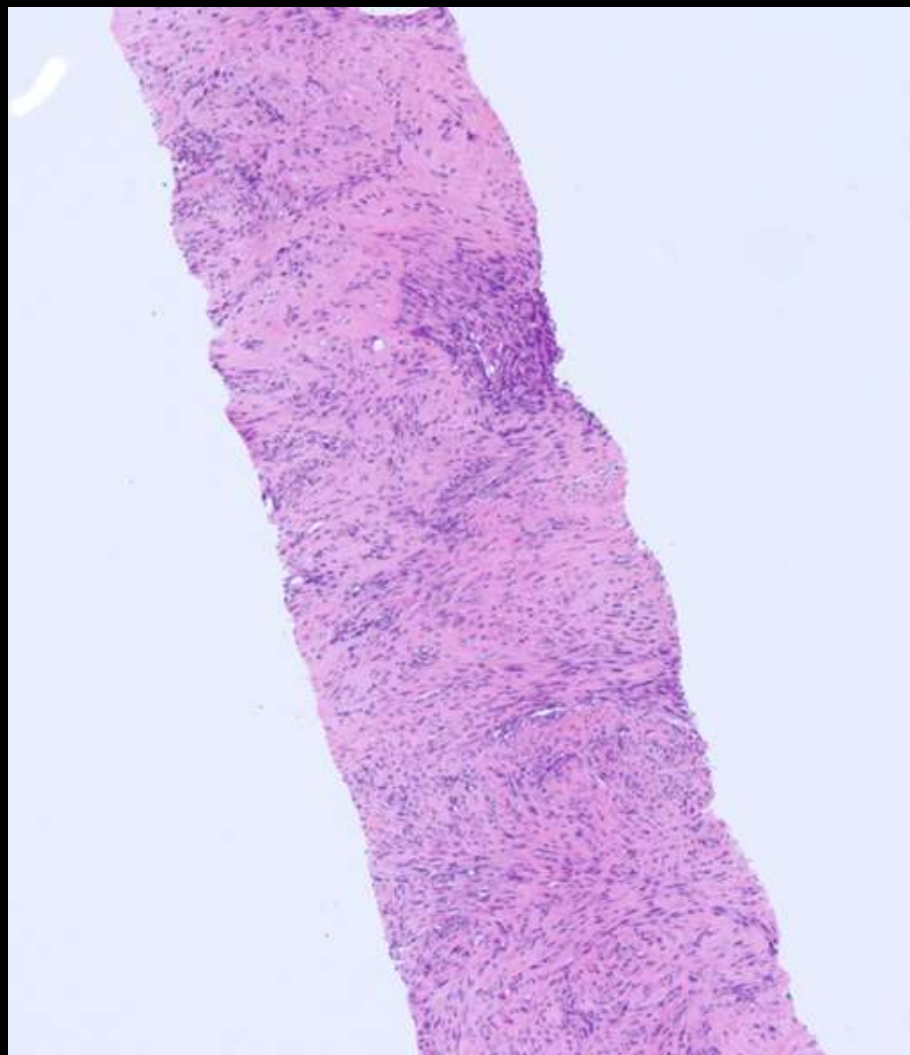


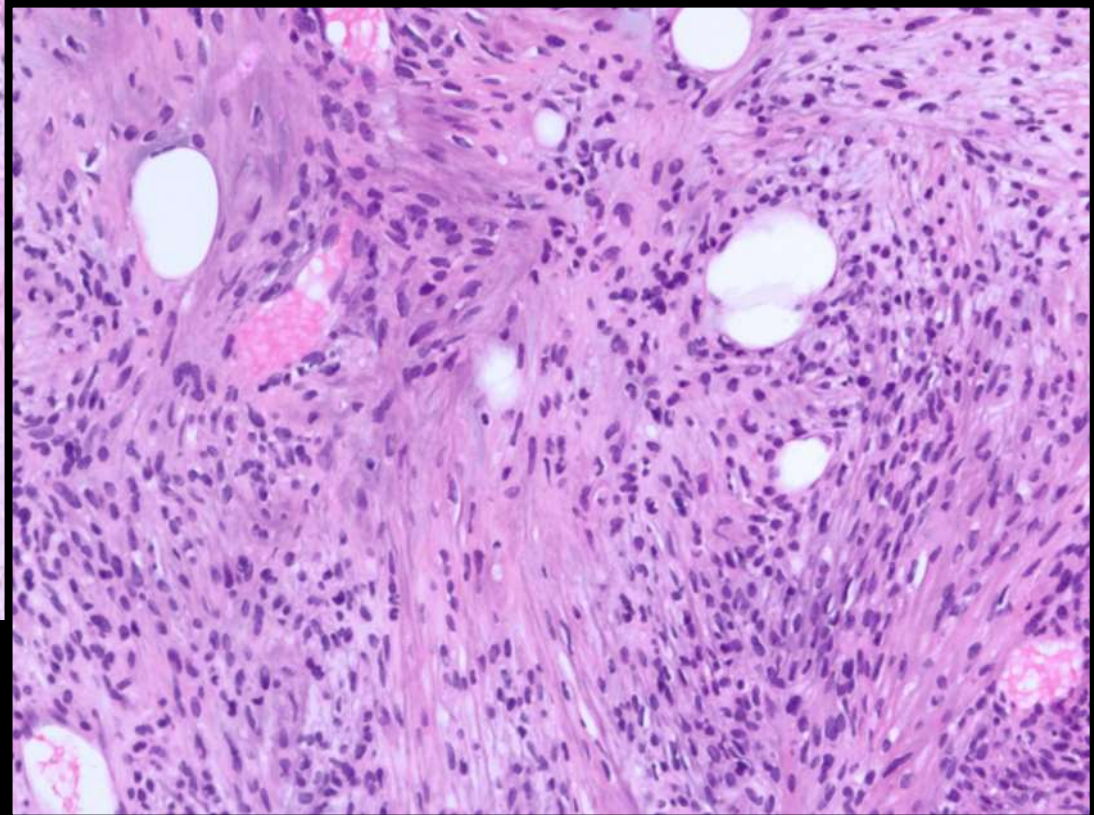
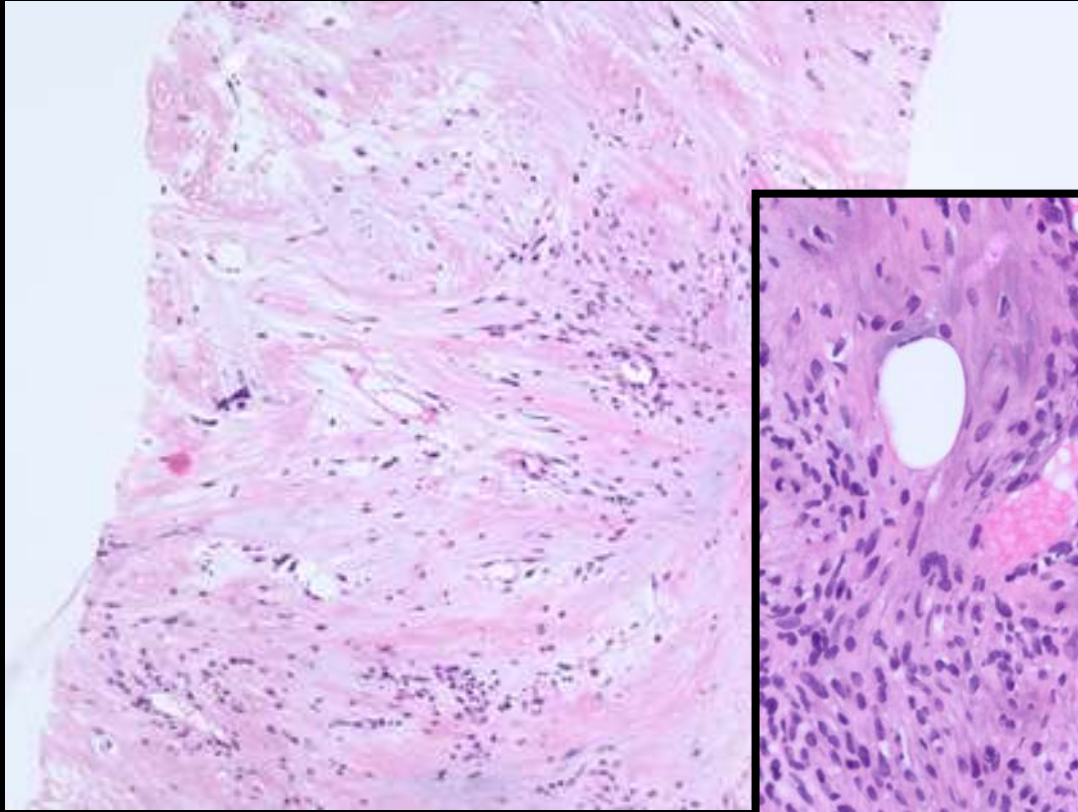
21-1205

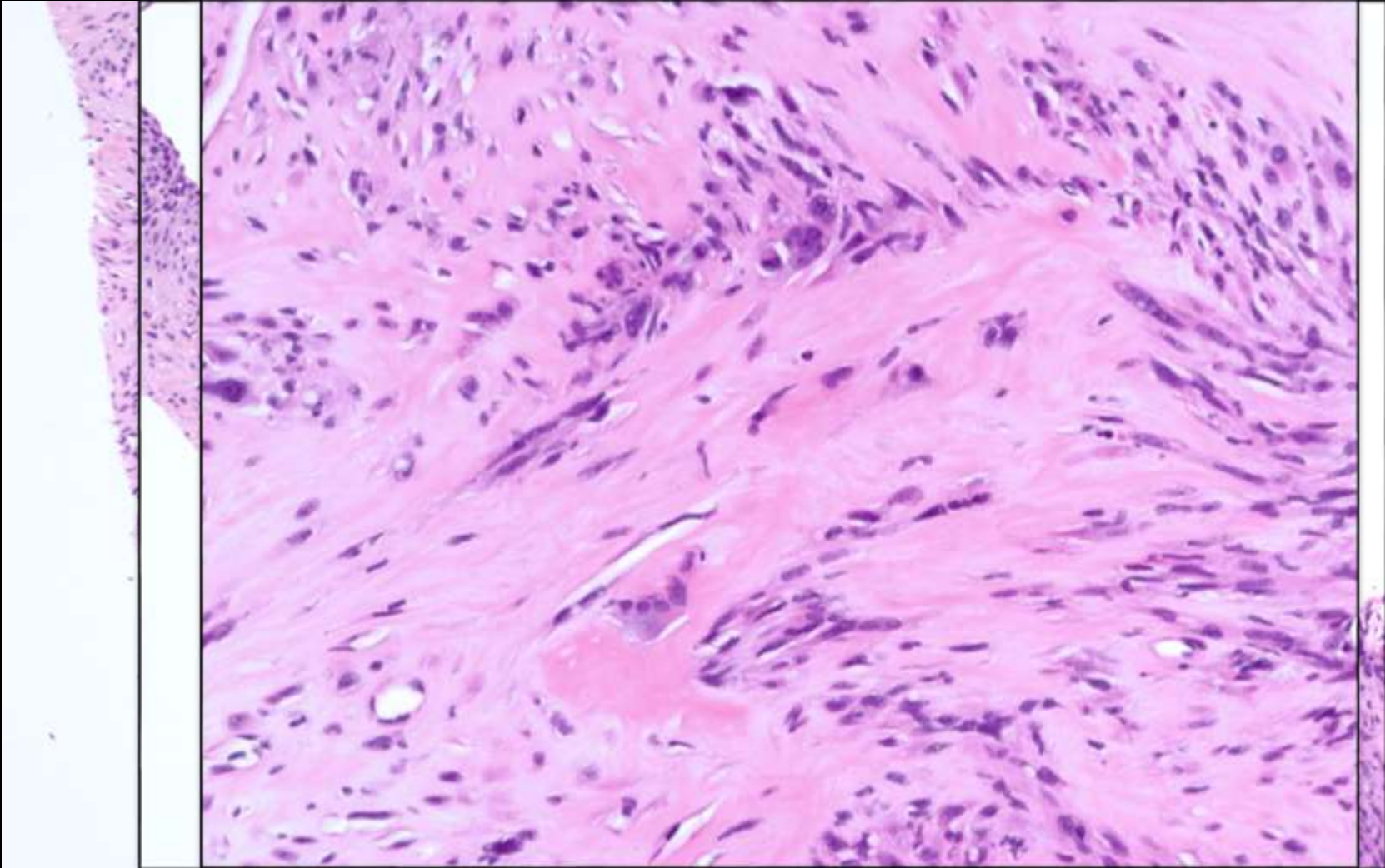
Bonnie Balzer; Cedars-Sinai Medical Center

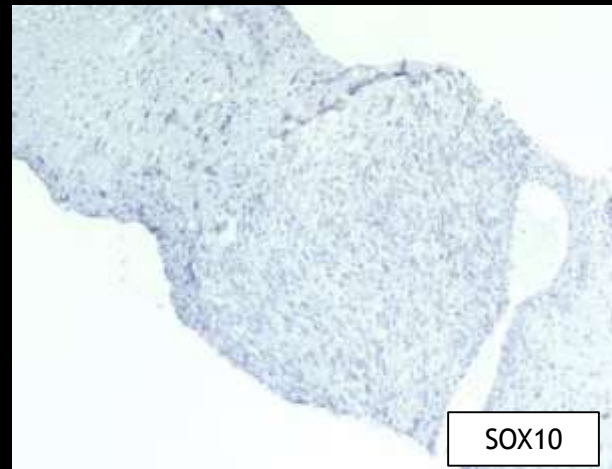
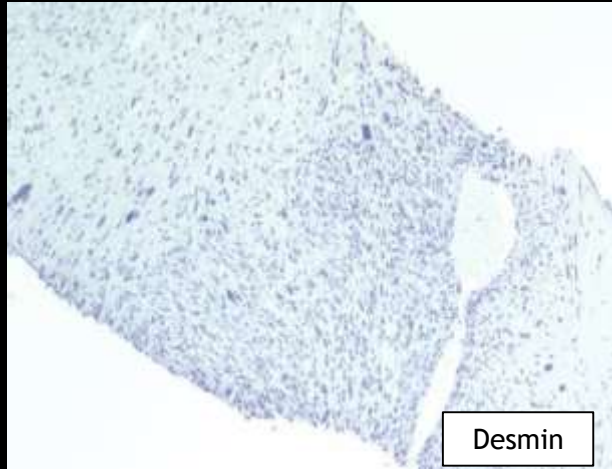
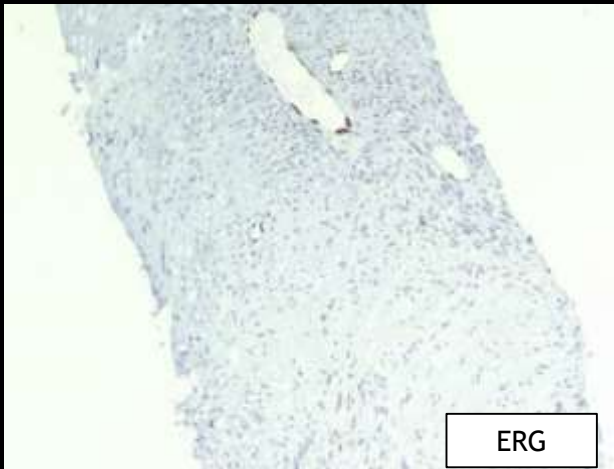
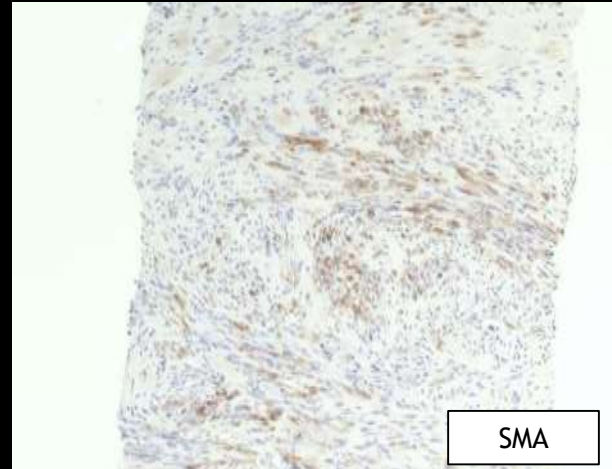
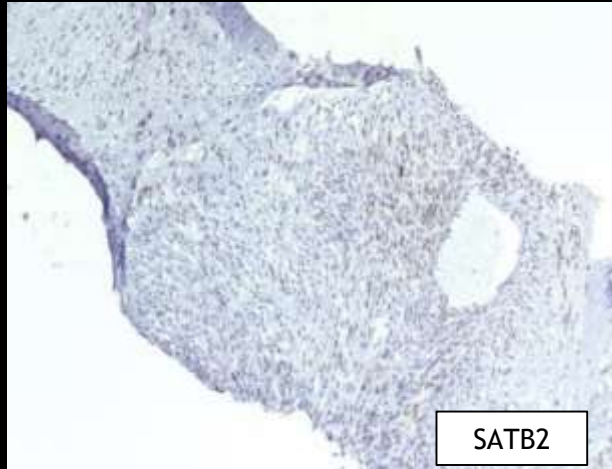
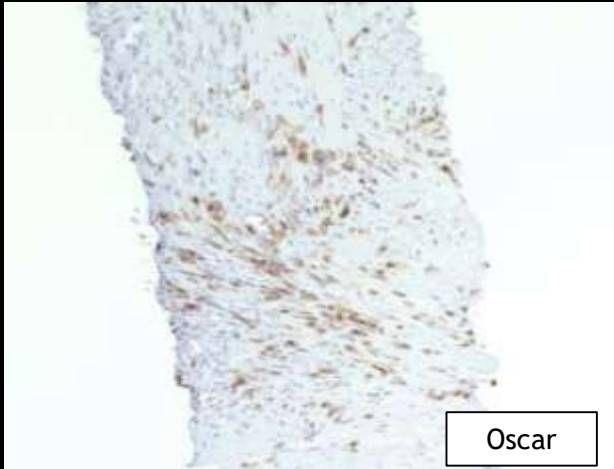
60-year-old F with no past medical history presents with right distal femur pain x5 months. Recent swelling and progressive pain leading to ambulatory difficulties.











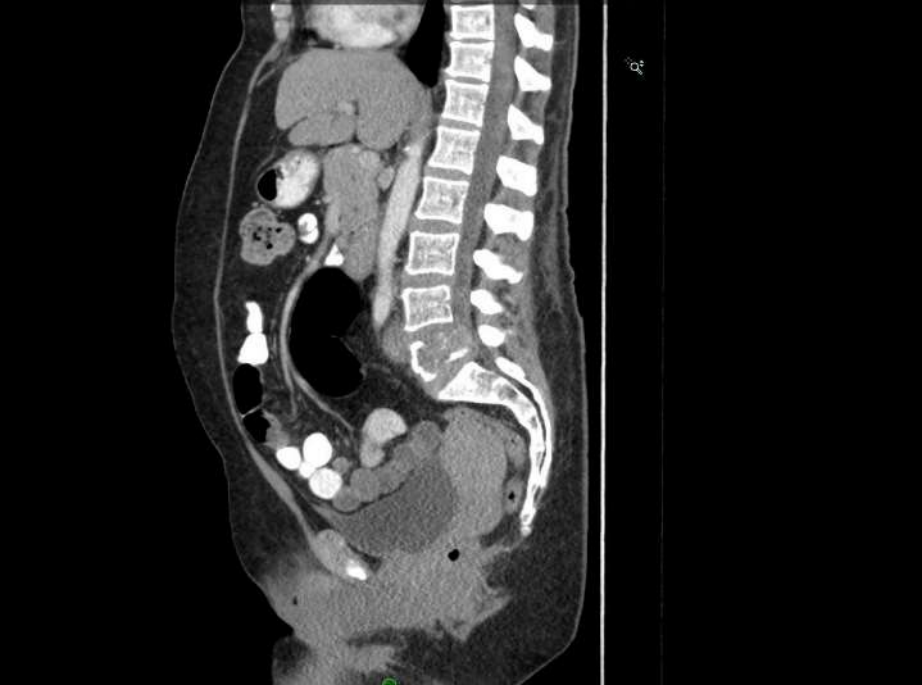
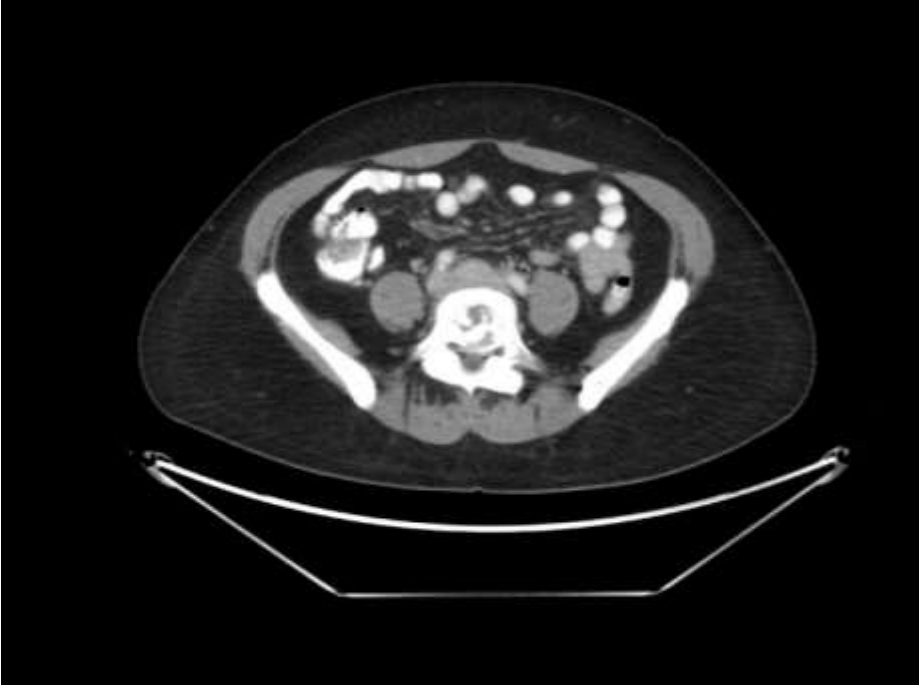
21-1206

Bonnie Balzer; Cedars-Sinai Medical Center

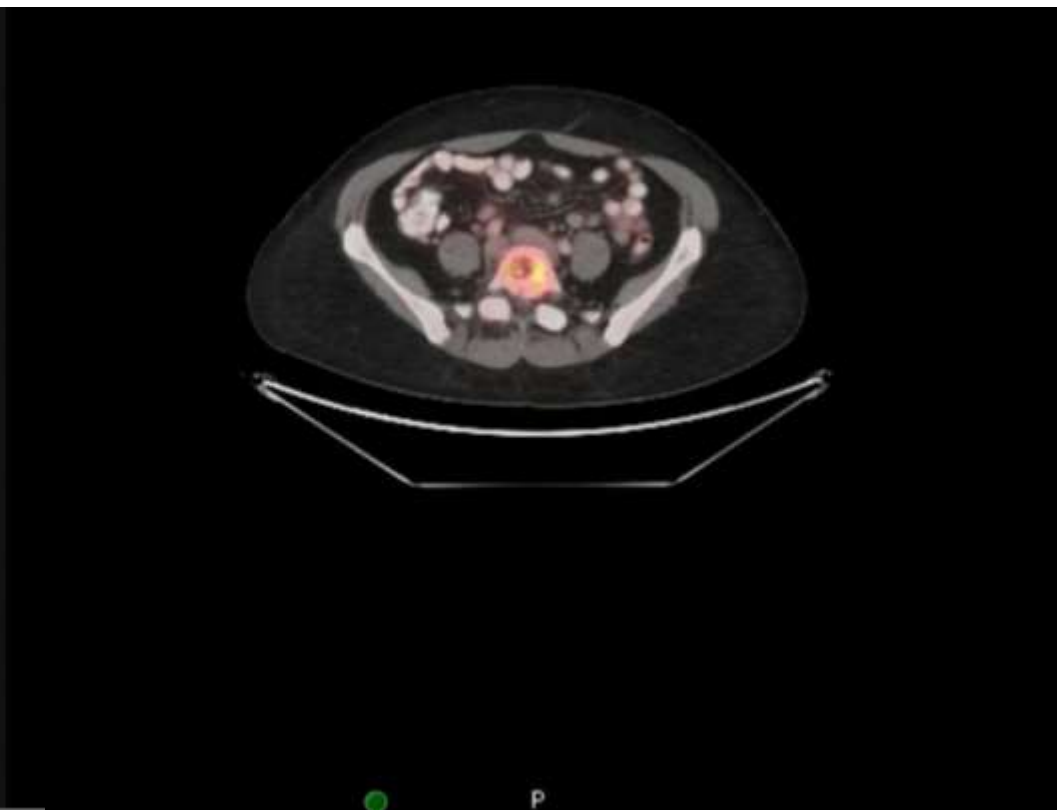
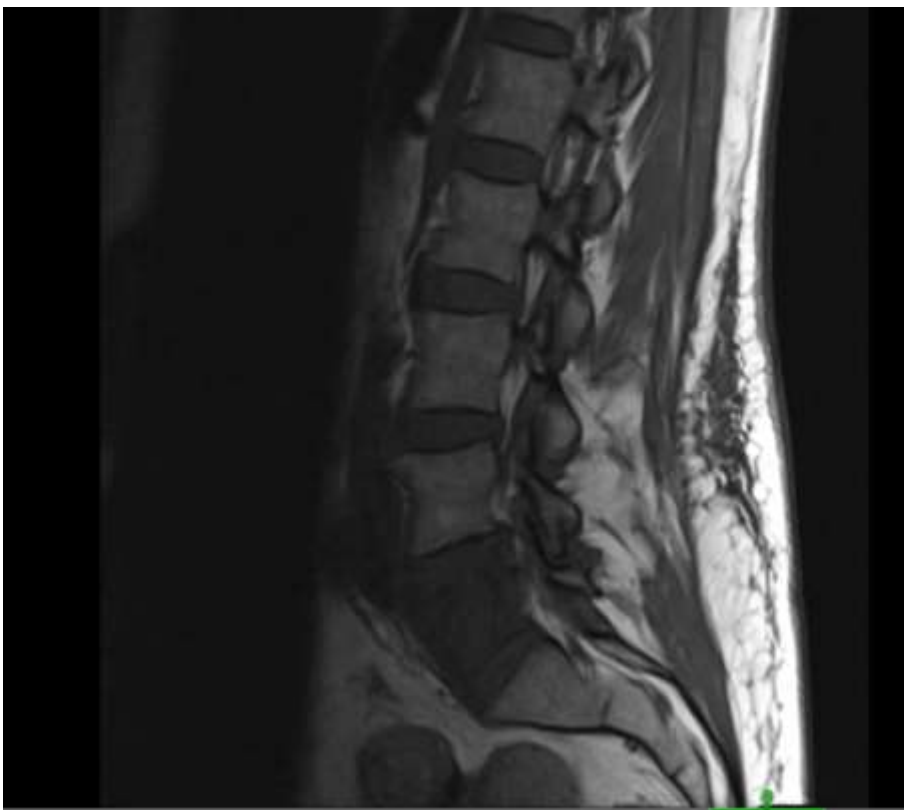
62-year-old F with lower back pain. Imaging showed L5 mass. Past medical hx: complex endometrial hyperplasia s/p curettage, 8.2mm RUL ground glass nodule, and stable 7mm liver lesion. Multiple core biopsies performed were non-diagnostic (rare keratin-positive cells, suspicious for carcinoma). Clinical course complicated by cord compression, and patient underwent emergency corpectomy.

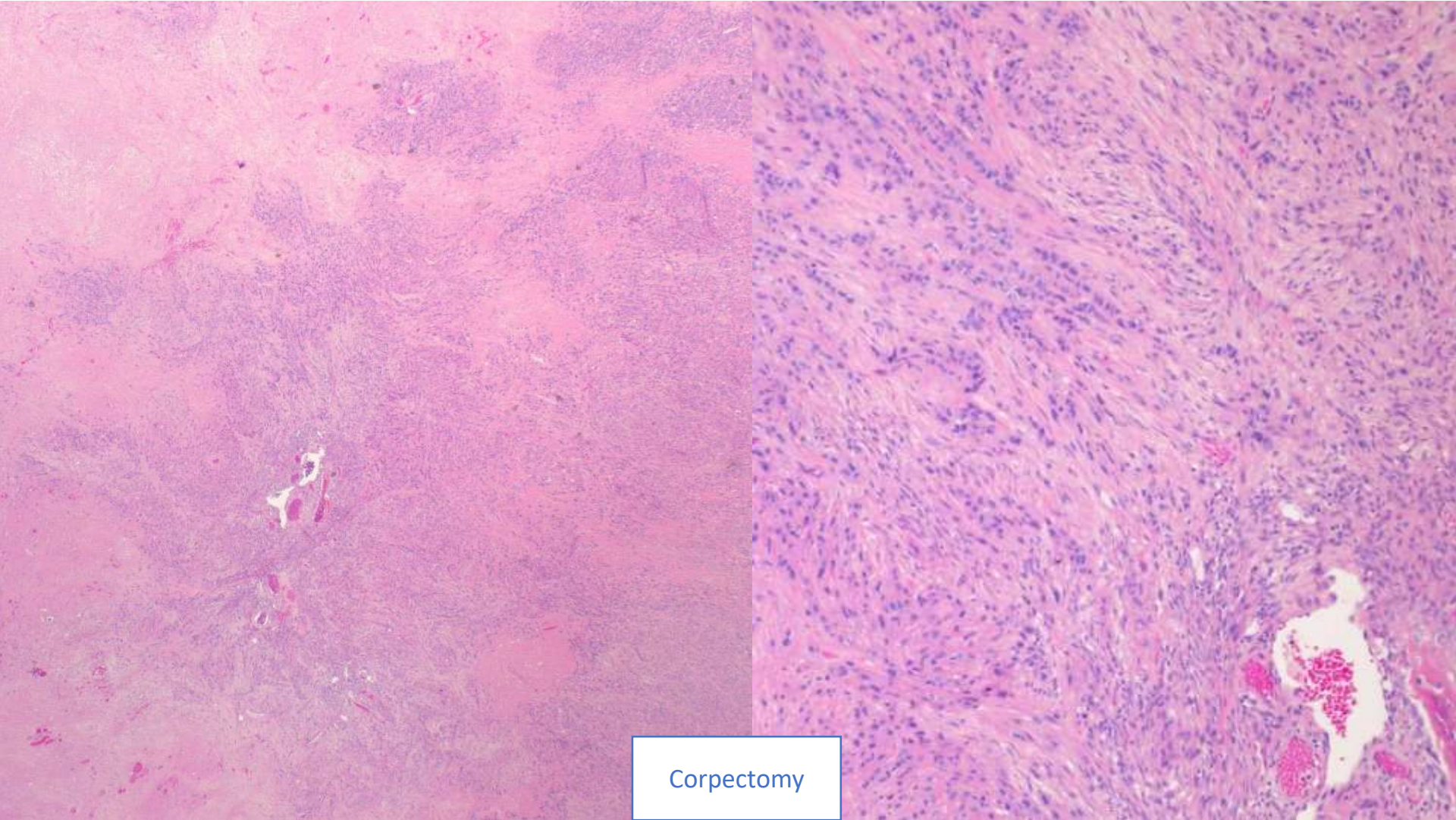
CT



MRI

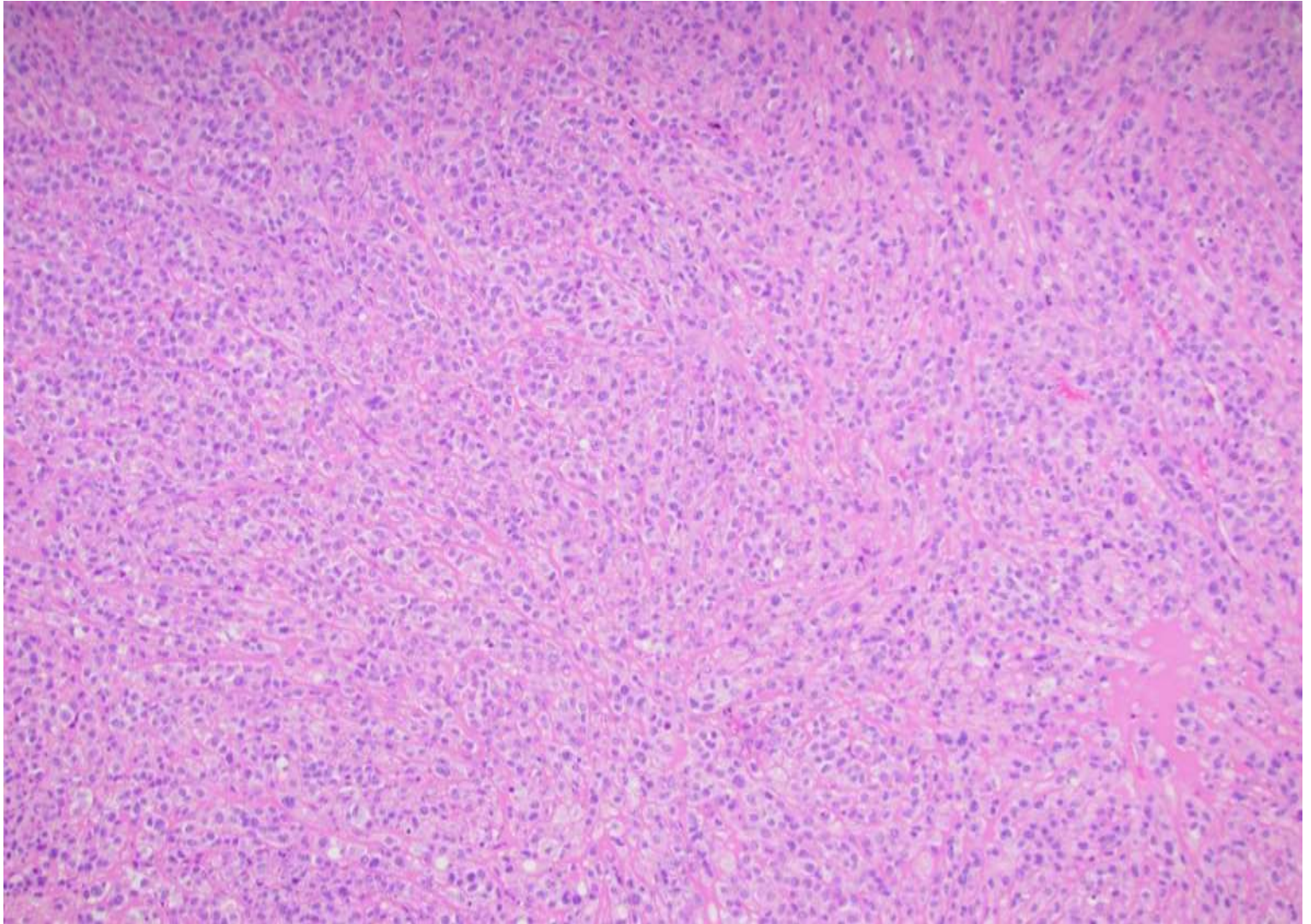
PET

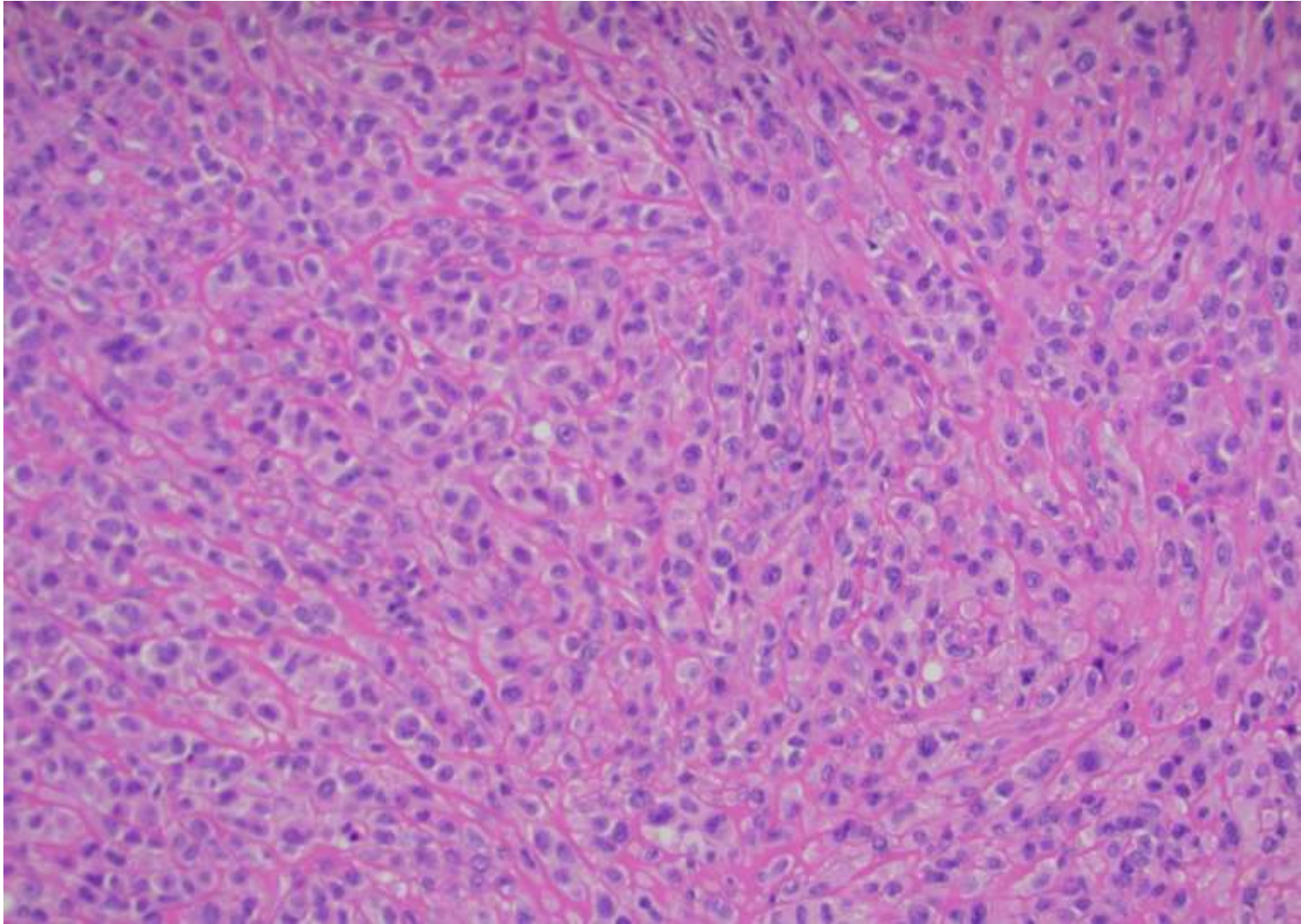


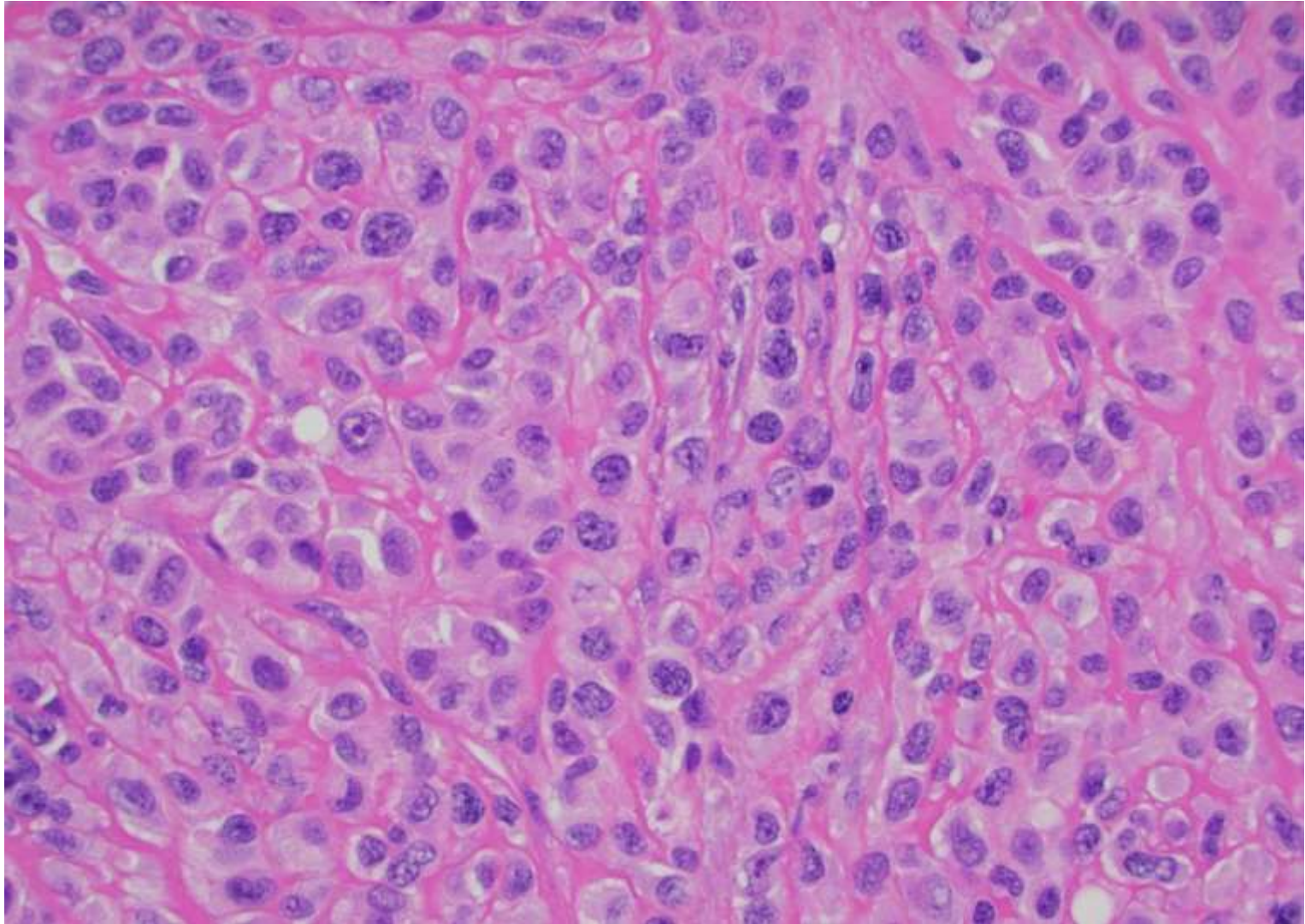


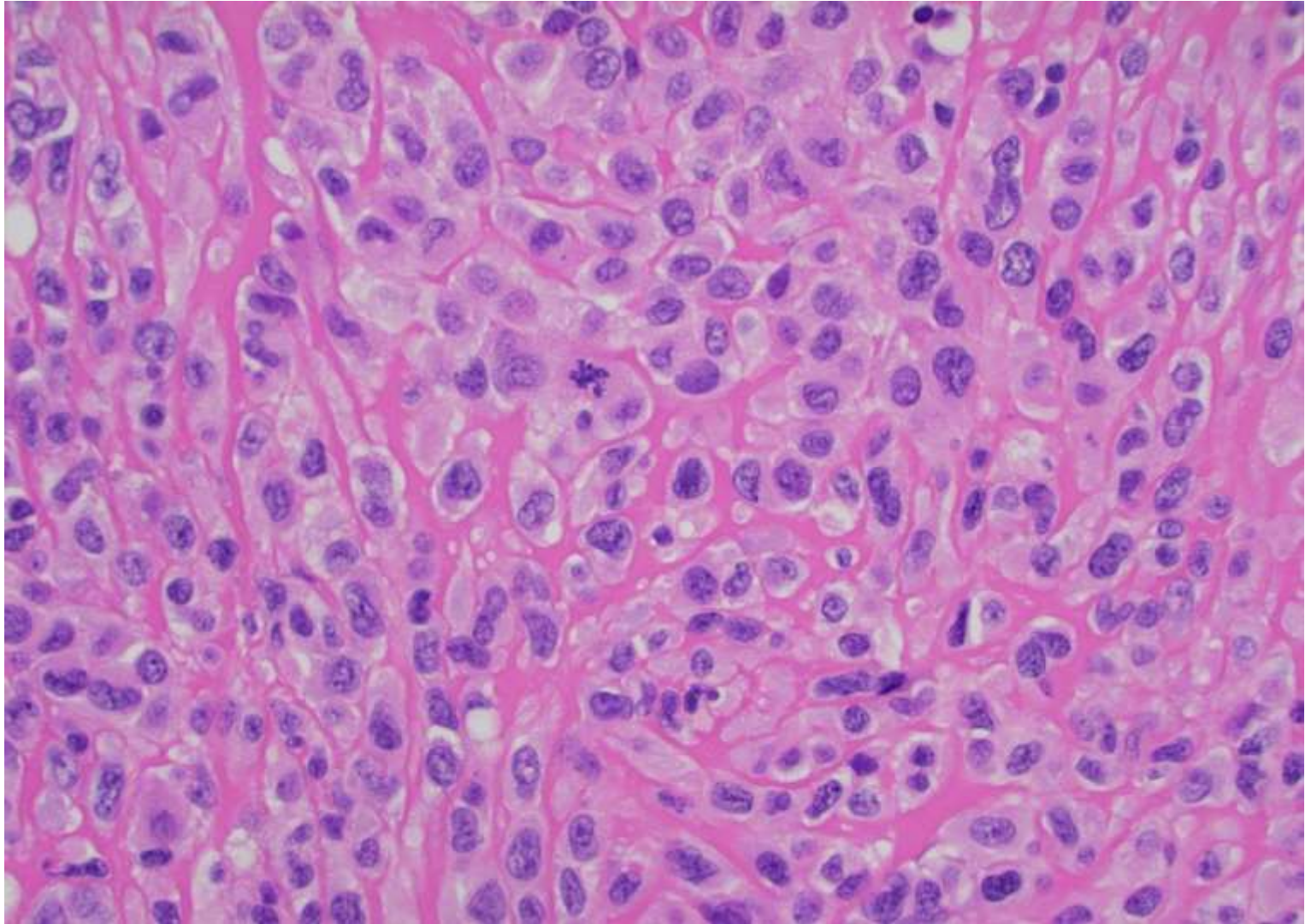
Corpectomy

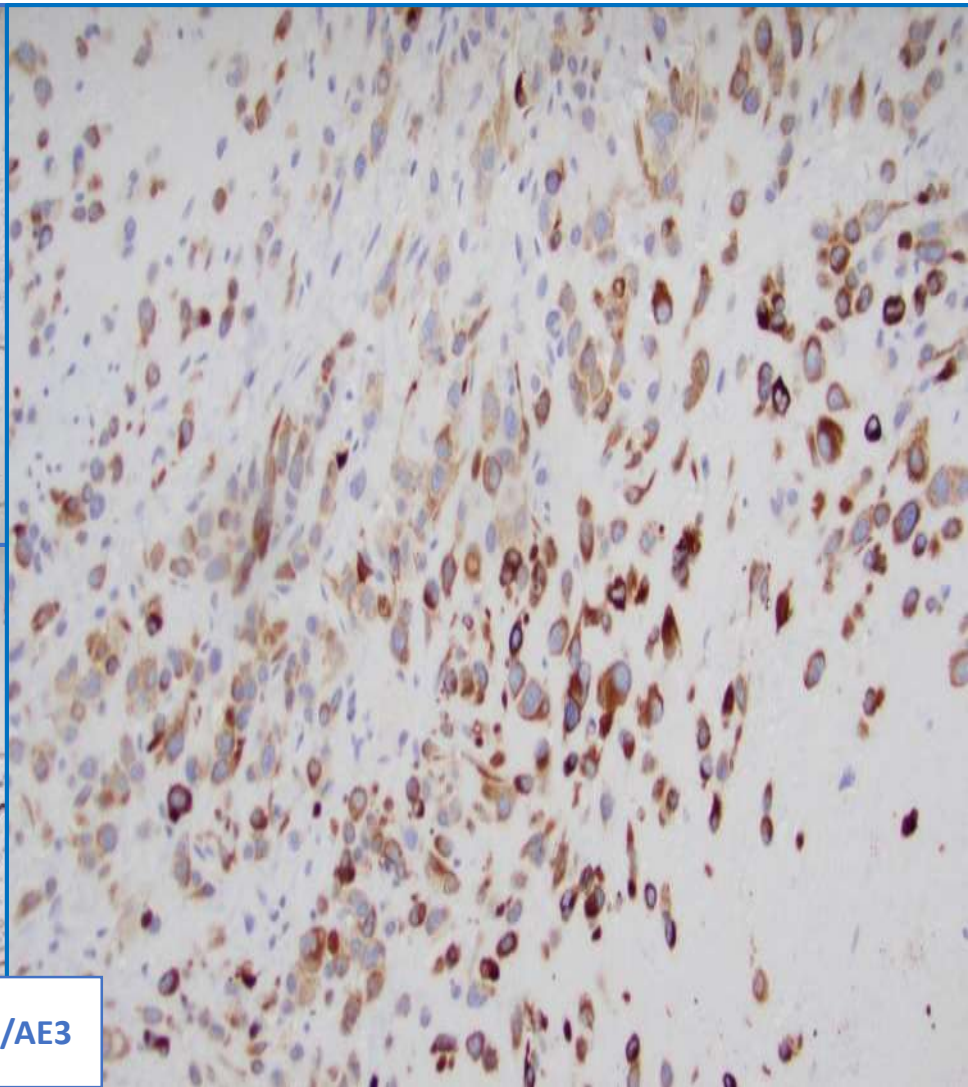
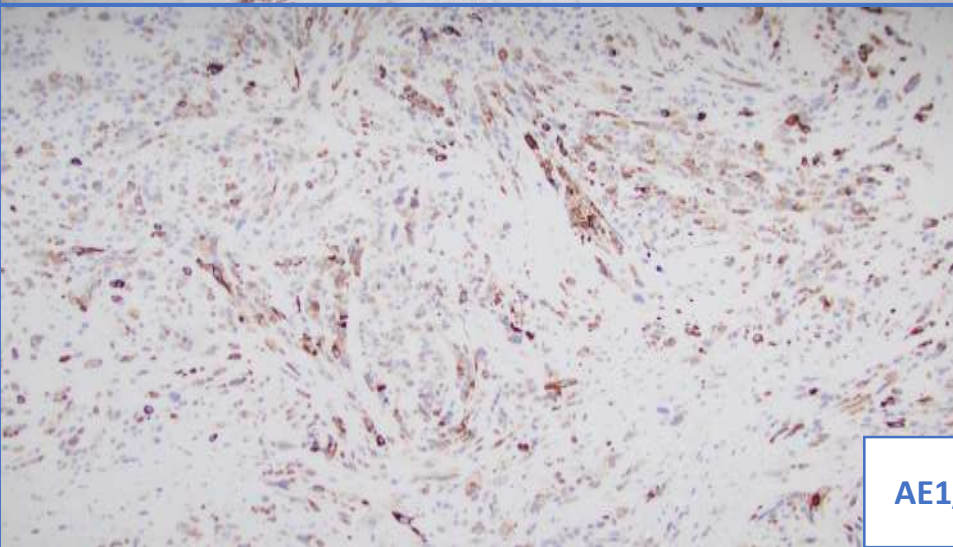
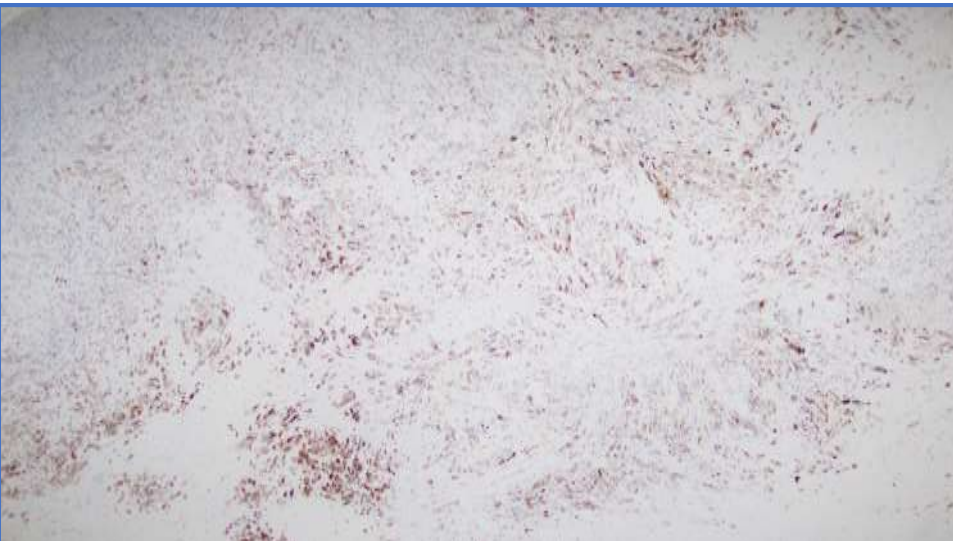
Corpectomy











AE1/AE3

Ancillary studies

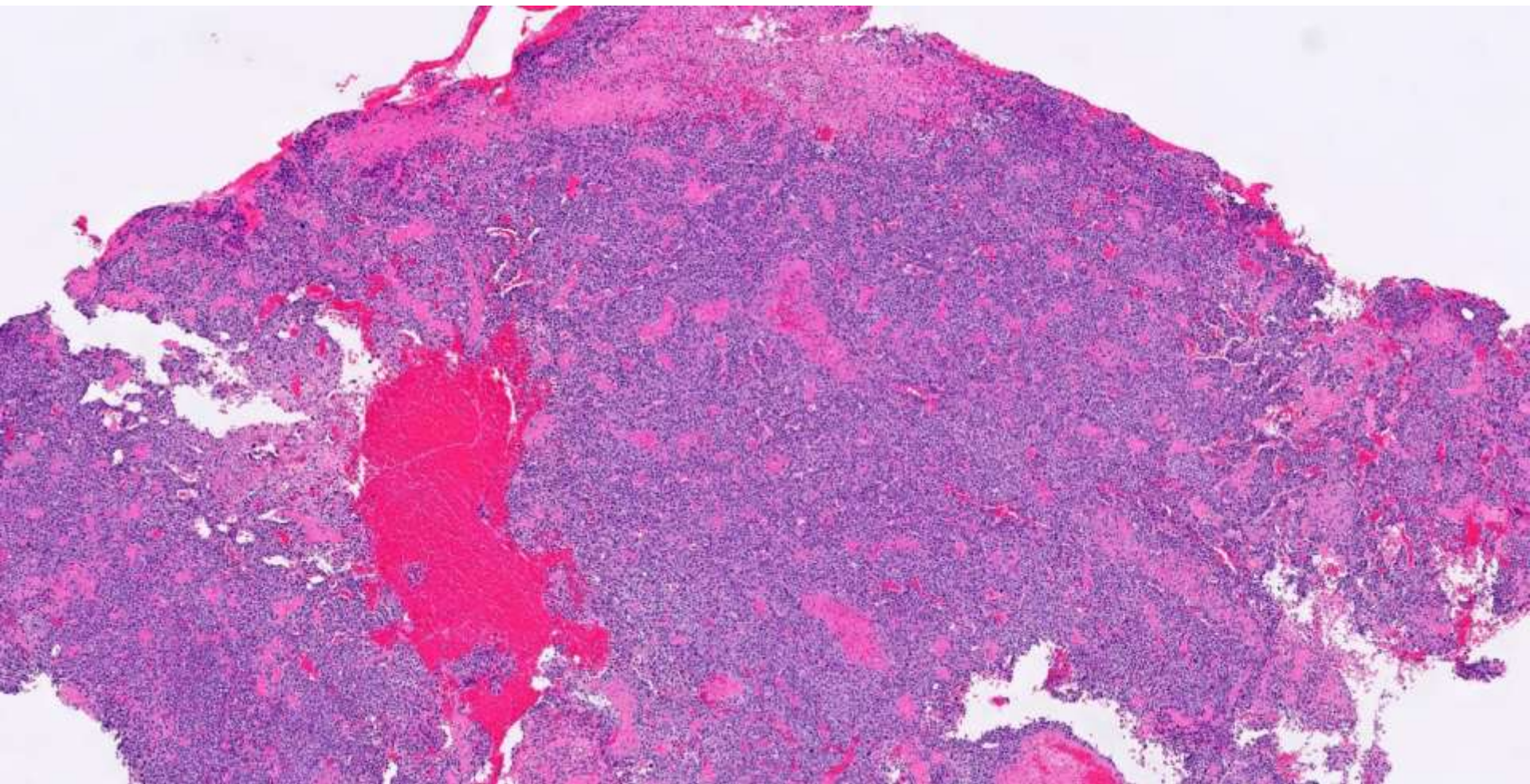
- Keratins: Multiple keratin mixes positive
 - CK7, CK20: Negative
- MDM2: Overexpressed
- Melanocytic markers (HMB45, Melan-A, SOX10, S100, BRAF): Negative
- Lineage markers (vascular, desmin, myogenin, actin): Negative
- Organ selective markers (PAX8, TTF, GATA3, SATB2, CDX2, etc.) Negative
- Fluorescence in situ hybridization:
 - Negative for MDM2 amplification
 - Negative for SYT rearrangement
 - Positive for EWSR1 rearrangement
- Next generation sequencing for partner: EWSR1-TFCP2 fusion detected

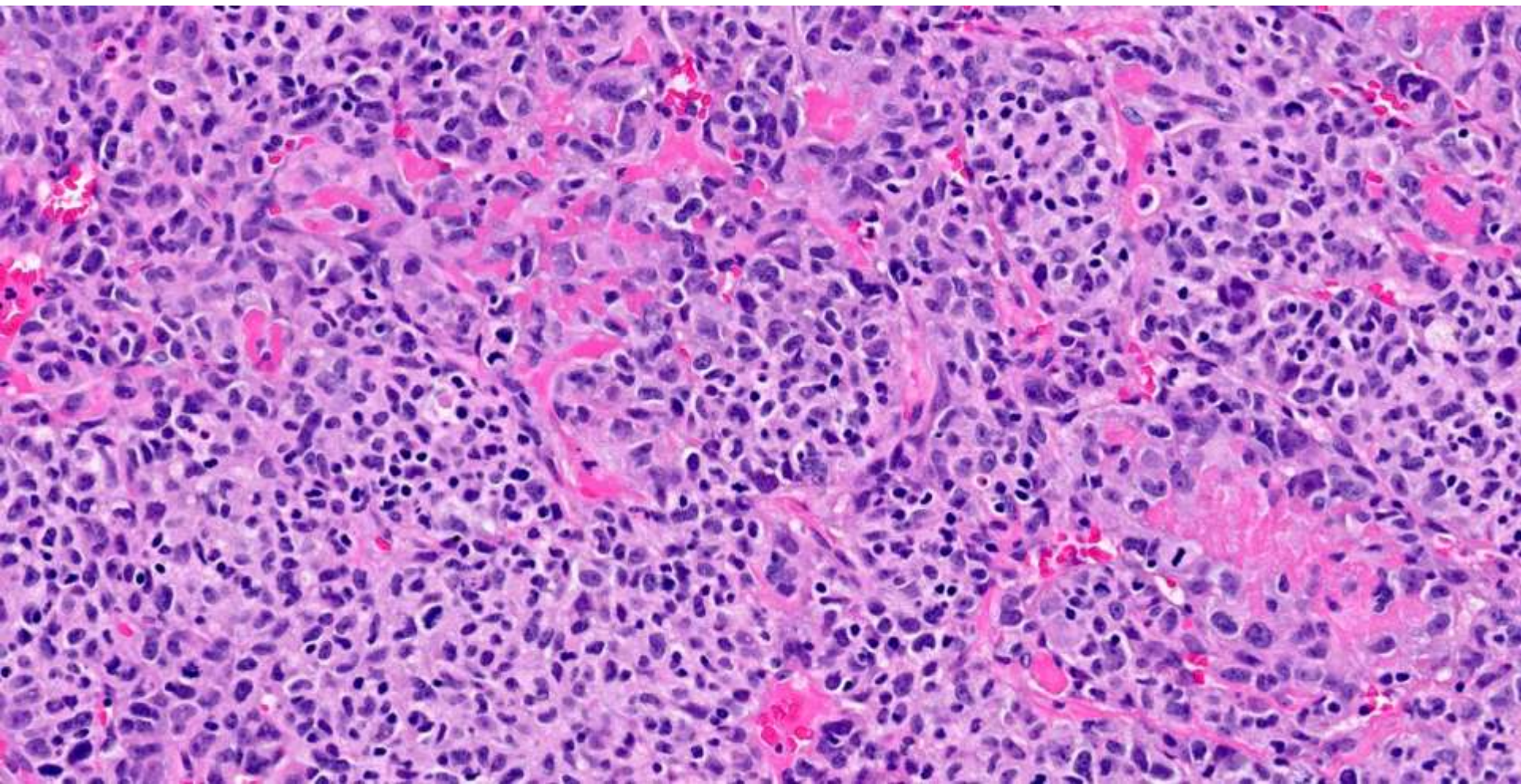


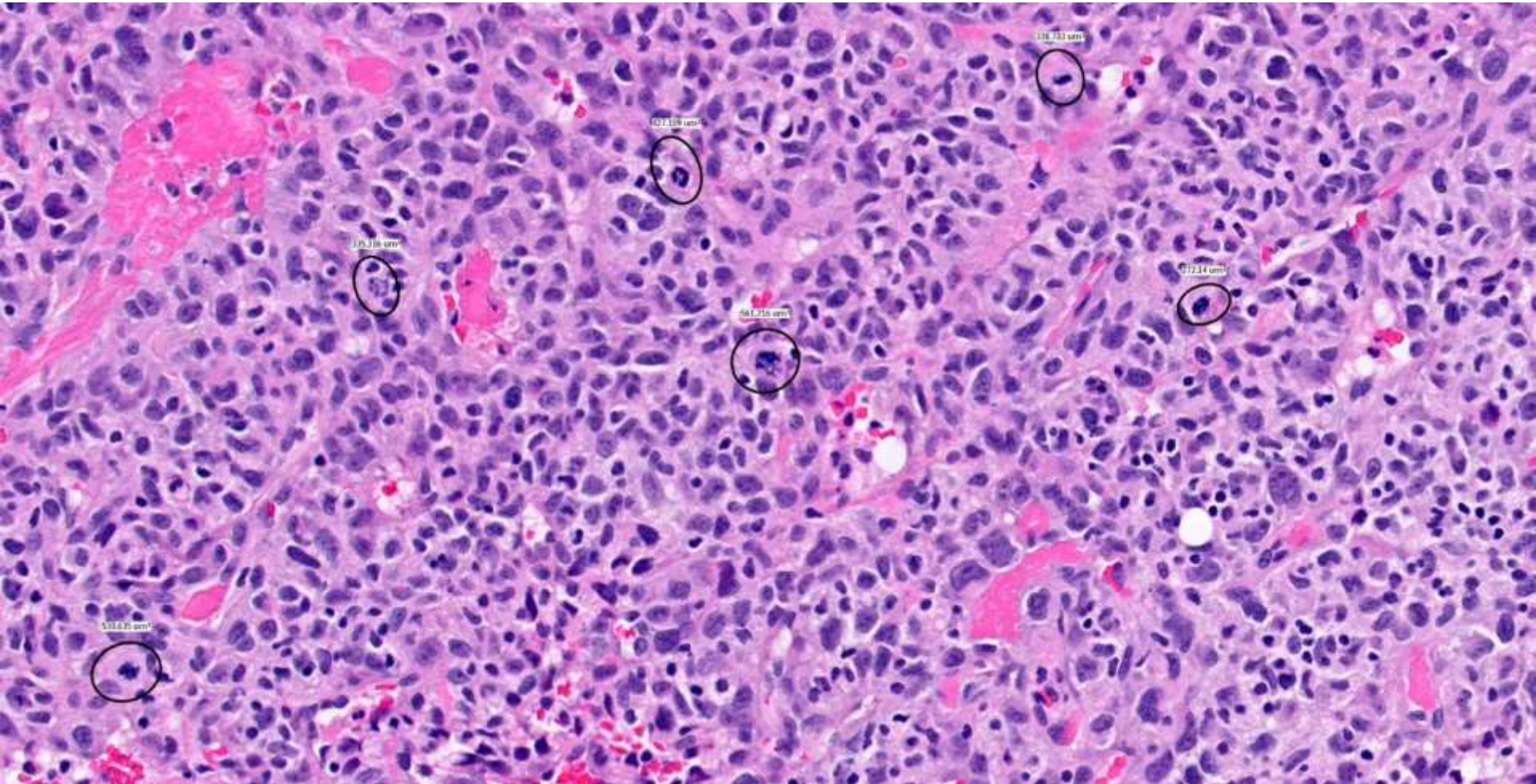
21-1207

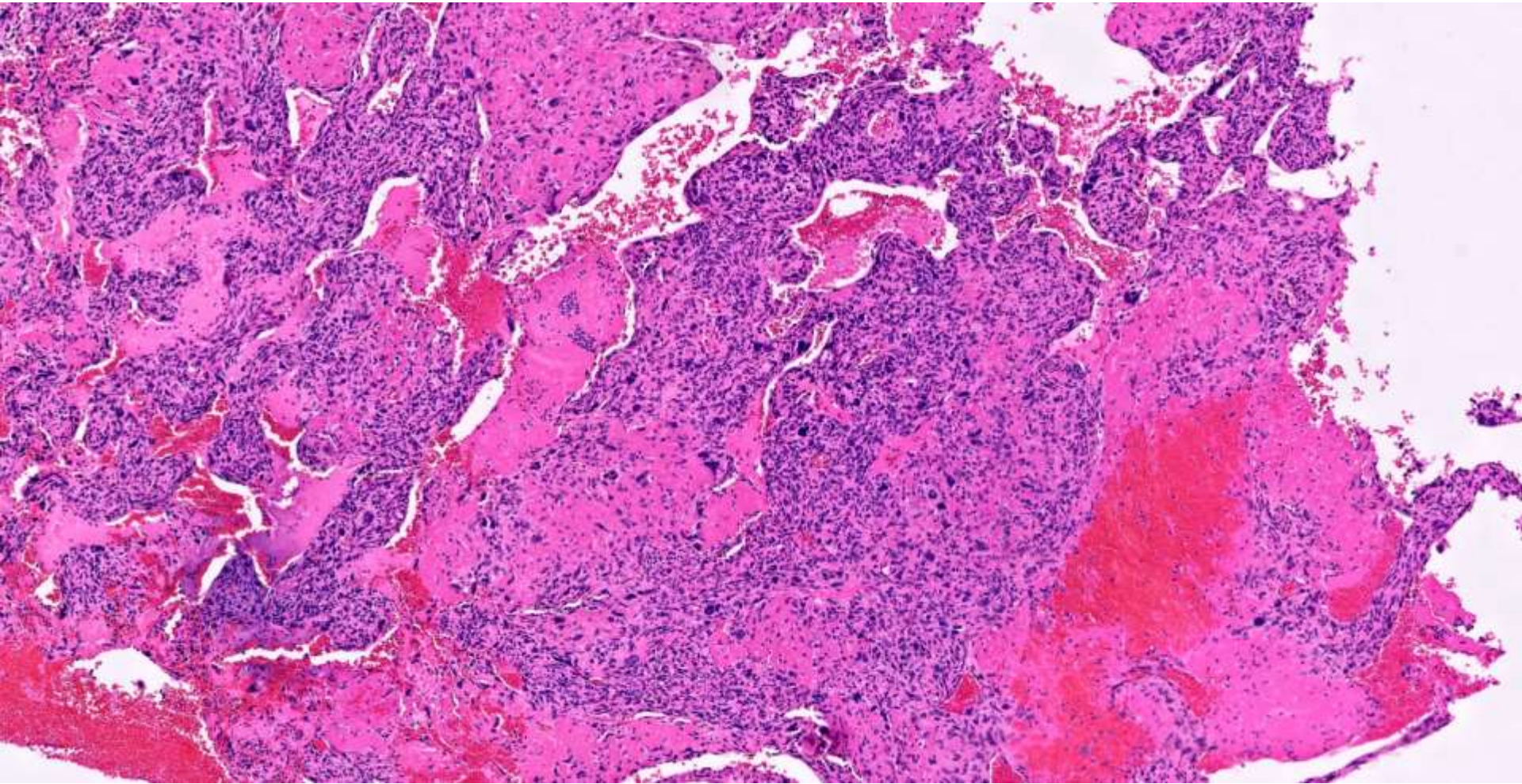
Kanish Mirchia/Elizabeth Treynor; UCSF/Washington Hospital

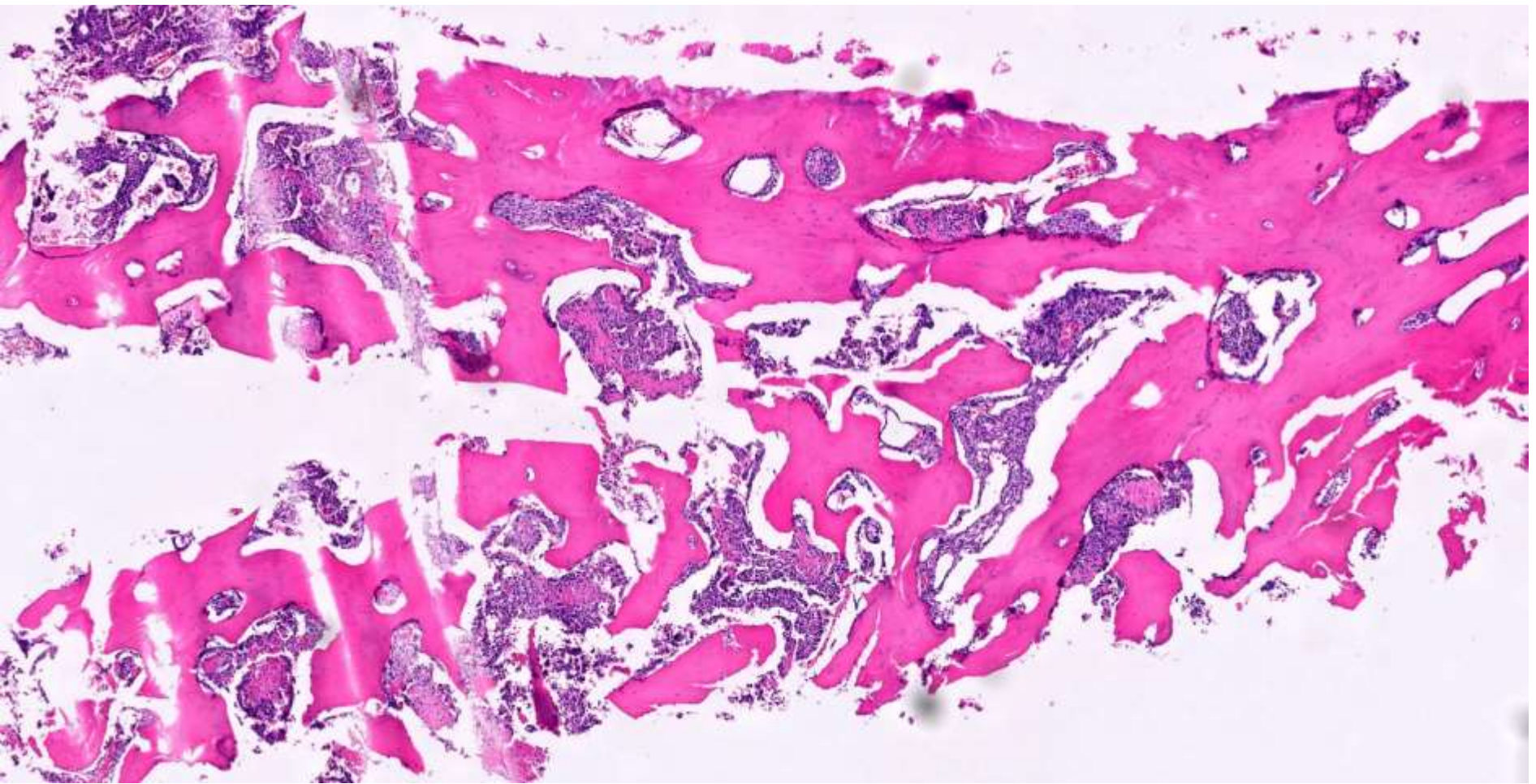
46-year-old F in usual state of health, with 1 month recurrent mid back pain and subsequent urinary incontinence and paraparesis. Imaging showed T8 extramedullary mass with cord compression.











IHC ?

