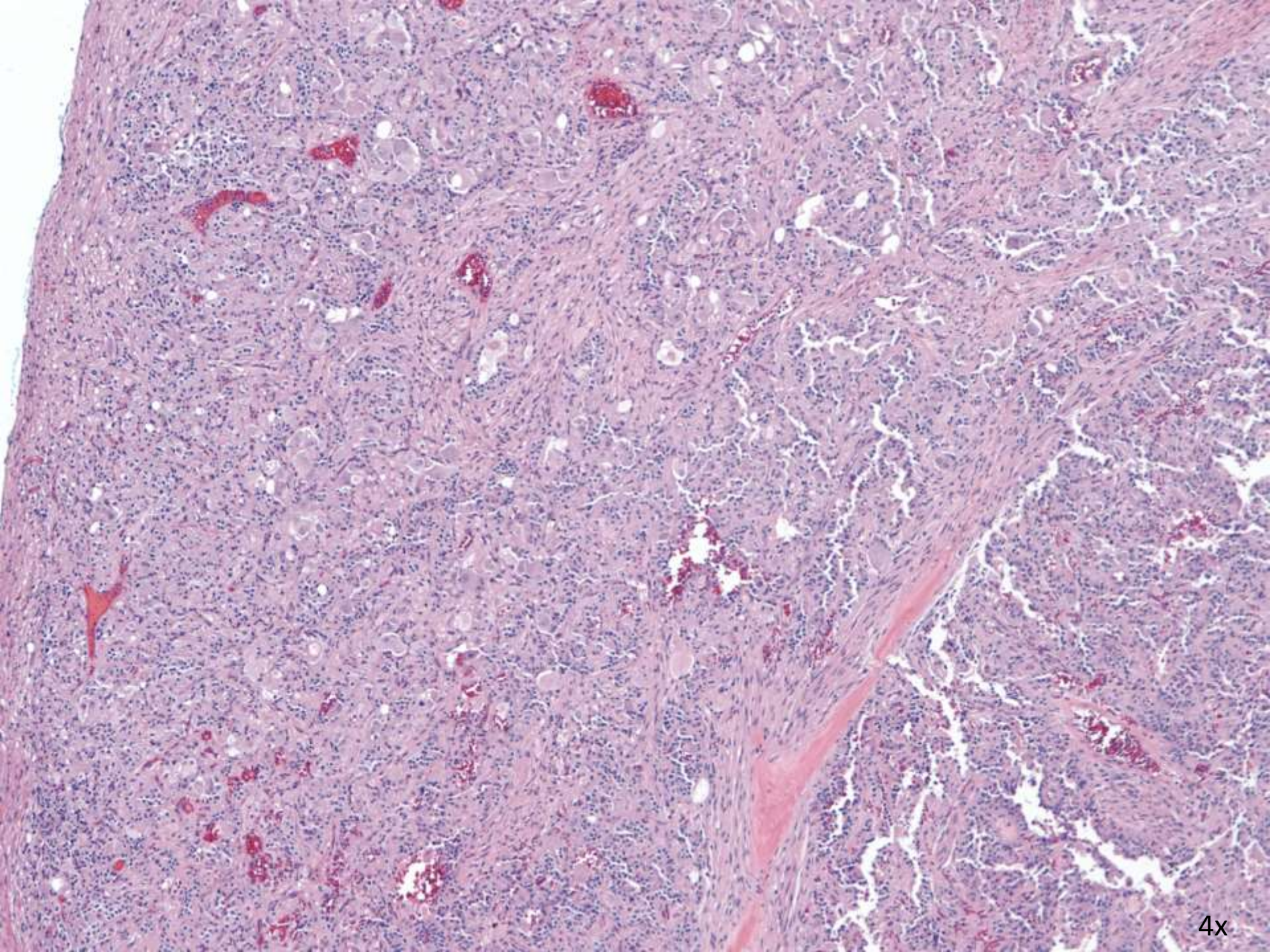


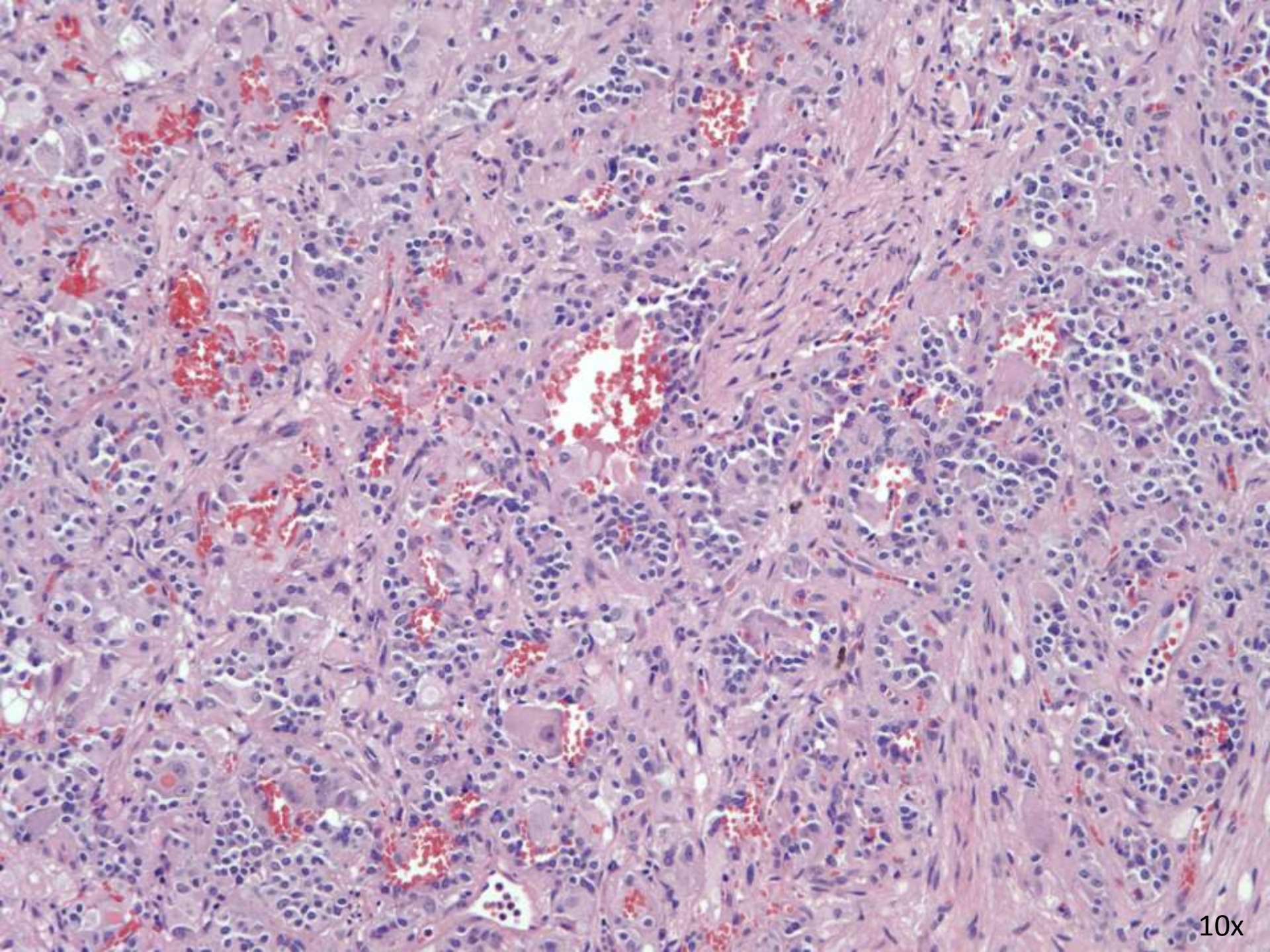
SB 6191

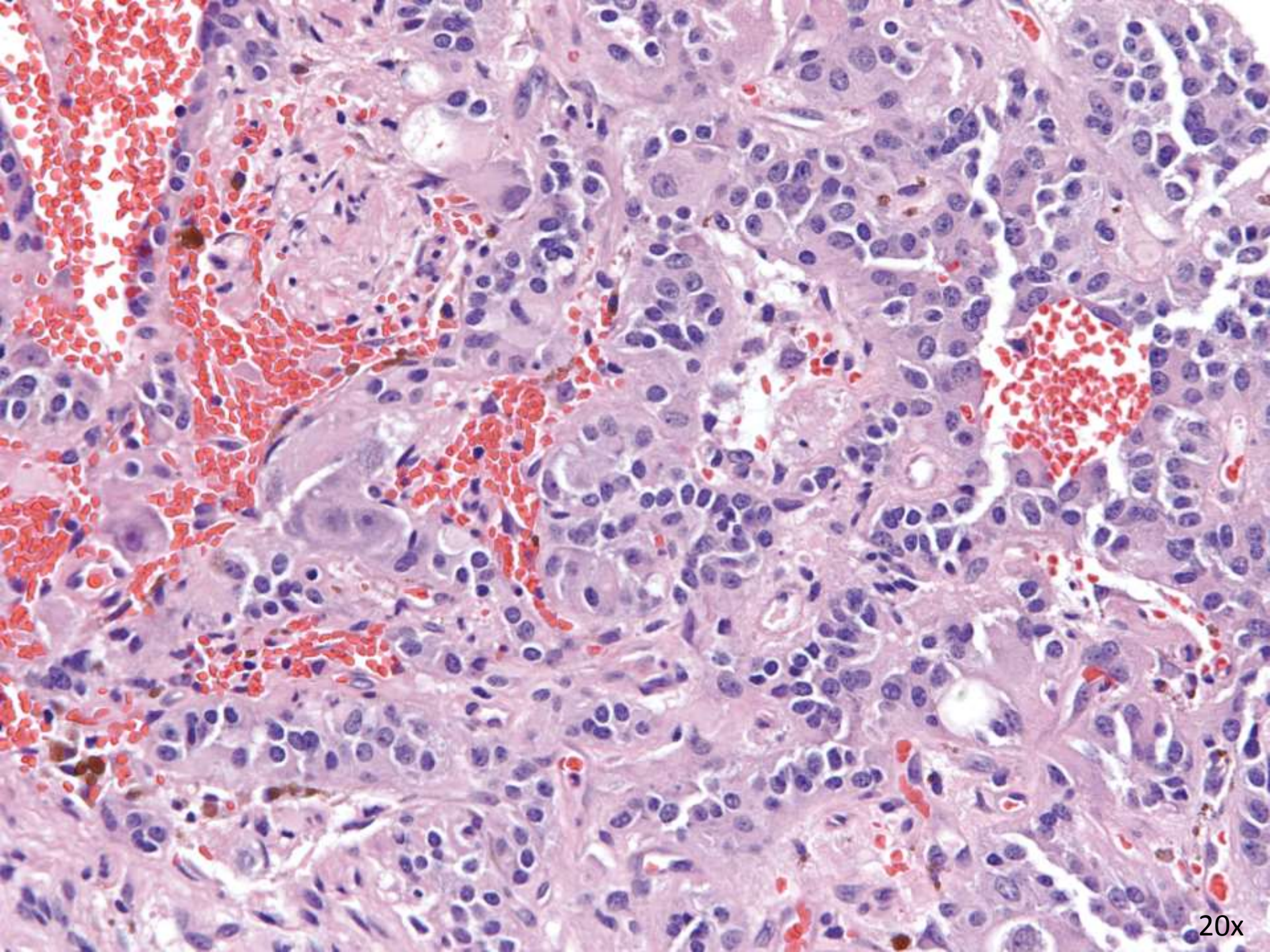
Seth Lummus/Hannes Vogel;

Stanford

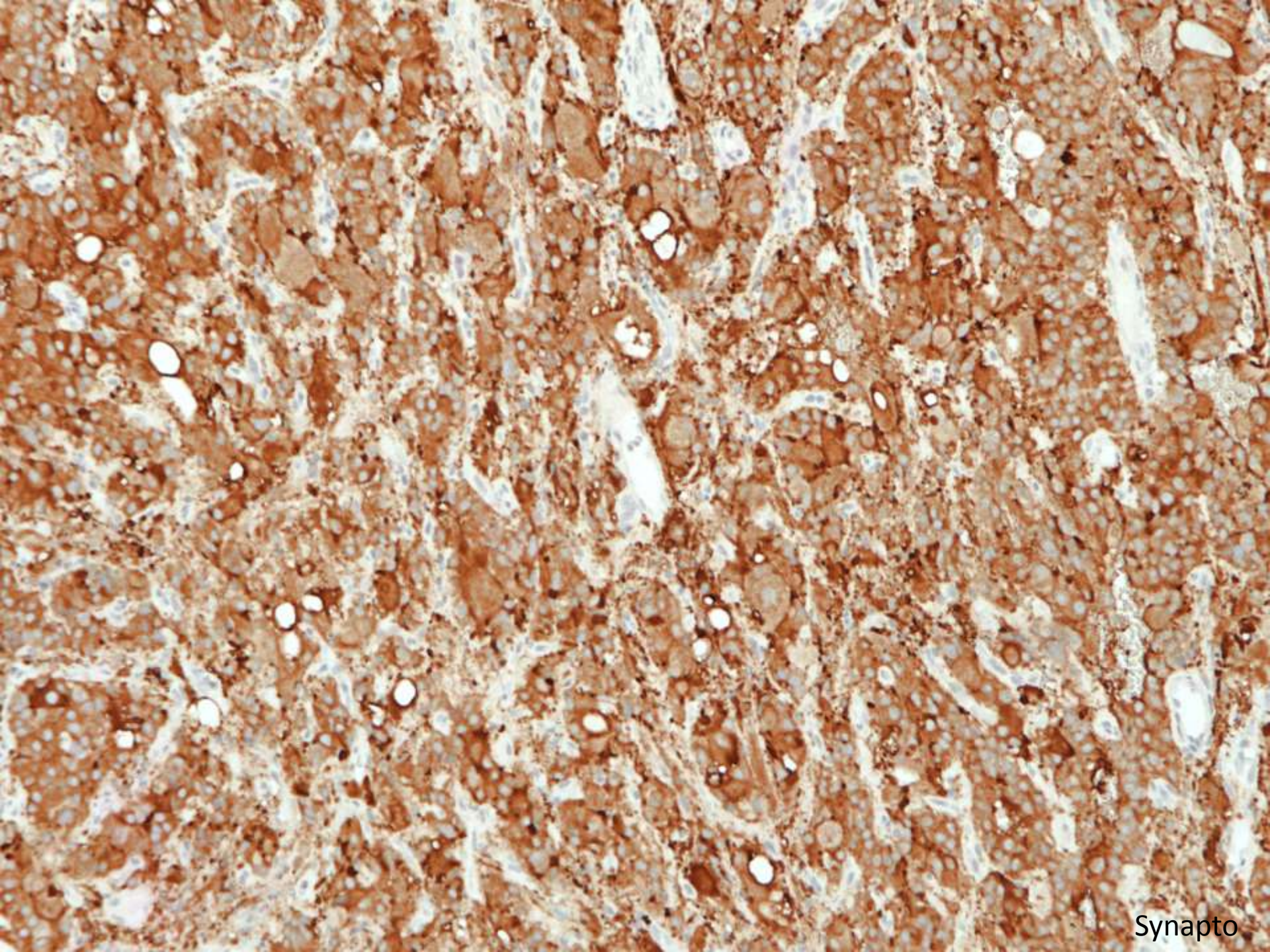
62-year-old male who presents with a 2 year history of significant neuropathy in both feet bilaterally. He describes this as numbness, tingling, and burning in both his feet. He has been taking gabapentin for this for the last 2 years, which he reports decreases the pain from approximately a 6/10 down to a 2/10. On occasion, once every few months, he has shooting pains in his upper thighs bilaterally. An MRI revealed an intradural lesion between L1-L2.



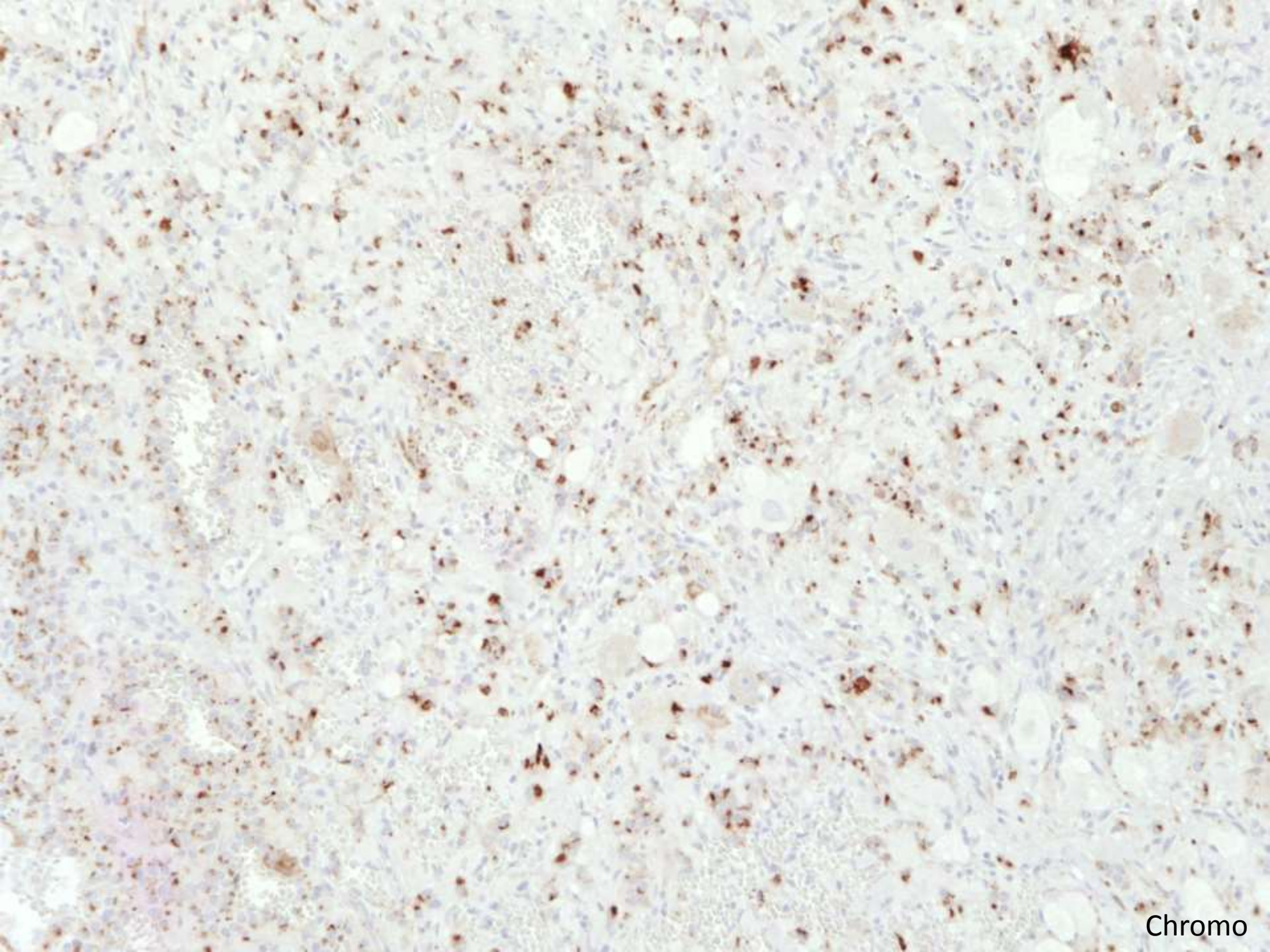




20x



Synapto

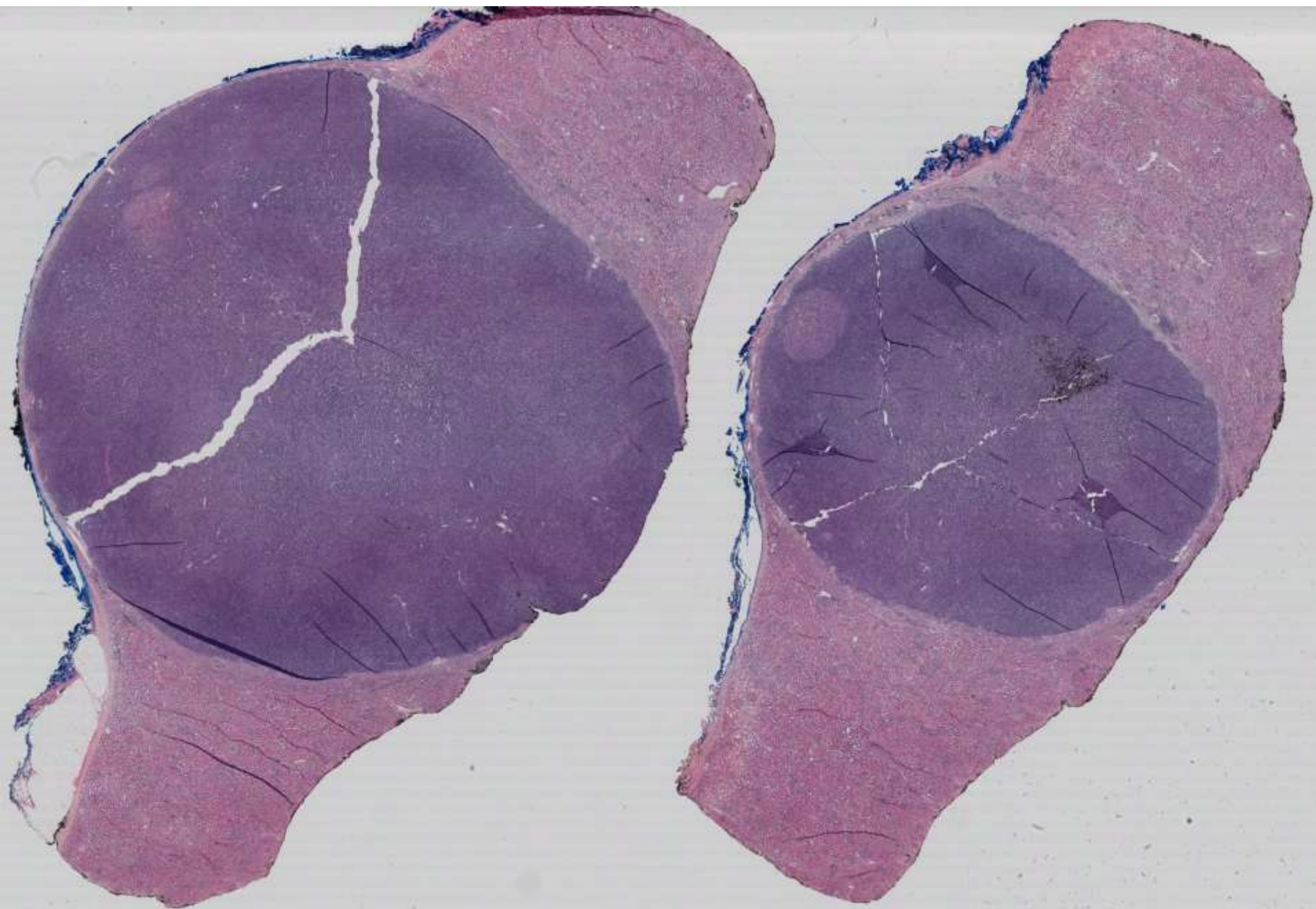


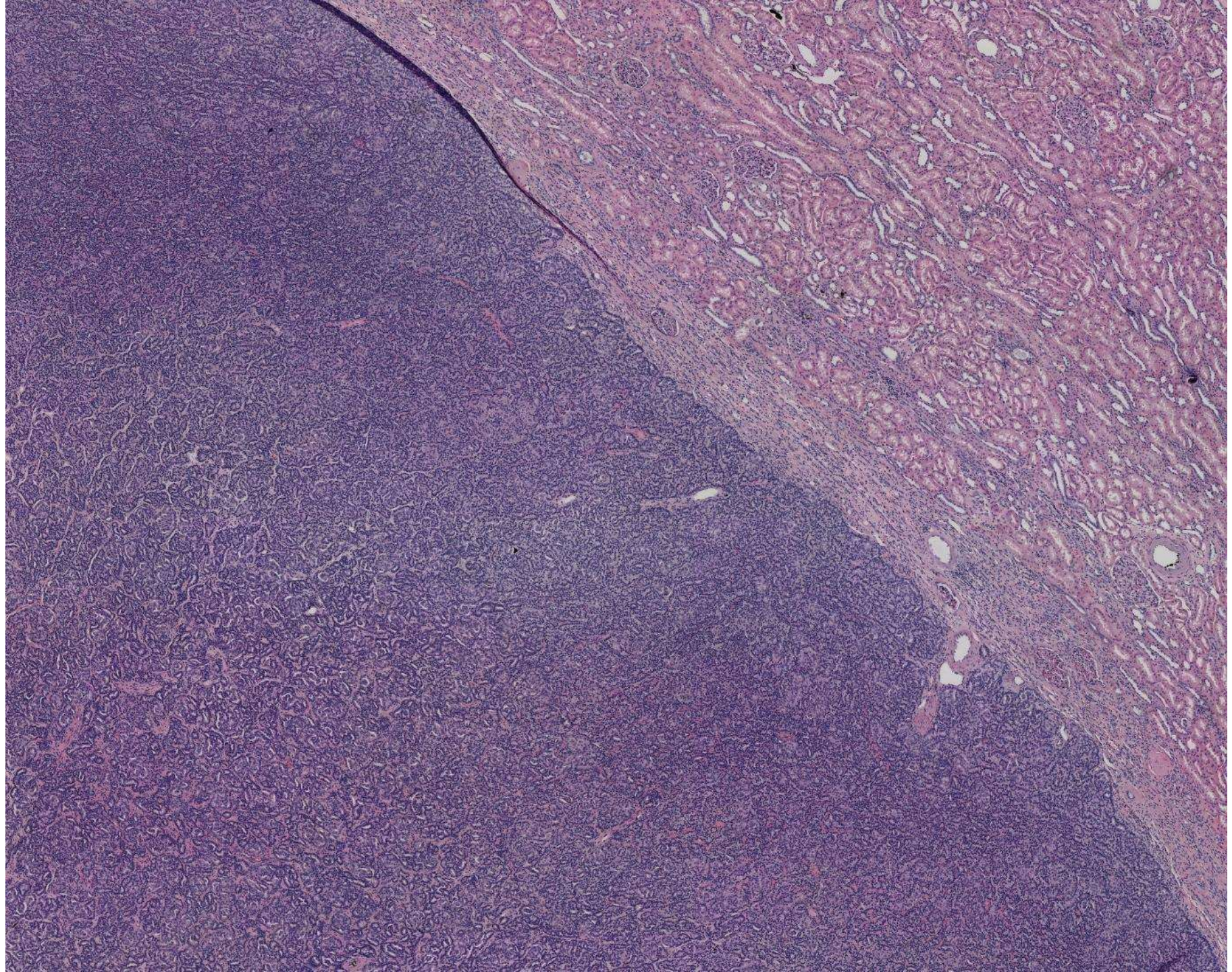
SB 6192 [scanned slide available]

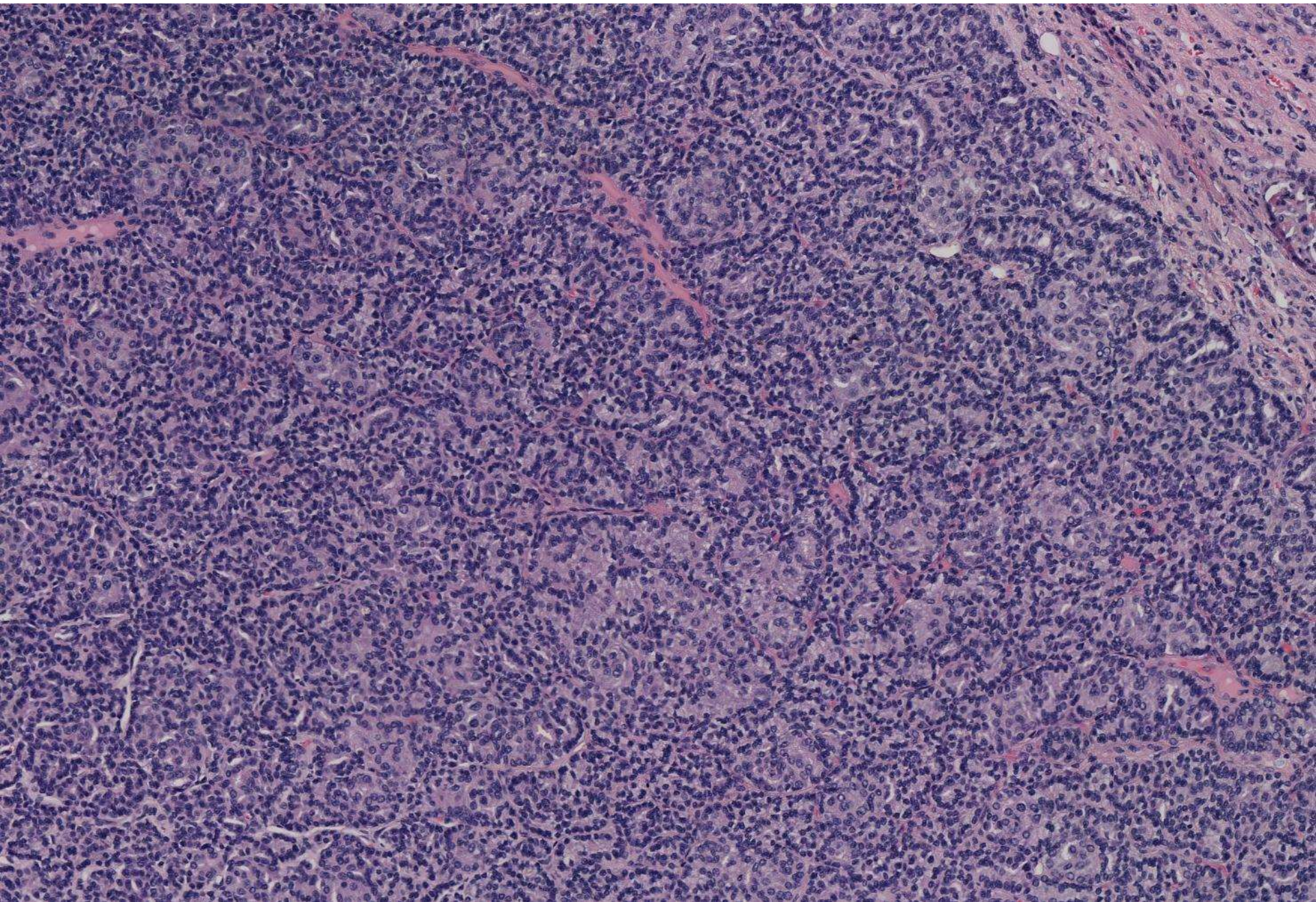
Dean Fong; Palo Alto VA

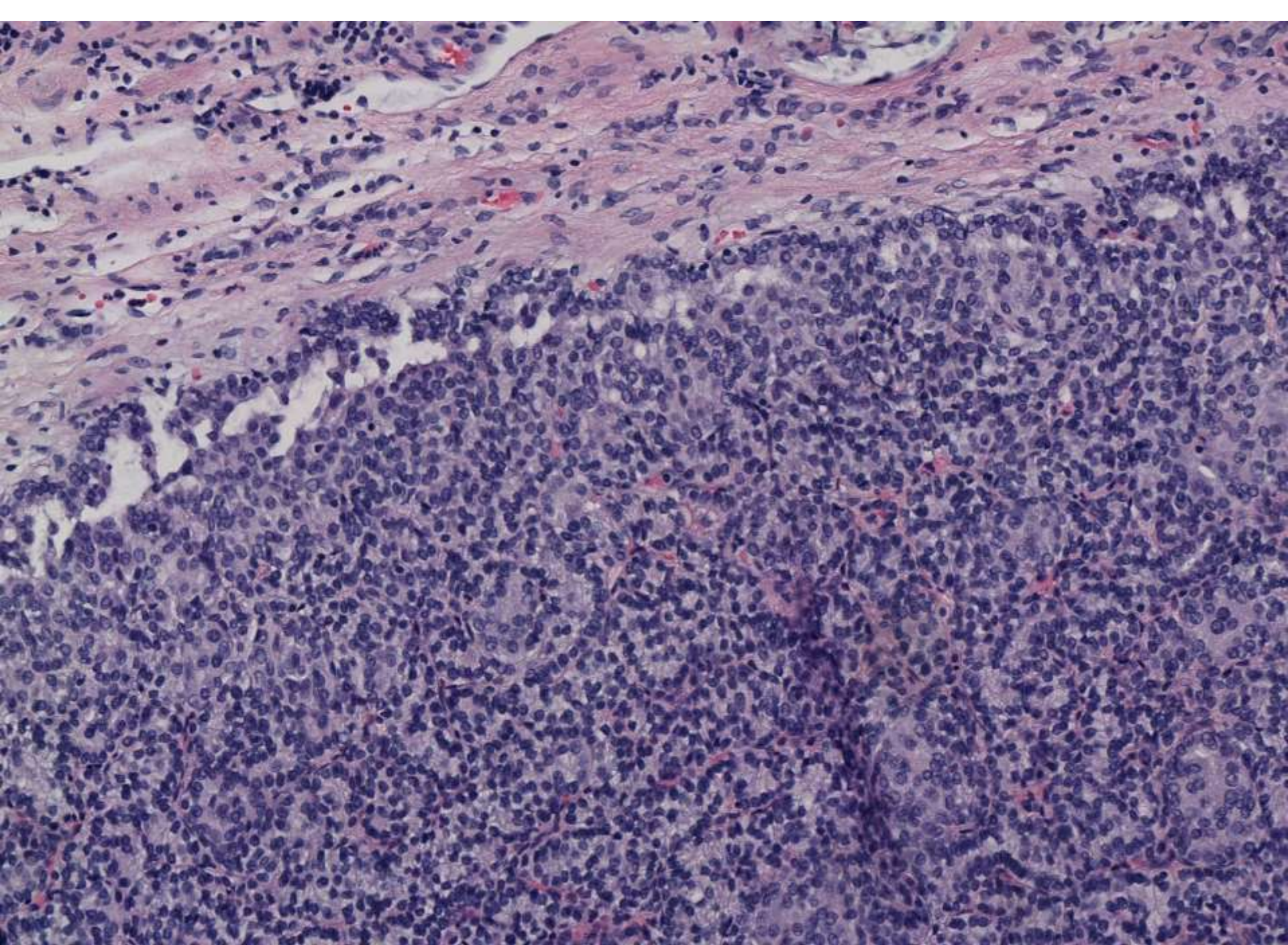
Right renal mass.

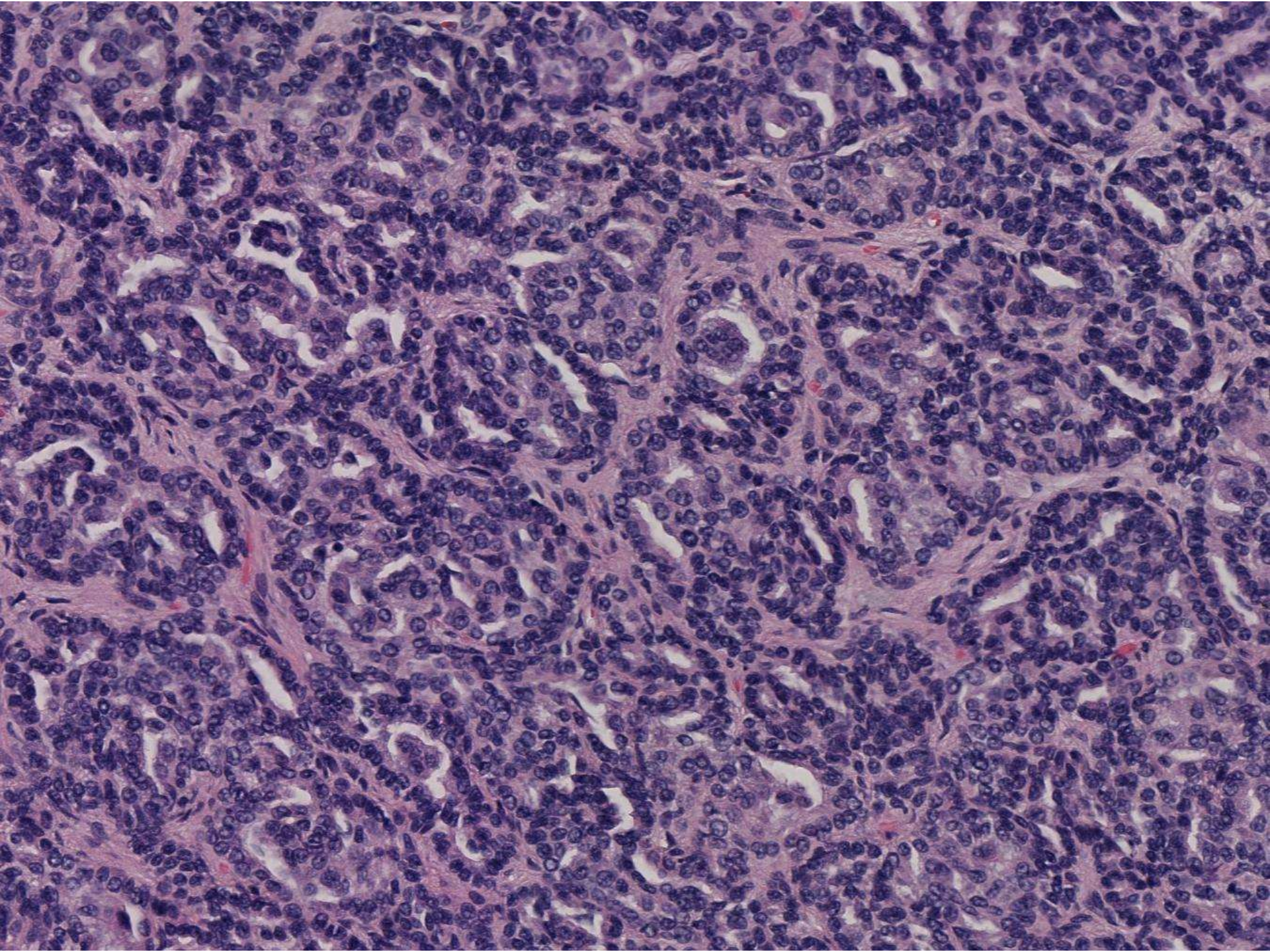
Right renal mass.

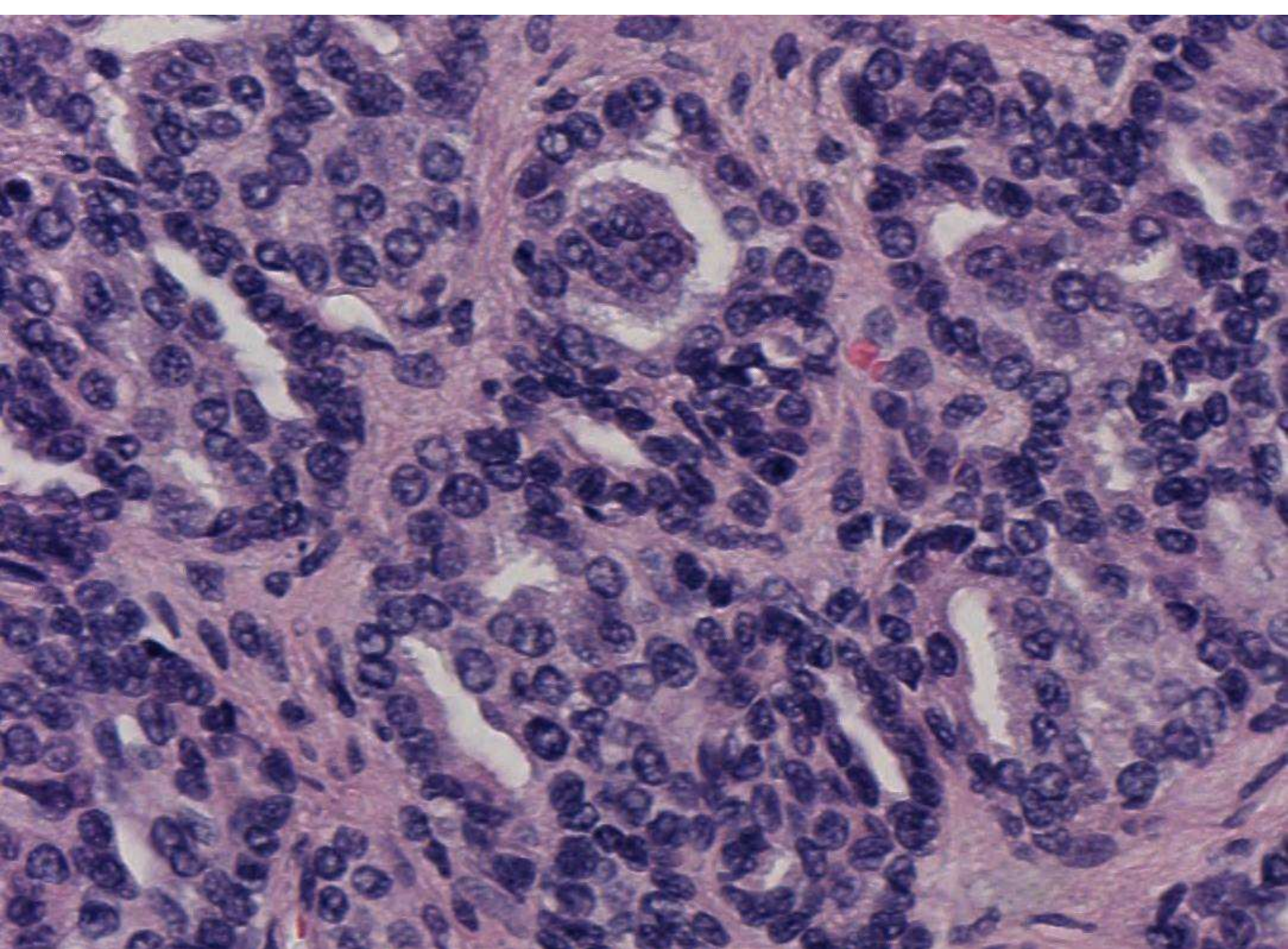






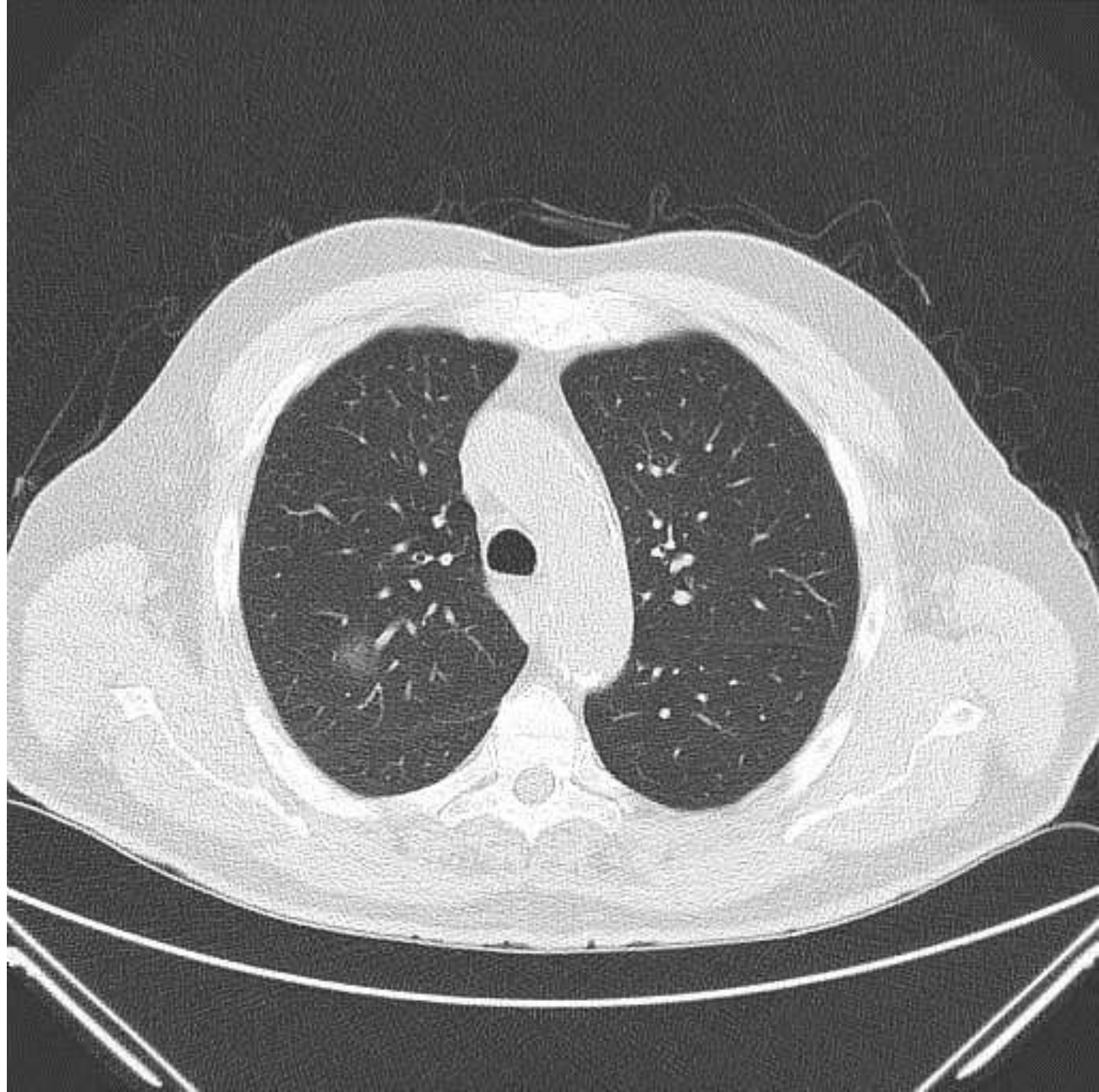


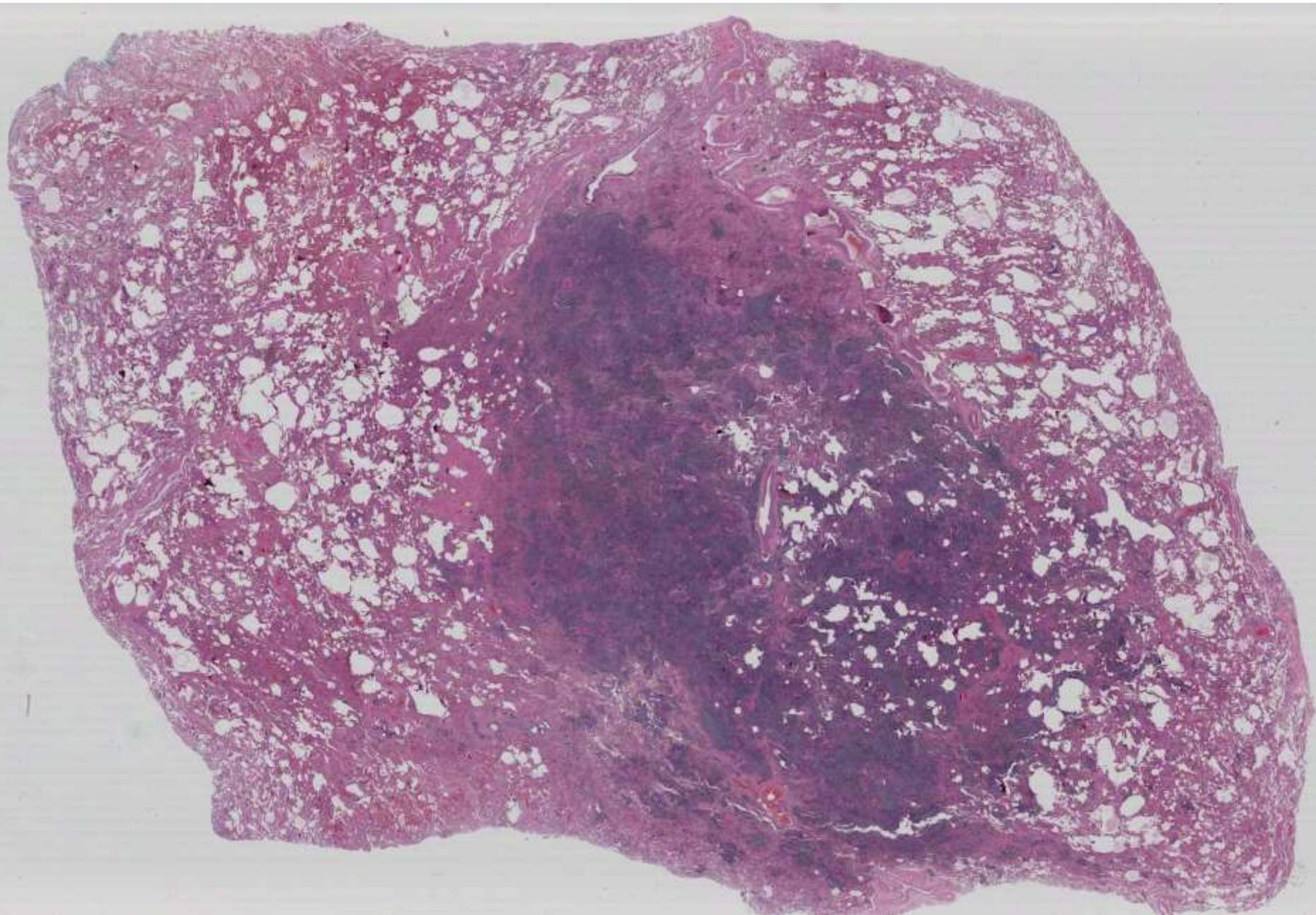


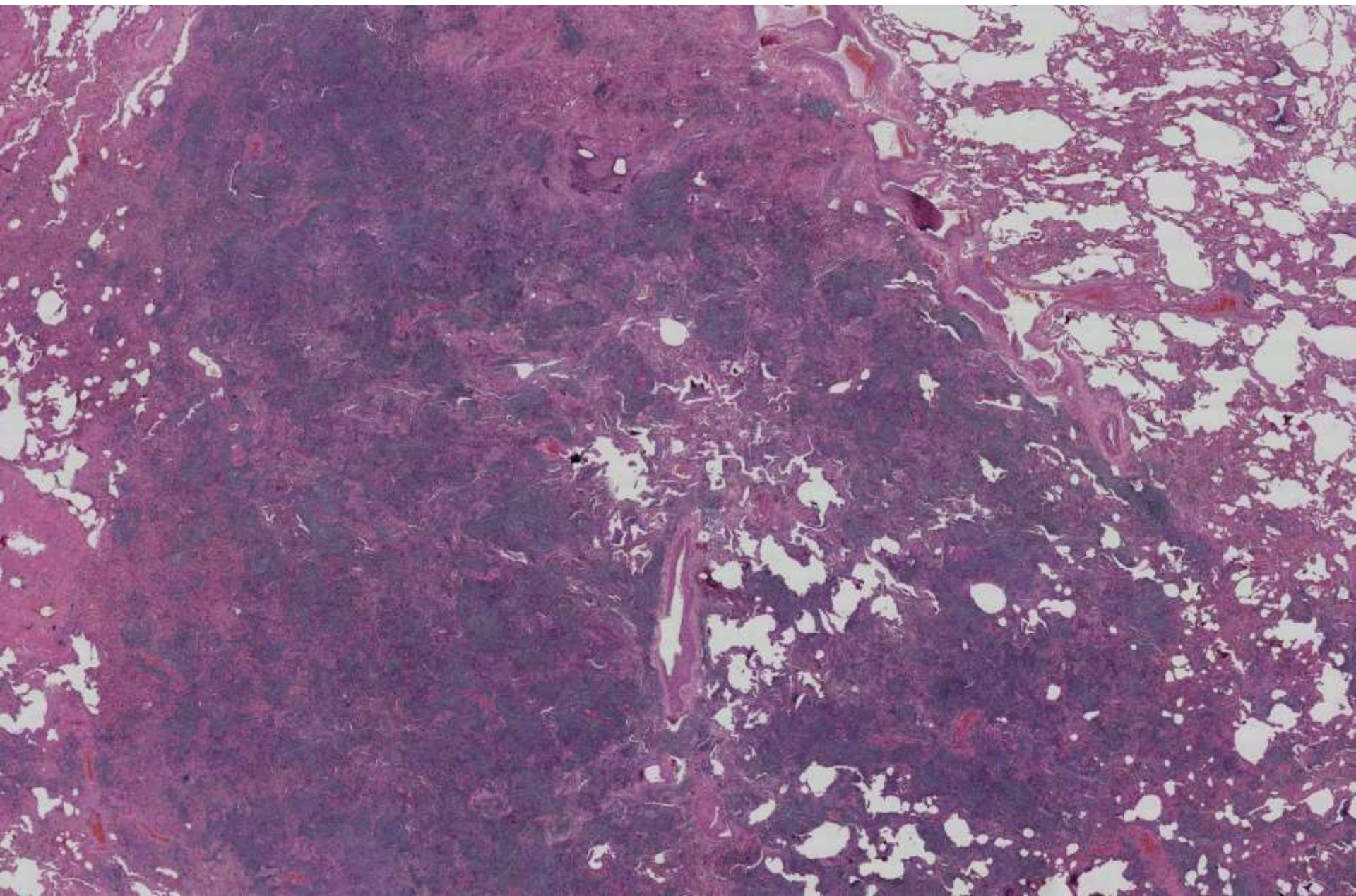


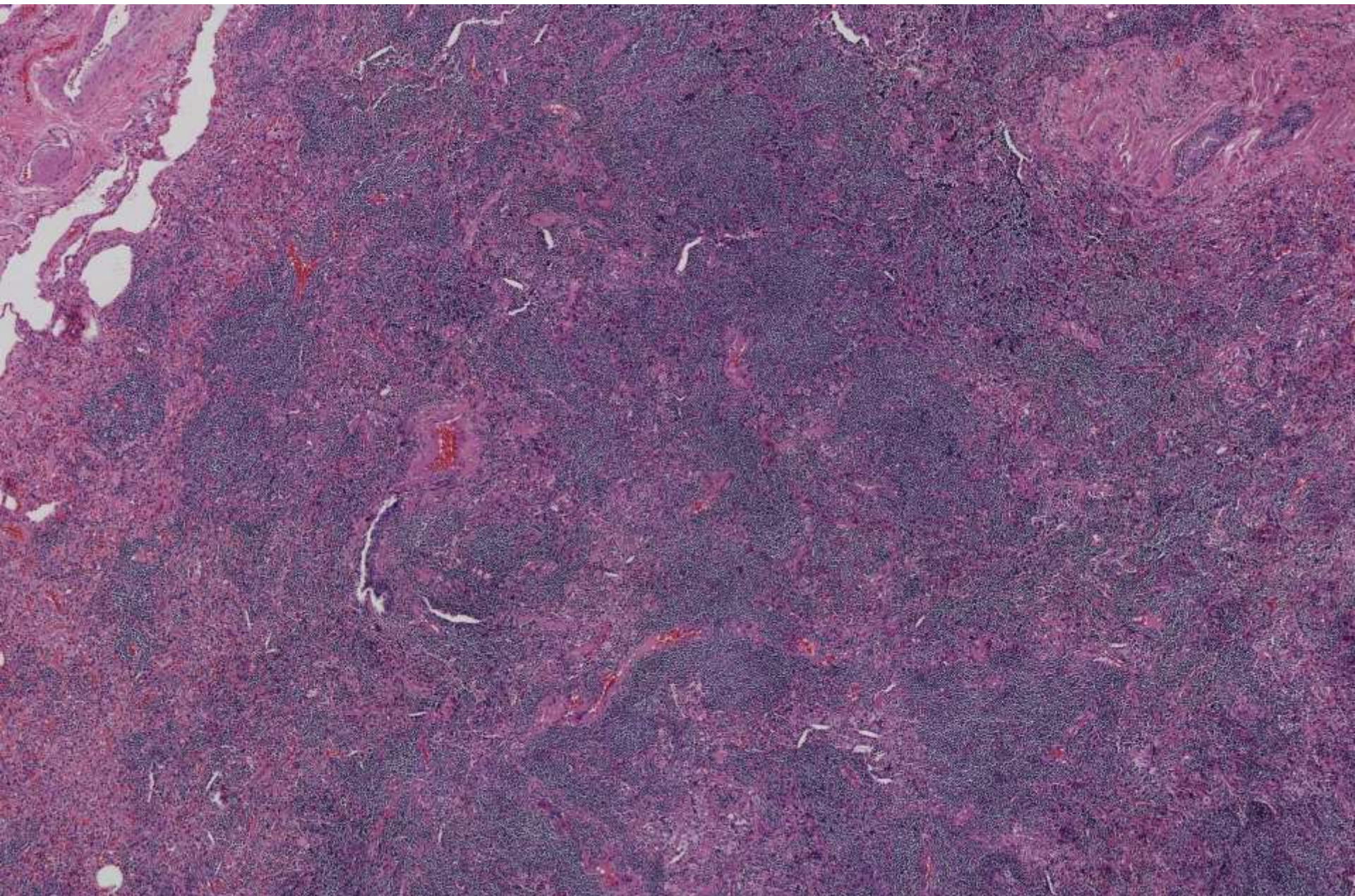
SB 6193 [scanned slide available]
Charles Lombard;
El Camino Hospital

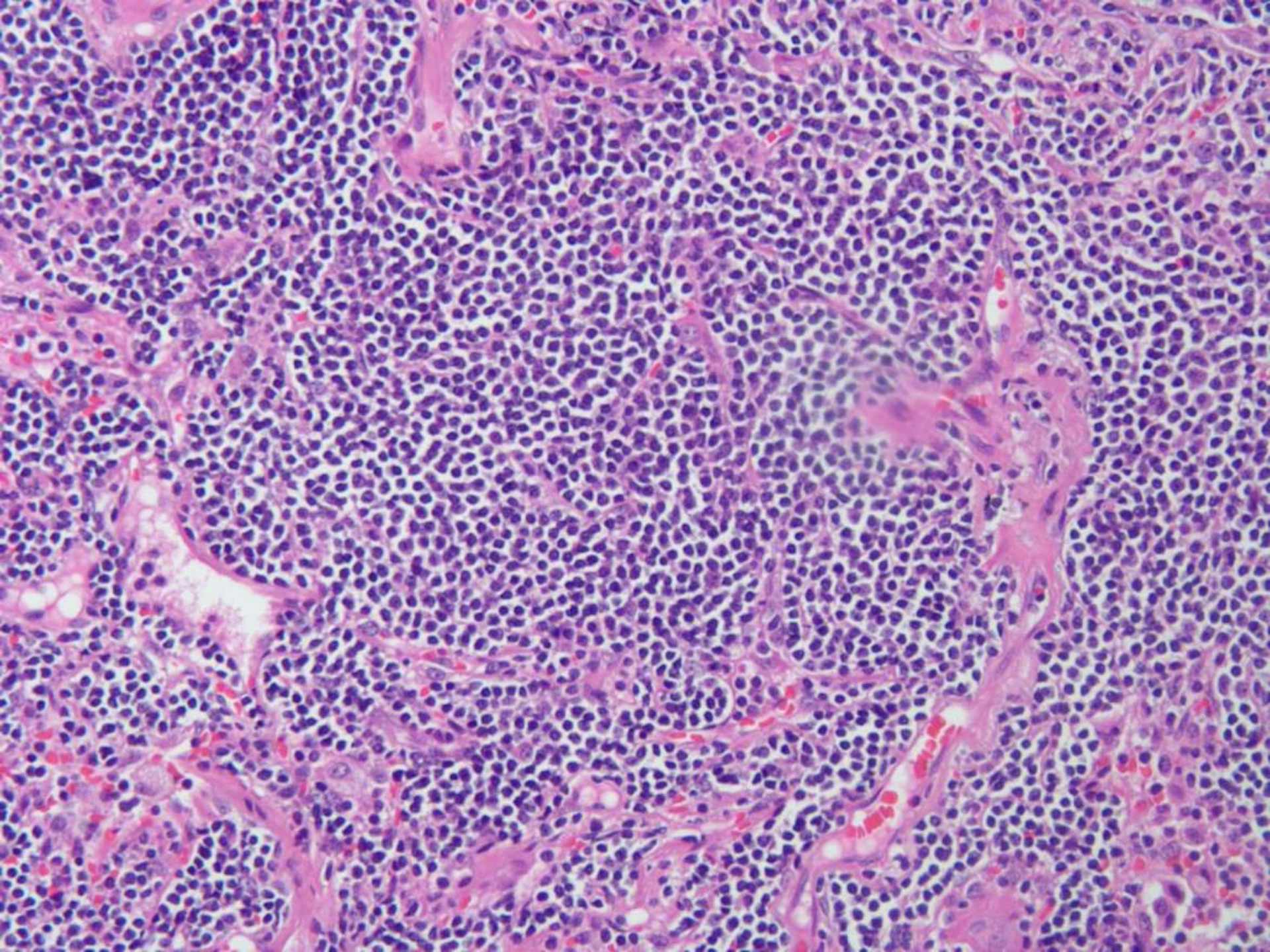
82-year-old man with pulmonary
nodule and hilar/mediastinal
lymphadenopathy.

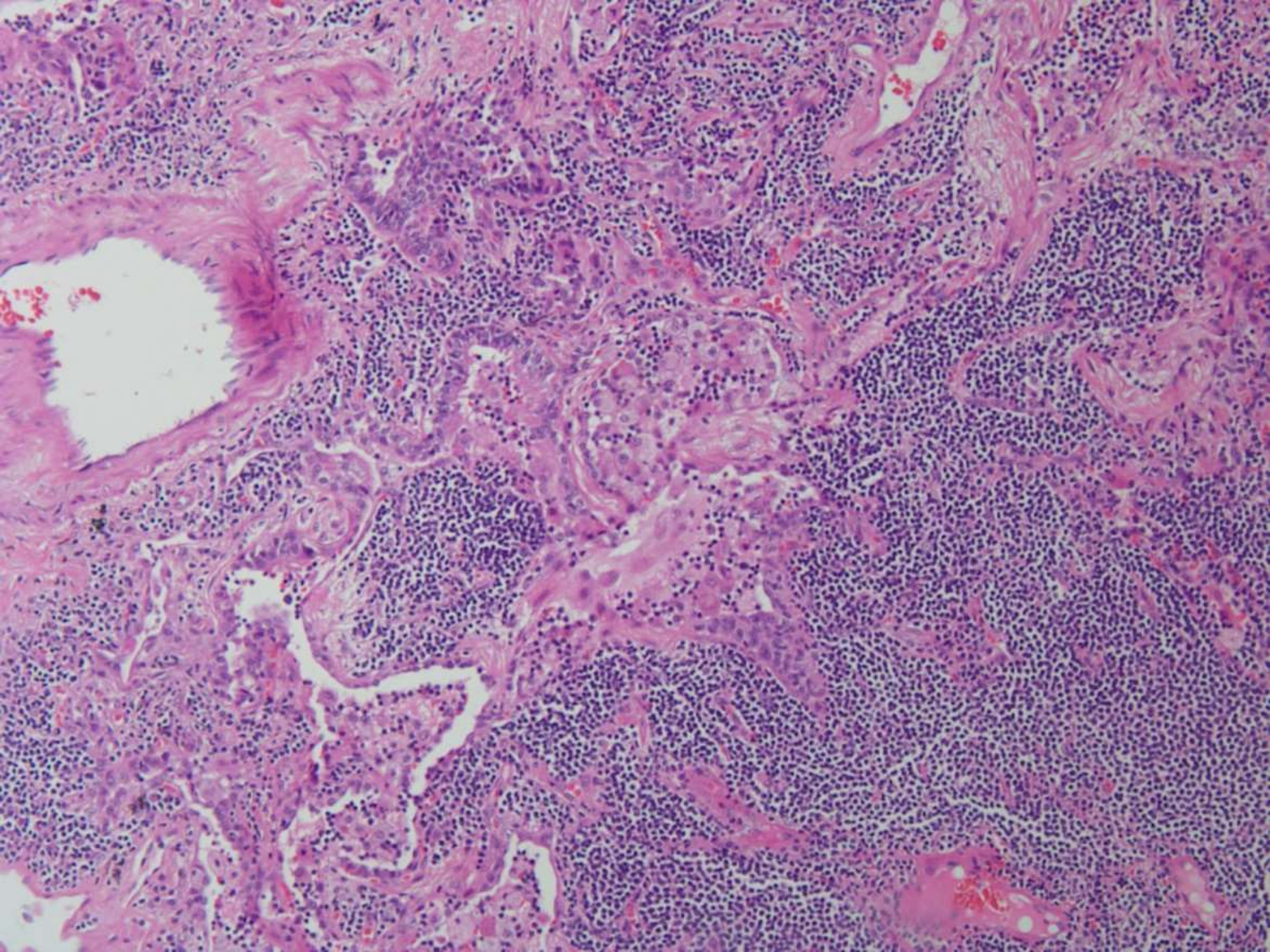


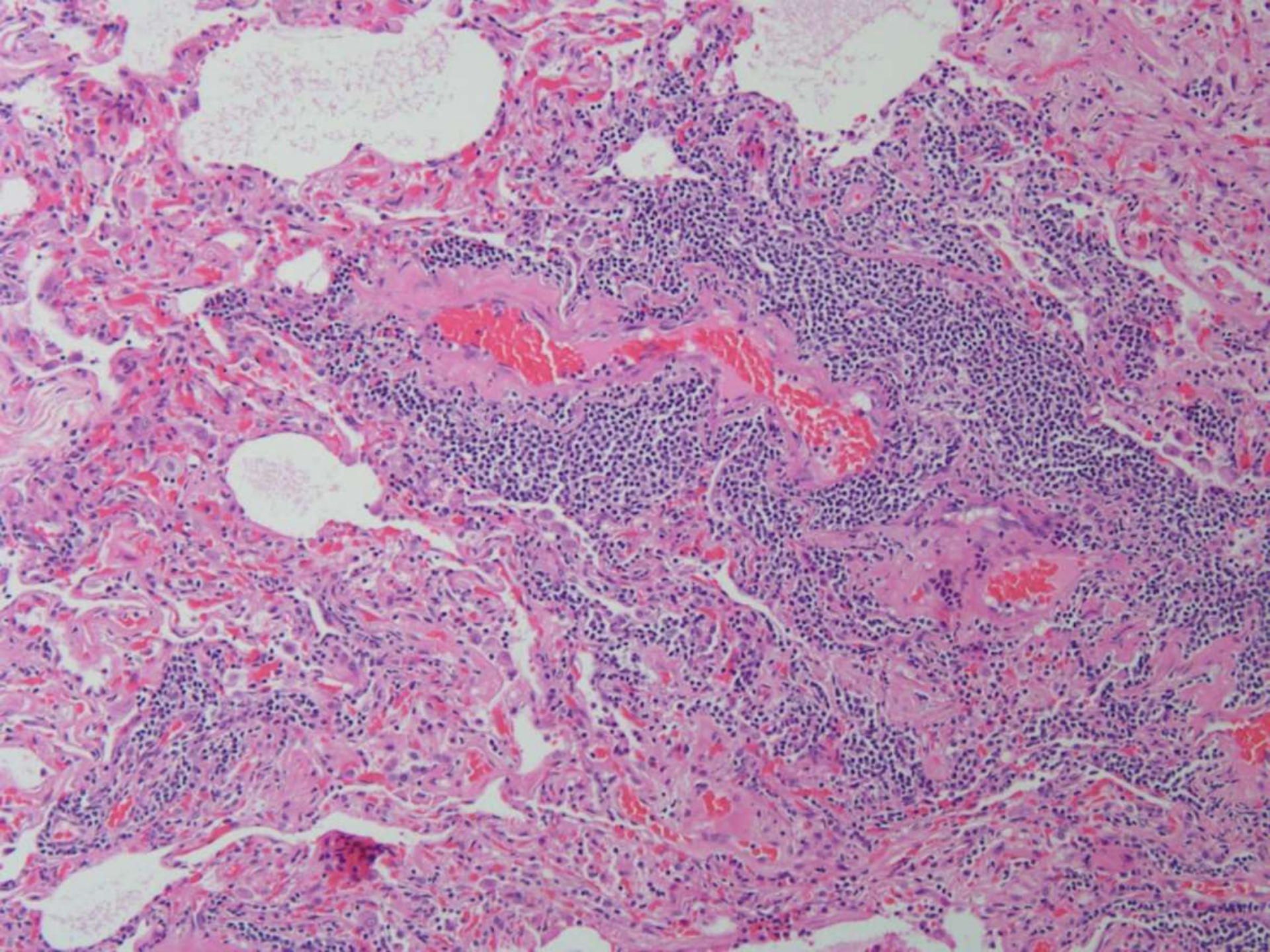




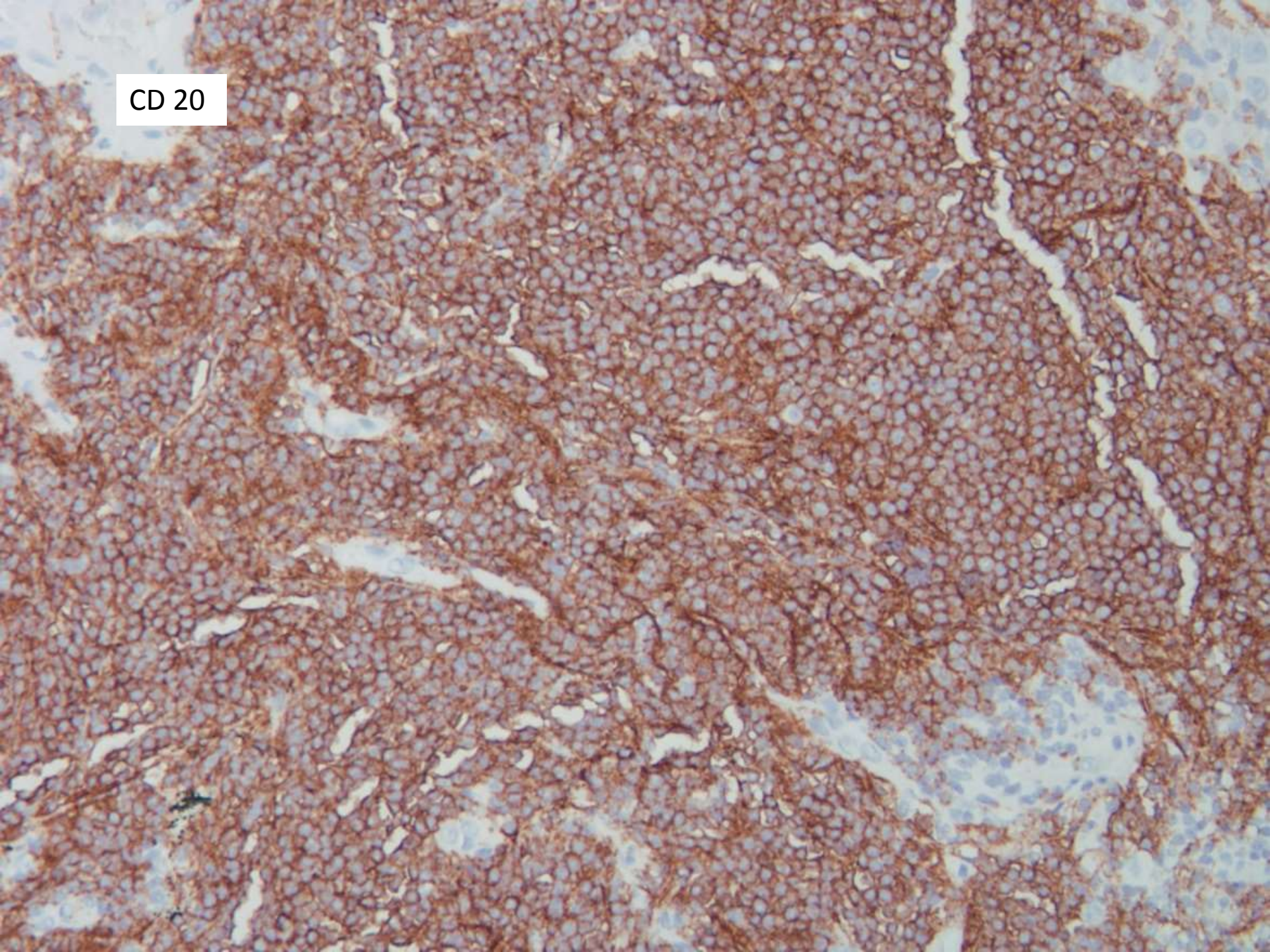




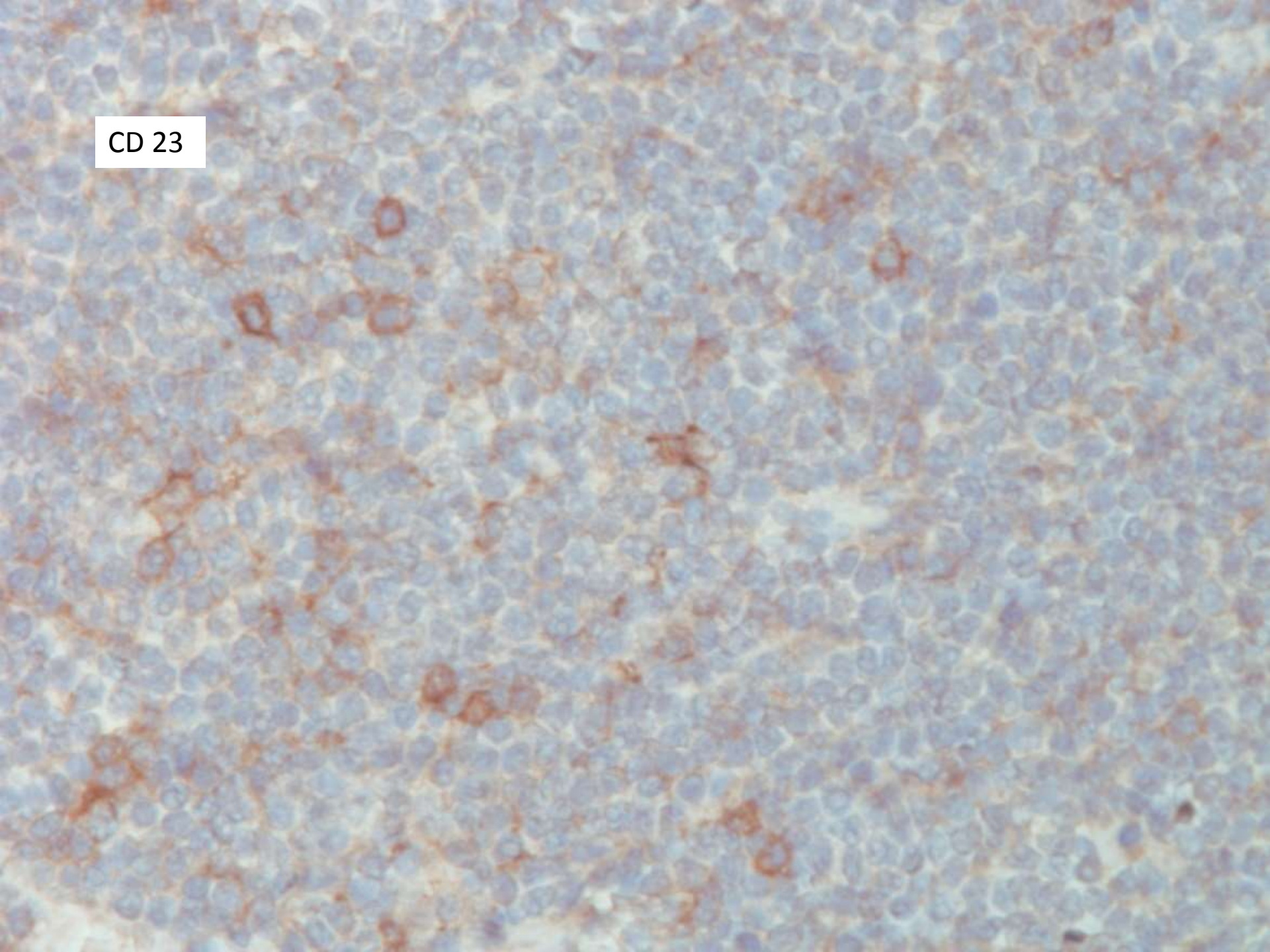




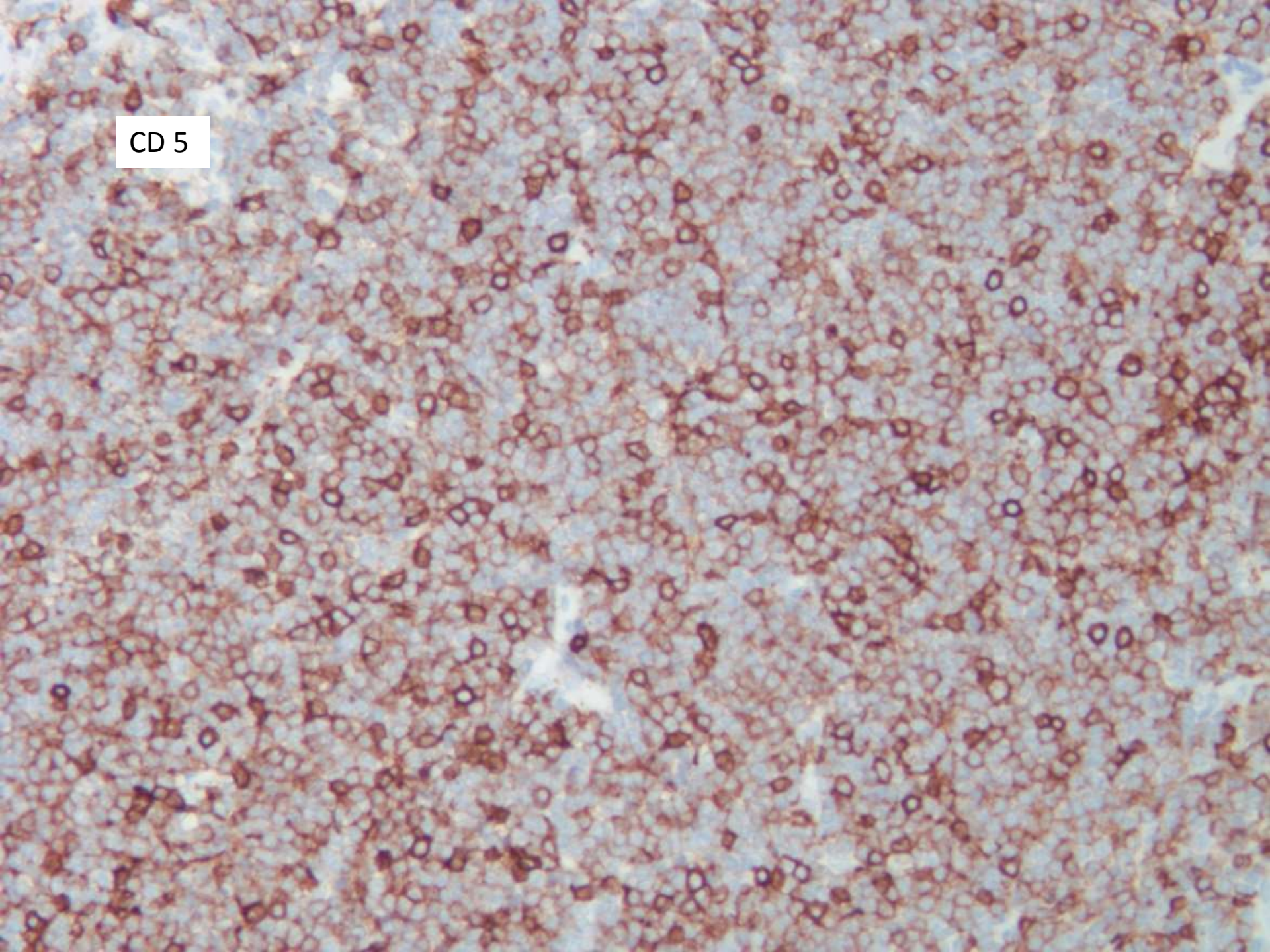
CD 20



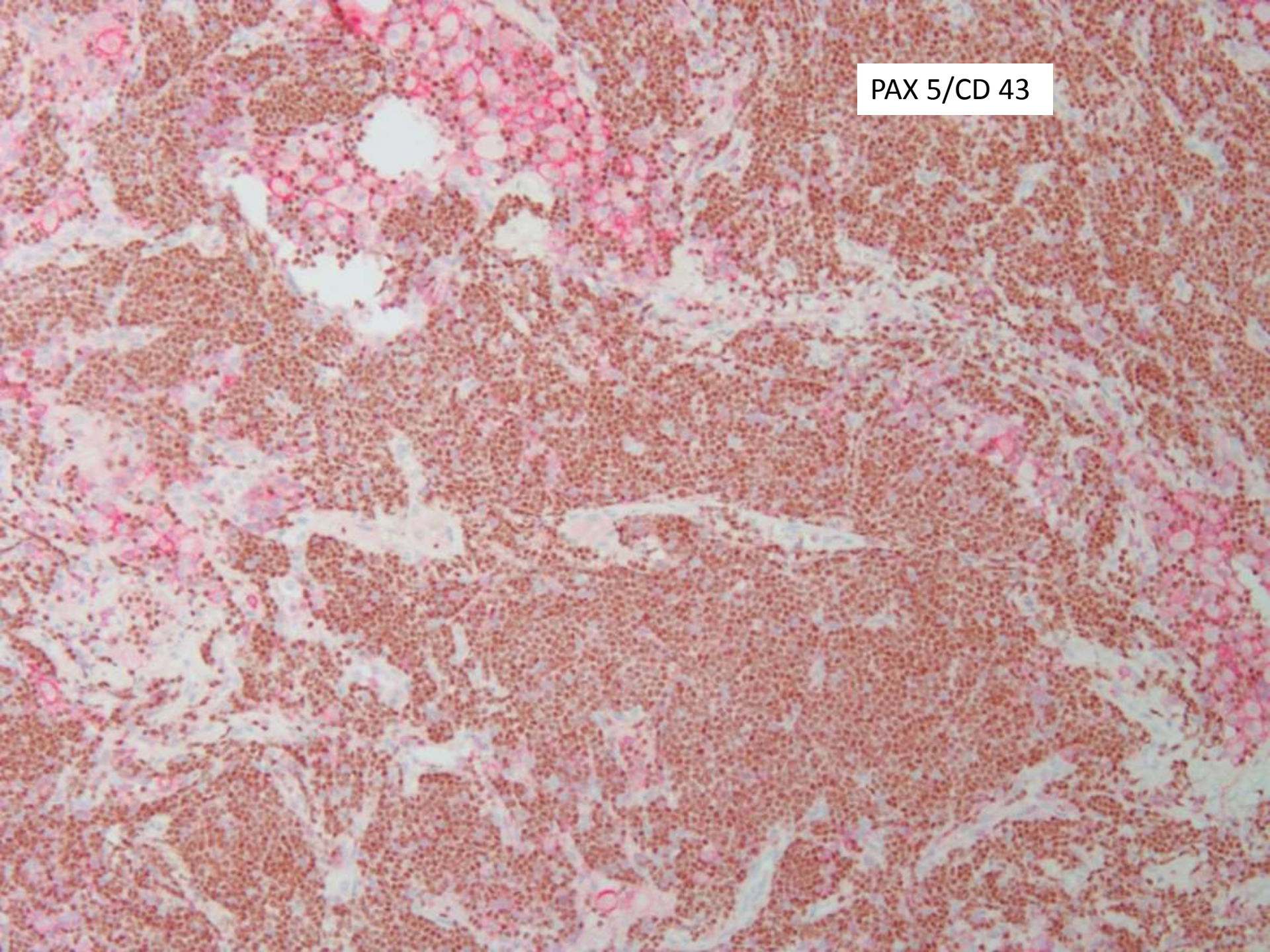
CD 23



CD 5

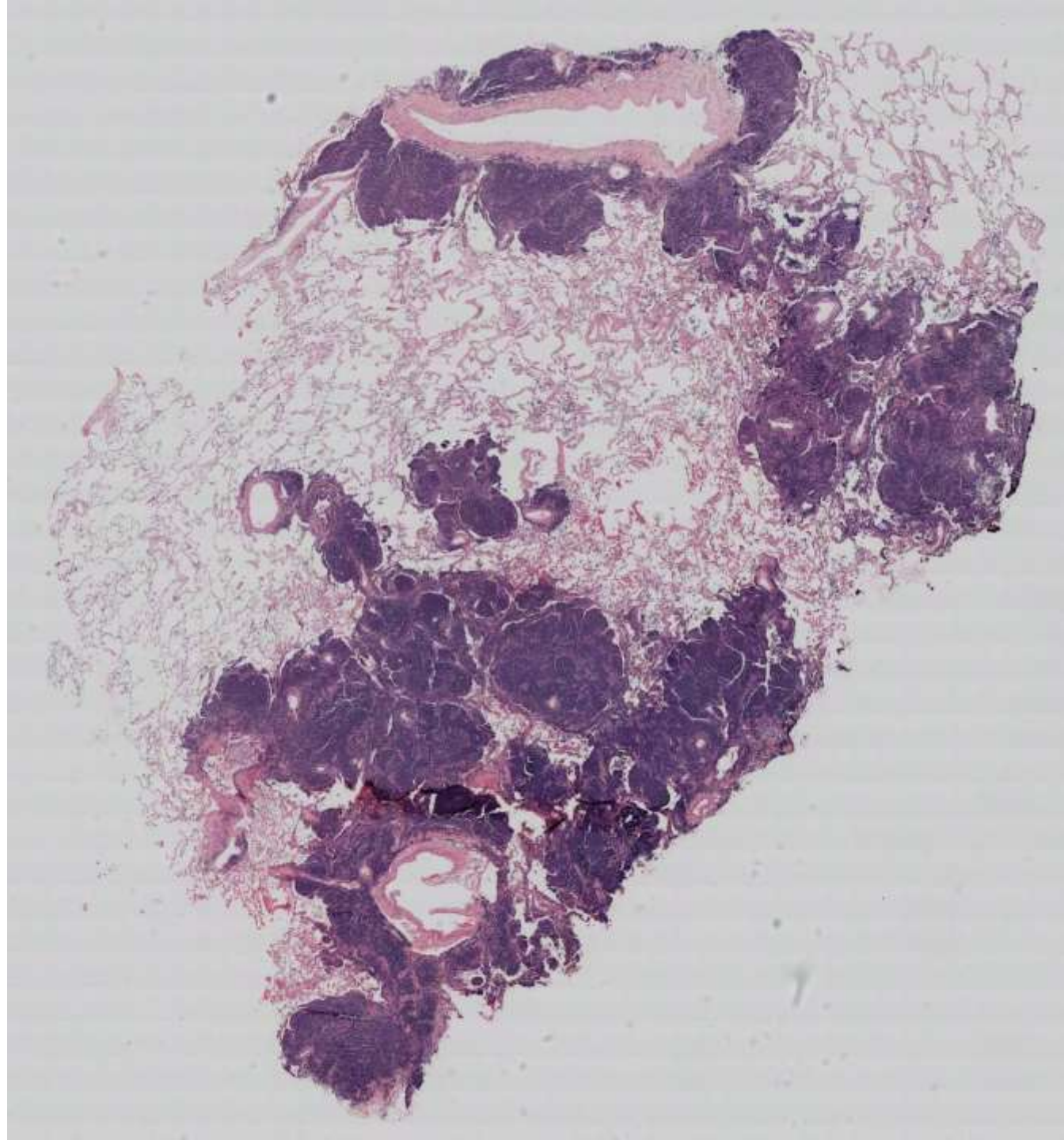


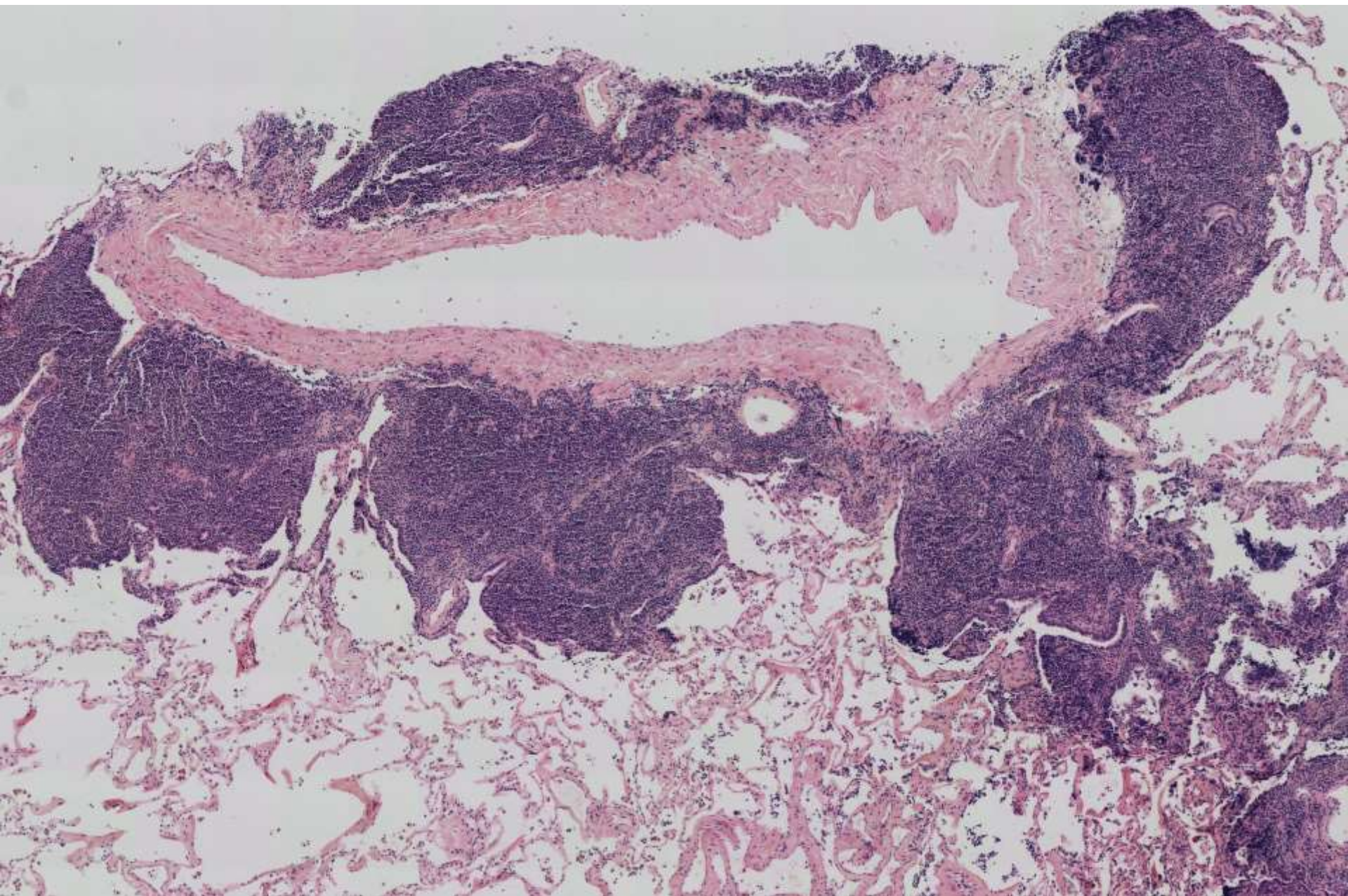
PAX 5/CD 43

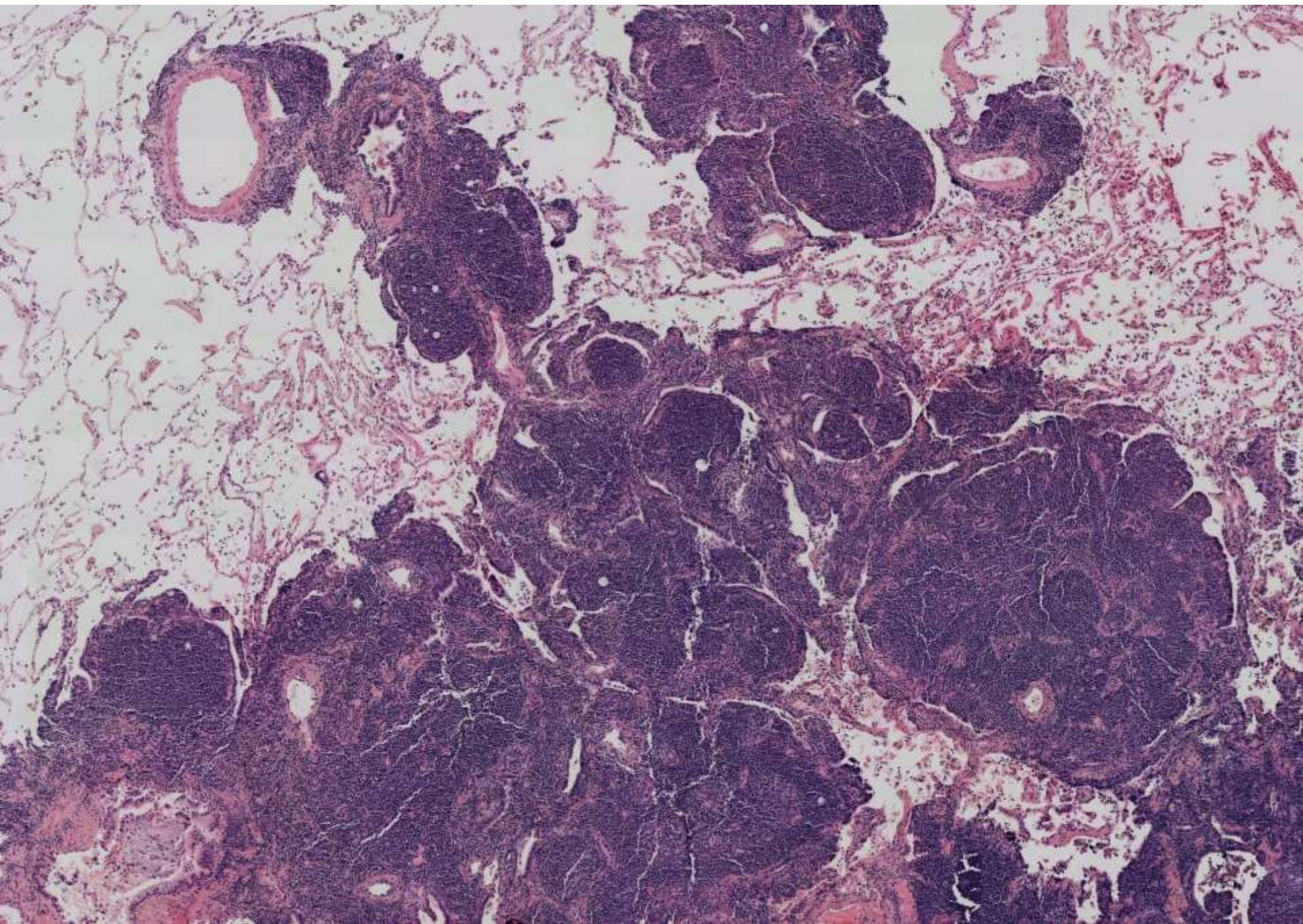


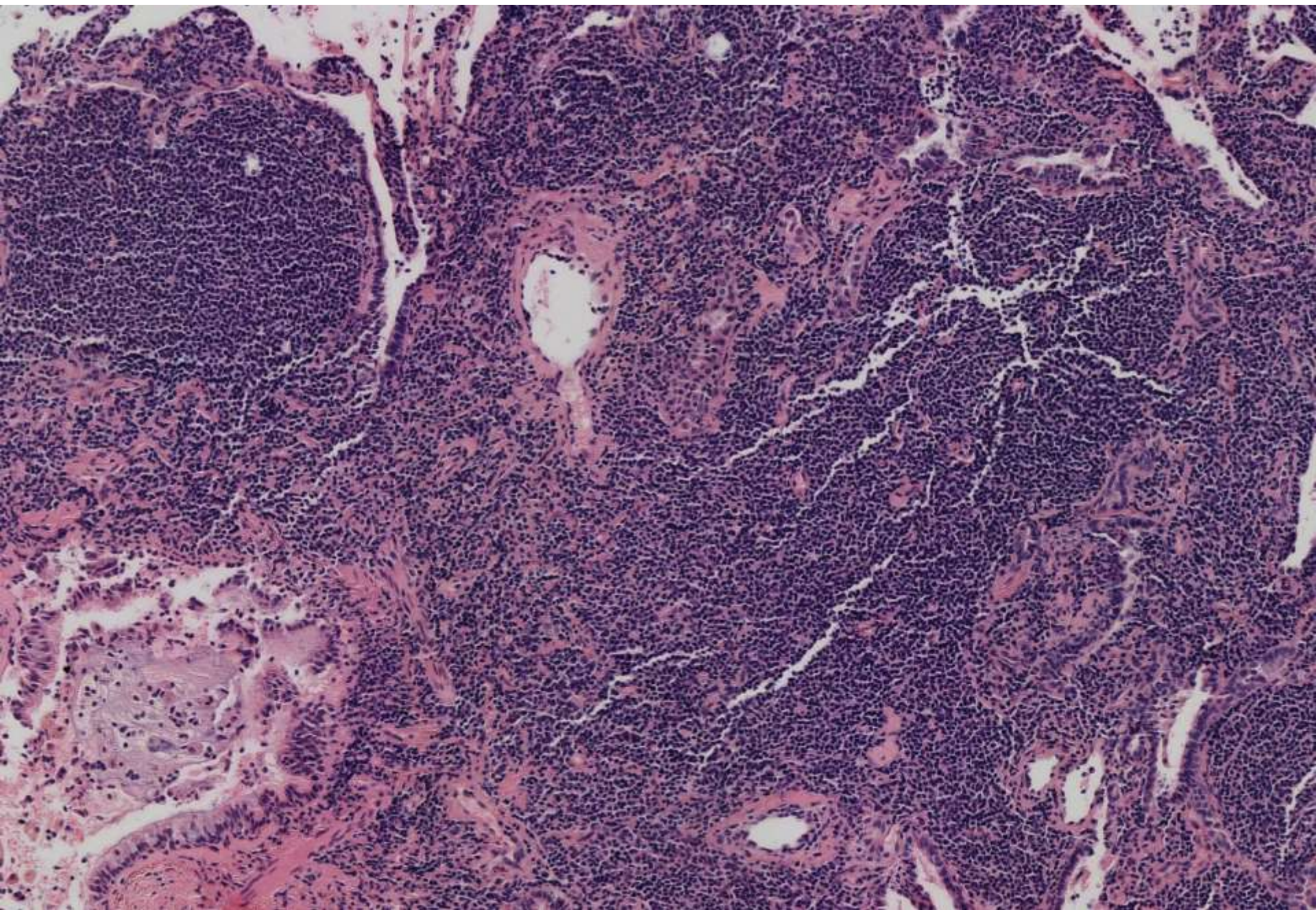
**SB 6194 [scanned slide available]
Simon Chen/Melissa Clark;
Palo Alto VA**

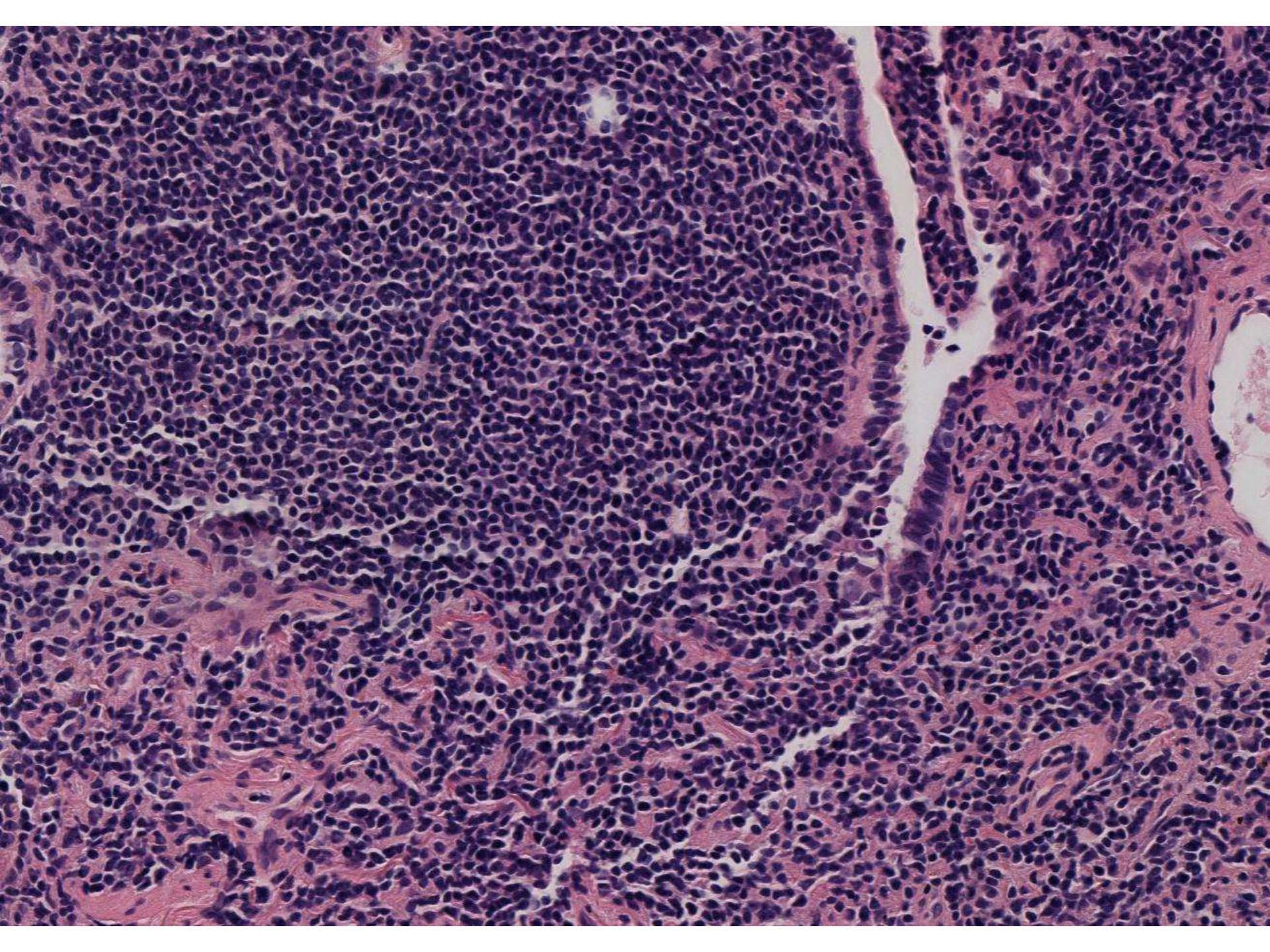
67-year-old man with lung nodule.

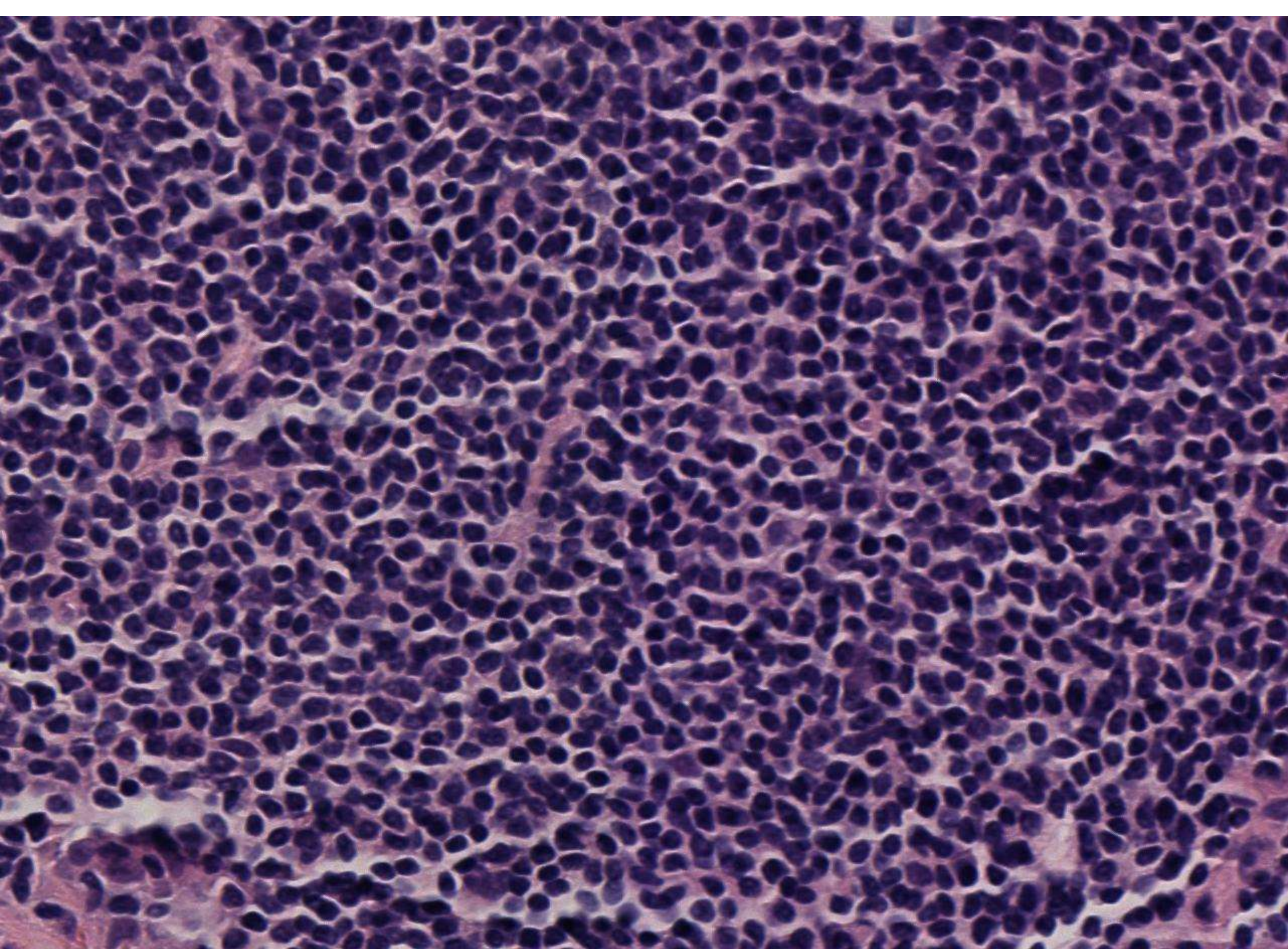


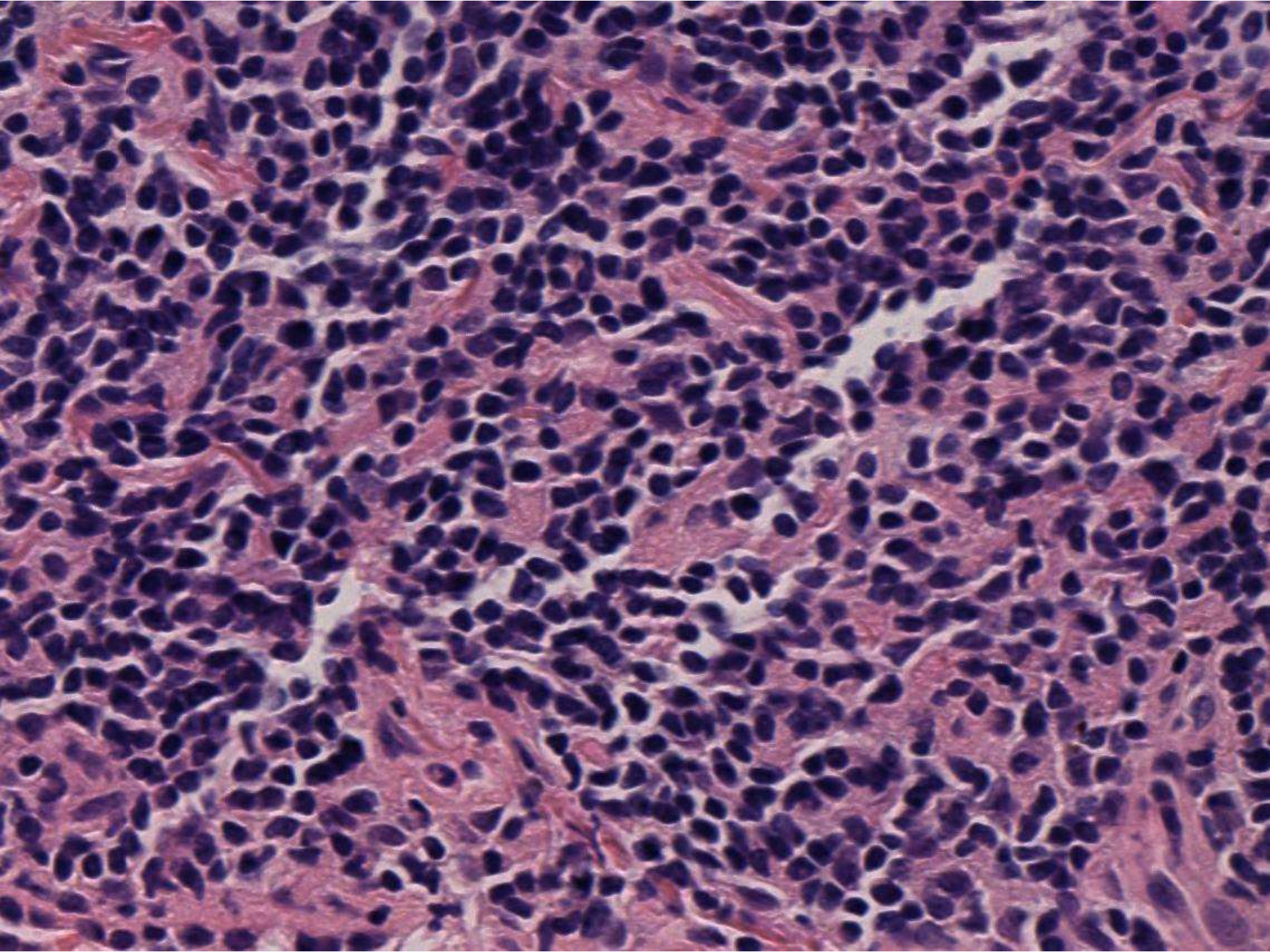






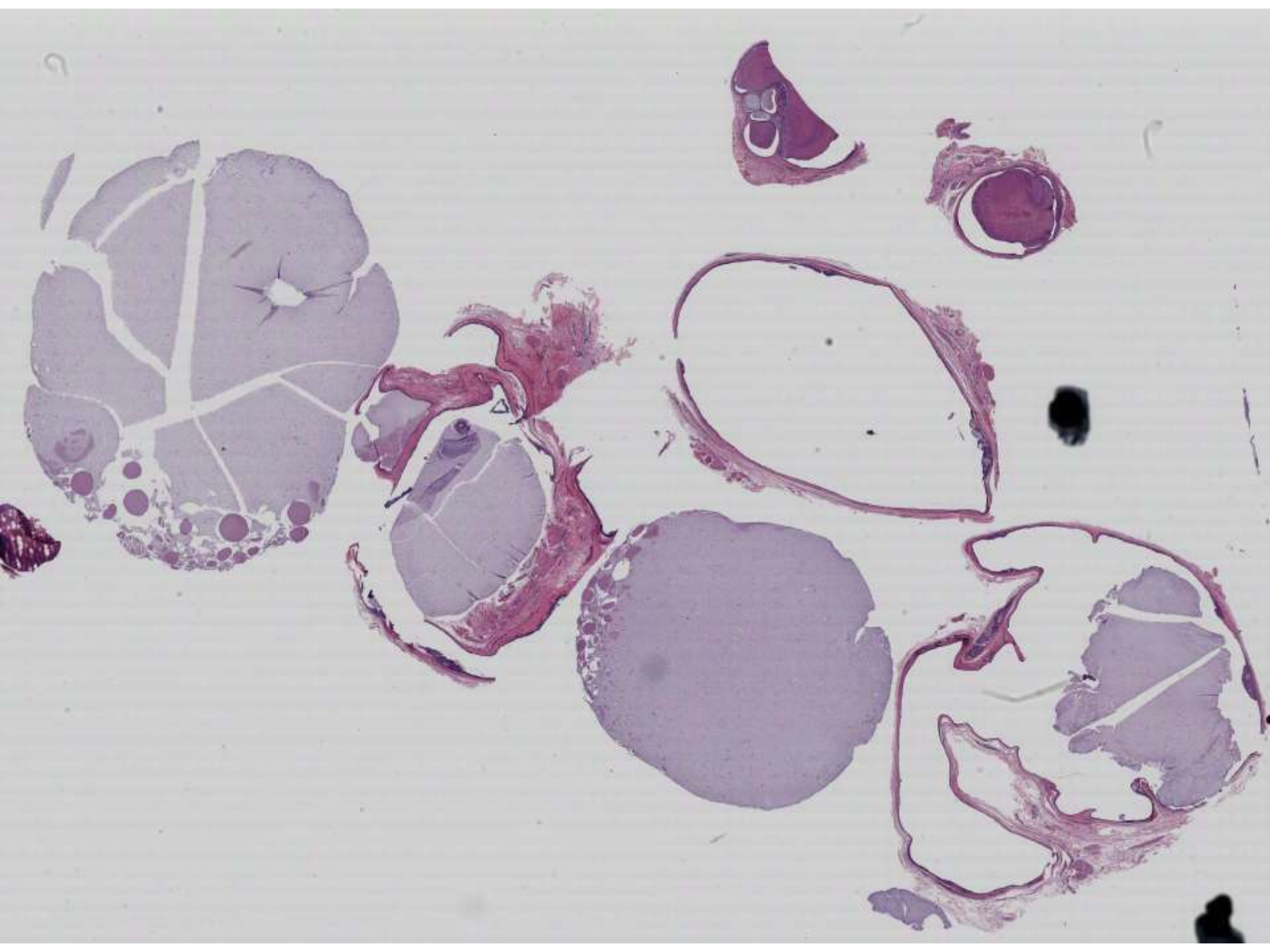


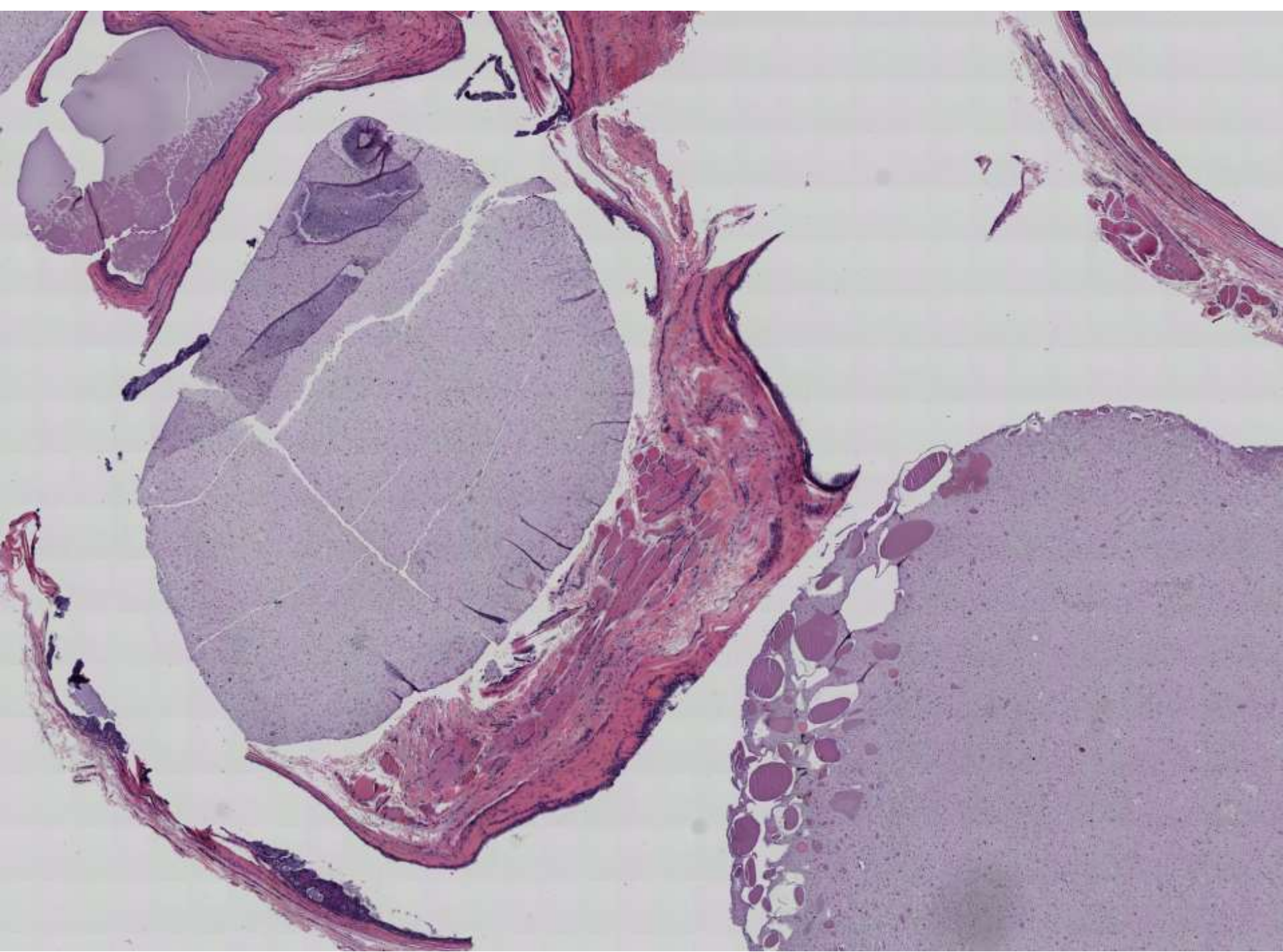


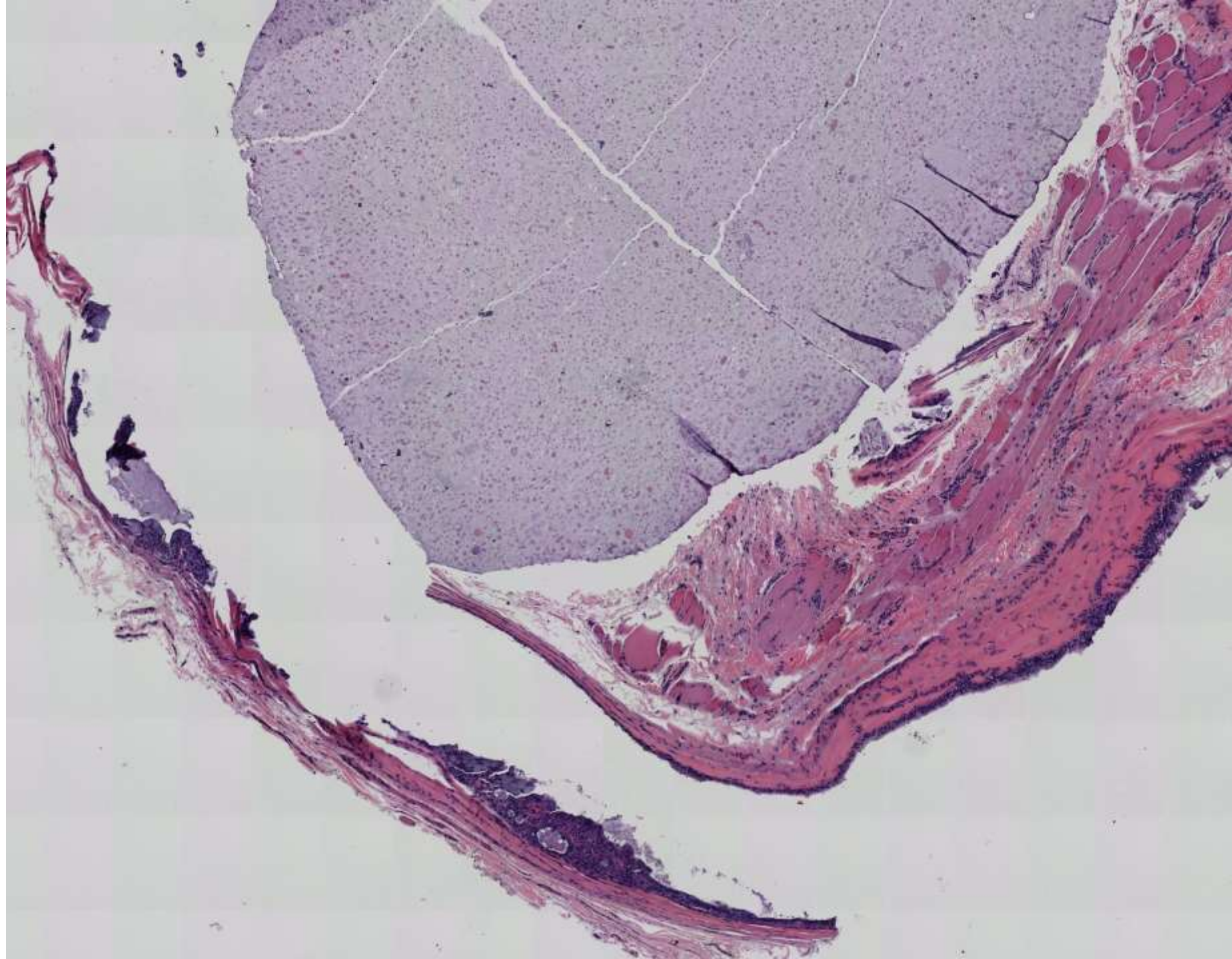


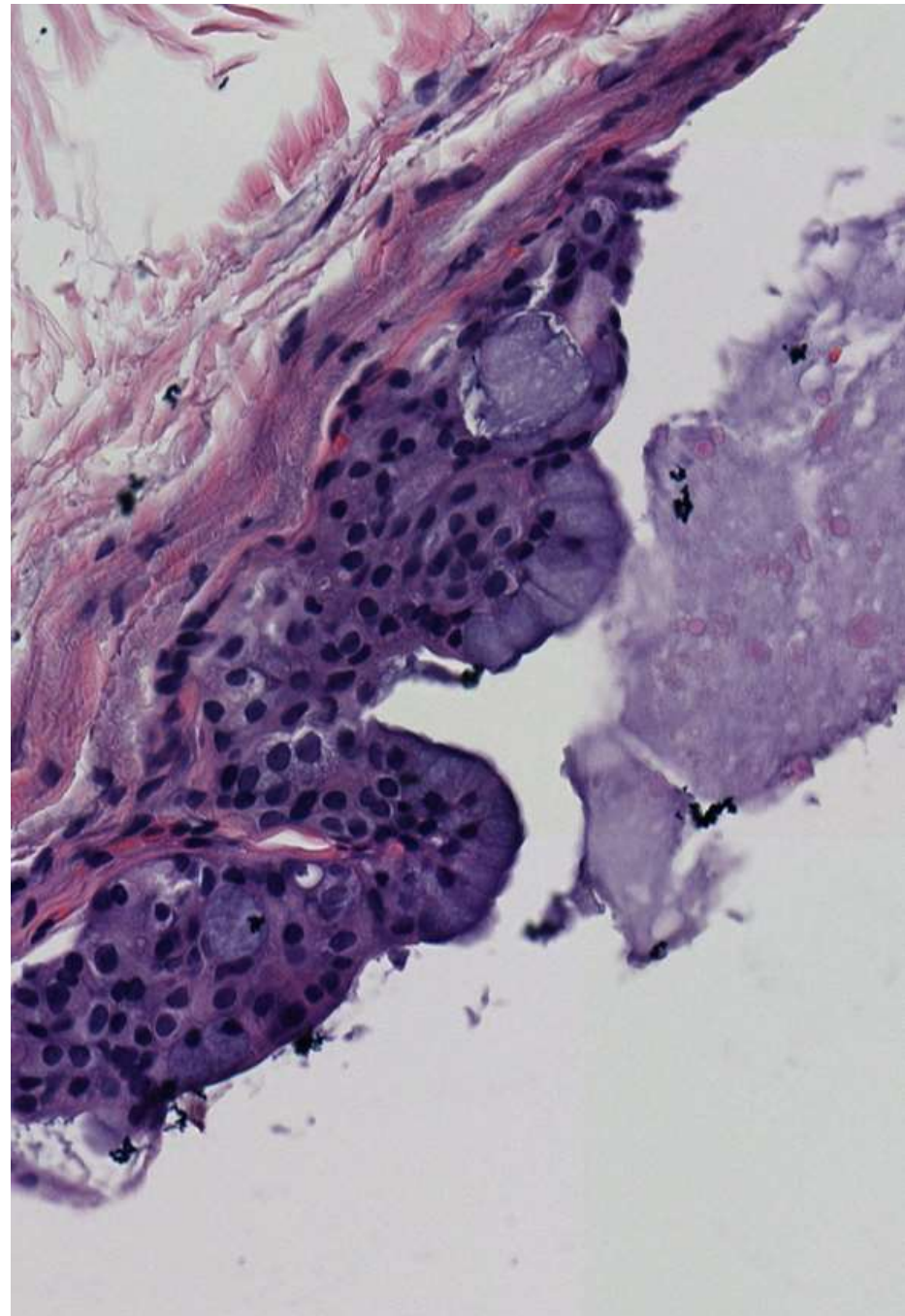
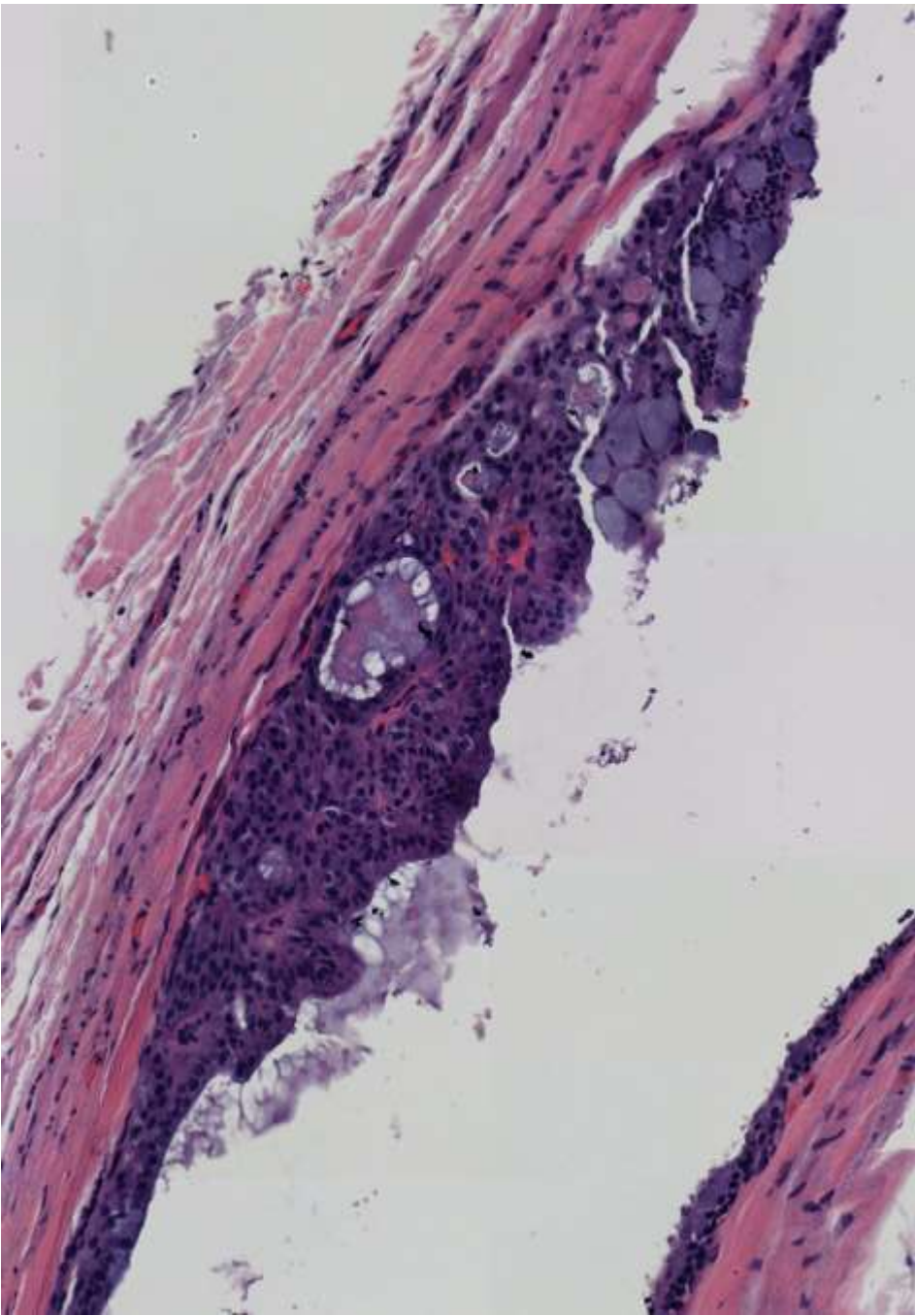
SB 6195 [scanned slide available]
Mahendra Ranchod; Calpath

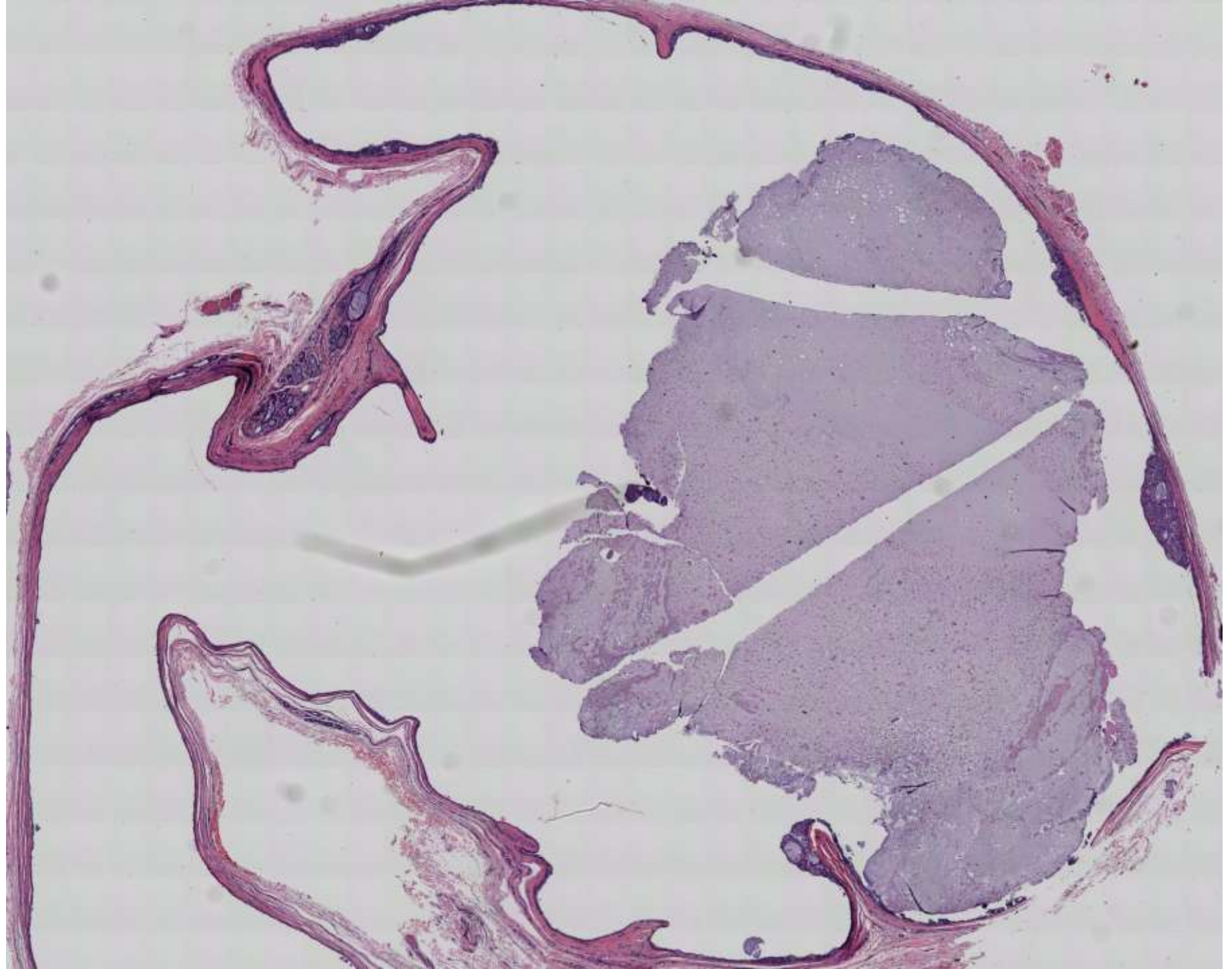
57-year-old man with nodule on
lower lip.

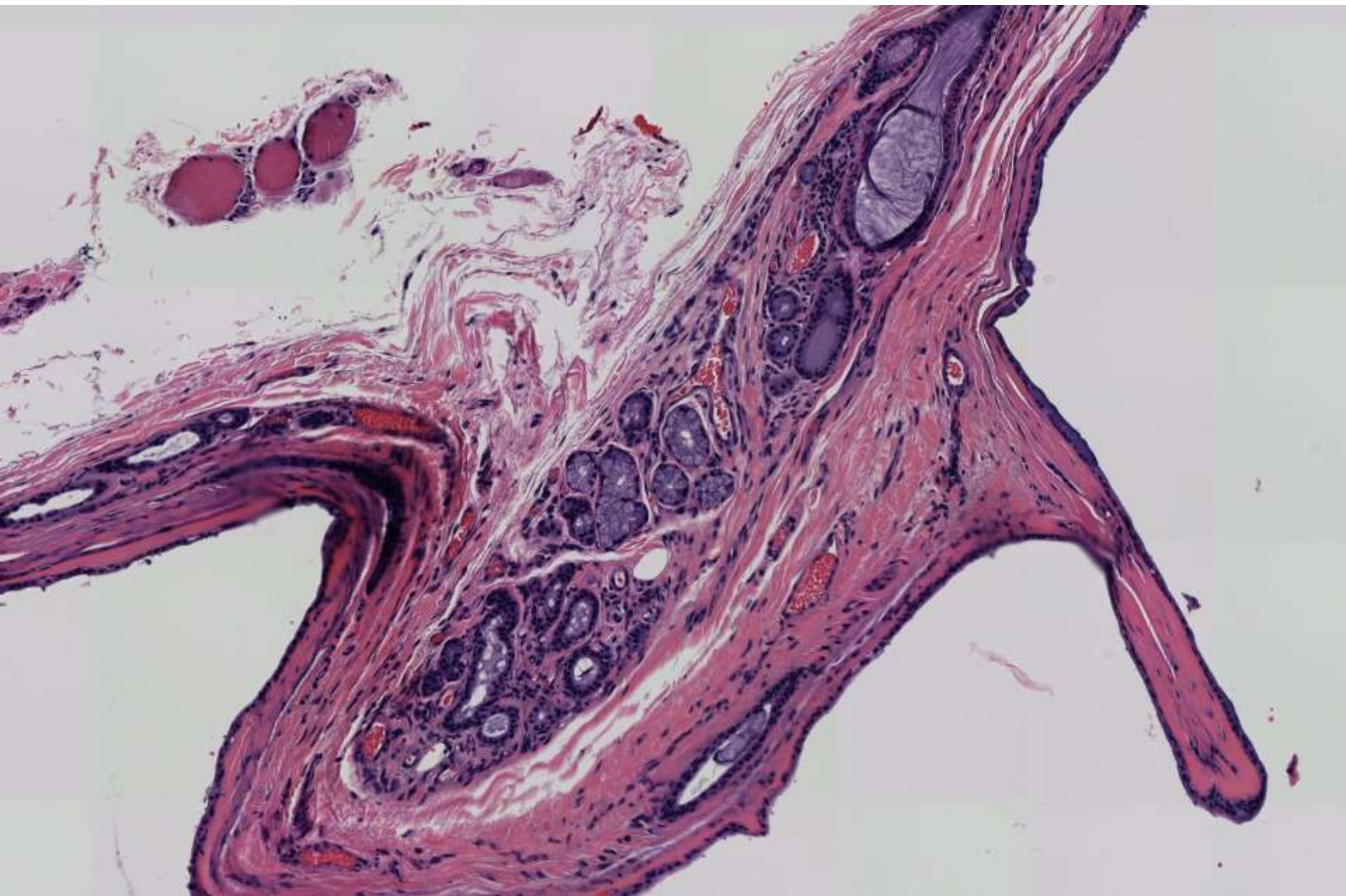


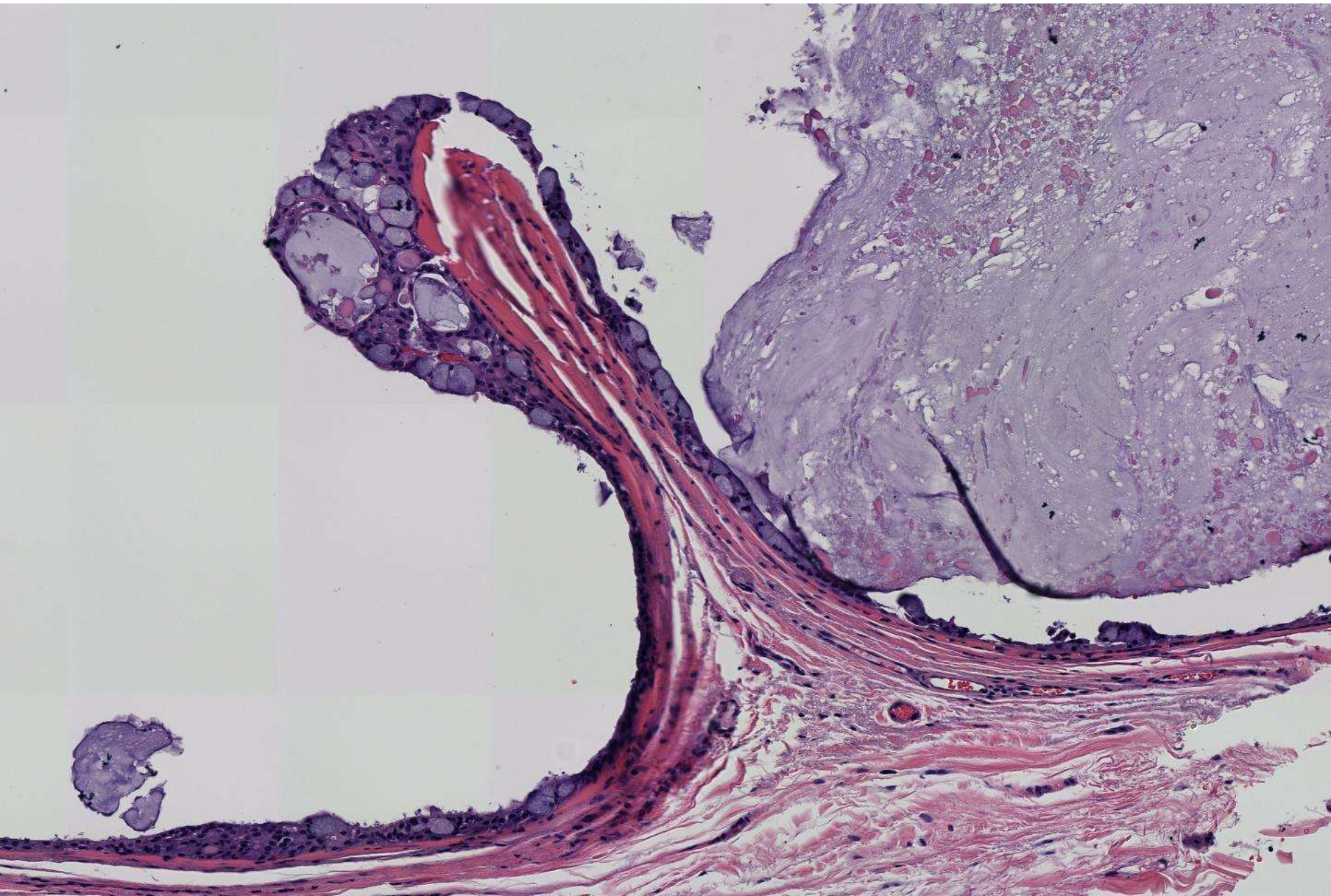


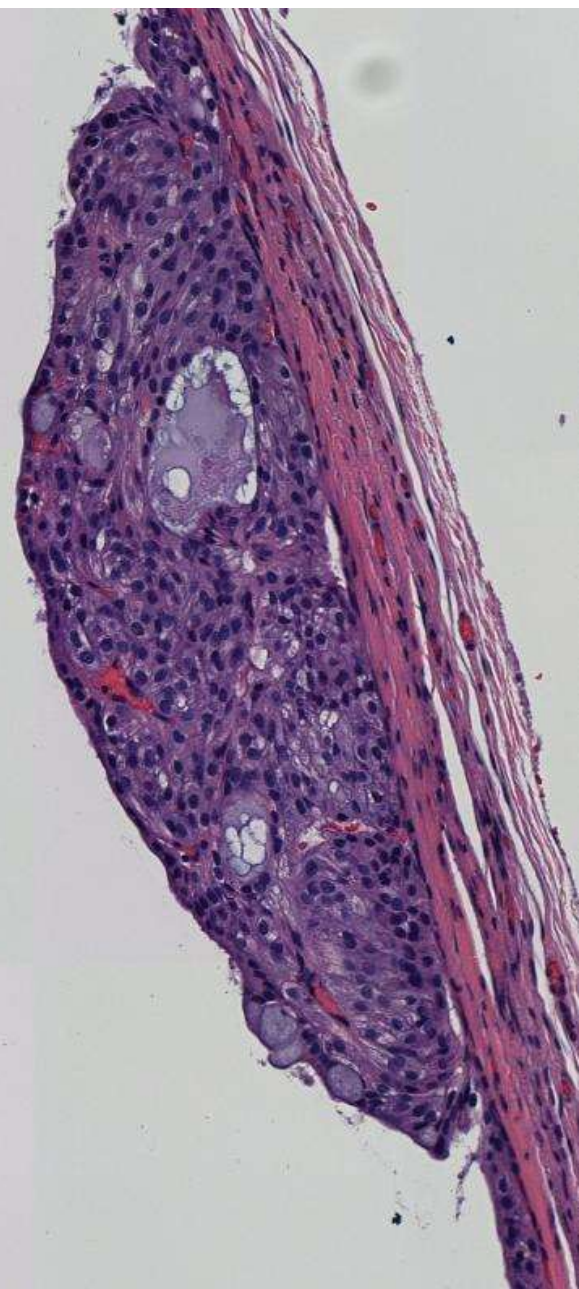
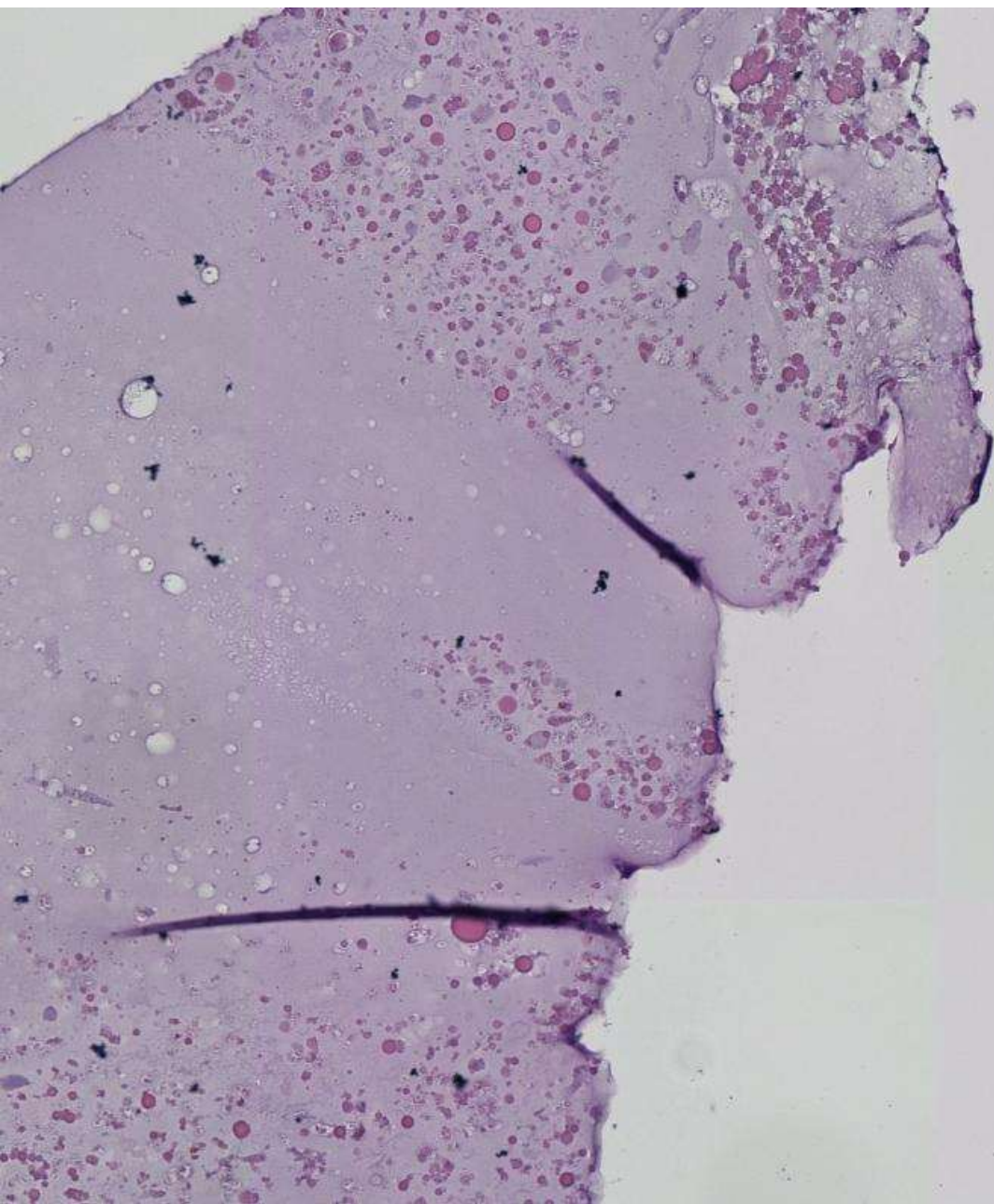
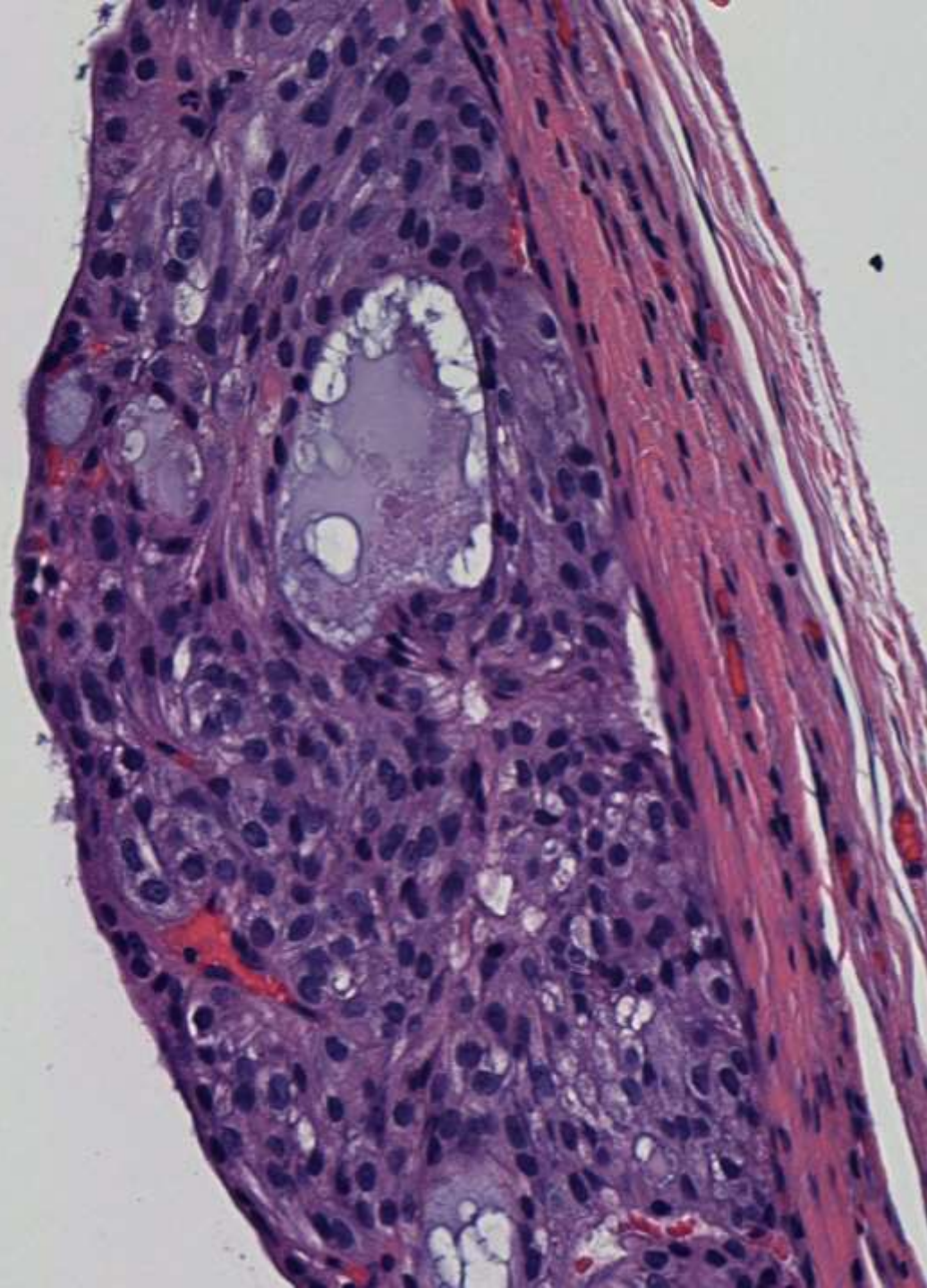


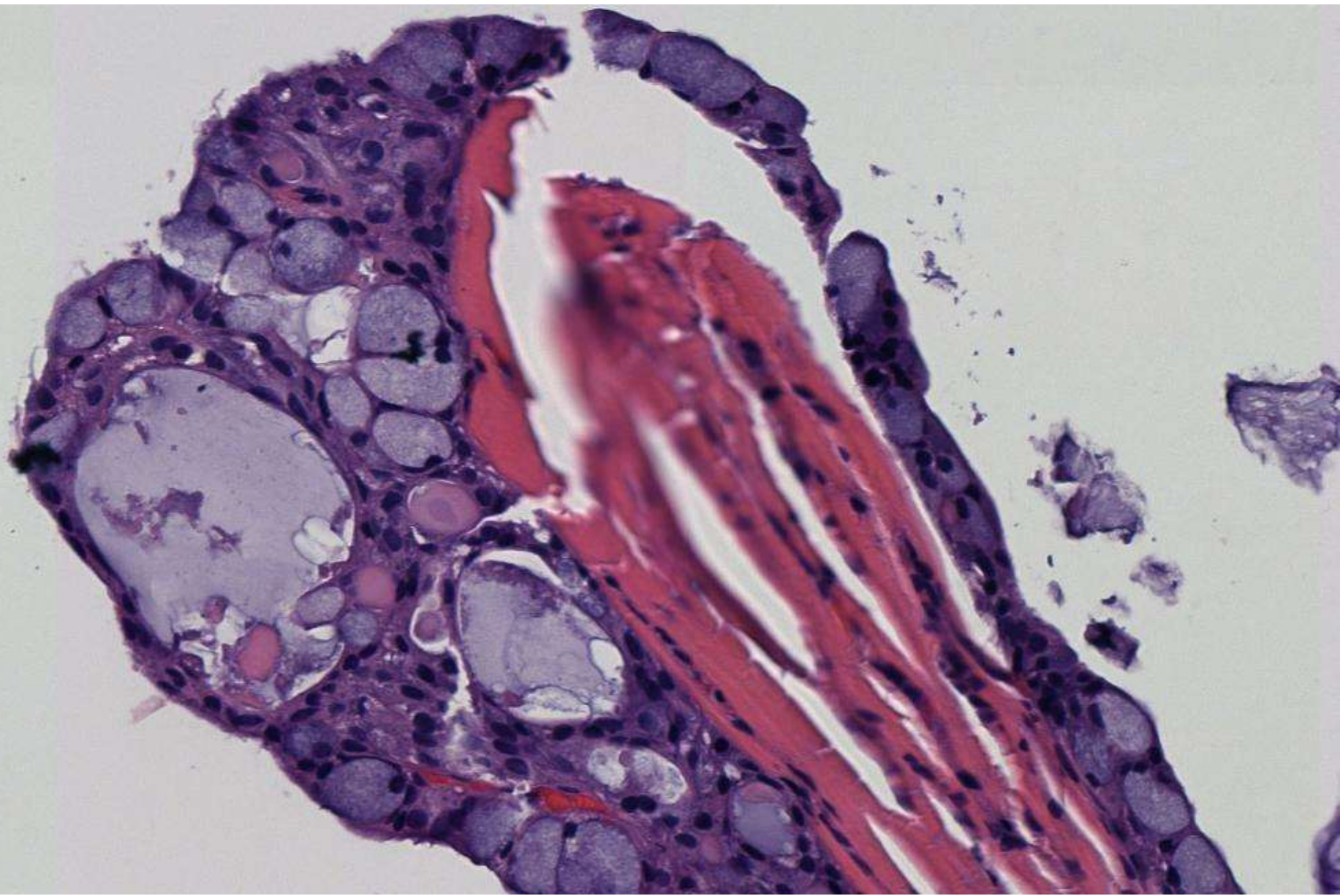








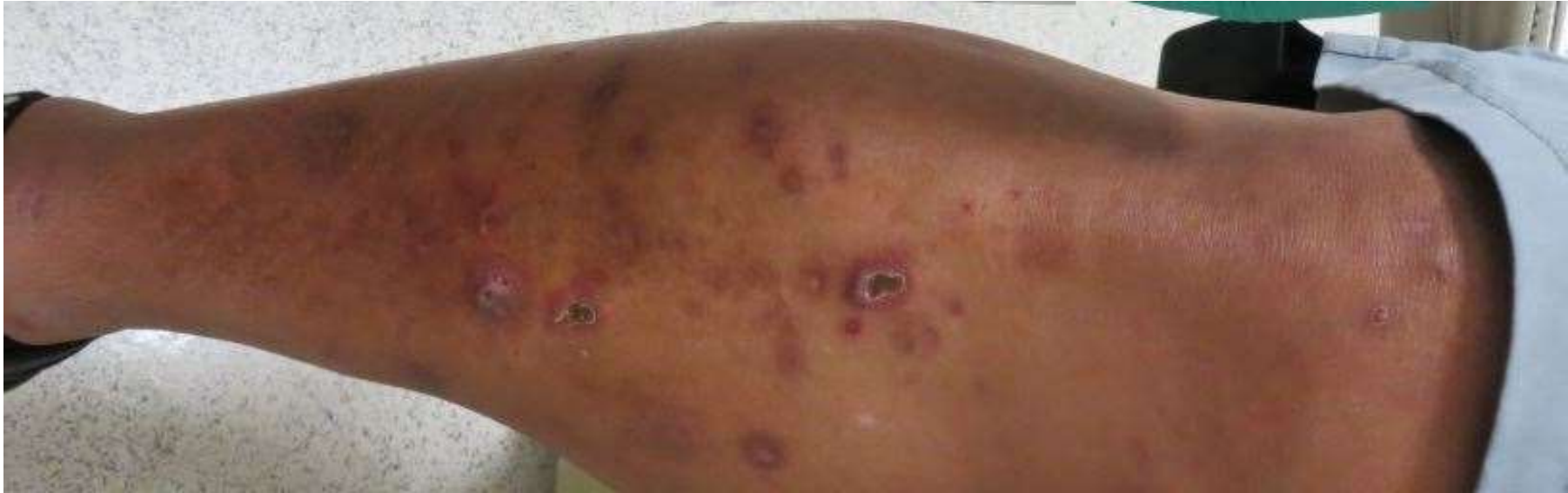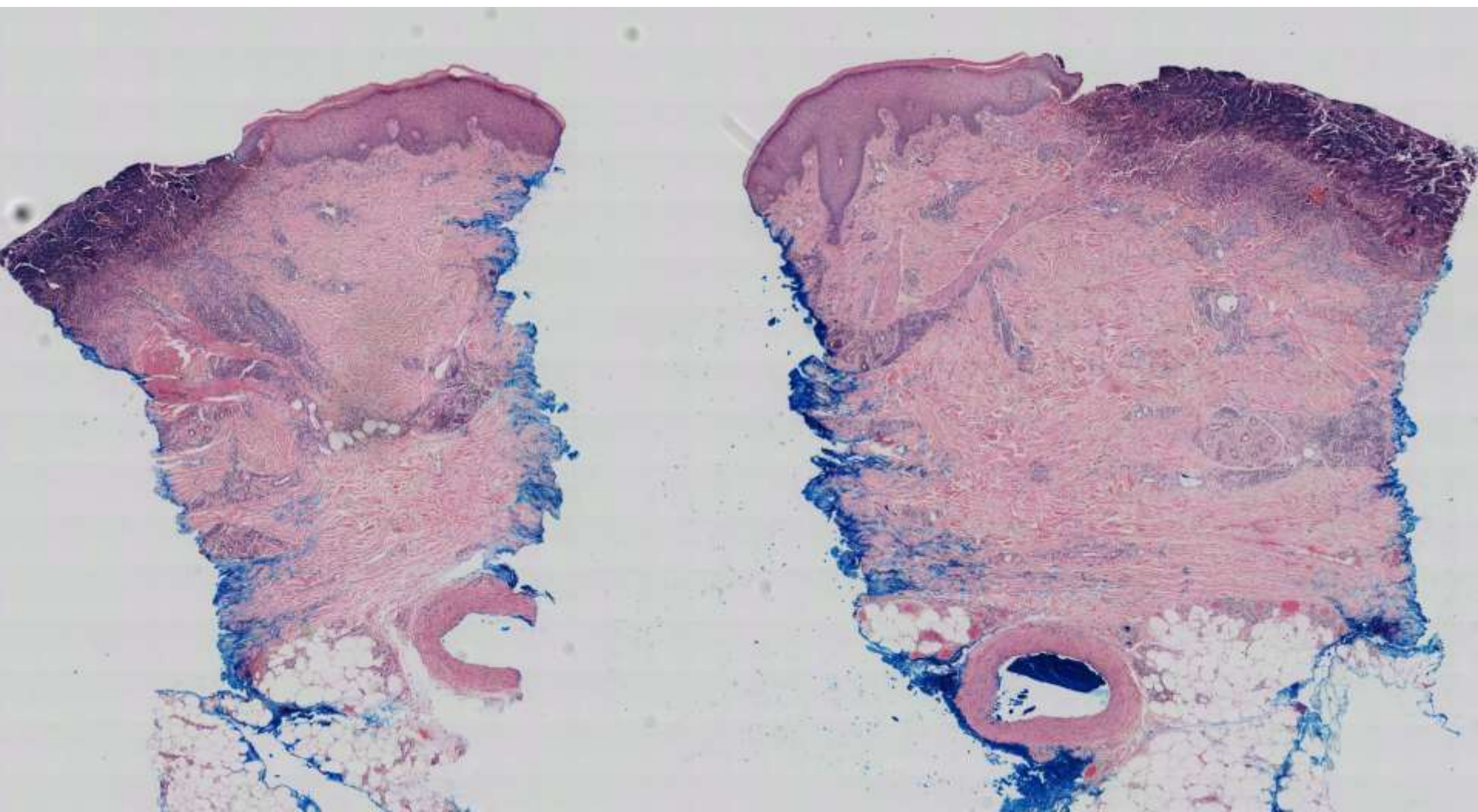


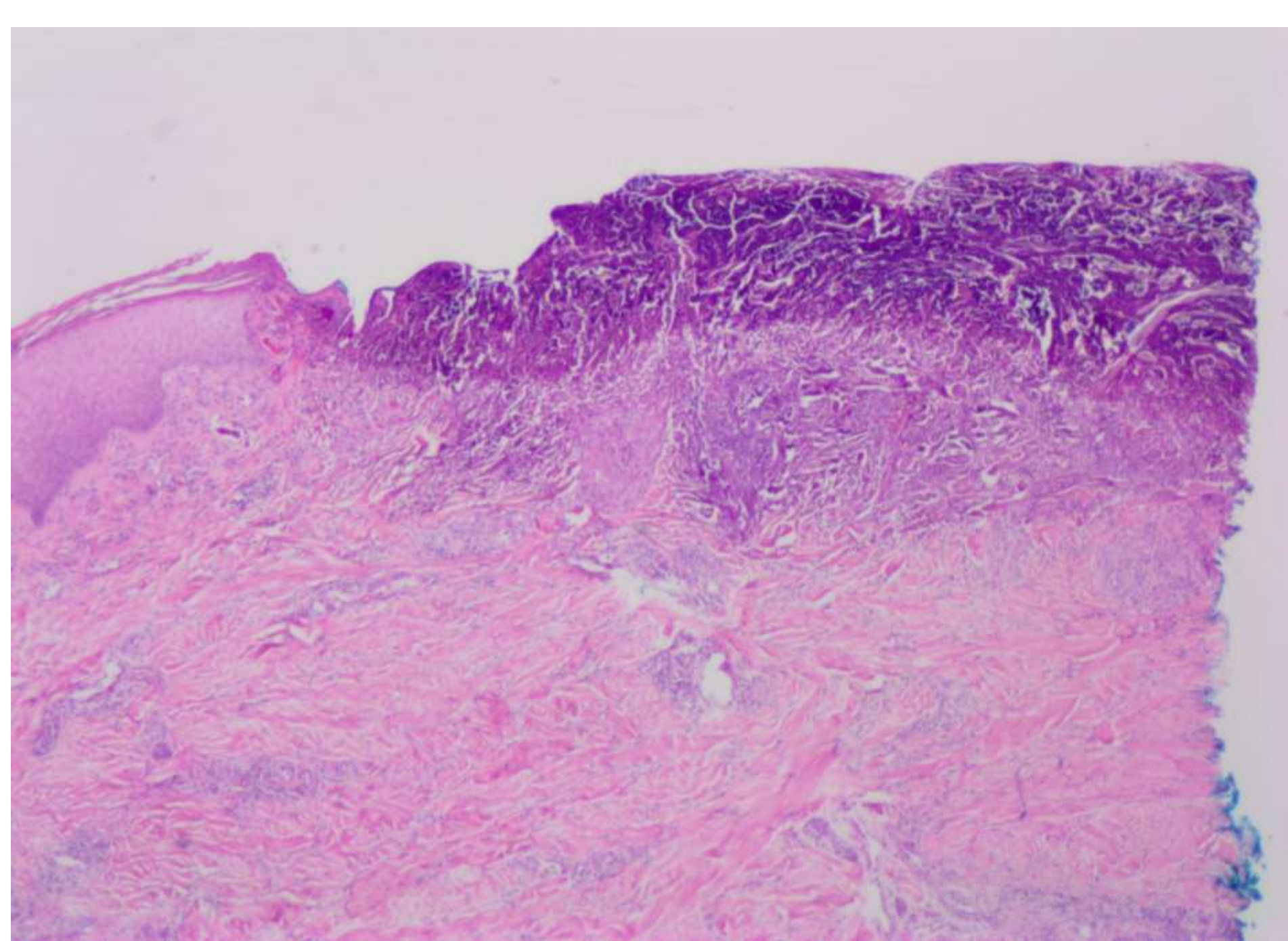


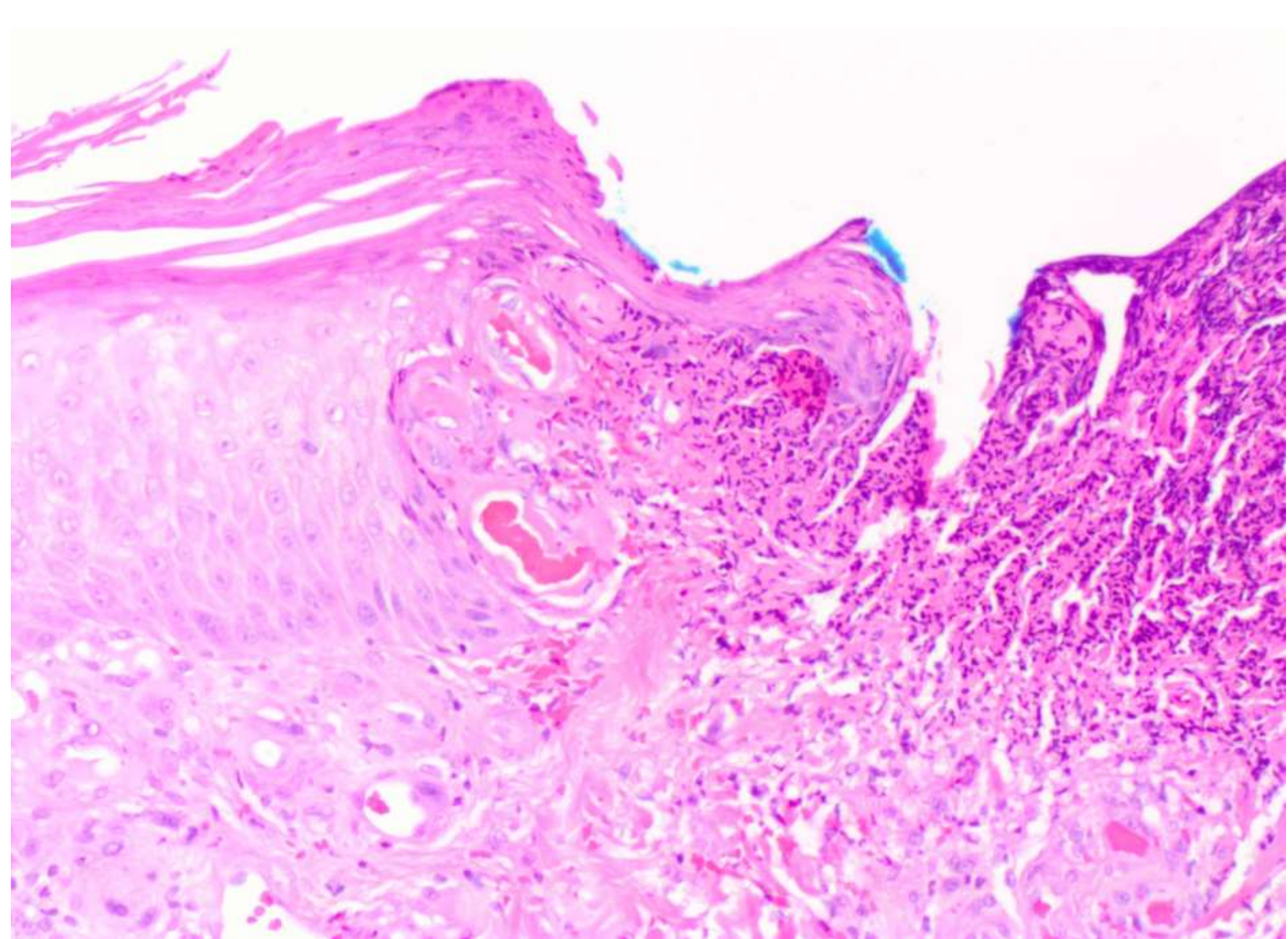
**SB 6196 [scanned slide available]
Mona Wood/Betsy Bailey/Christine
Louie; Palo Alto VA**

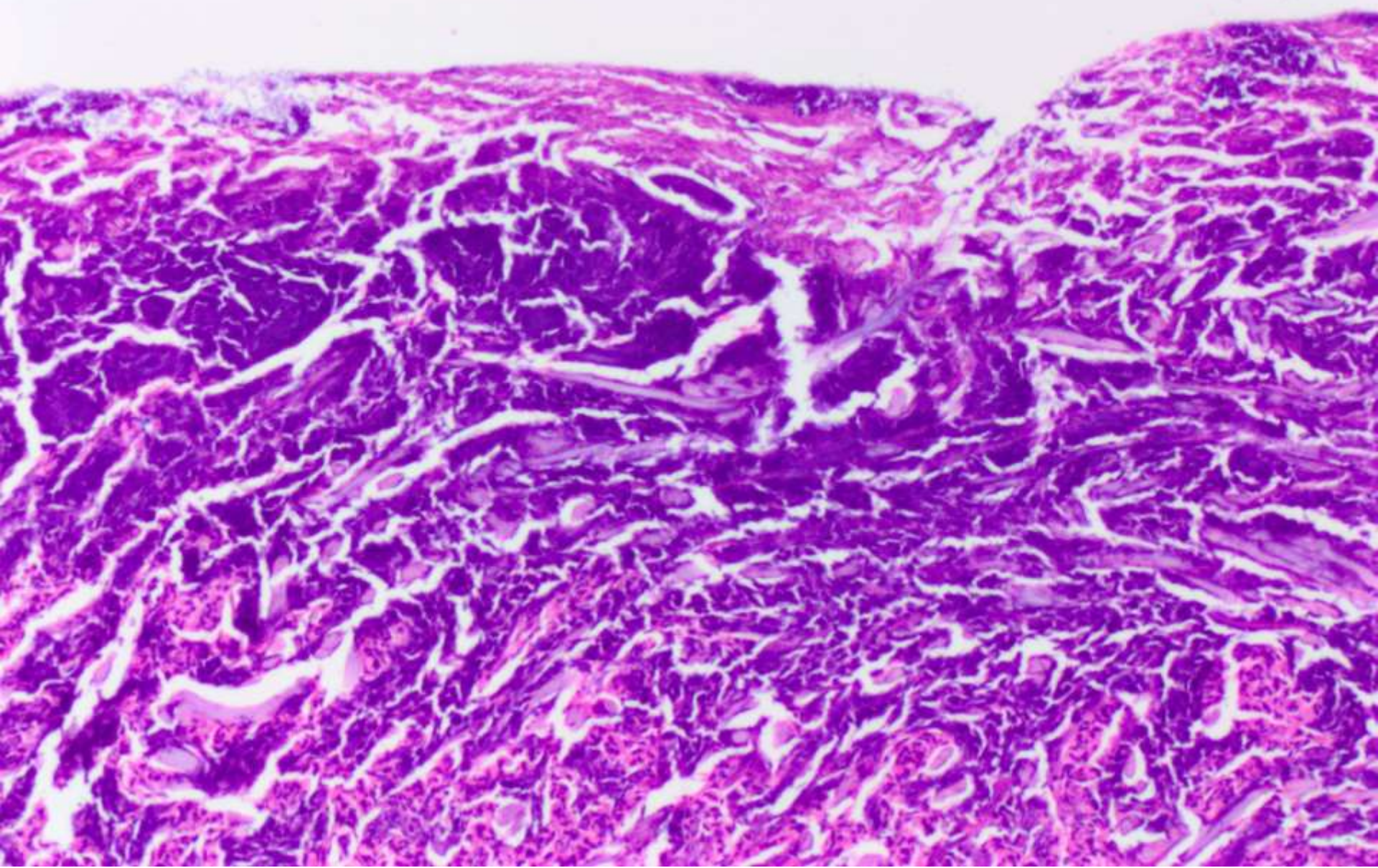
56-year-old male with history of poorly-controlled insulin dependent diabetes with itchy hyperpigmented bumps on legs, present for last 5 years.

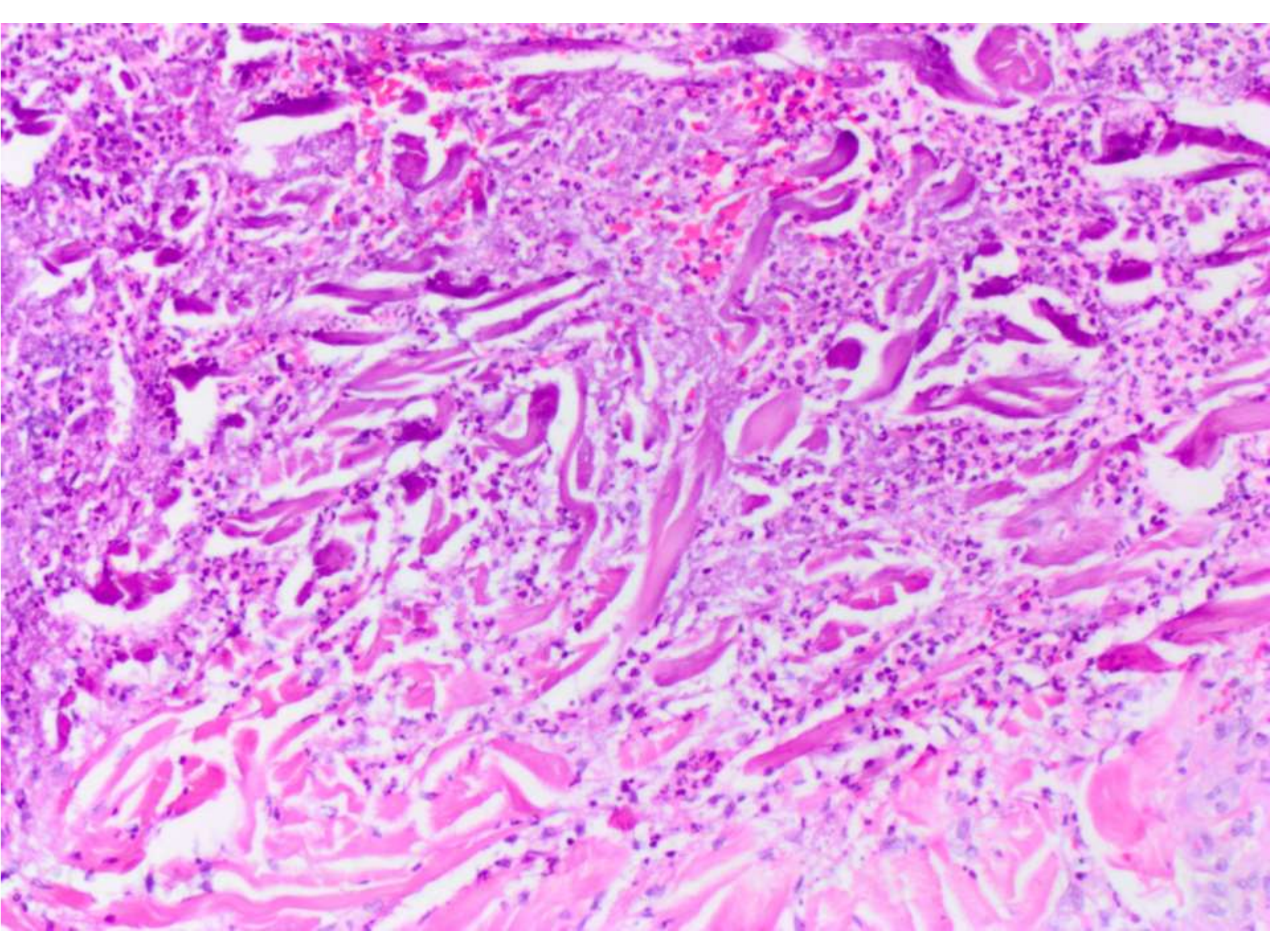






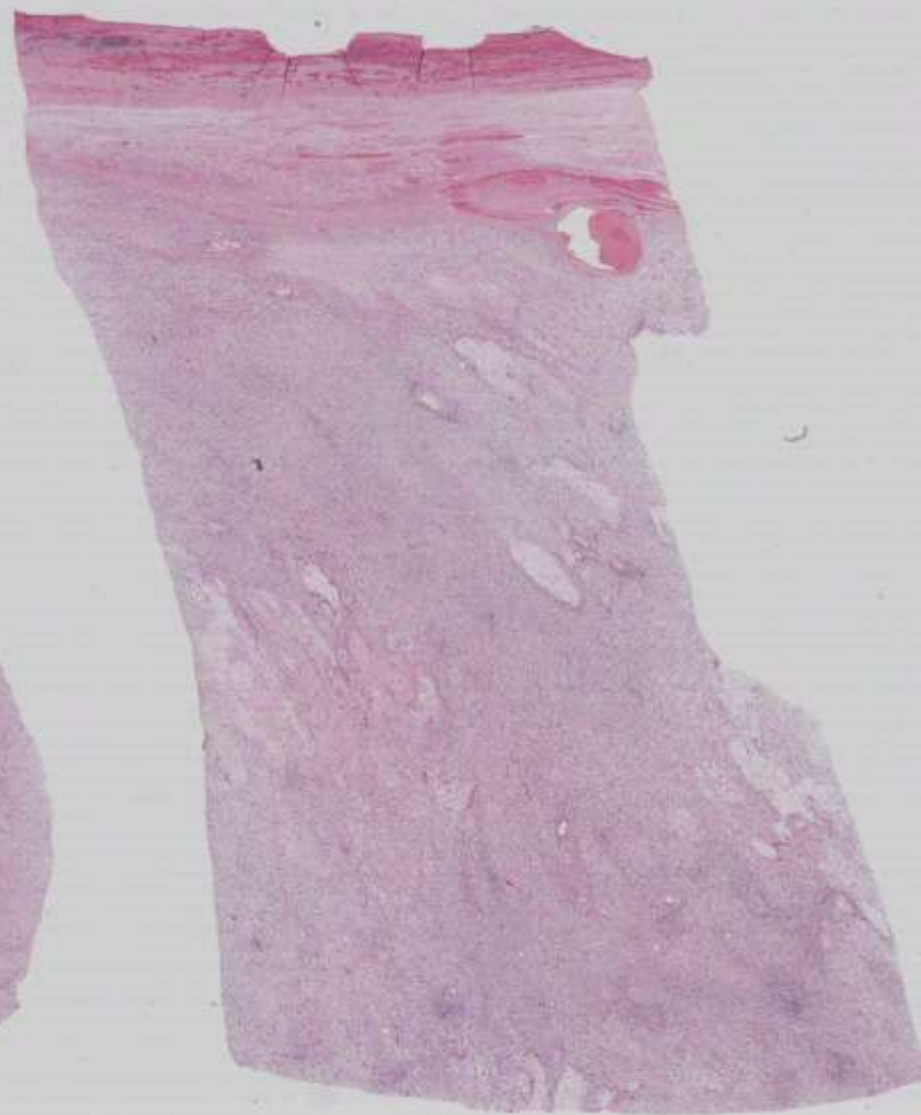
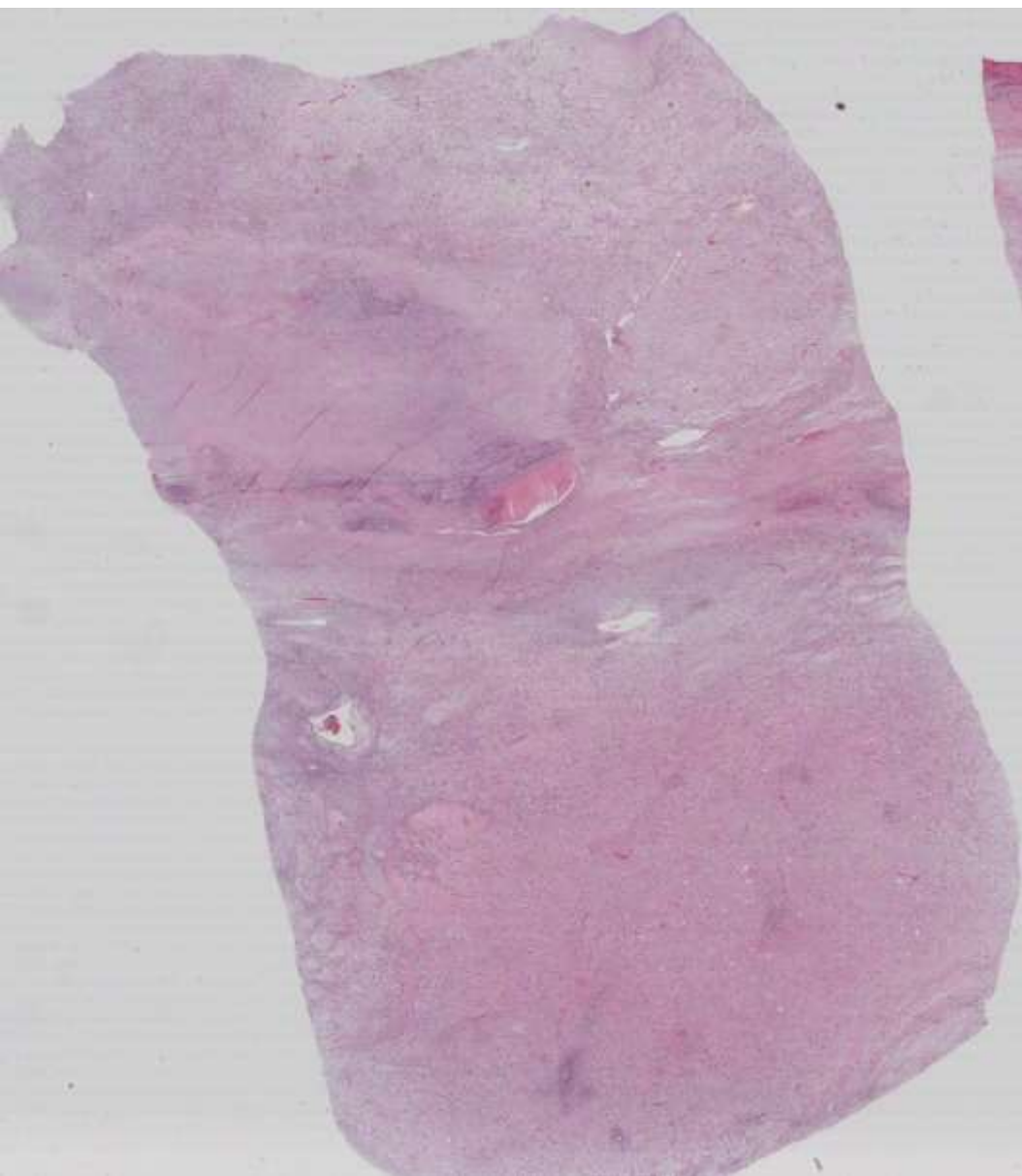


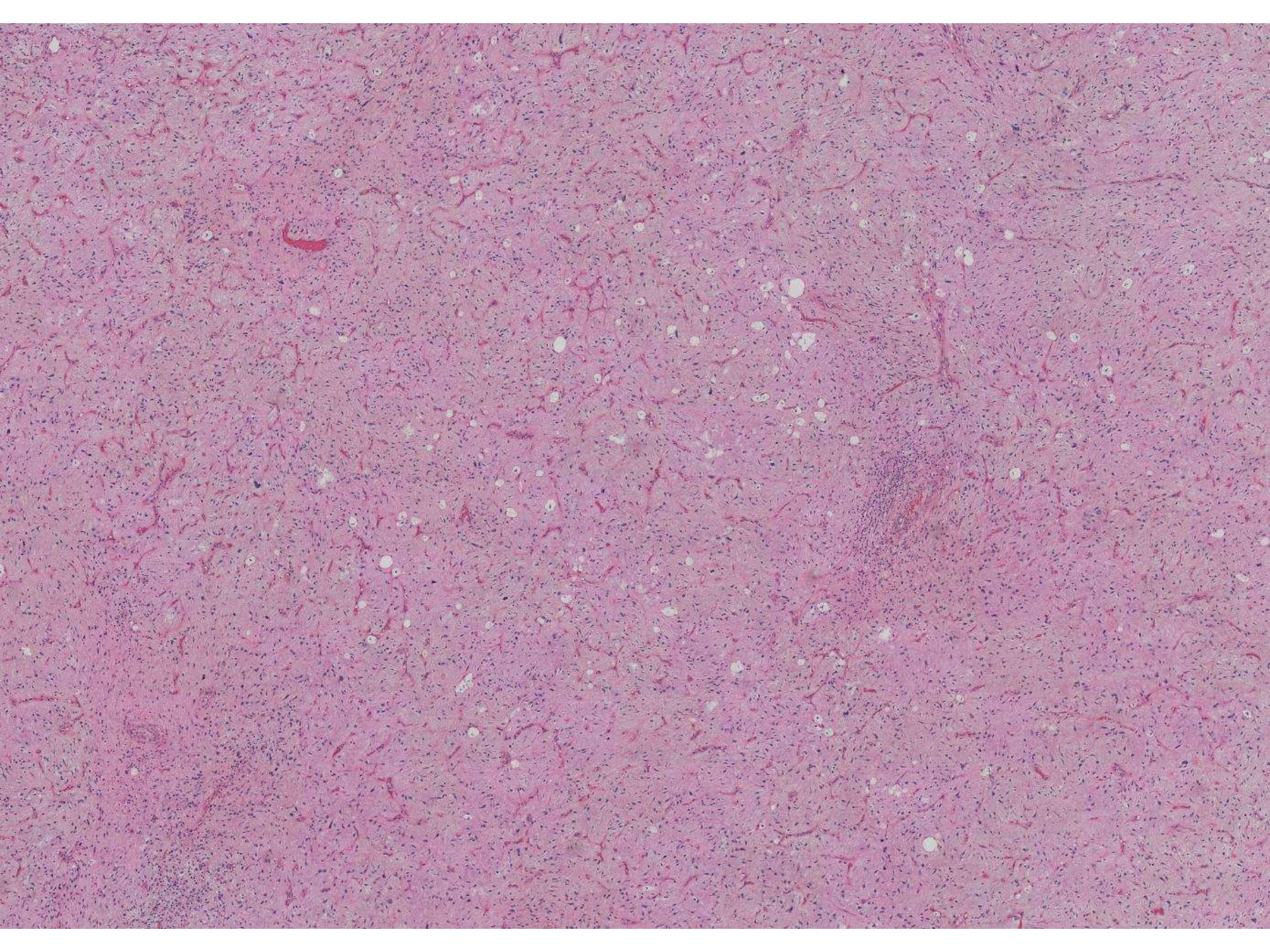


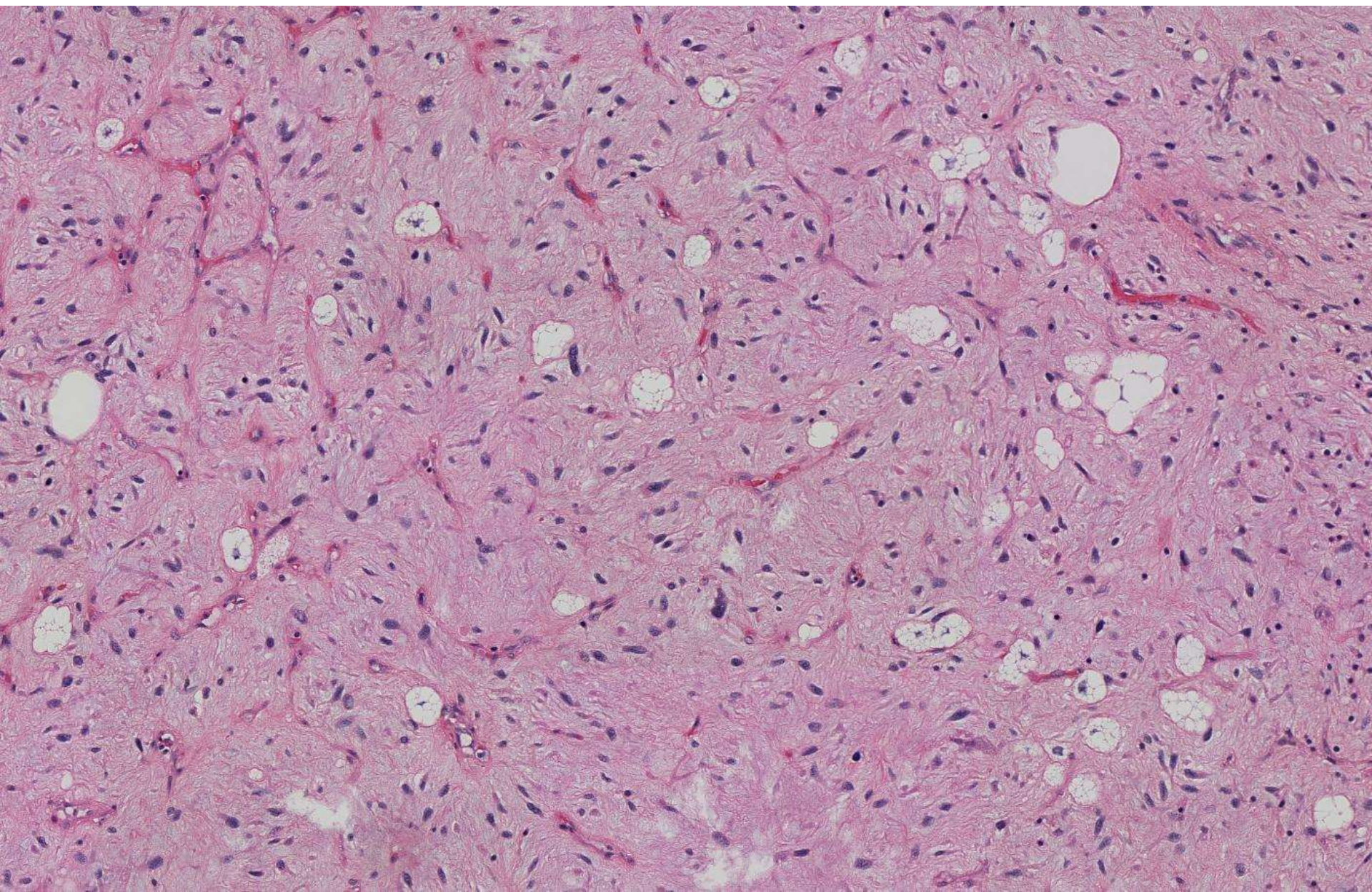


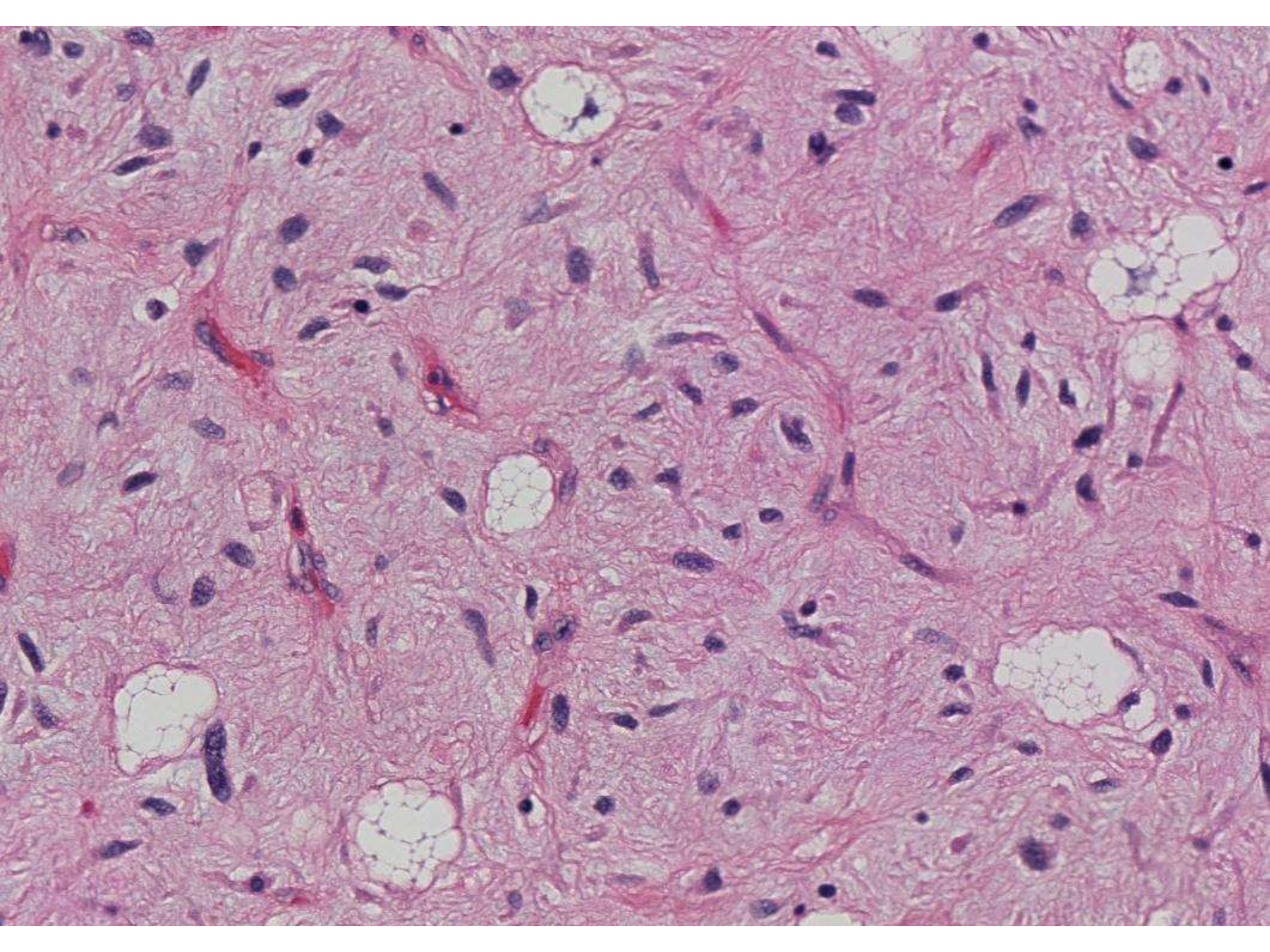
**SB 6197 [scanned slide available]
John Cannatella/Ben Buelow; USCF**

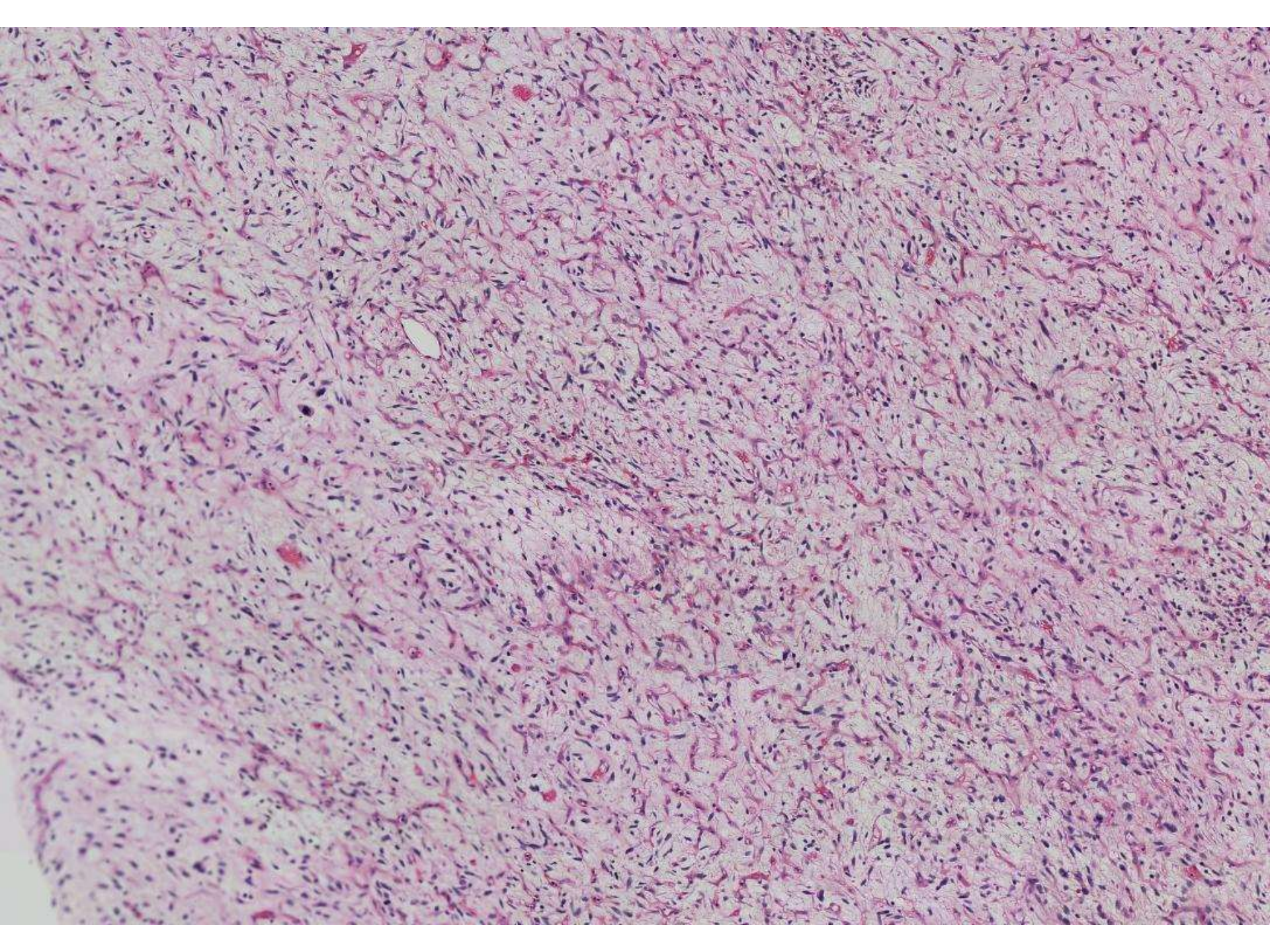
80-year-old man with
retroperitoneal/abdominal mass.

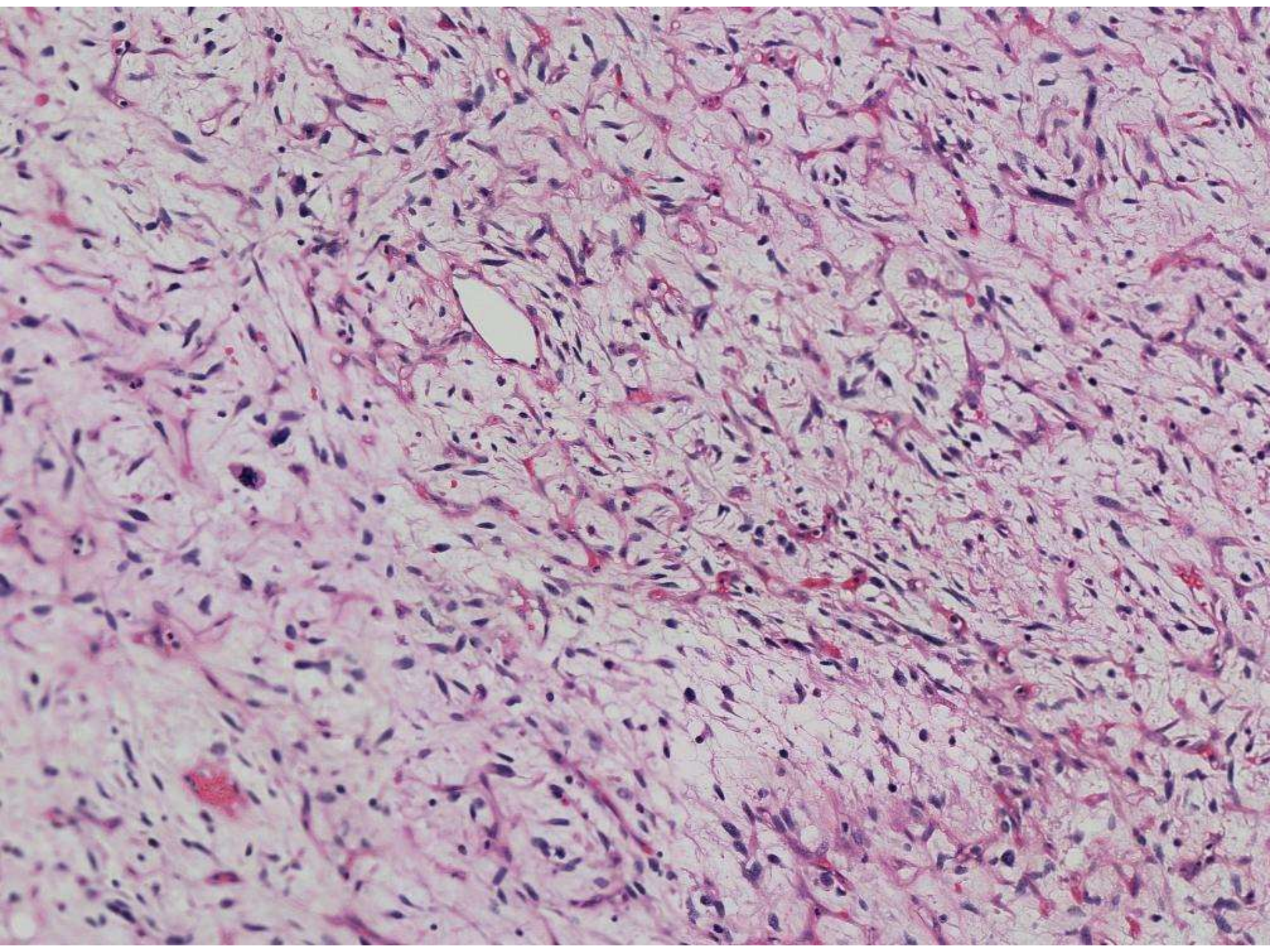


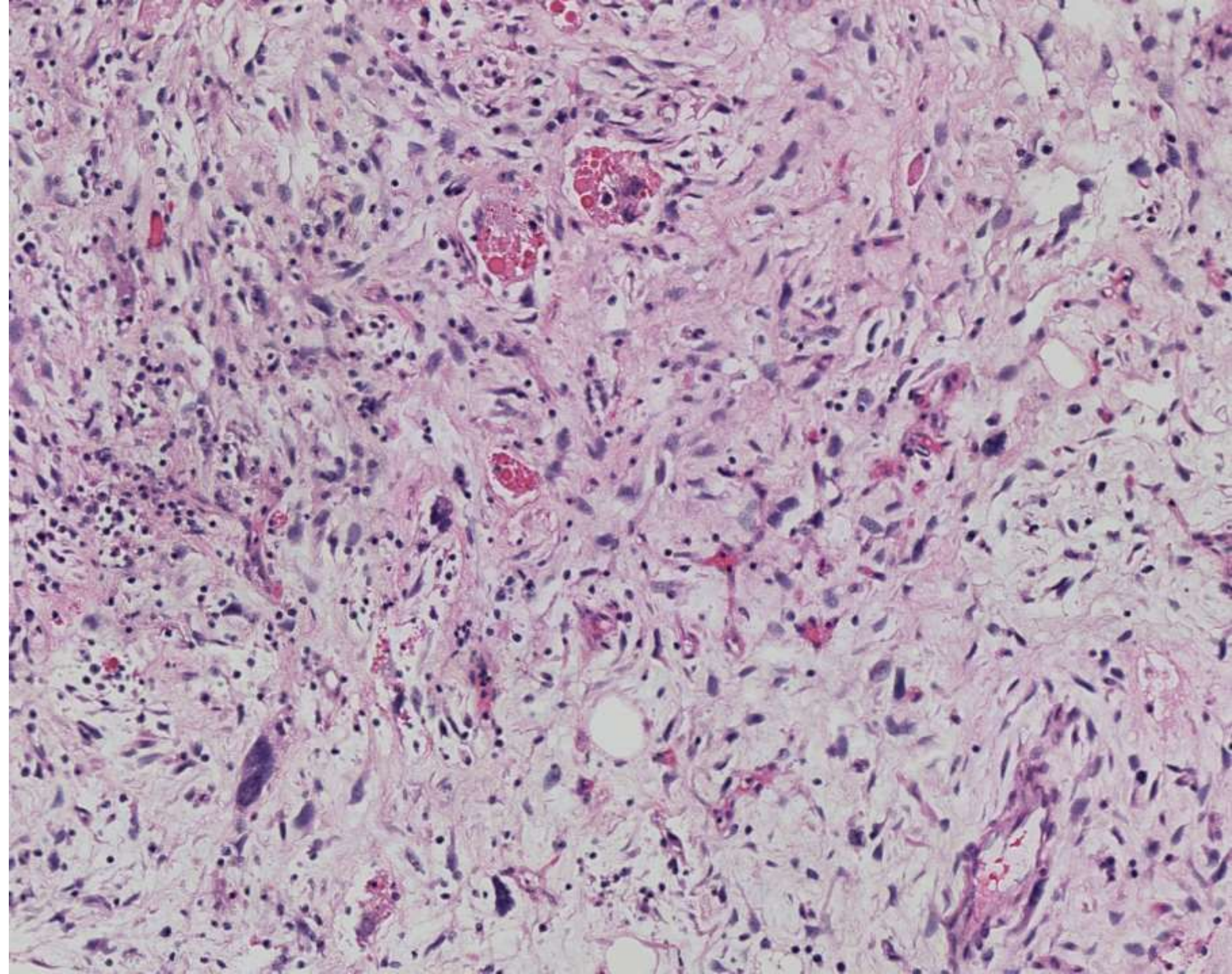


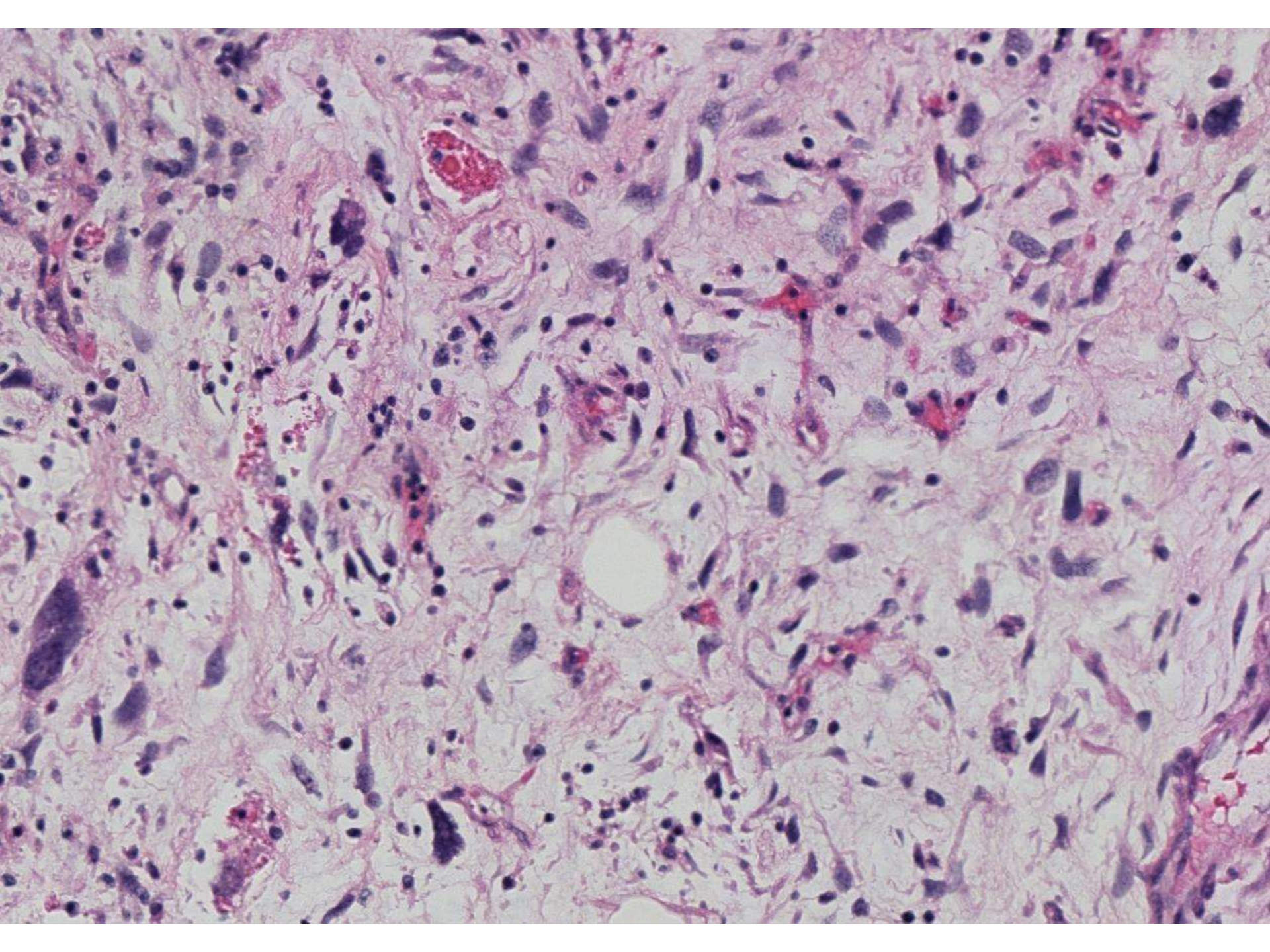






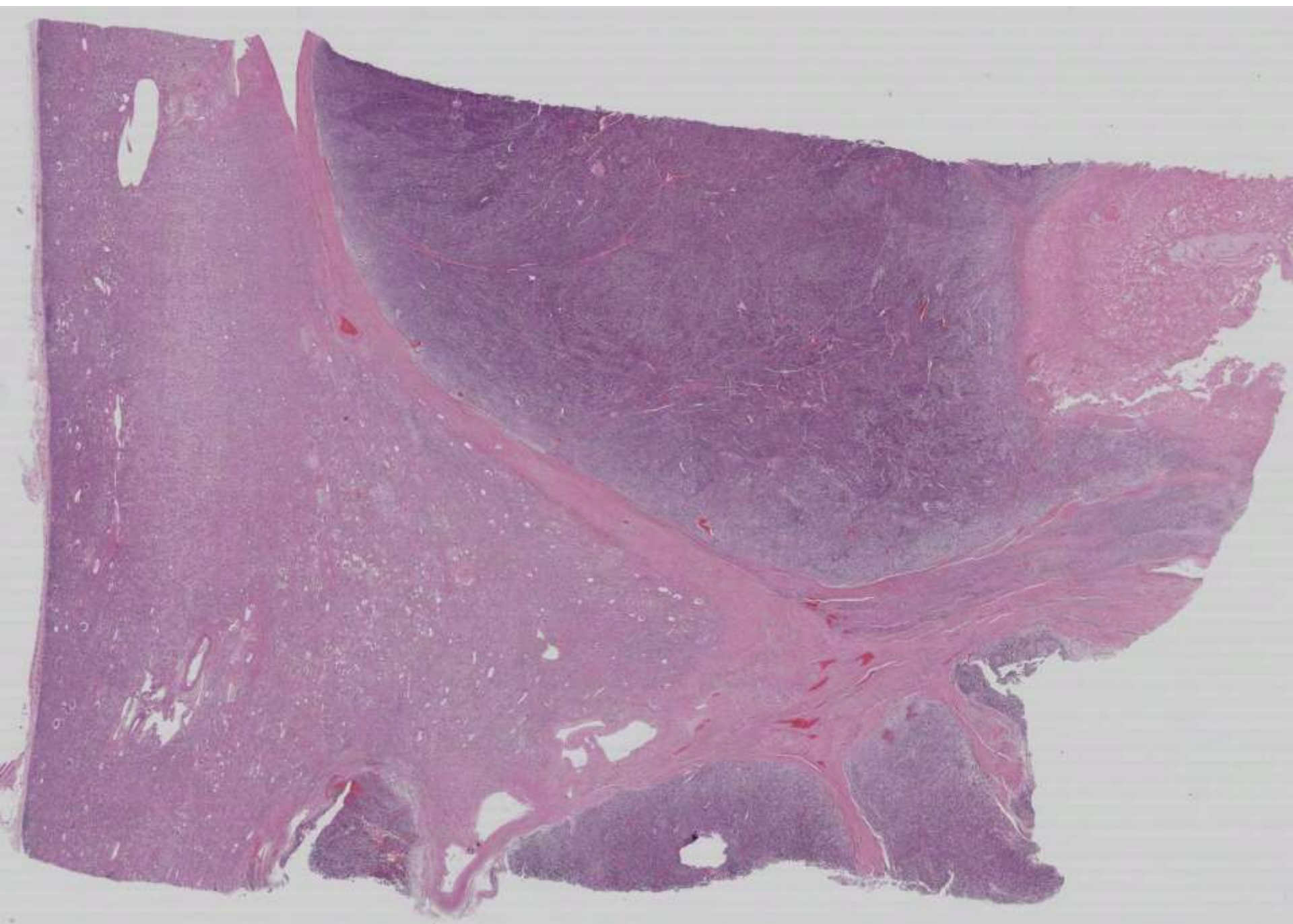


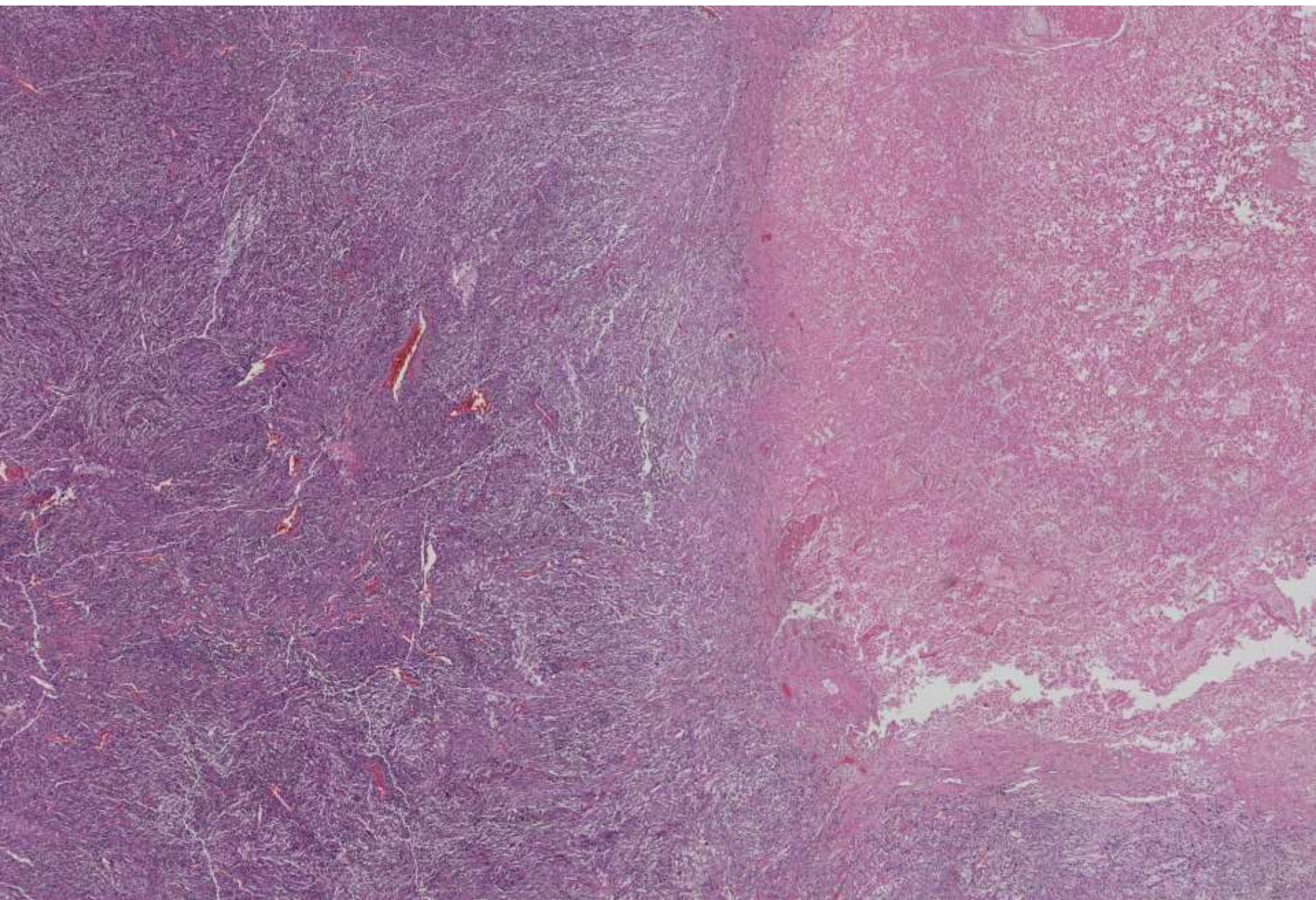


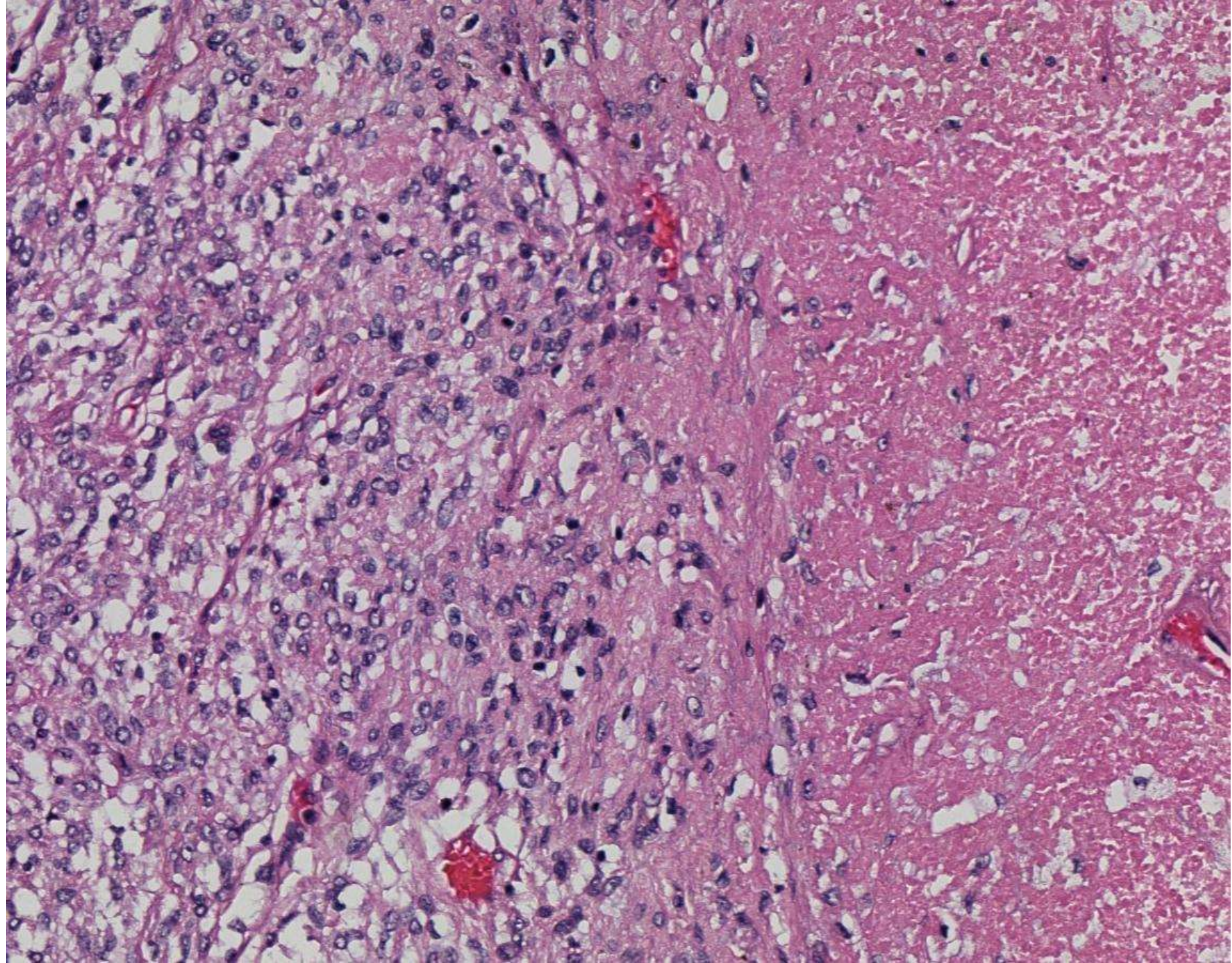


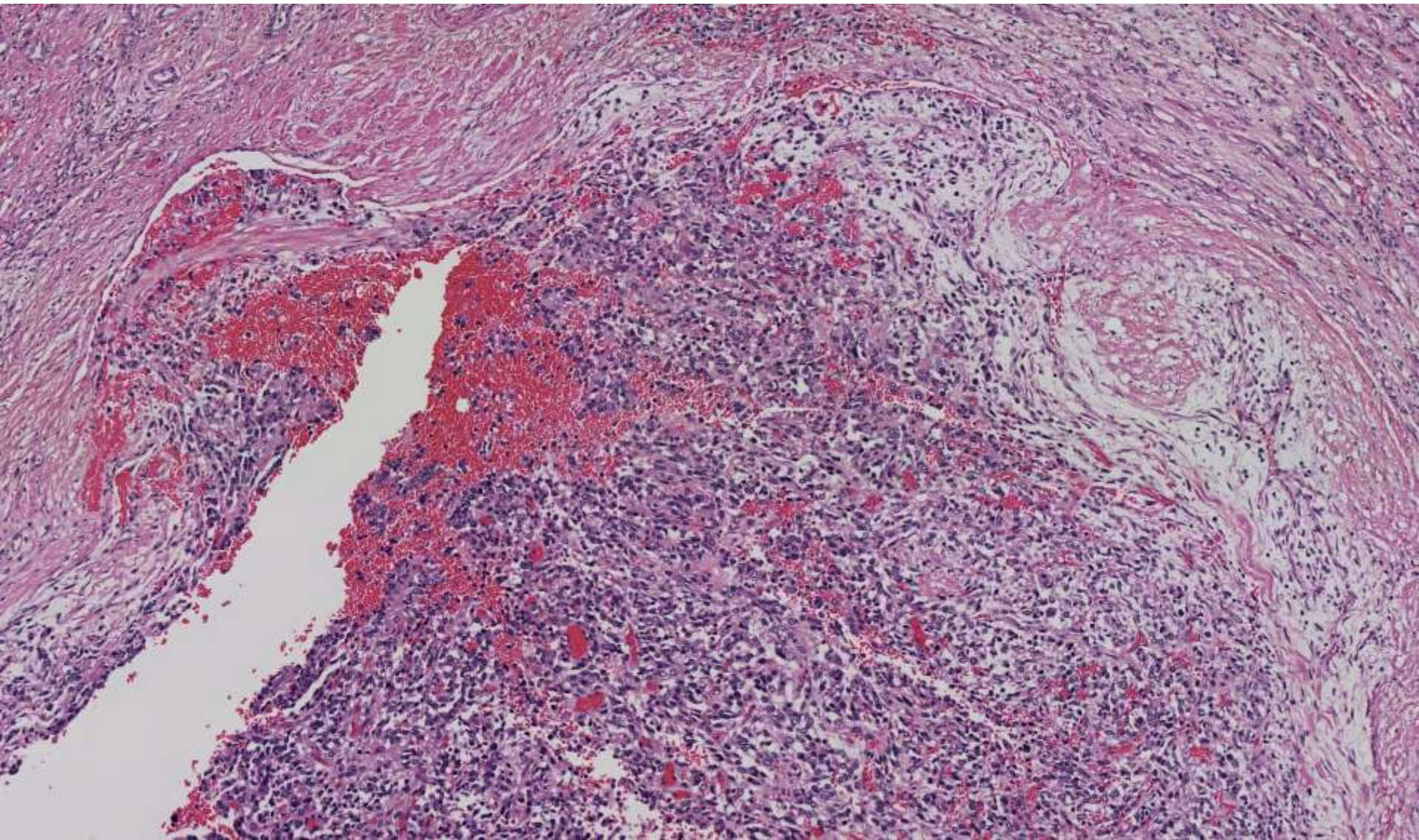
SB 6198 [scanned slide available]
Emily Chan/Jeff Simko; UCSF

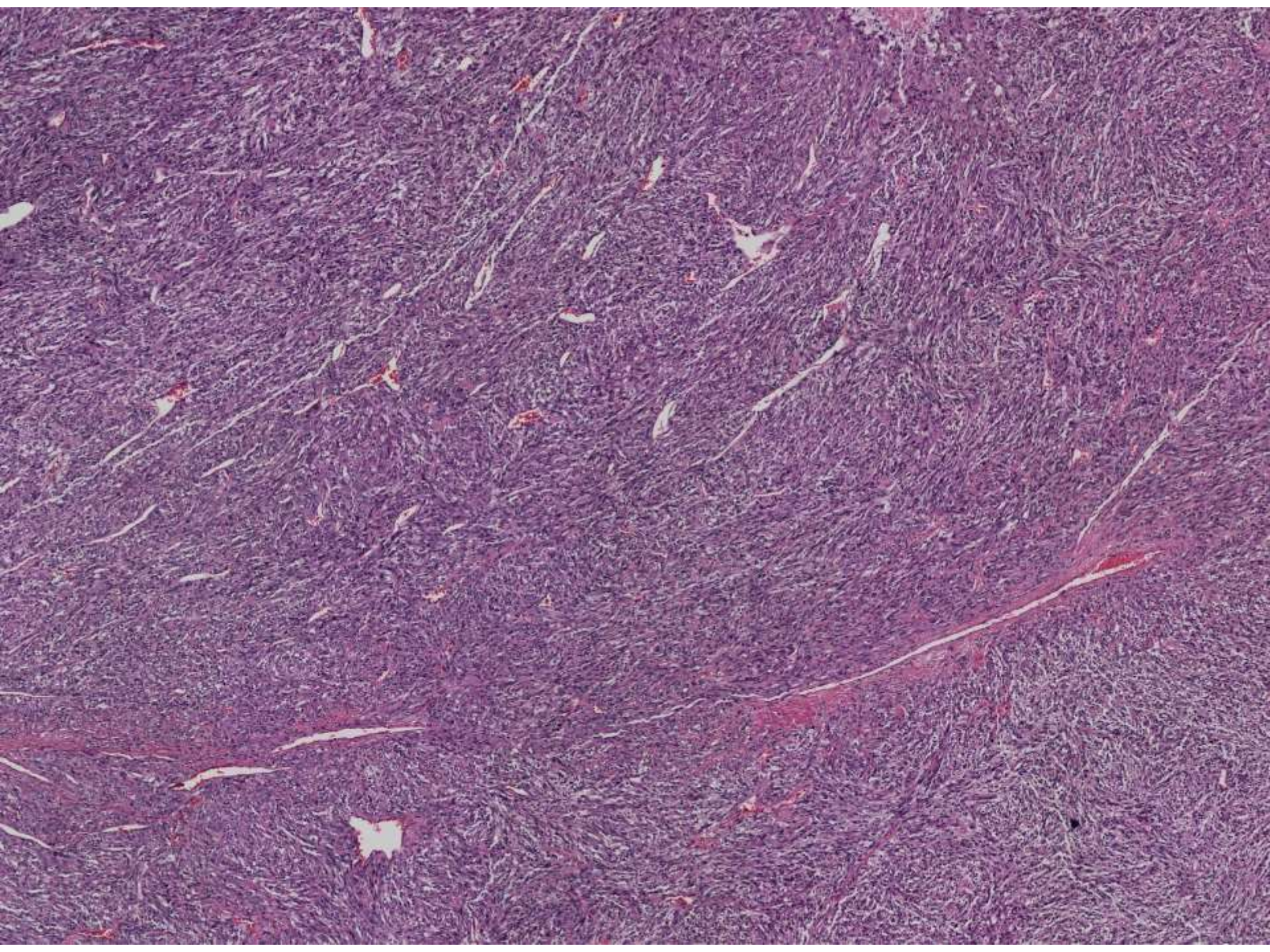
51-year-old man with 18cm renal mass.

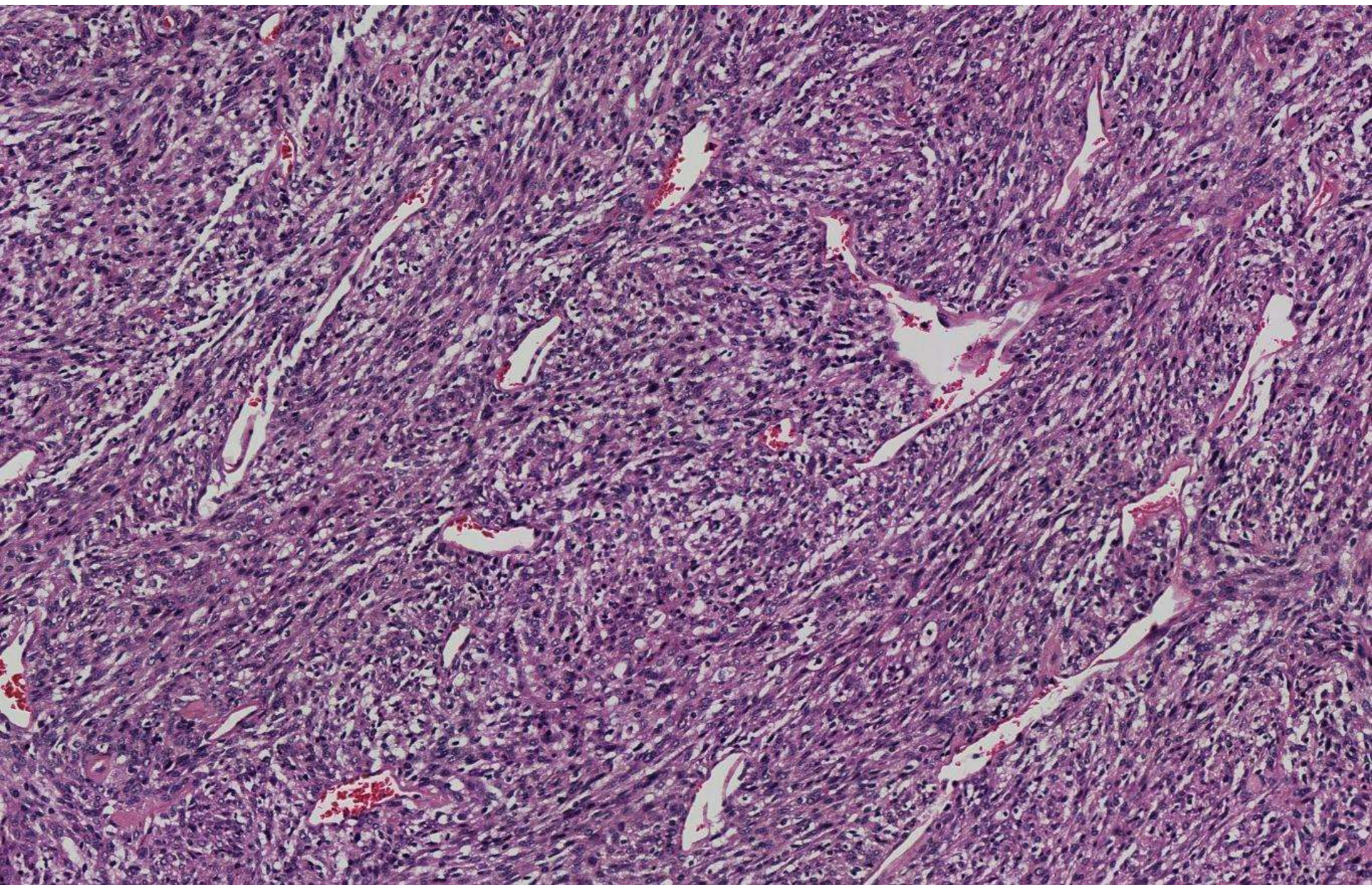


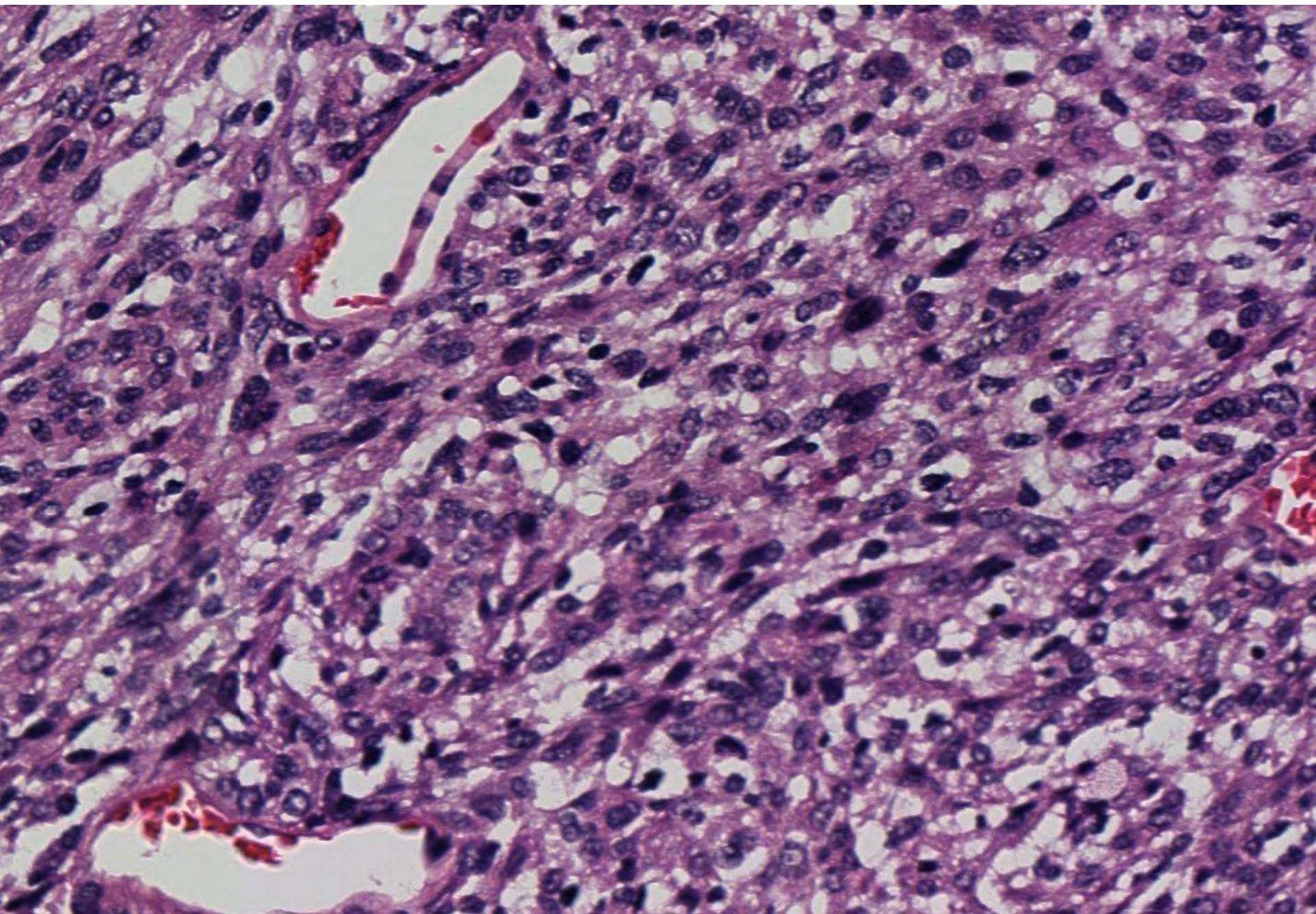


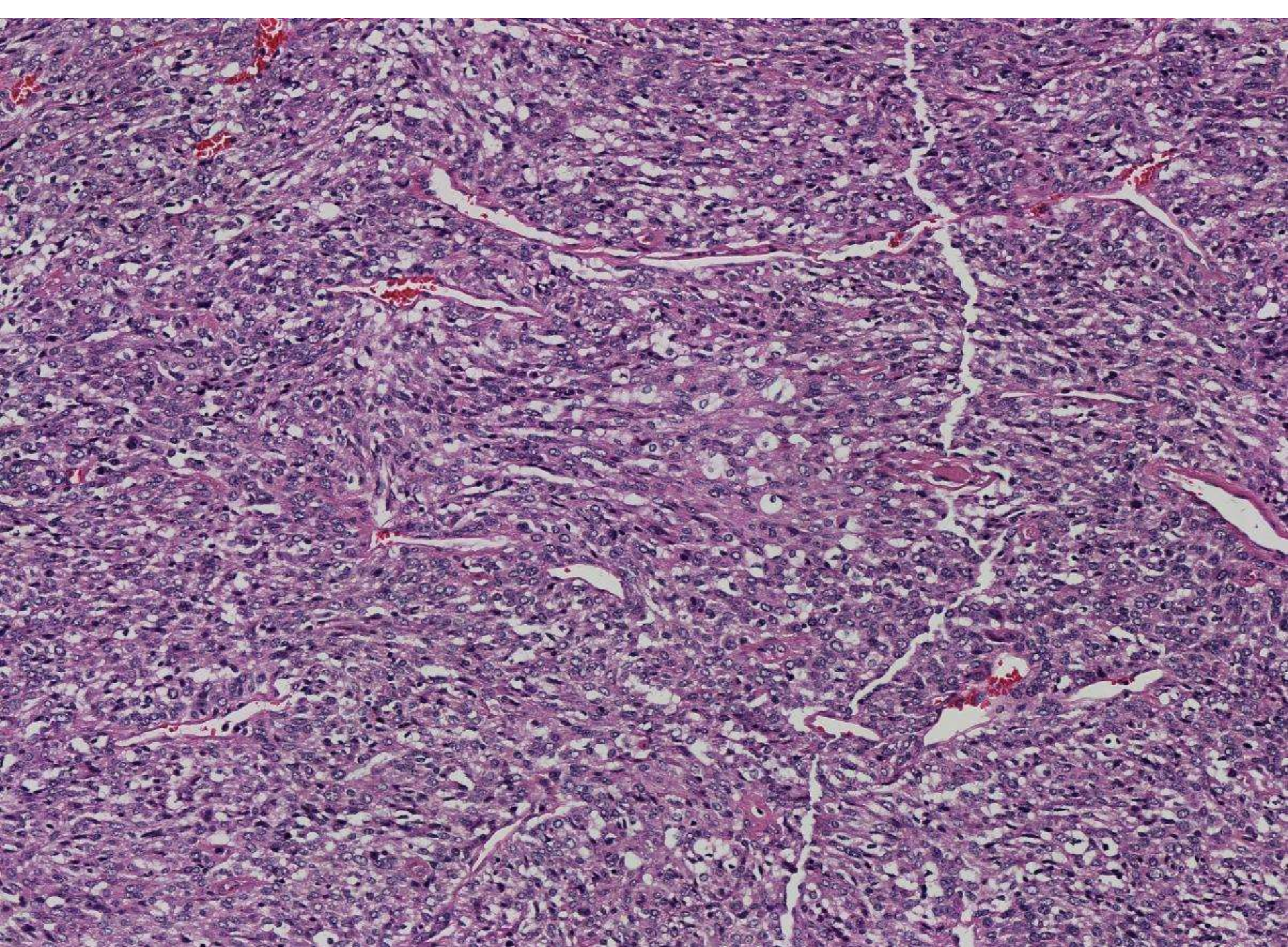


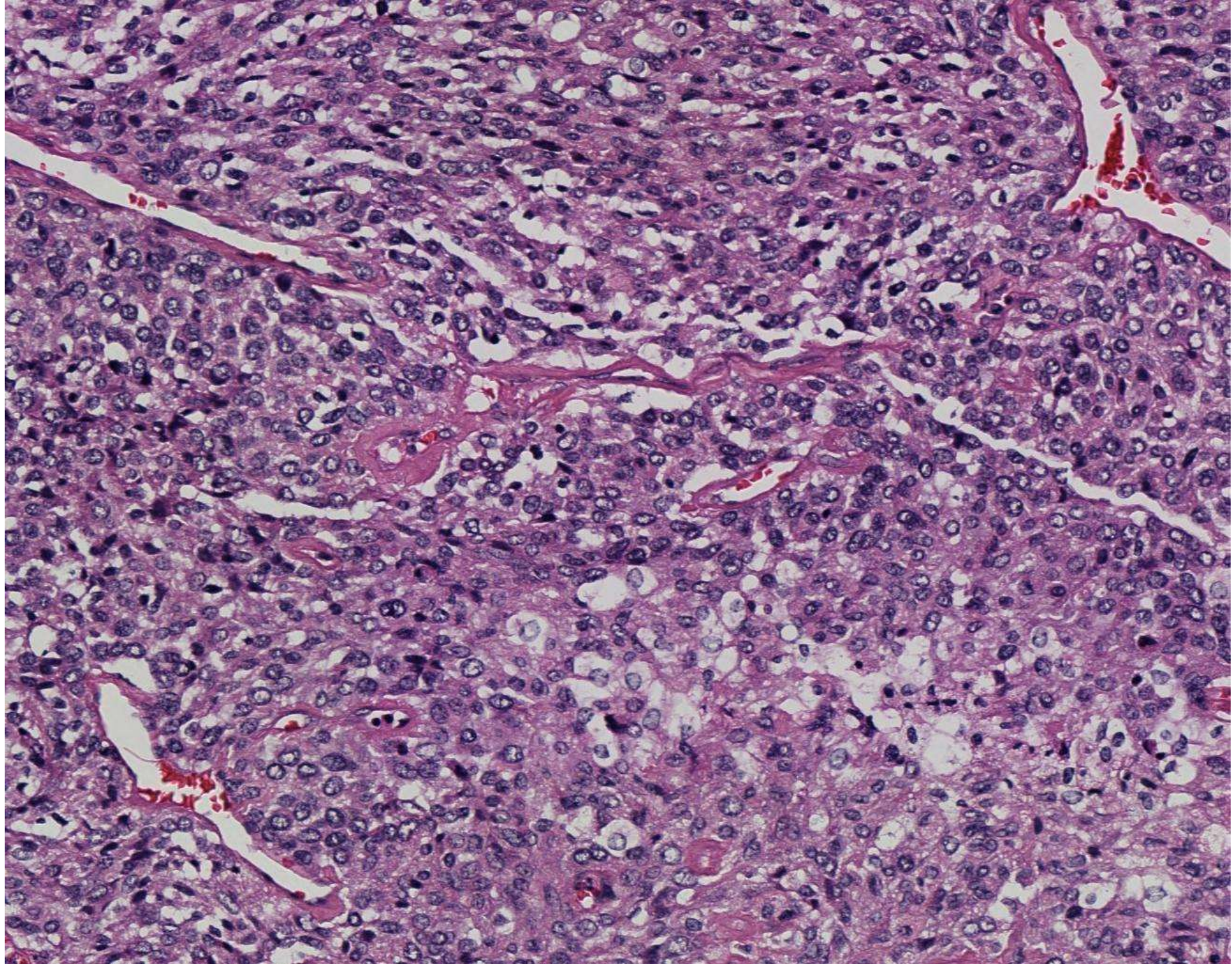










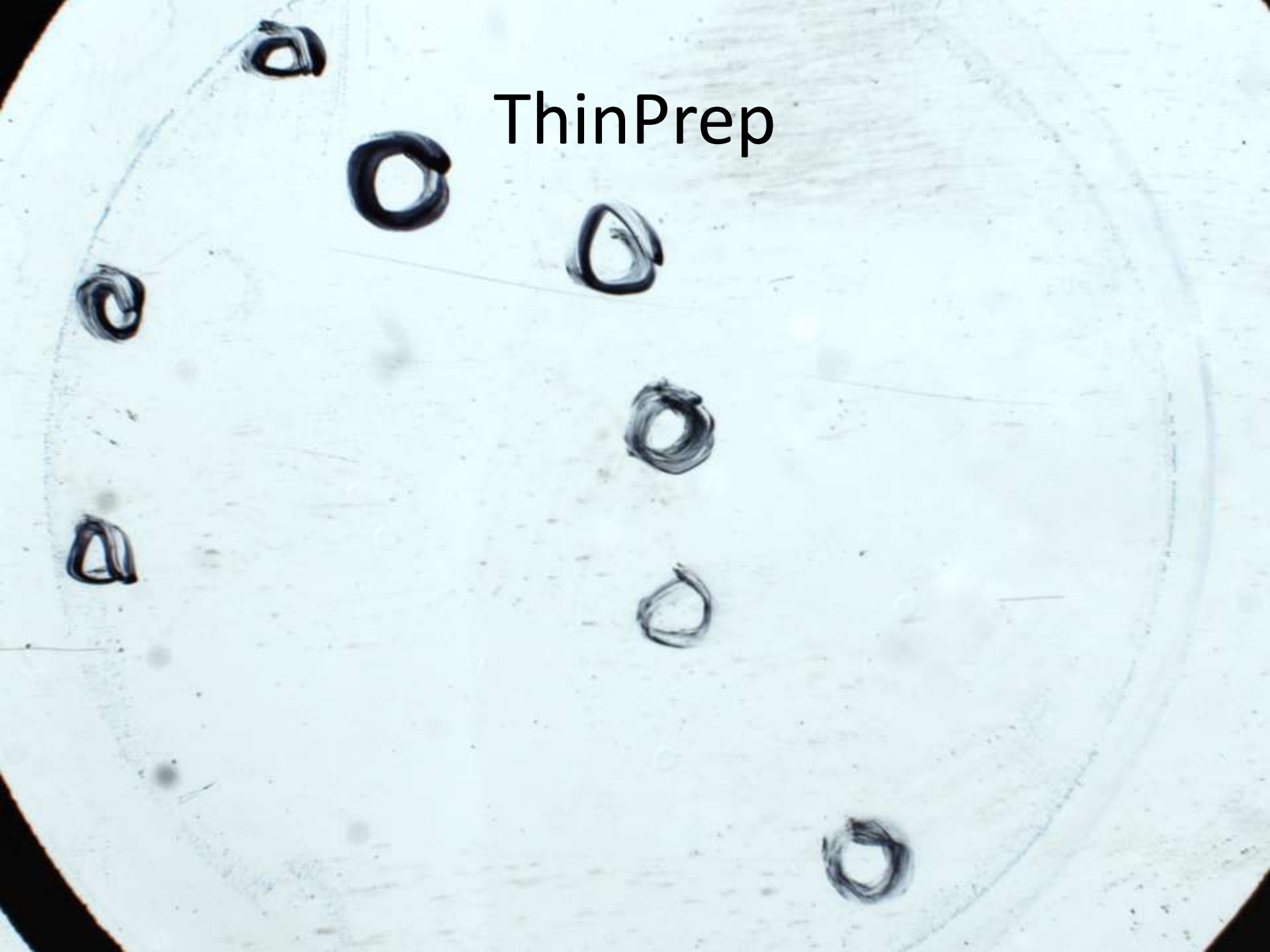

SB 6199

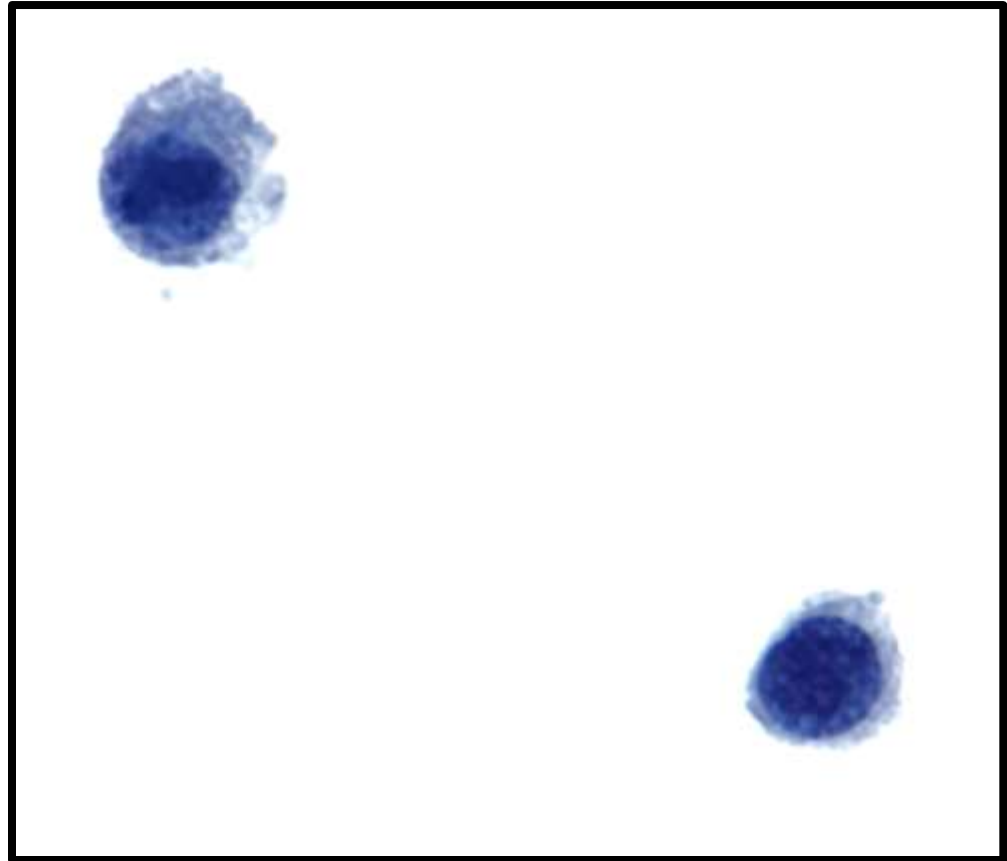
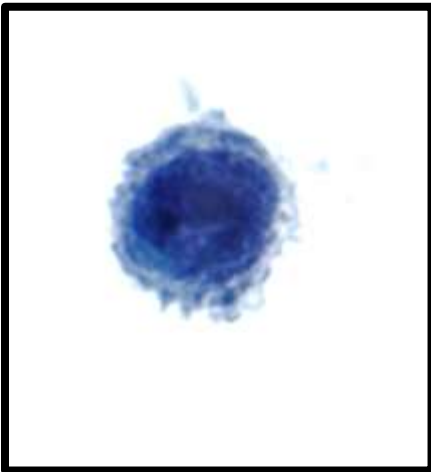
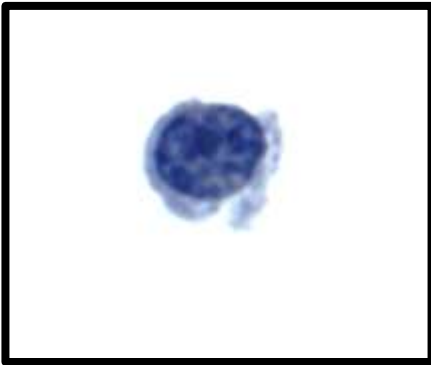
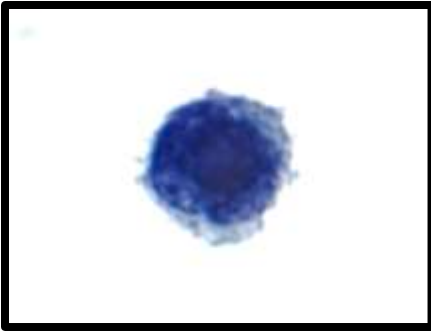
**Alana Shain/Yaso Natkunam;
Washington Hospital/Stanford**

60-year-old woman with h/o invasive lobular carcinoma s/p mastectomy in 2010. Now with left breast swelling and abnormal MRI. Left breast cyst fluid submitted.

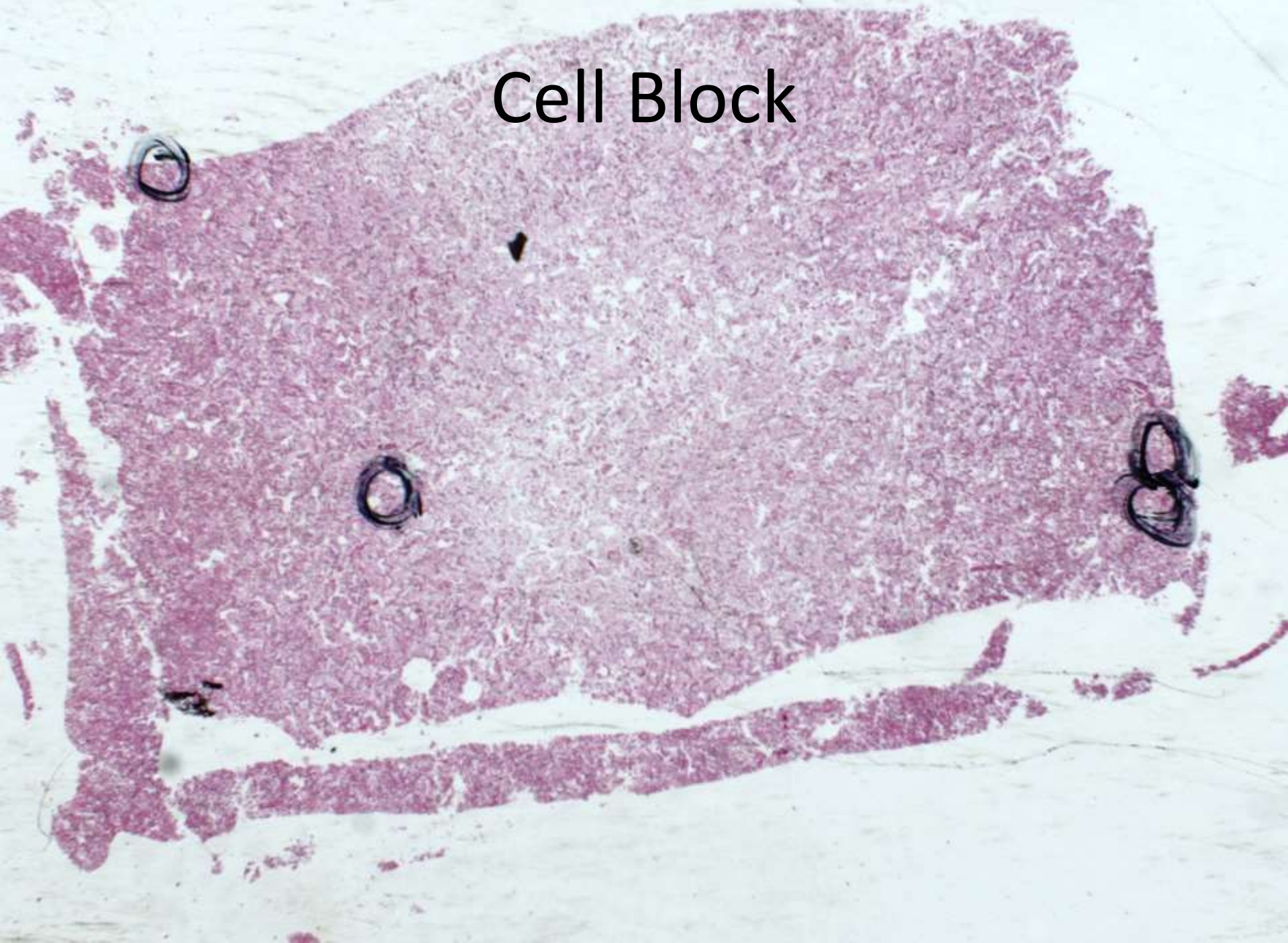
ThinPrep



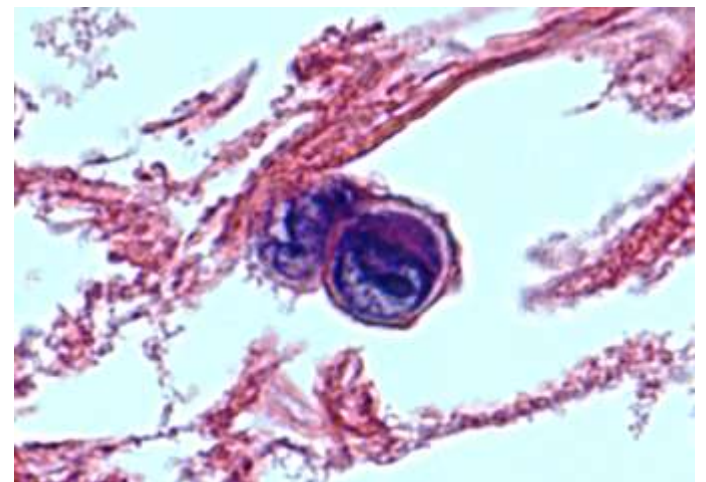
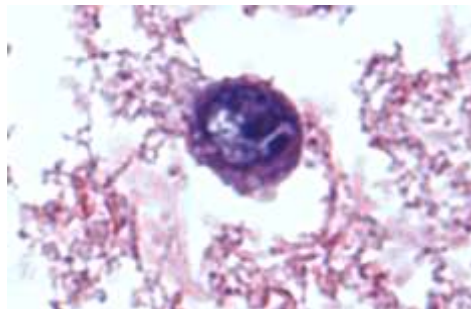
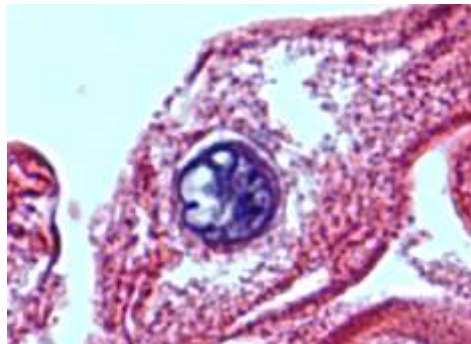
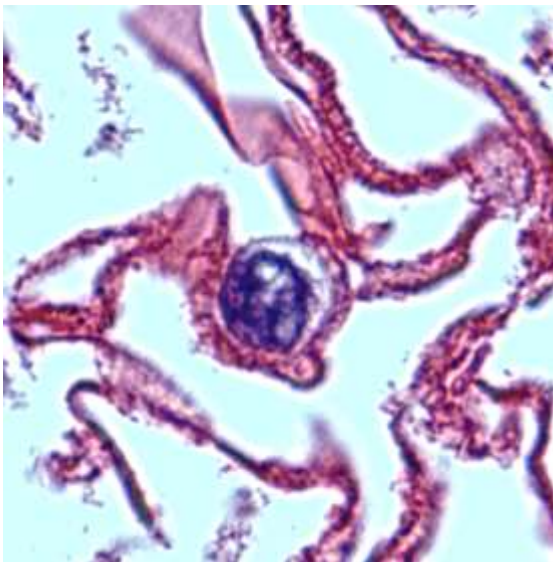
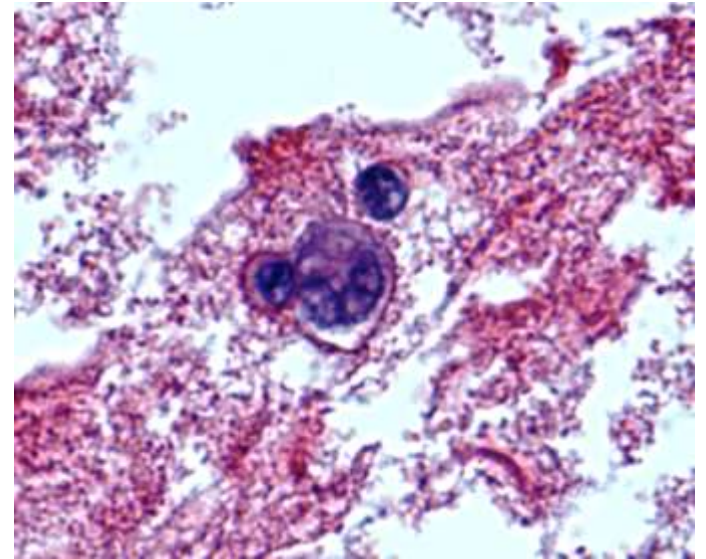
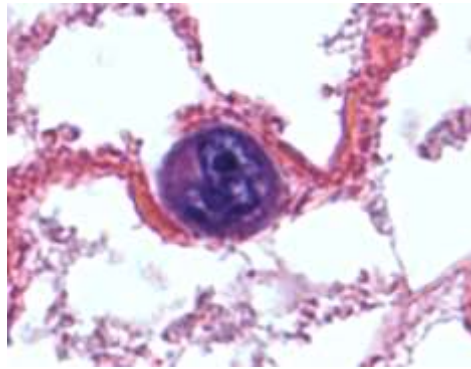
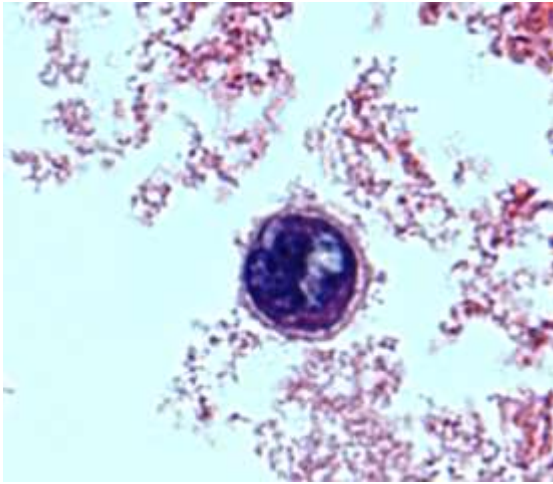
ThinPrep (60X)



Cell Block



Cell Block (60X)



SB 6200 [scanned slide available]
John Moretto; CPMC

Irregular/spiculated right upper lobe
20x17cm pulmonary nodule as well as
similar nodule in apex of left upper lobe,
increased from prior studies.

