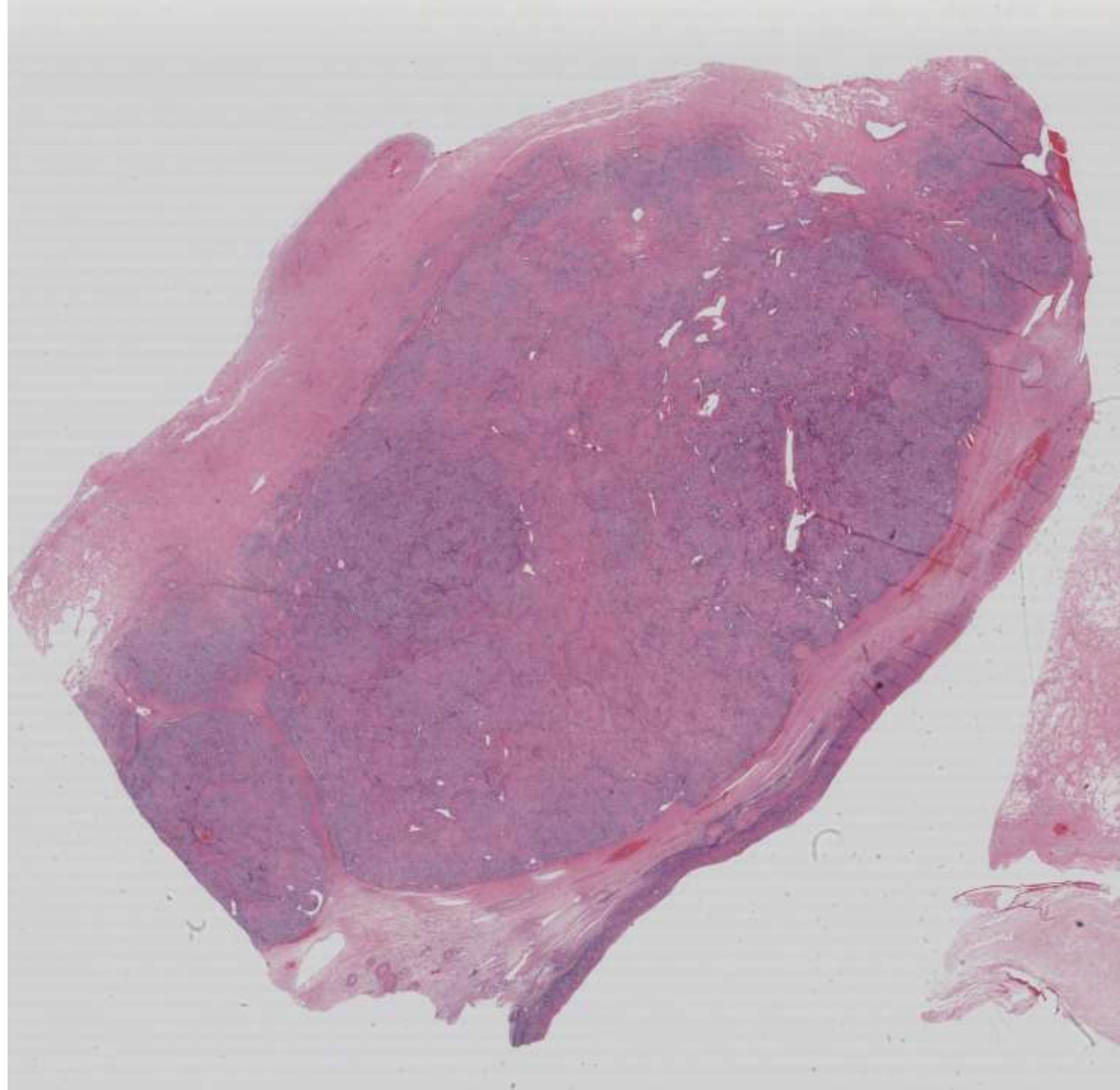
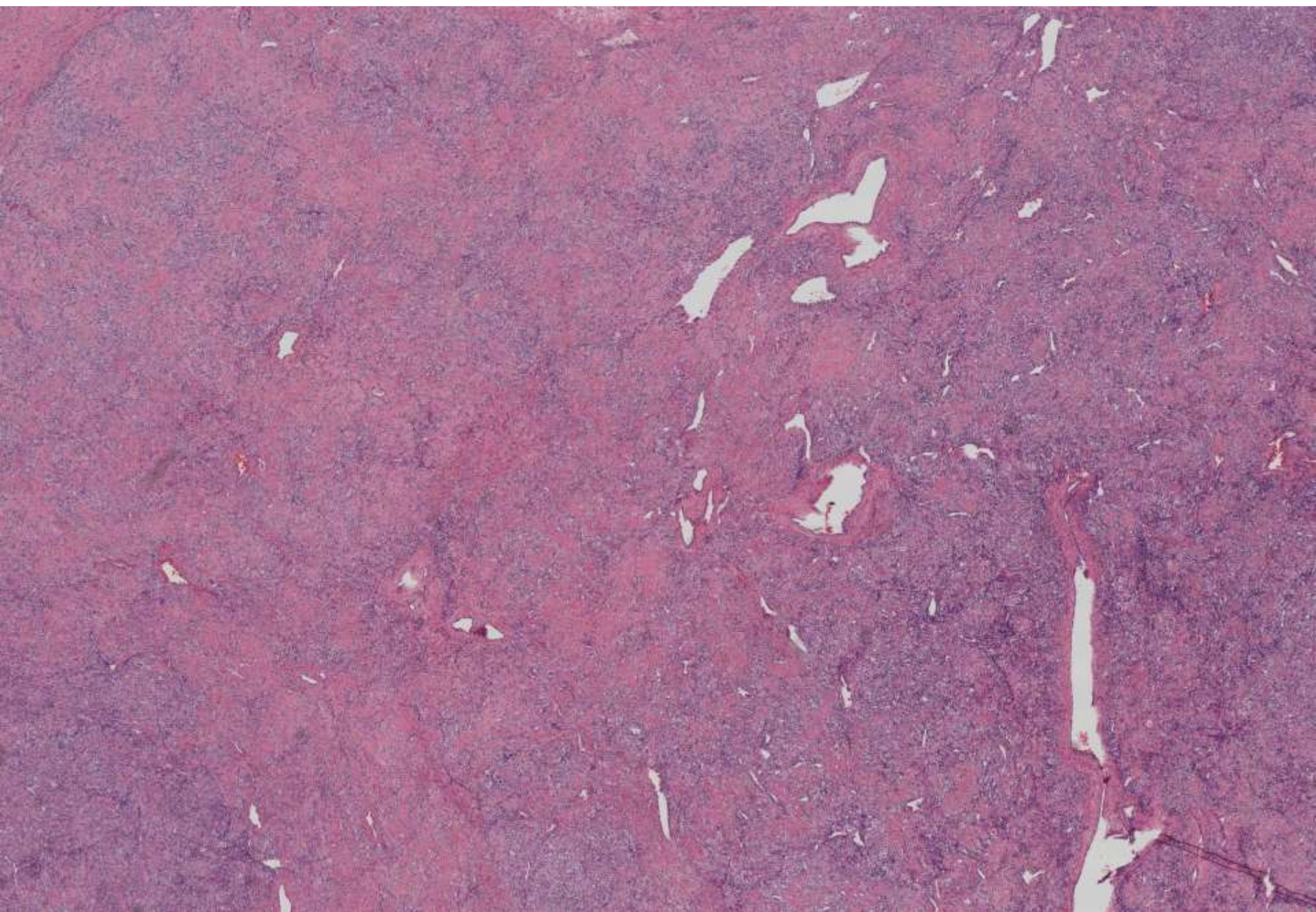


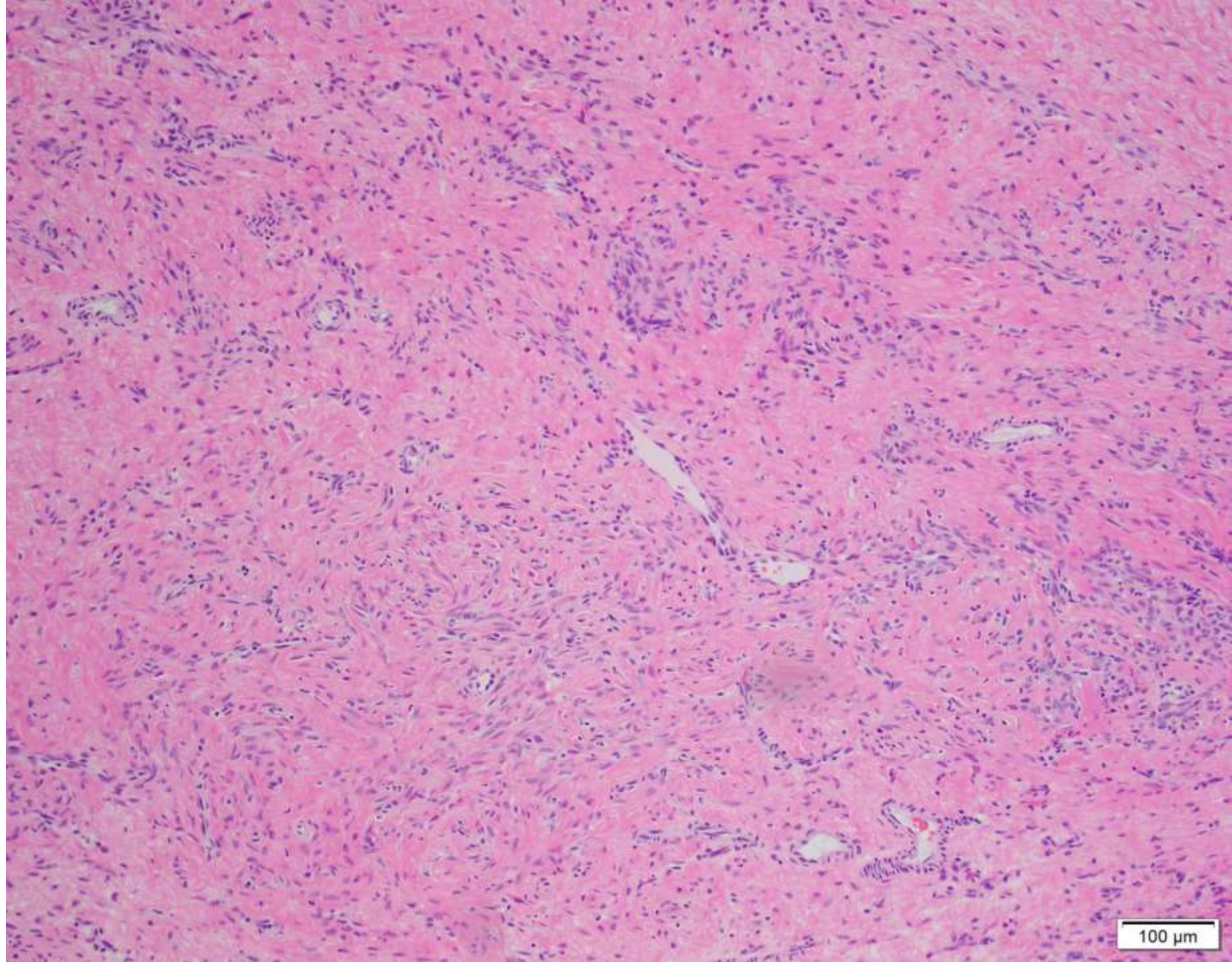
SB 6181

(scanned slide available)

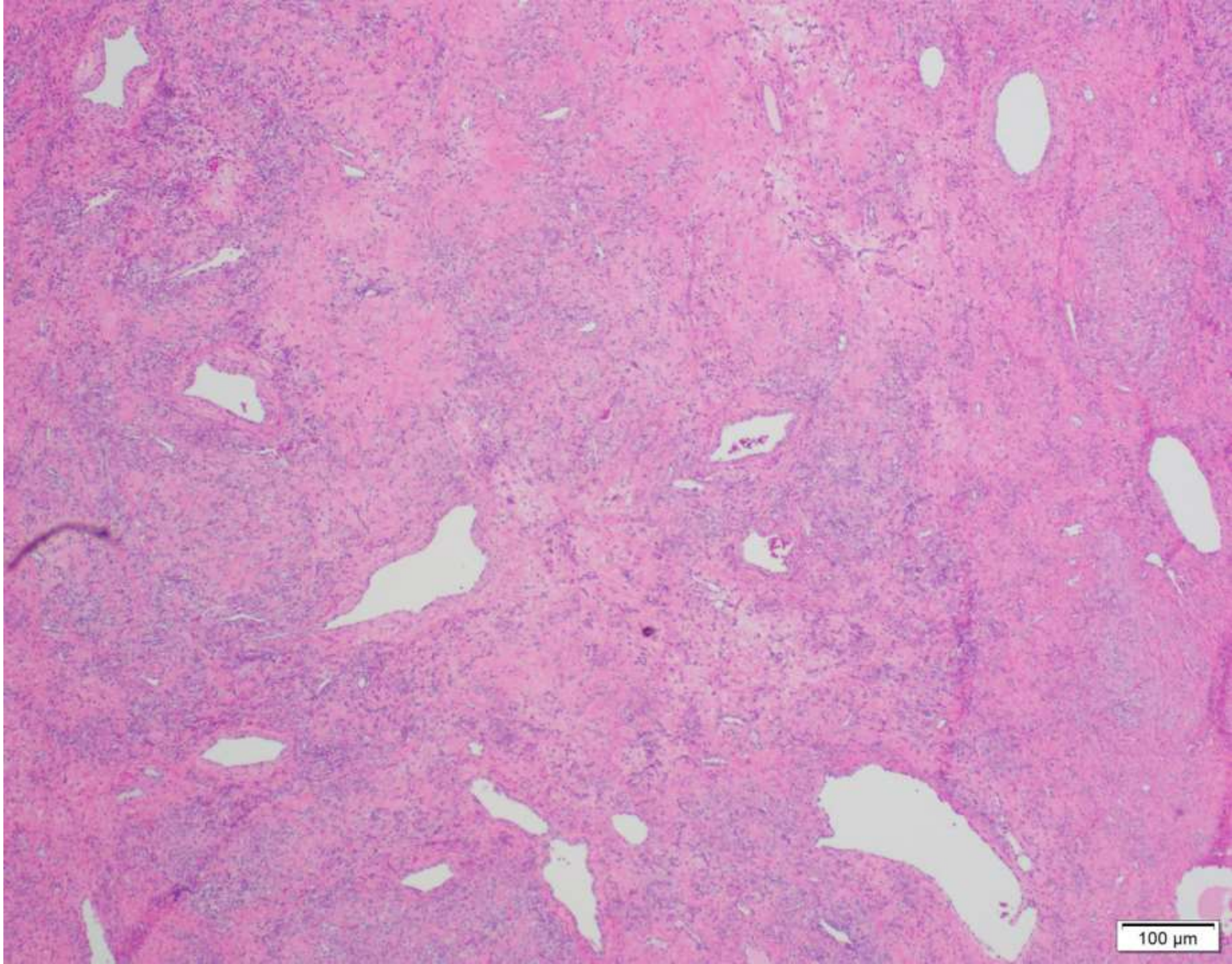
Mala Adhikari; Kaiser Santa Clara
27-year-old woman with 8.4cm
complex cystic and solid ovarian mass
on ultrasound.

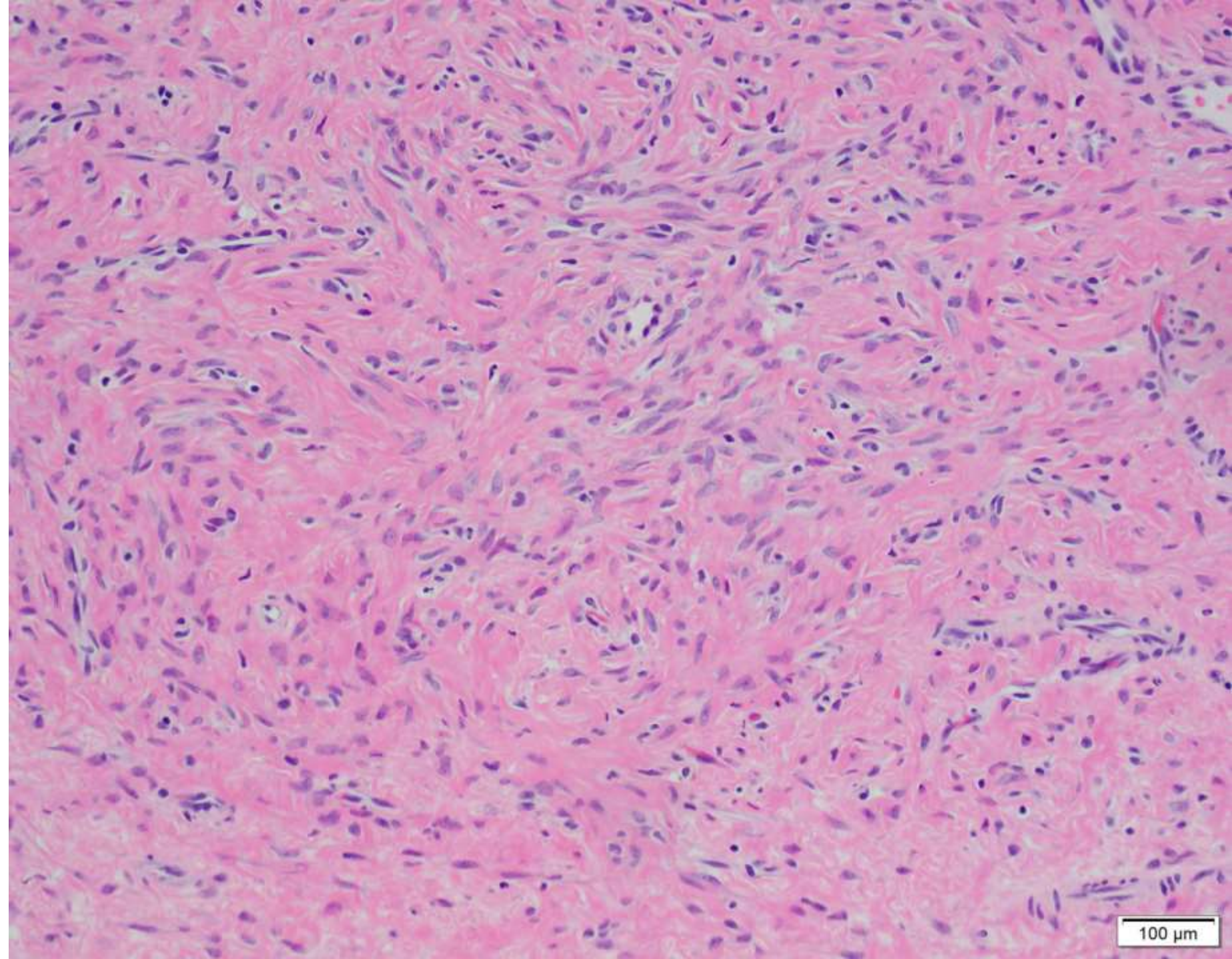




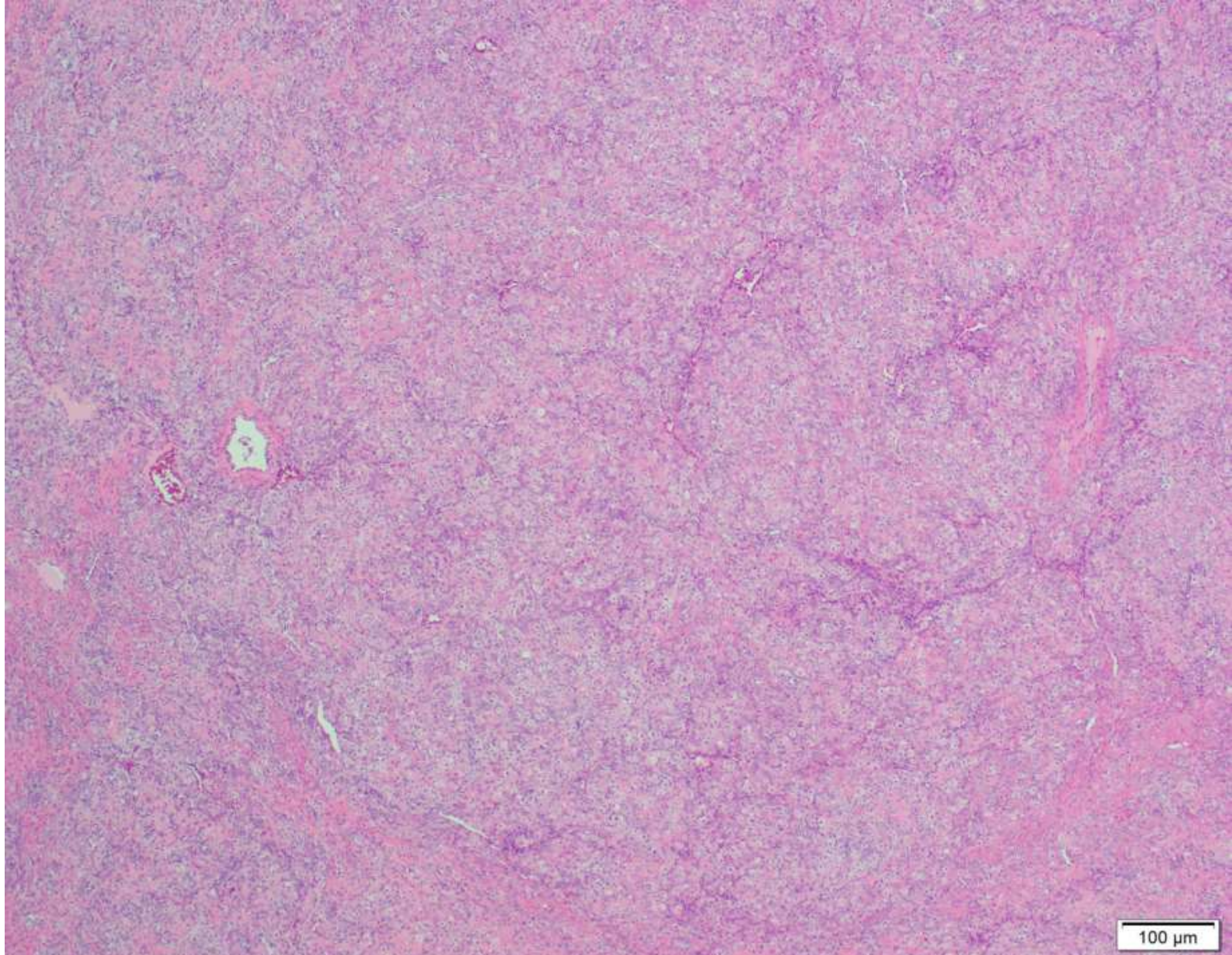


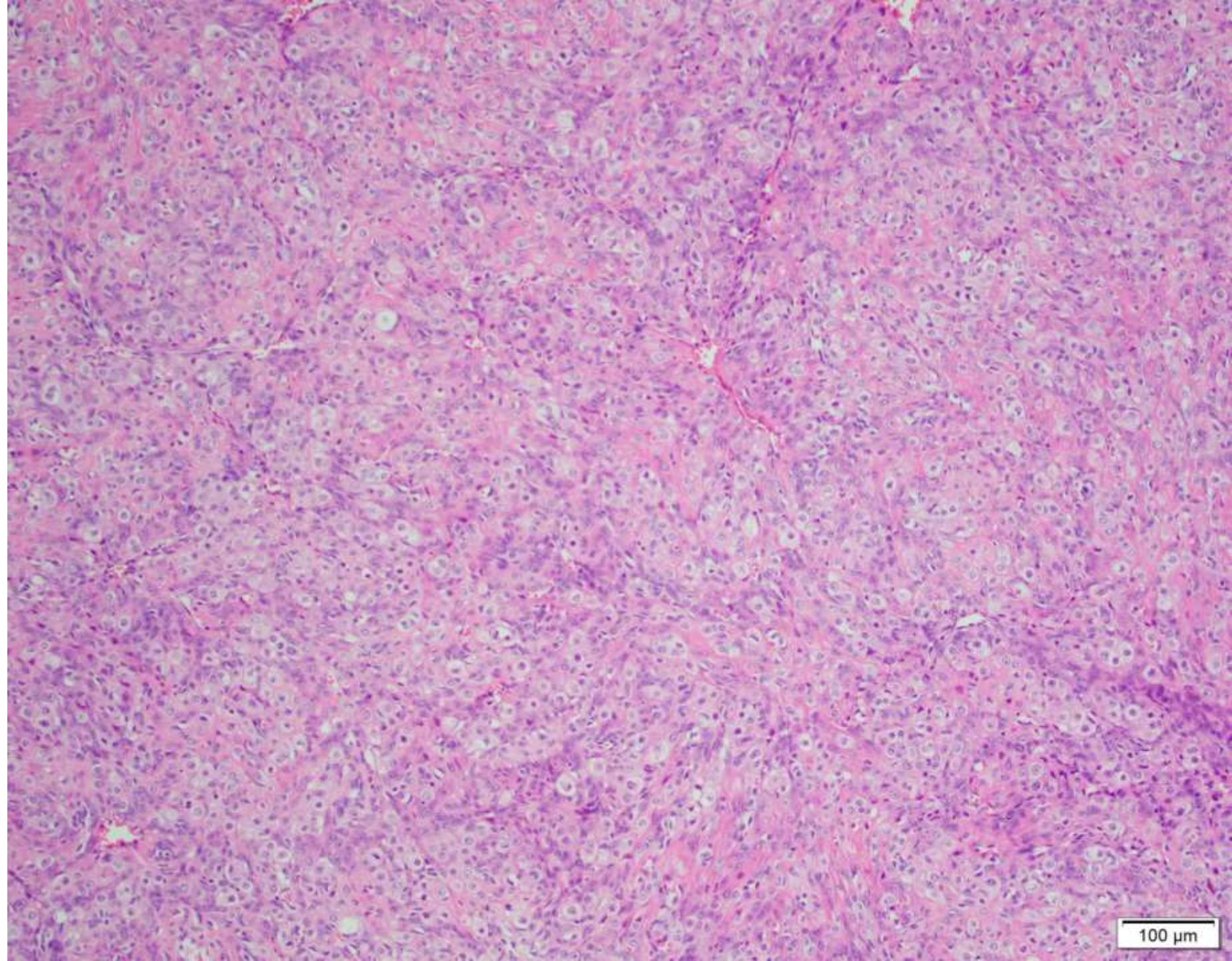
100 μm

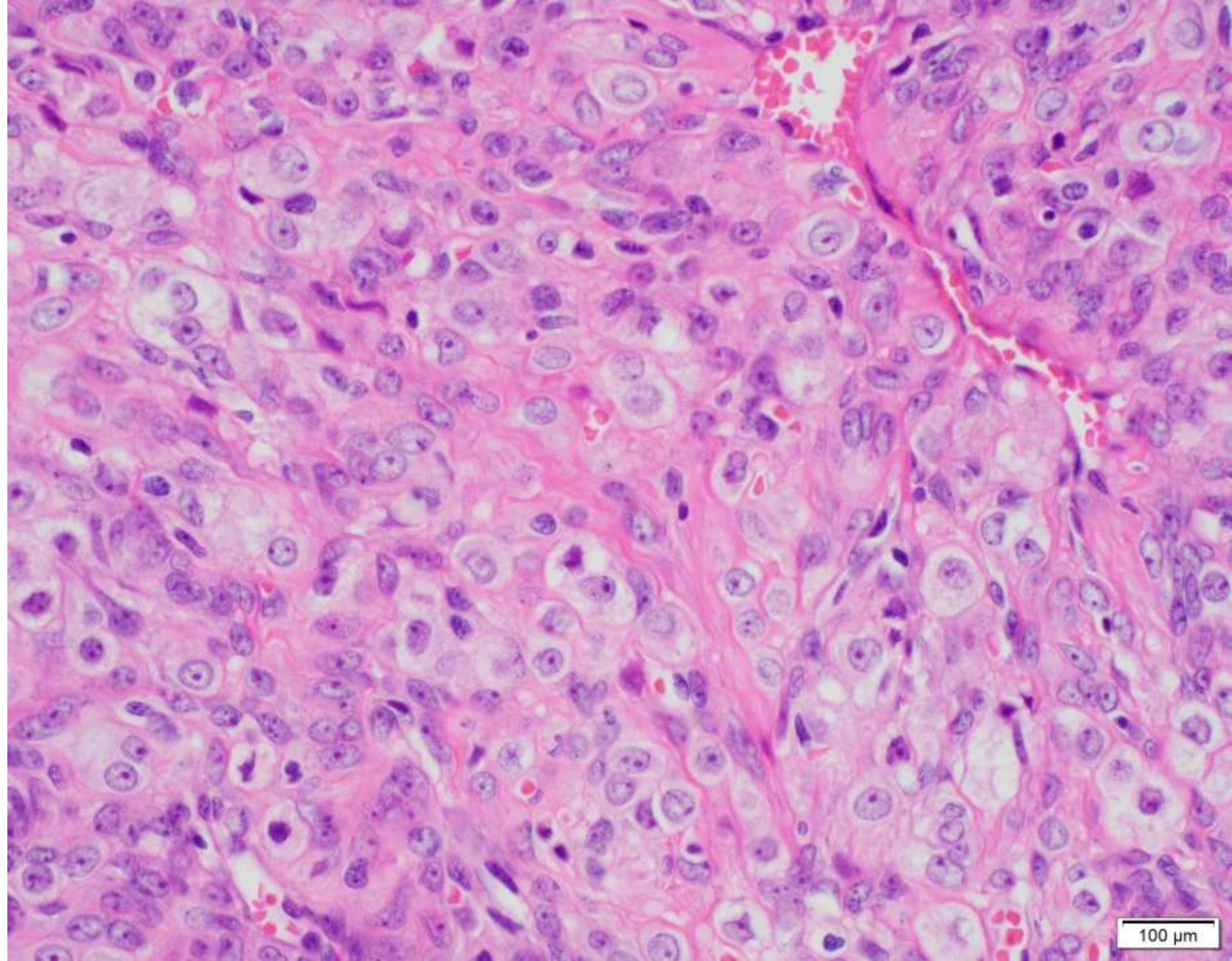




100 μm



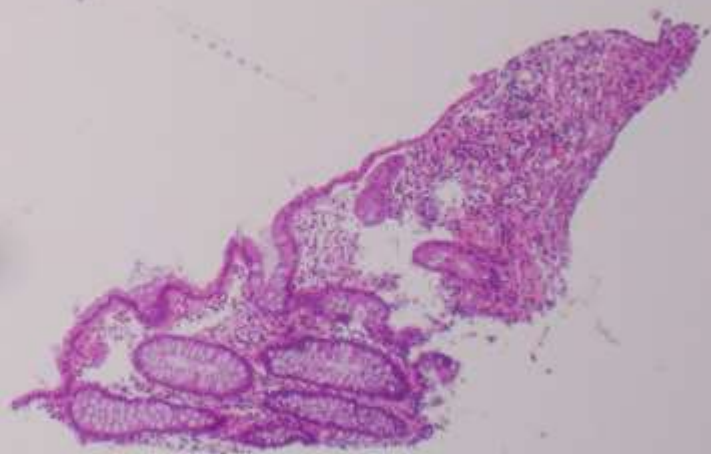
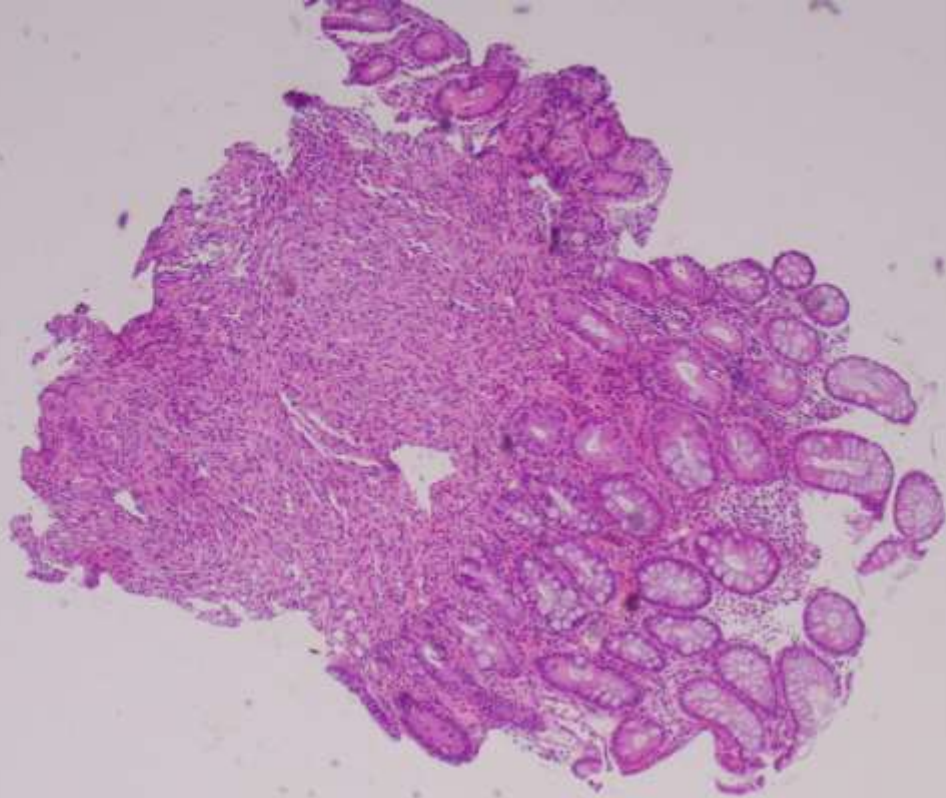


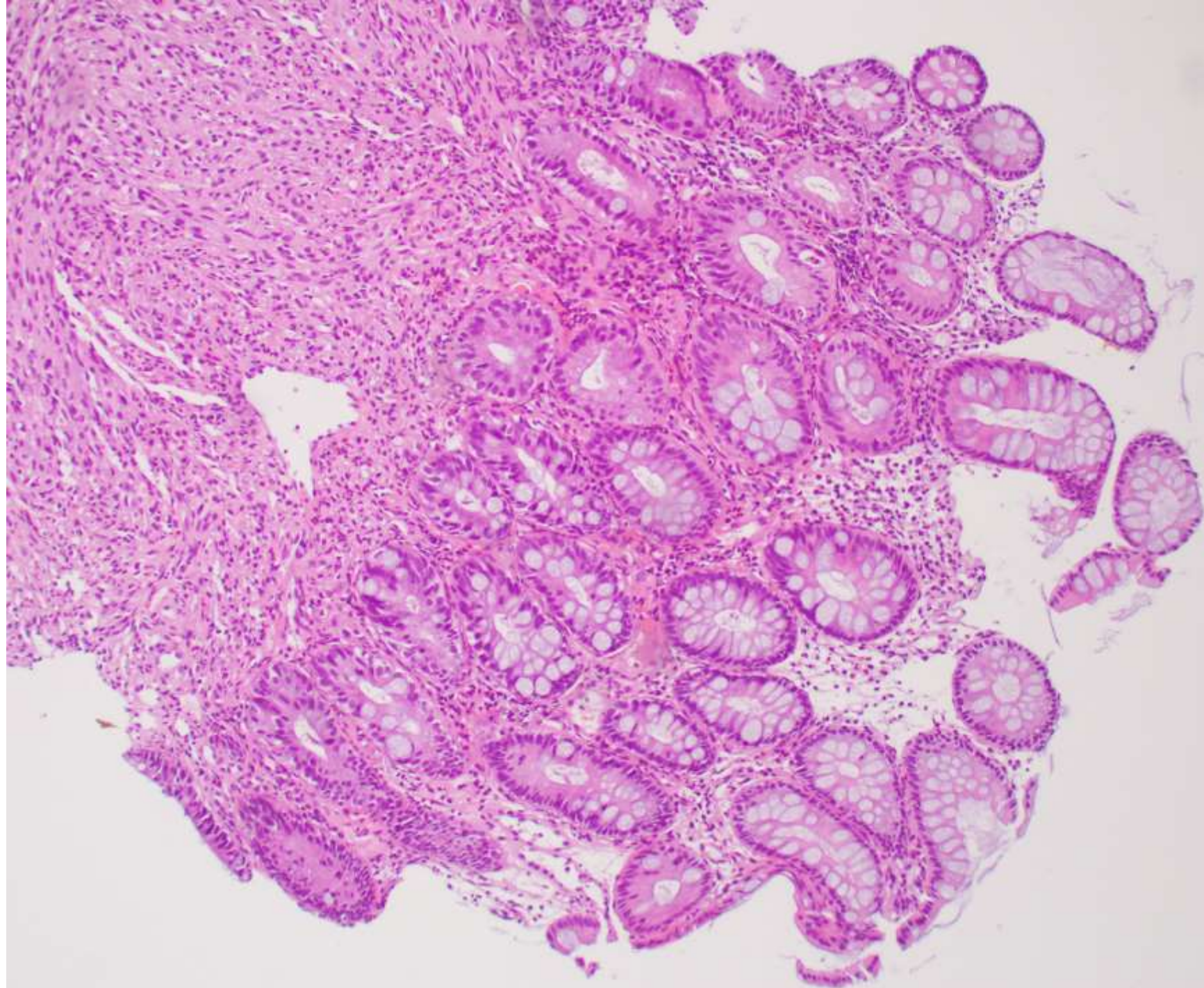


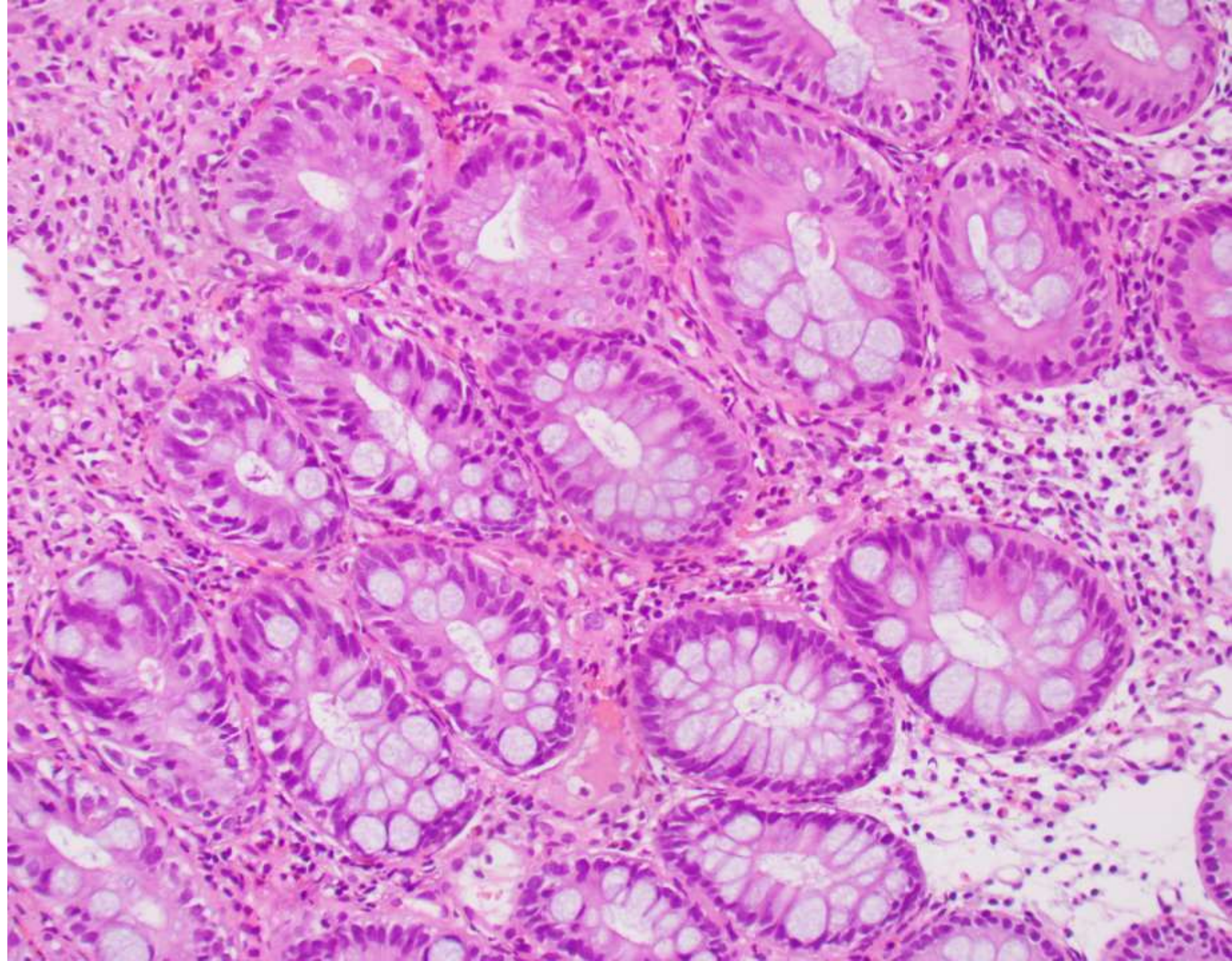
SB 6182

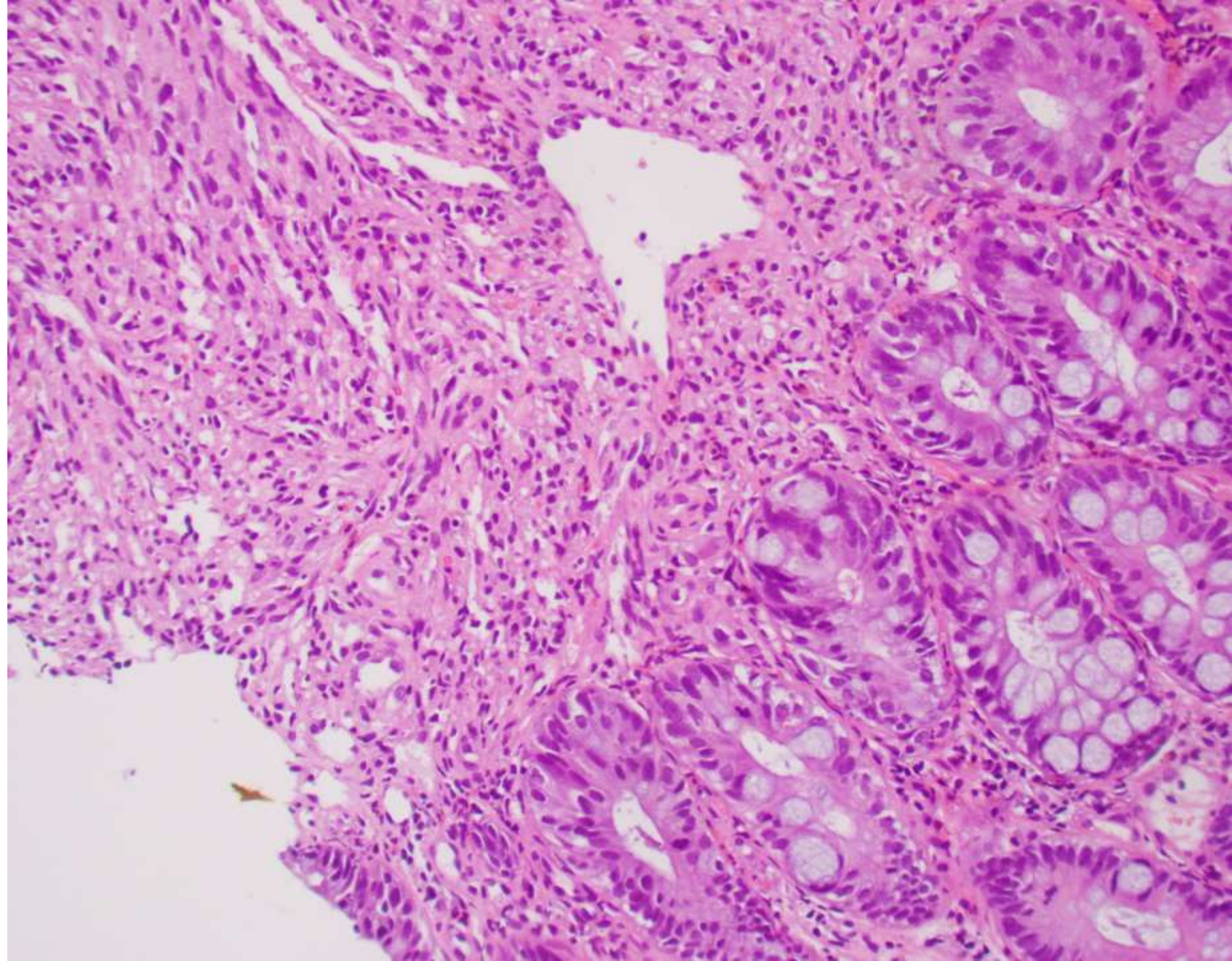
(scanned slide available)

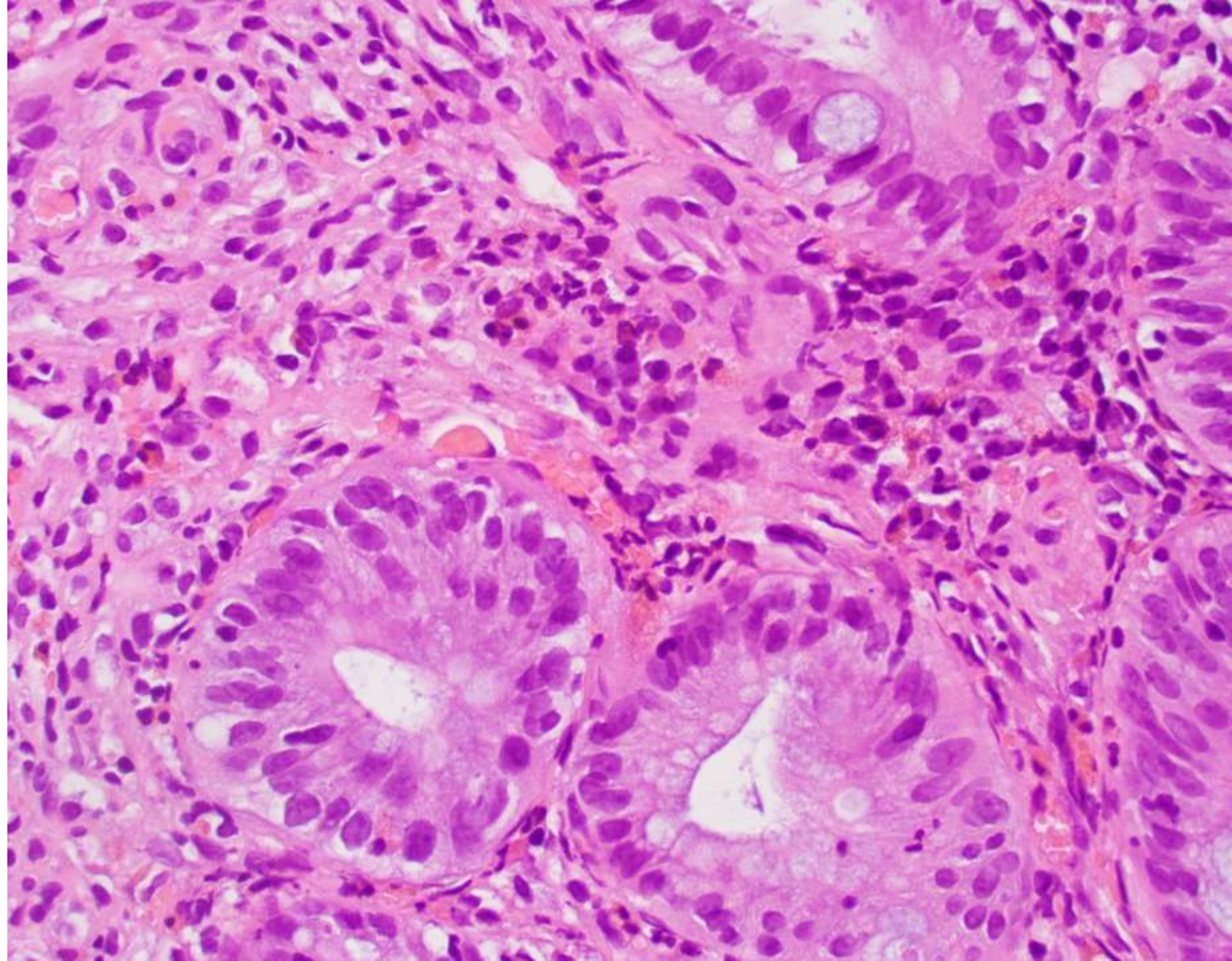
Walden Browne; Kaiser Oakland
53-year-old man with diarrhea. Colon
biopsy performed to rule out
microscopic colitis.

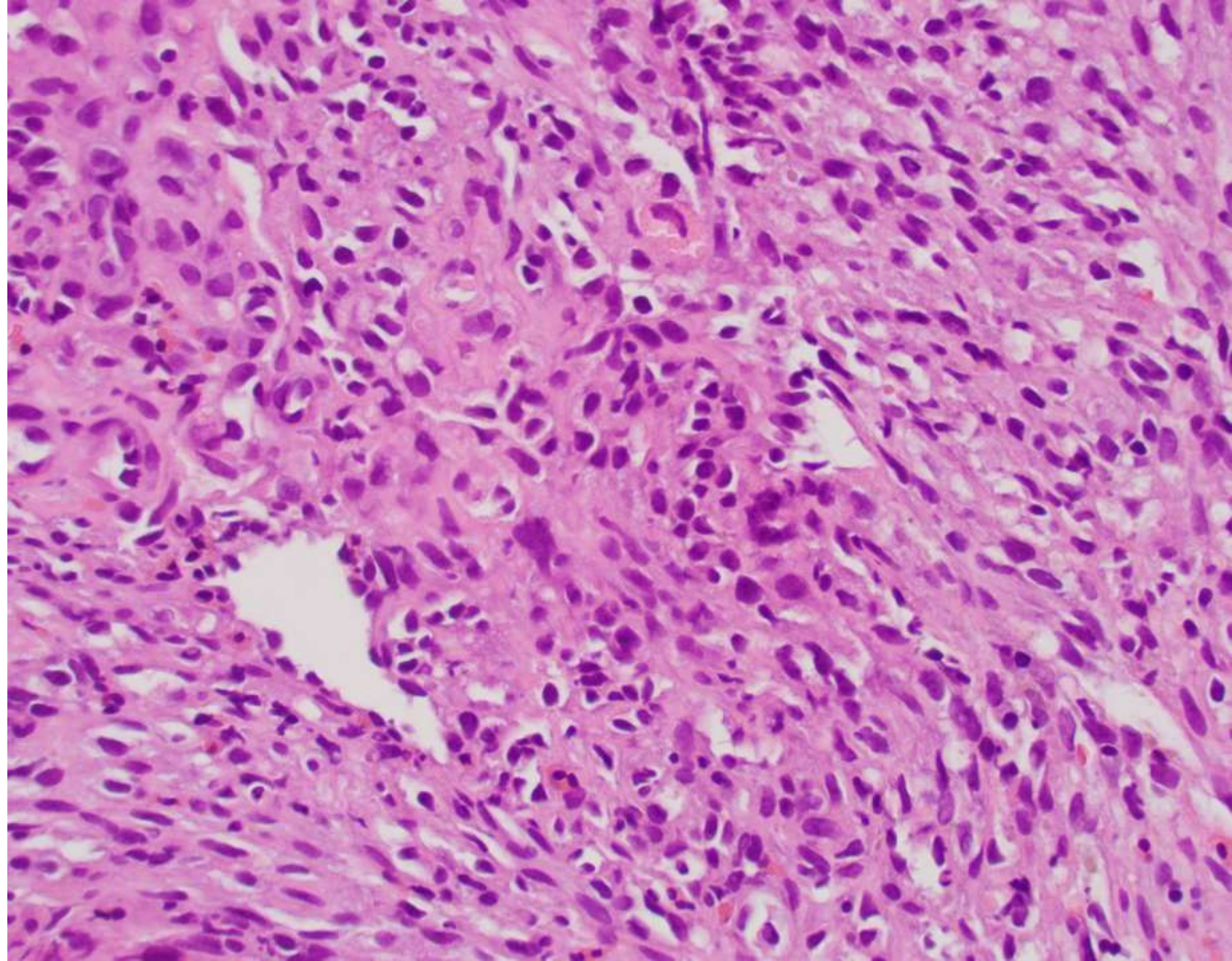










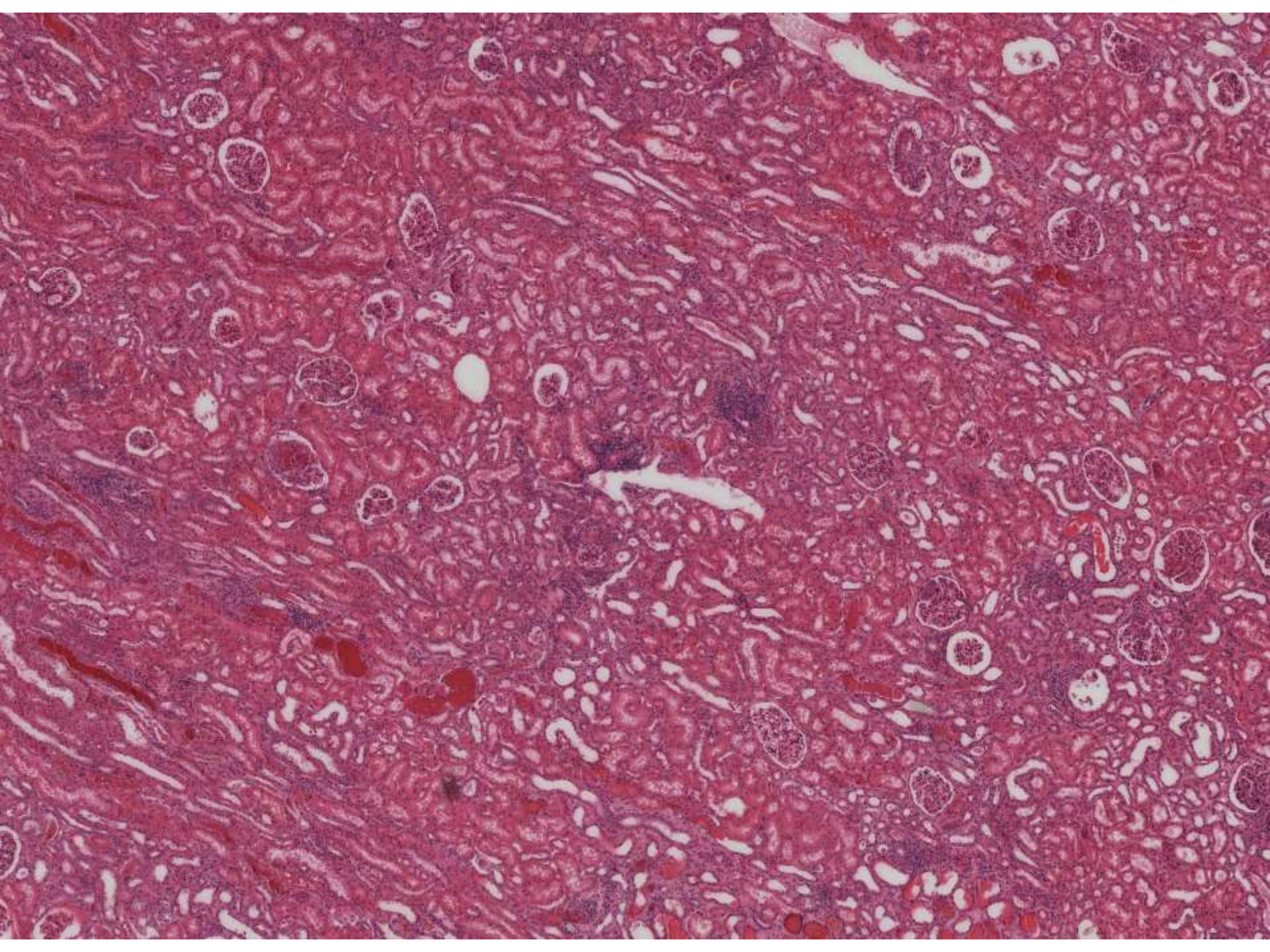


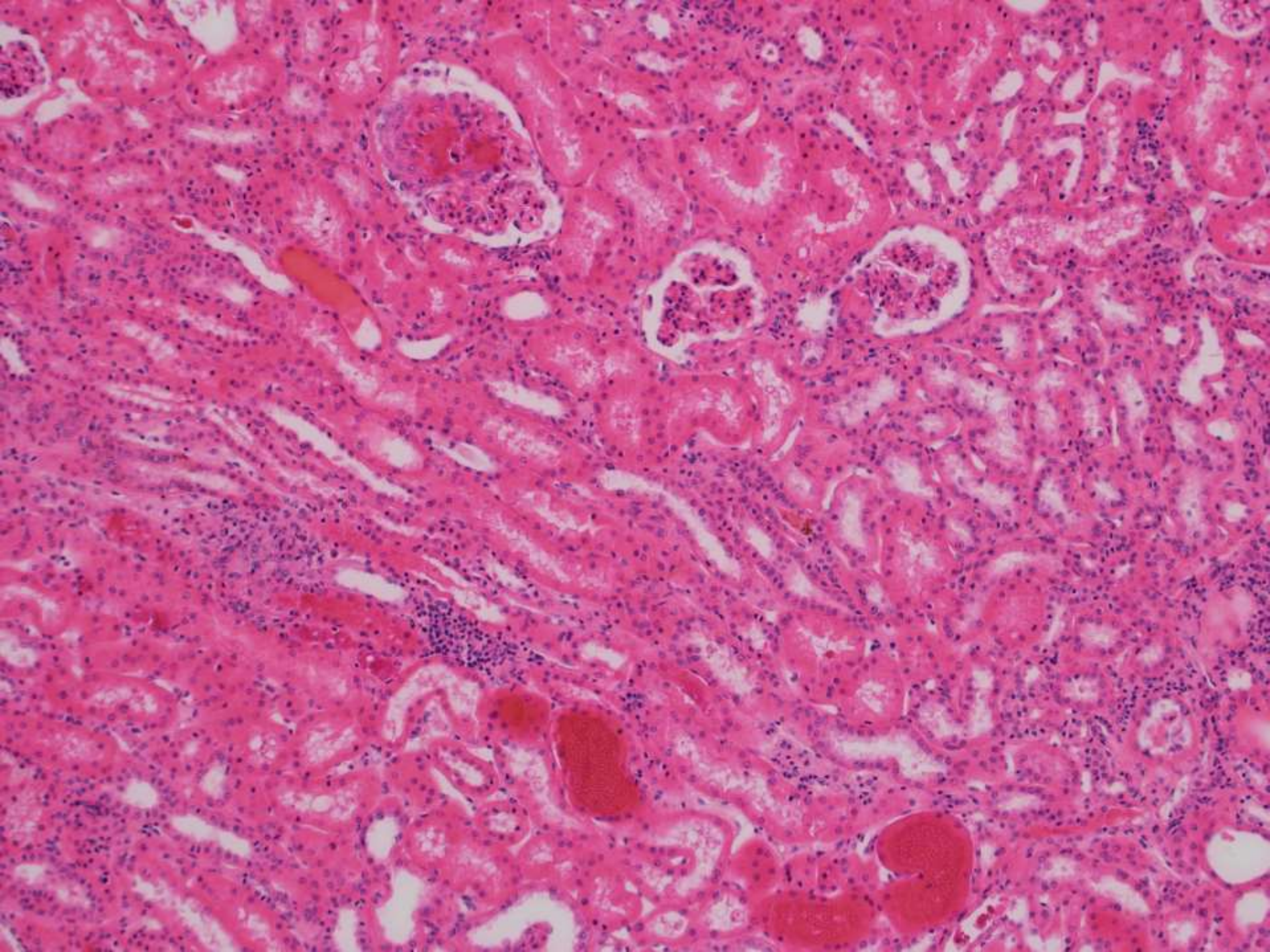
SB 6183

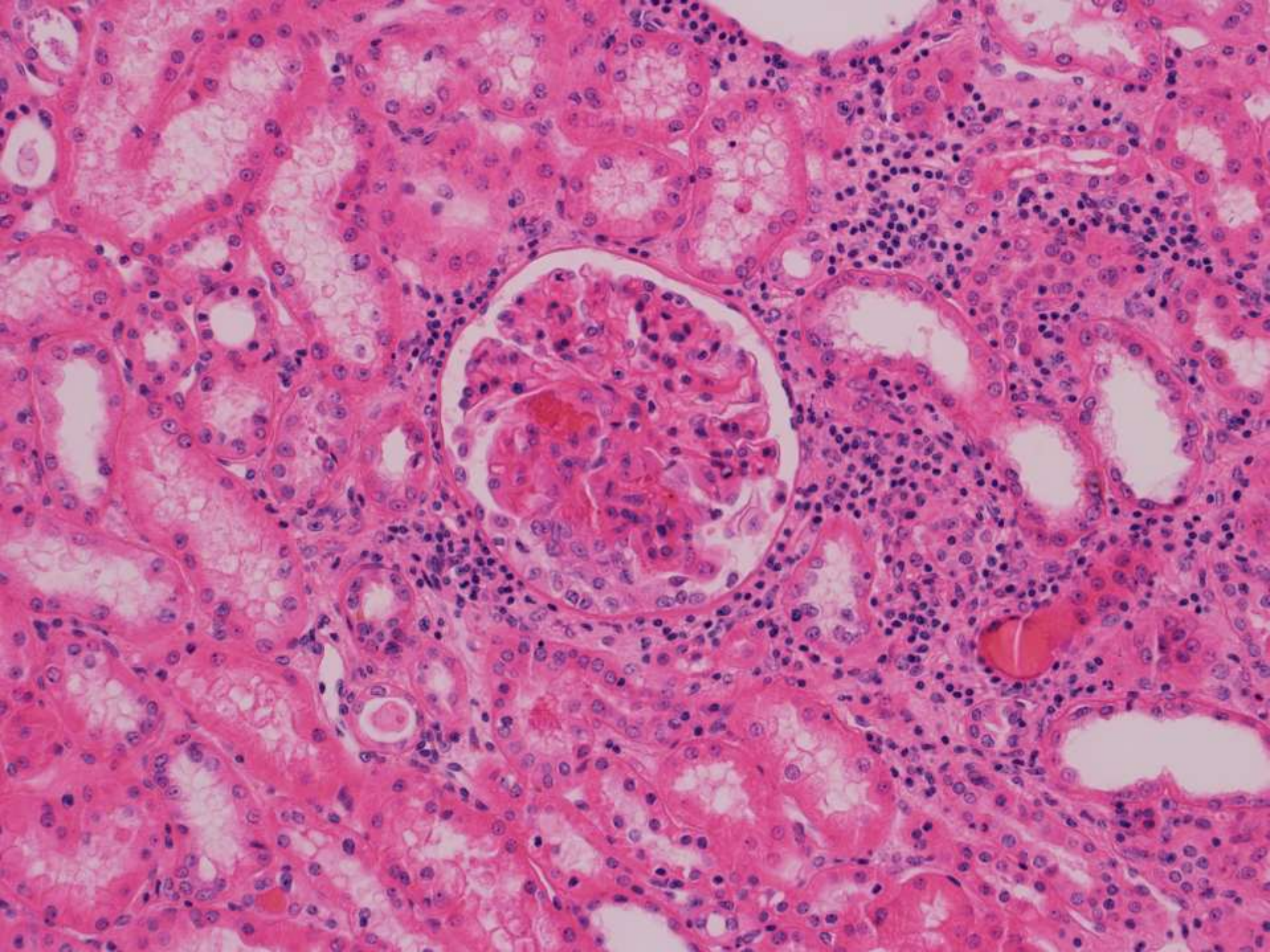
(scanned slide available)

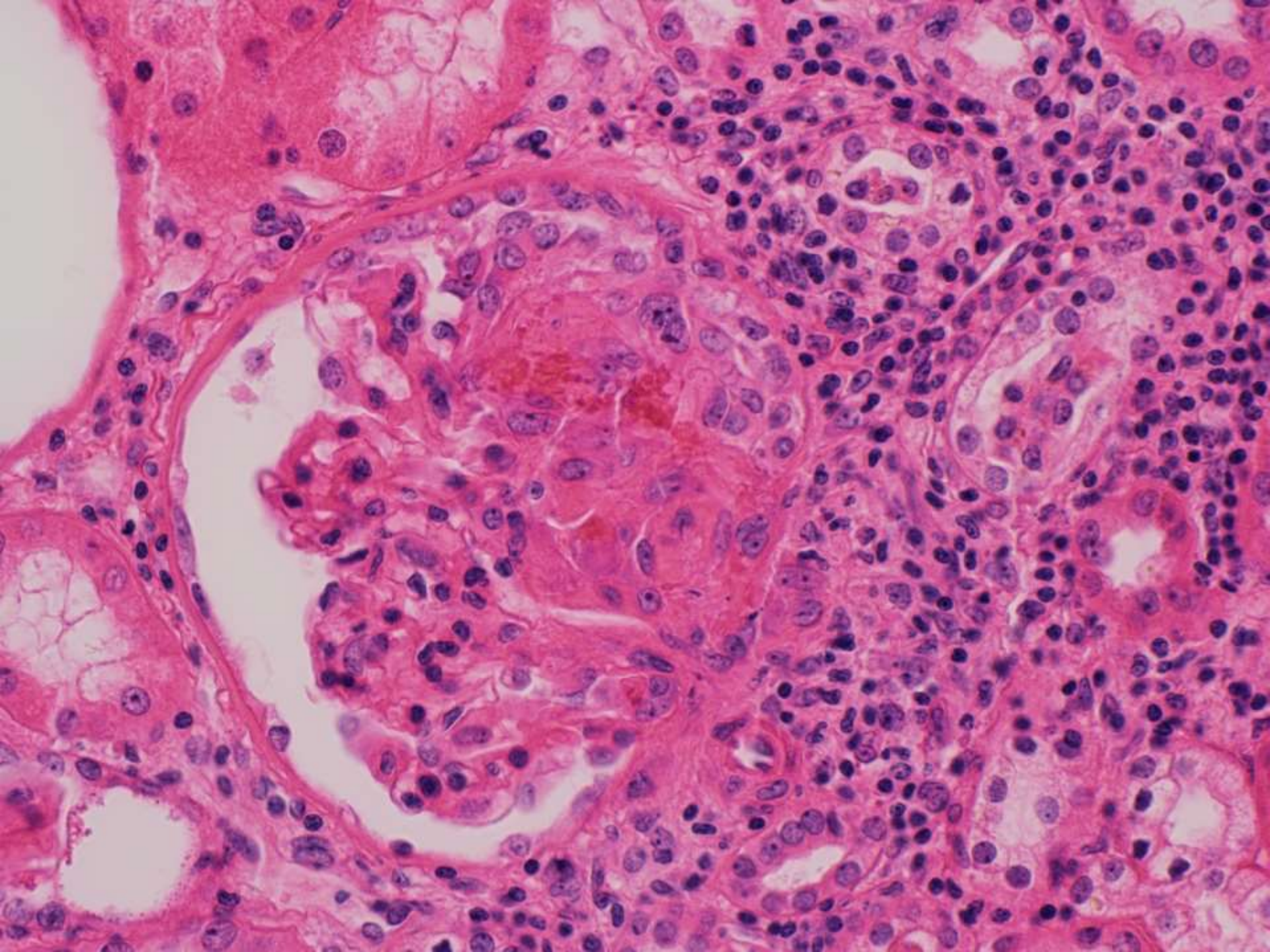
Megan Troxell; Stanford

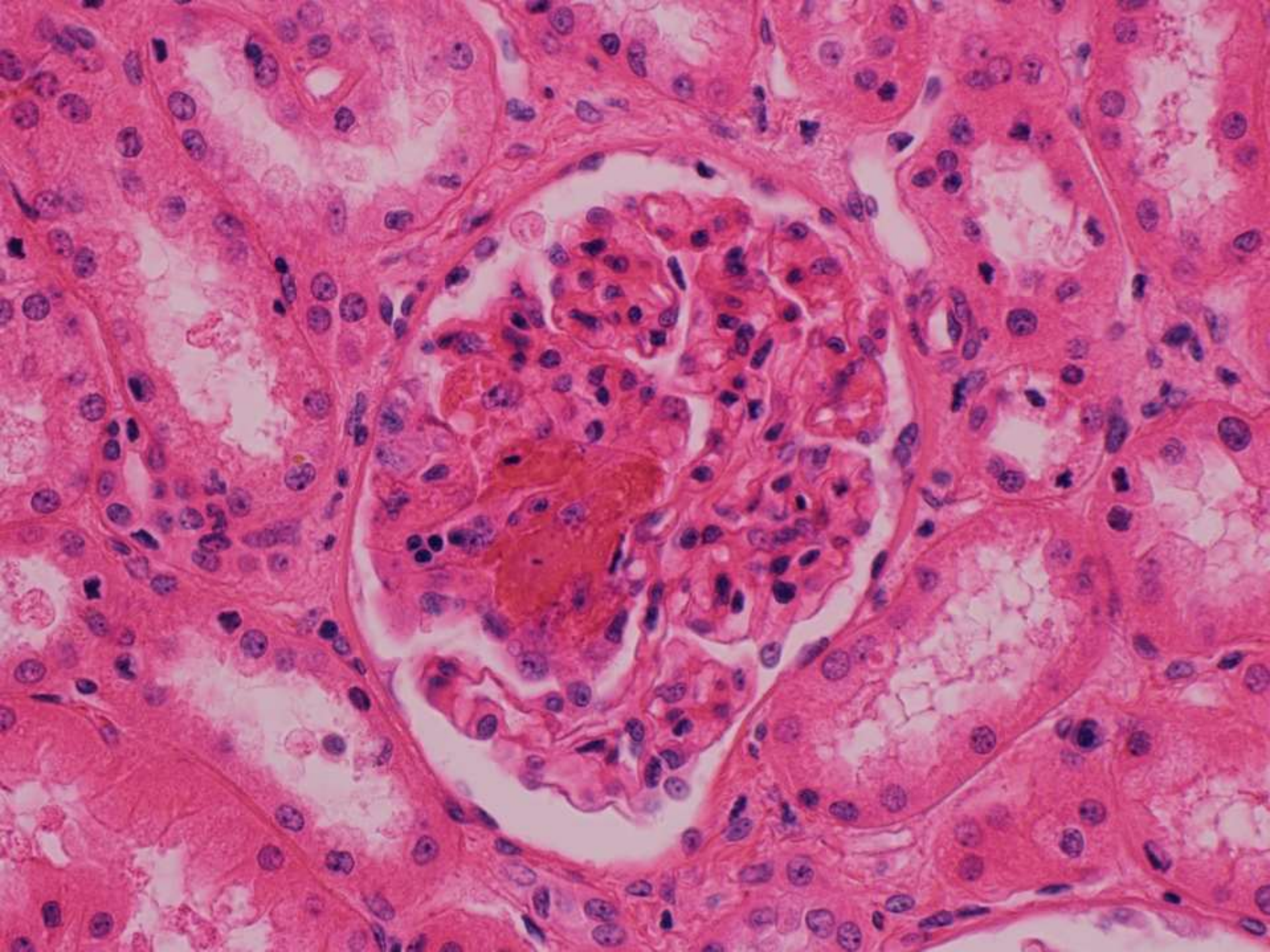
62-year-old diabetic woman with nephrectomy for clear cell RCC; non-neoplastic kidney section submitted. Creatinine rose from 1.1 to 2.0 after surgery.

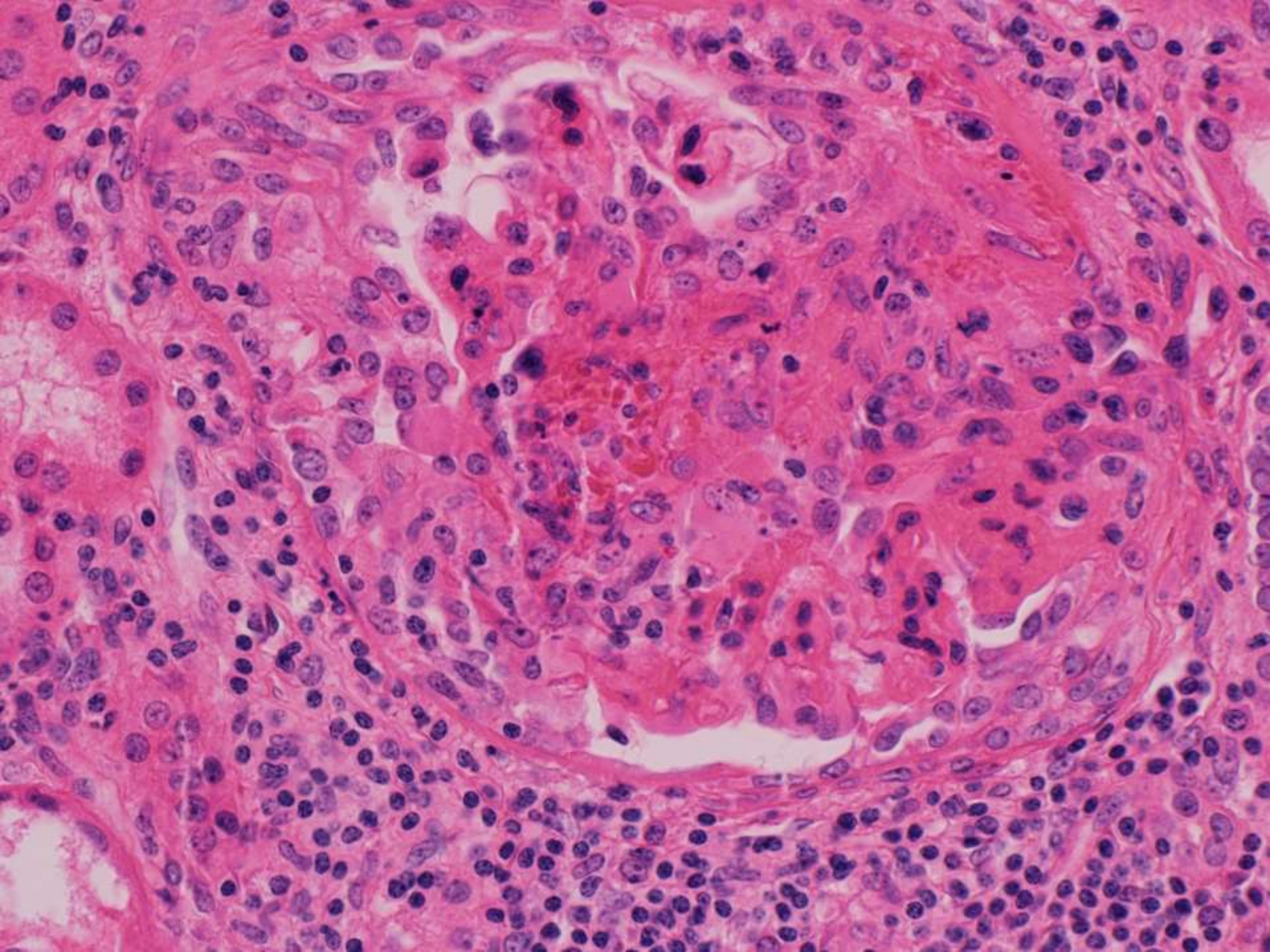








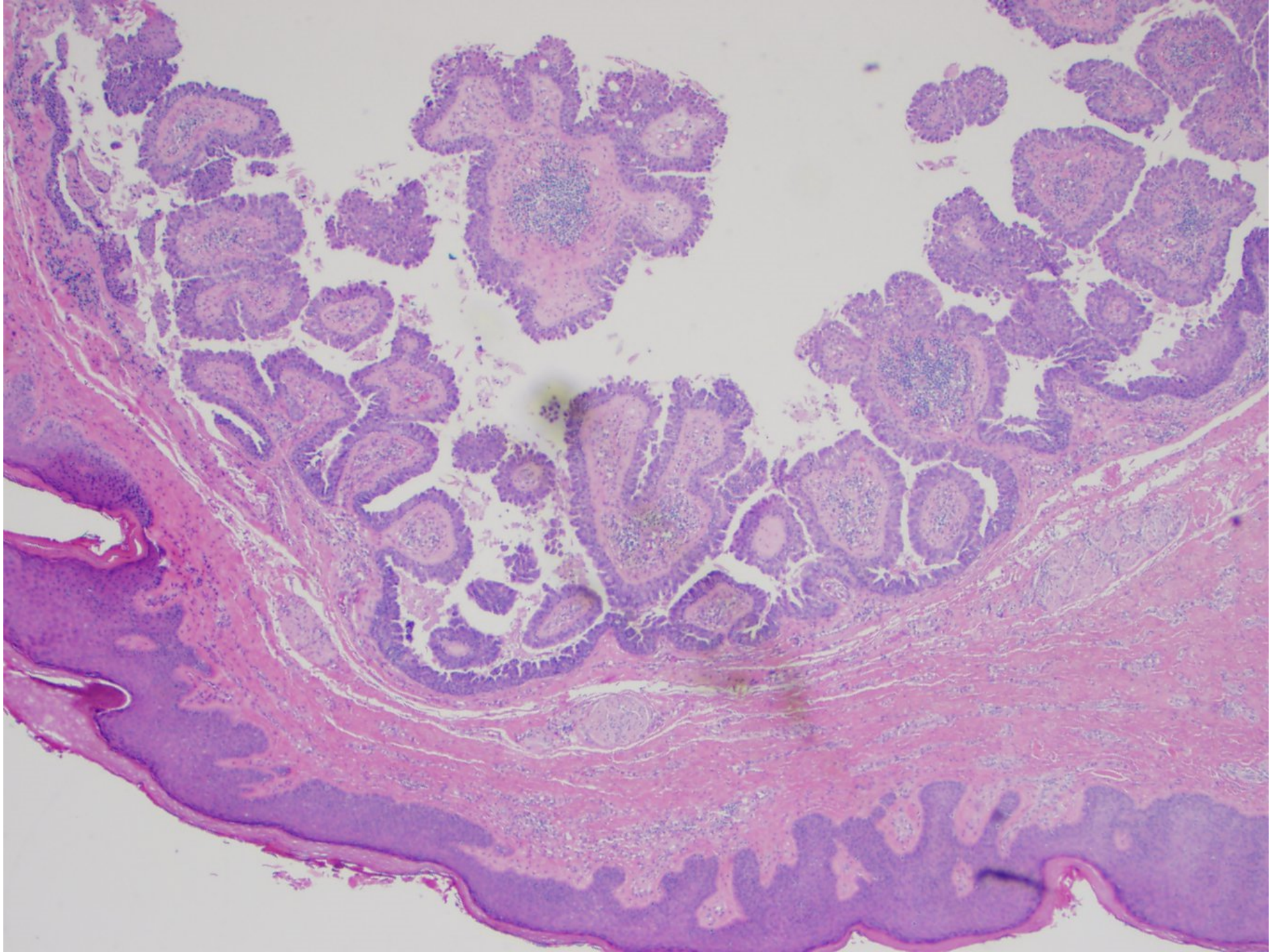


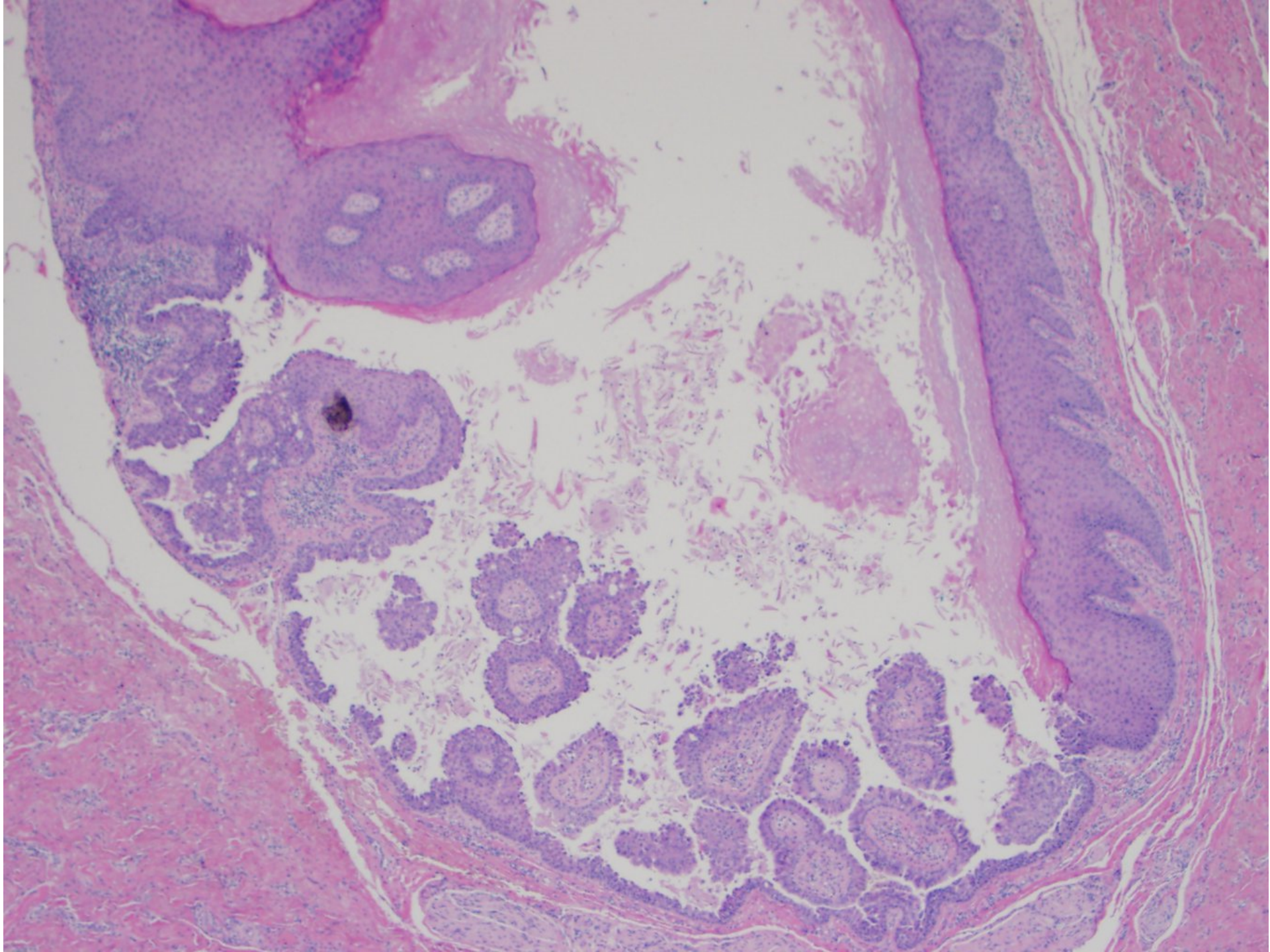


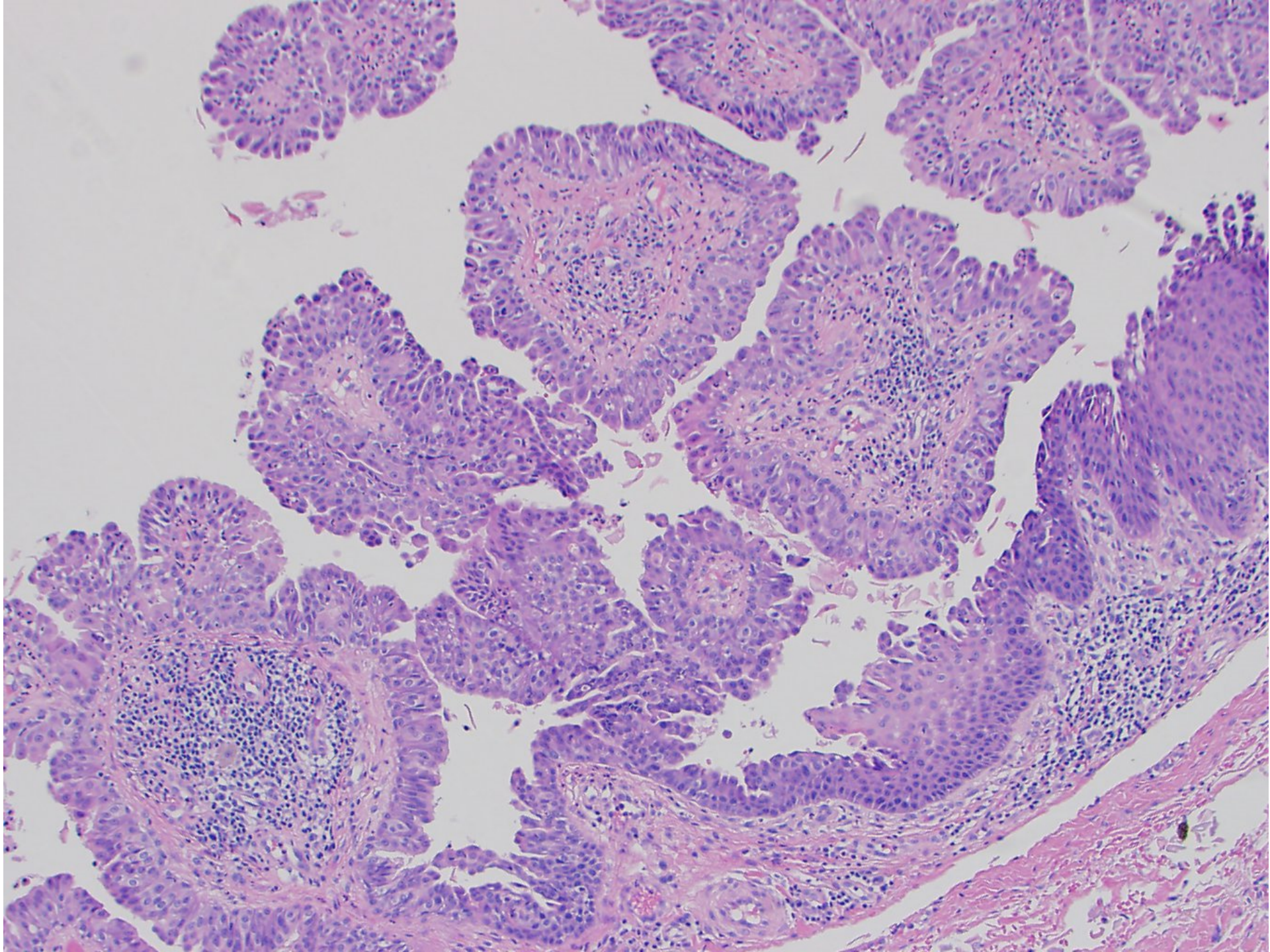
SB 6184

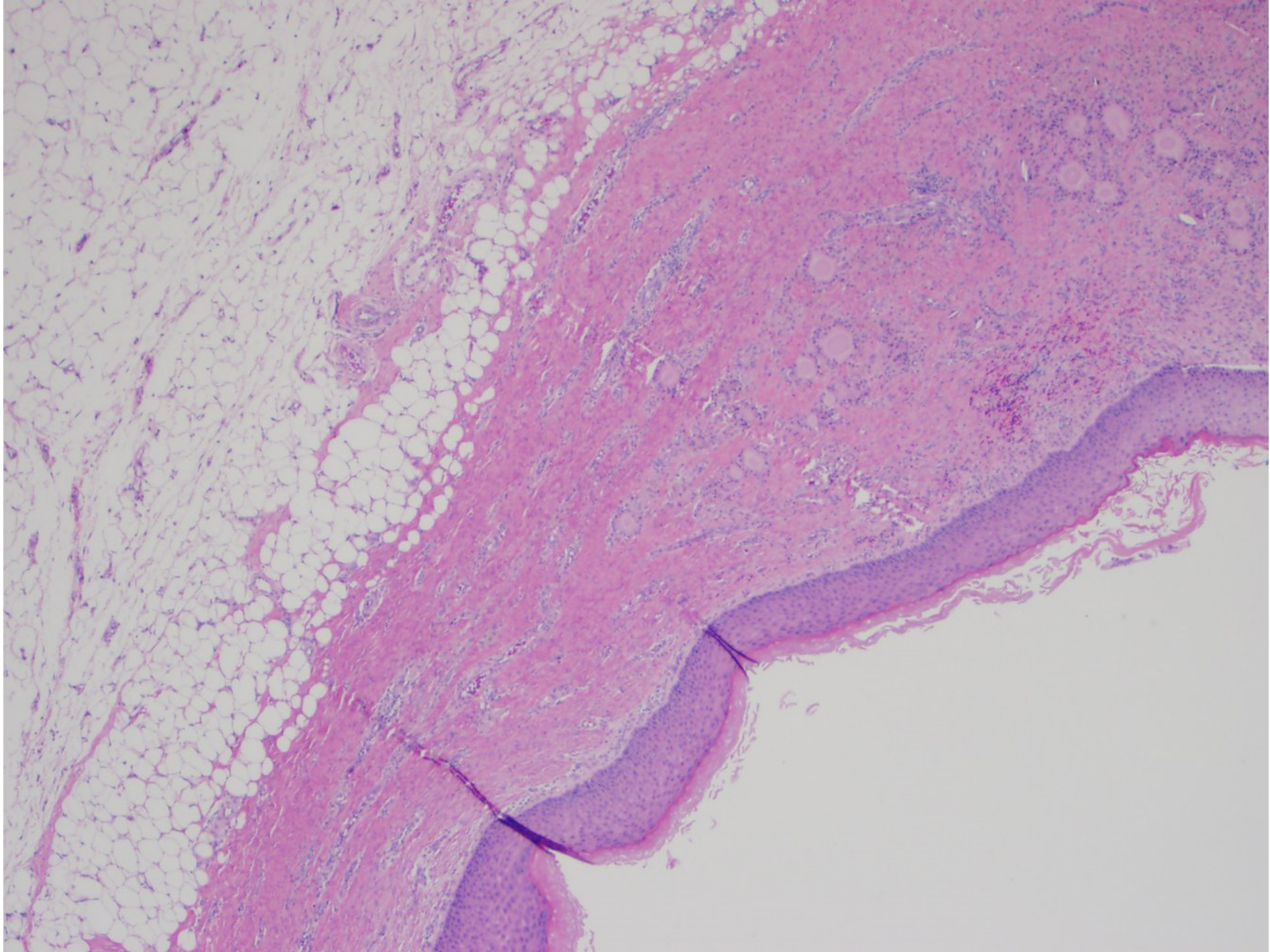
Greg Rumore; Kaiser Walnut Creek

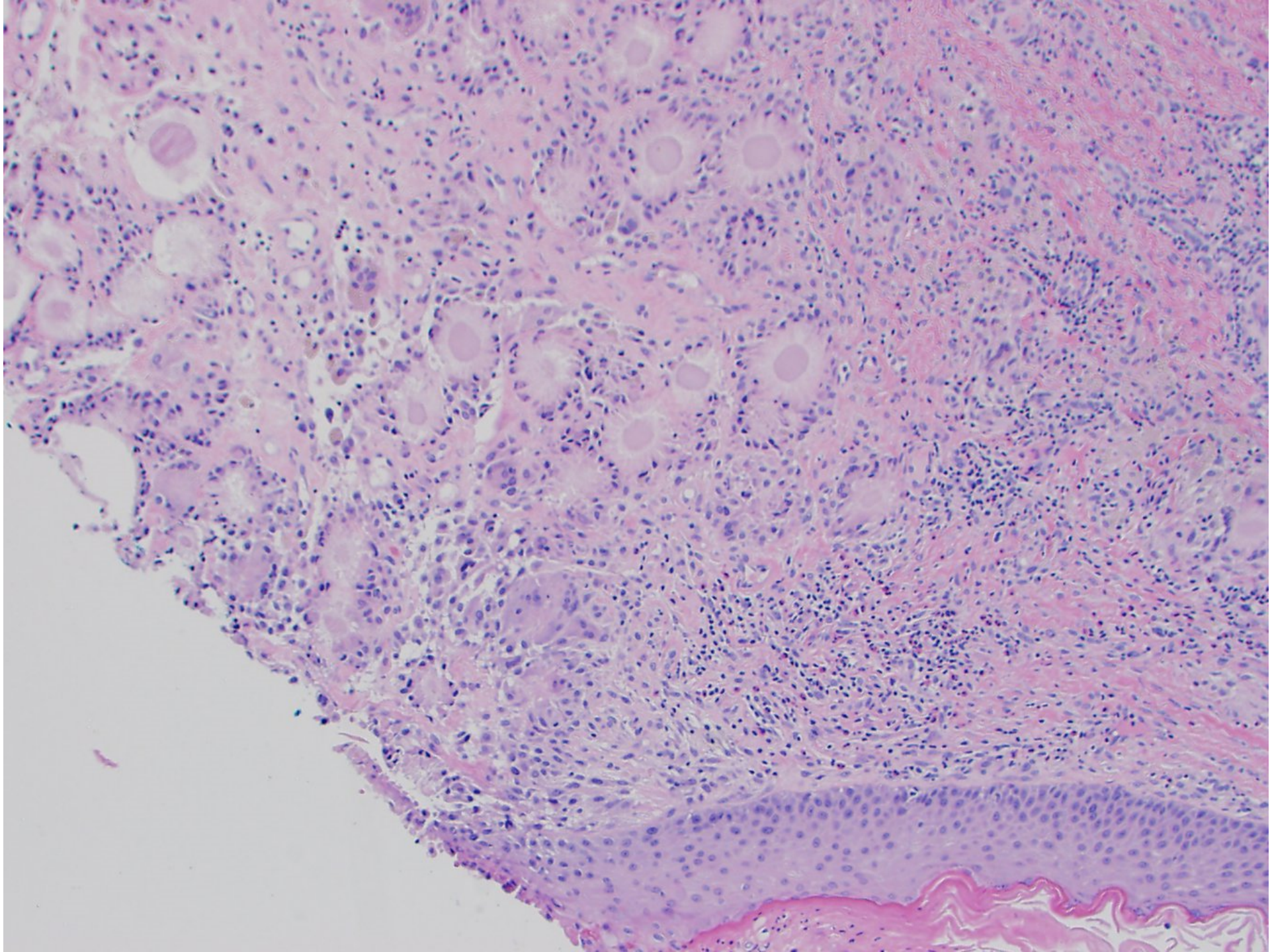
51-year-old woman with posterior
thigh cyst.

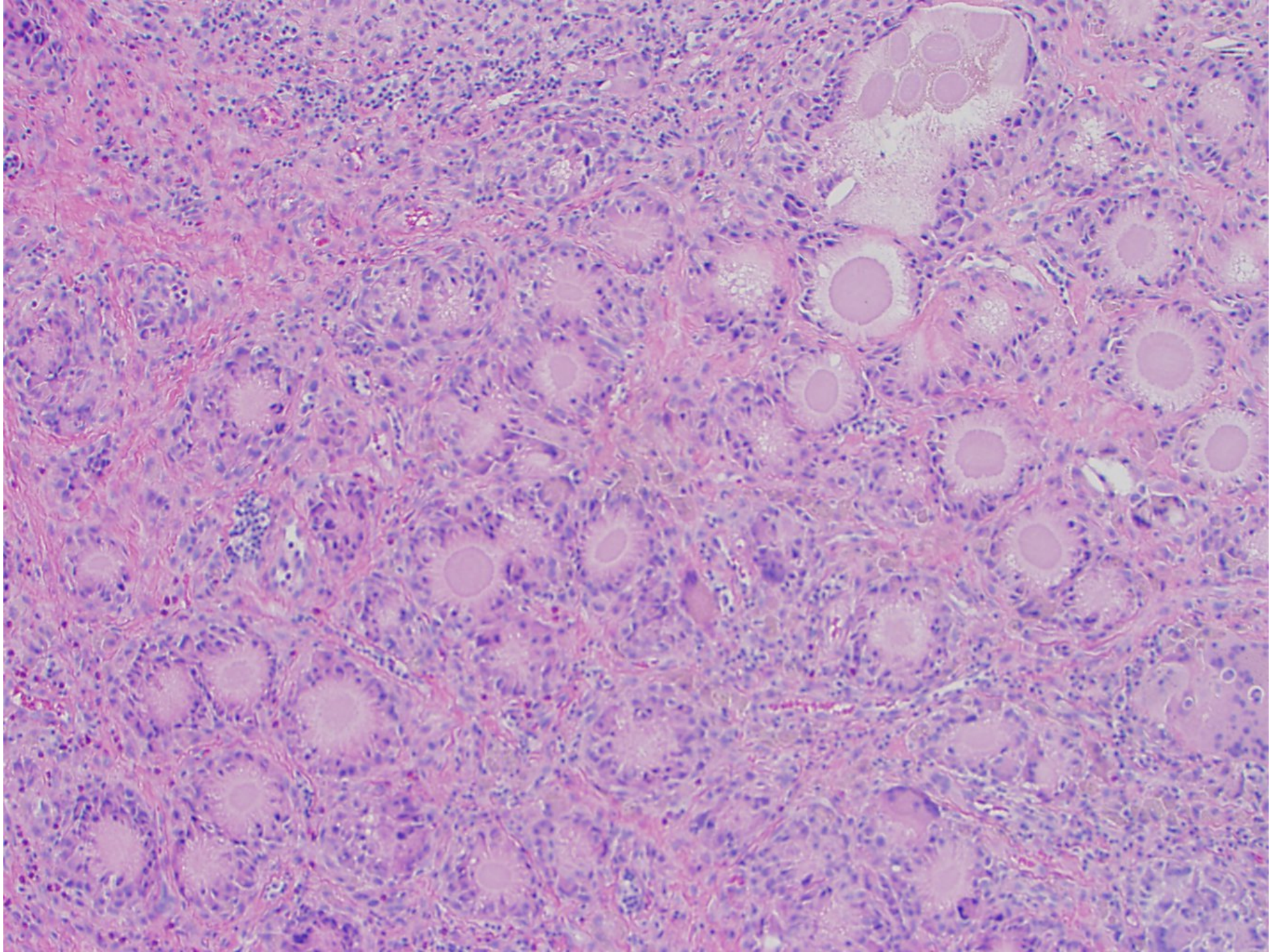


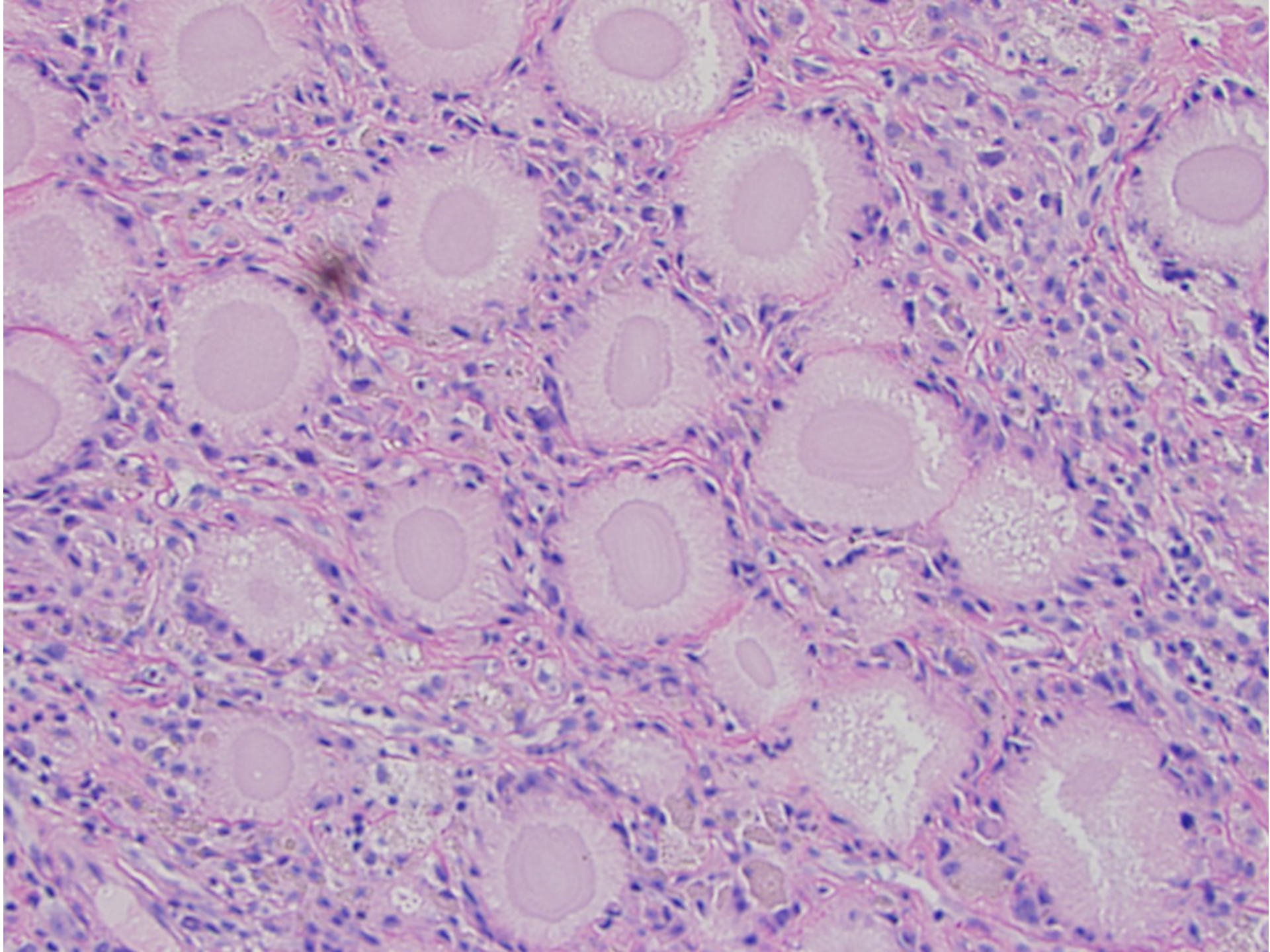


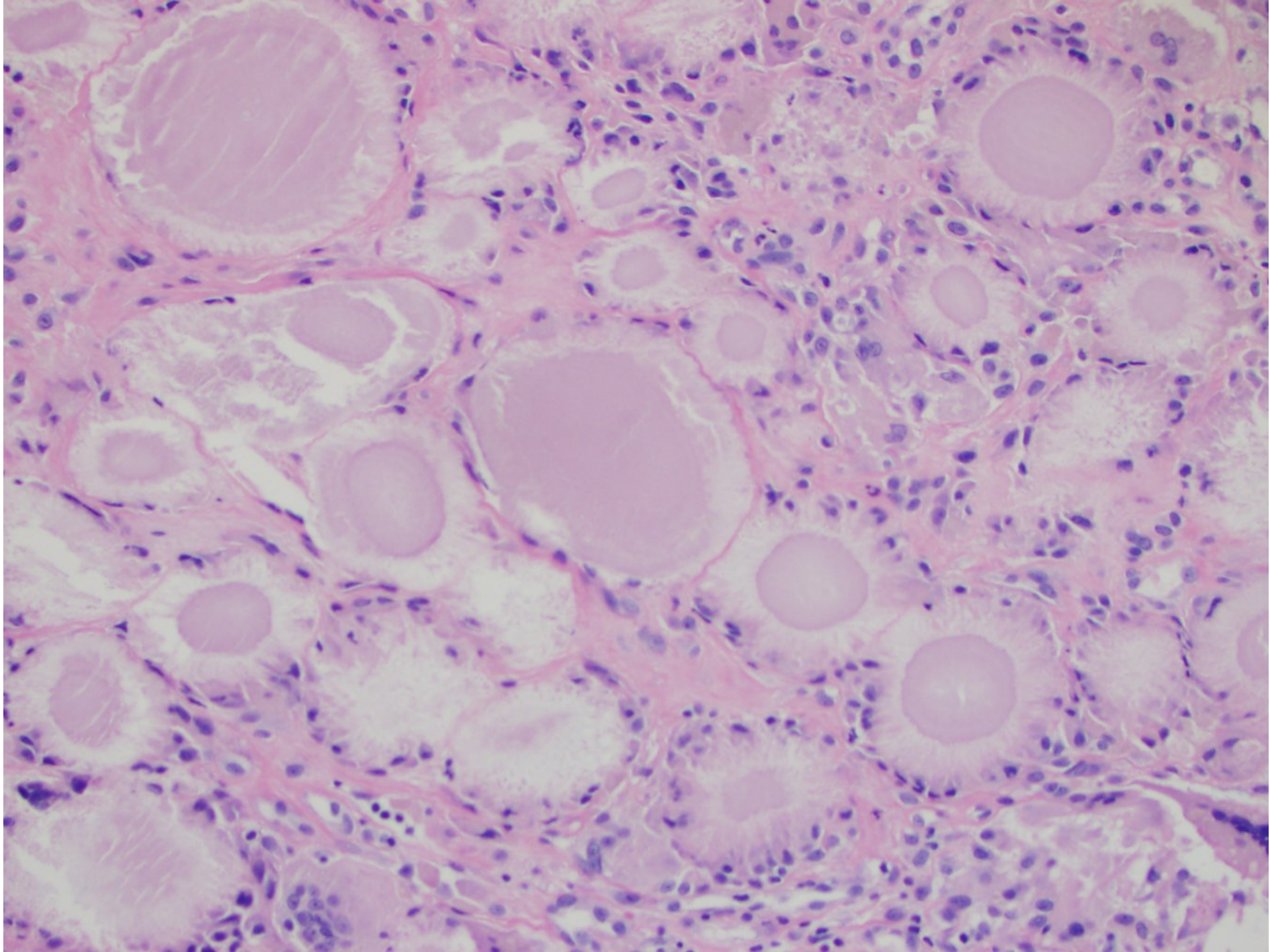


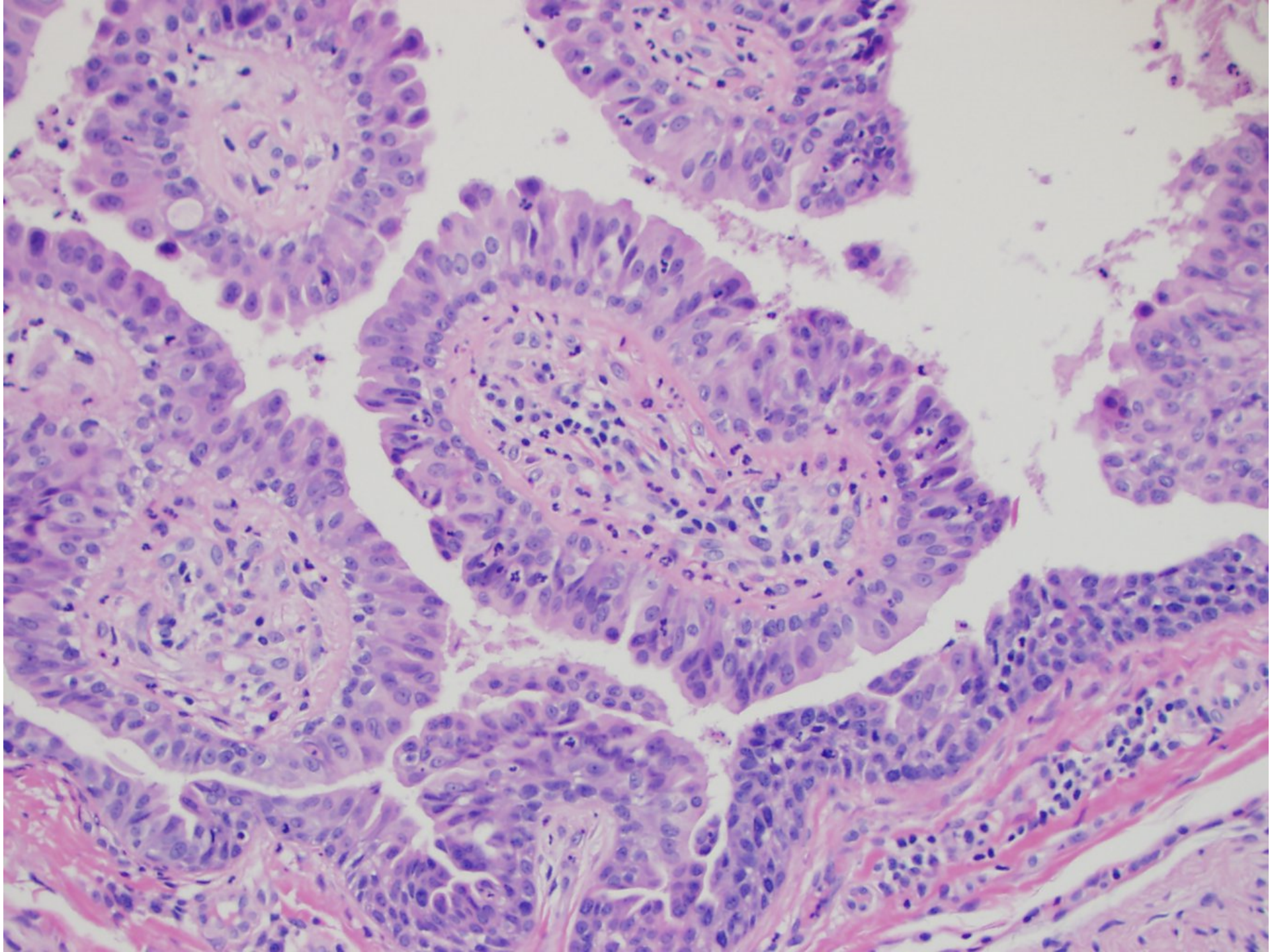


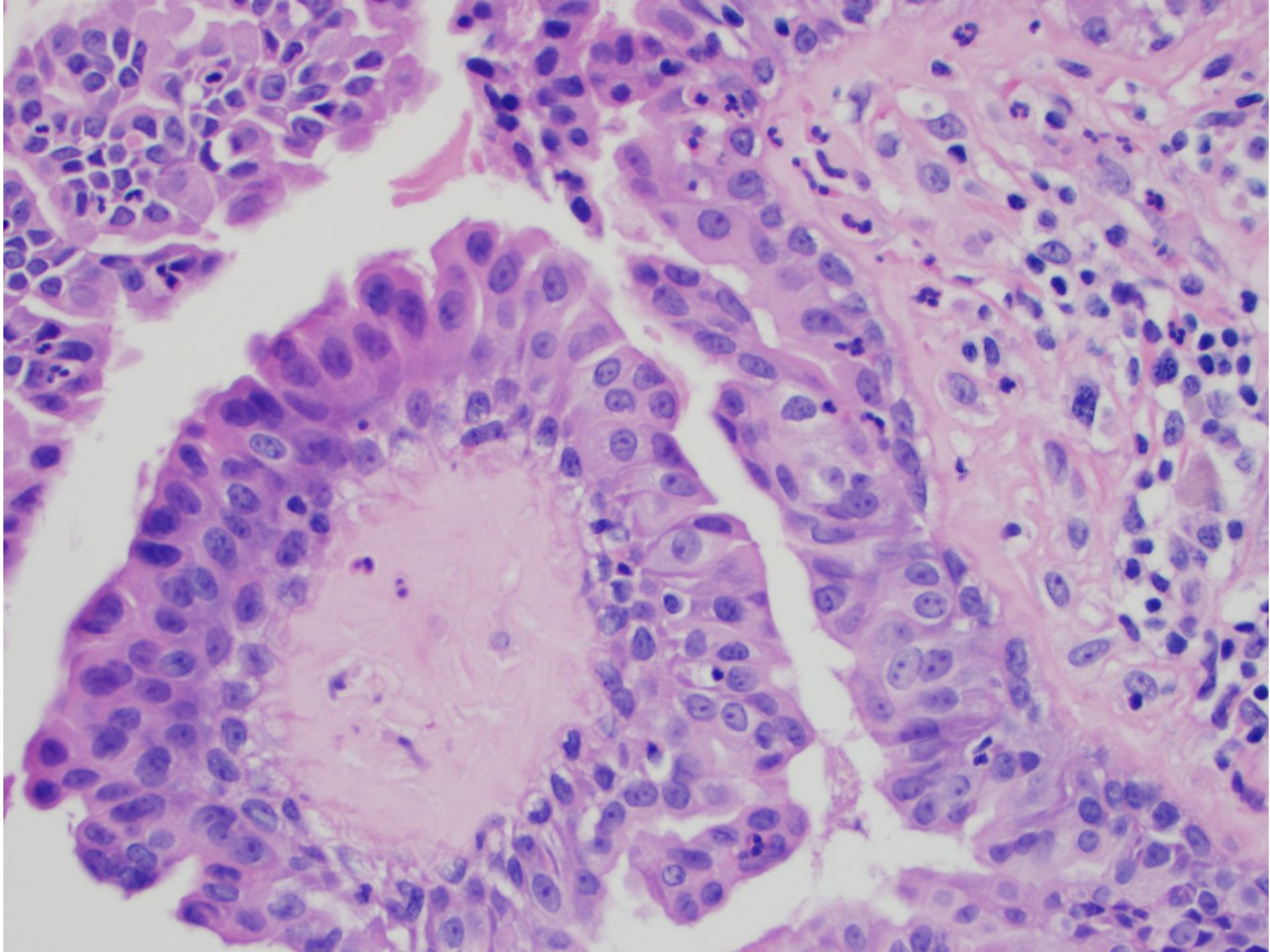








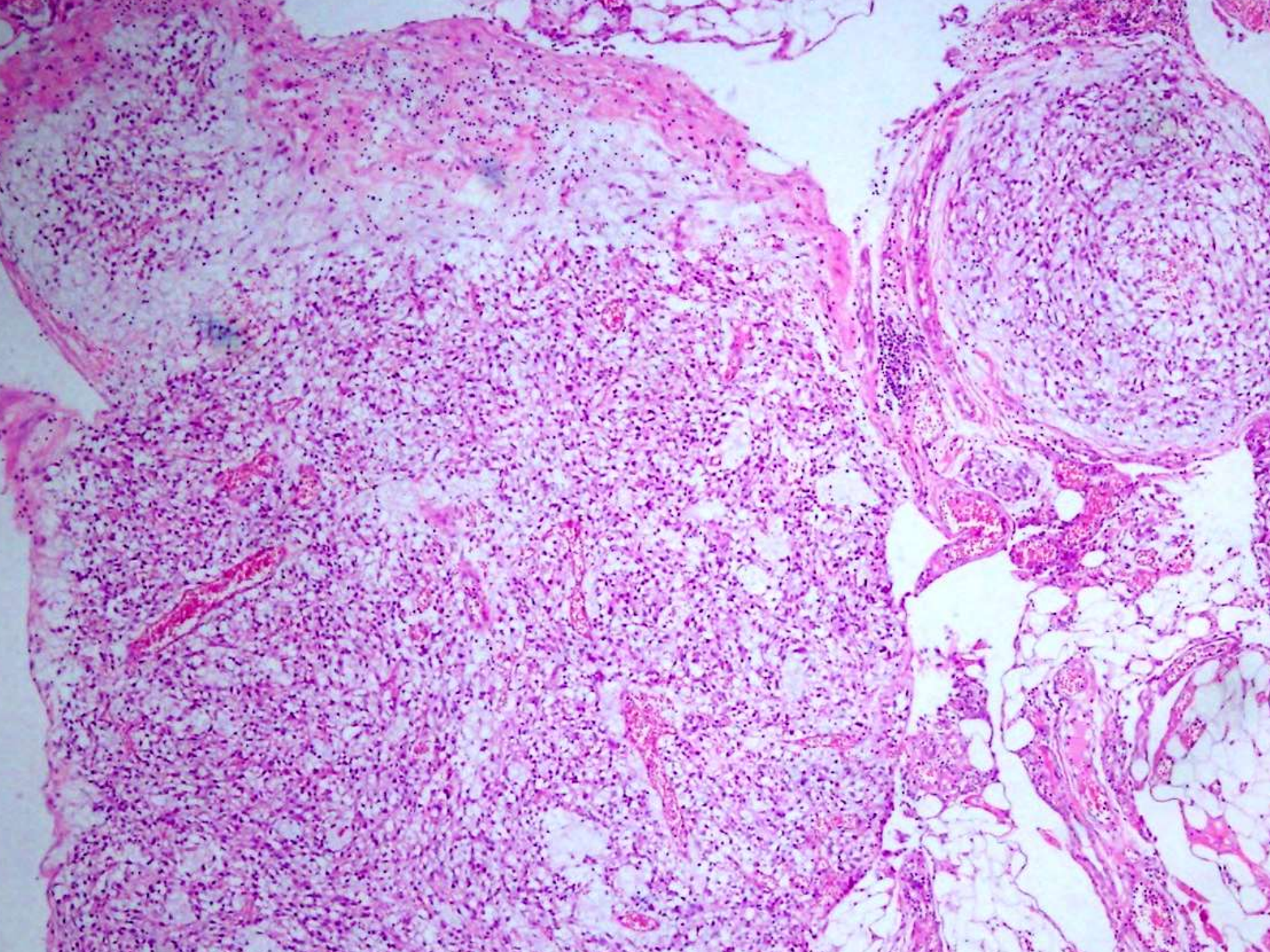


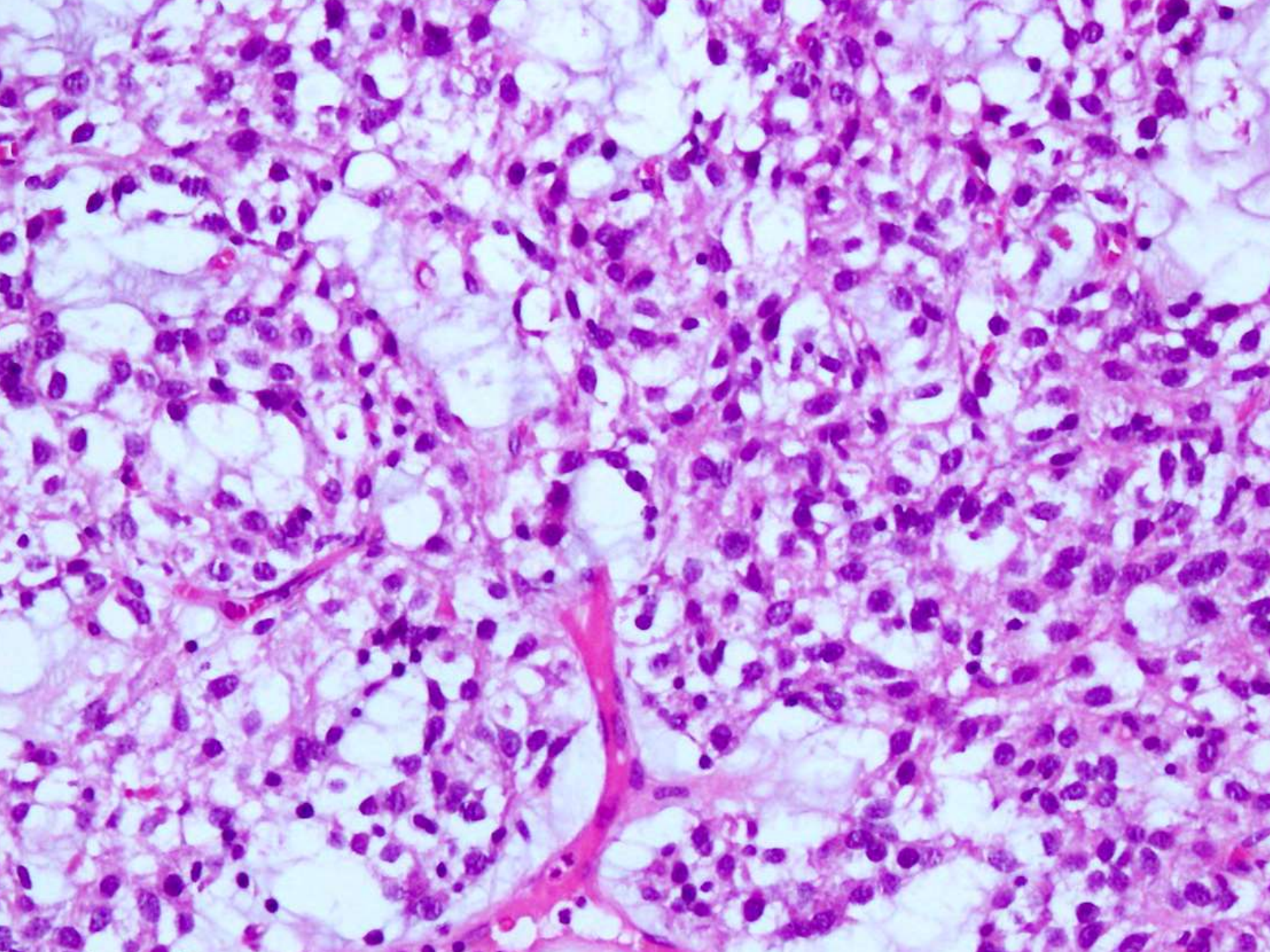


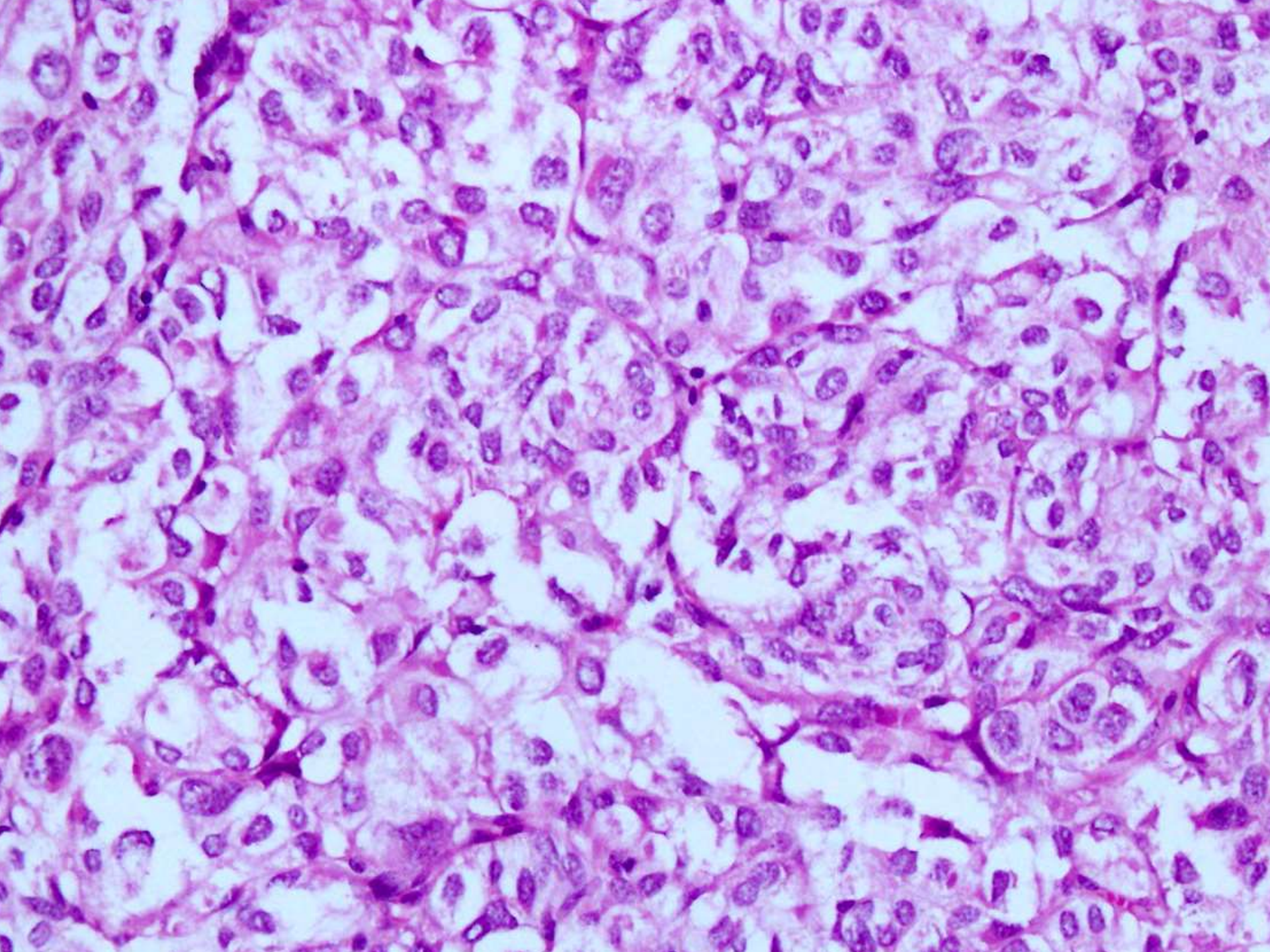
SB 6185

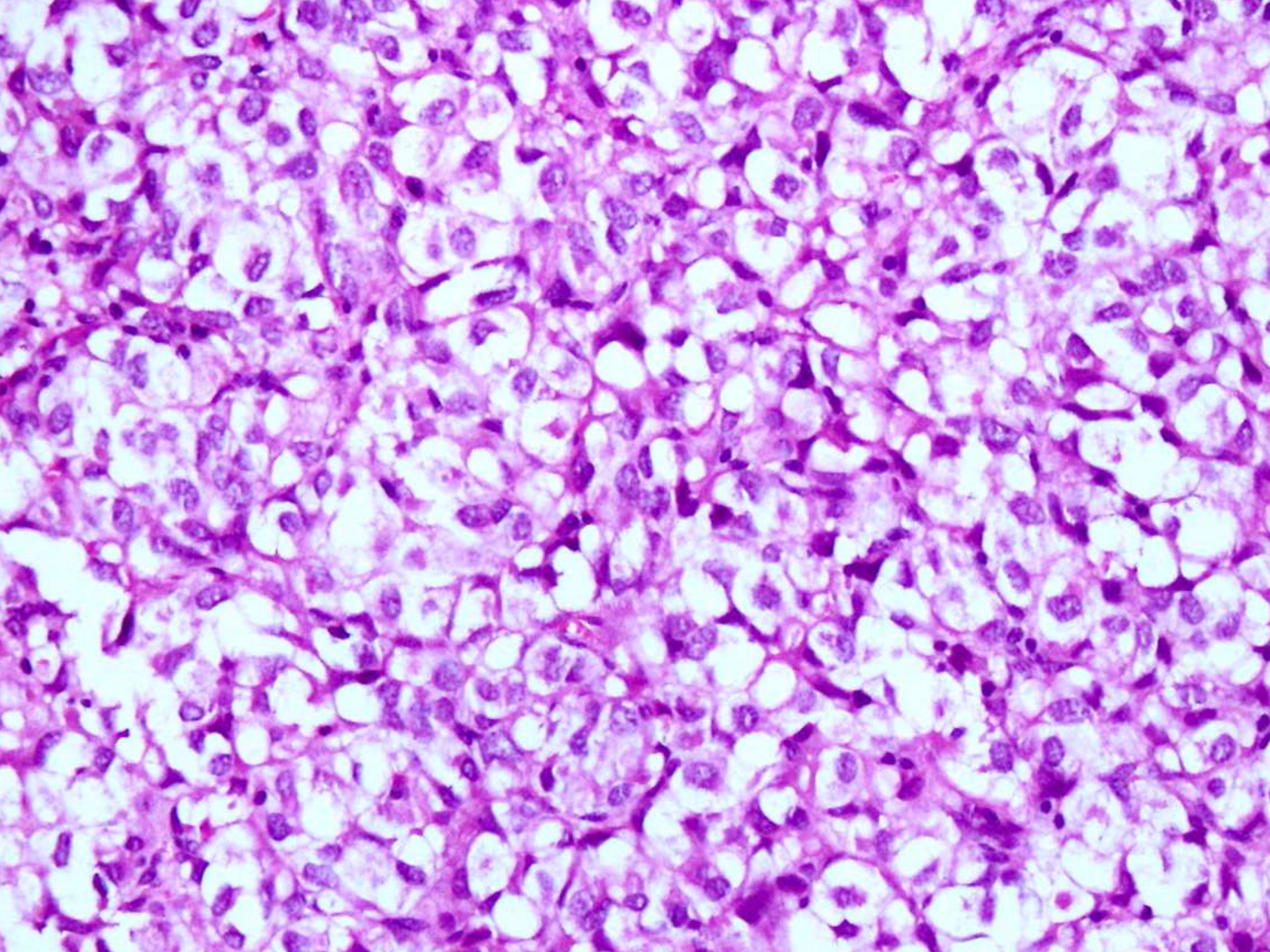
Nabeen Nayak; Sir Ganga Ram Hospital, New Dehli

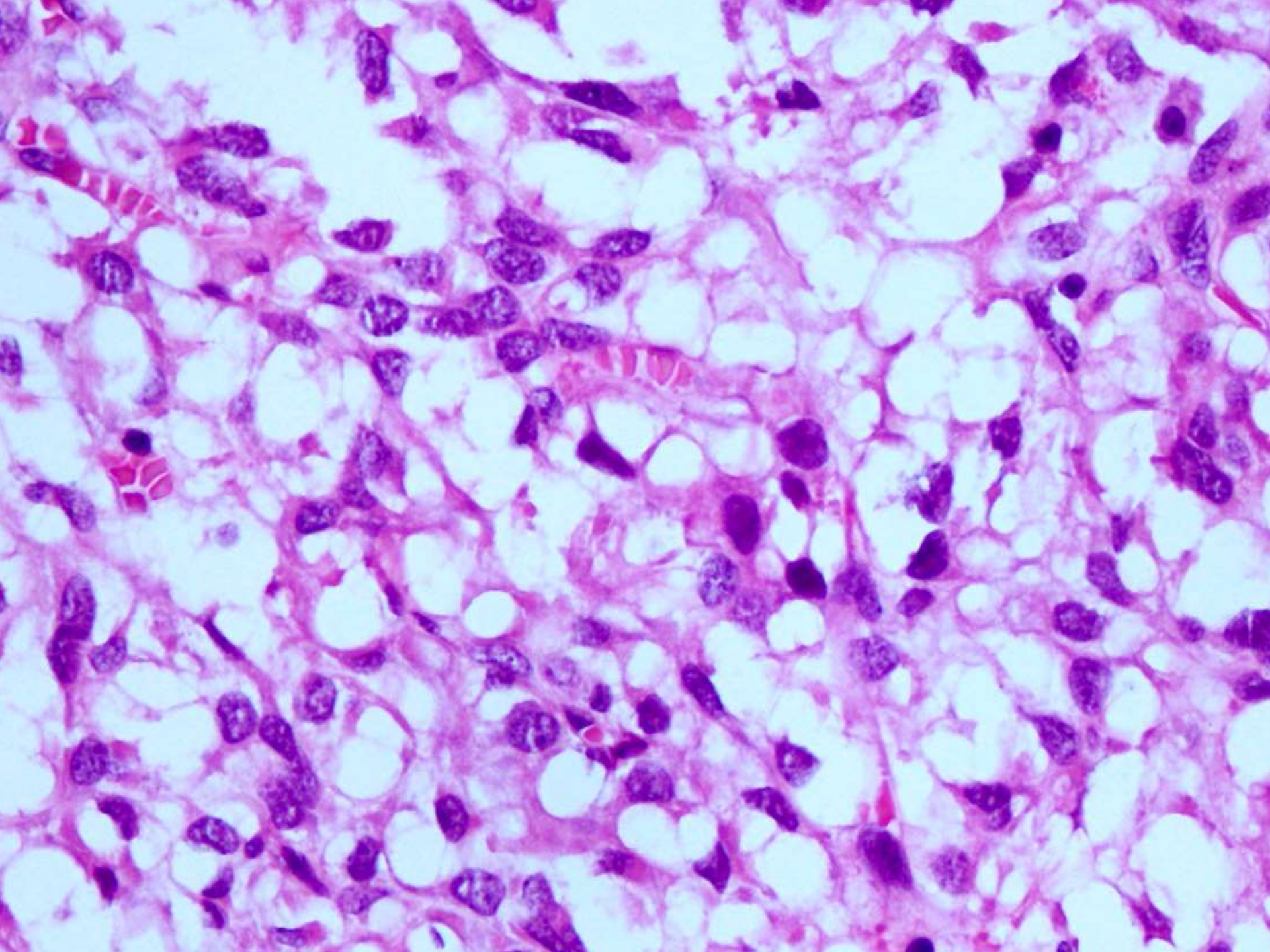
A 34-yr-old woman was referred to the Gastroenterology service because of lower abdominal pain and constipation for 5 days with no other comorbidity. Except for some lower abdominal fullness, routine physical examination and investigations revealed no significant abnormality. Thoraco-abdominal CT scans showed an ill-defined mass 10x9.6 cm in right pelvis inseparable from that side ovary. Diagnostic laparoscopy showed abdominal caking and some hemoperitoneum in that area adherent to right ovary with nodules (? metastatic) in lower omentum. Multiple biopsies were taken.

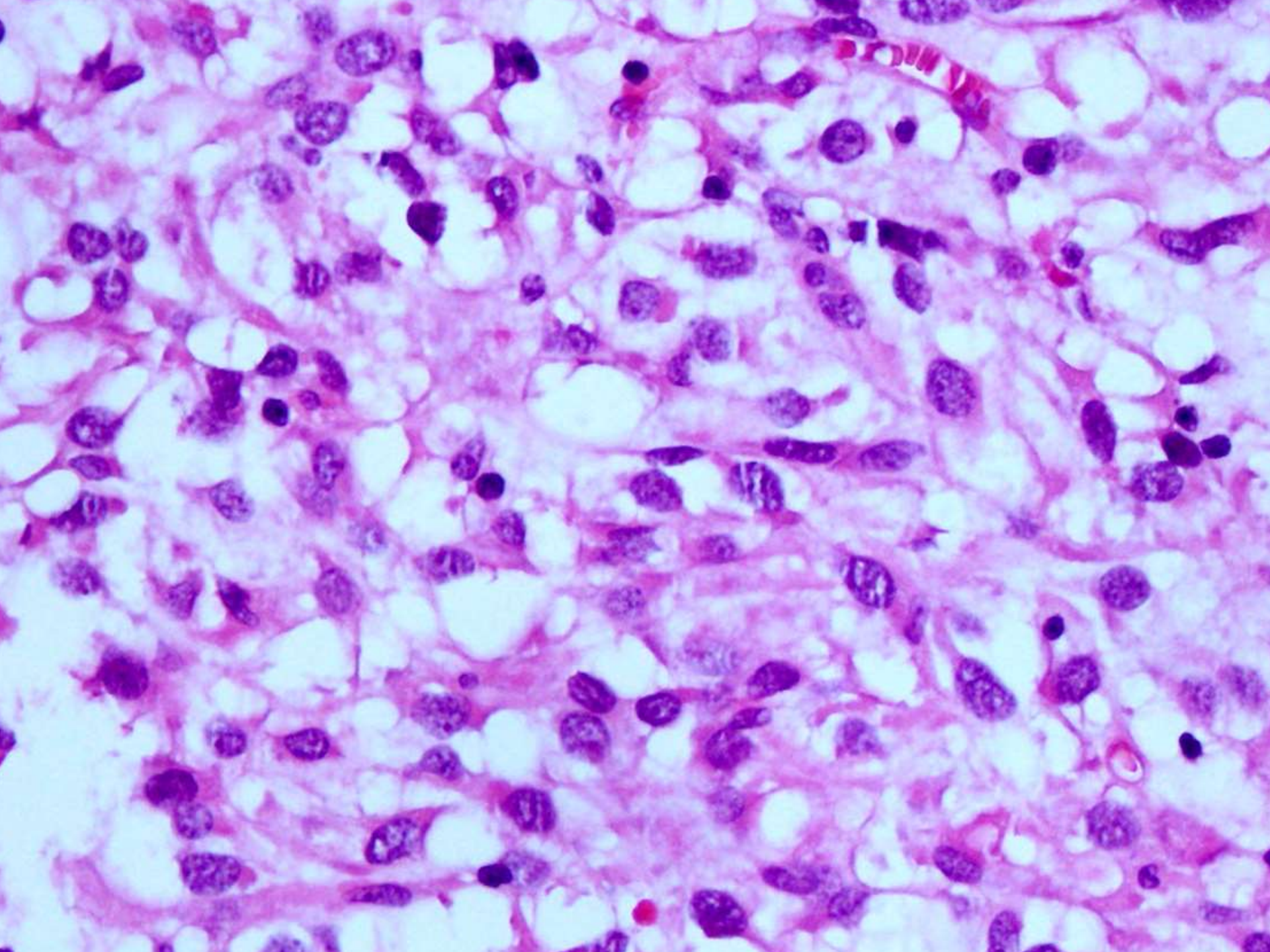








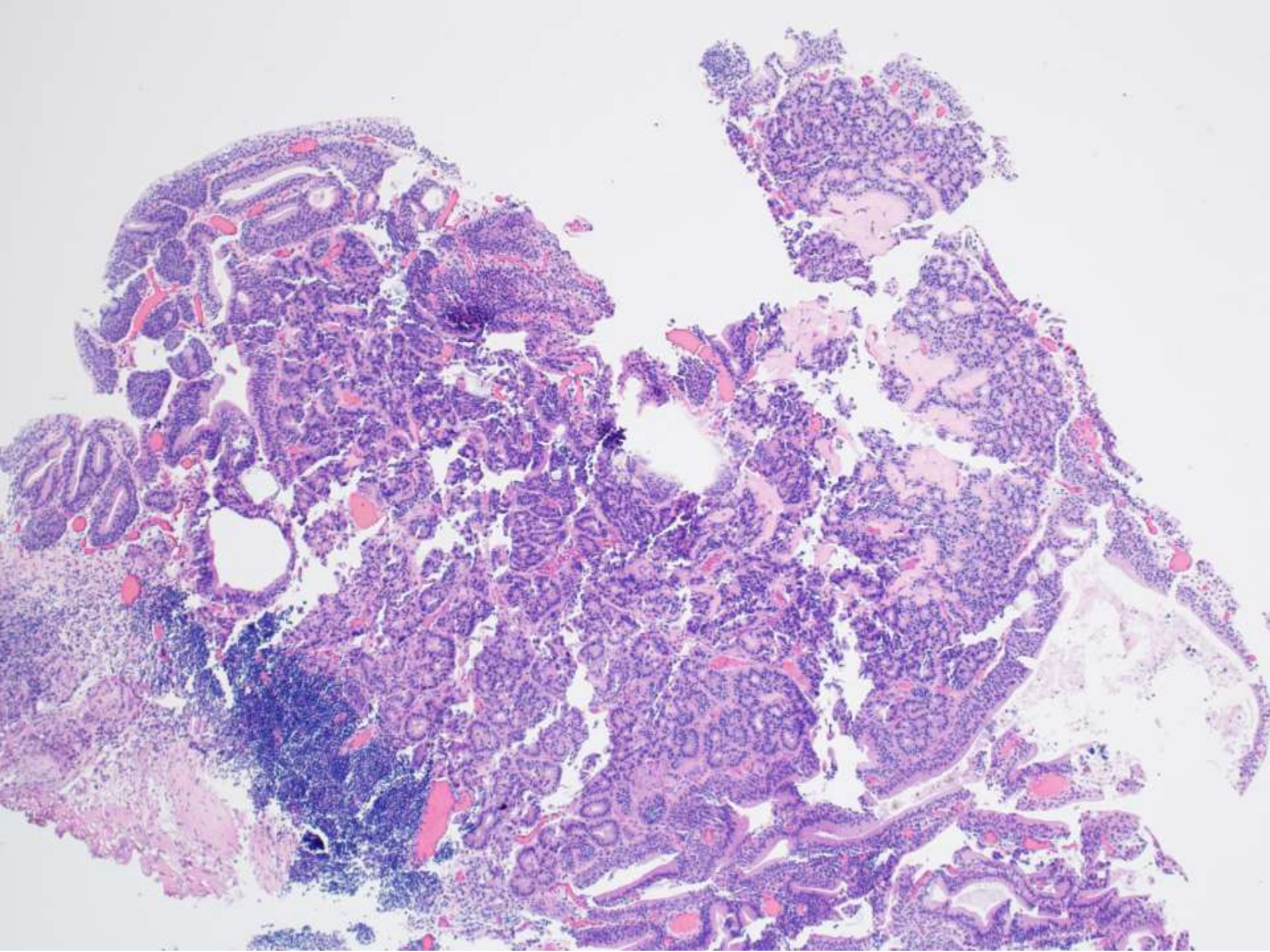


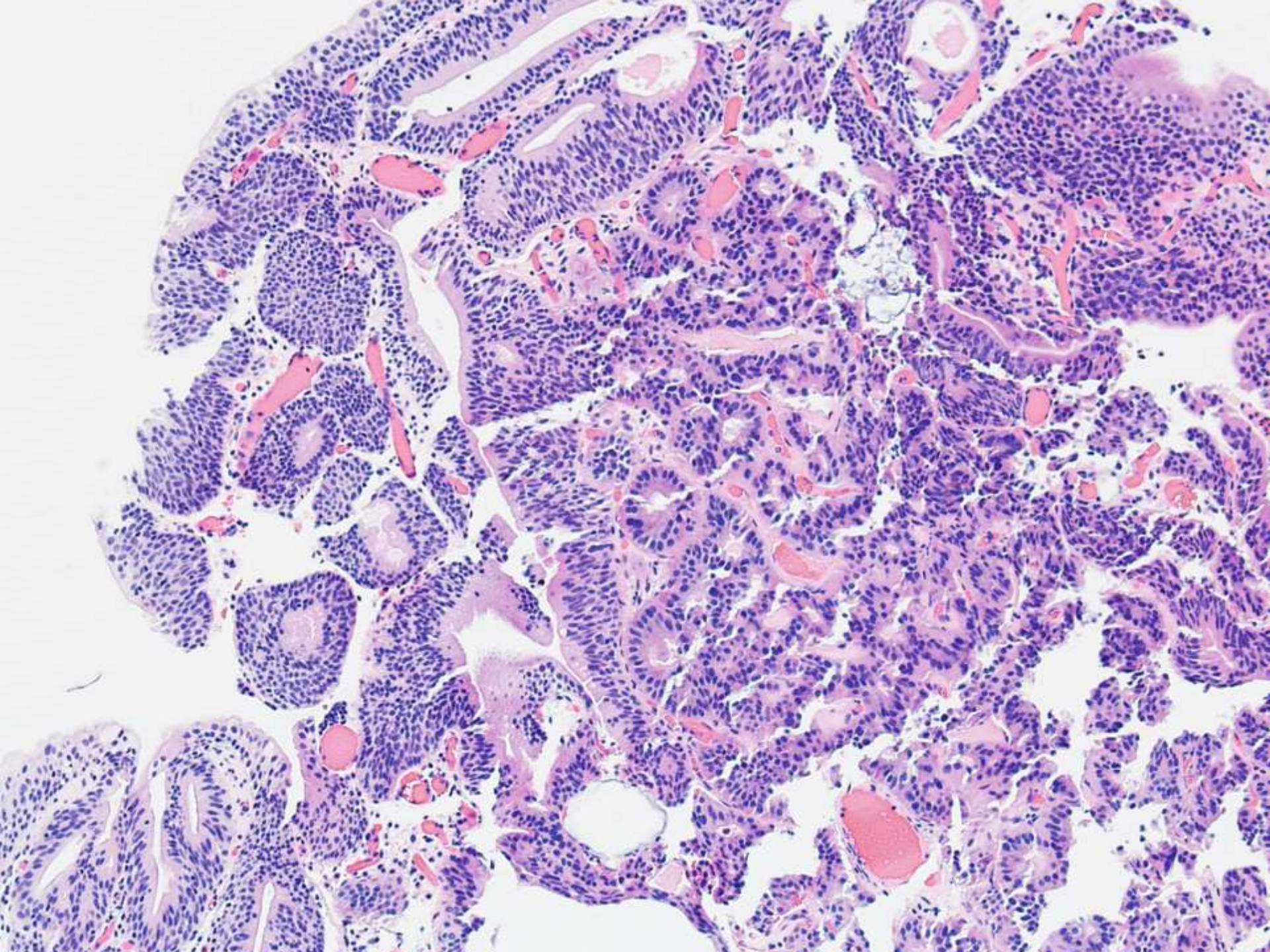


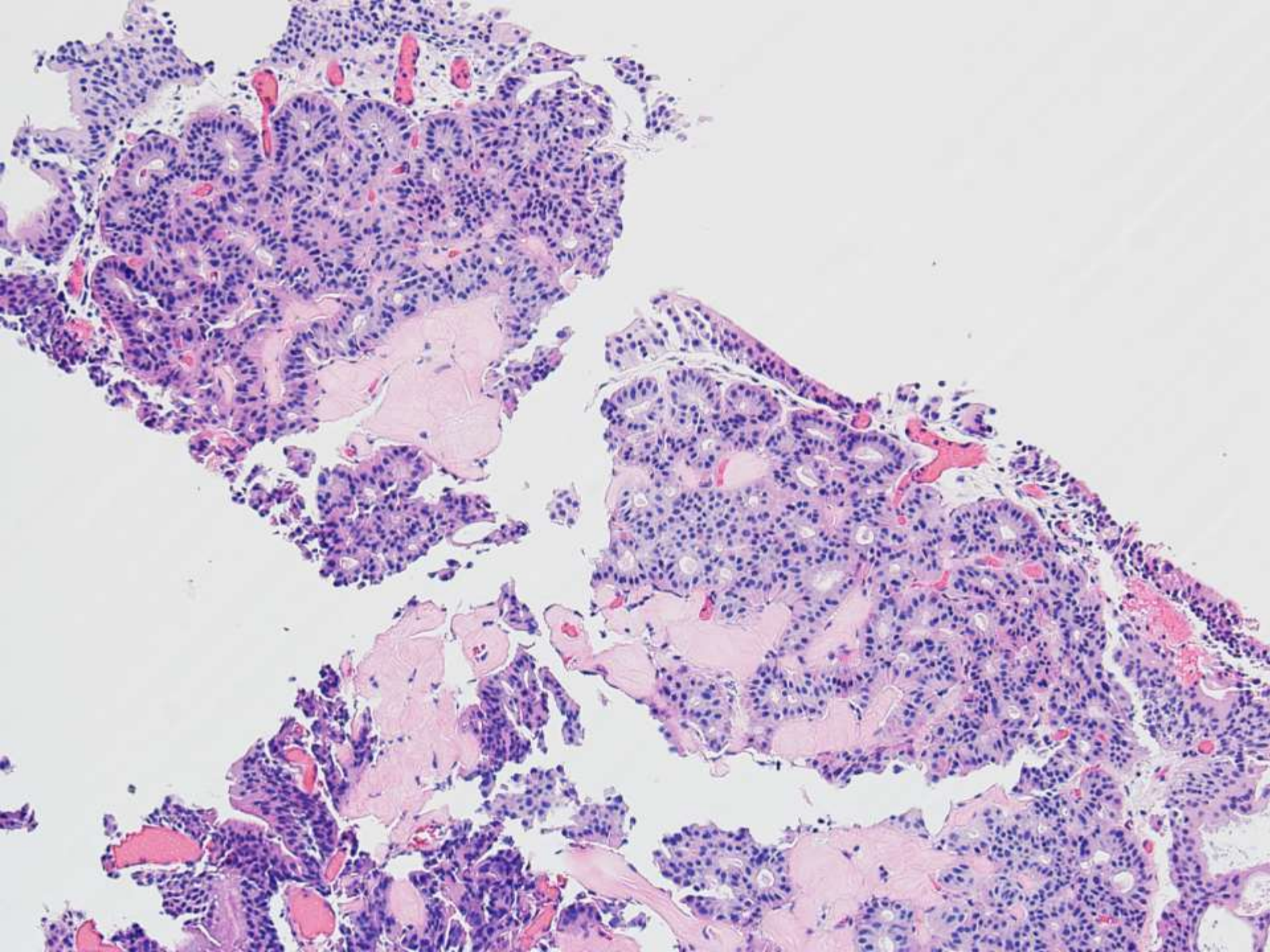
SB 6186

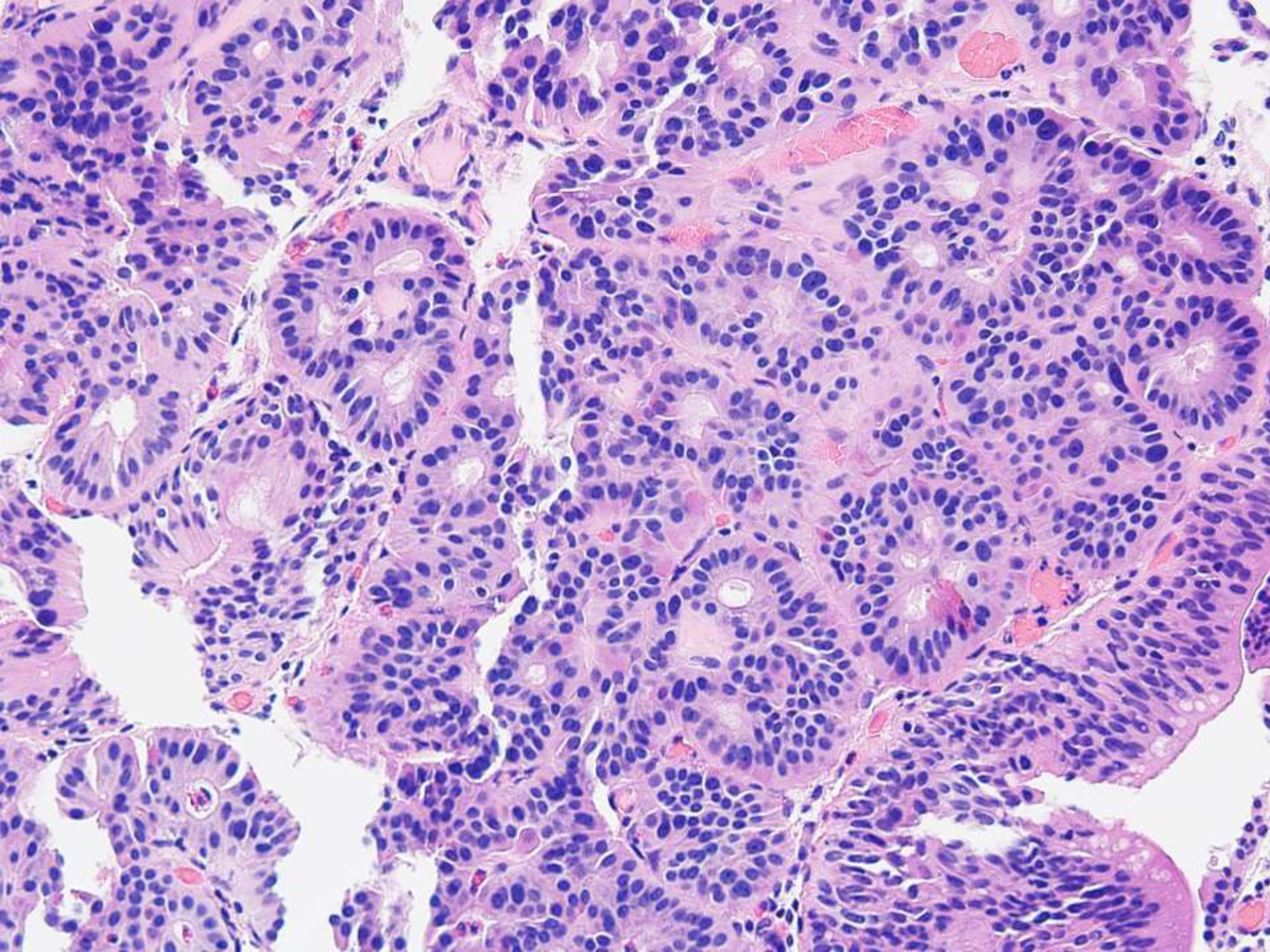
Sunny Kao; Stanford

80-year-old man with bladder
tumor for TURBT.





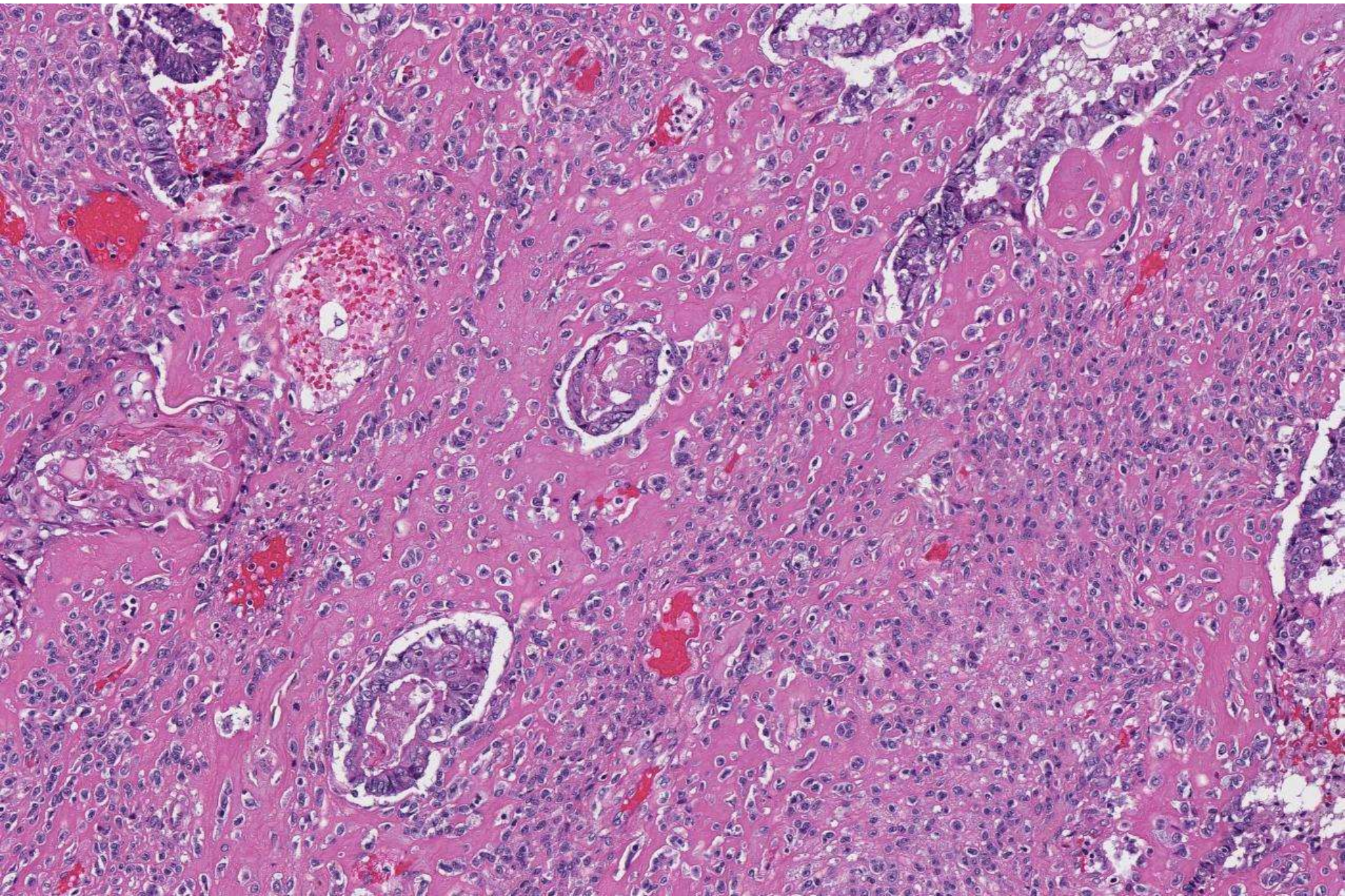


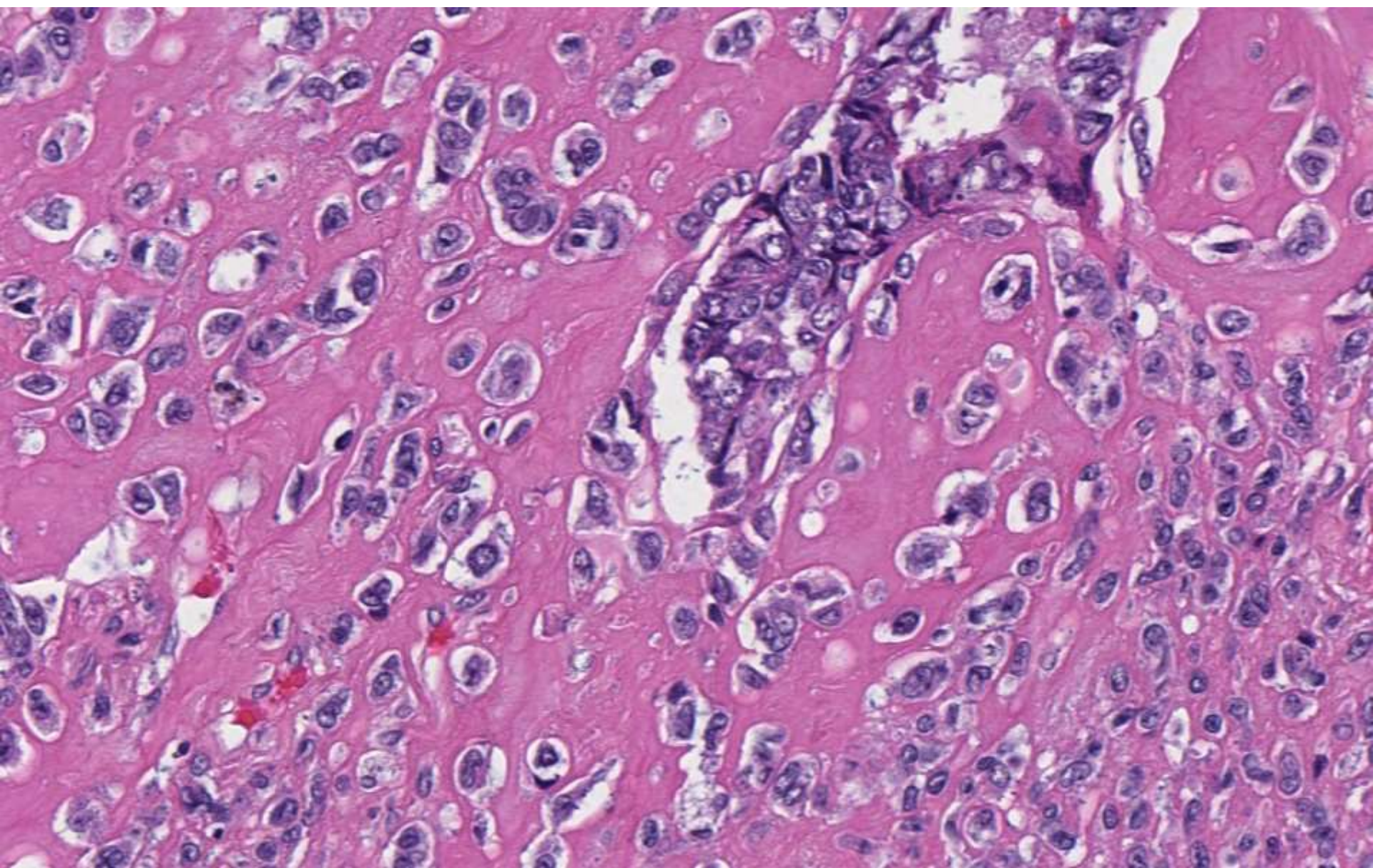


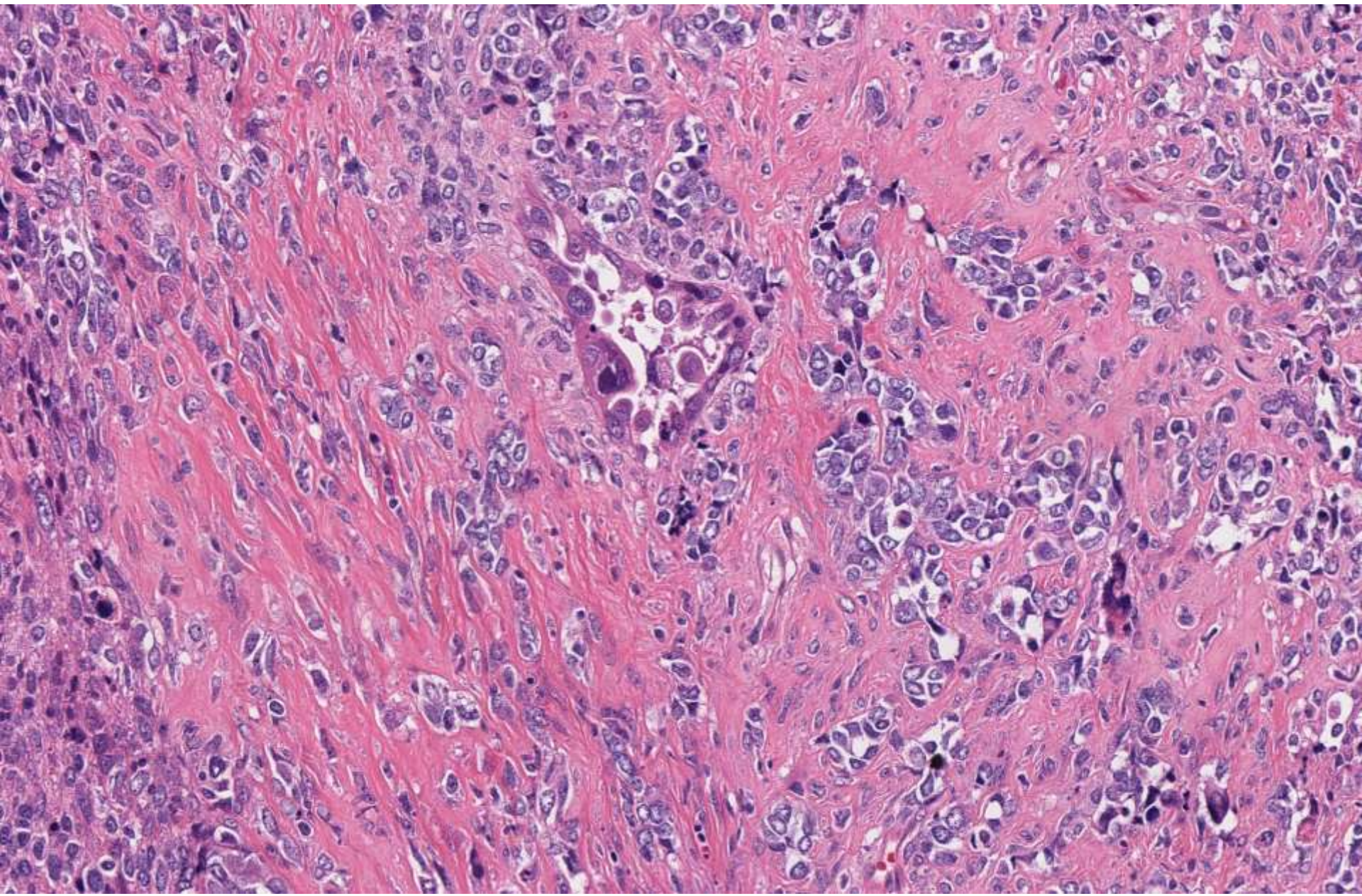
SB 6187

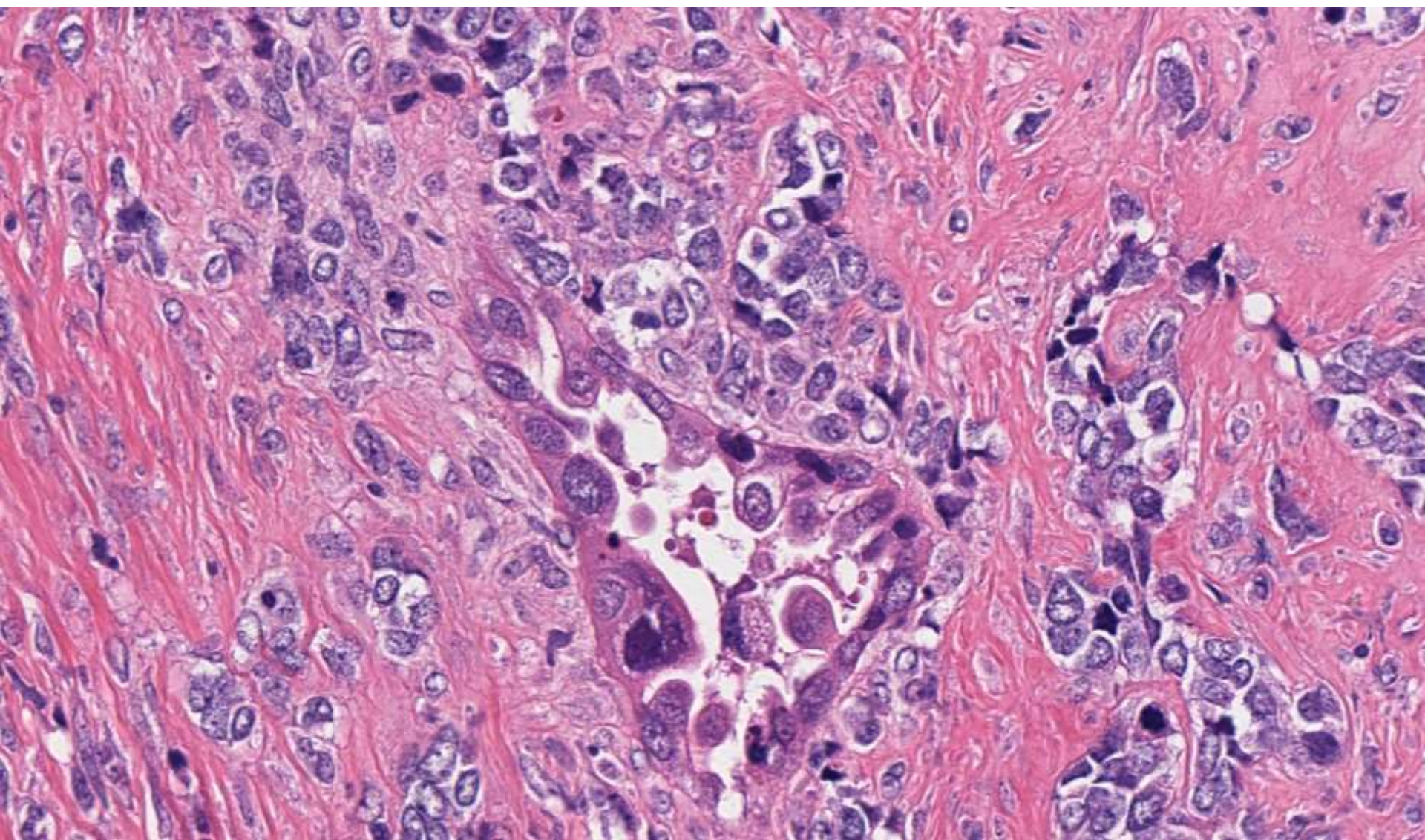
Ankur Sangoi; El Camino Hospital

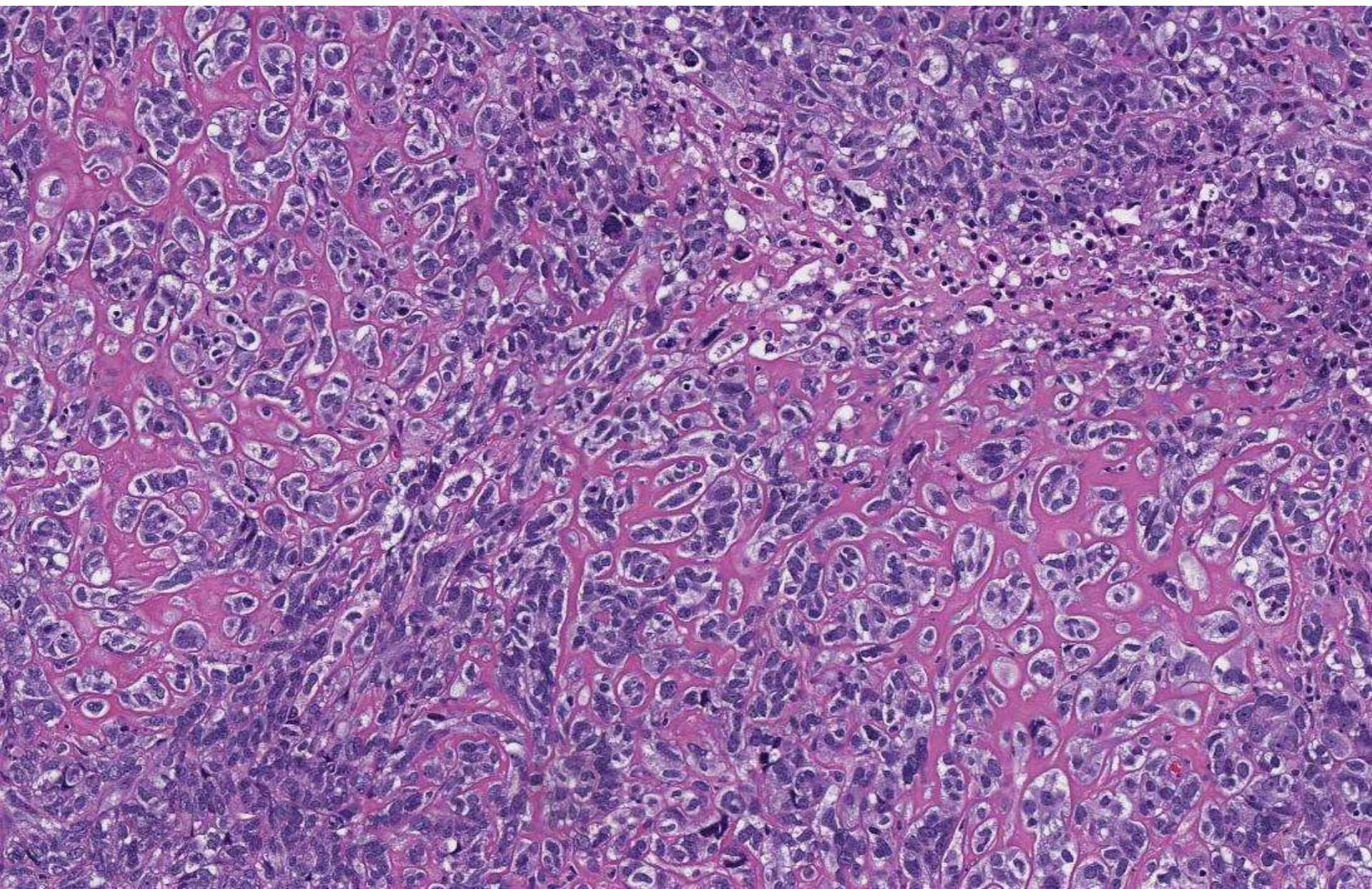
Middle-aged woman with polypoid endometrial mass, invading inner myometrium; staging lymph nodes were negative. Sections from the hysterectomy submitted.

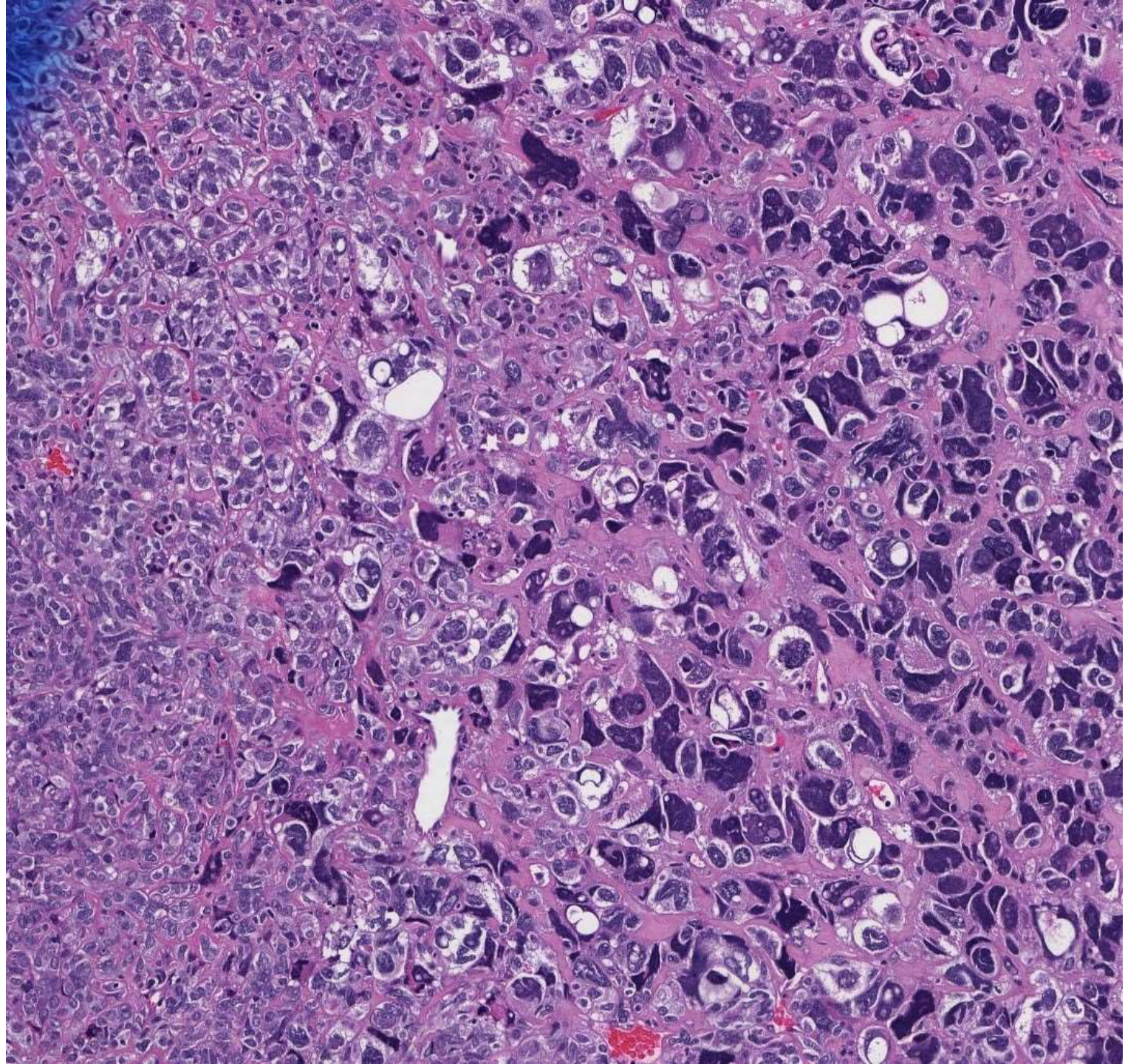


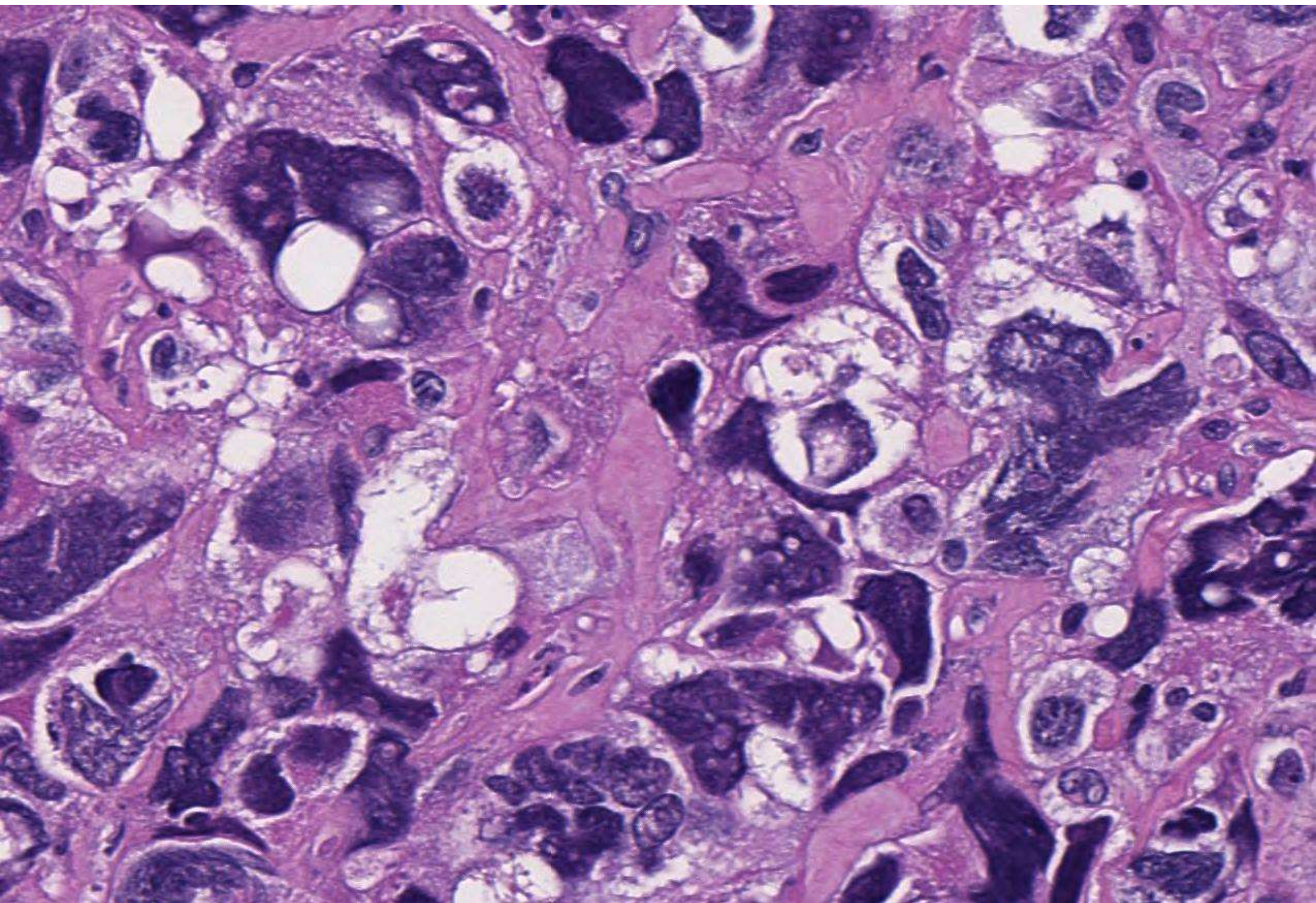






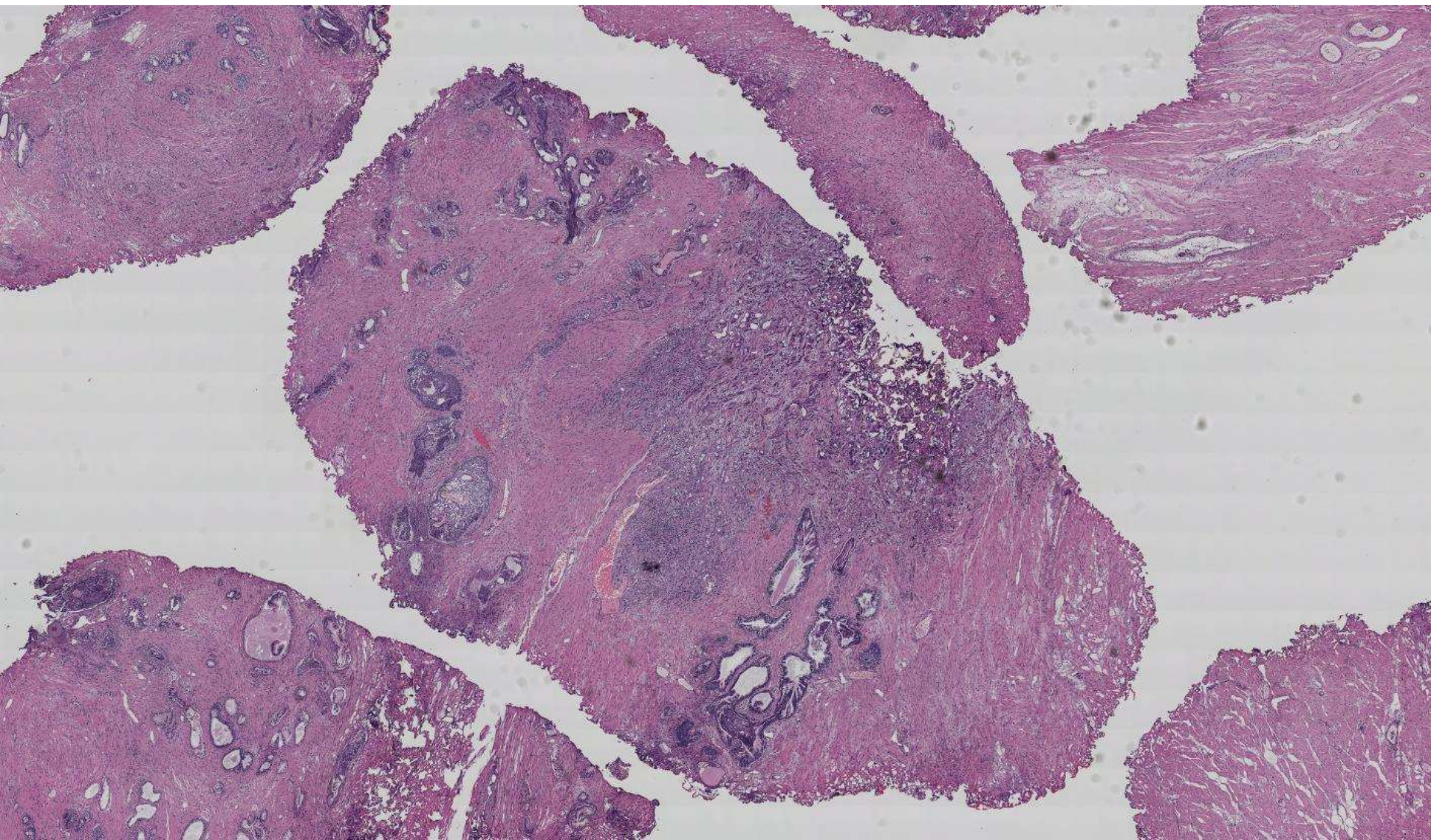


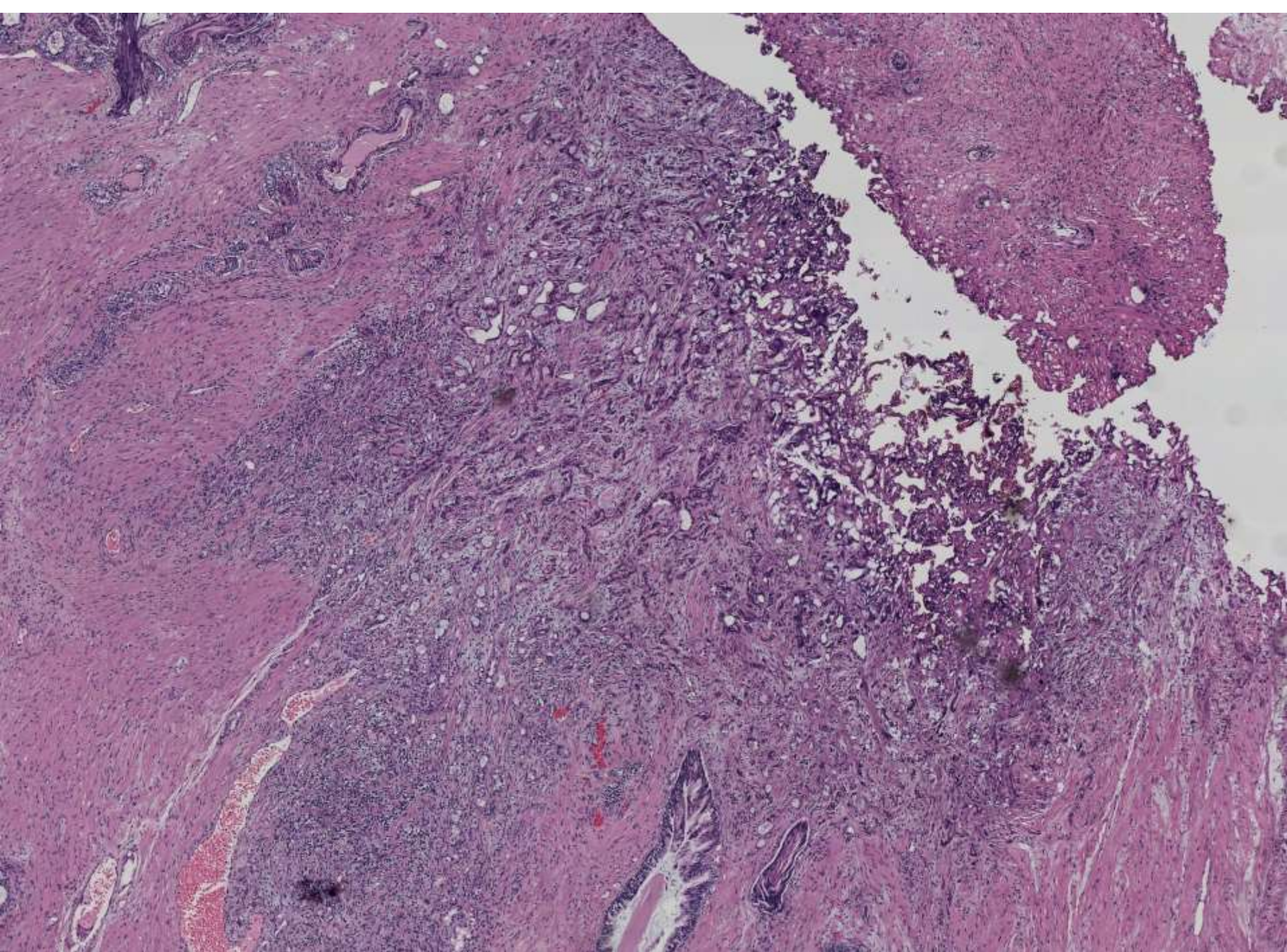


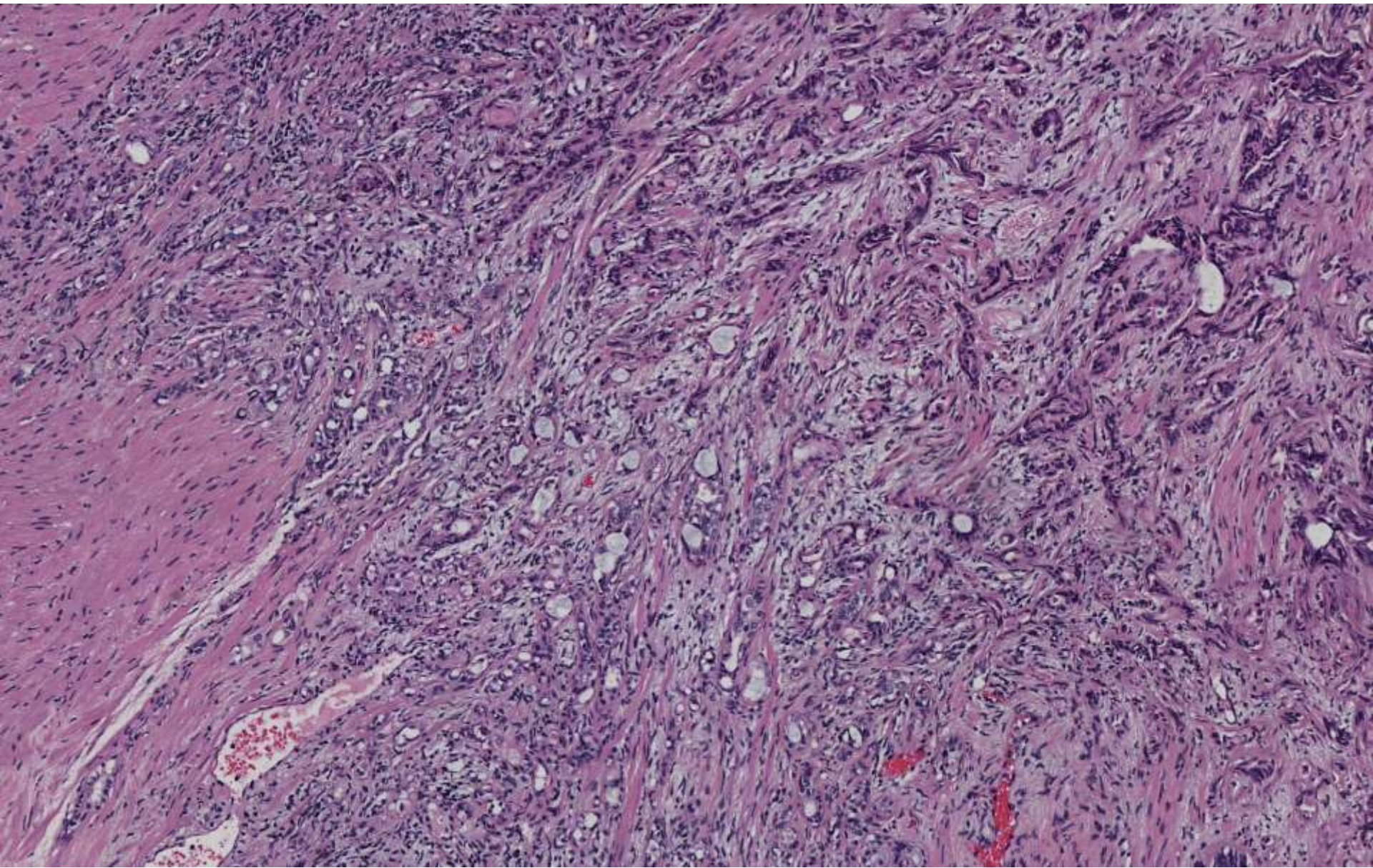


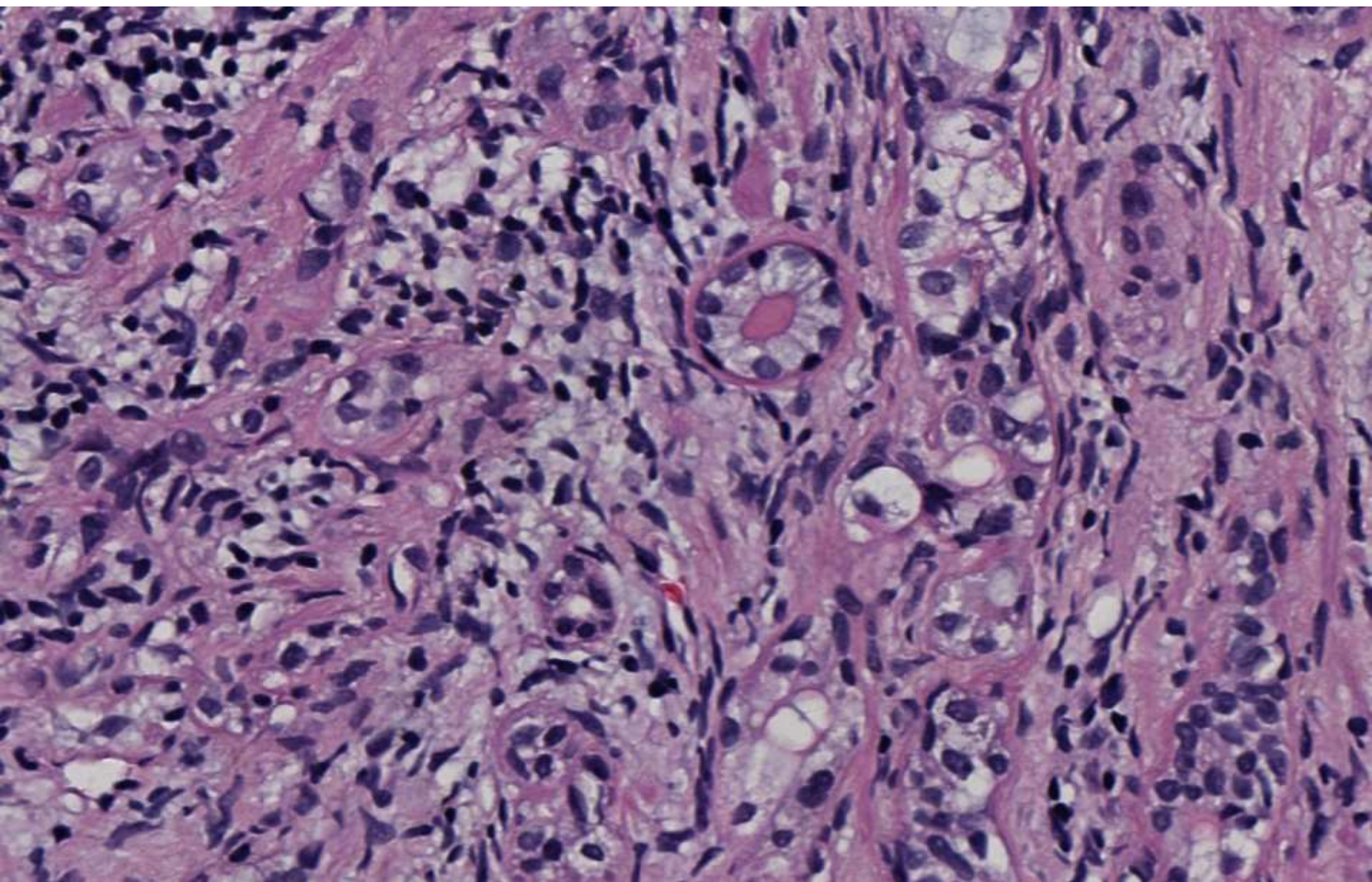
SB 6188
(scanned slide available)

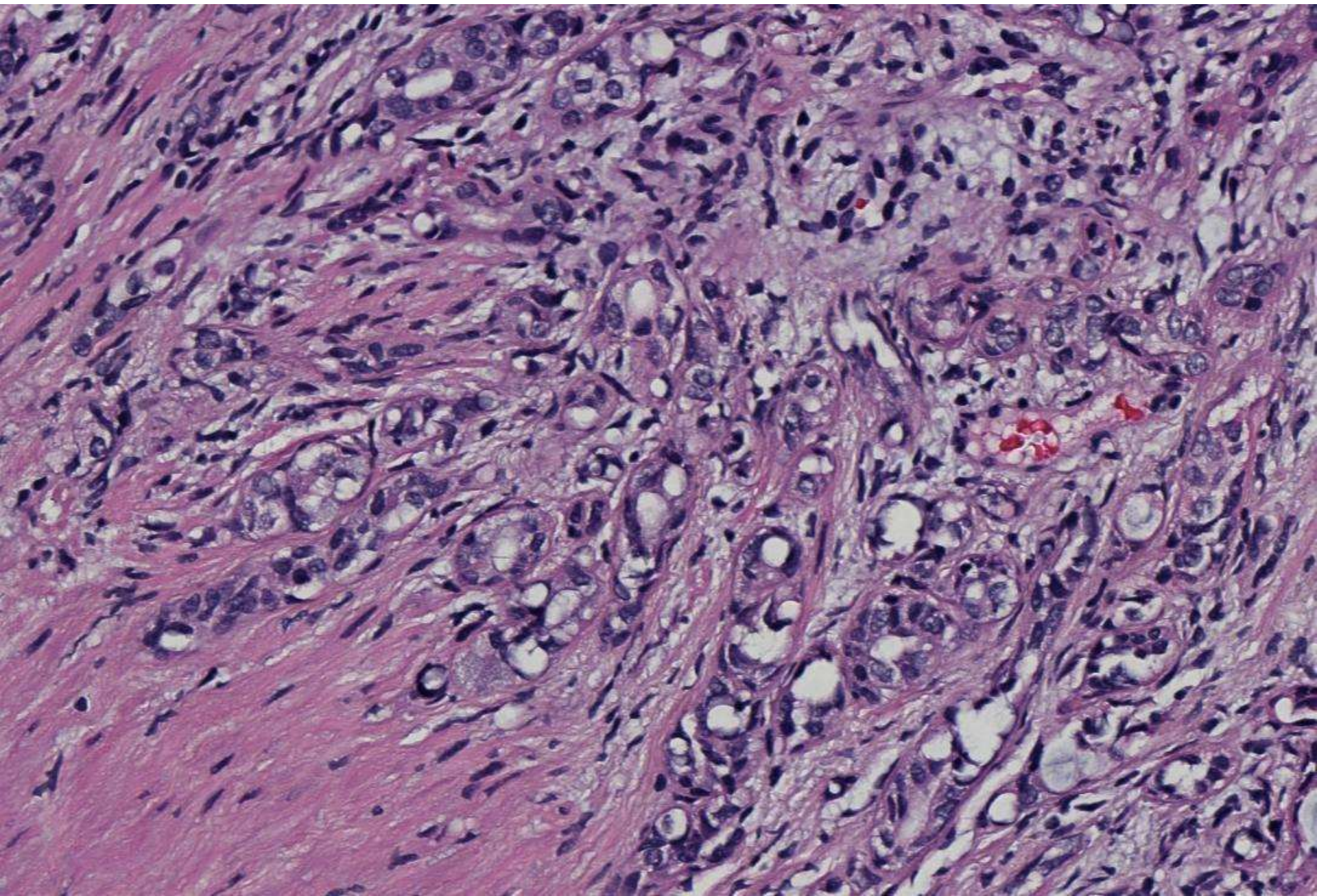
Ankur Sangoi; El Camino Hospital
62-year-old man with BPH. TURP
performed.

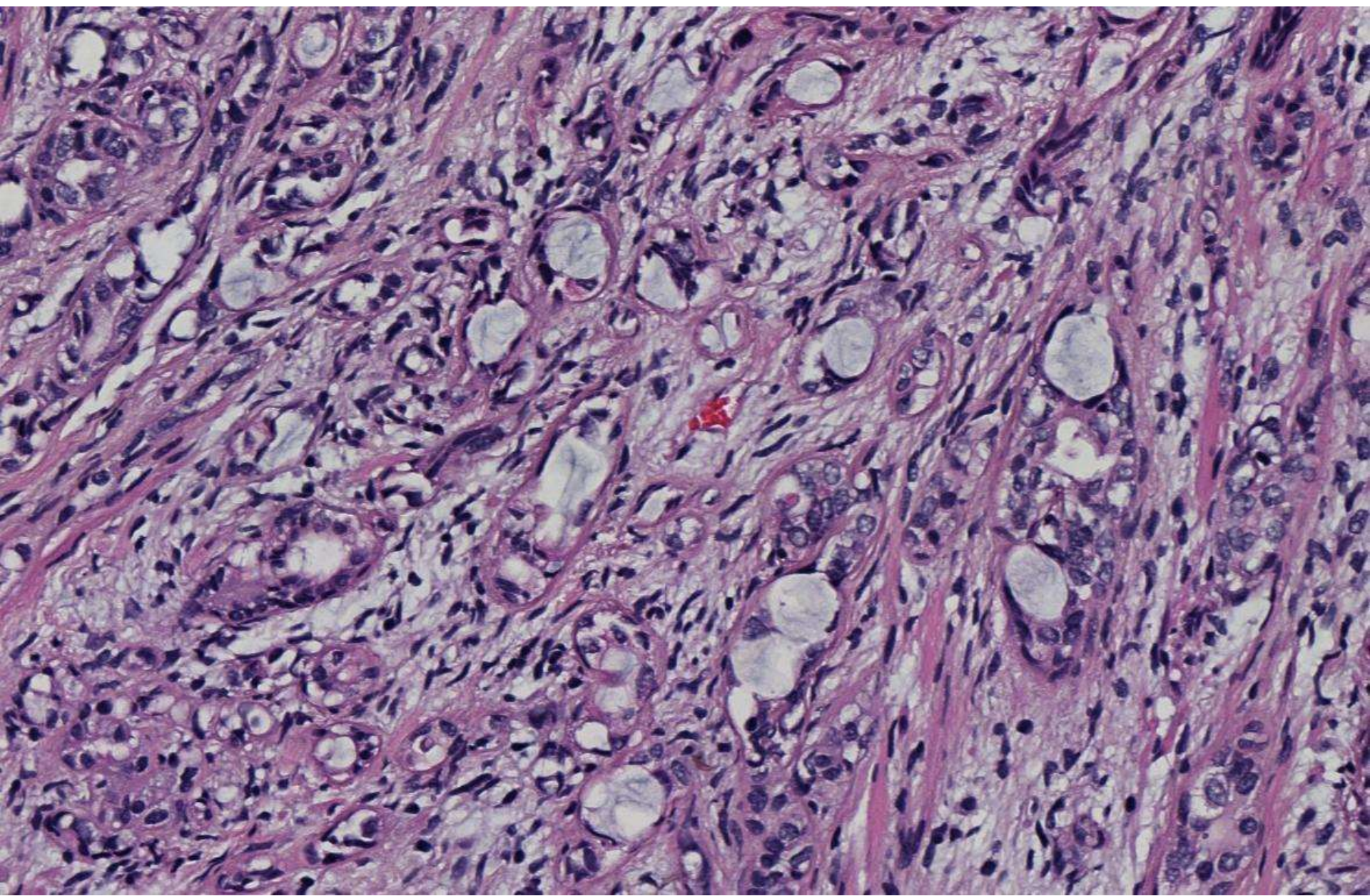


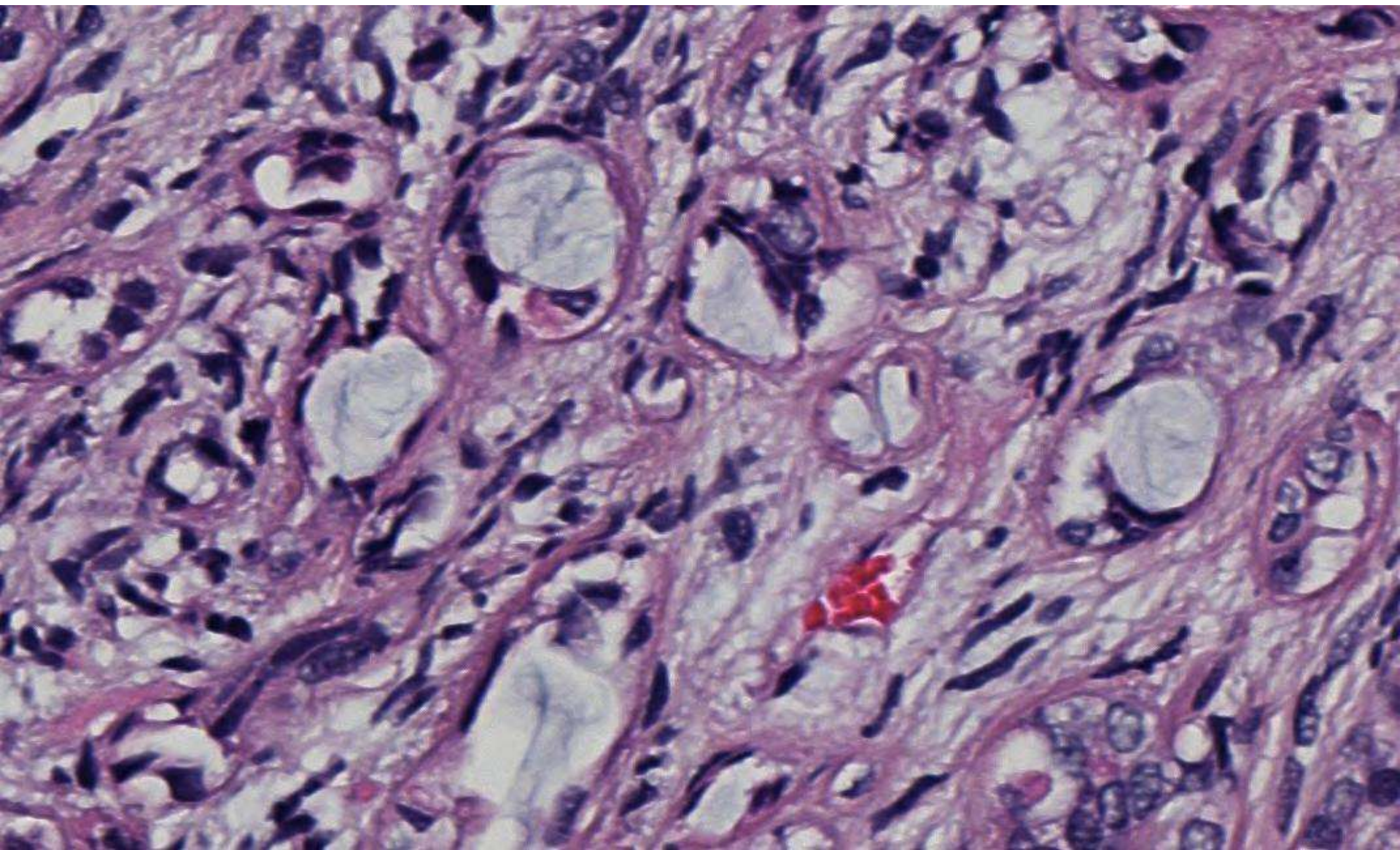






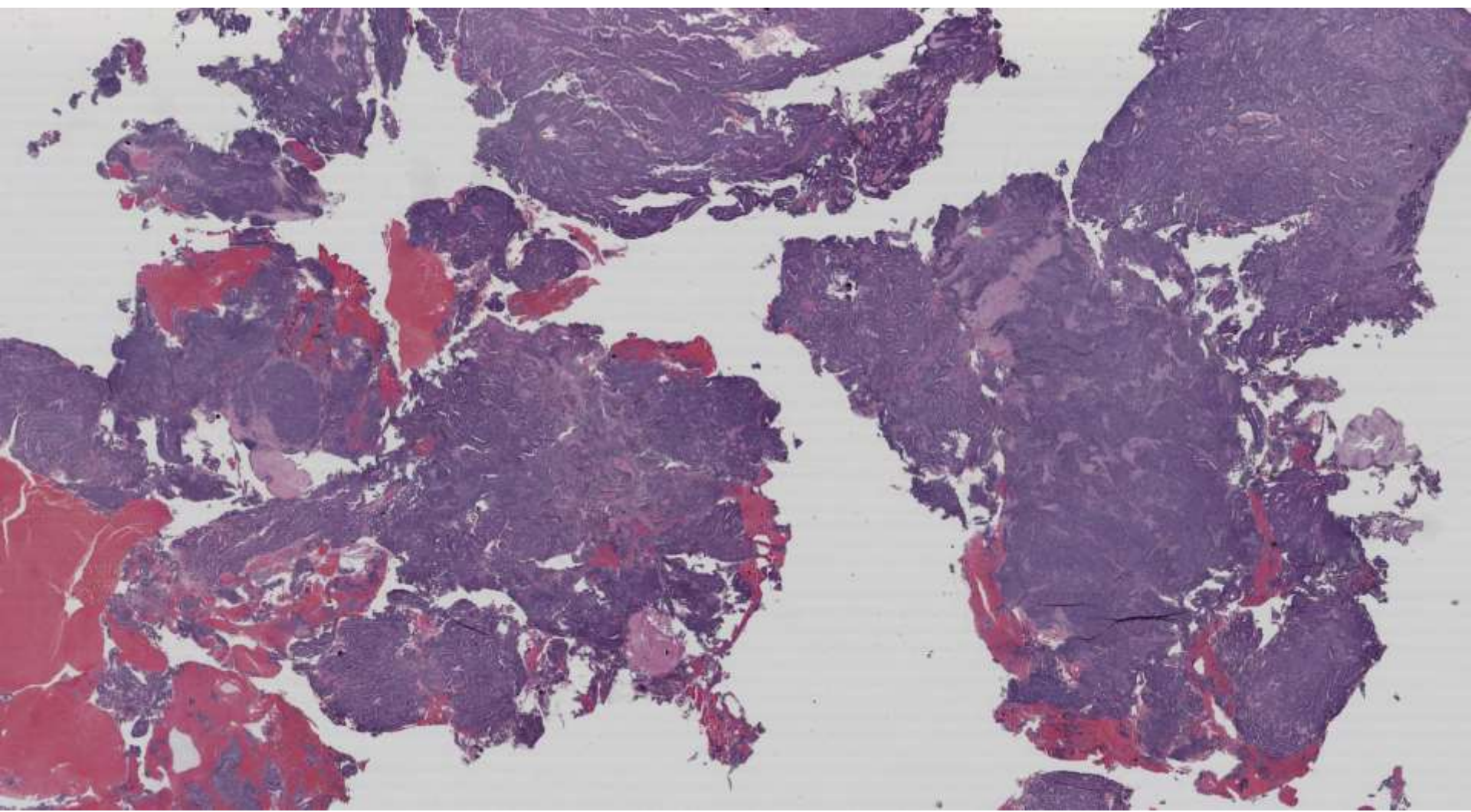


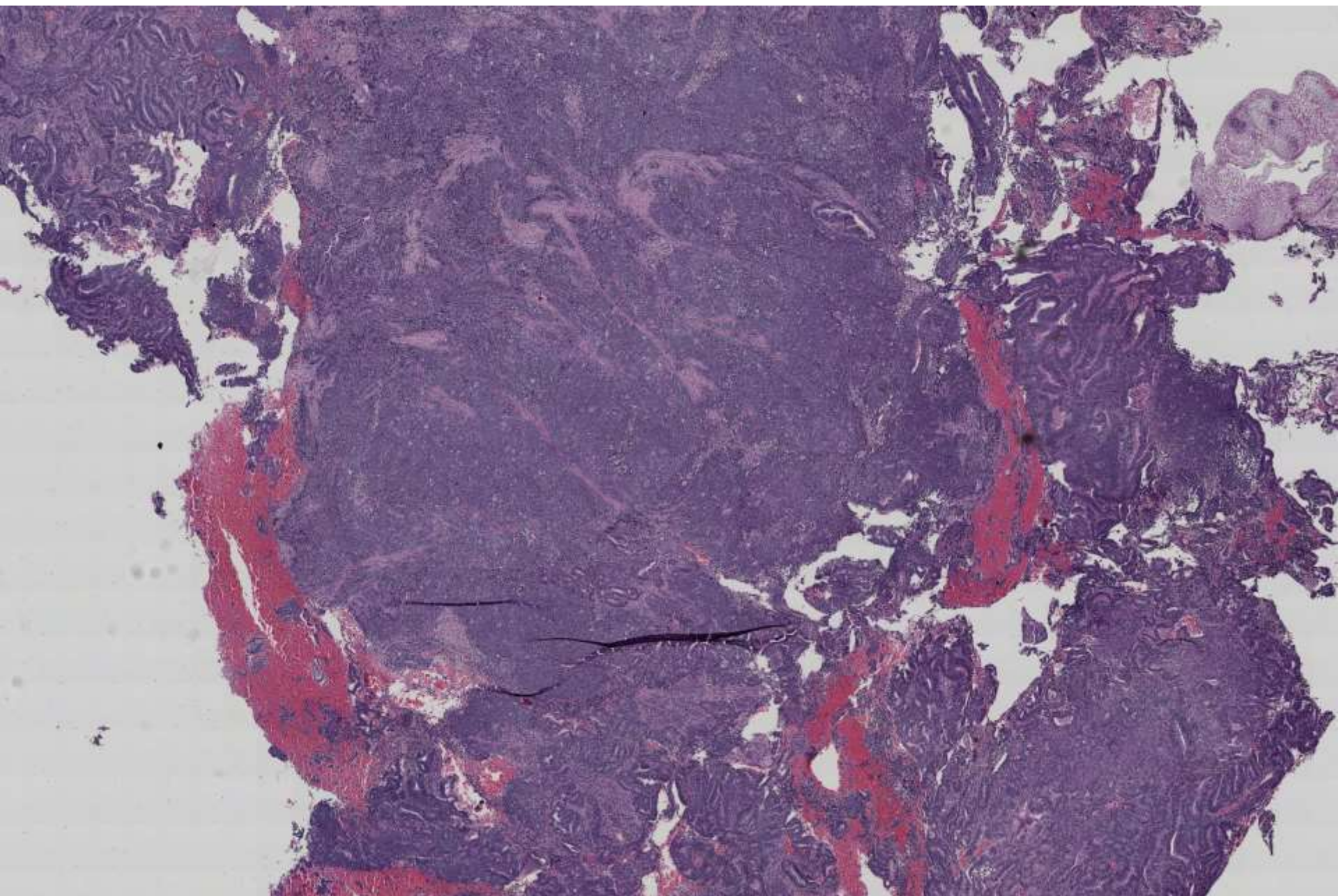


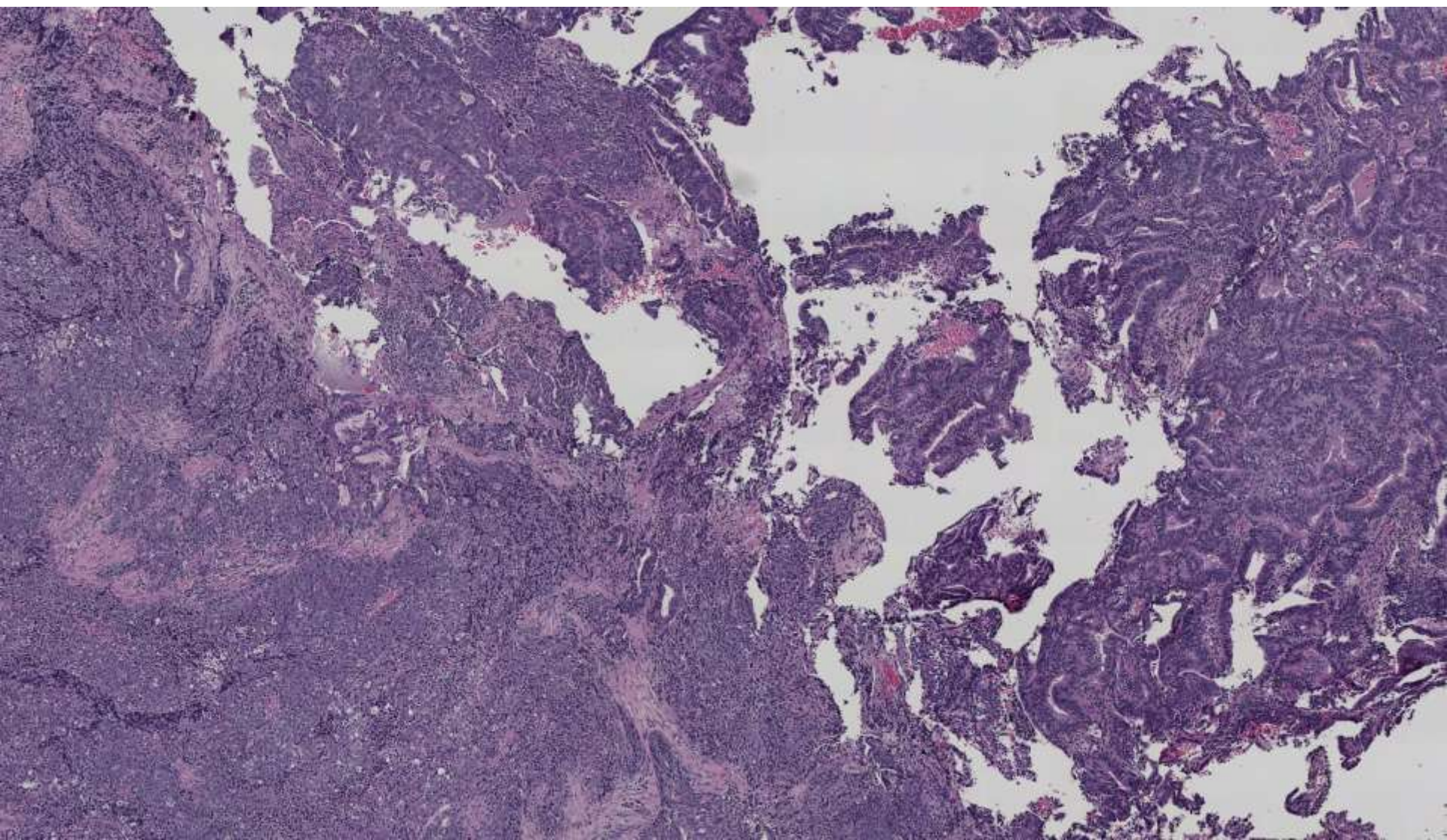


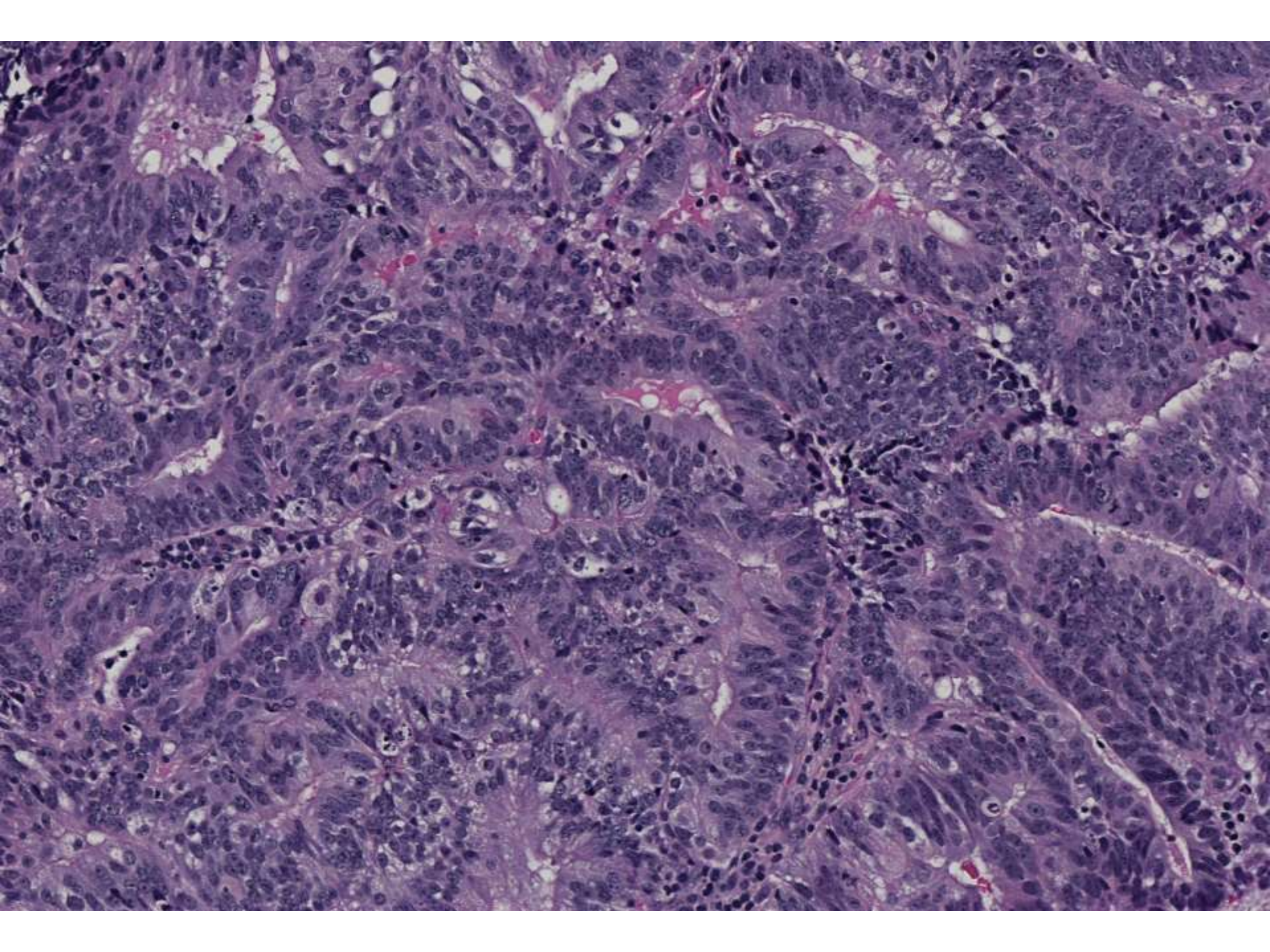
SB 6189
(scanned slide available)

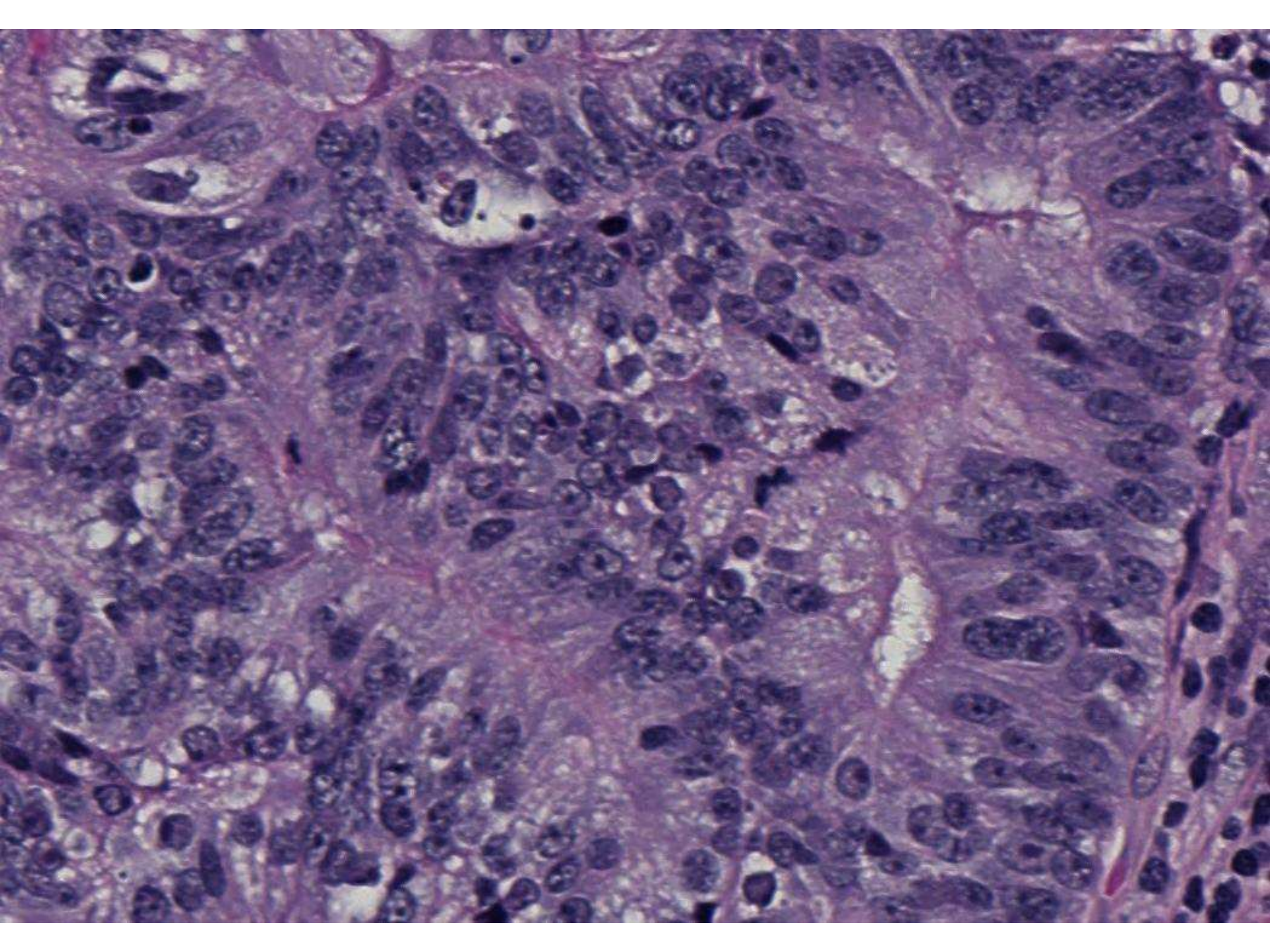
Ankur Sangoi; El Camino Hospital
67-year-old woman with endometrial
biopsy.

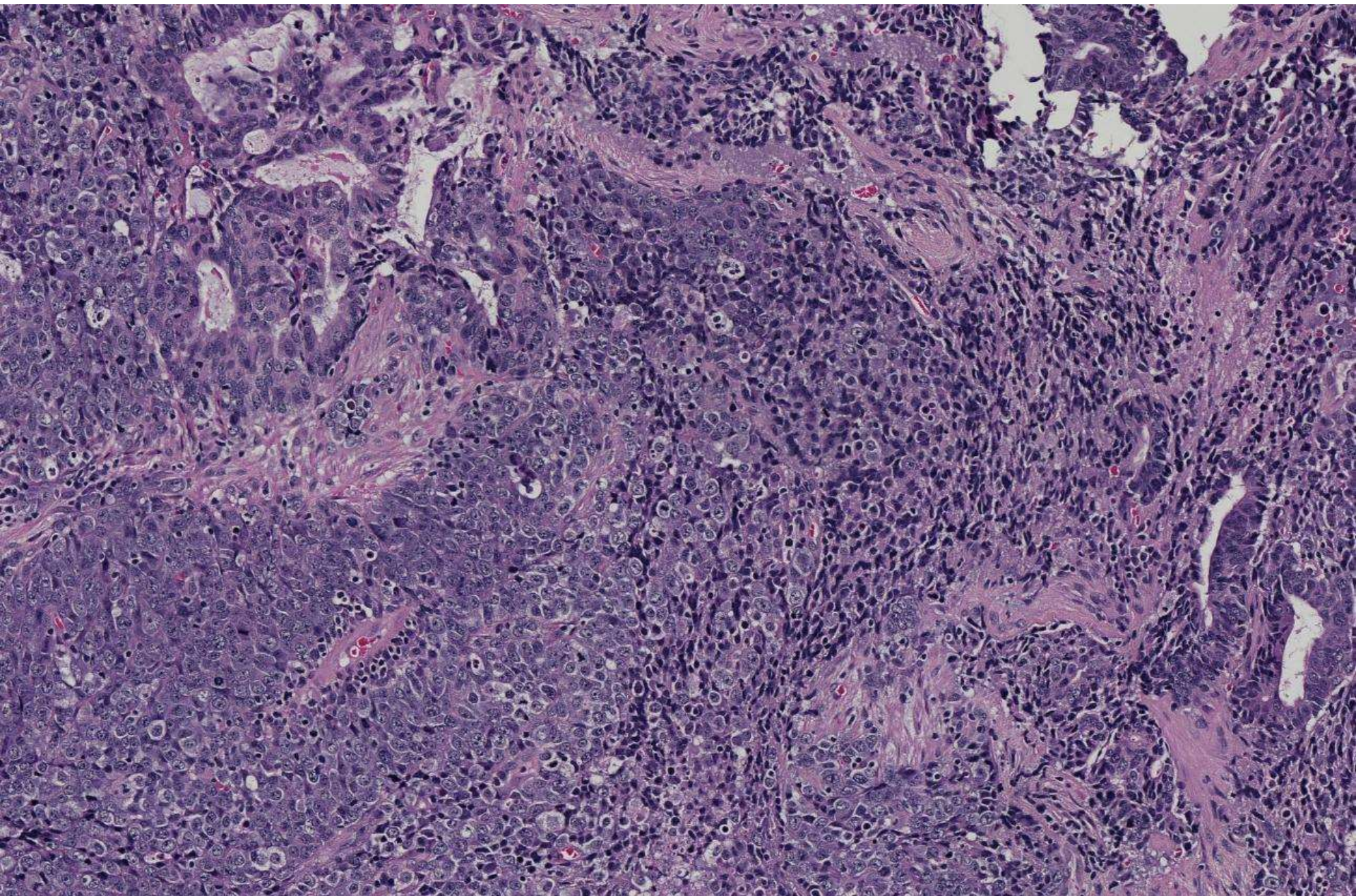


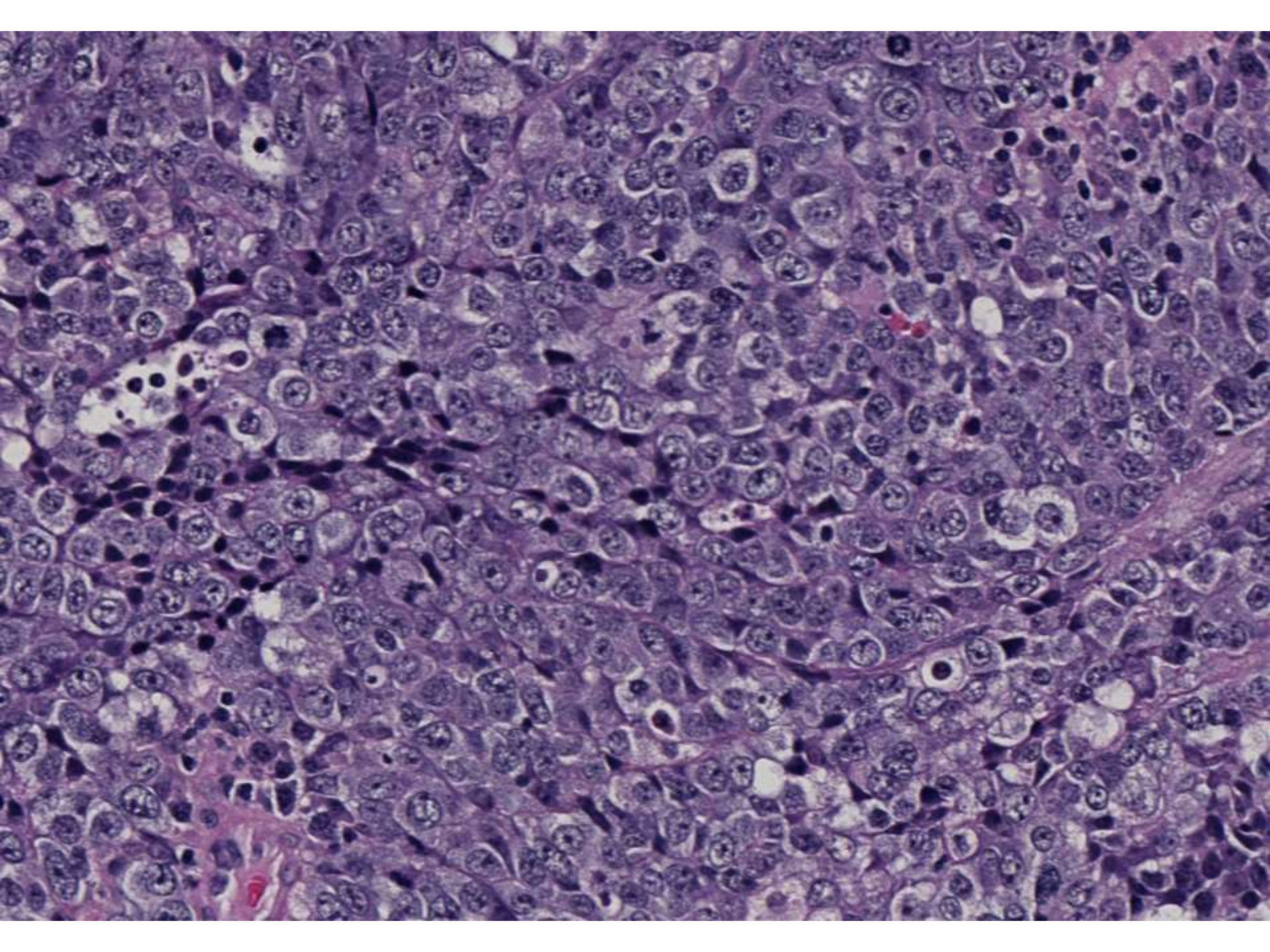


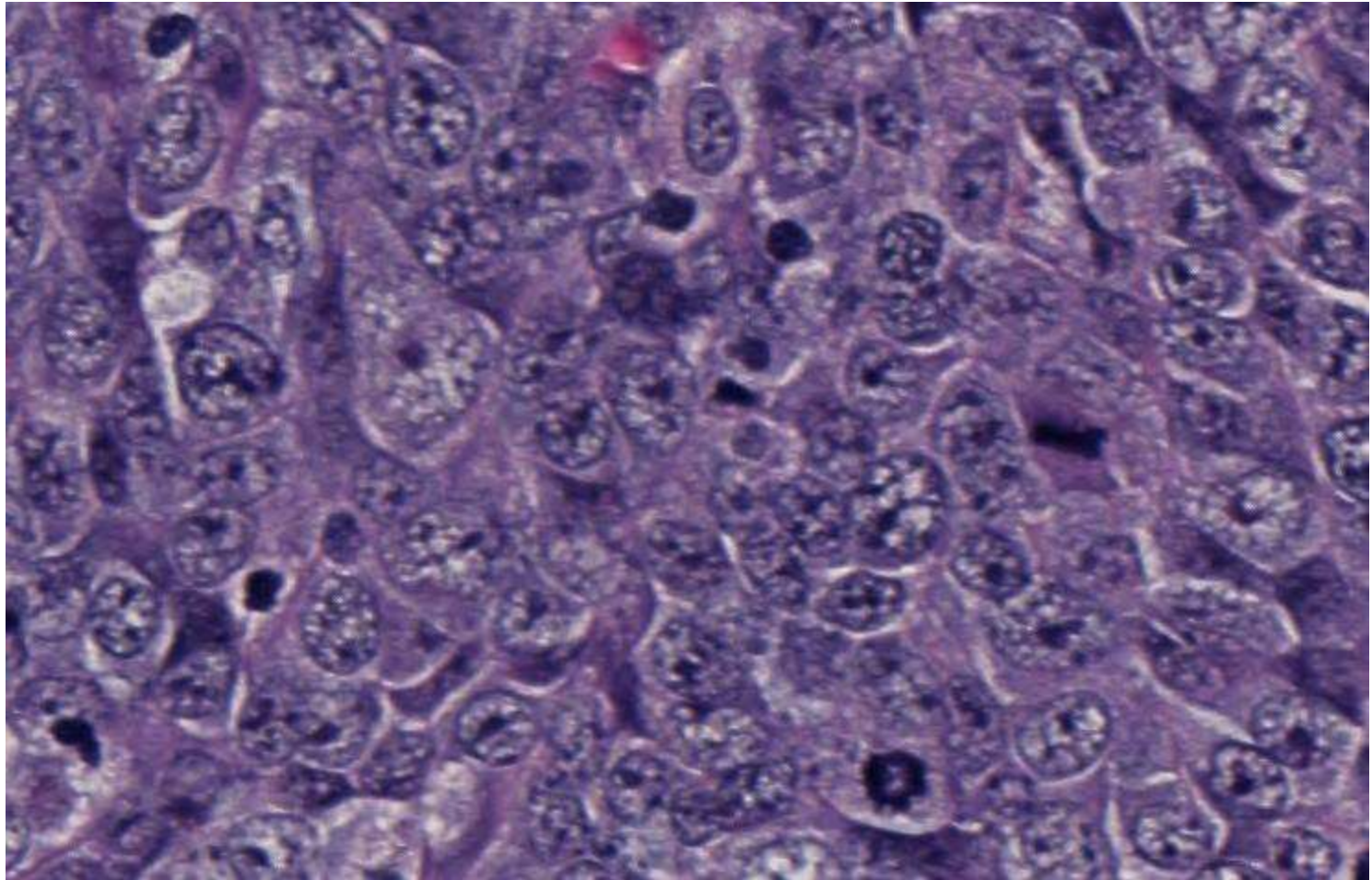












SB 6190

(scanned slide available)

Ankur Sangoi; El Camino Hospital

38-year-old woman with radical hysterectomy for cervical cancer. Pelvic sentinel lymph node biopsy submitted.

