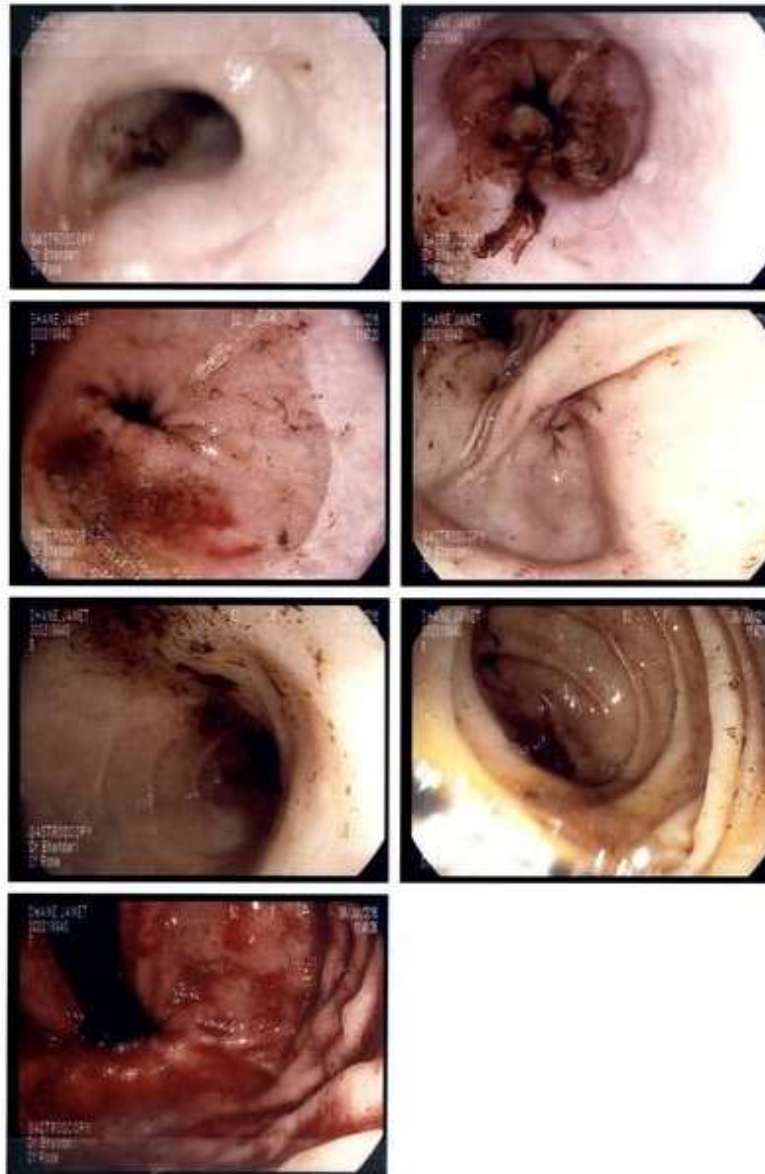


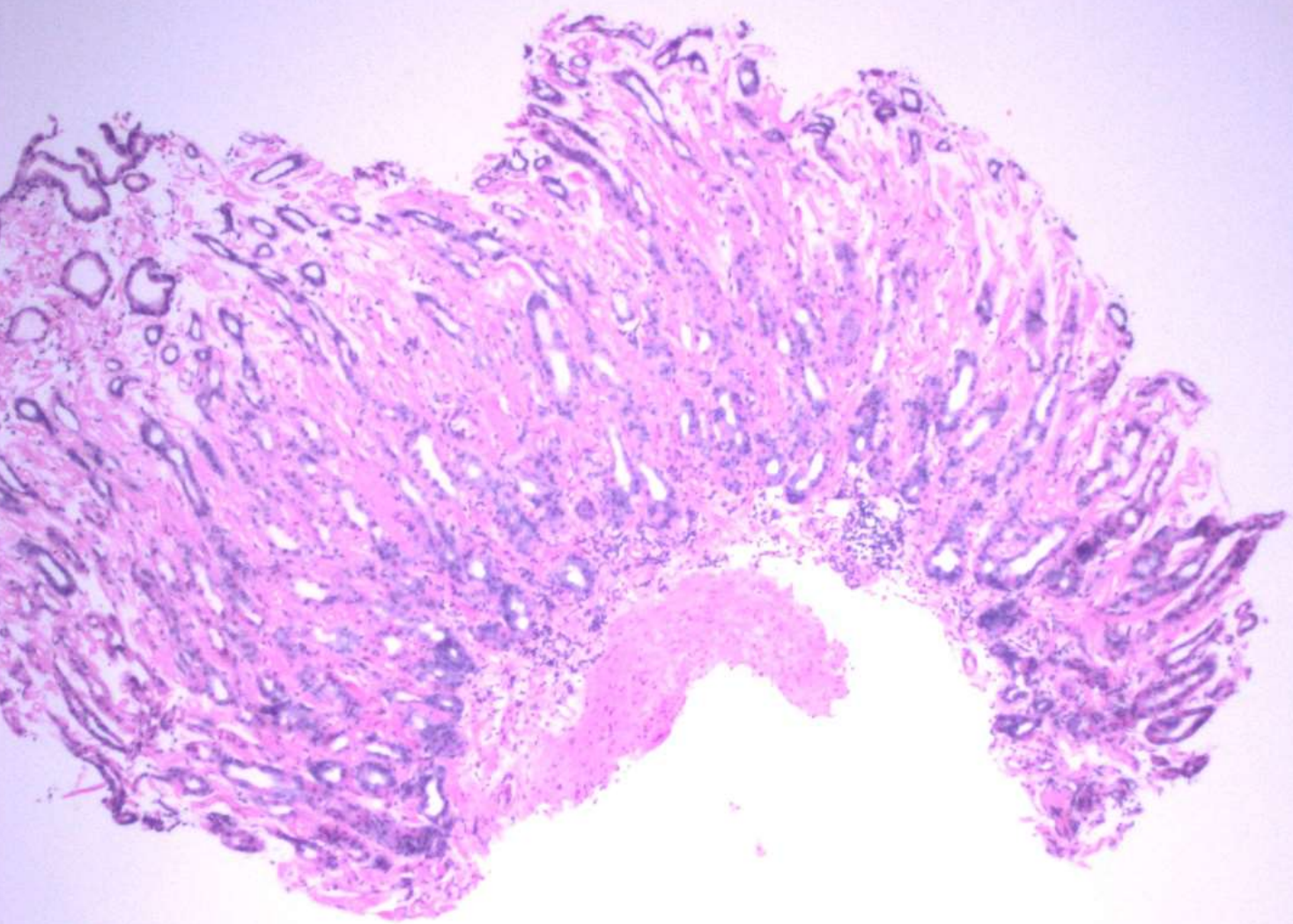
SB 6161

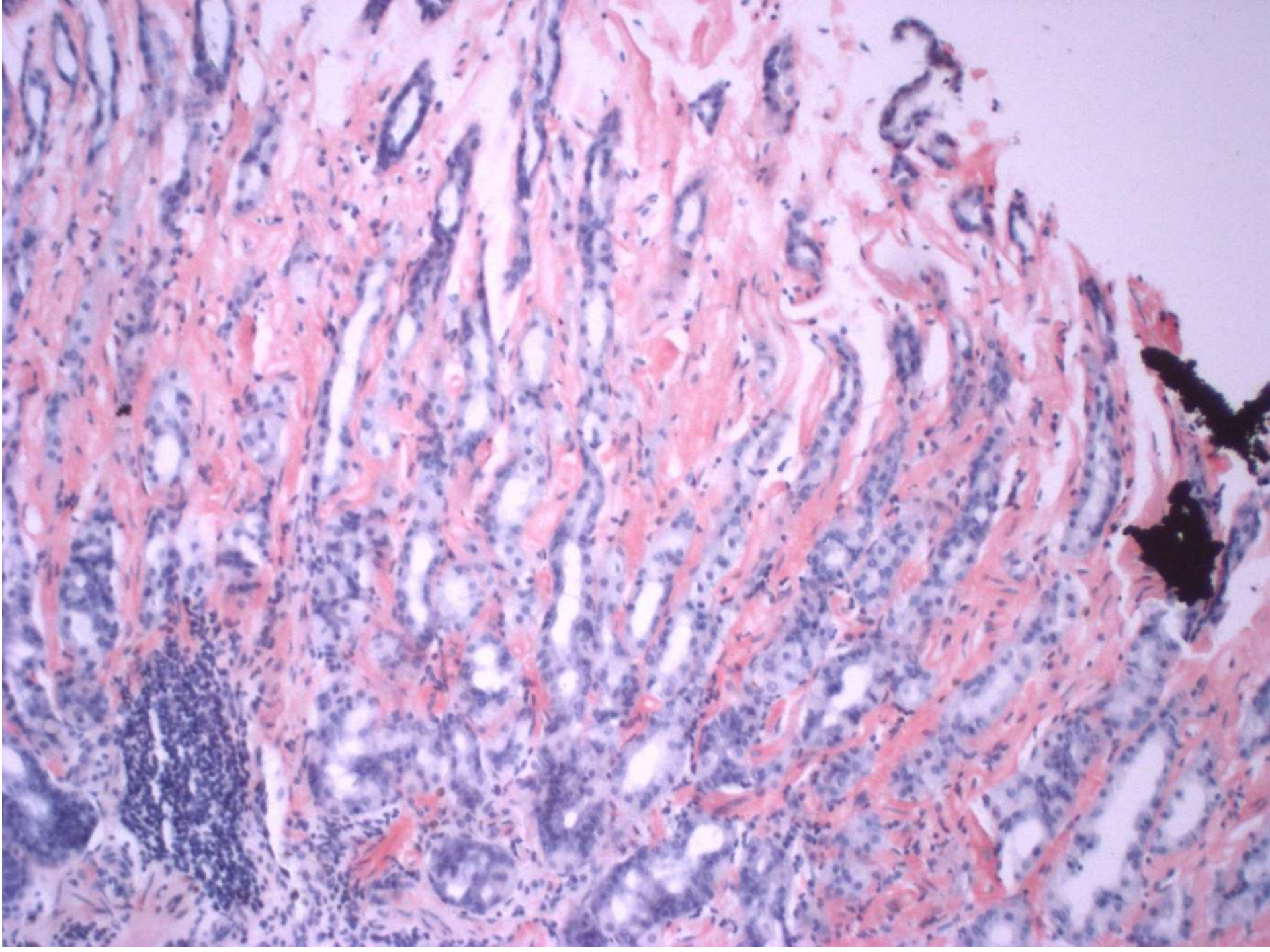
Claude Burdick; St. Rose Hospital

53-year-old woman on dialysis and bleeding from gastric fundus requiring 20 transfusions. No h/o chronic inflammatory disease. Gastric biopsy submitted.

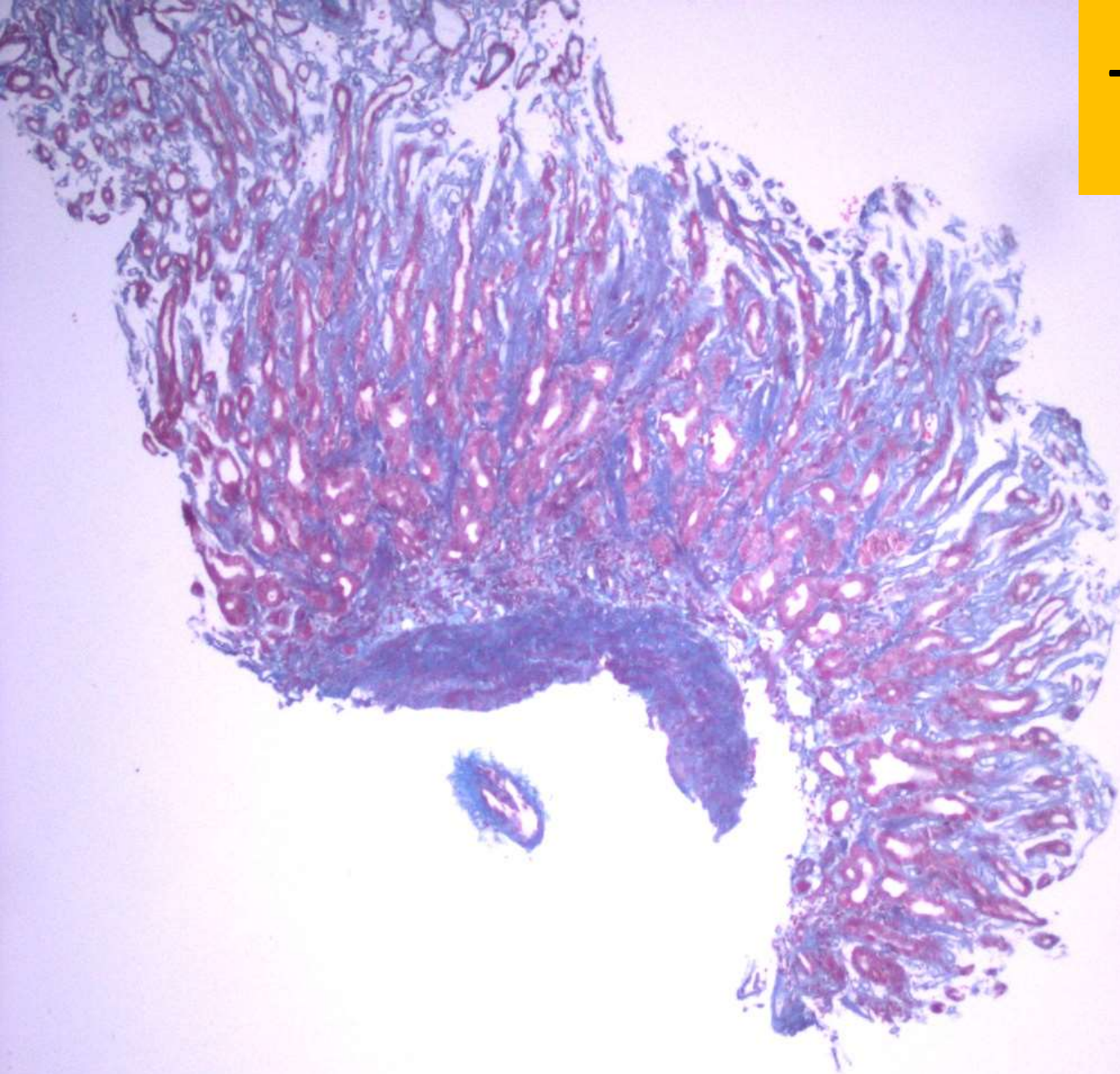
Endoscopy



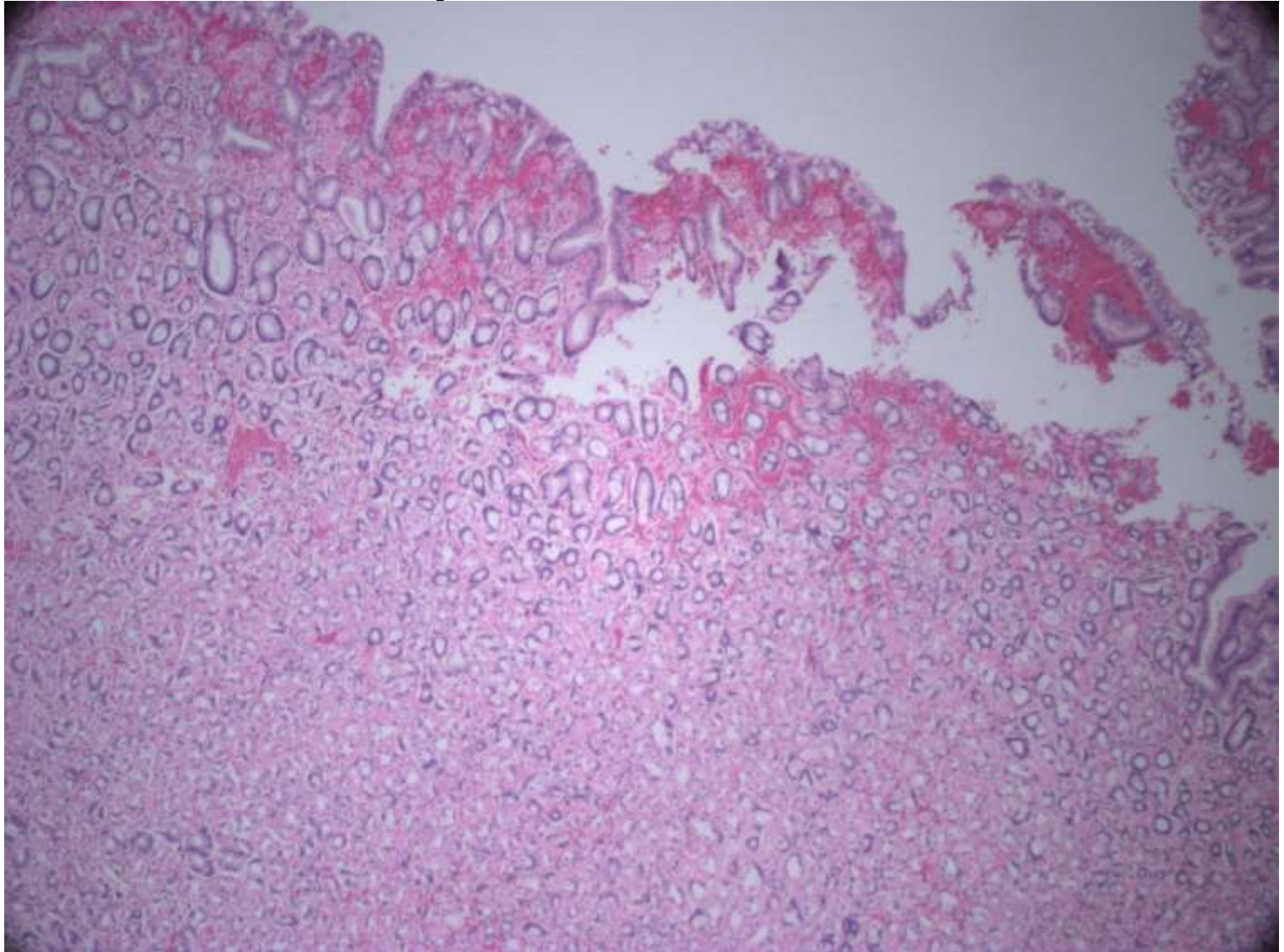


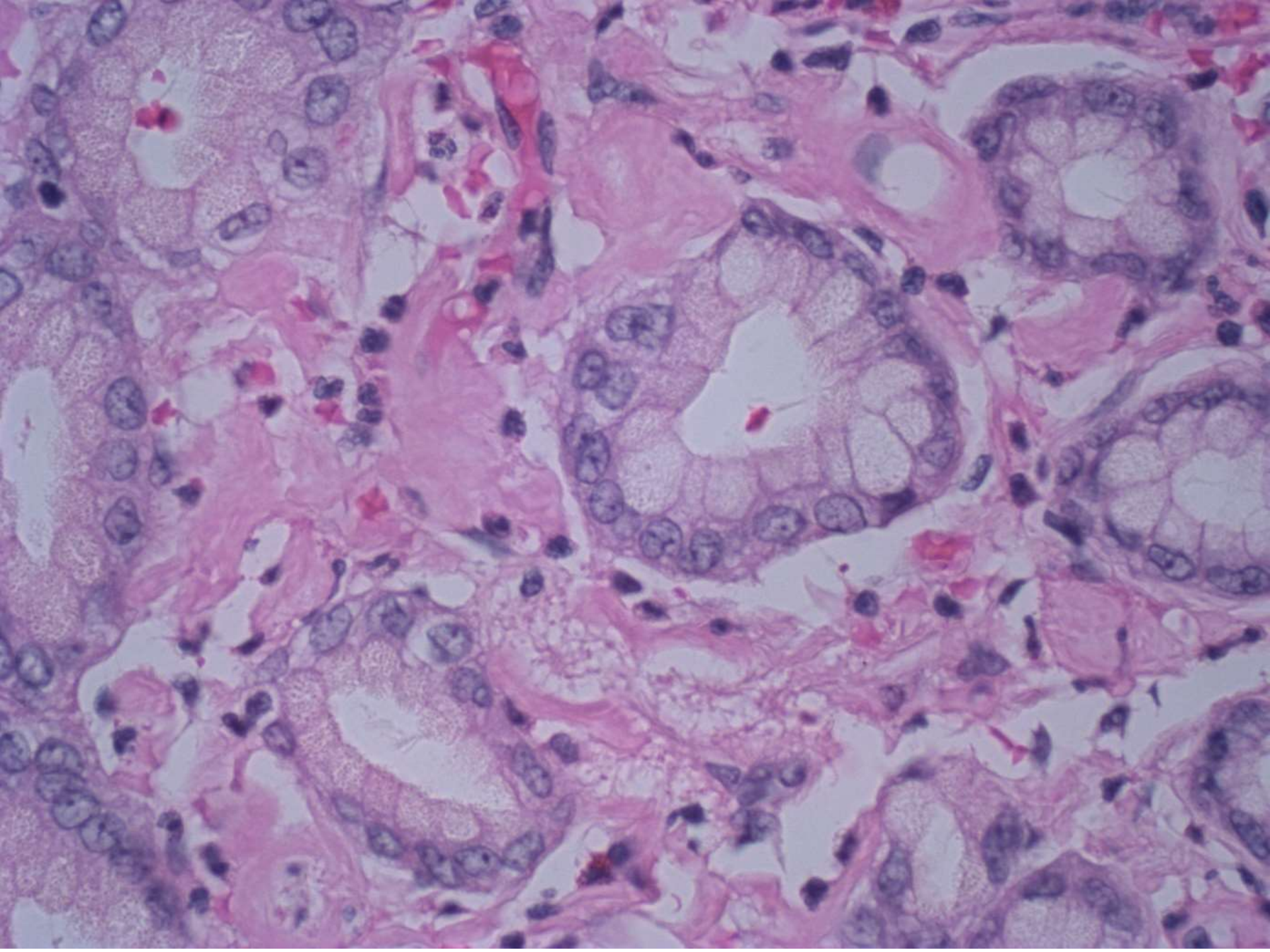


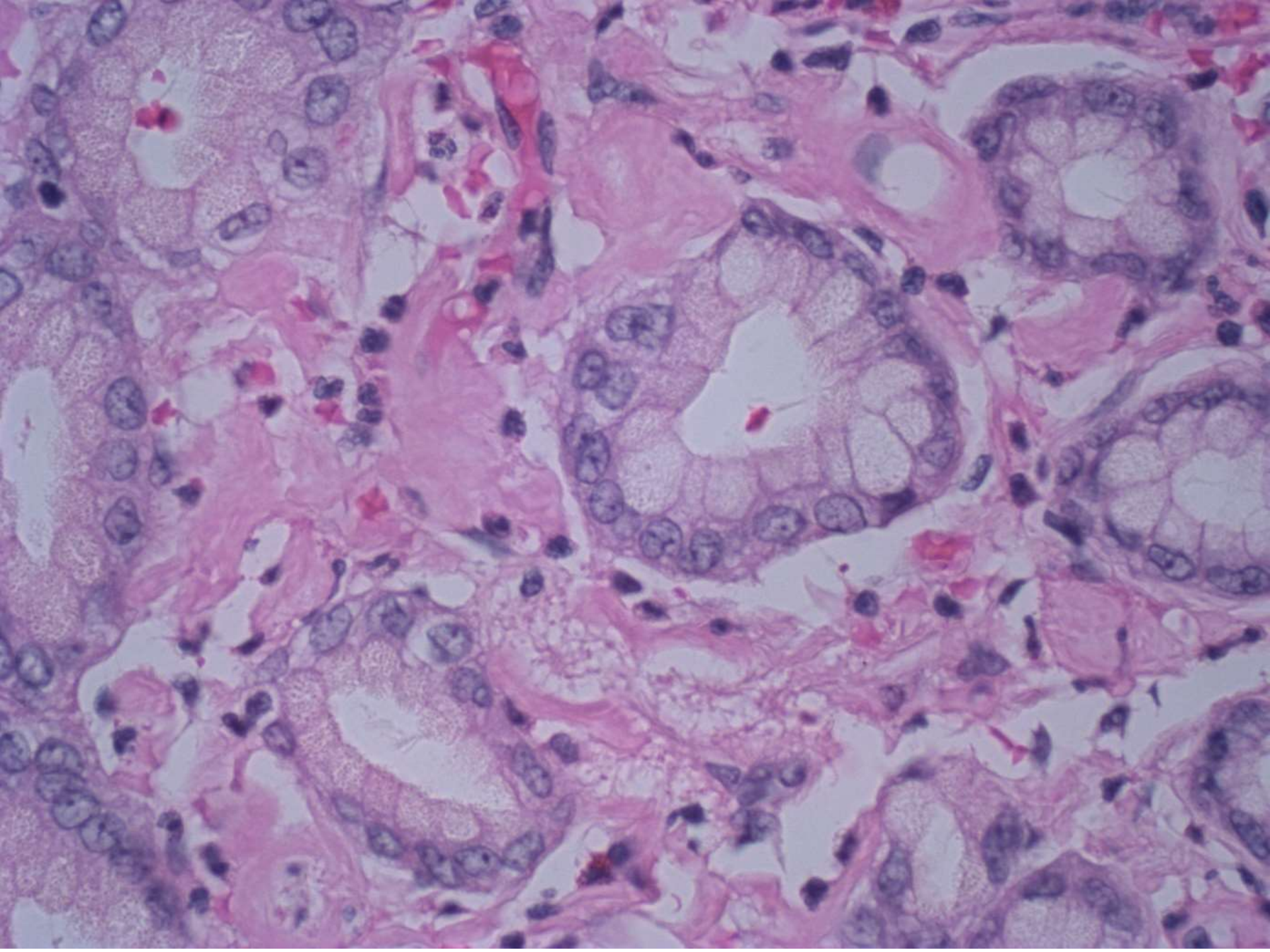
Trichrome



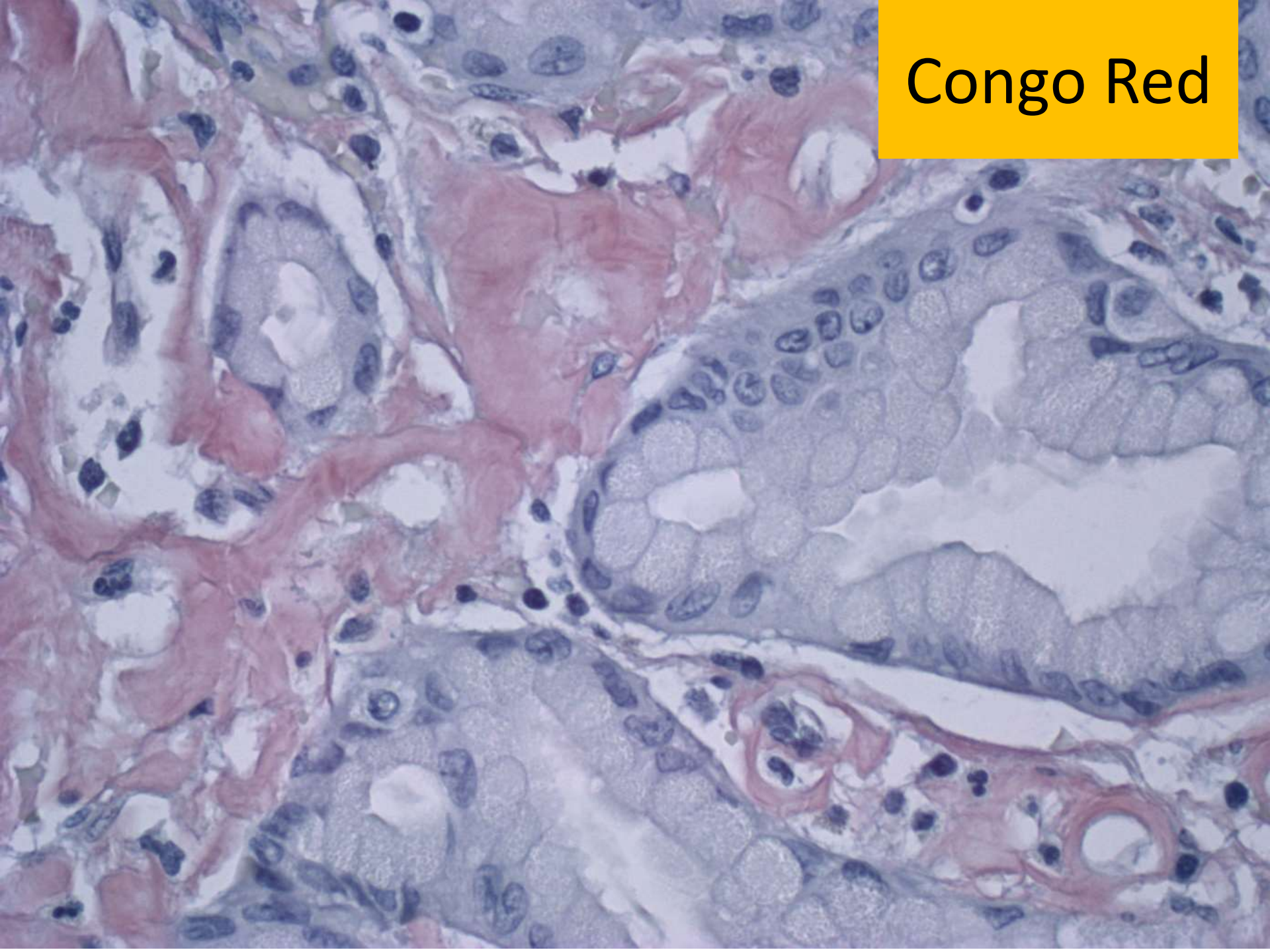
Sleeve Gastrectomy showed bleeding from epithelial surface.







Congo Red

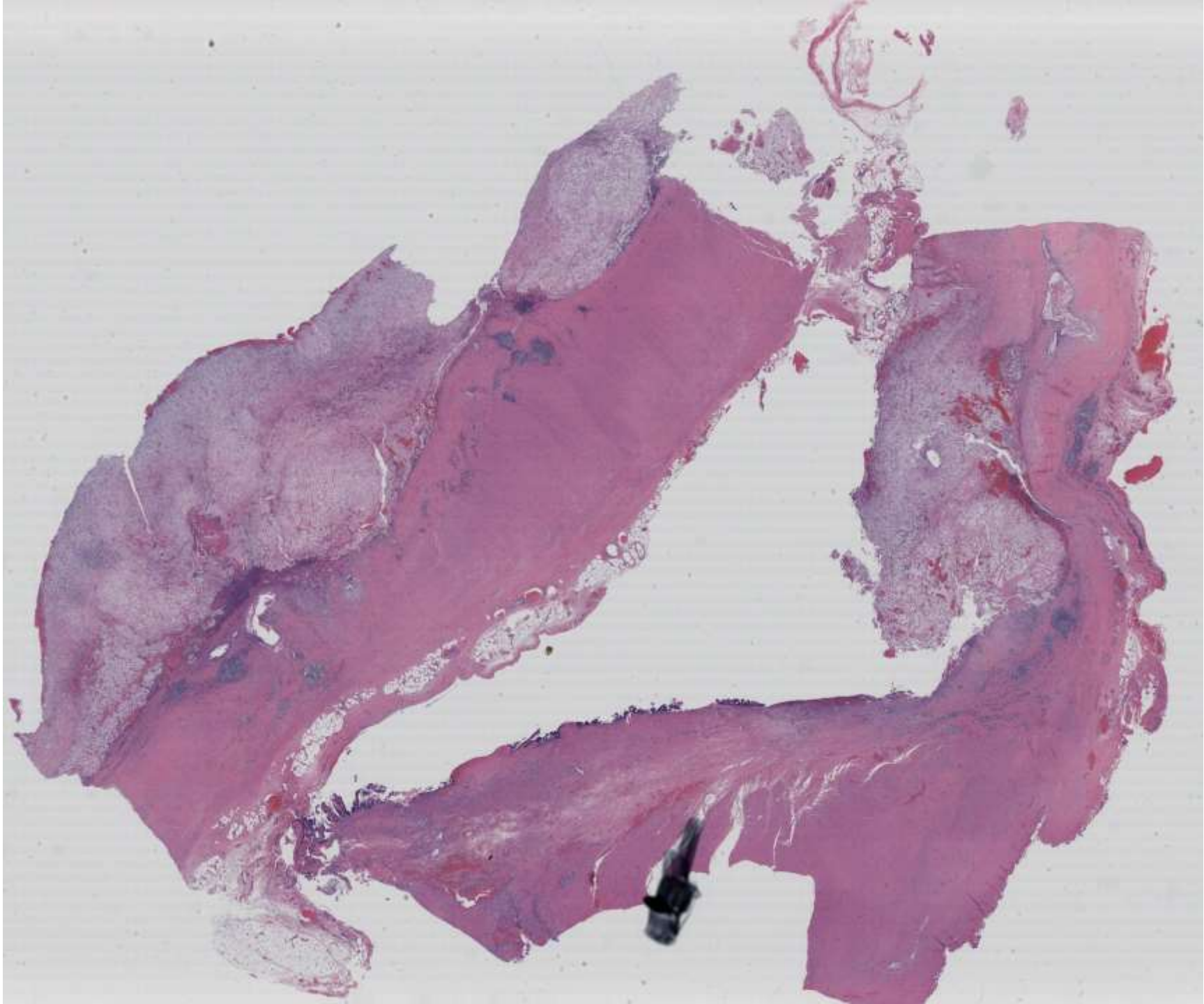


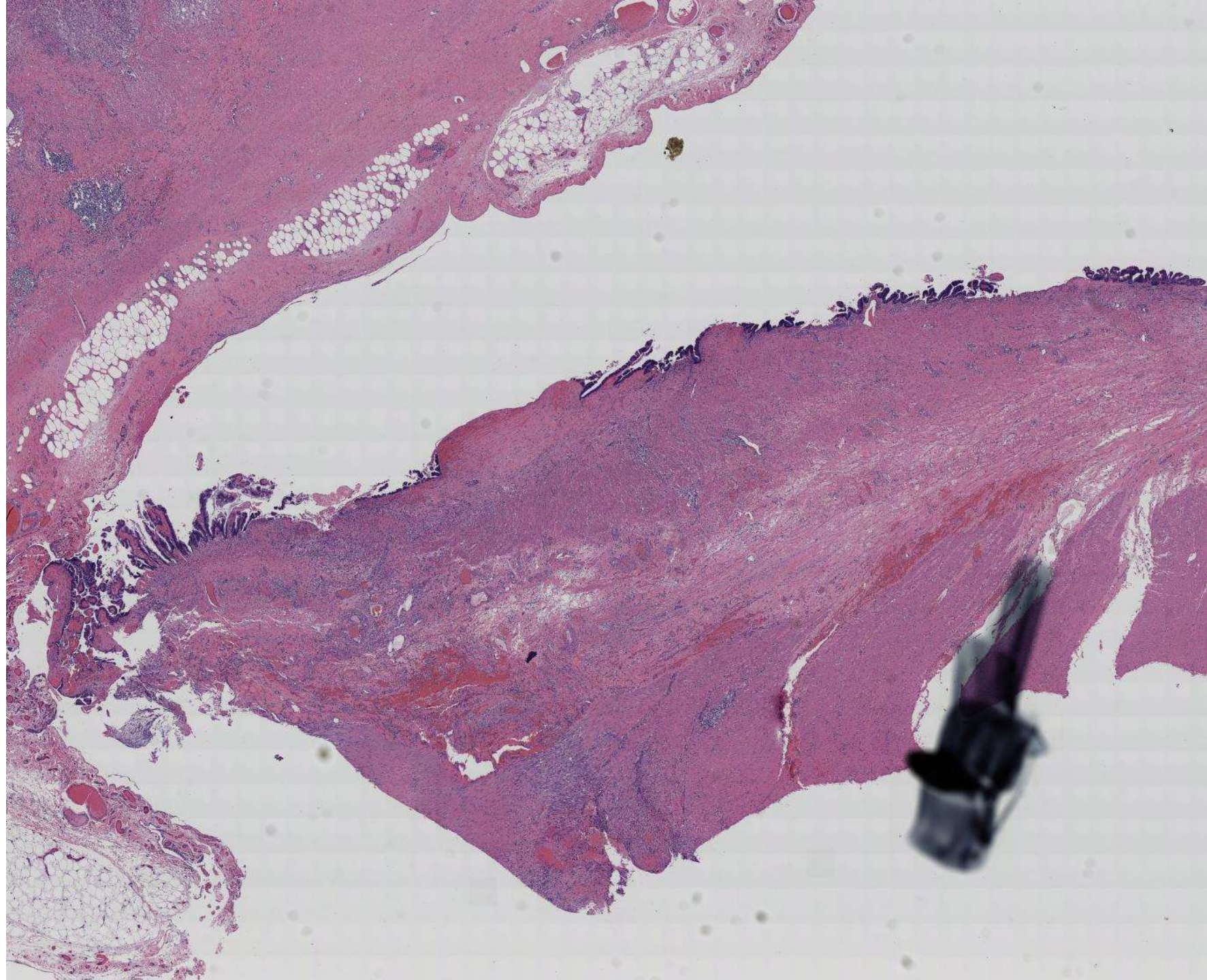
SB 6162

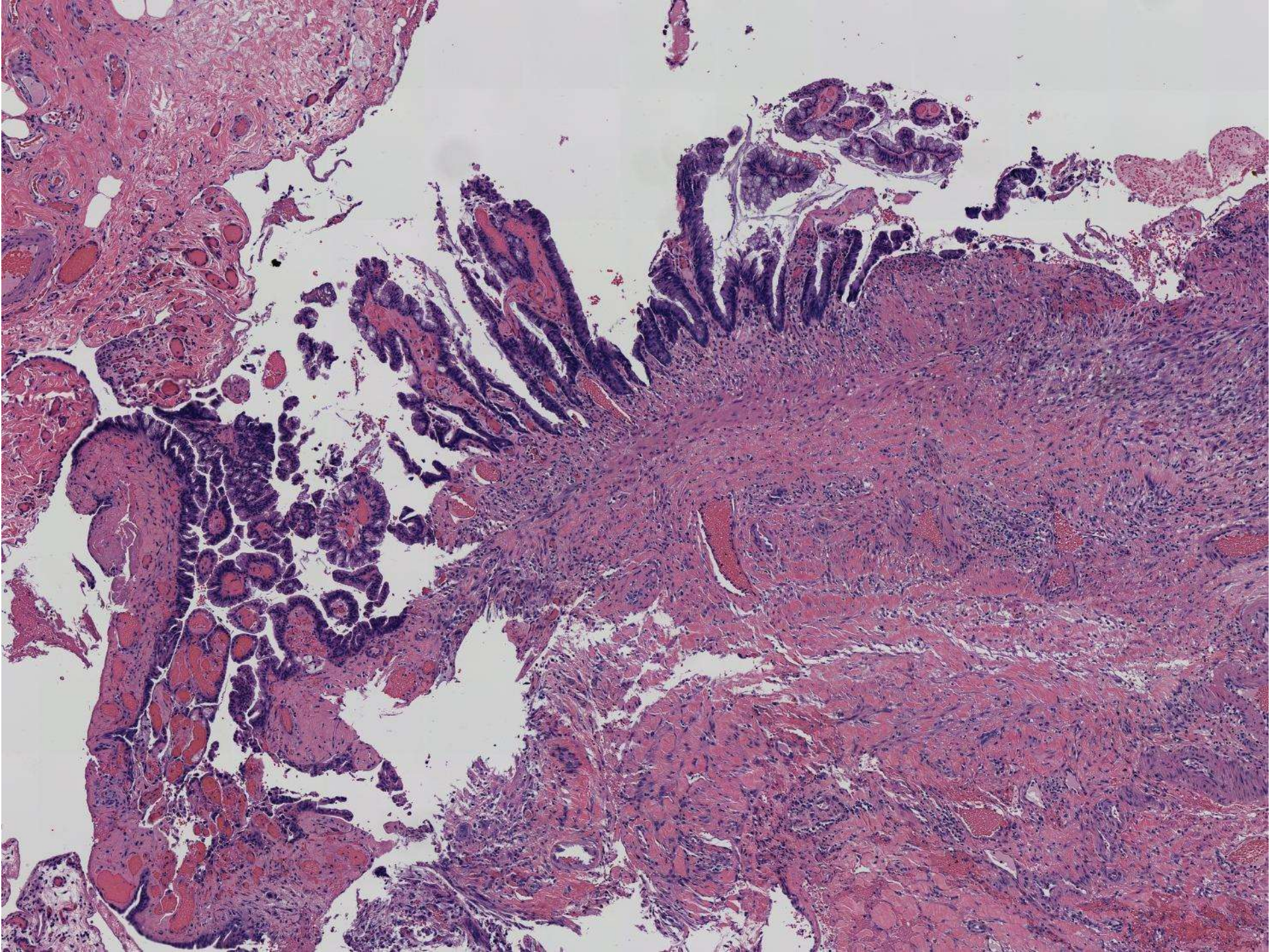
(scanned slide available)

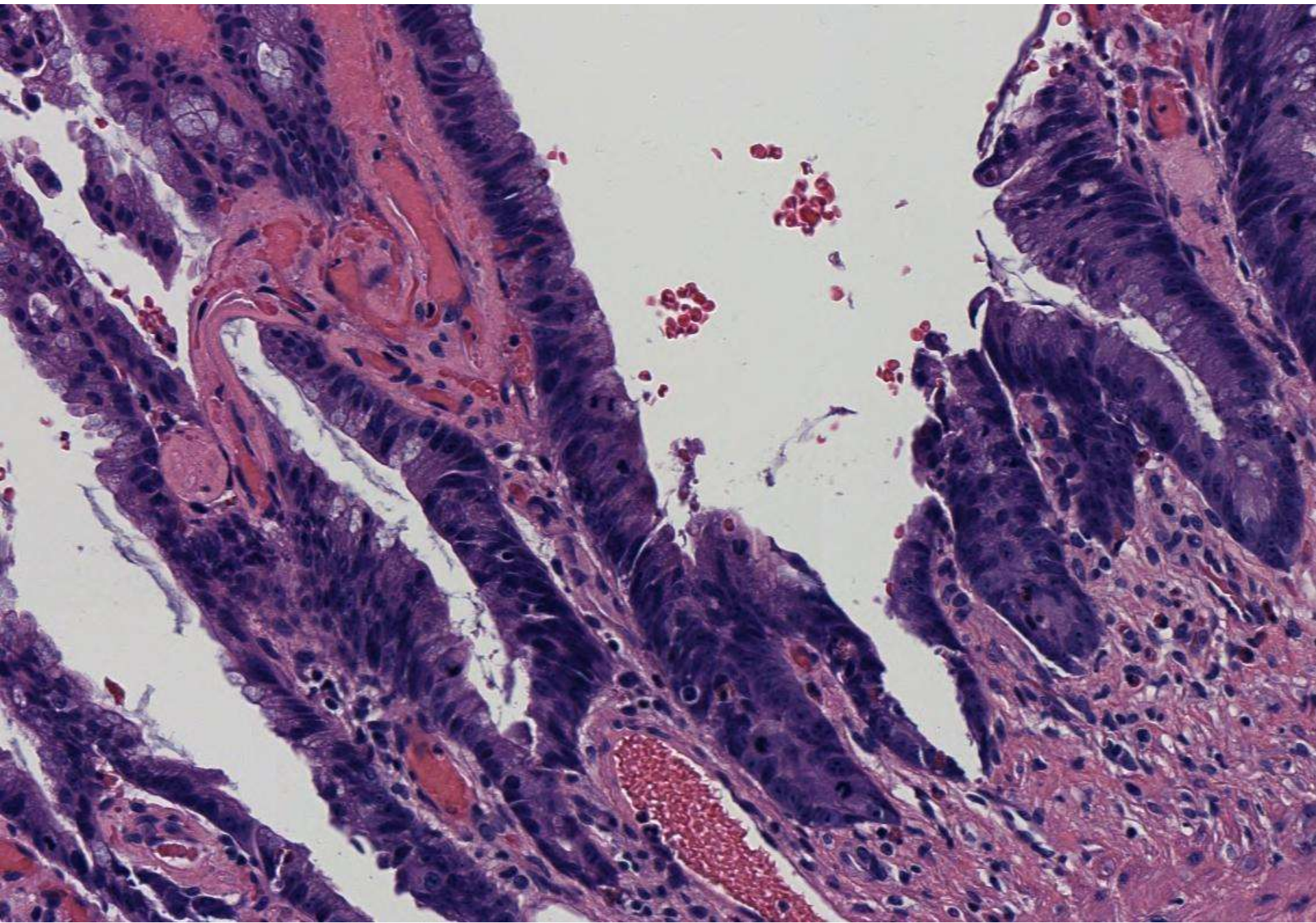
Mahendra Ranchod; Good Samaritan Hospital

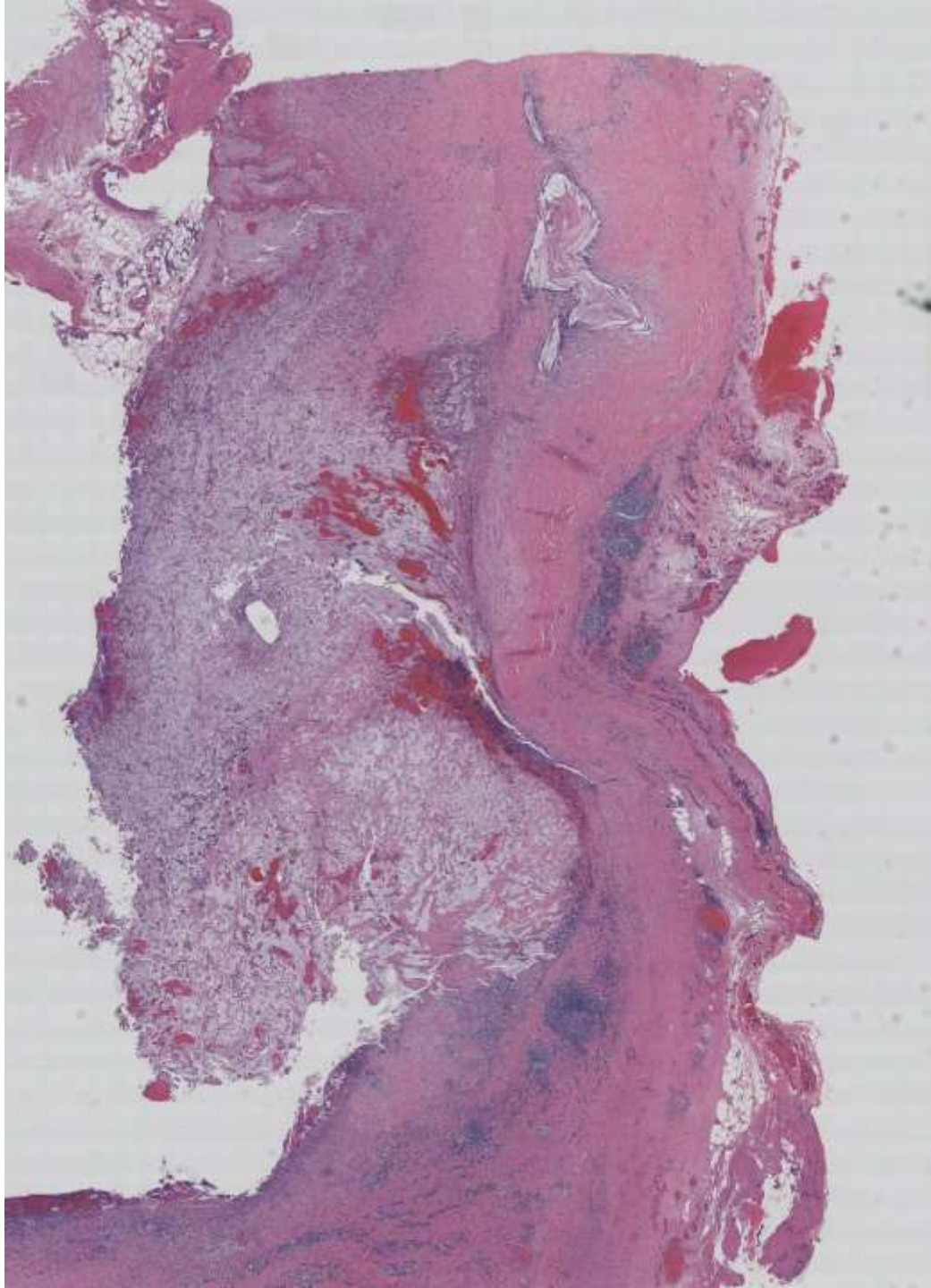
34-year-old woman with colostomy performed for imperforate anus. Draining cutaneous fistula after take of colostomy. Segment of colon resection.

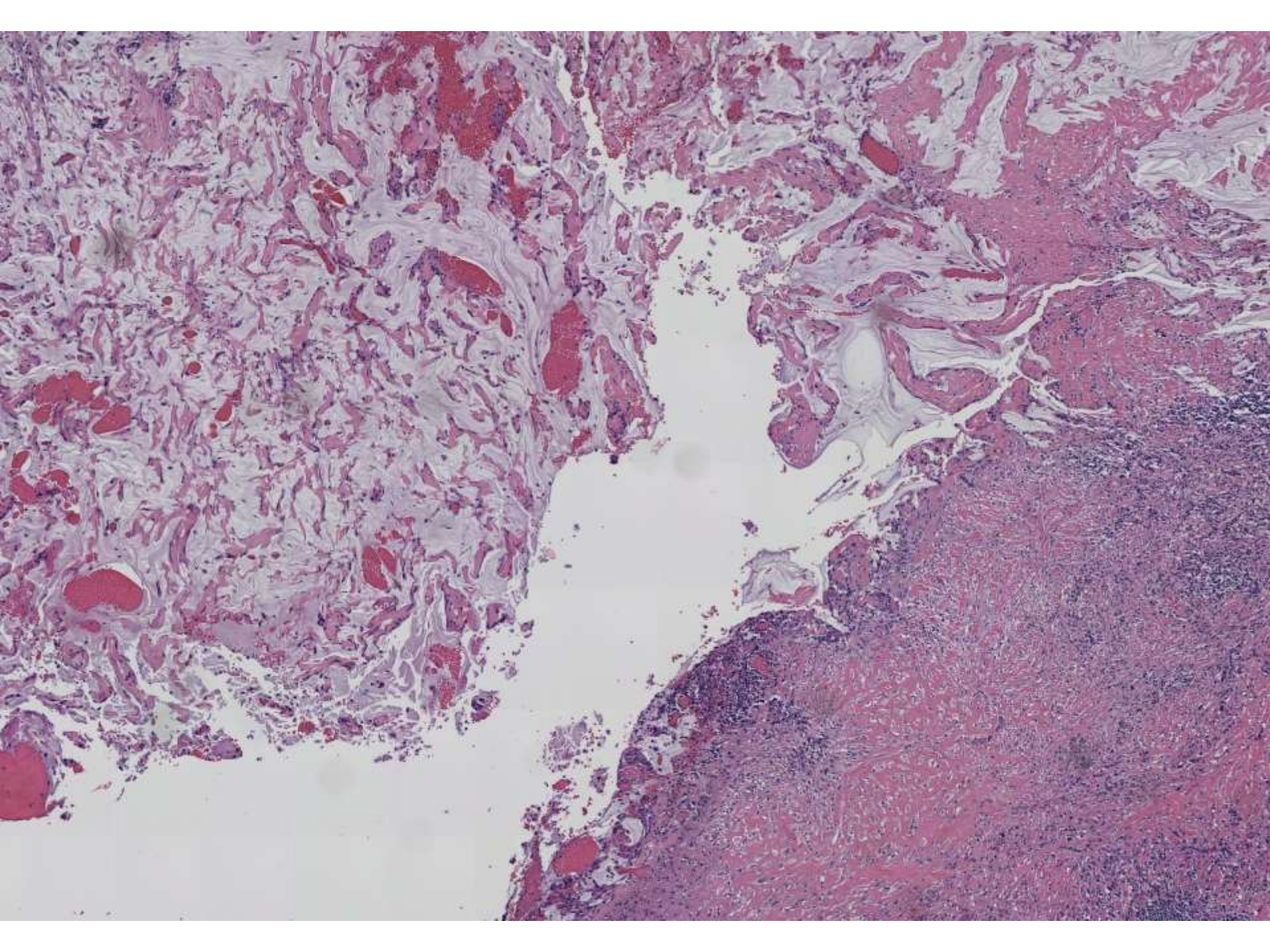


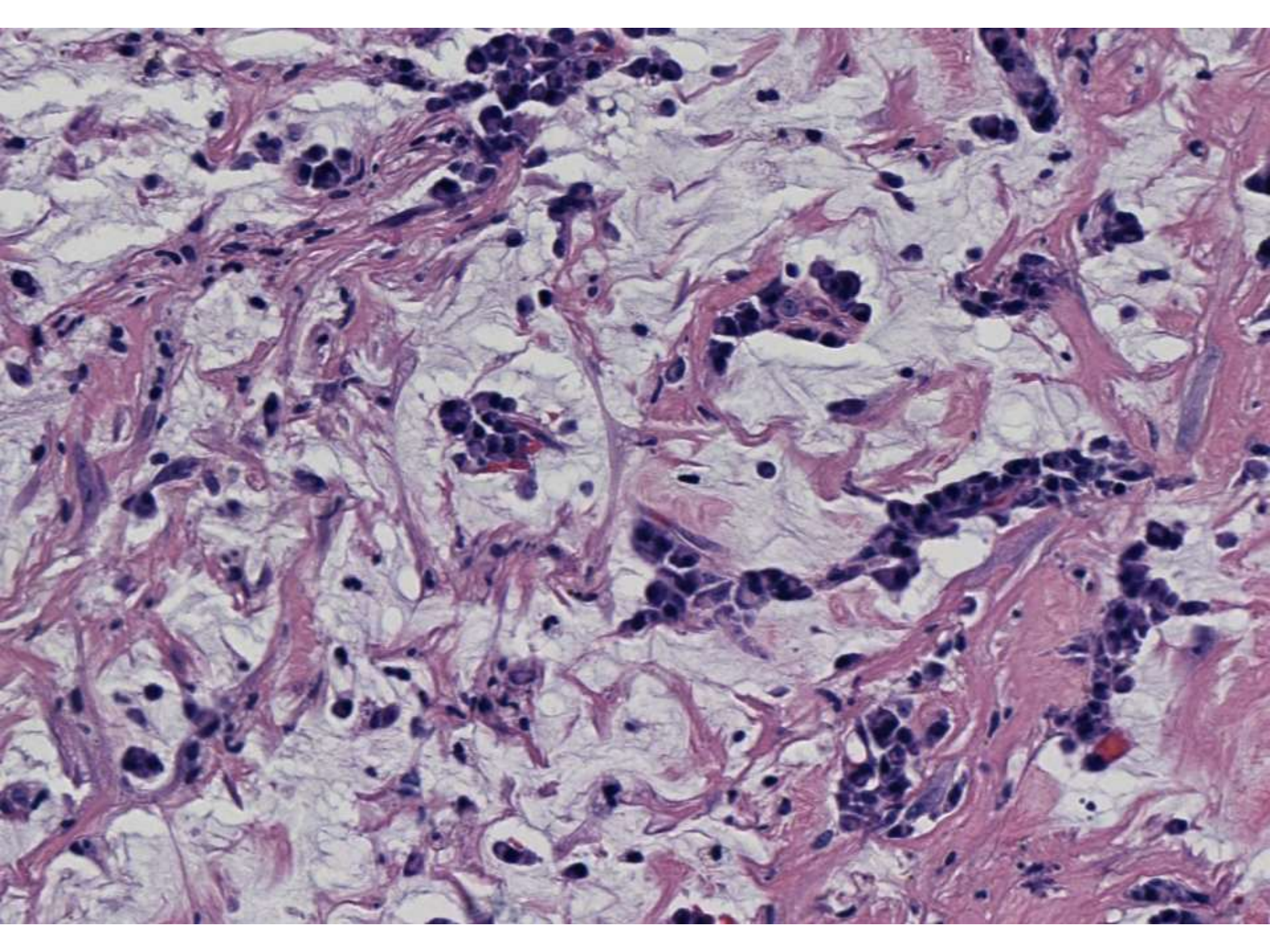


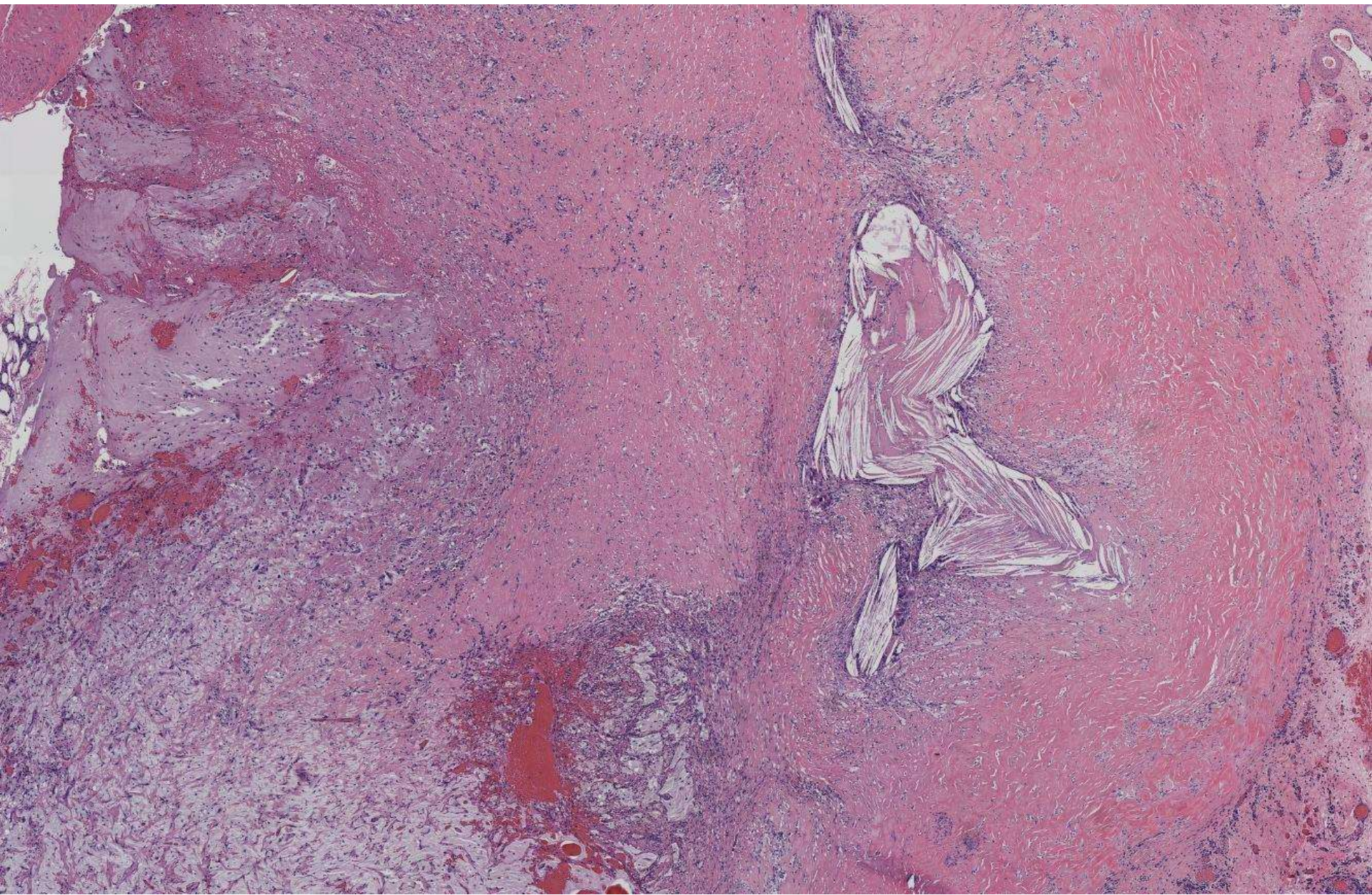


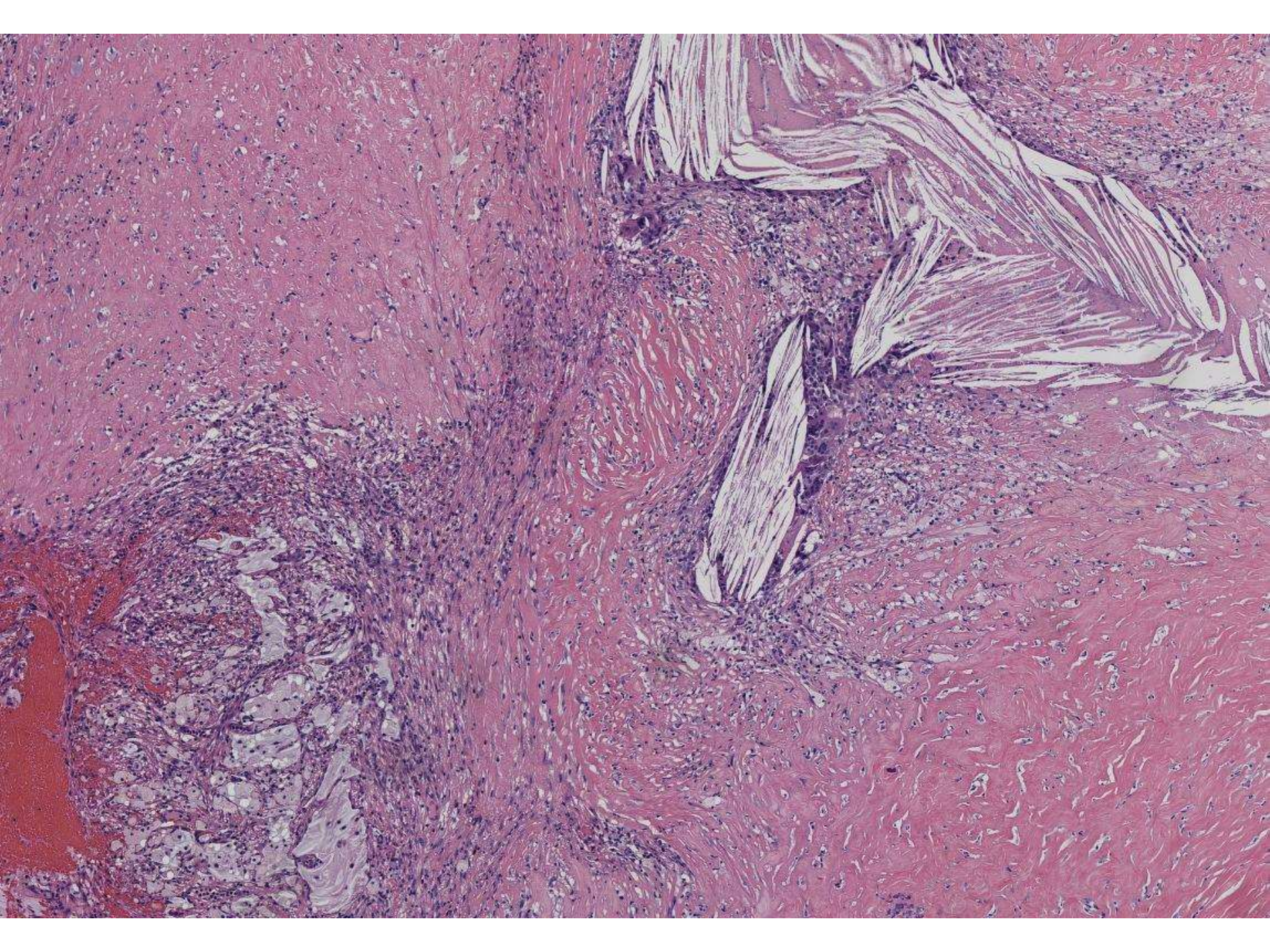








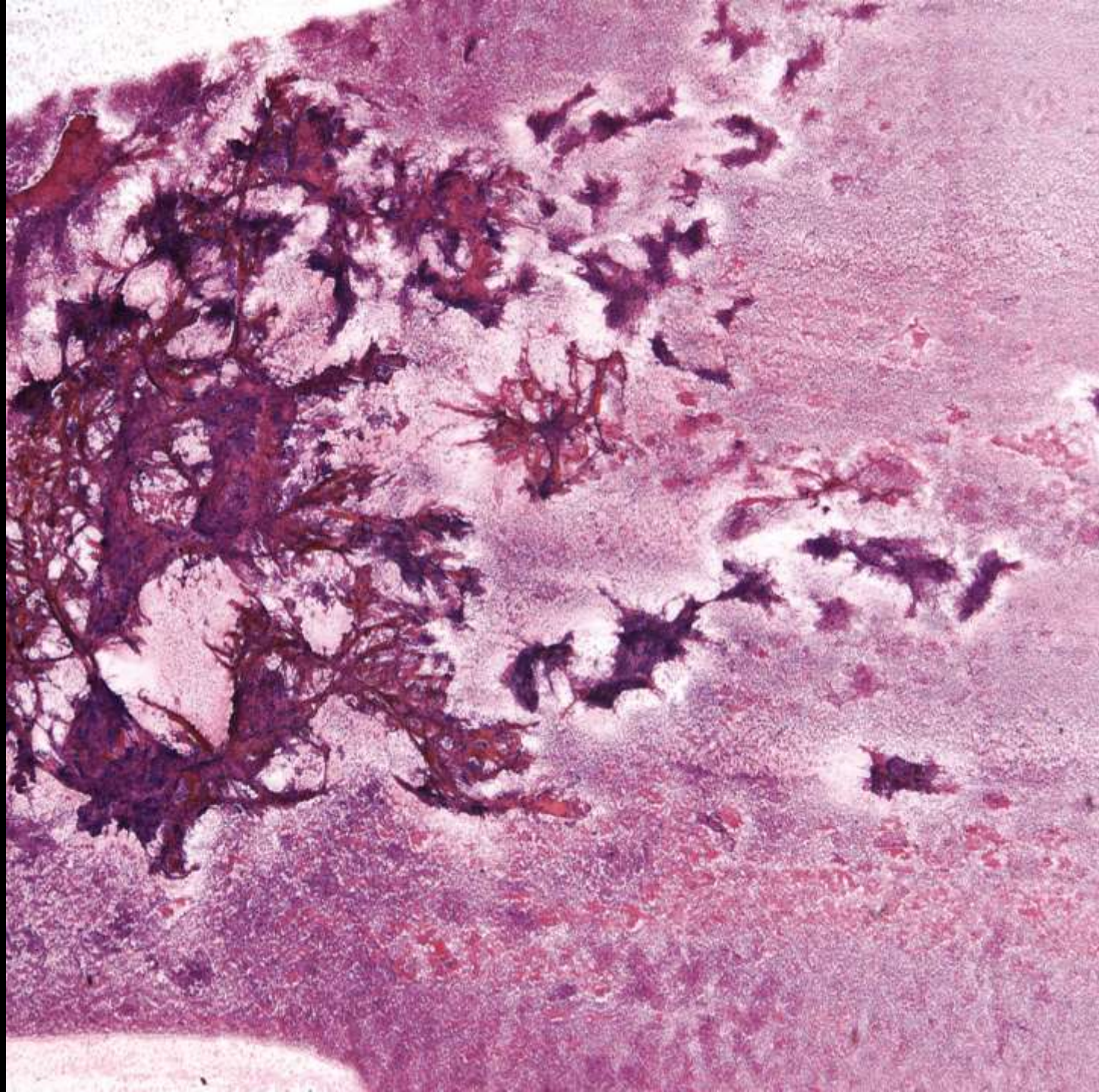


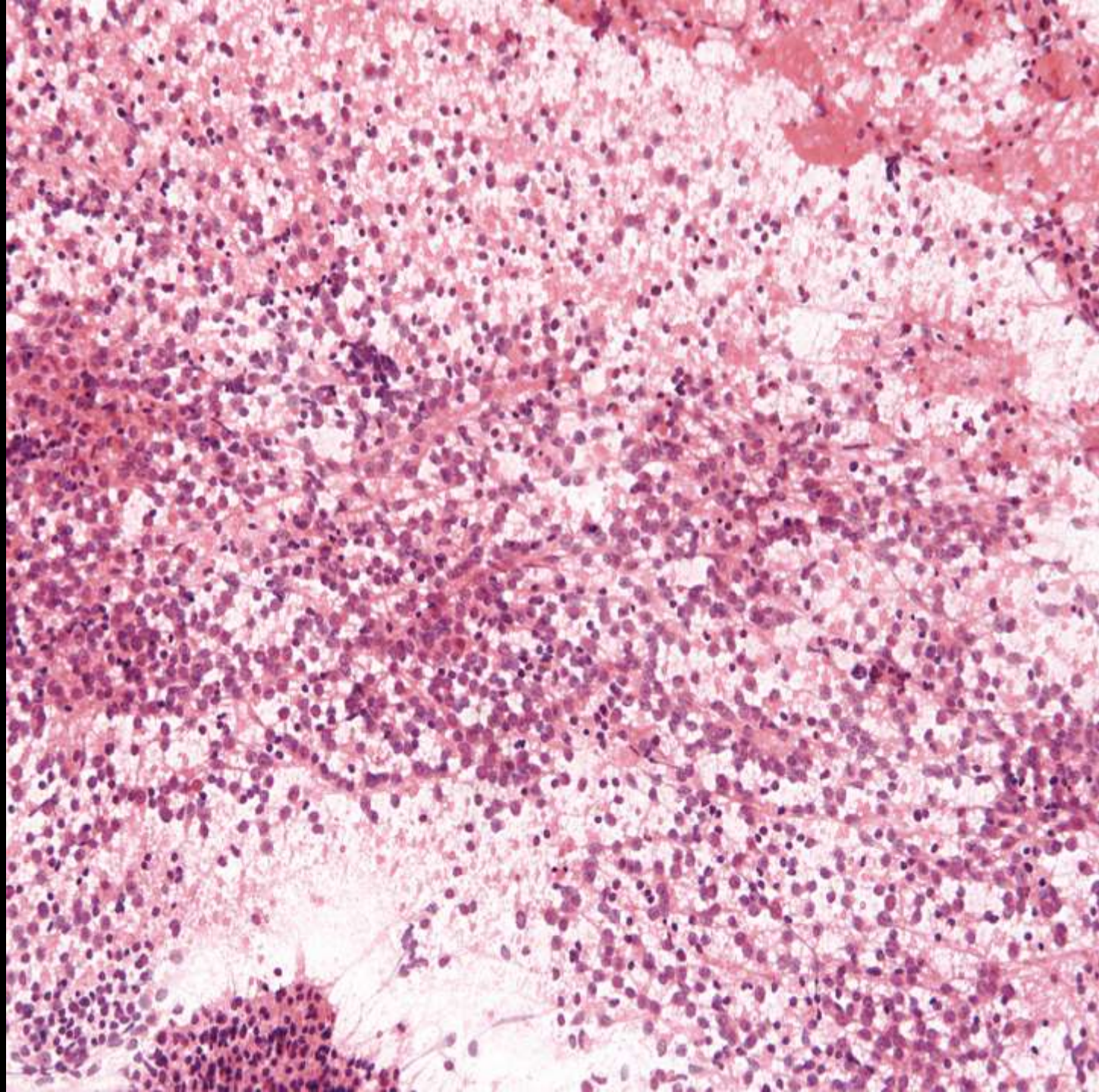


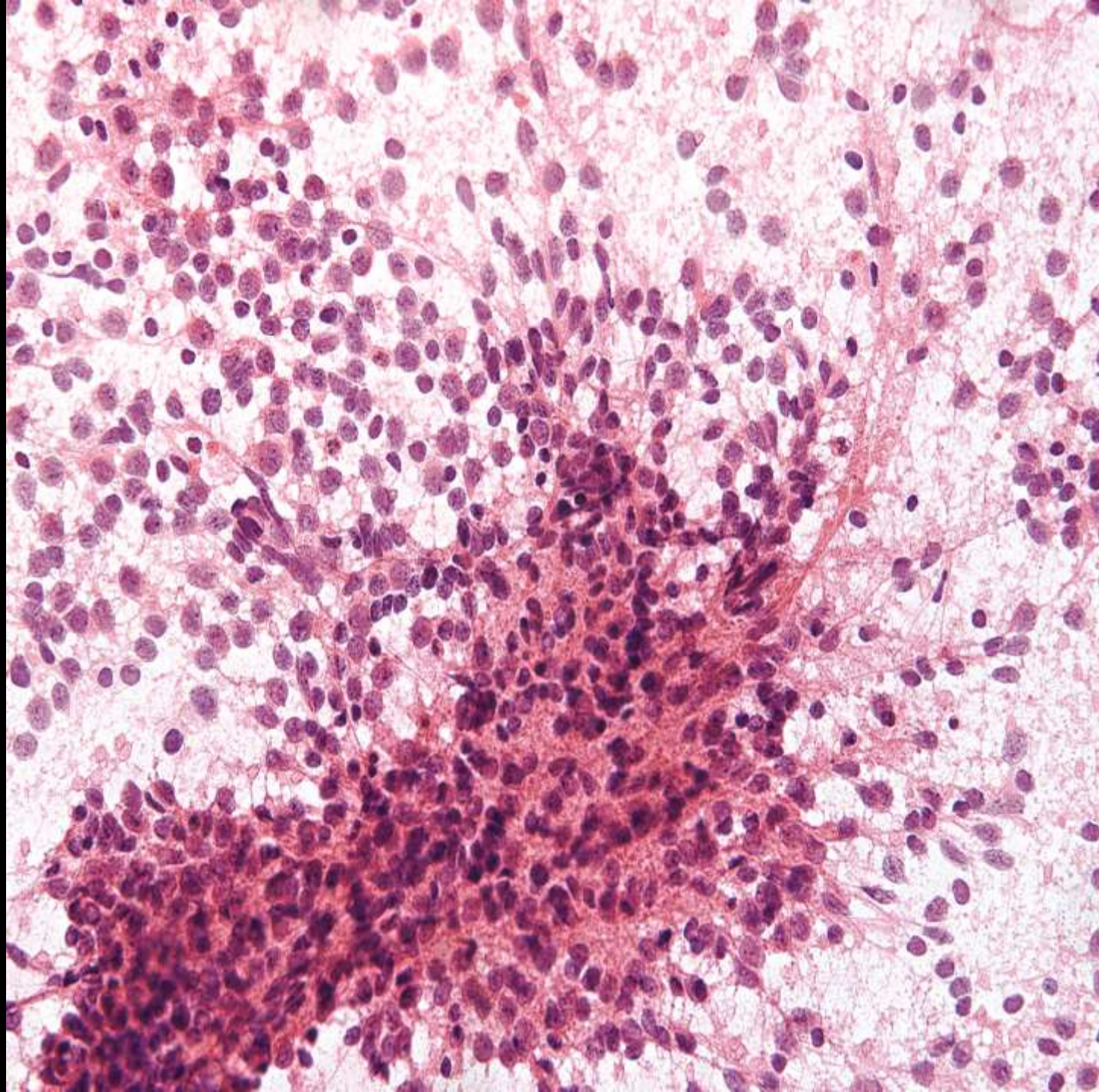
SB 6163

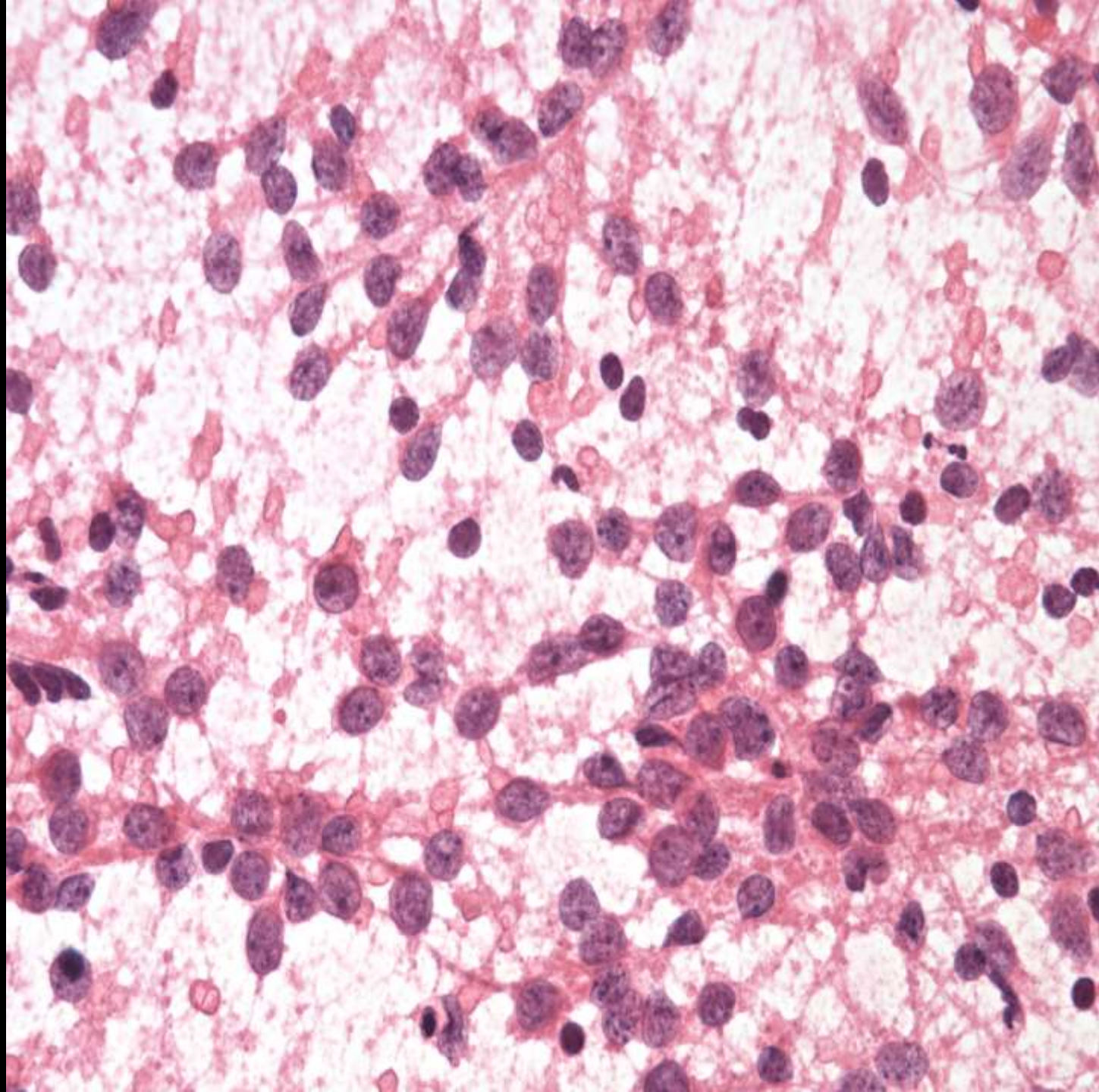
Peyman Samghabadi/Donald Born; Stanford

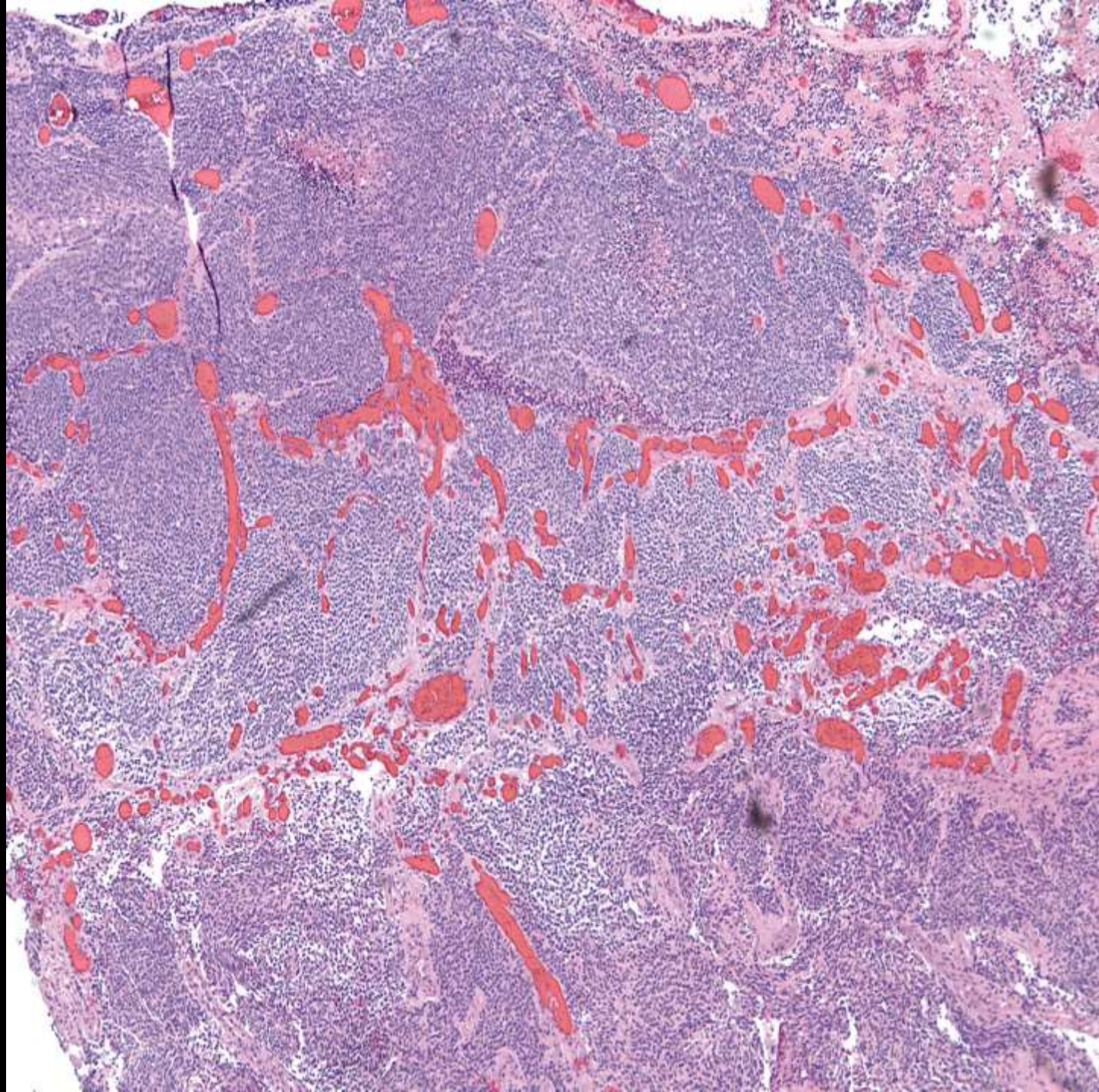
17-year-old previously healthy male presents with 2 month h/o of intermittent headache, nausea, emesis, and slow cognition thought to be post-concussive from a collision during a basketball game. MRI reveals a contrast-enhancing mass in the right temporoparietal area associated with a cyst and edema.

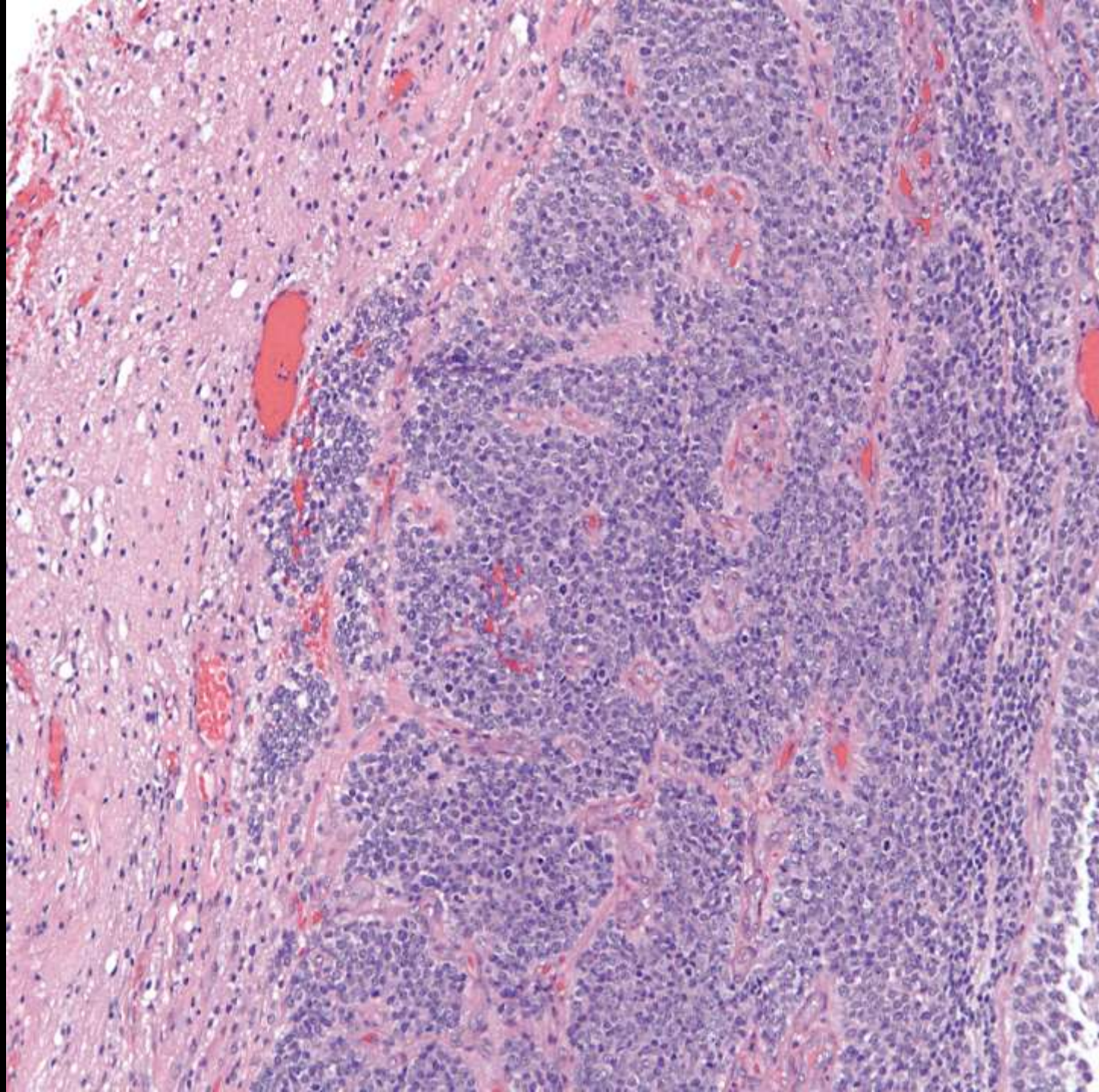


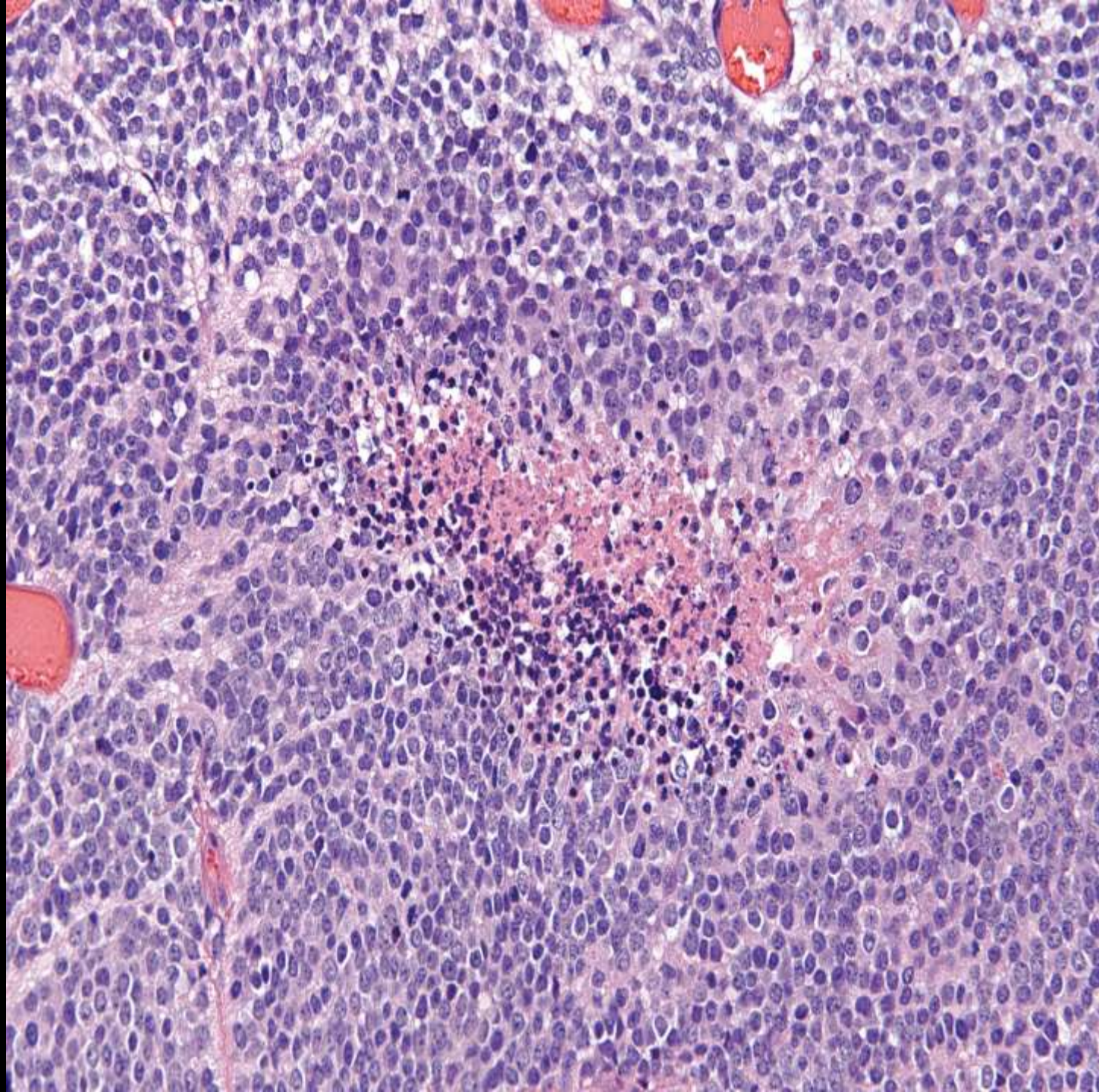


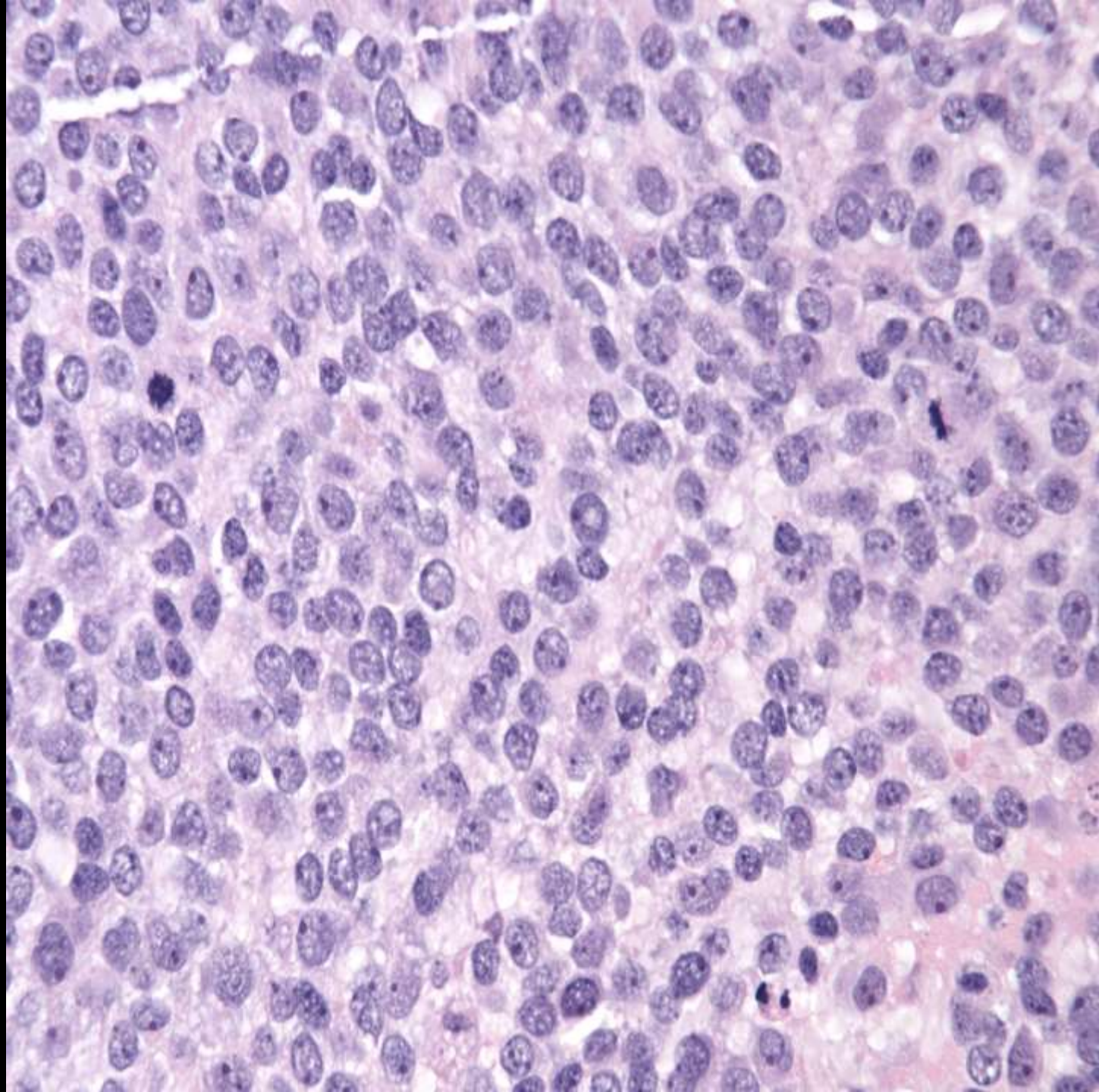


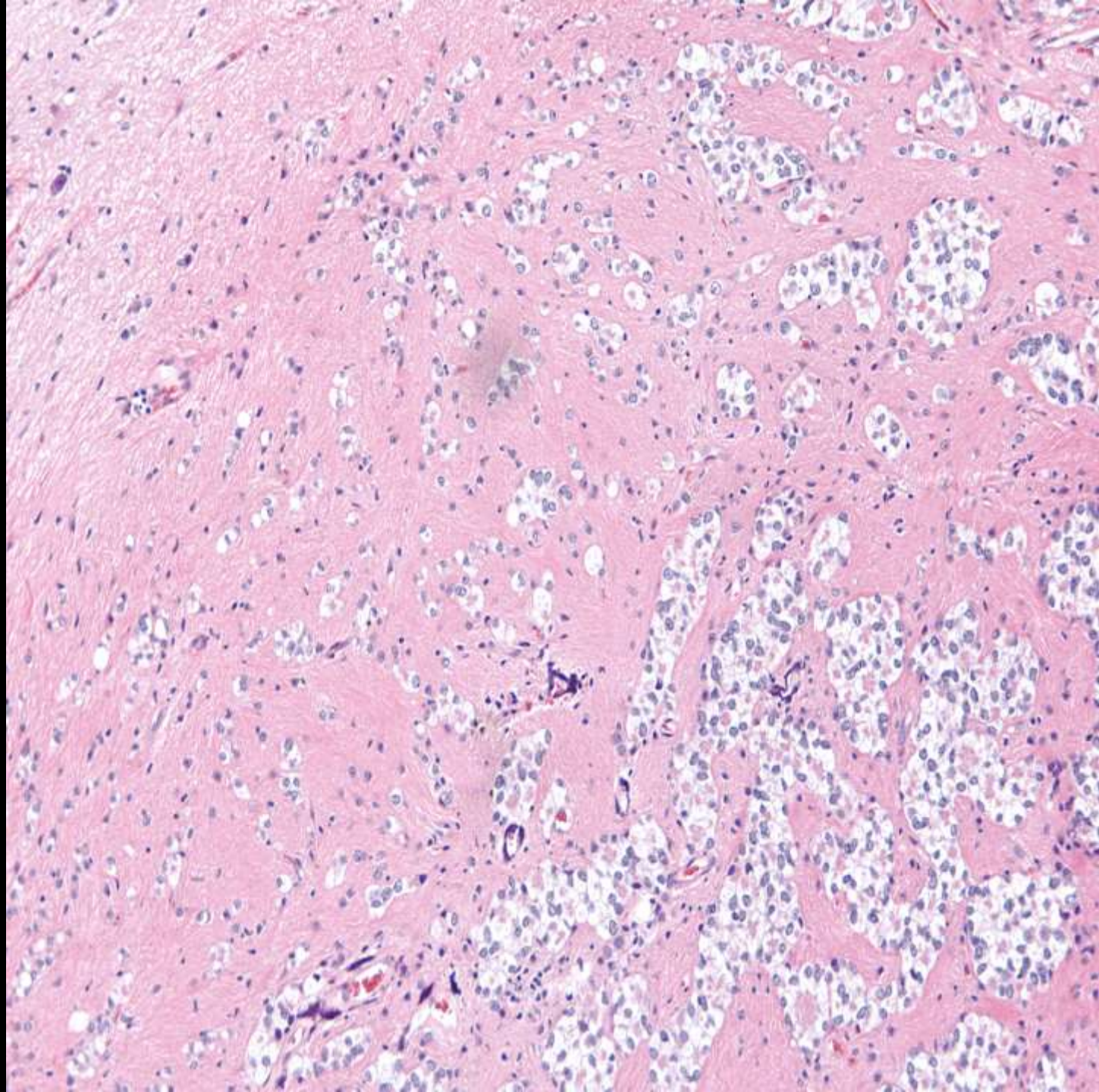


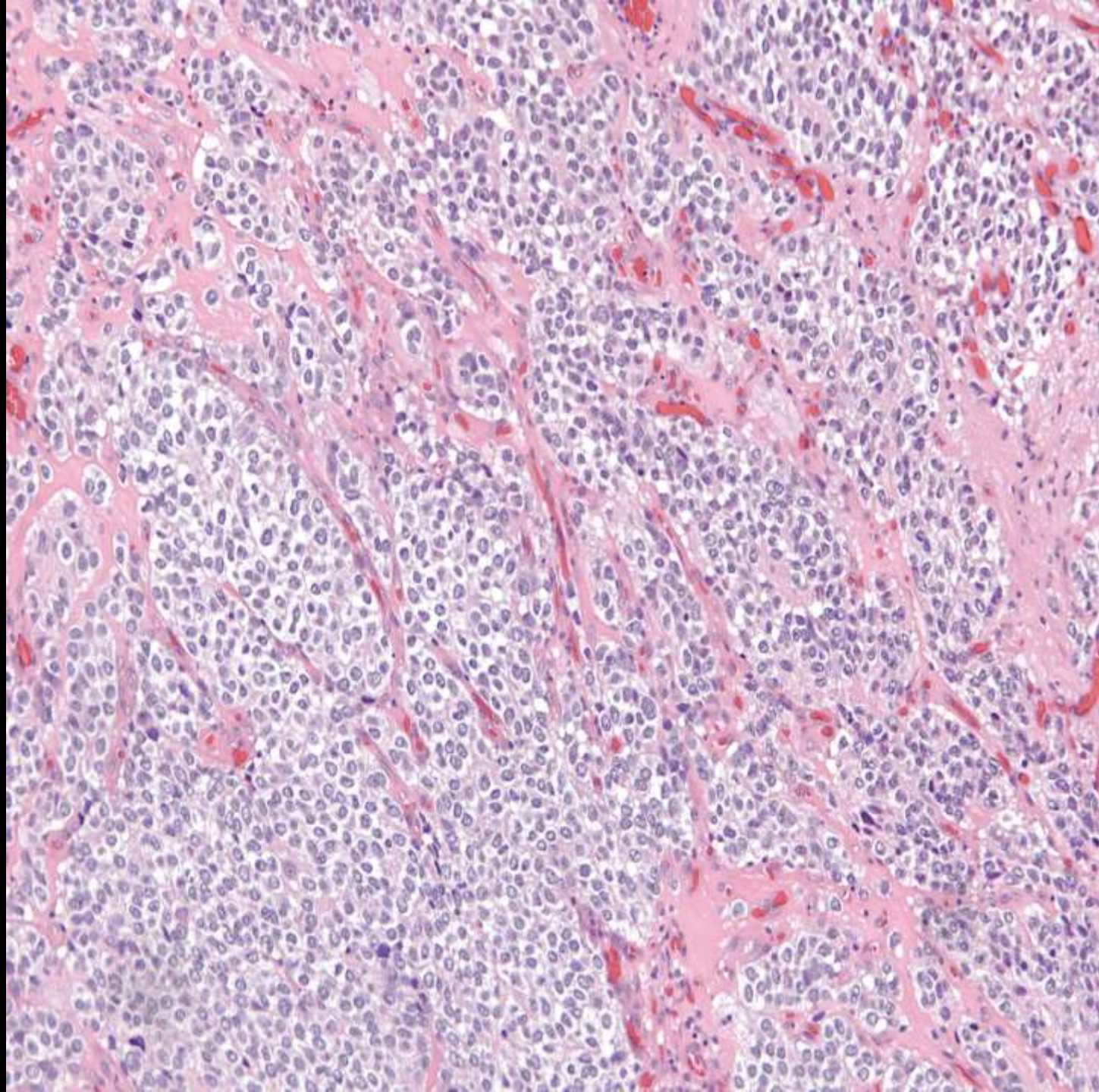


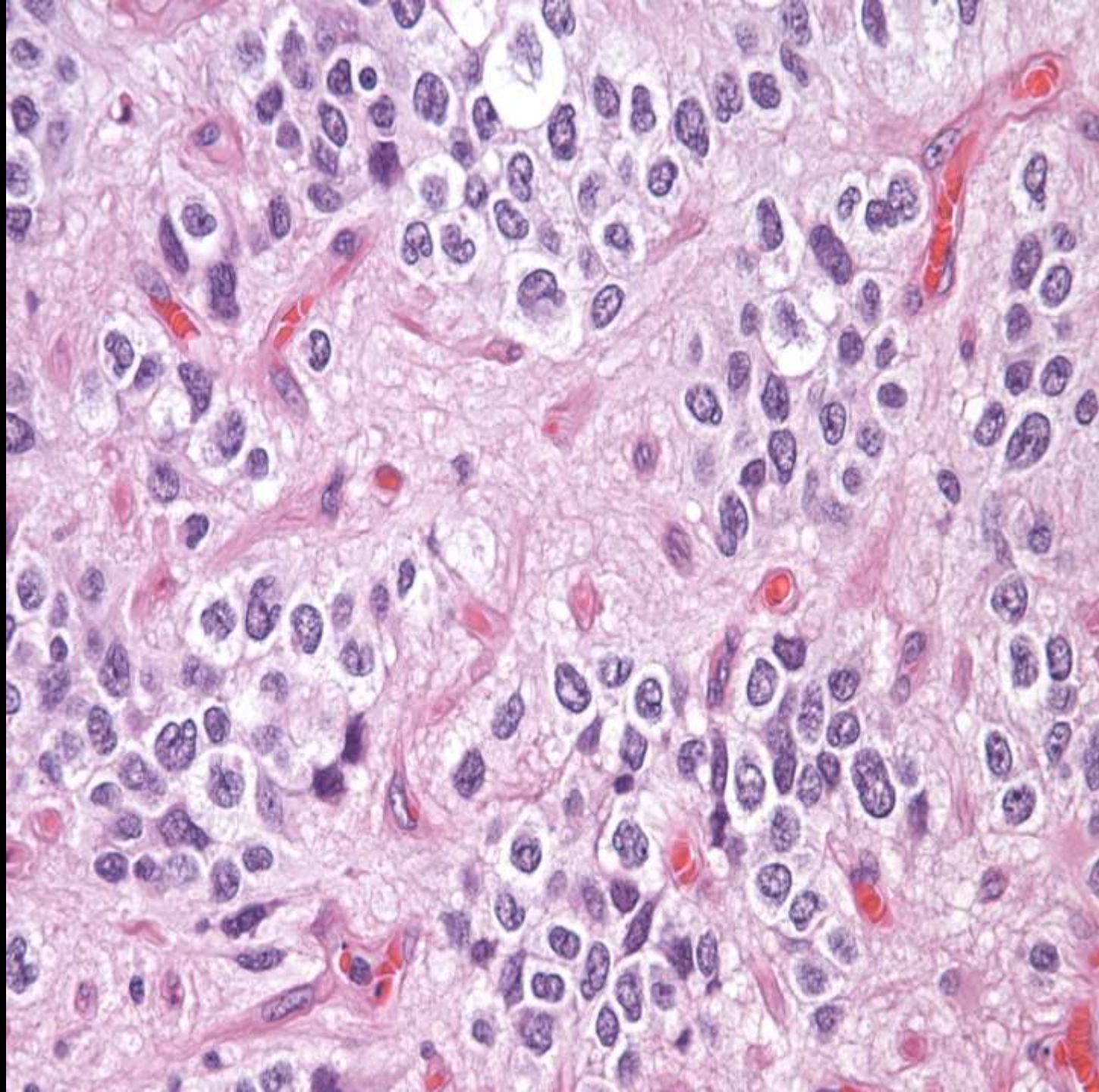










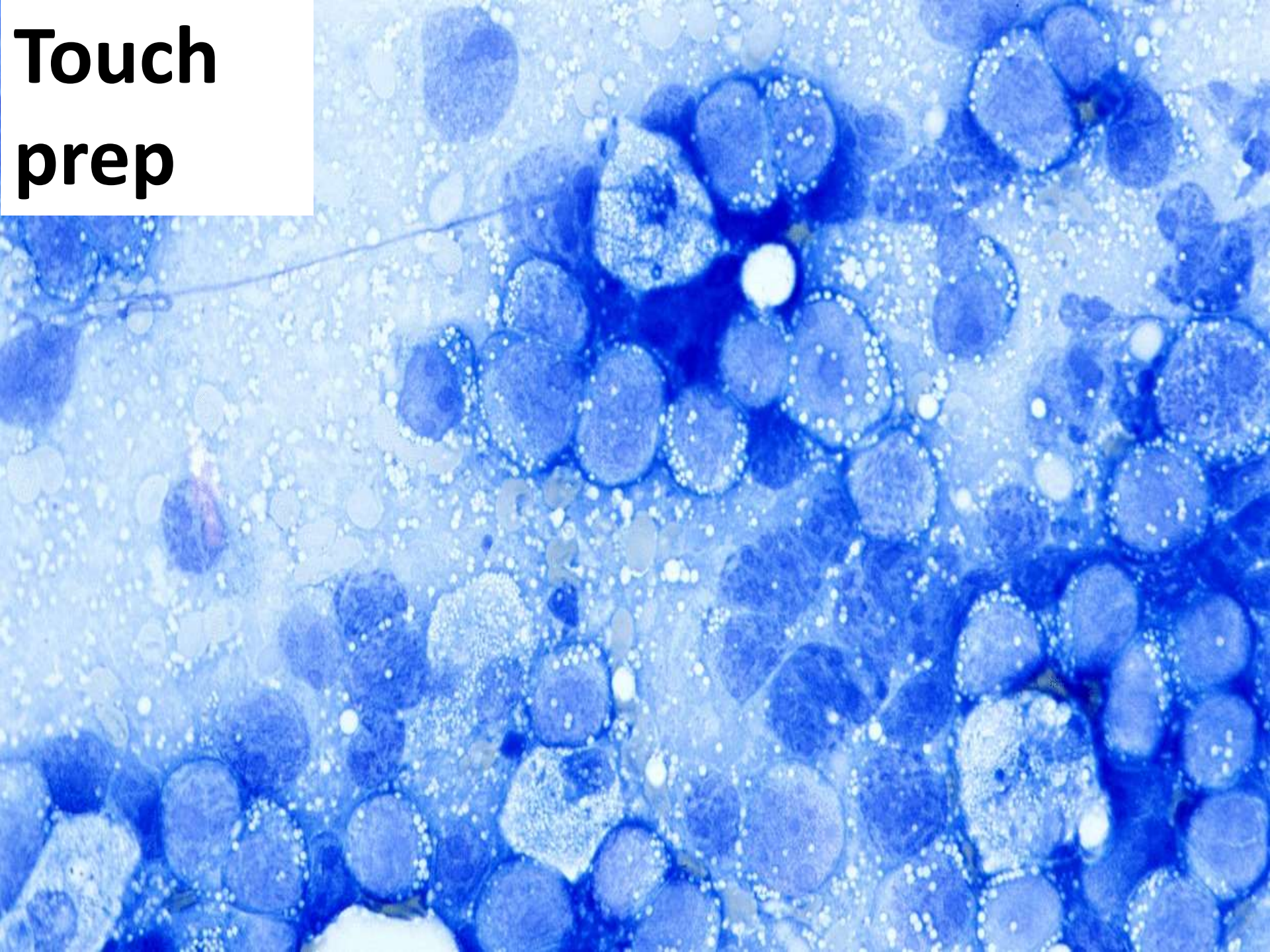


SB 6164

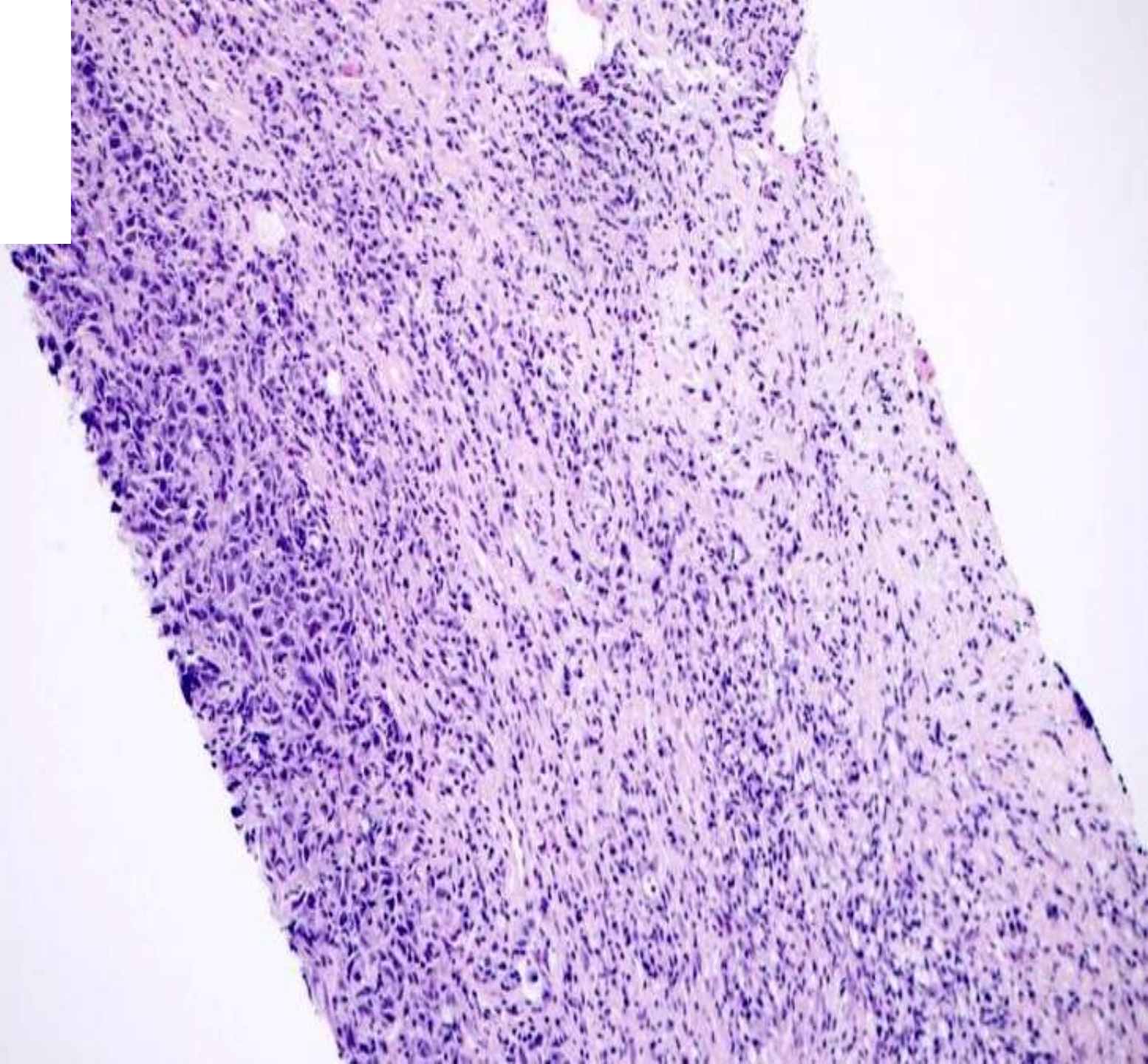
Yiting Li/Yi Xie; UCSF

44-year-old HIV positive man with
retroperitoneal lymphadenopathy.

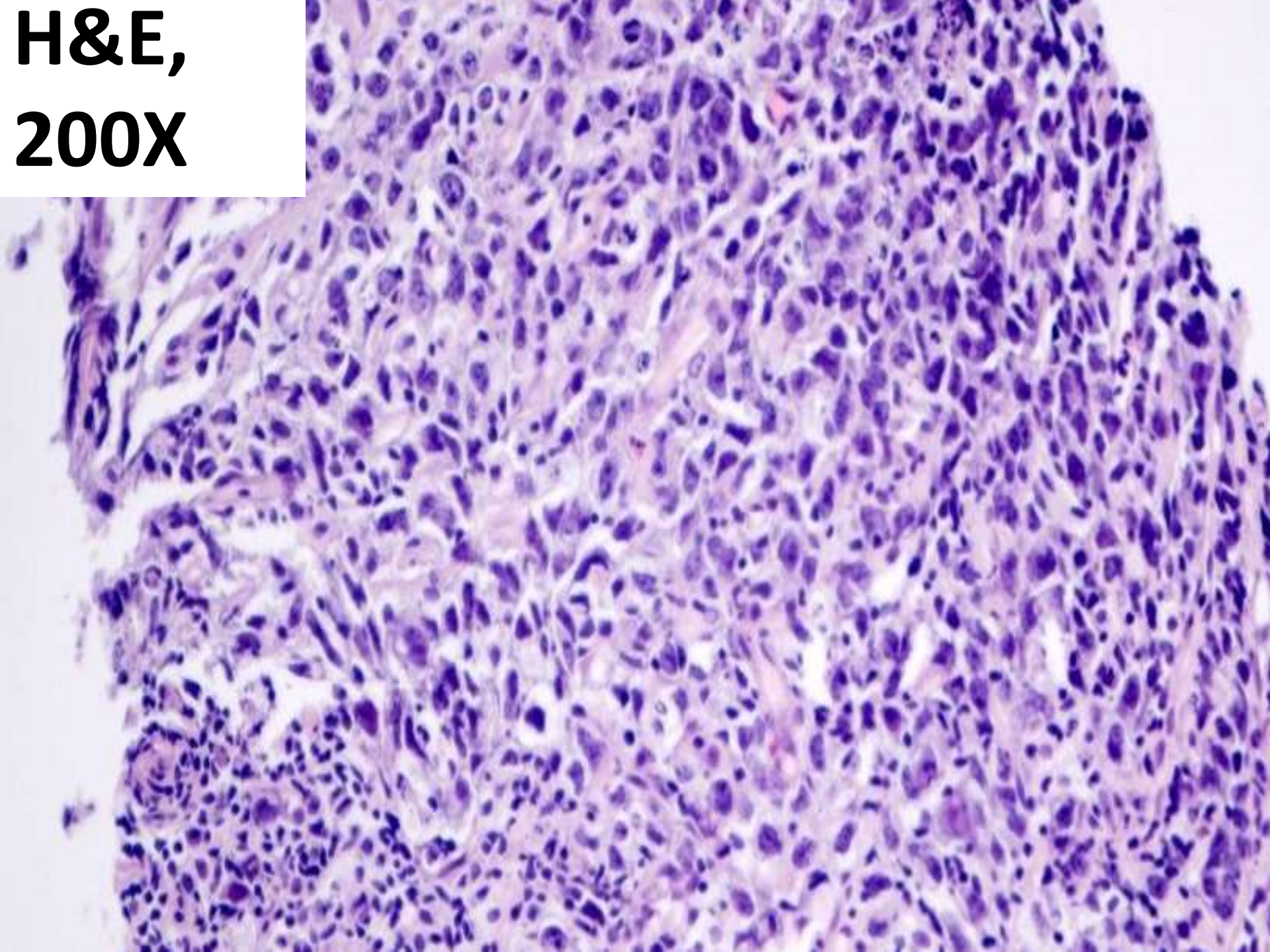
**Touch
prep**



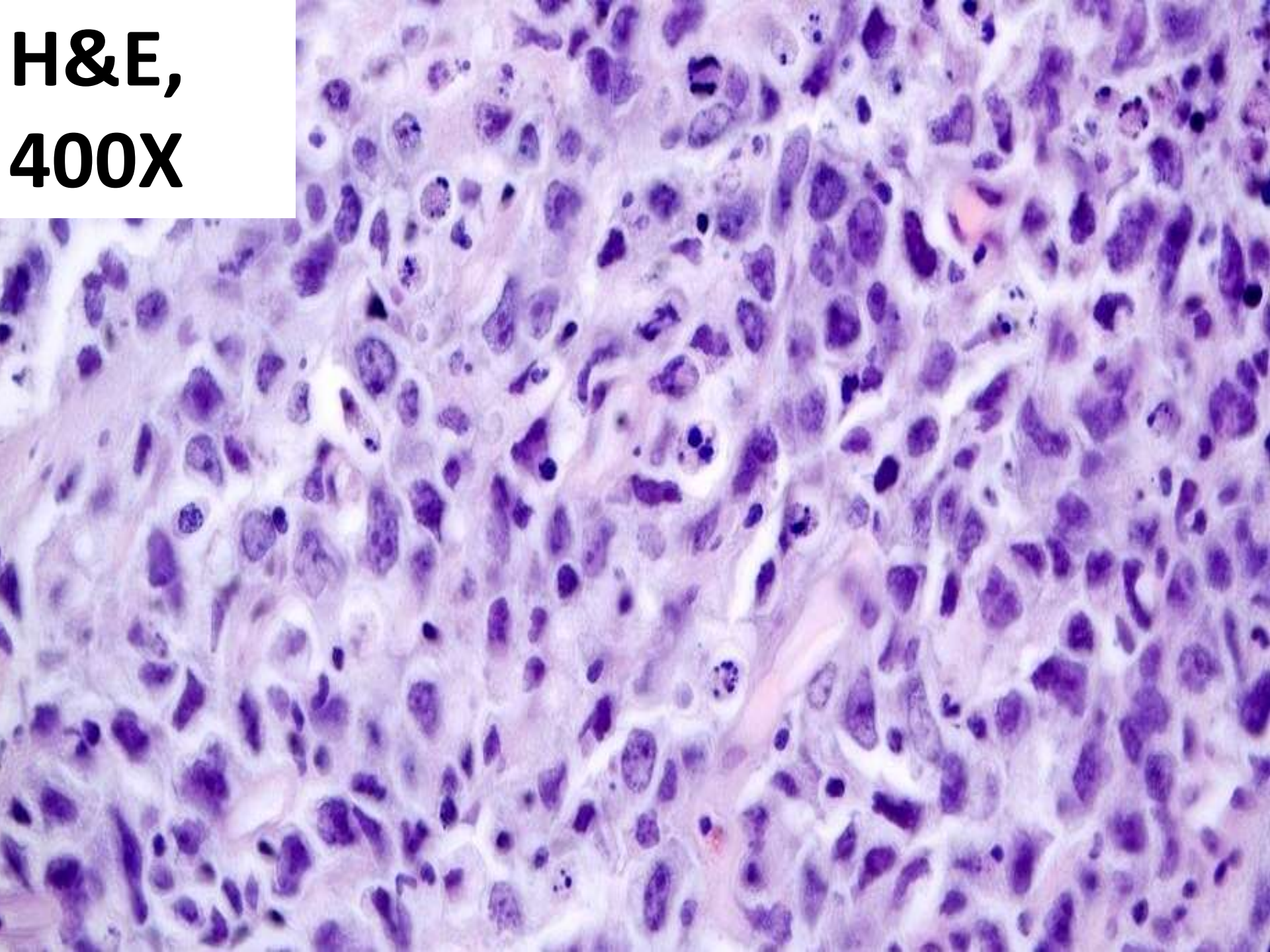
**H&E,
100X**



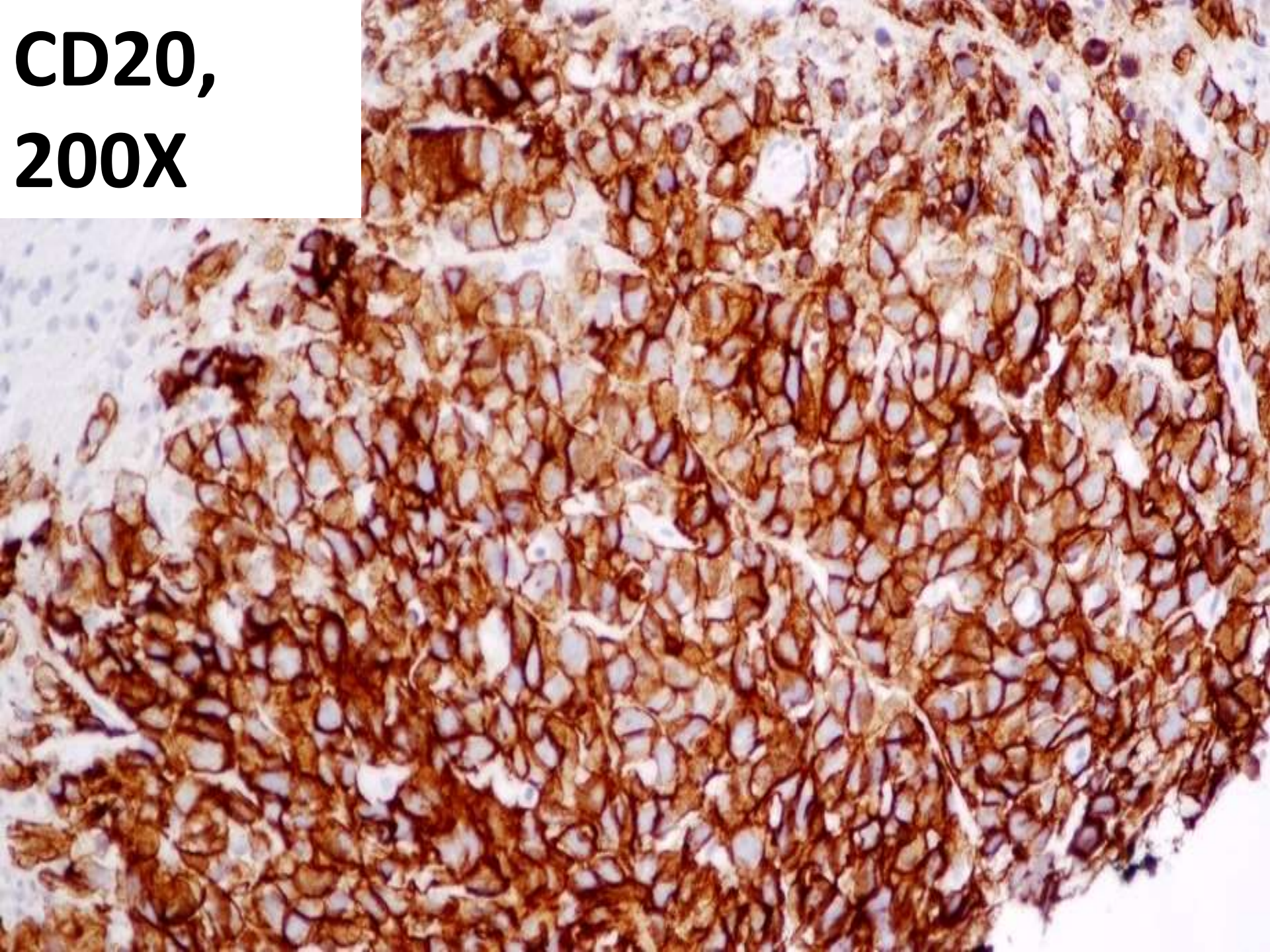
**H&E,
200X**



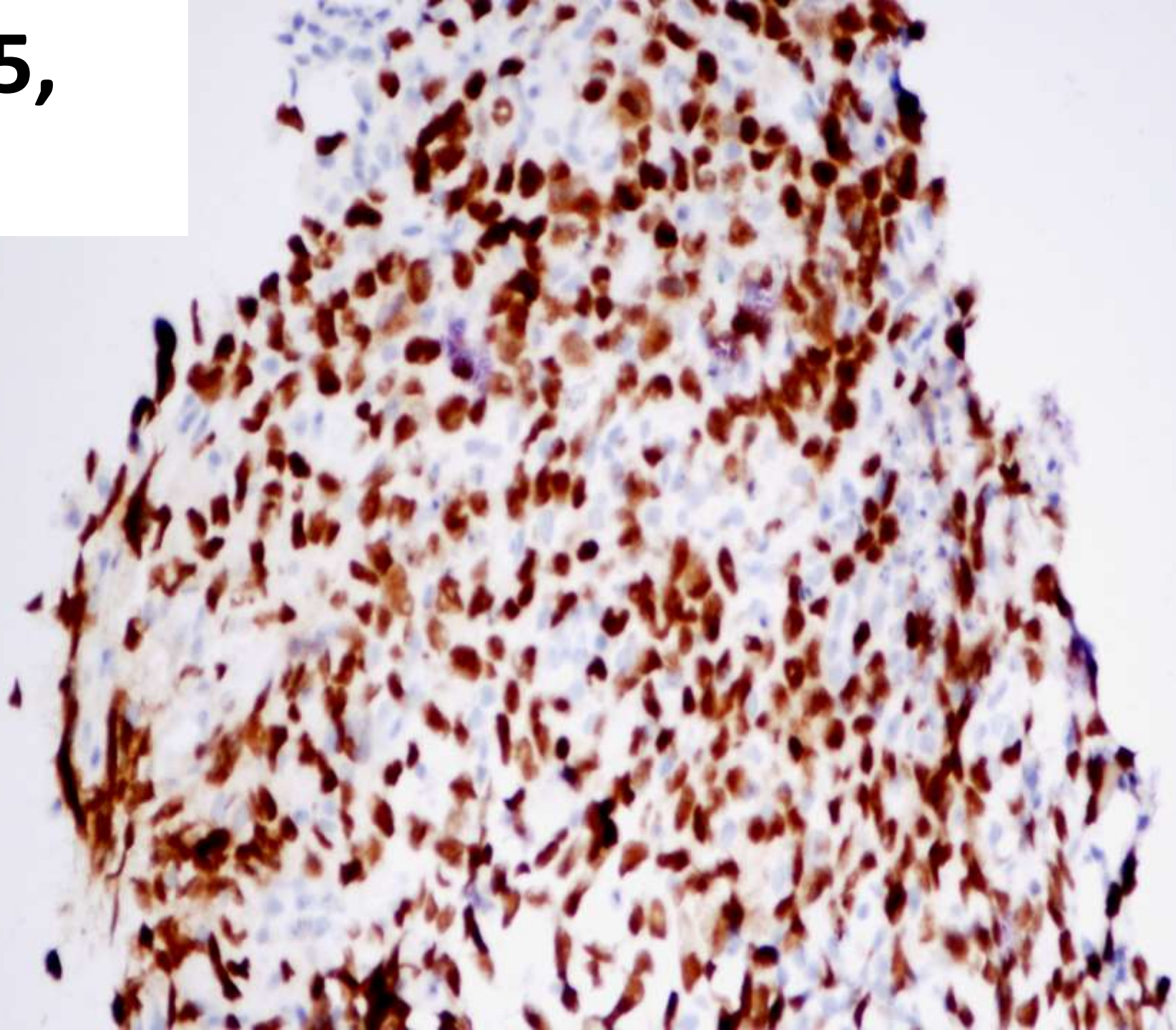
**H&E,
400X**



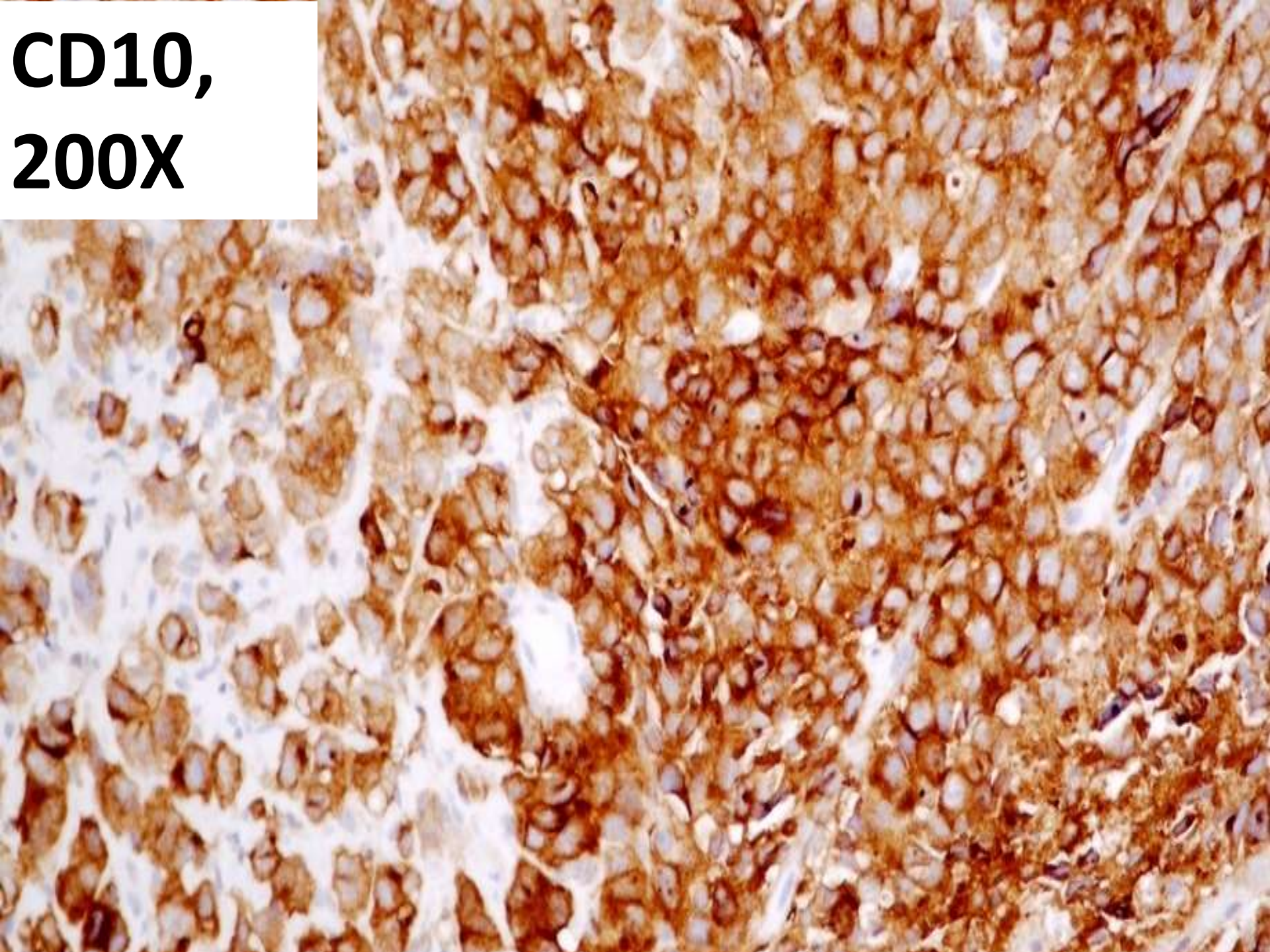
**CD20,
200X**



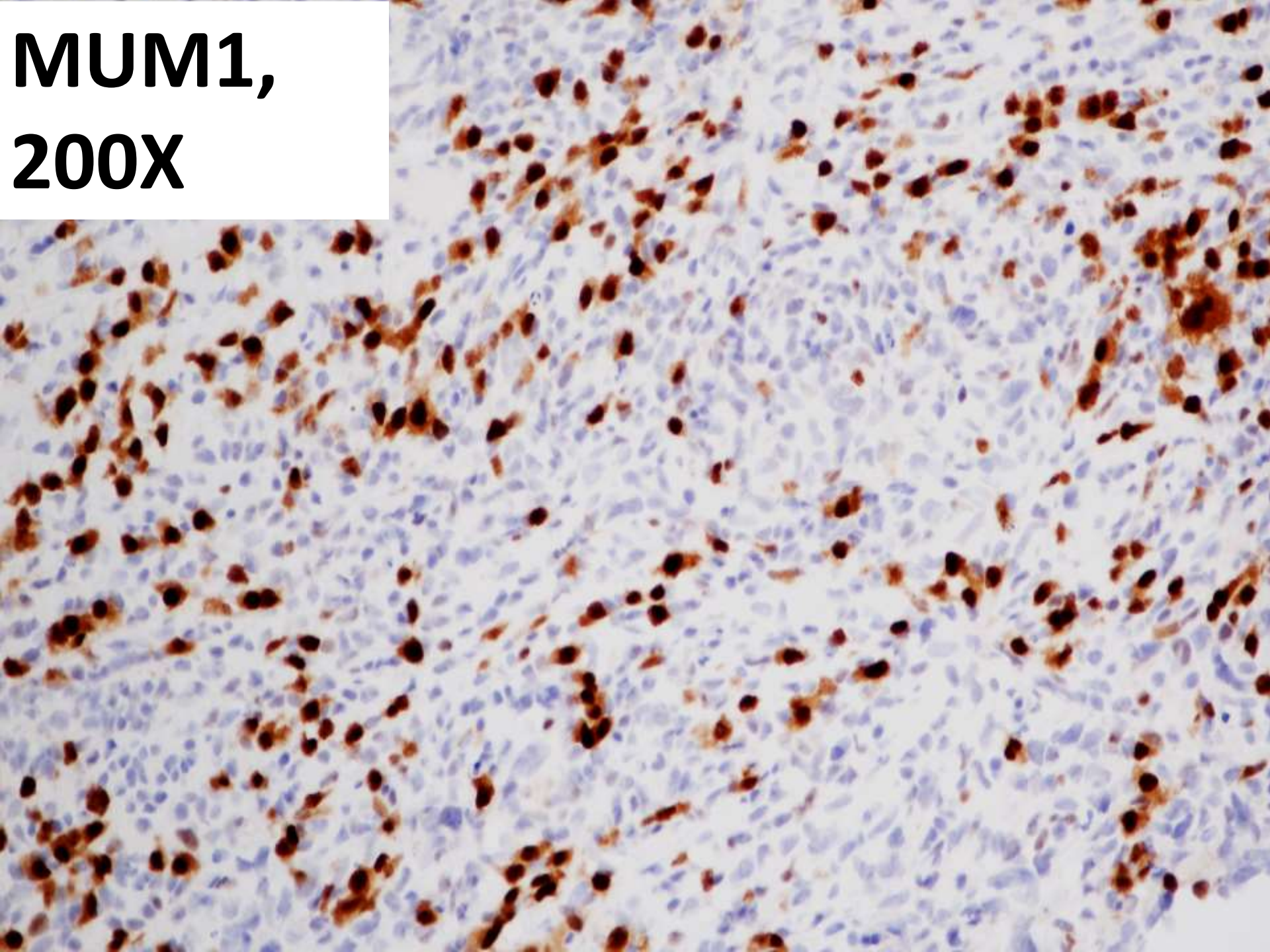
**PAX-5,
200X**



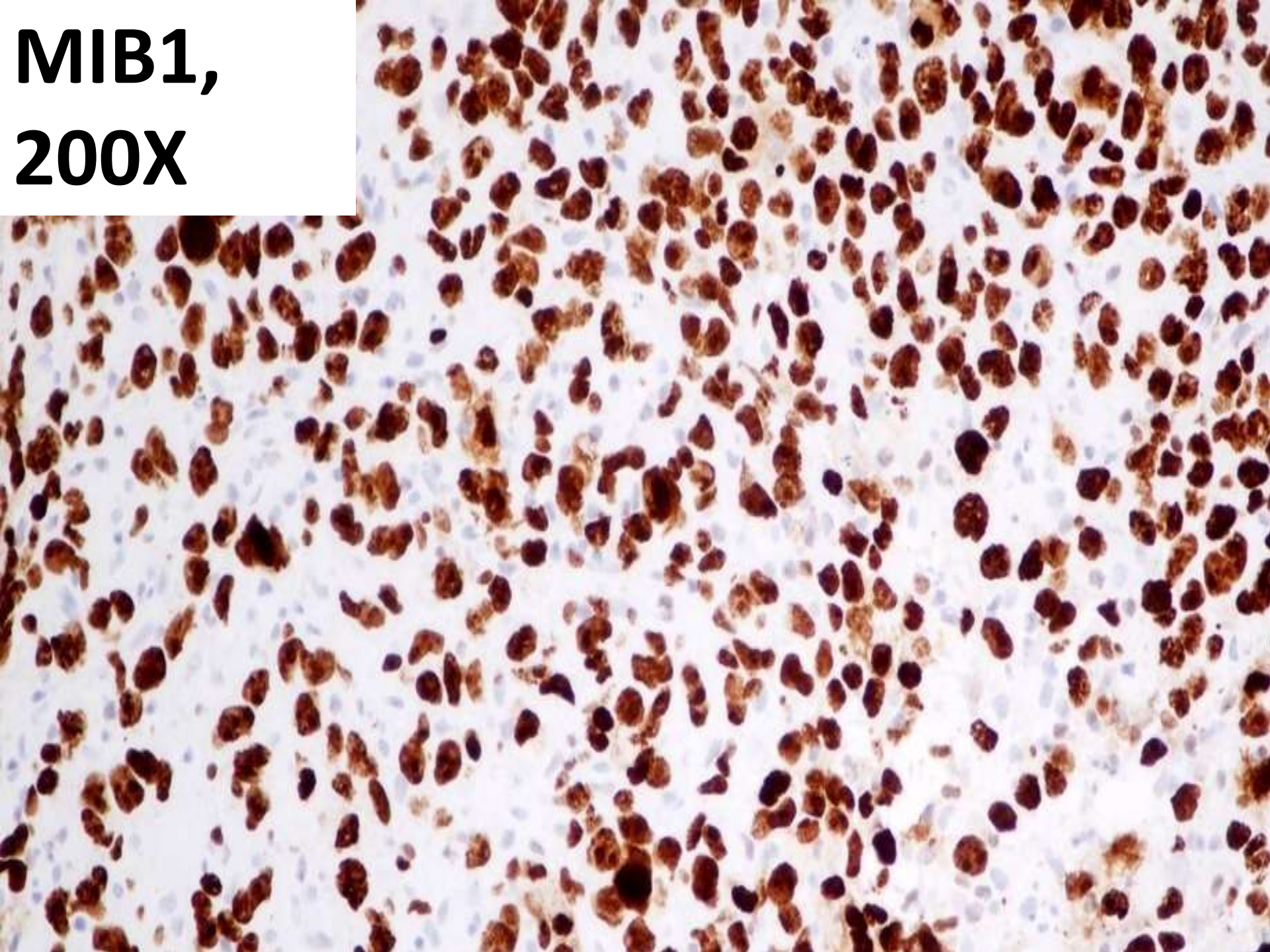
**CD10,
200X**

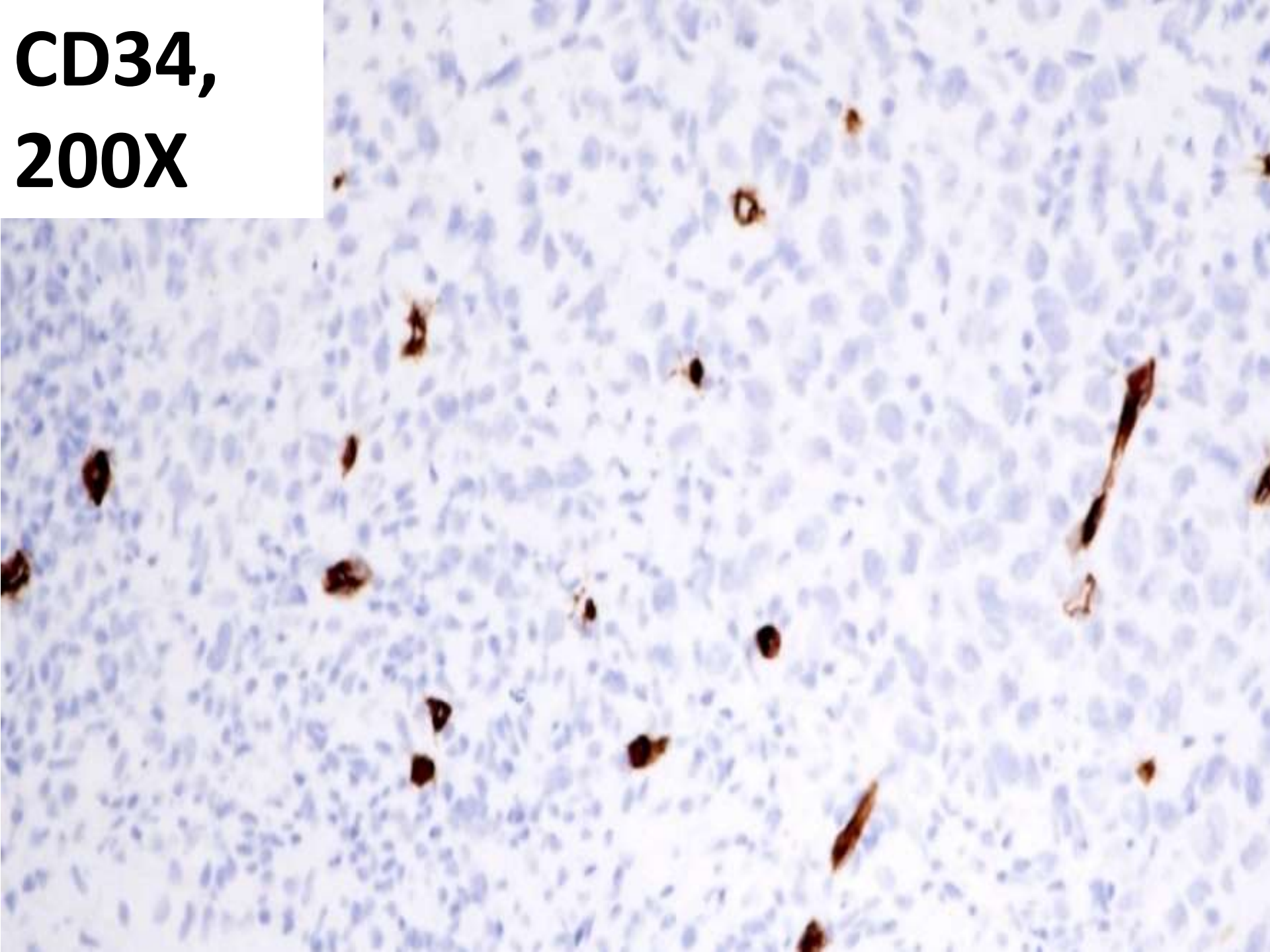


**MUM1,
200X**



**MIB1,
200X**





**CD34,
200X**

Large atypical cells

Positive

- CD20
- PAX-5
- CD10

Negative

- BCL-6
- MUM-1
- CD34
- CD117
- EBER

Ki-67:

-90-95% proliferative rate

CD3:

- Highlights interspersed background small T lymphocytes.

Flow cytometry

Dx: Paucicellular specimen with an abnormal B-cell population

- Limited by low cellularity
- The CD45 negative cells gate events are
 - Positive for CD19, CD20, and CD10
 - Negative for surface light chain

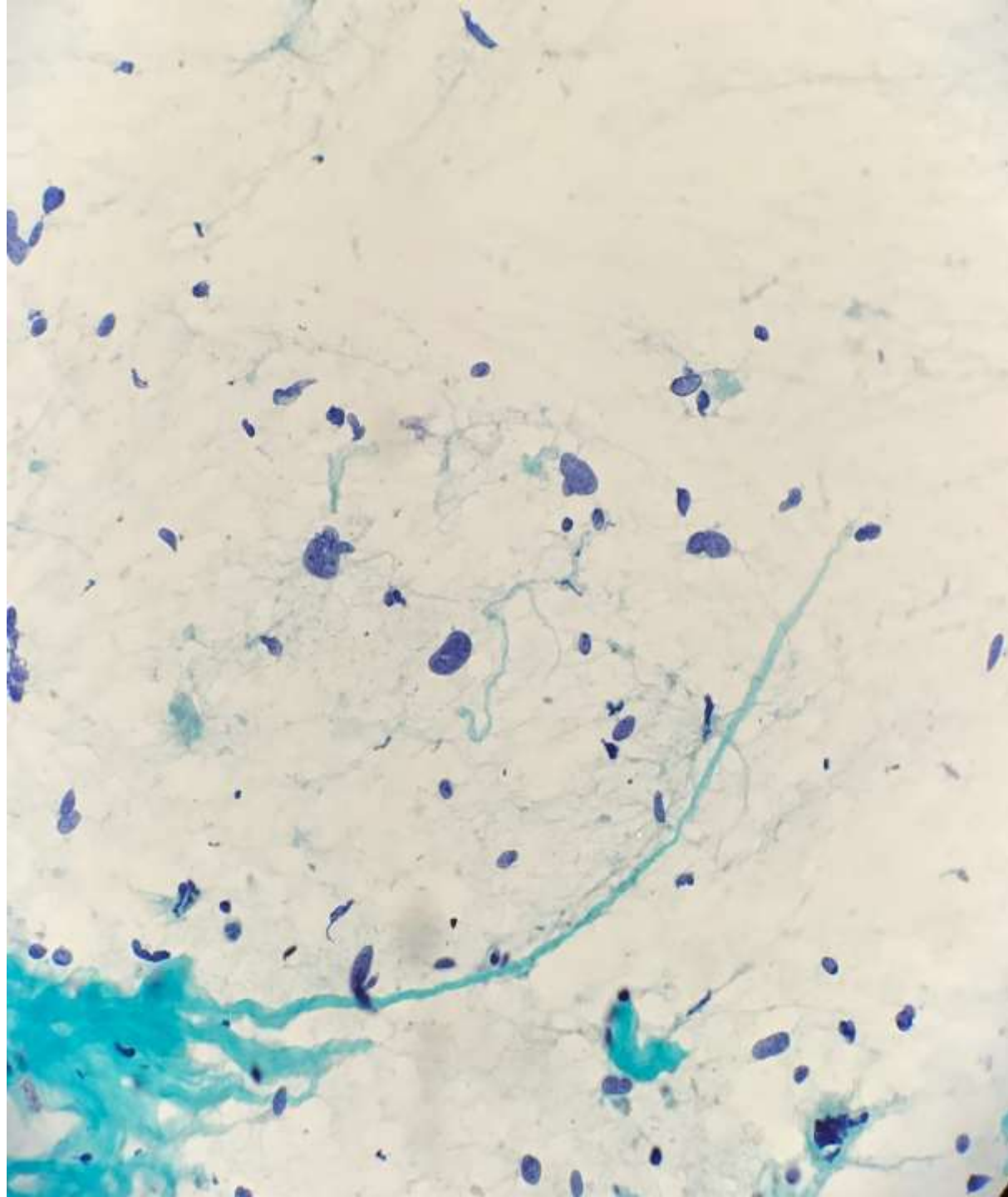FISH

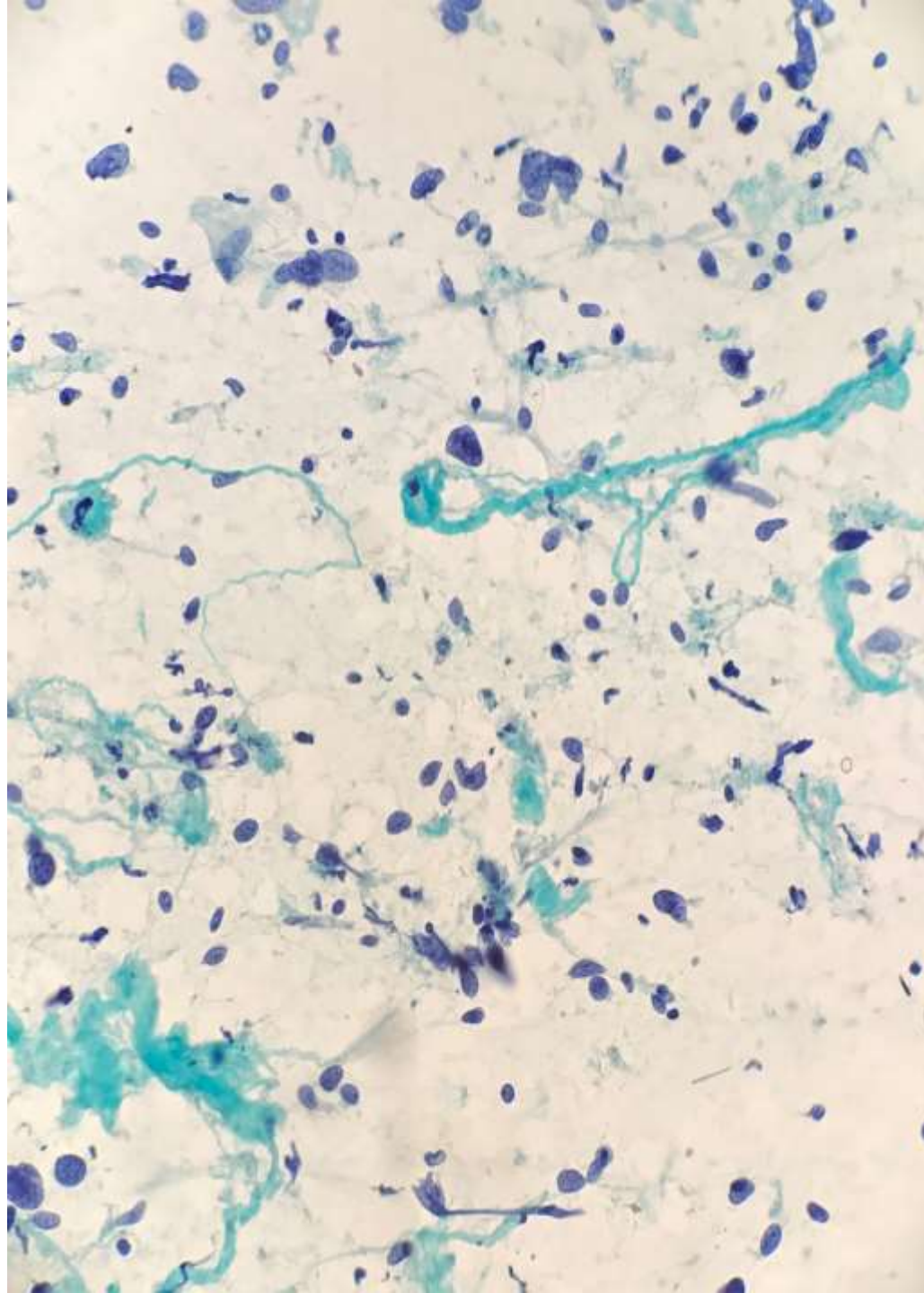
- Positive for t(8;14)(q24;q32) IGH/MYC
- Positive for additional copies of the BCL6 gene or chromosome 3
- Negative for t(14;18)(q32;q21) IGH/BCL2

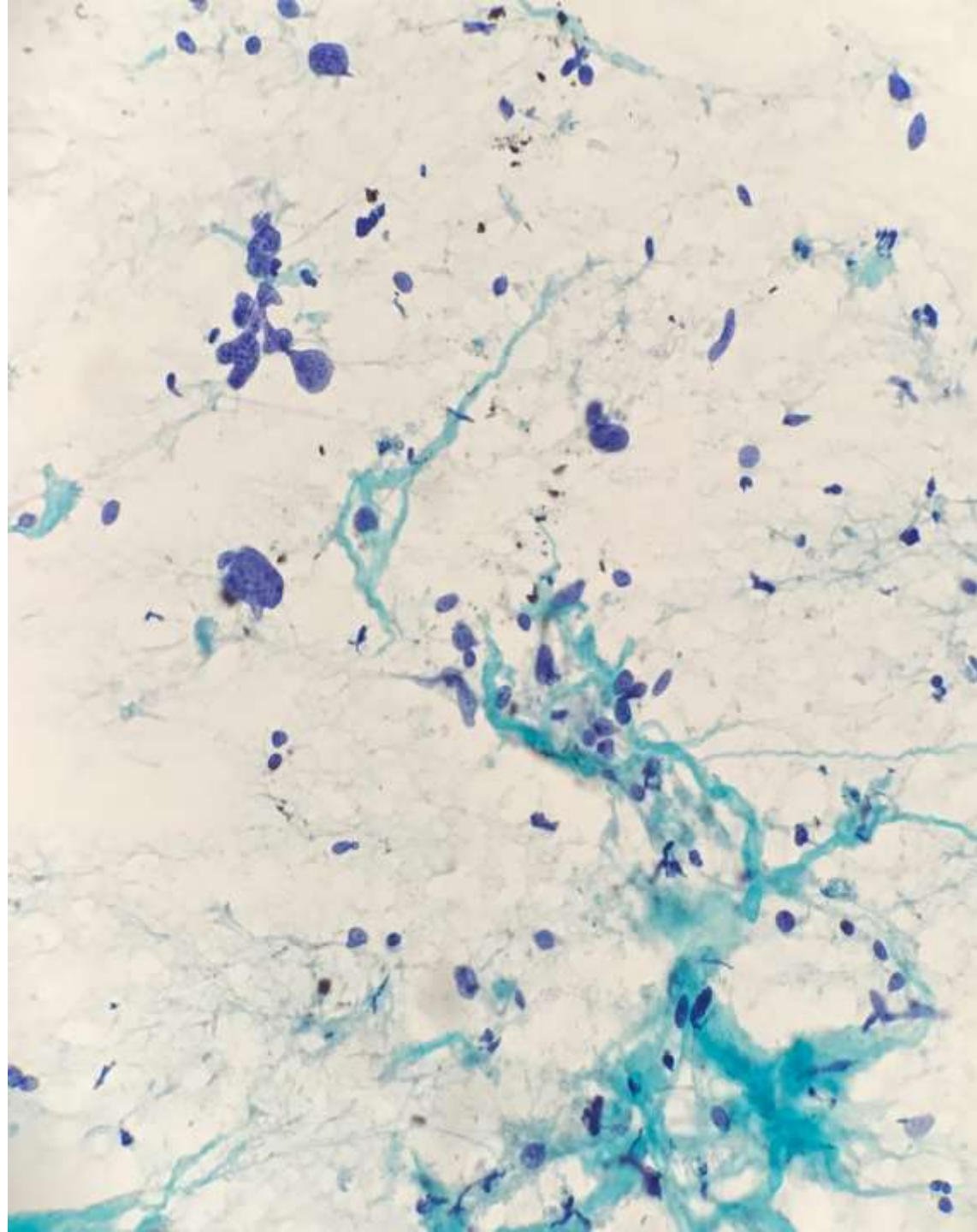
SB 6165

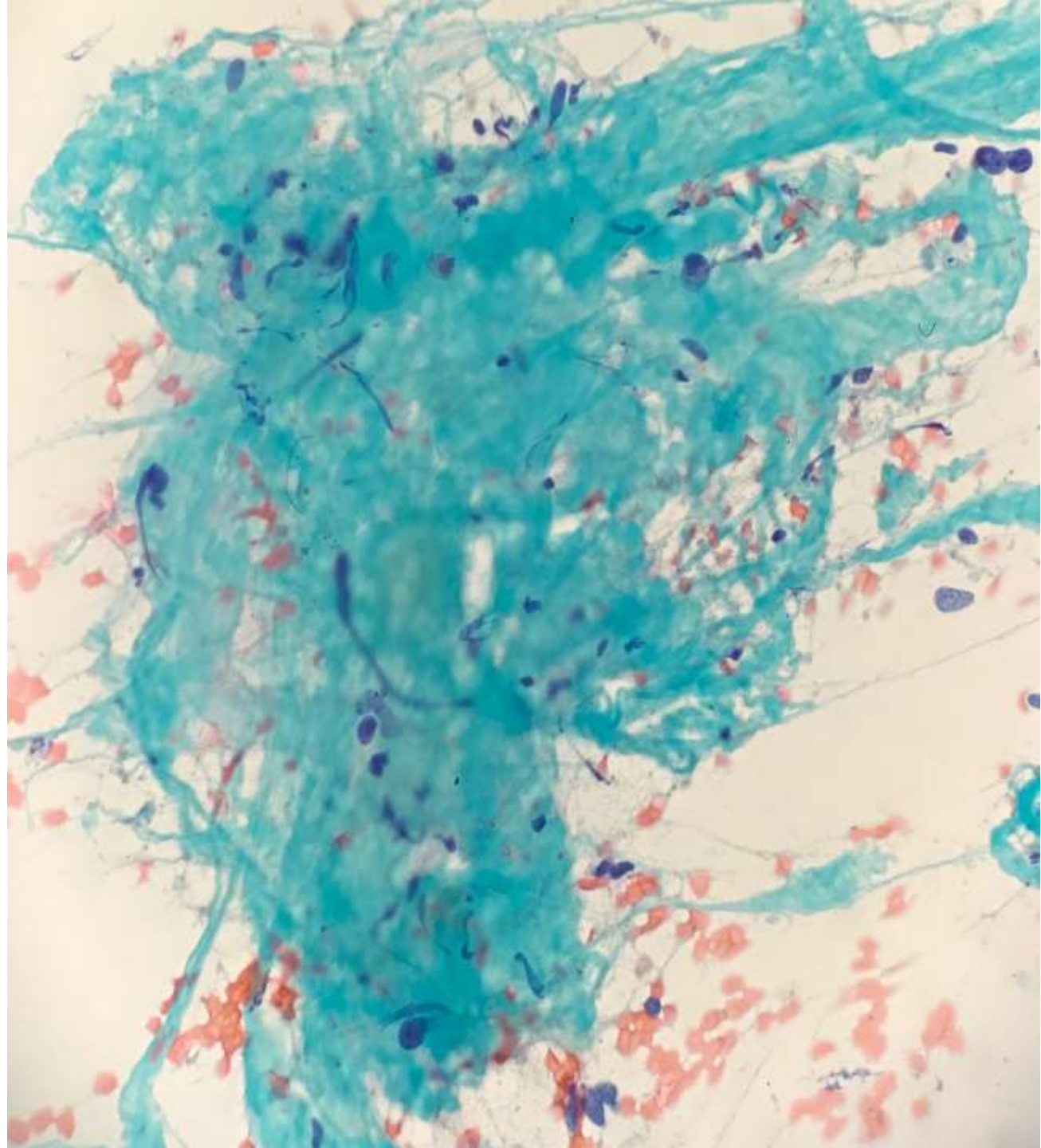
Michael DiMaio; Marin General Hospital

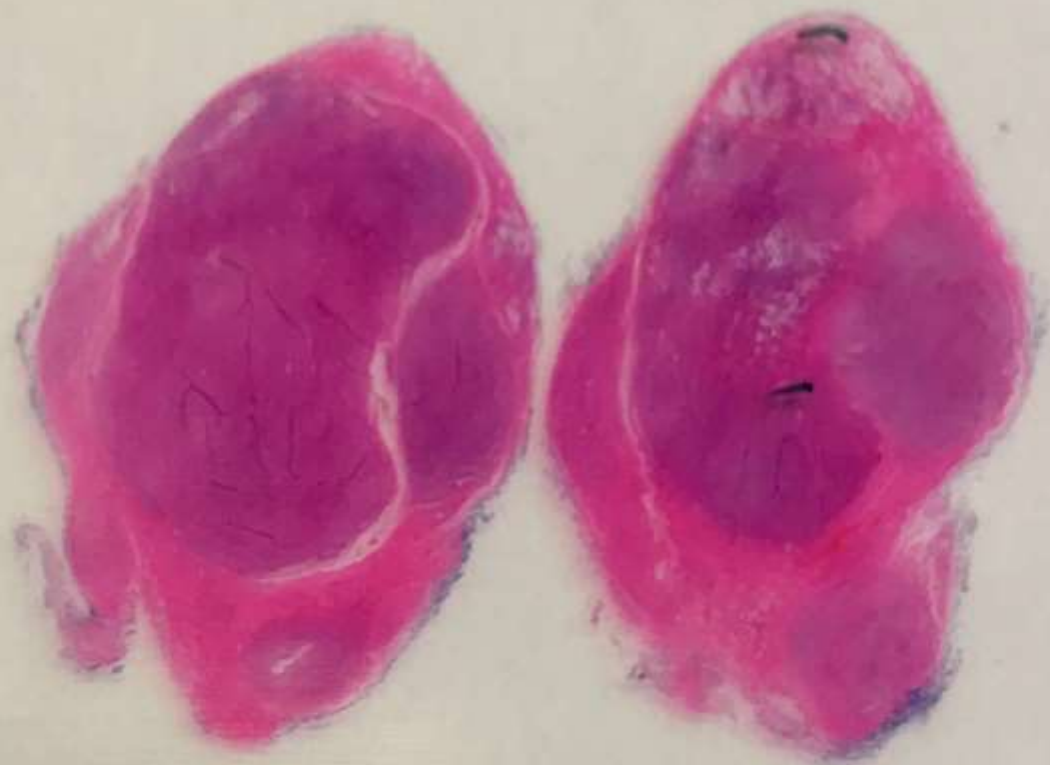
55-year-old man with post-auricular 2 to 3cm rubbery, mobile, painless nodule present for several years covered by his hairline, and has not grown noticeably. It was noticed when his wife touched his head. He presented initially for FNA, then 3 months later for excision.







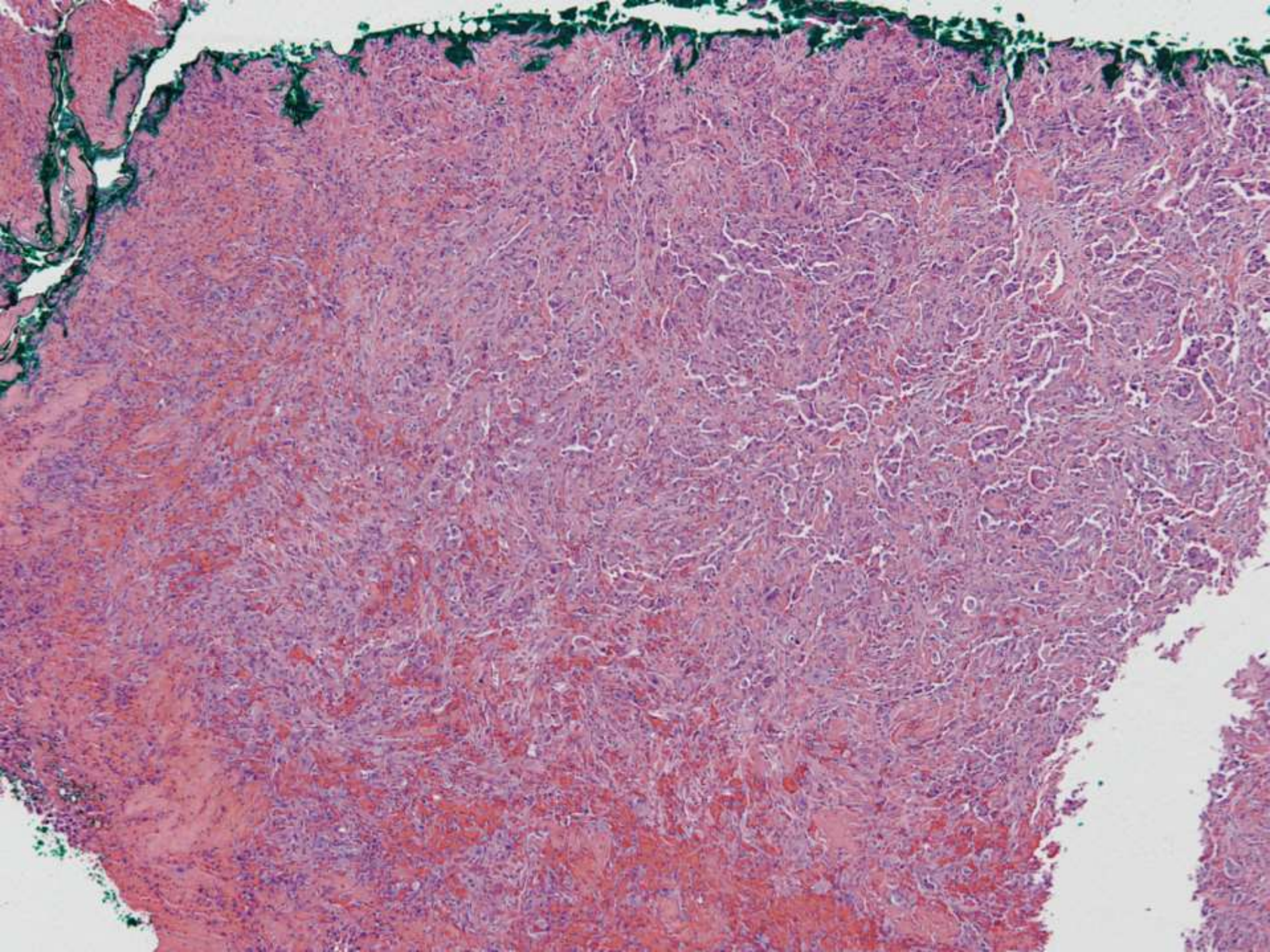


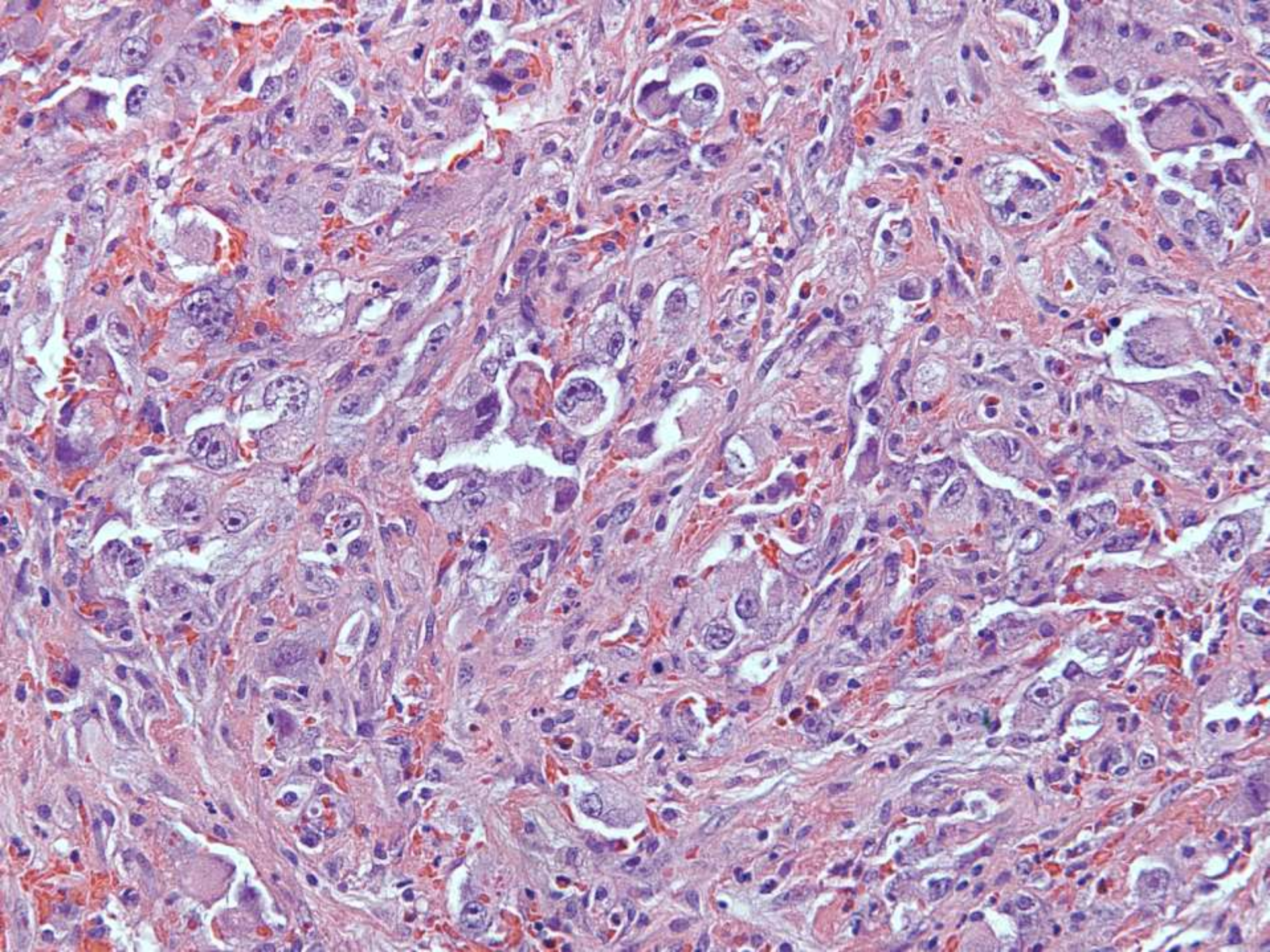


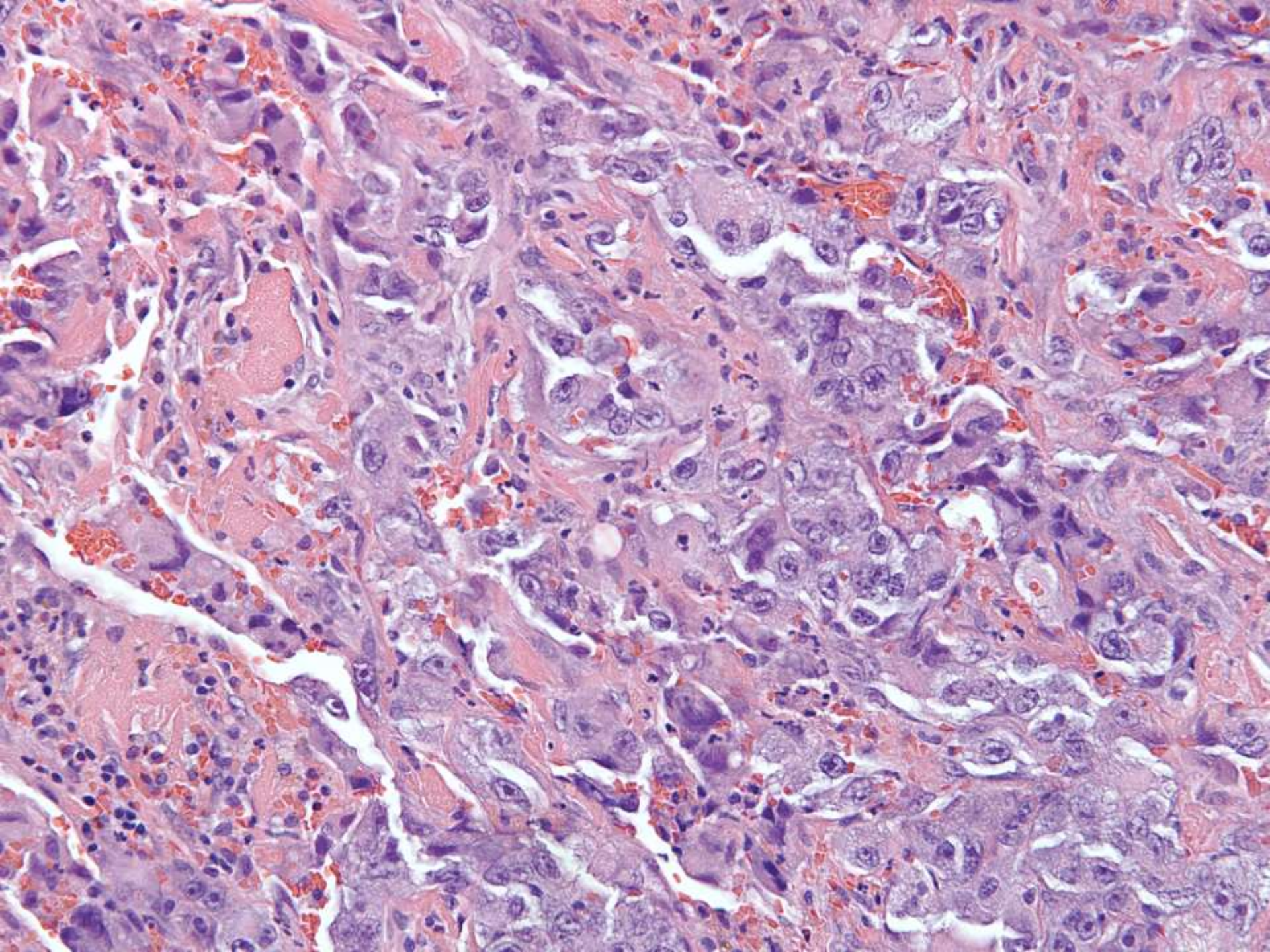
SB 6166

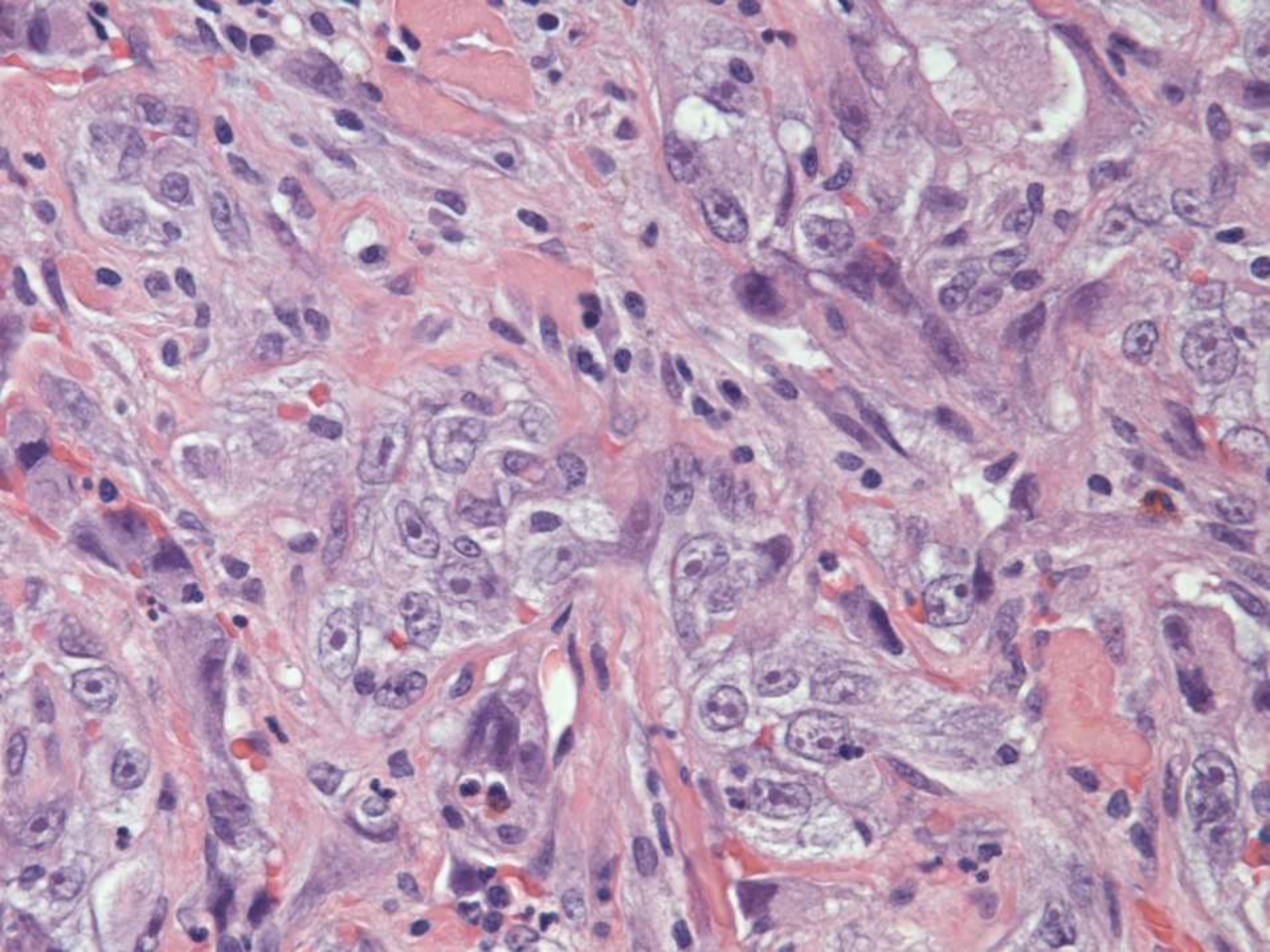
**Greg Charville/Dean Fong; Stanford & Palo
Alto VA**

73-year-old man with a unilateral pleural
effusion. Biopsy of thickened pleura submitted.





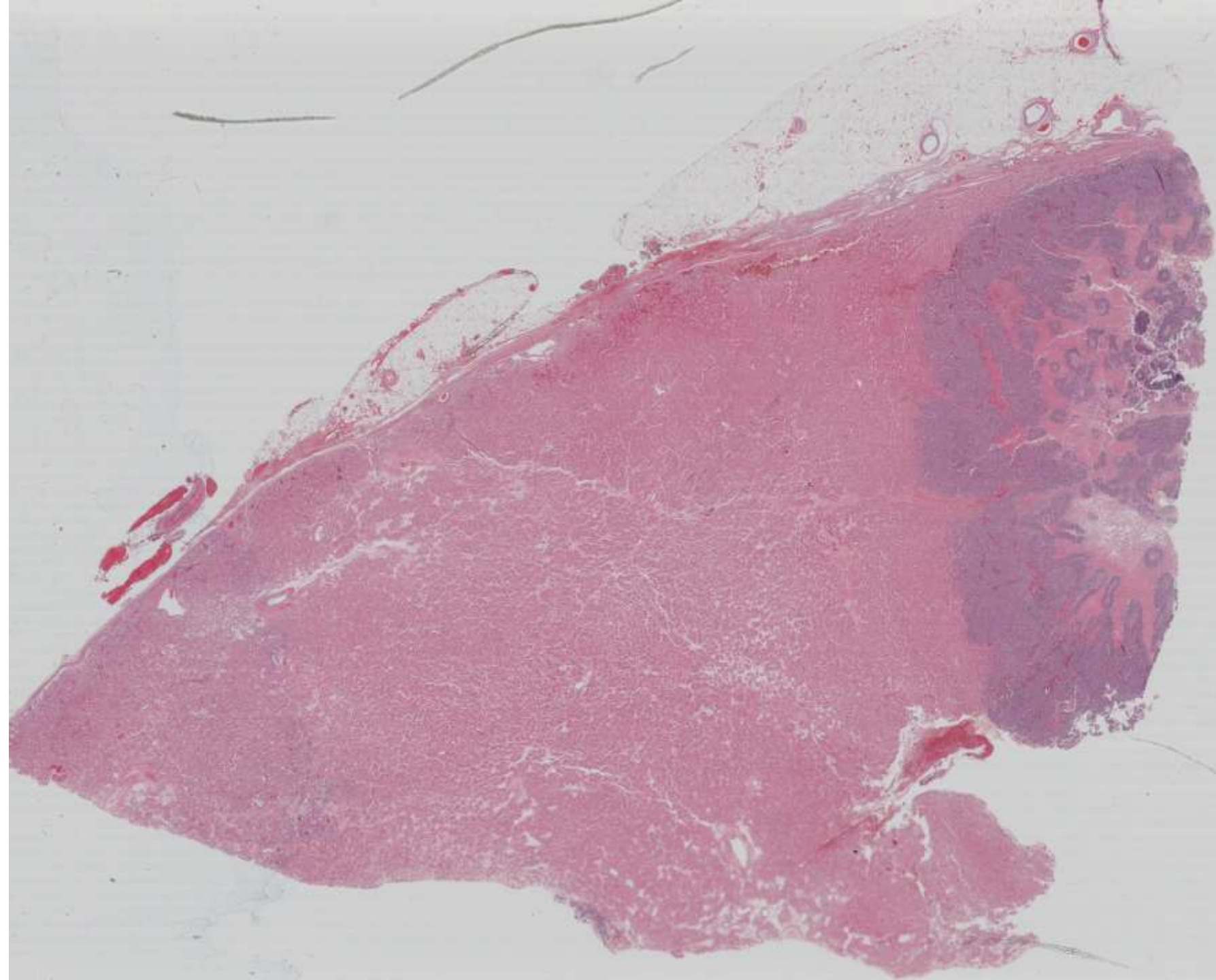


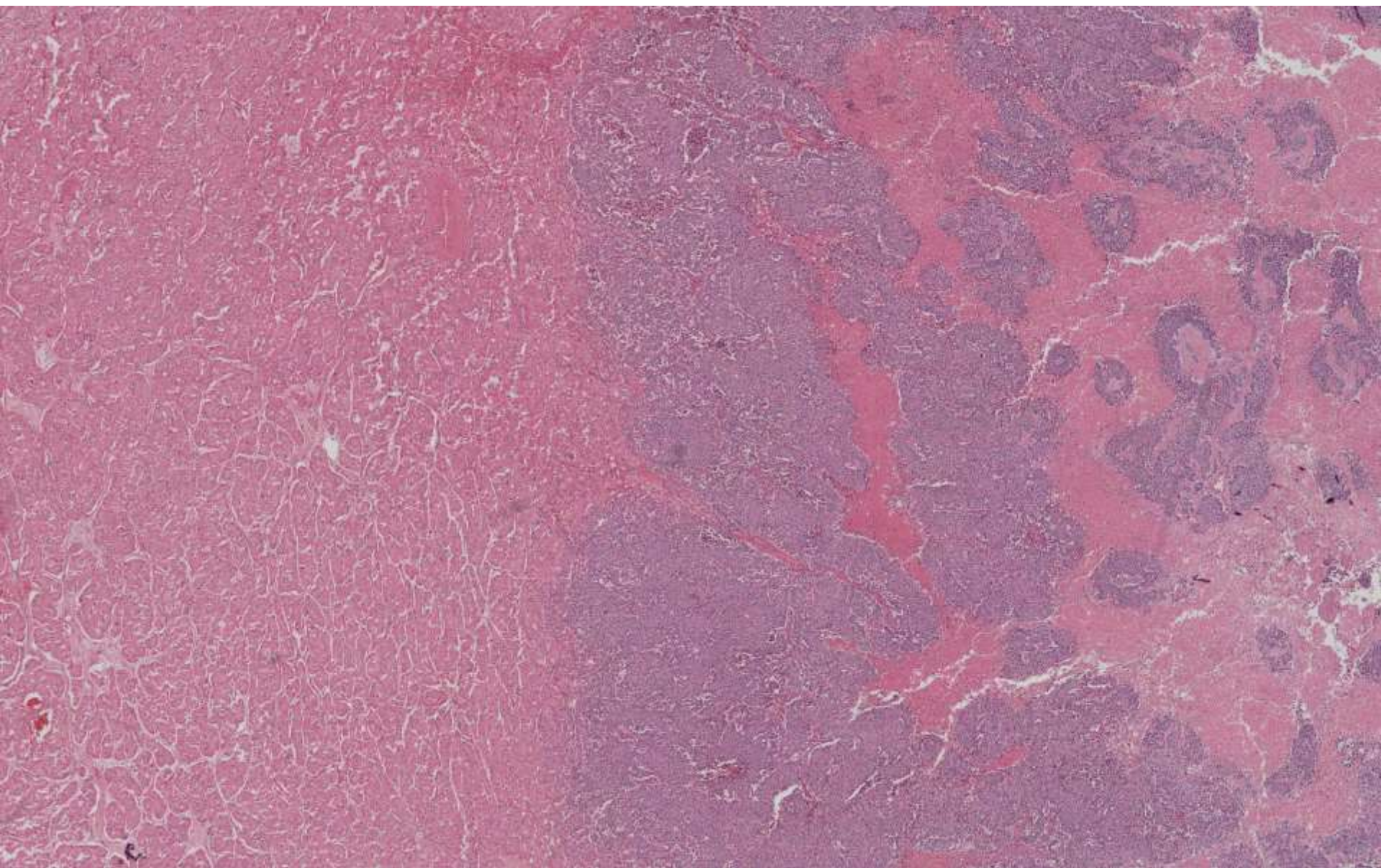


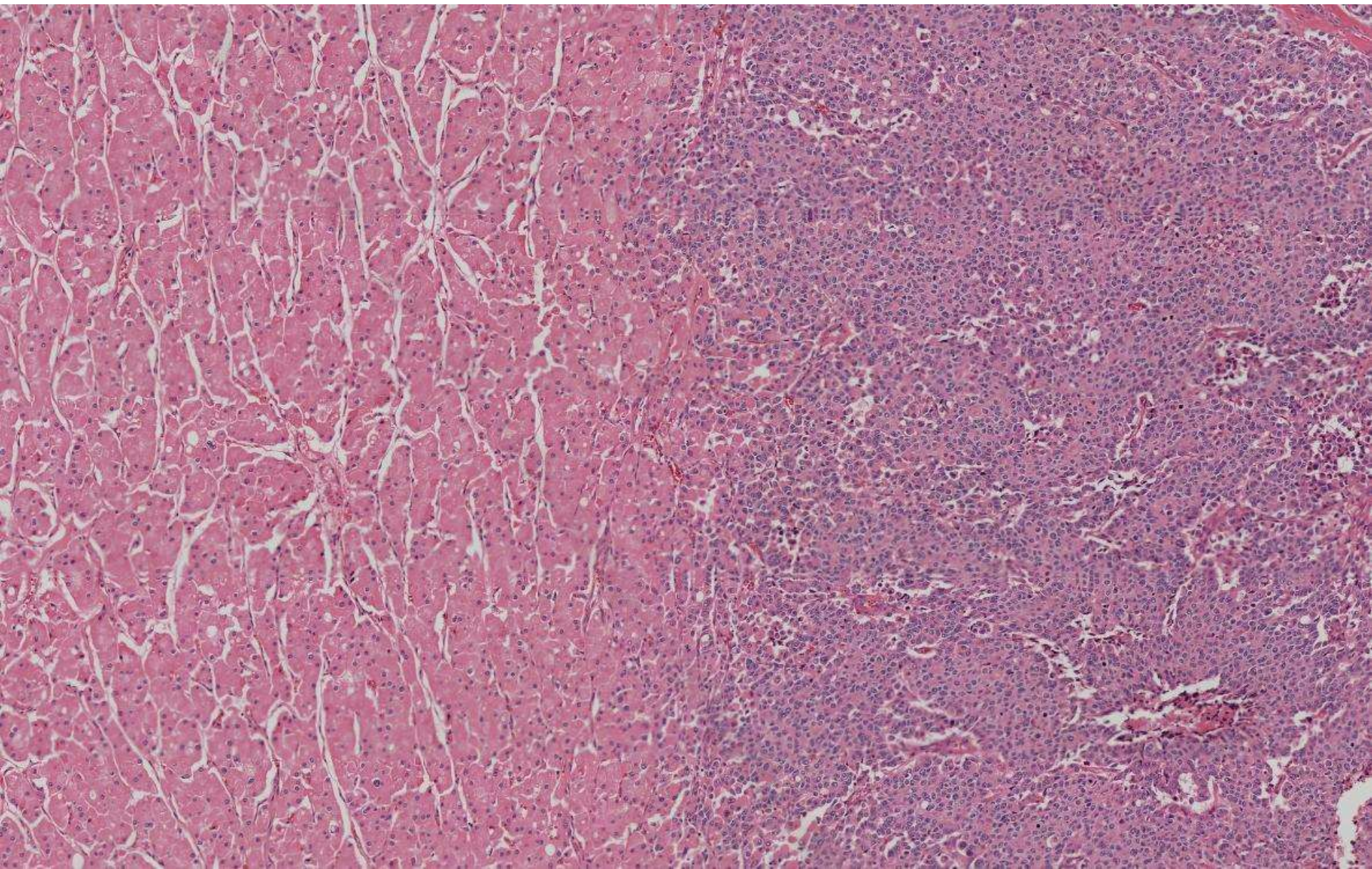
SB 6167
(scanned slide available)

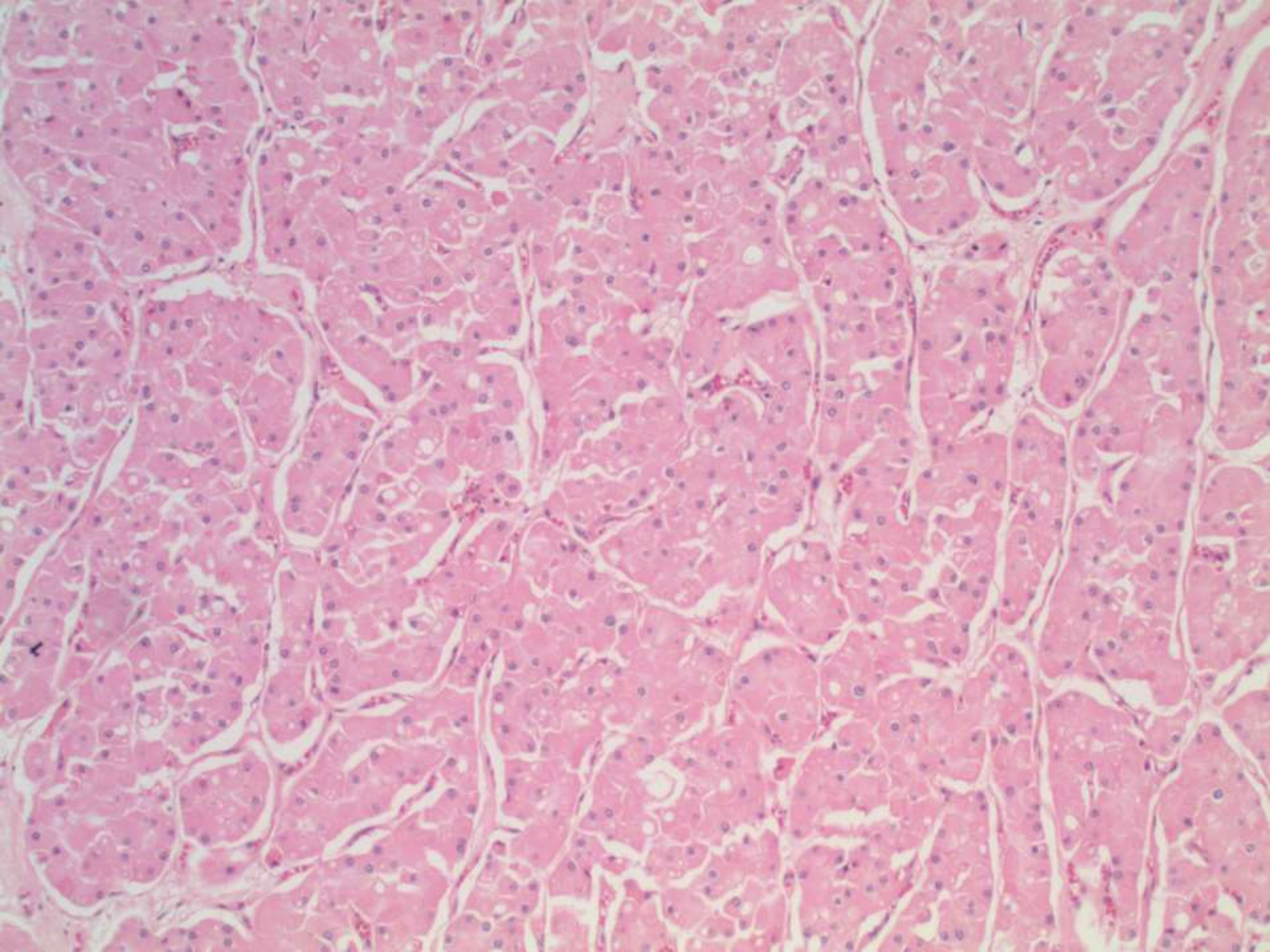
**Greg Charville/Megan Troxell;
Stanford**

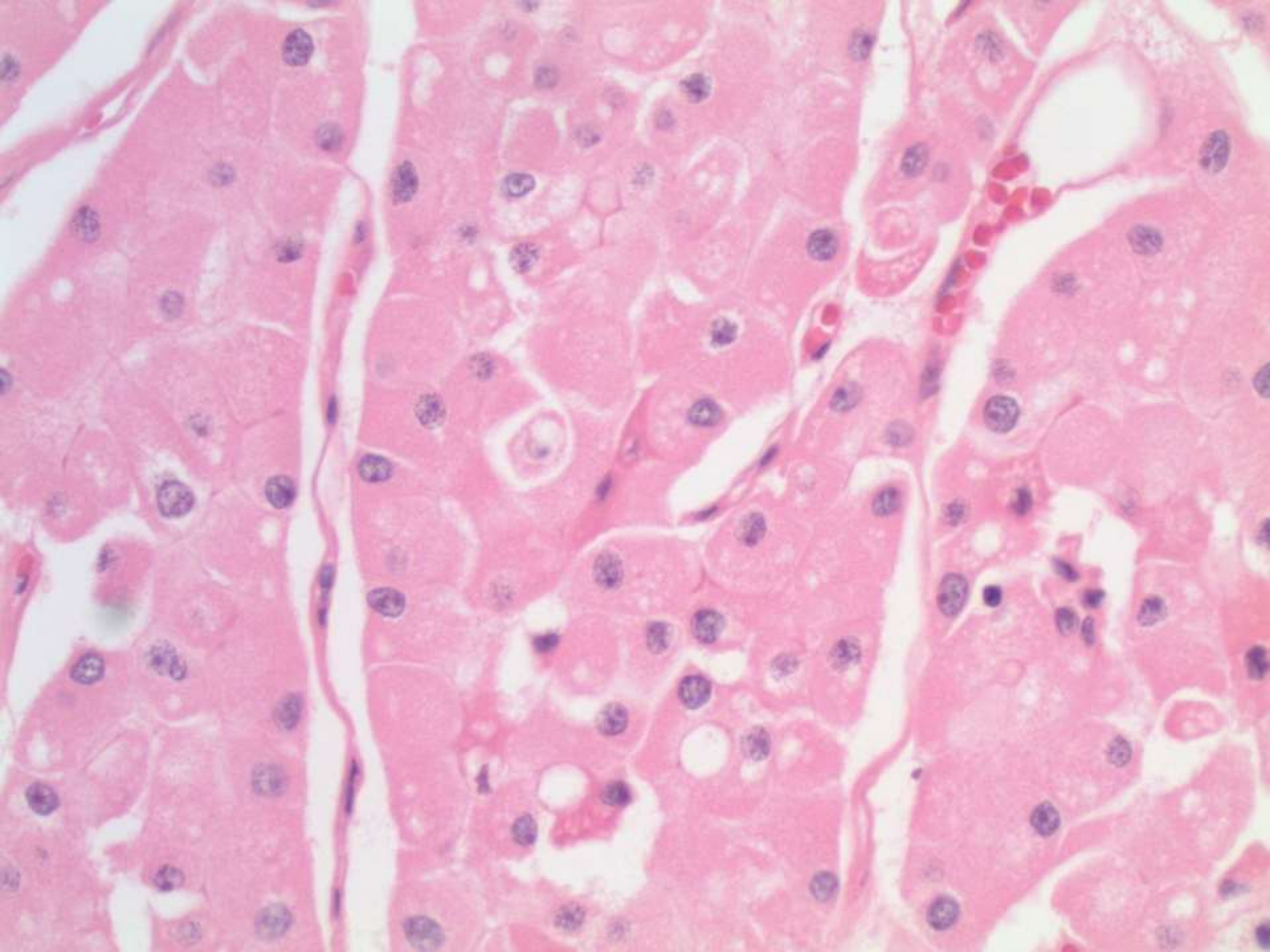
Woman with large renal mass.

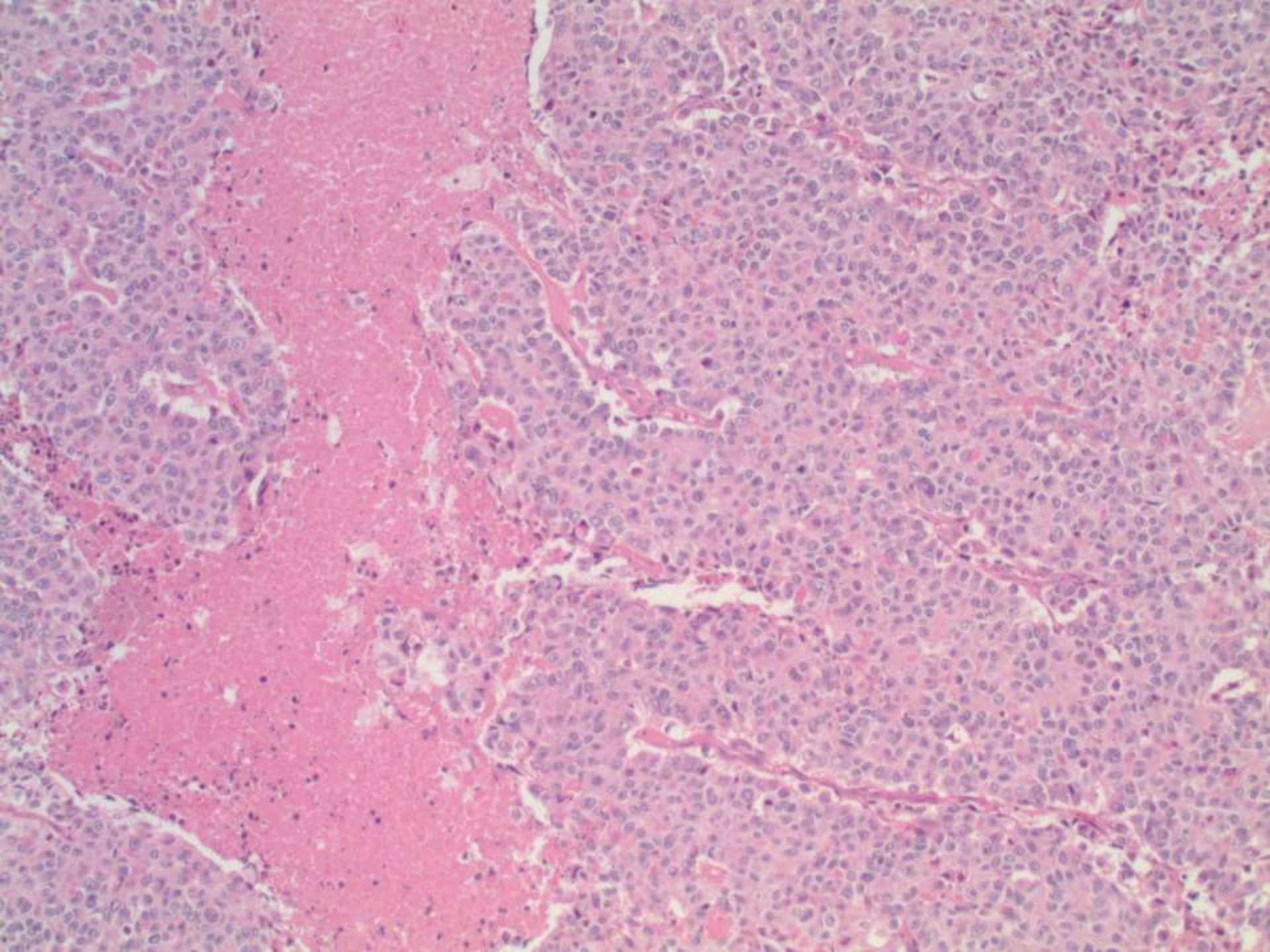


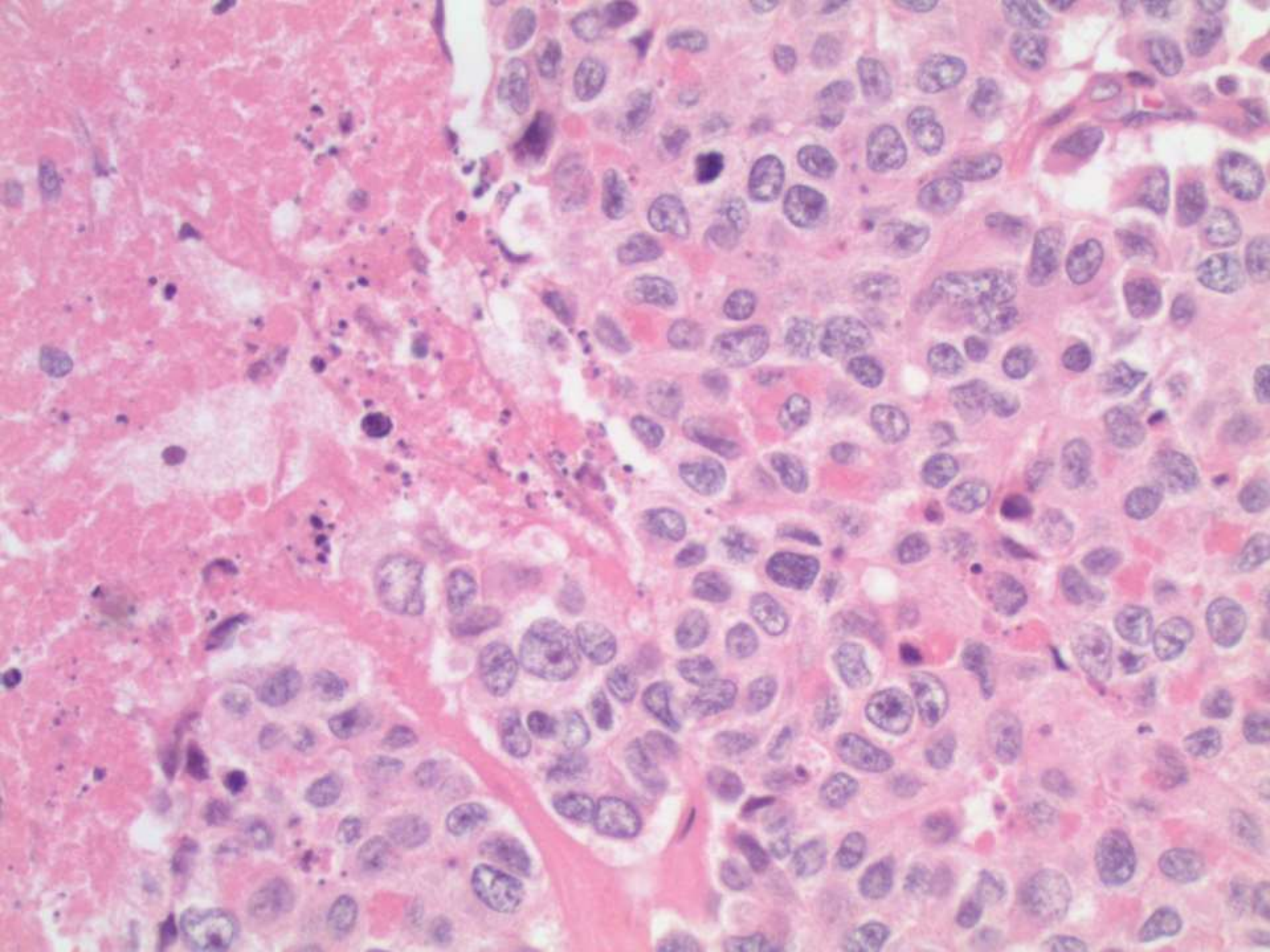










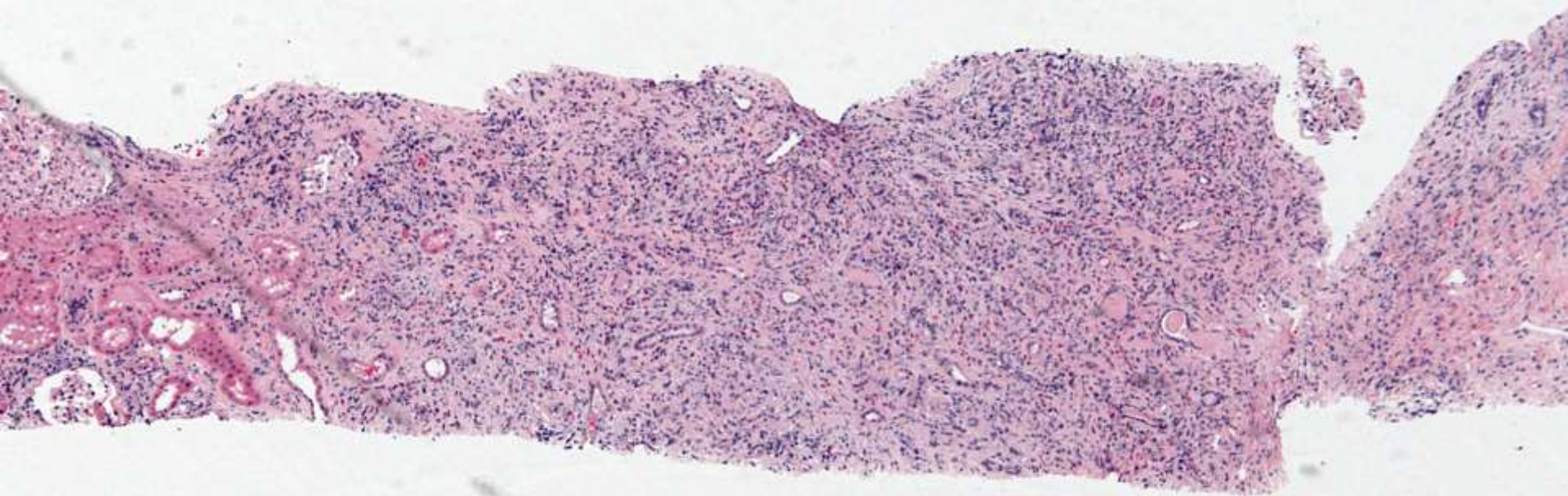


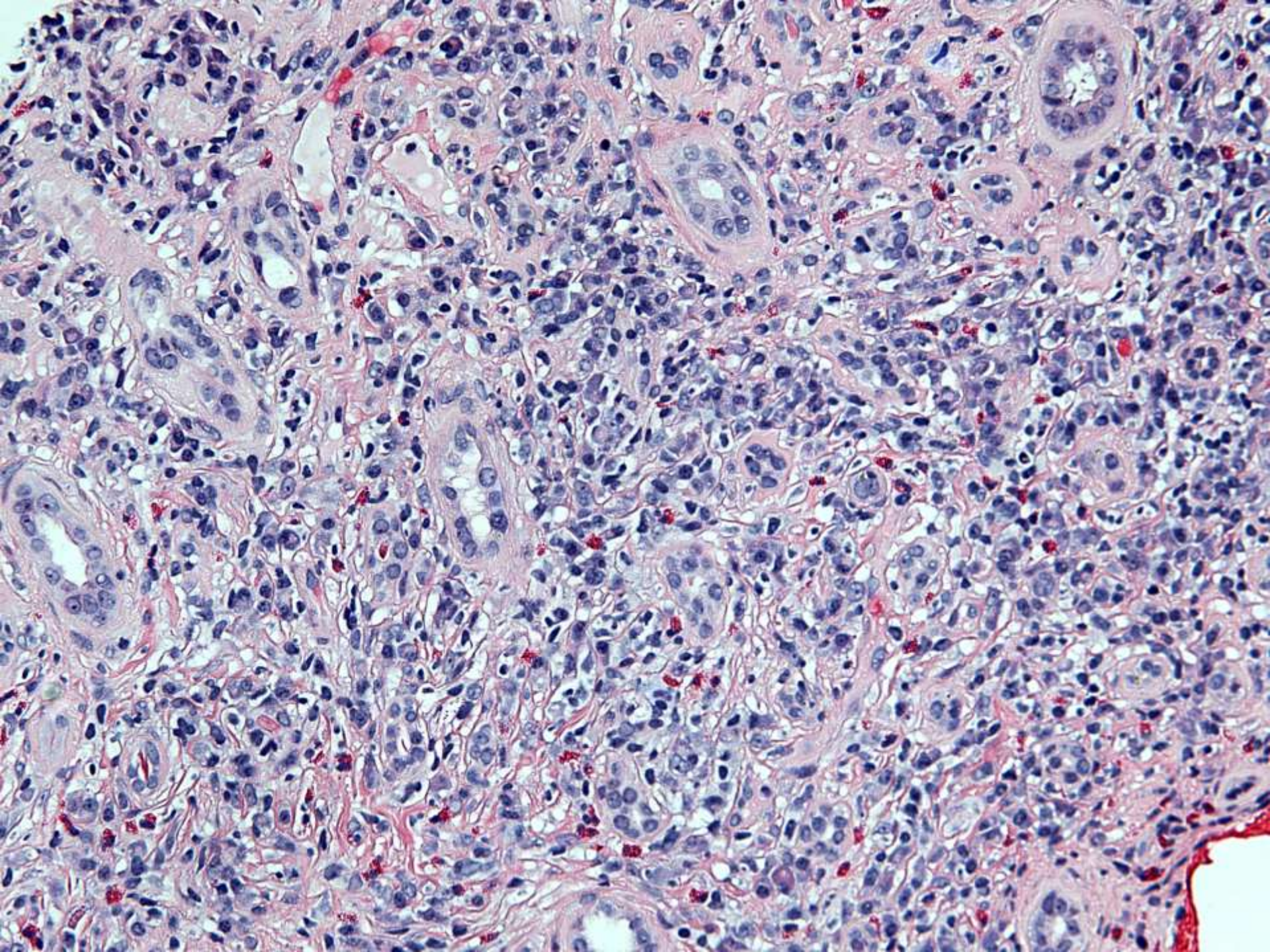
SB 6168

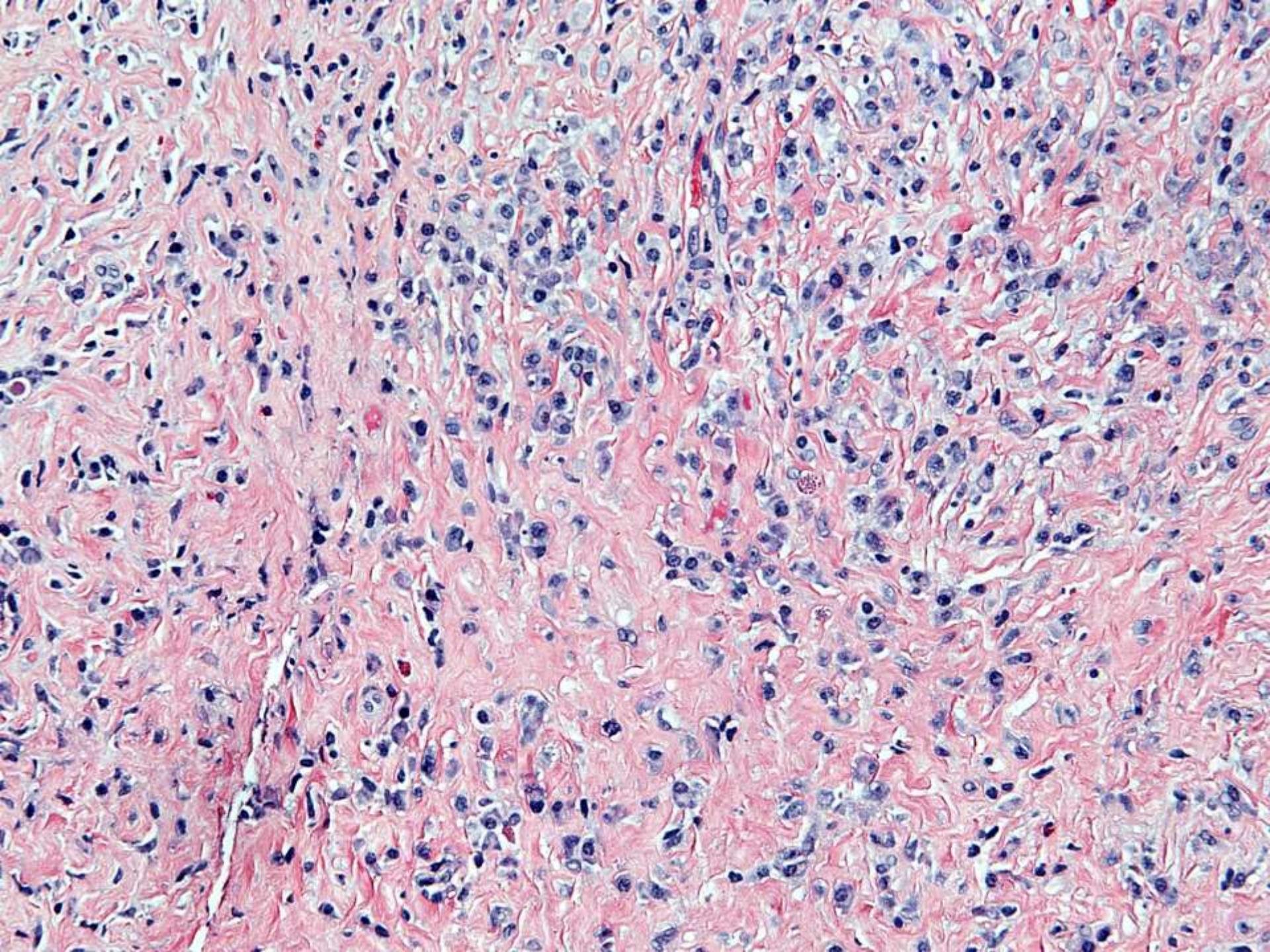
(scanned slide available)

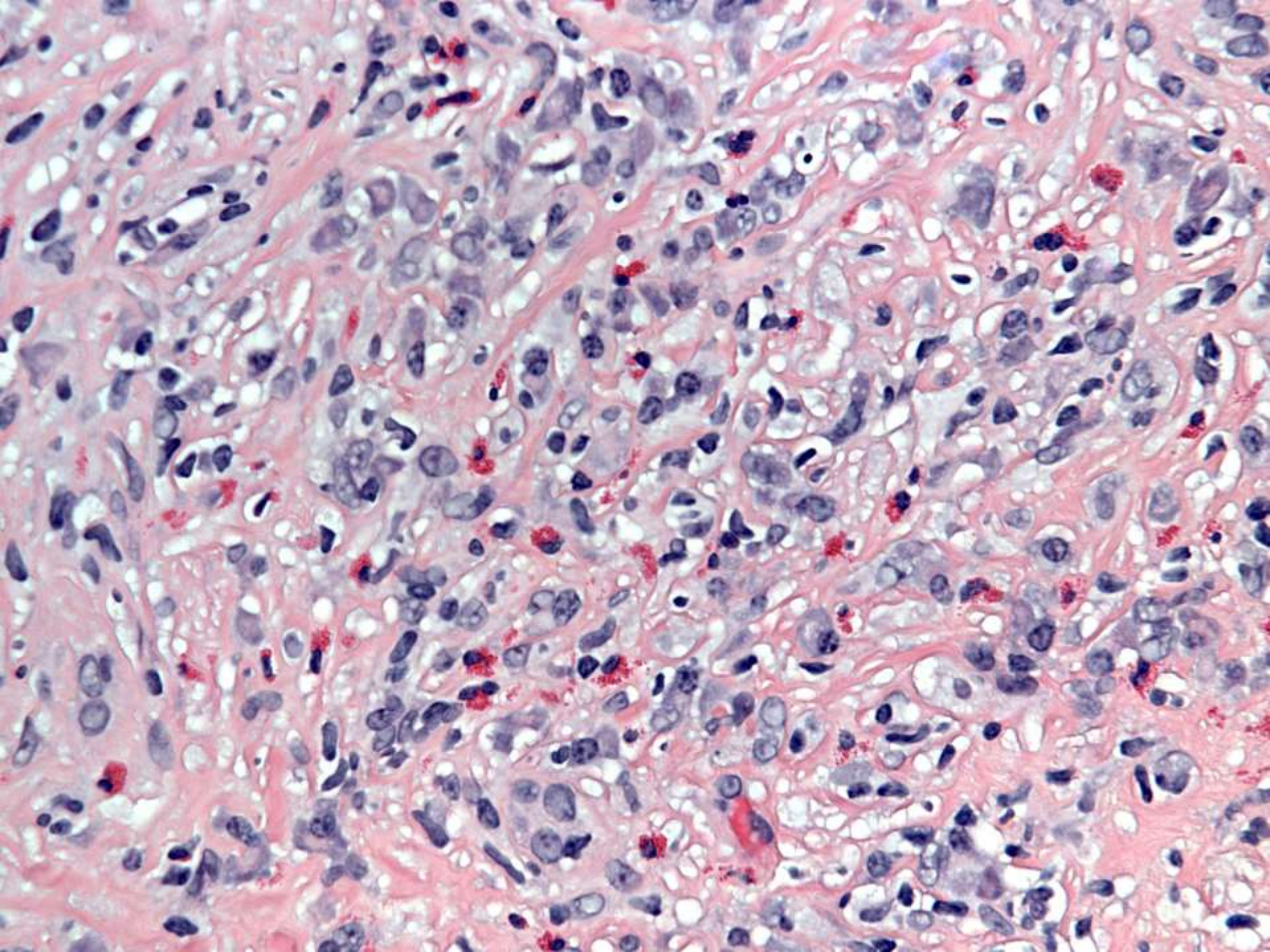
Serena Tan/Megan Troxell; Stanford

55-year-old man with diabetes,
pancreatitis, and elevated creatinine.
Needle biopsy of renal mass.





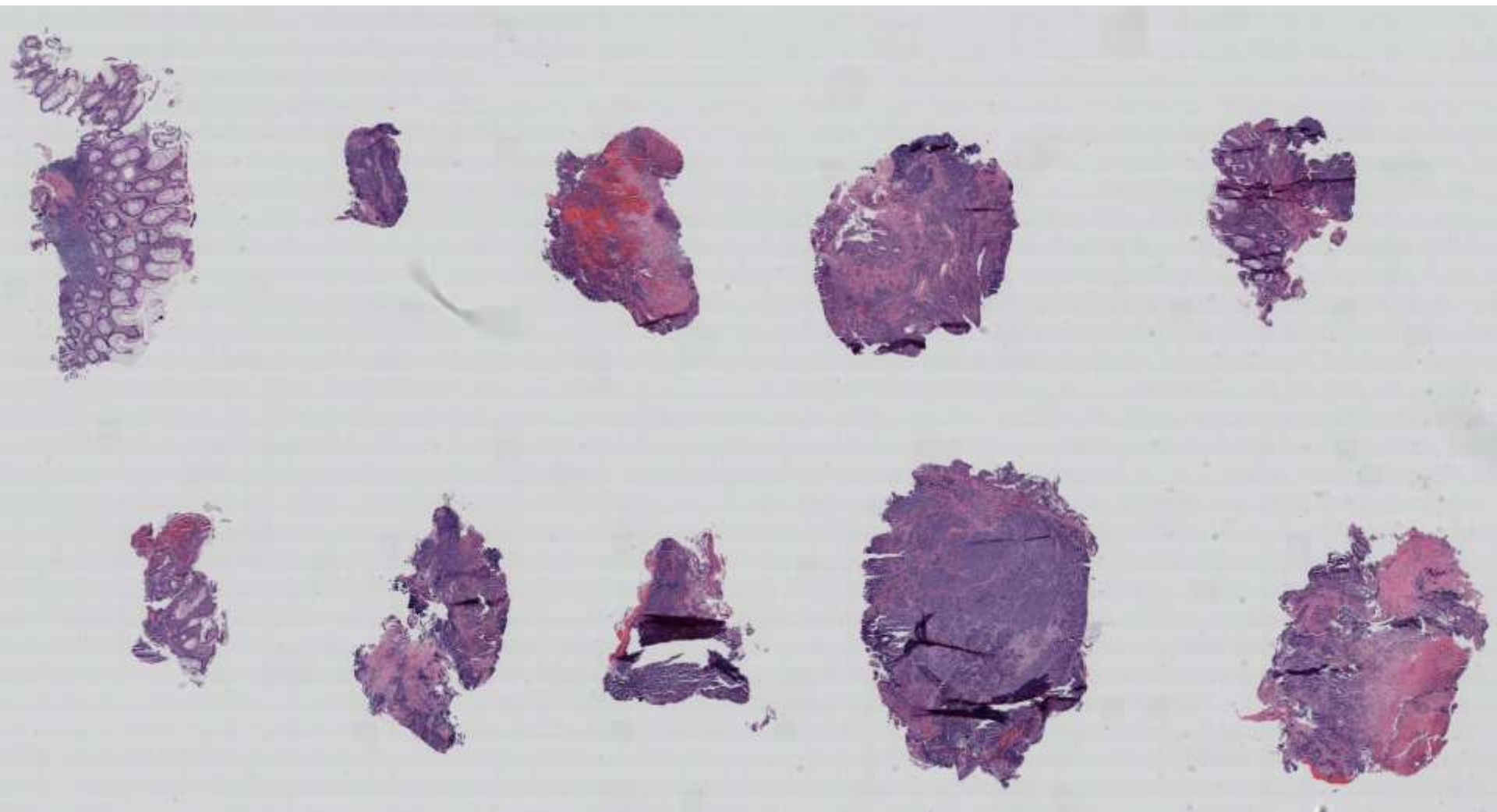


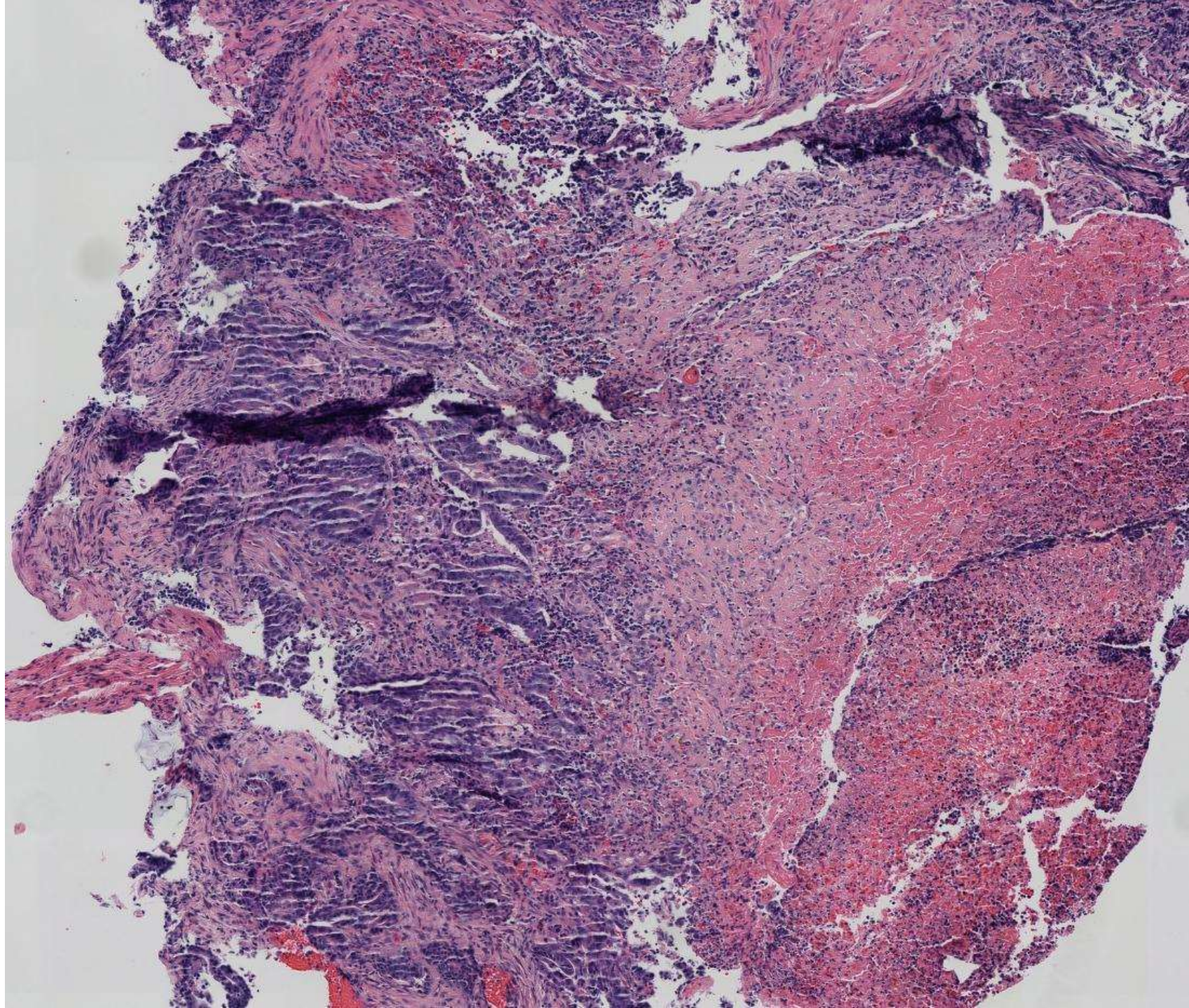


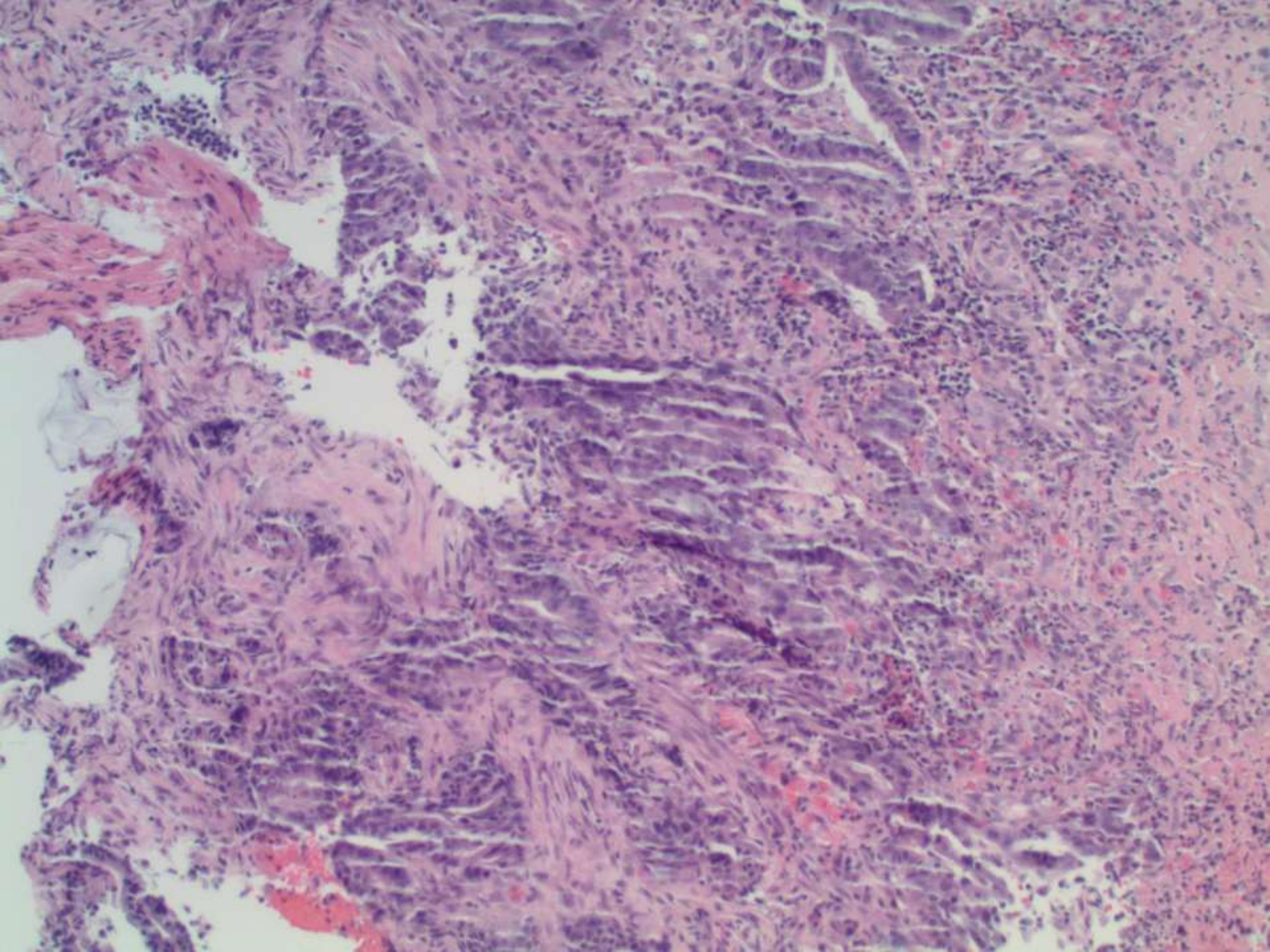
SB 6169
(scanned slide available)

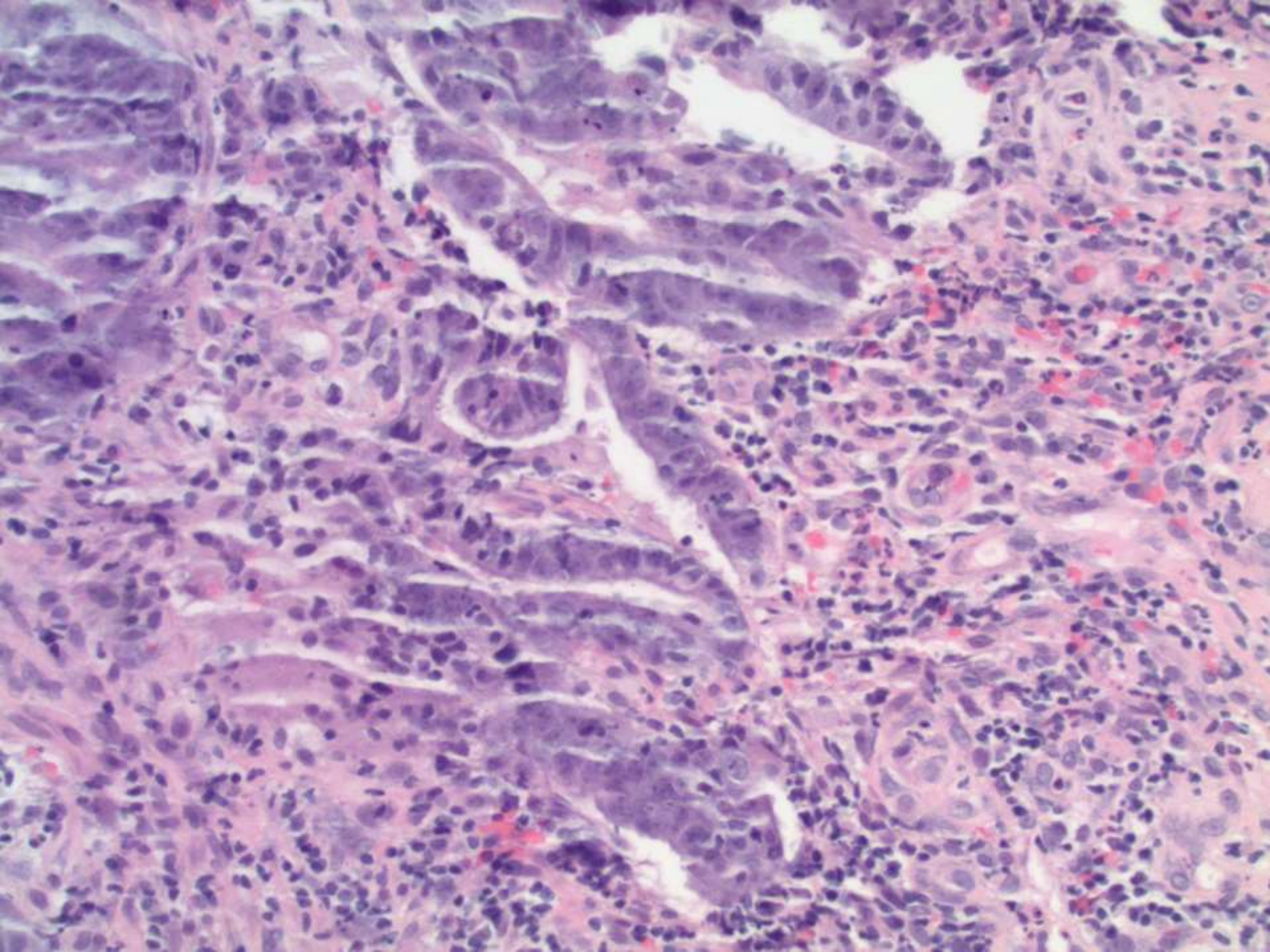
Kelly Mooney/Dean Fong; VA Palo
Alto

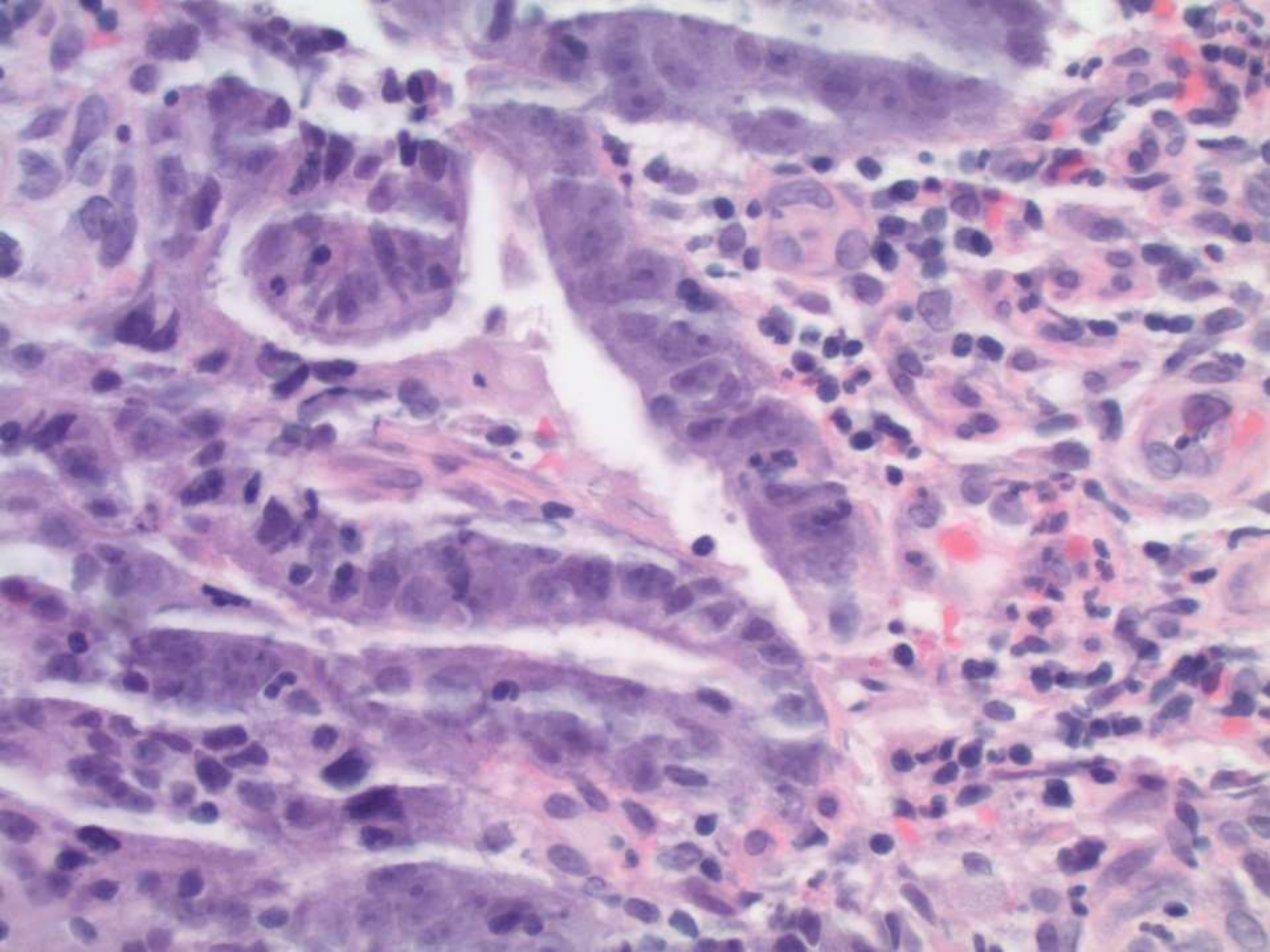
Bleeding tumor/mass in rectum.

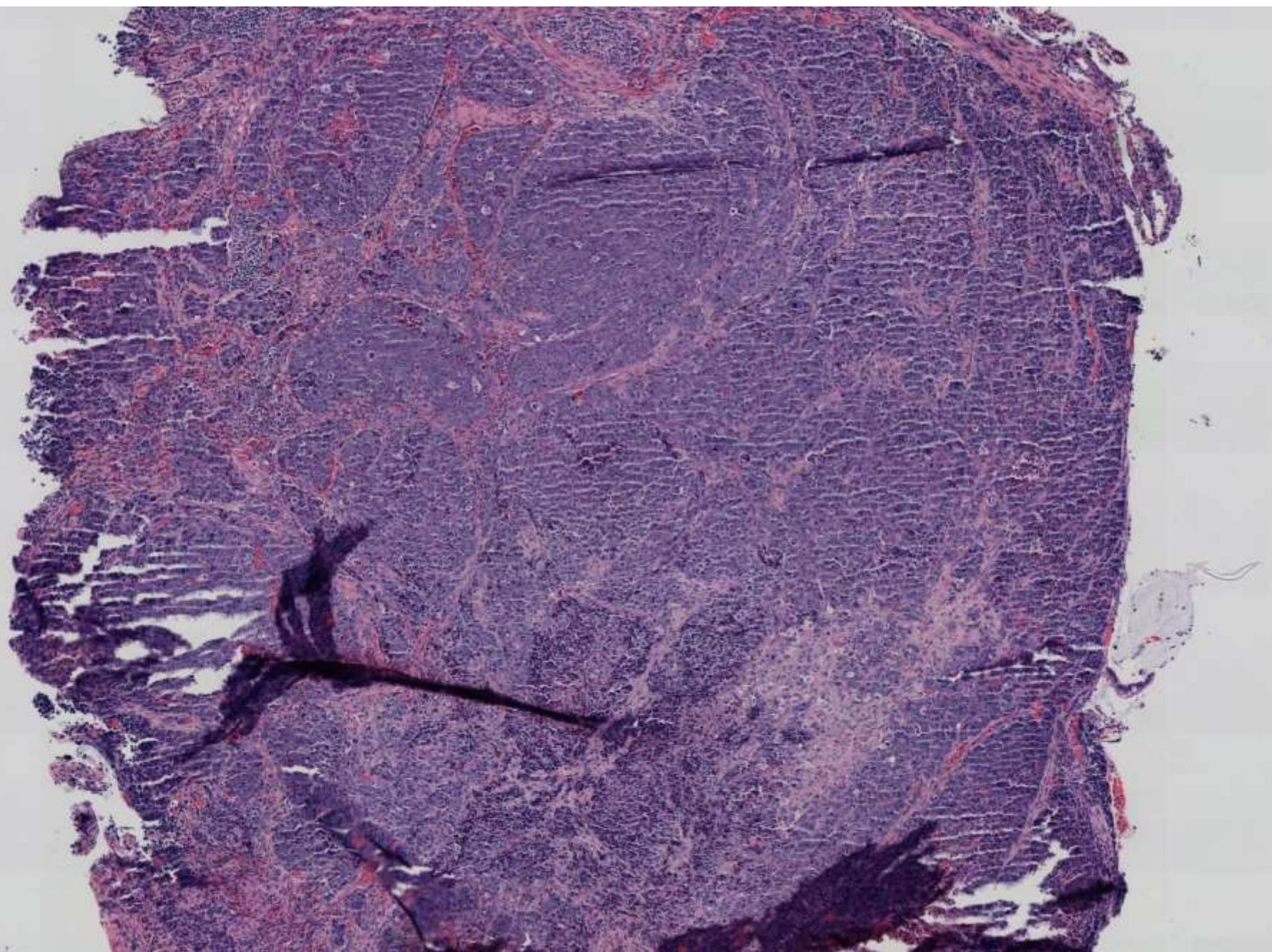


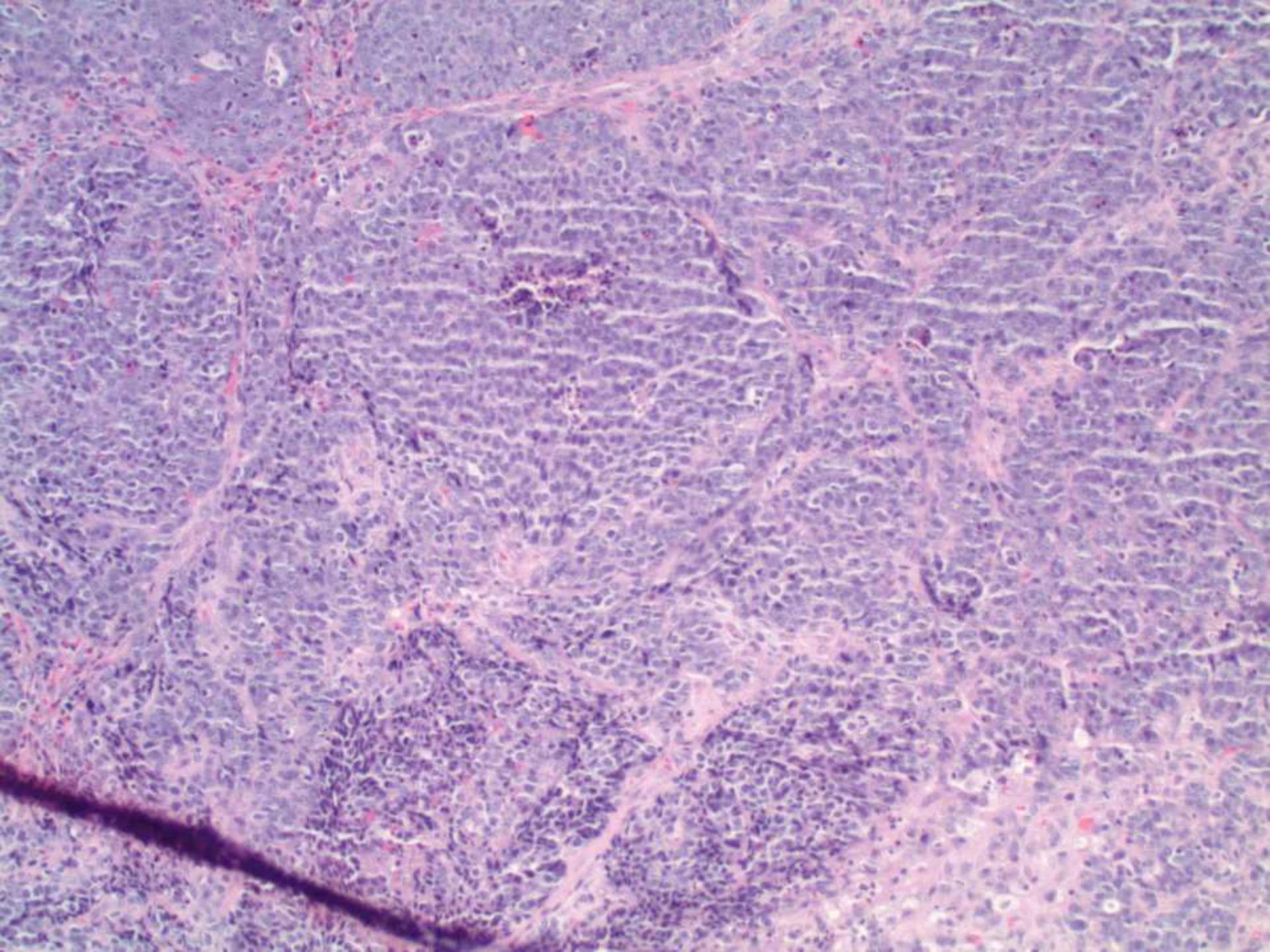


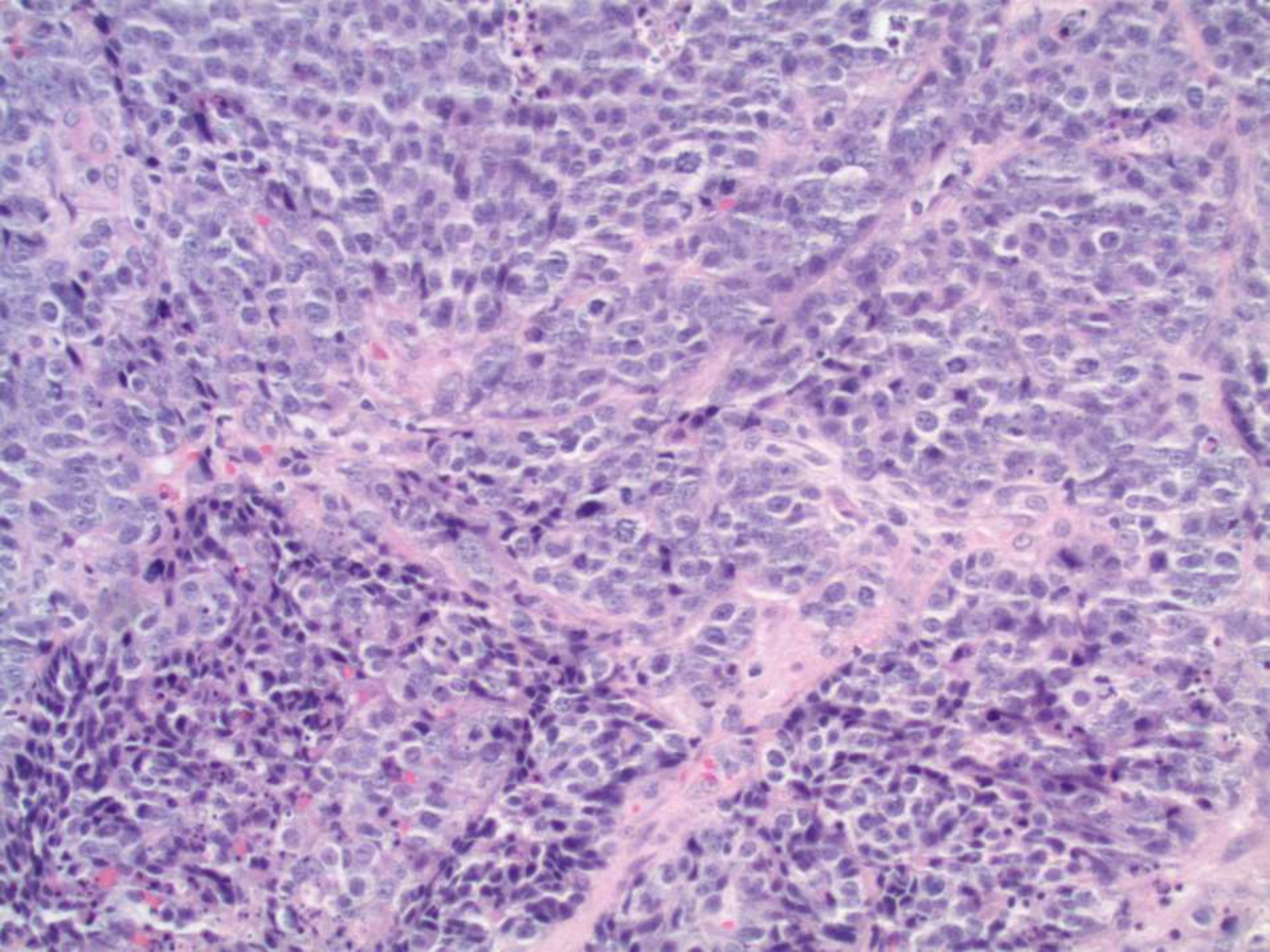


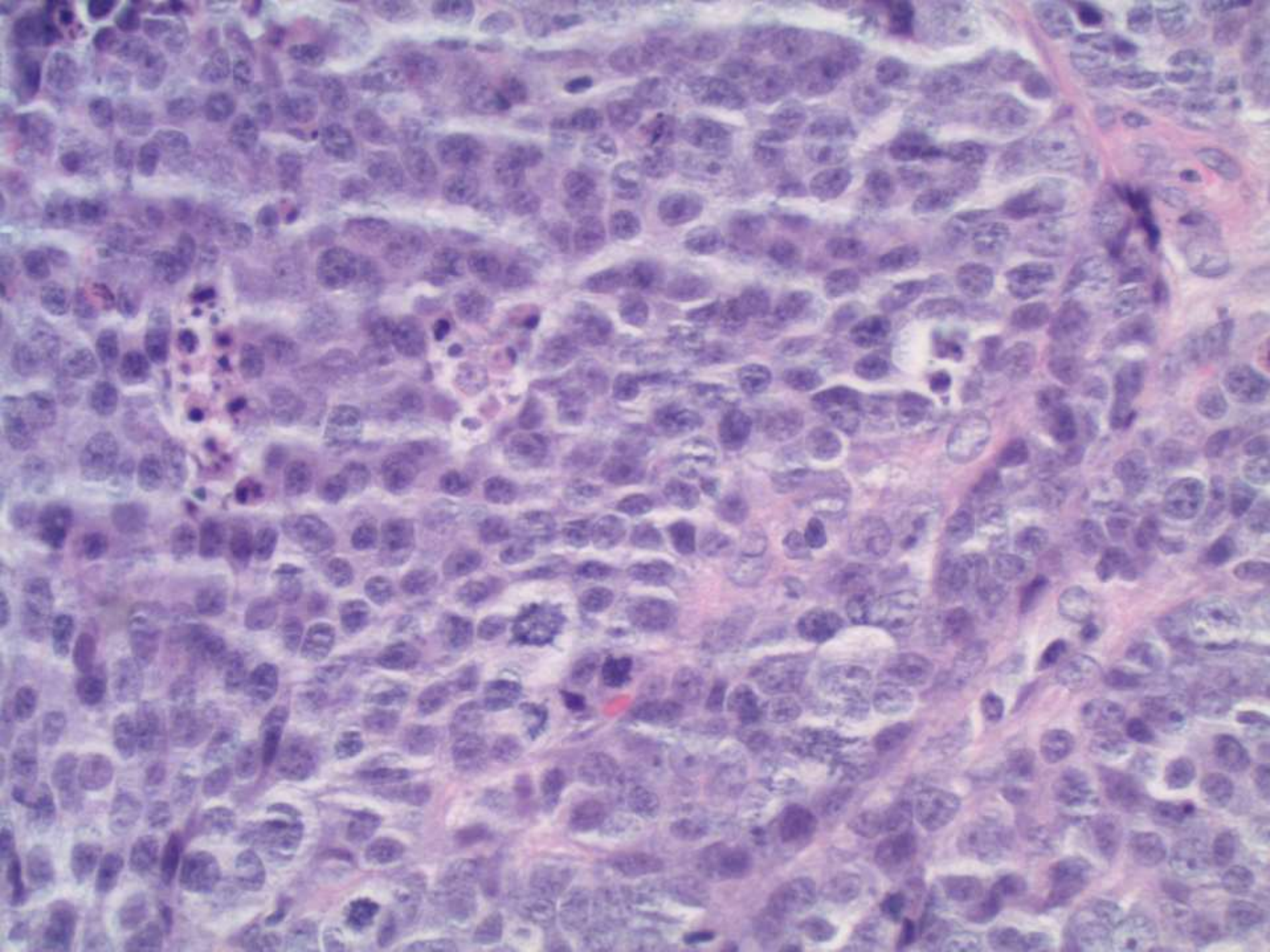












SB 6170

Alana Shain/Christine Louie; VA Palo Alto

61-year-old man with mediastinal mass.

Endoscopic ultrasound-guided FNA
performed.

