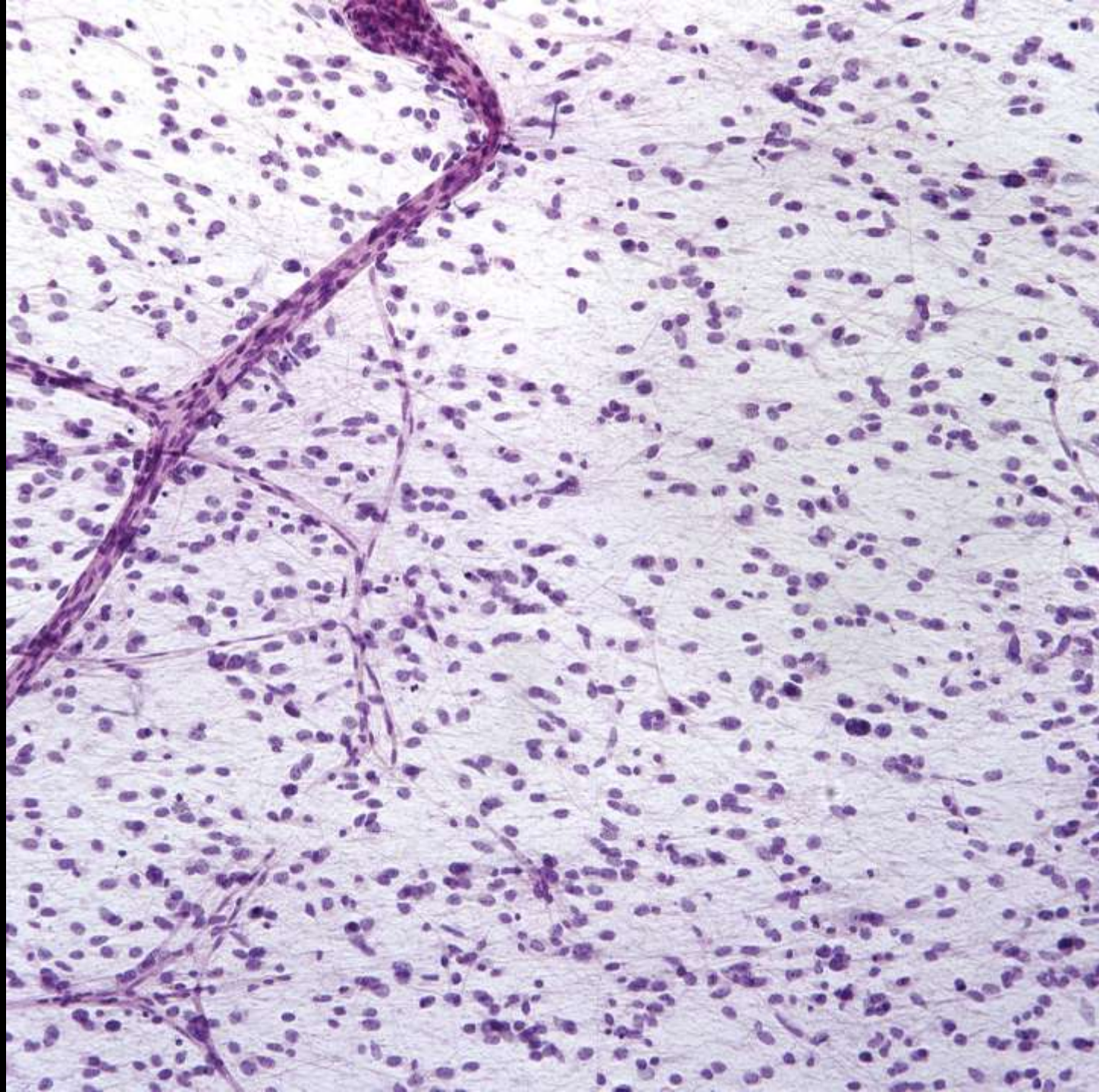
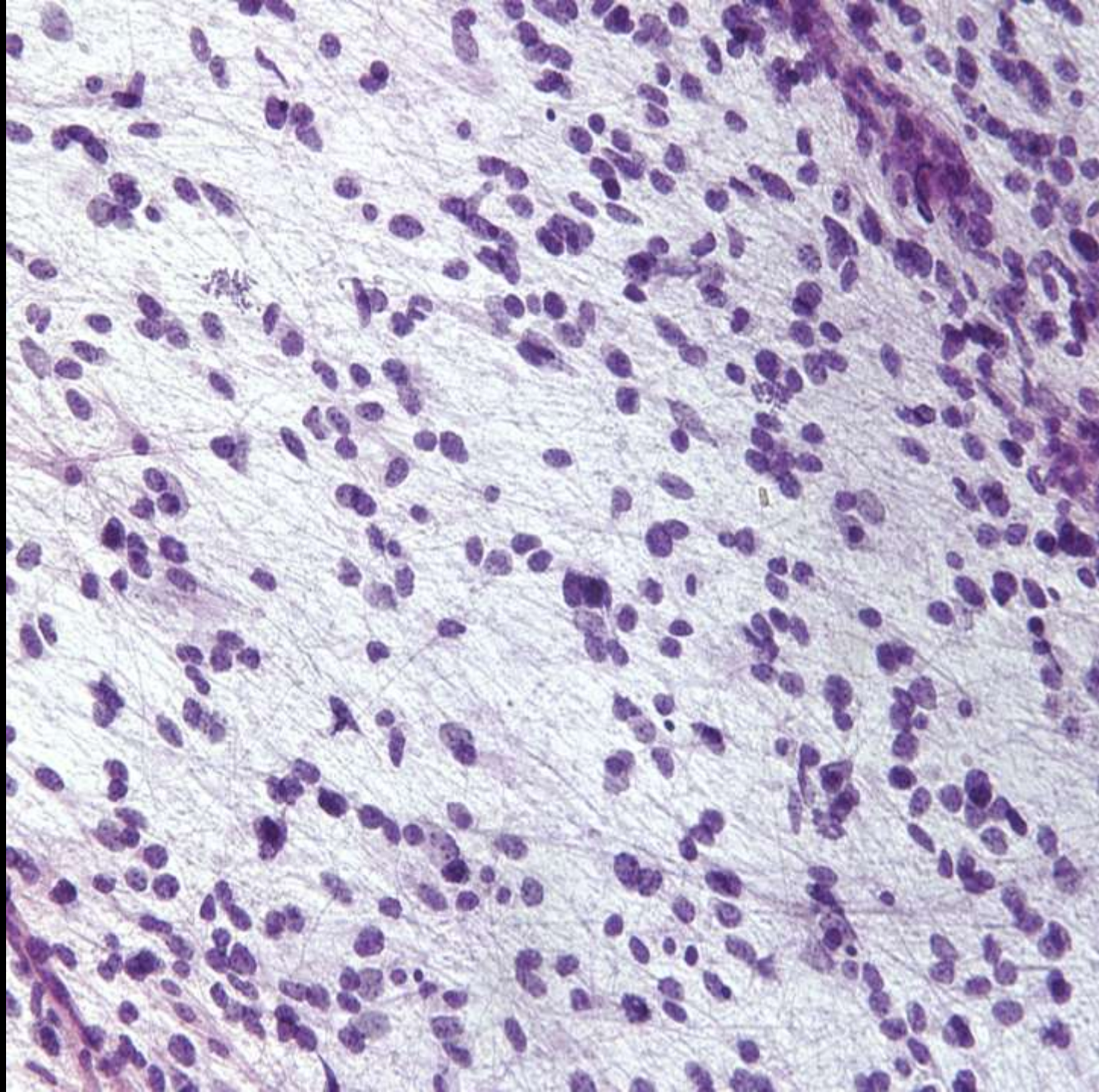


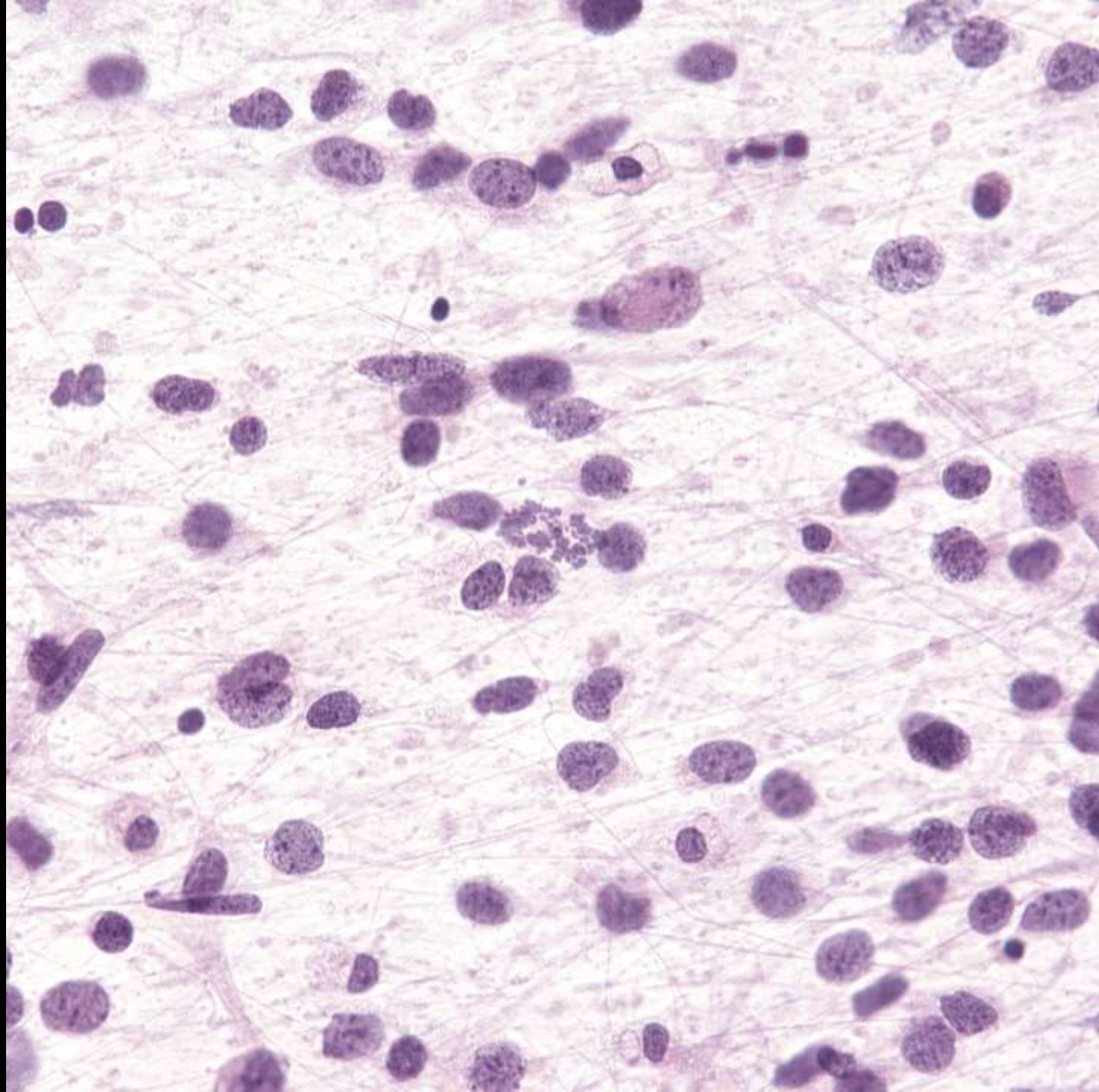
SB 6121

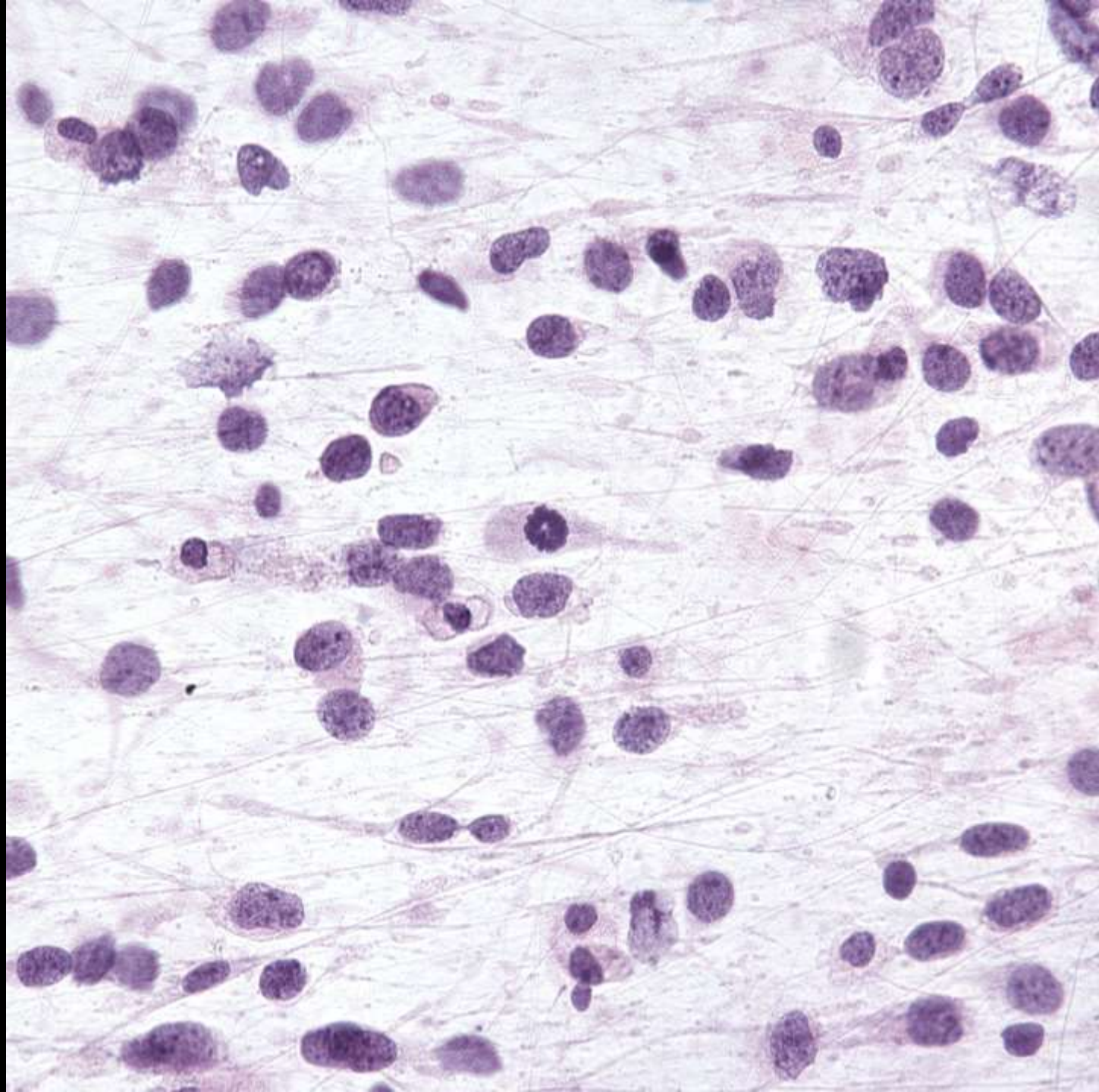
Peyman Samghabadi/Hannes Vogel; Stanford

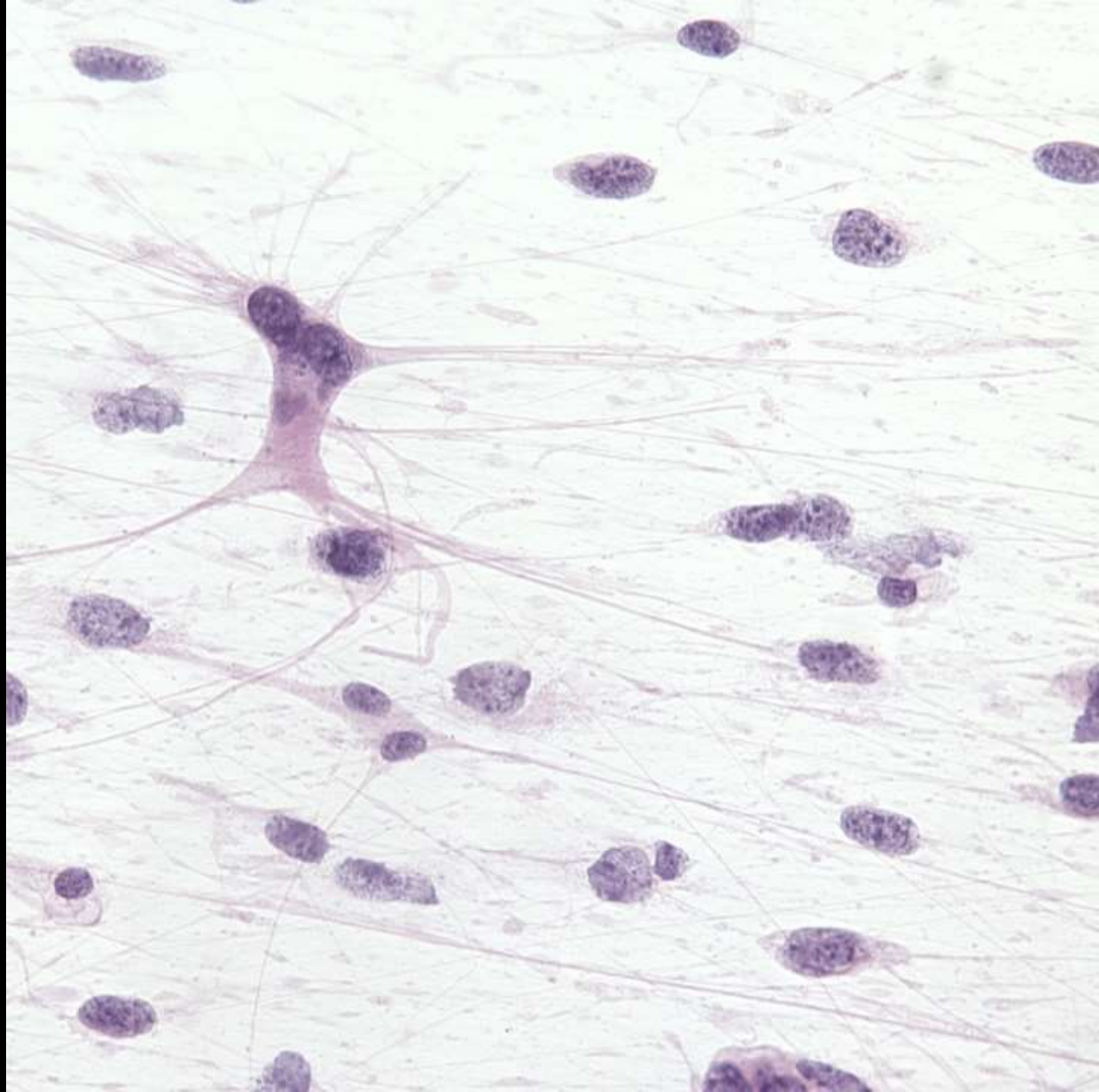Previously-healthy 6-year old female who presents with a several week history of head tilt and more recently history of balance difficulties, including a collision with a schoolmate with resultant loss of consciousness. She was taken to the ED where a head CT revealed a 3x4cm hypoechoic lesion in the left posterior fossa with mass effect on the pons. DDx includes primary cystic abnormalities such as arachnoid cyst and neoplastic lesions.

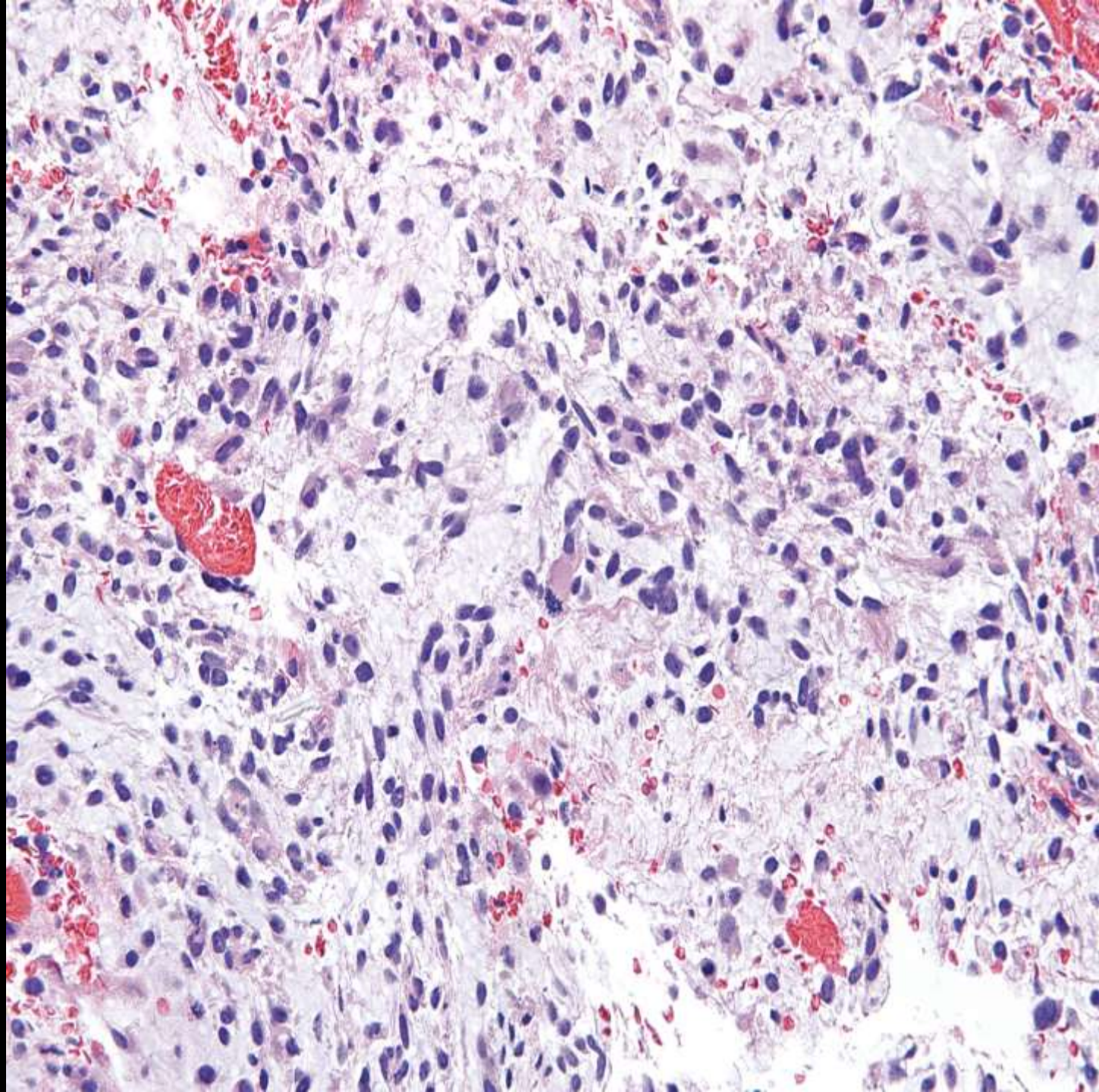


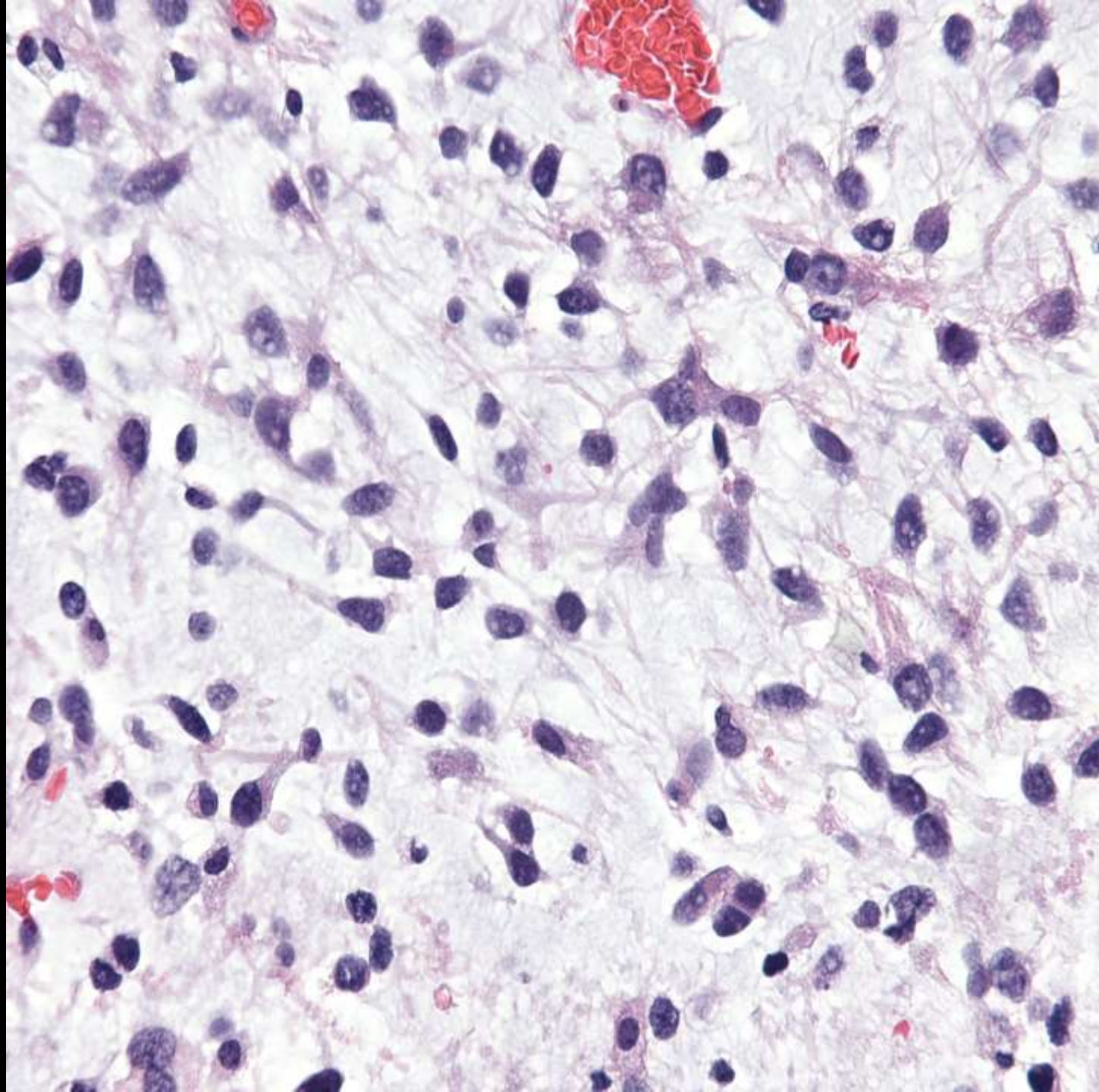


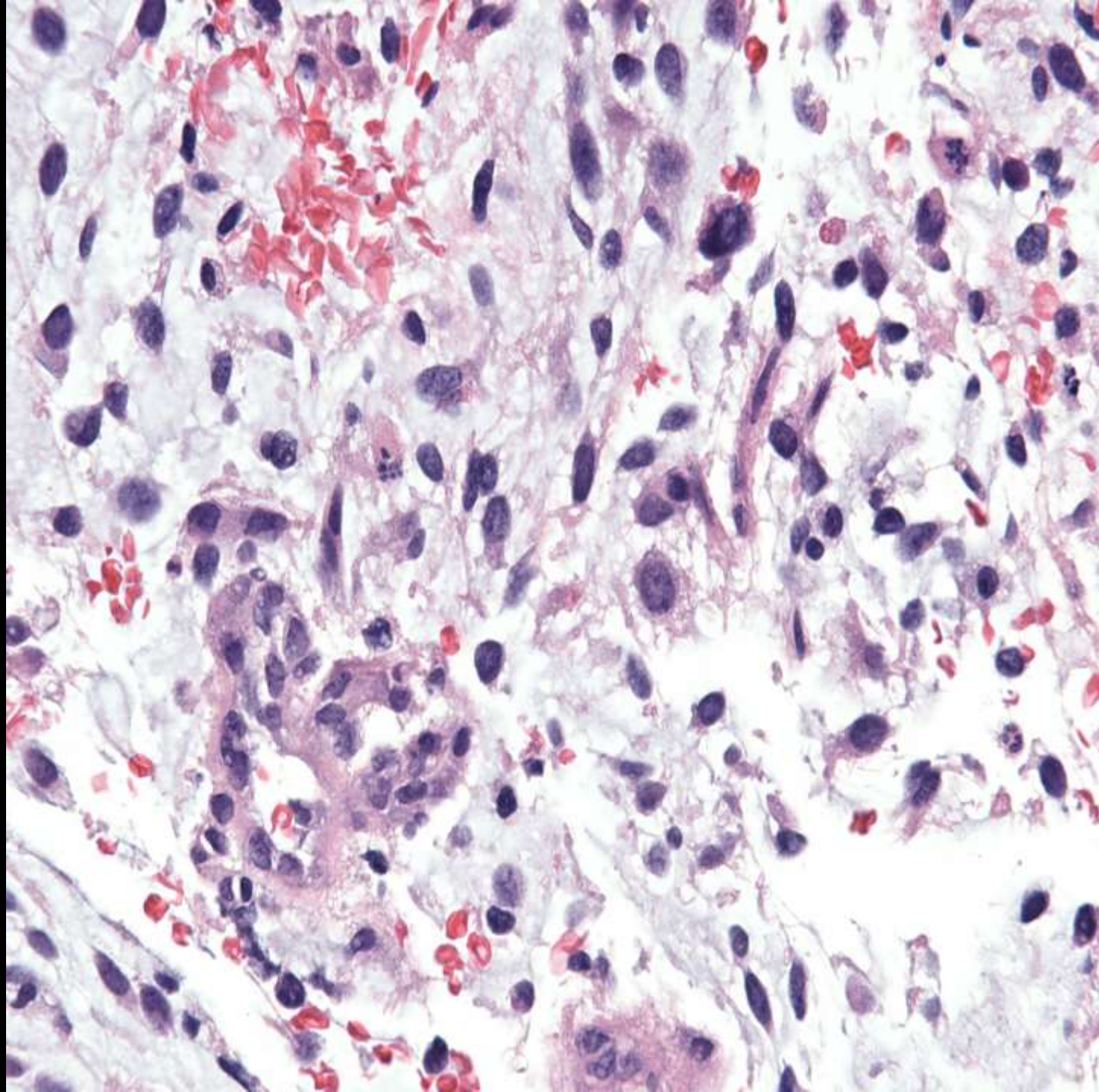










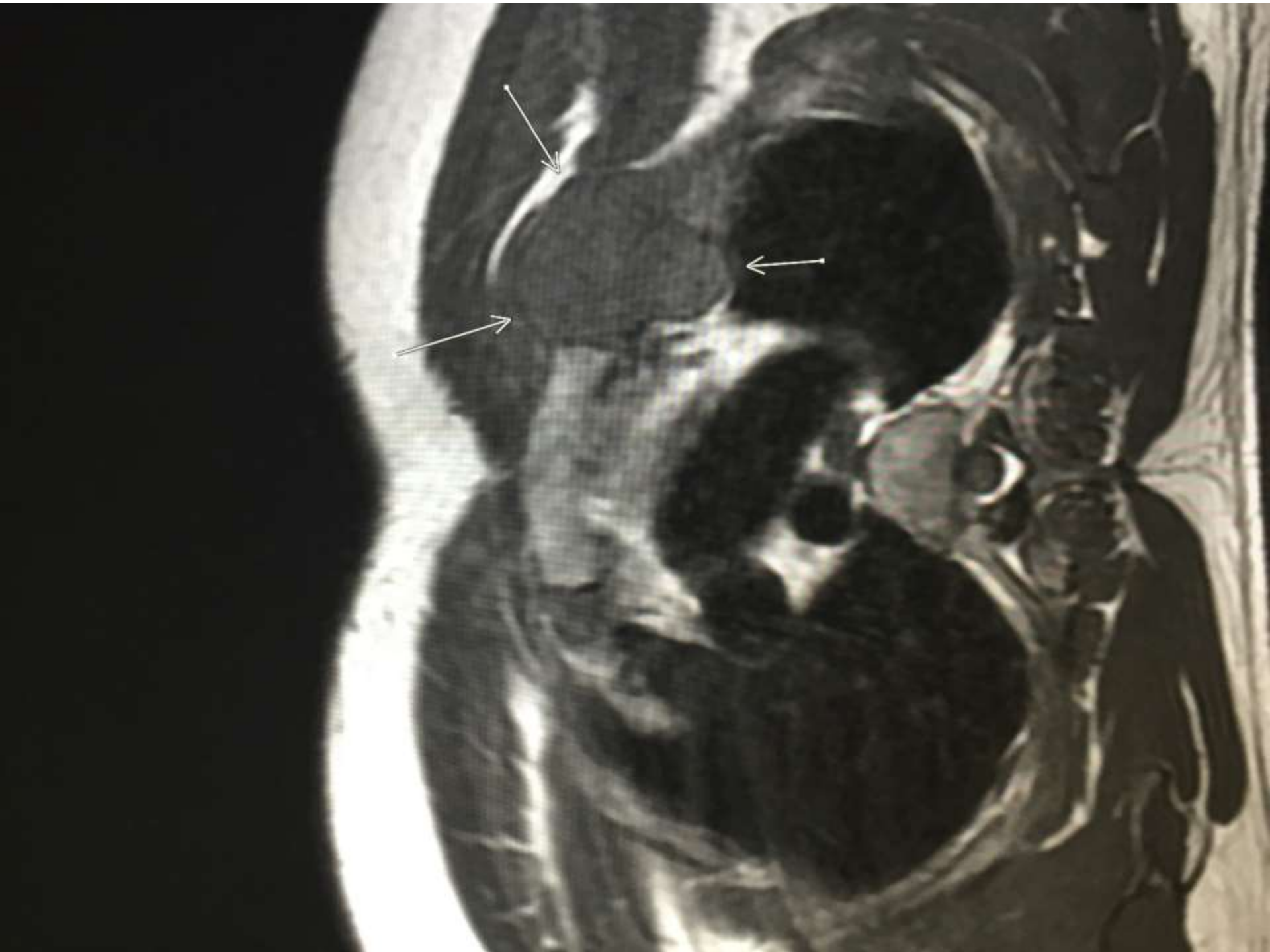


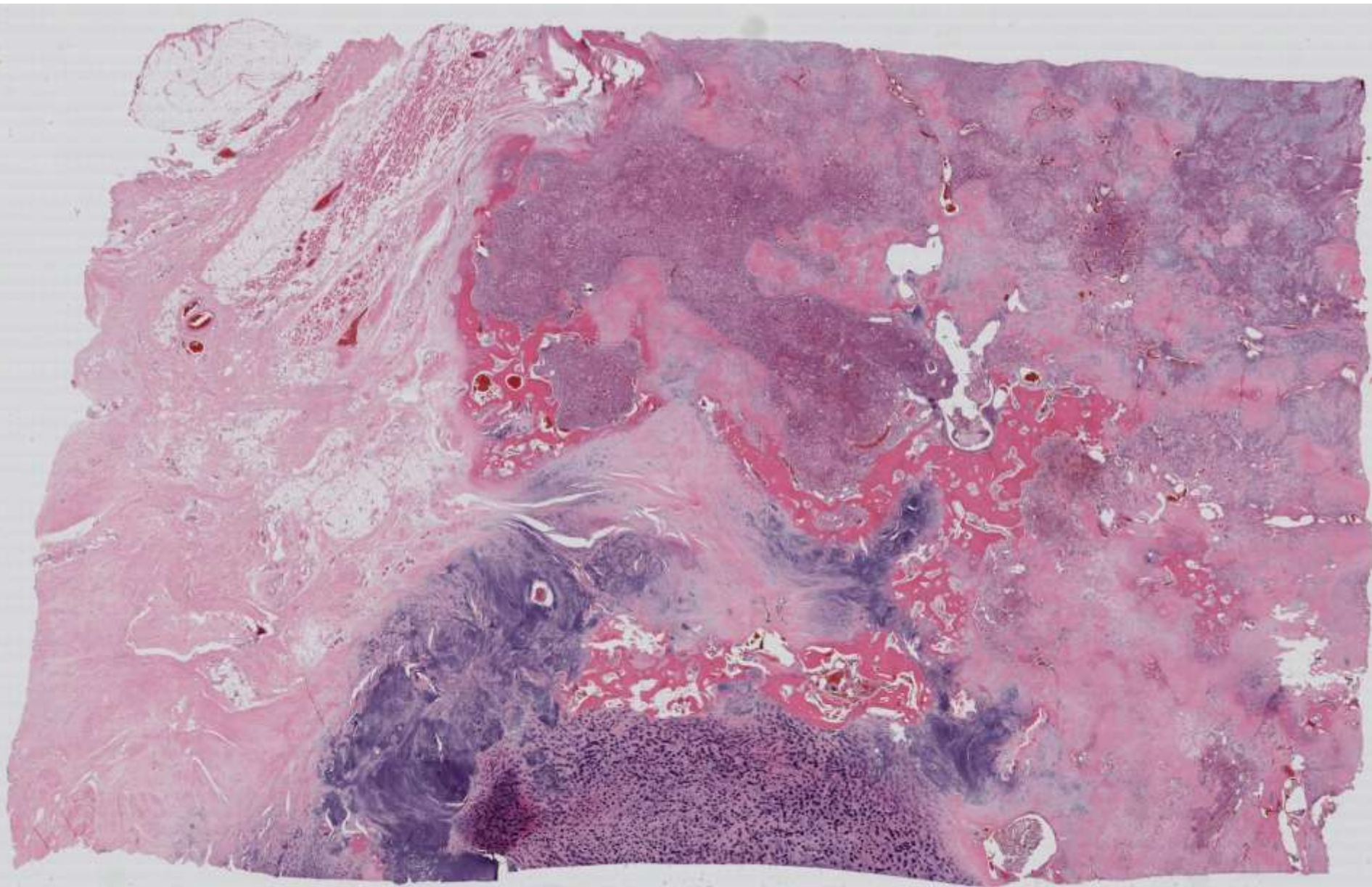
SB 6122

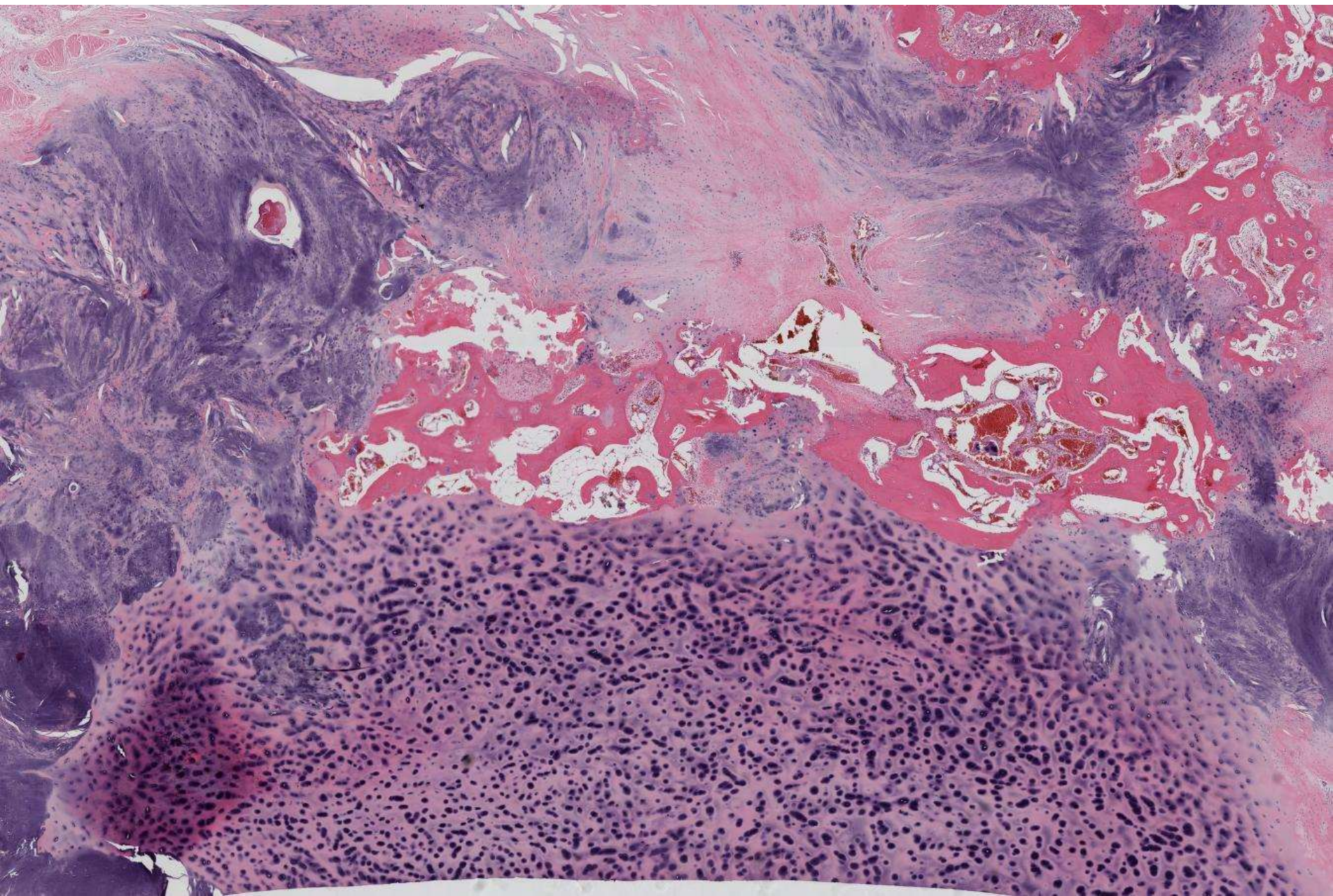
(scanned slide available)

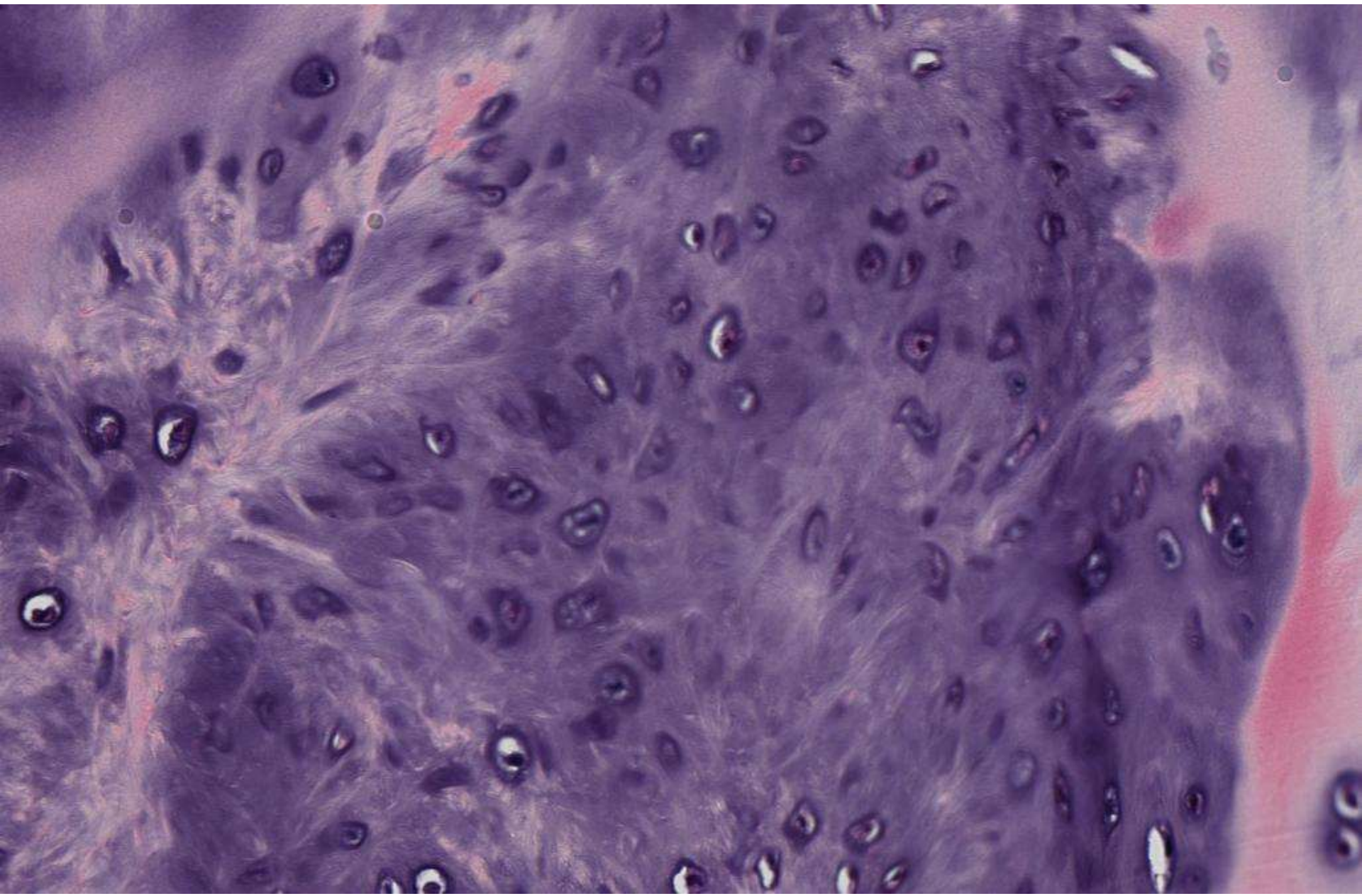
John Moretto; CPMC

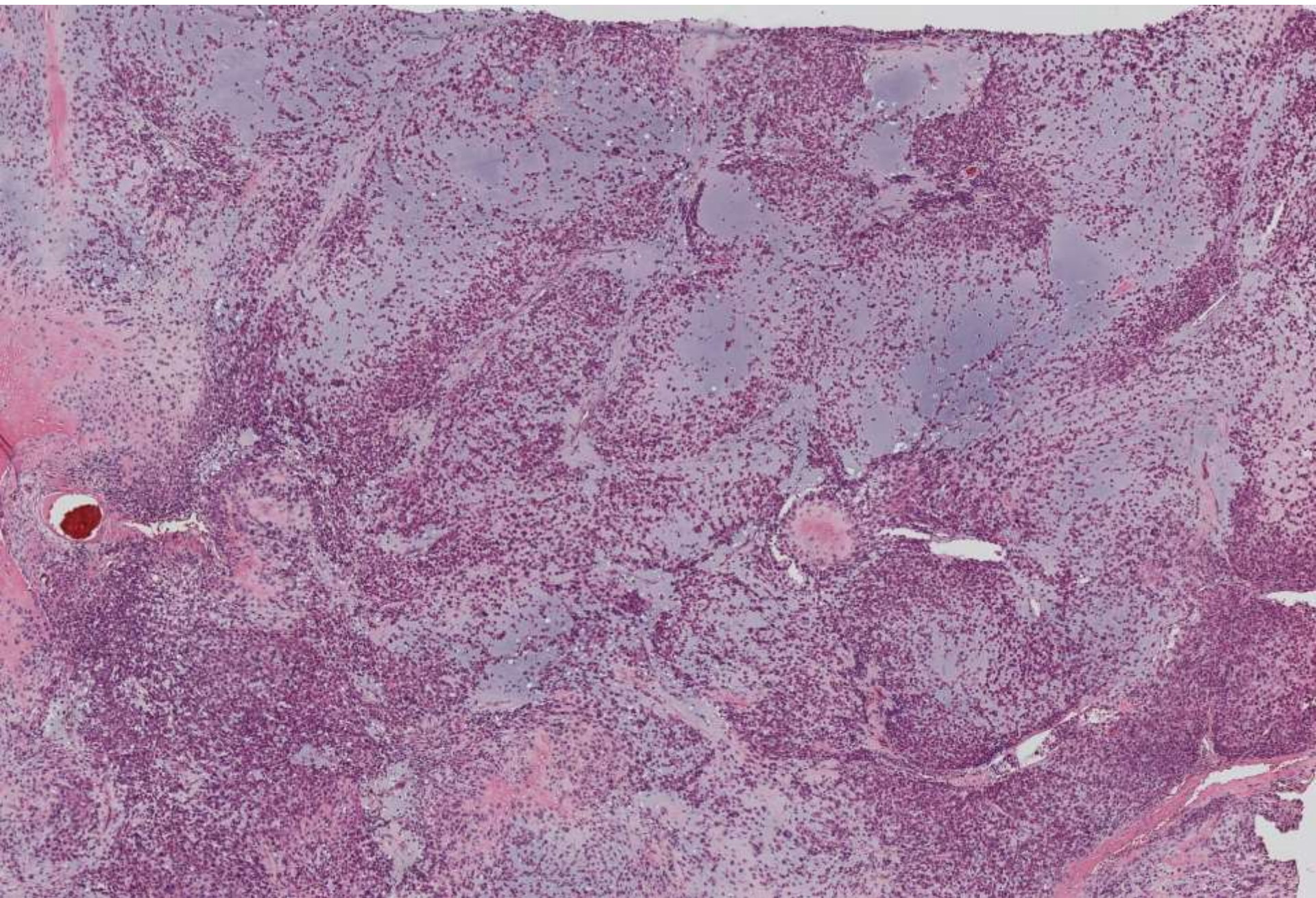
38-year-old man with 6.2x4.7x4.6cm
chest wall tumor apparently arising
from first left rib.

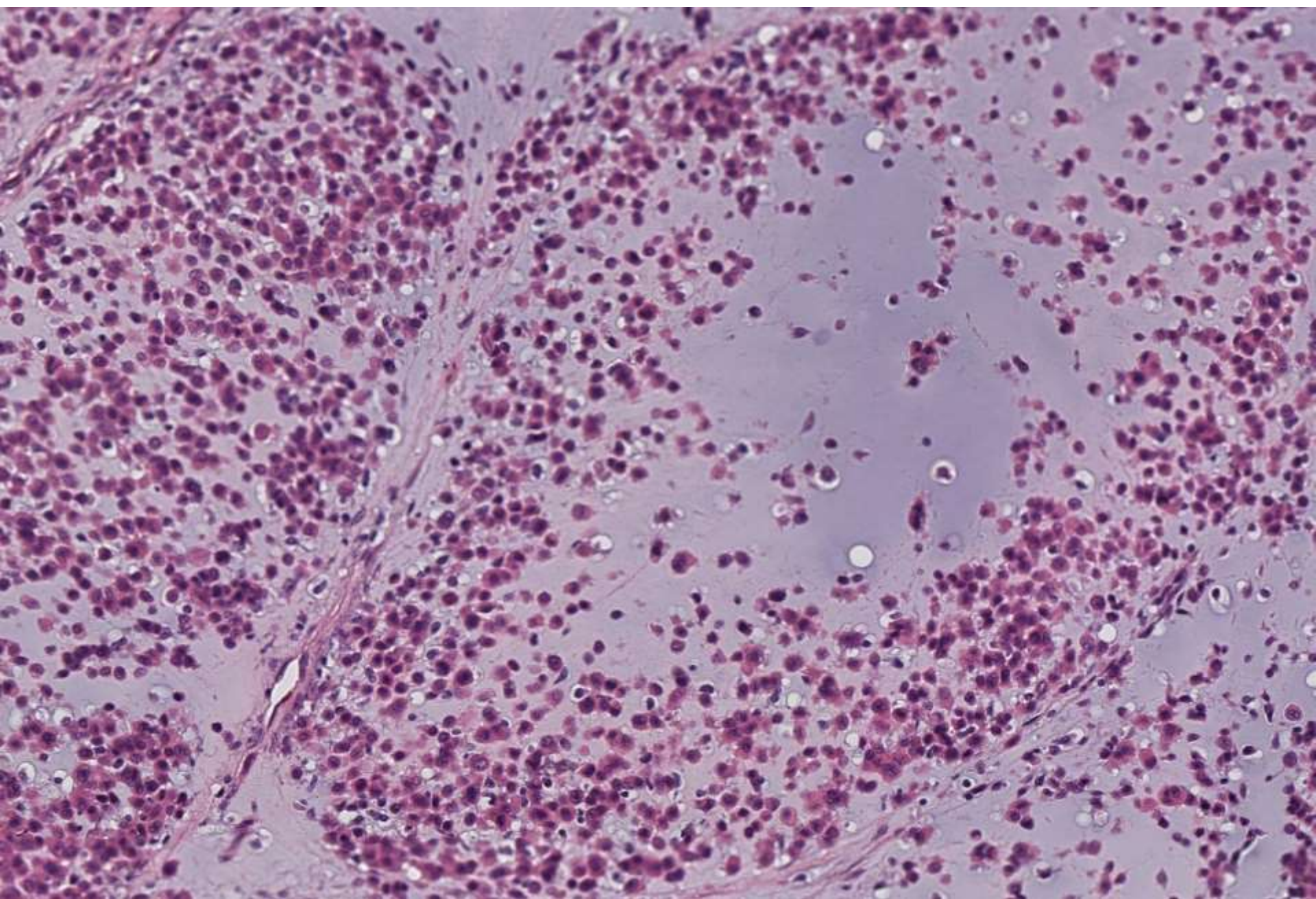


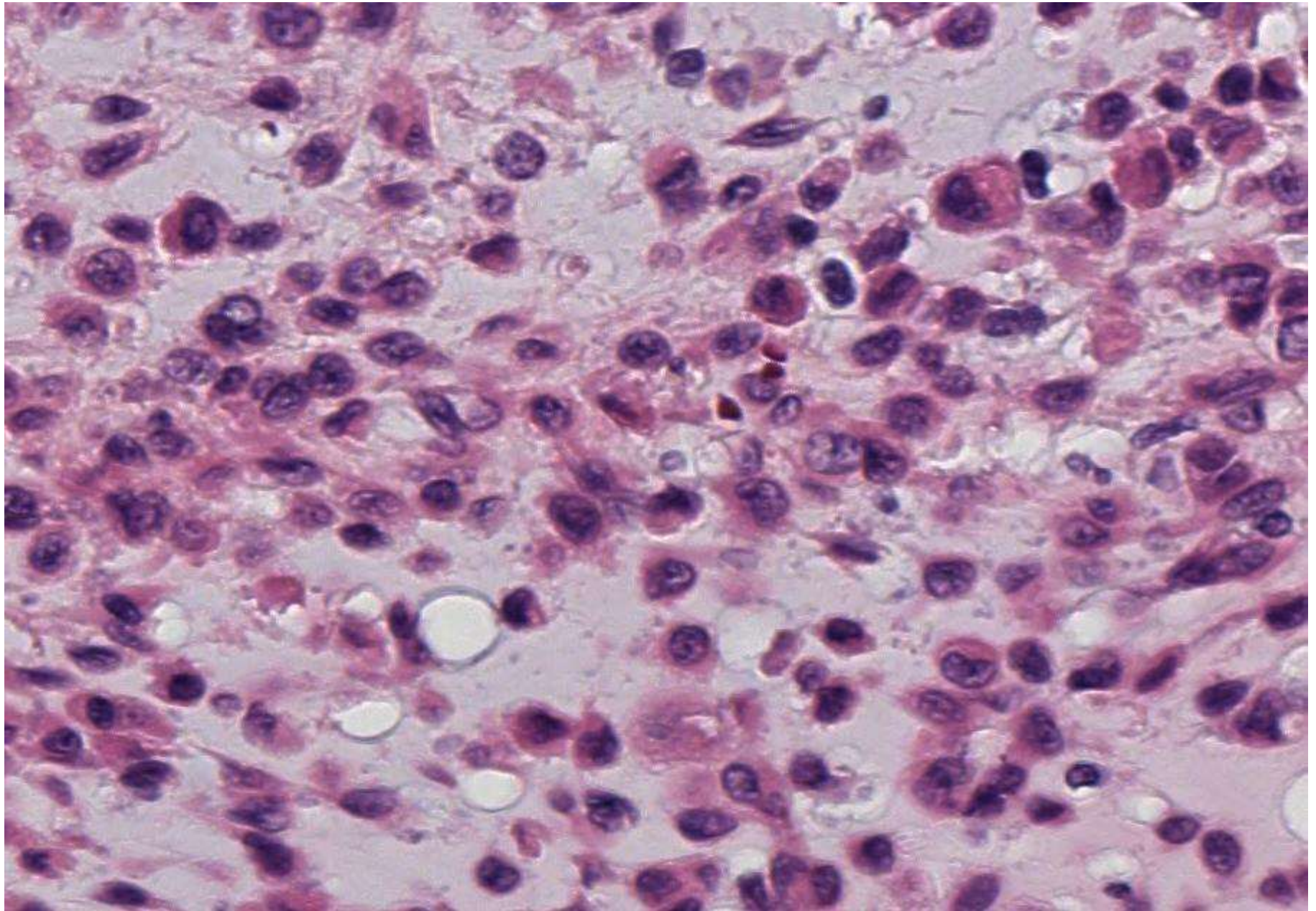


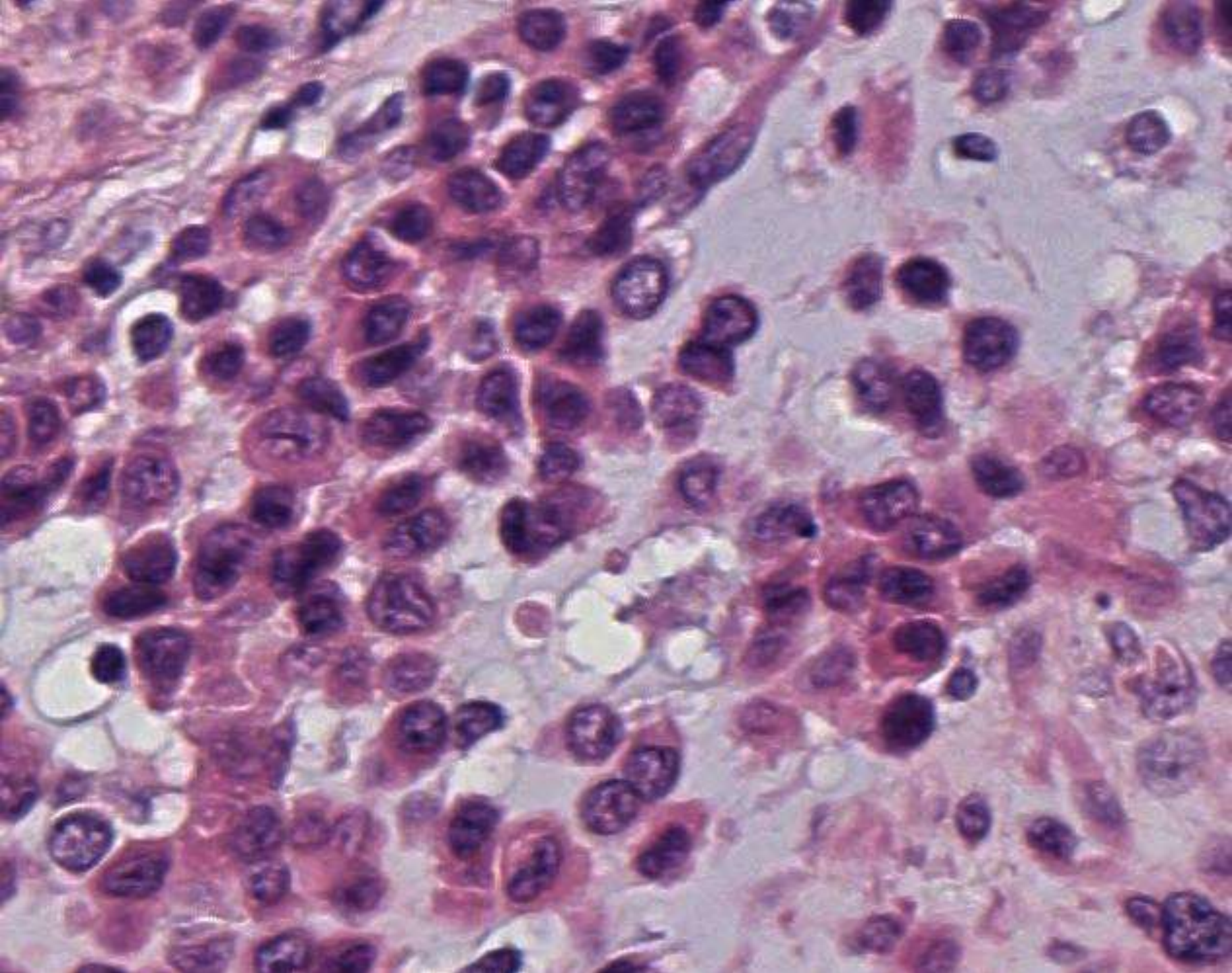


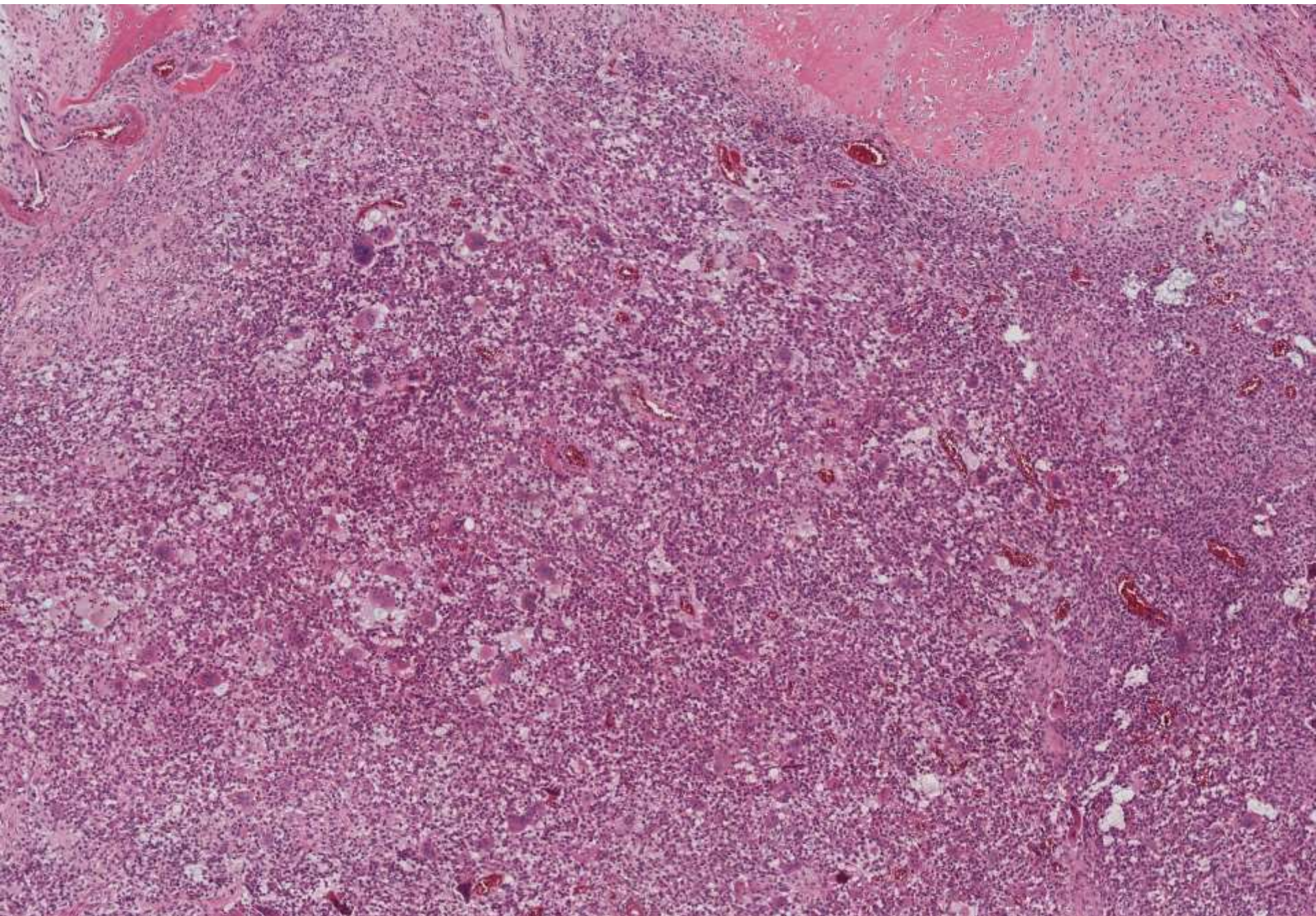


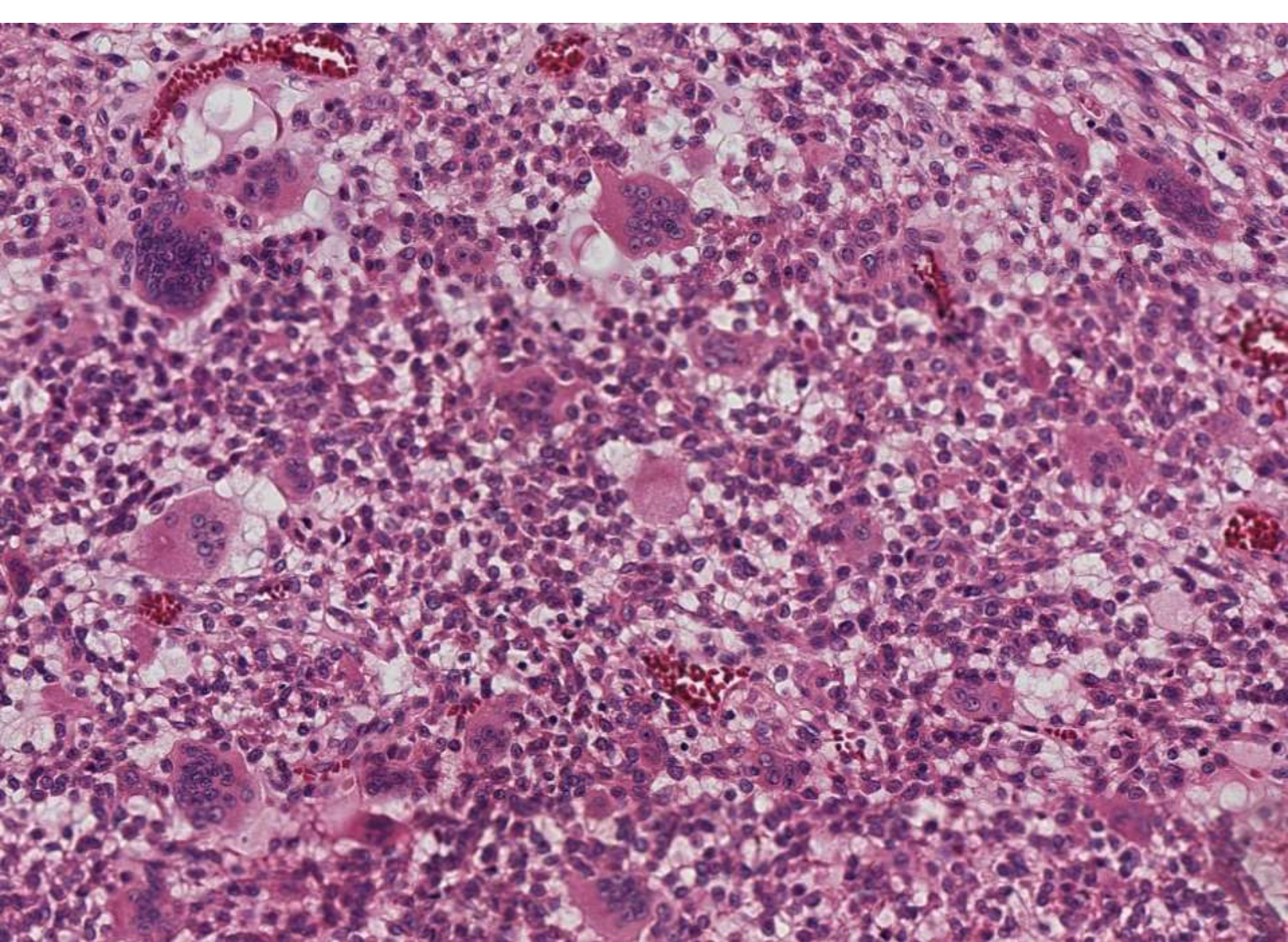


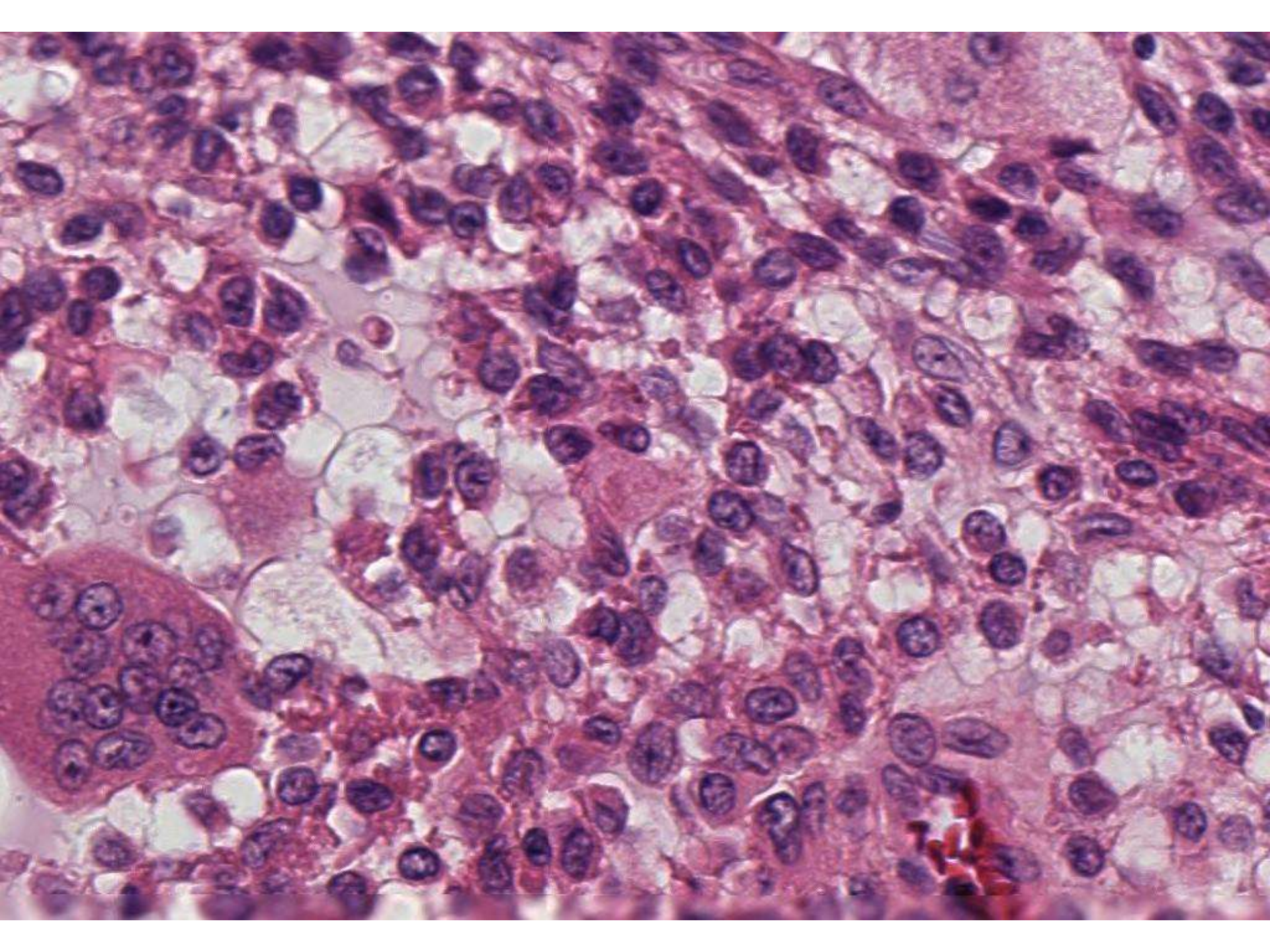








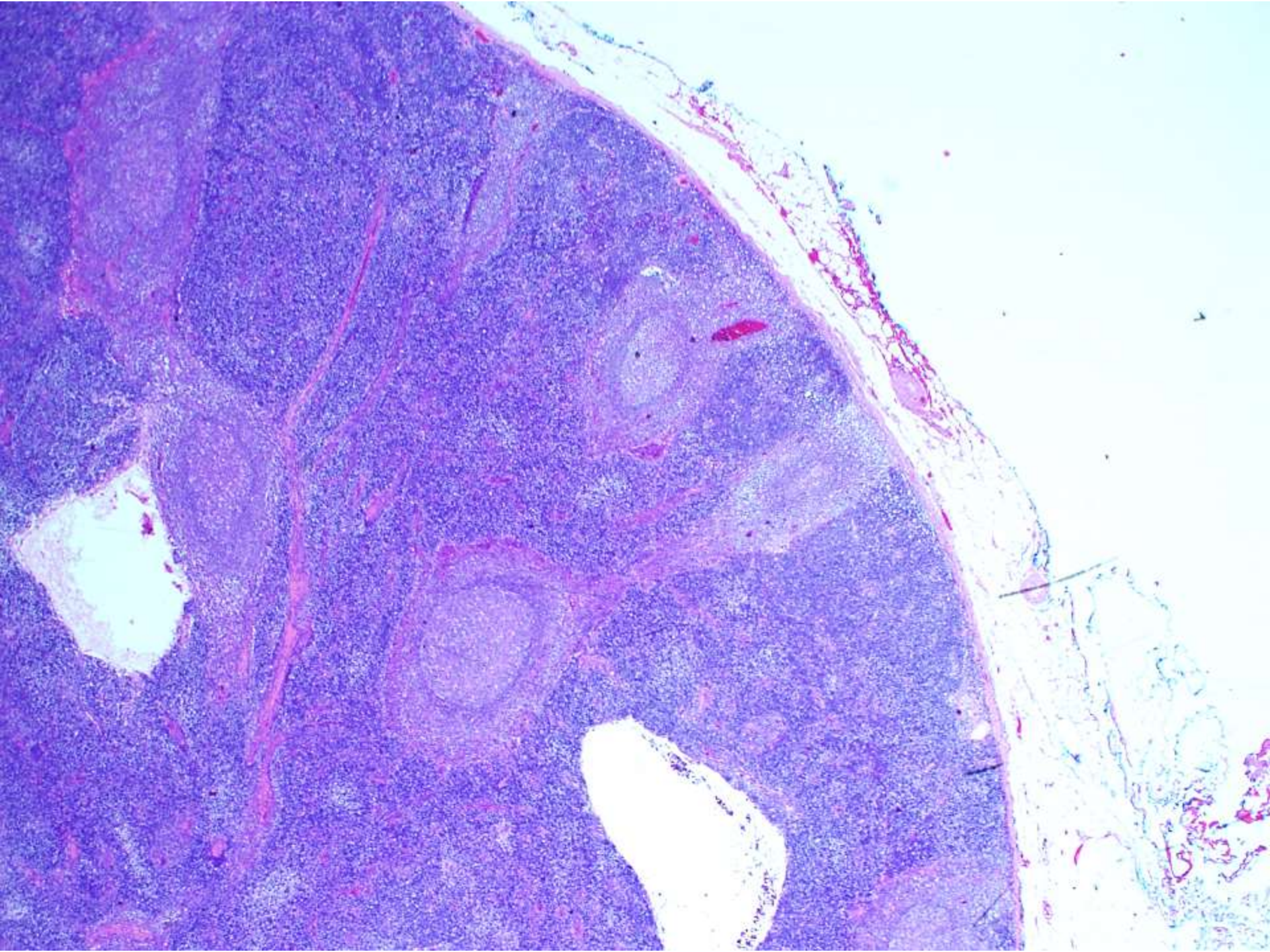


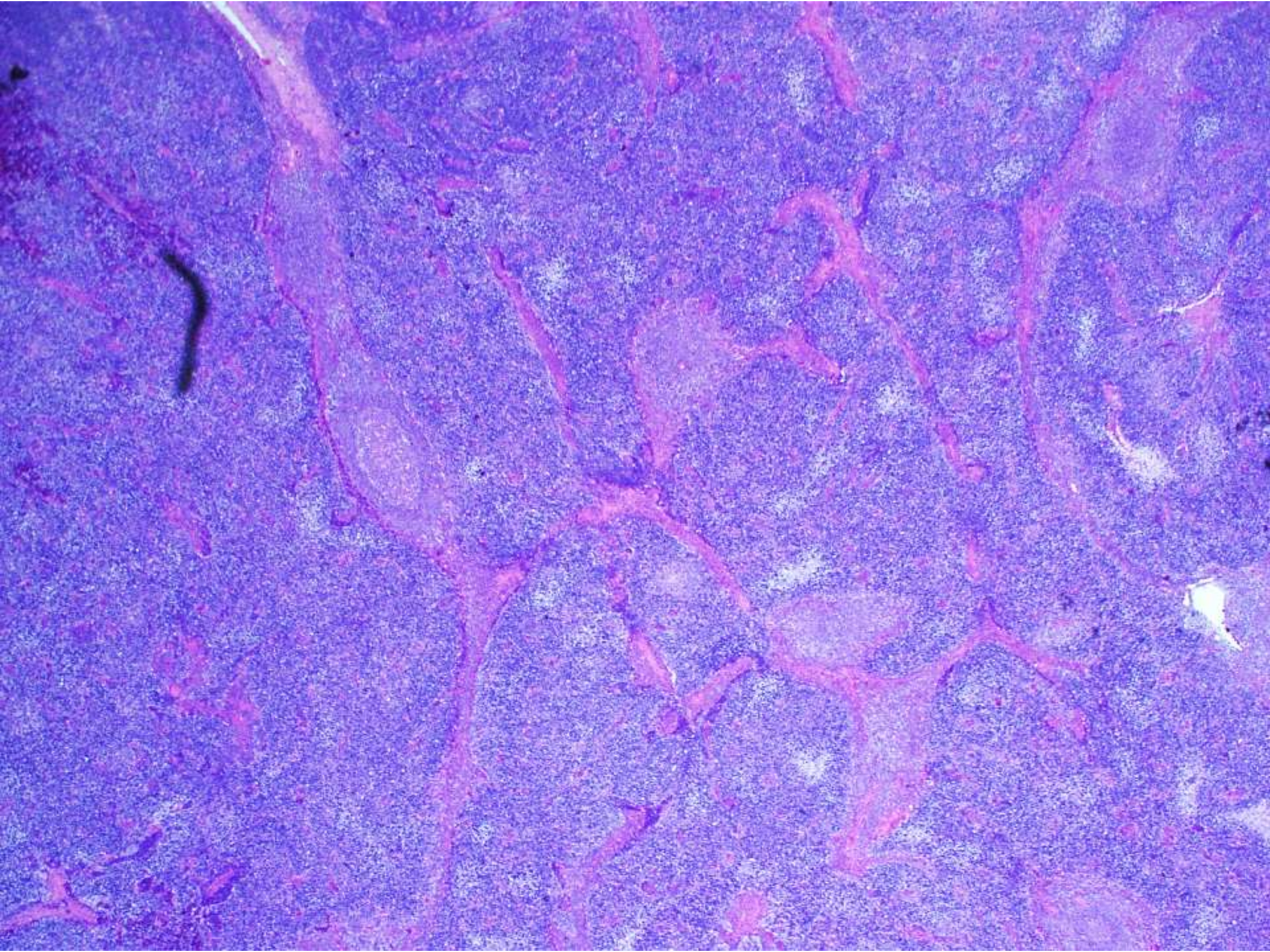


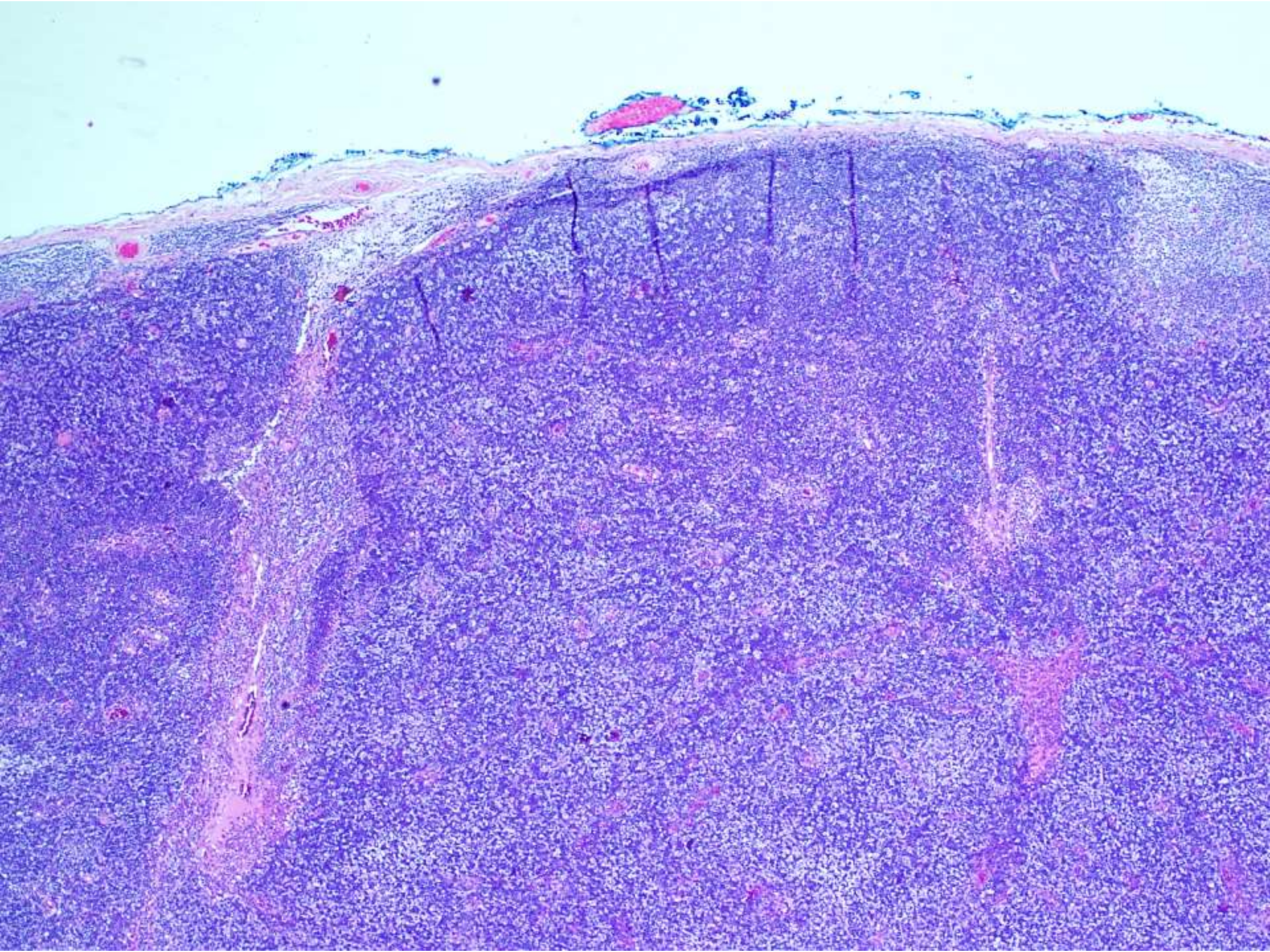
SB 6123

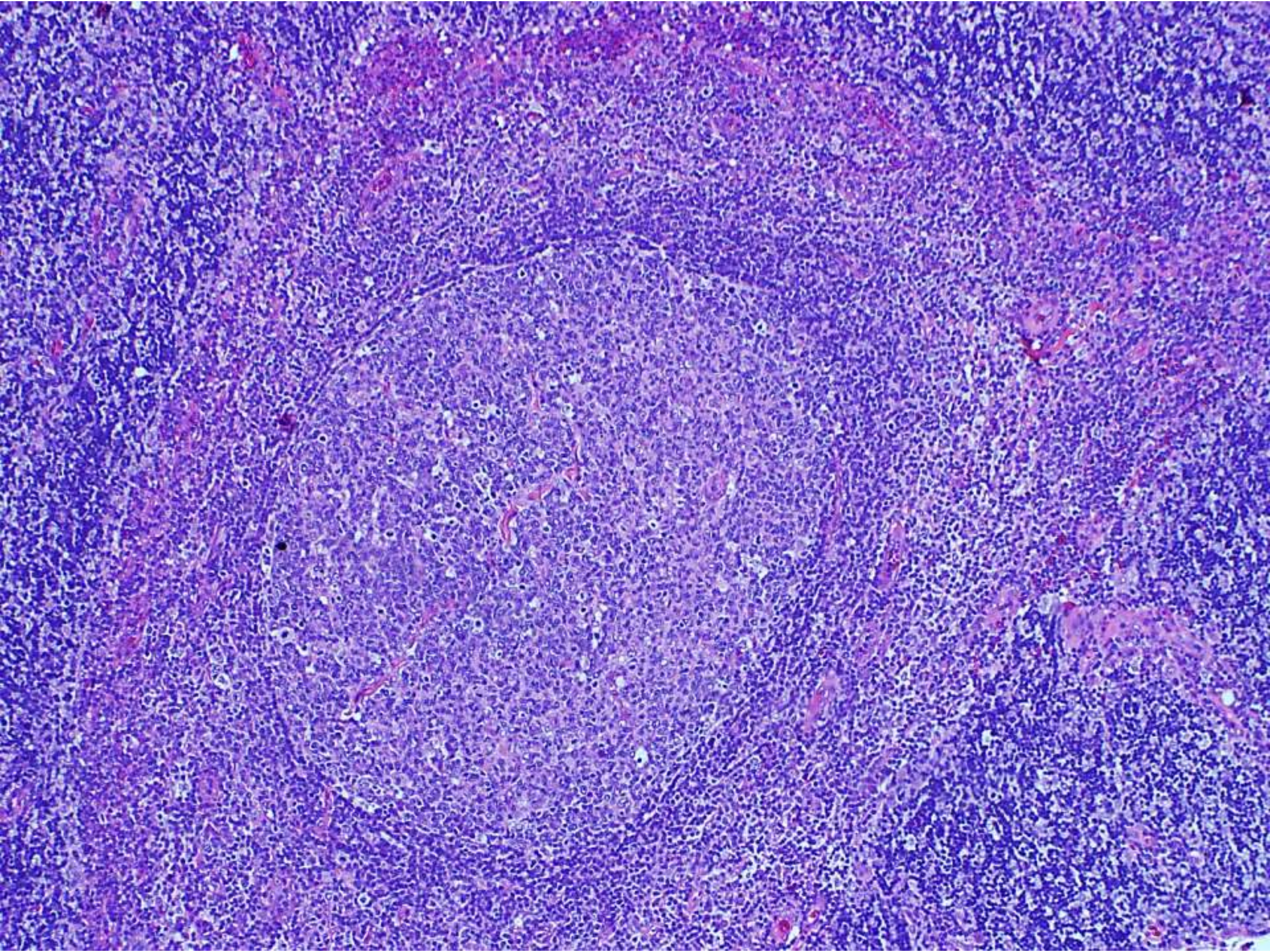
Sharon Wu/Roger Warnke; Stanford

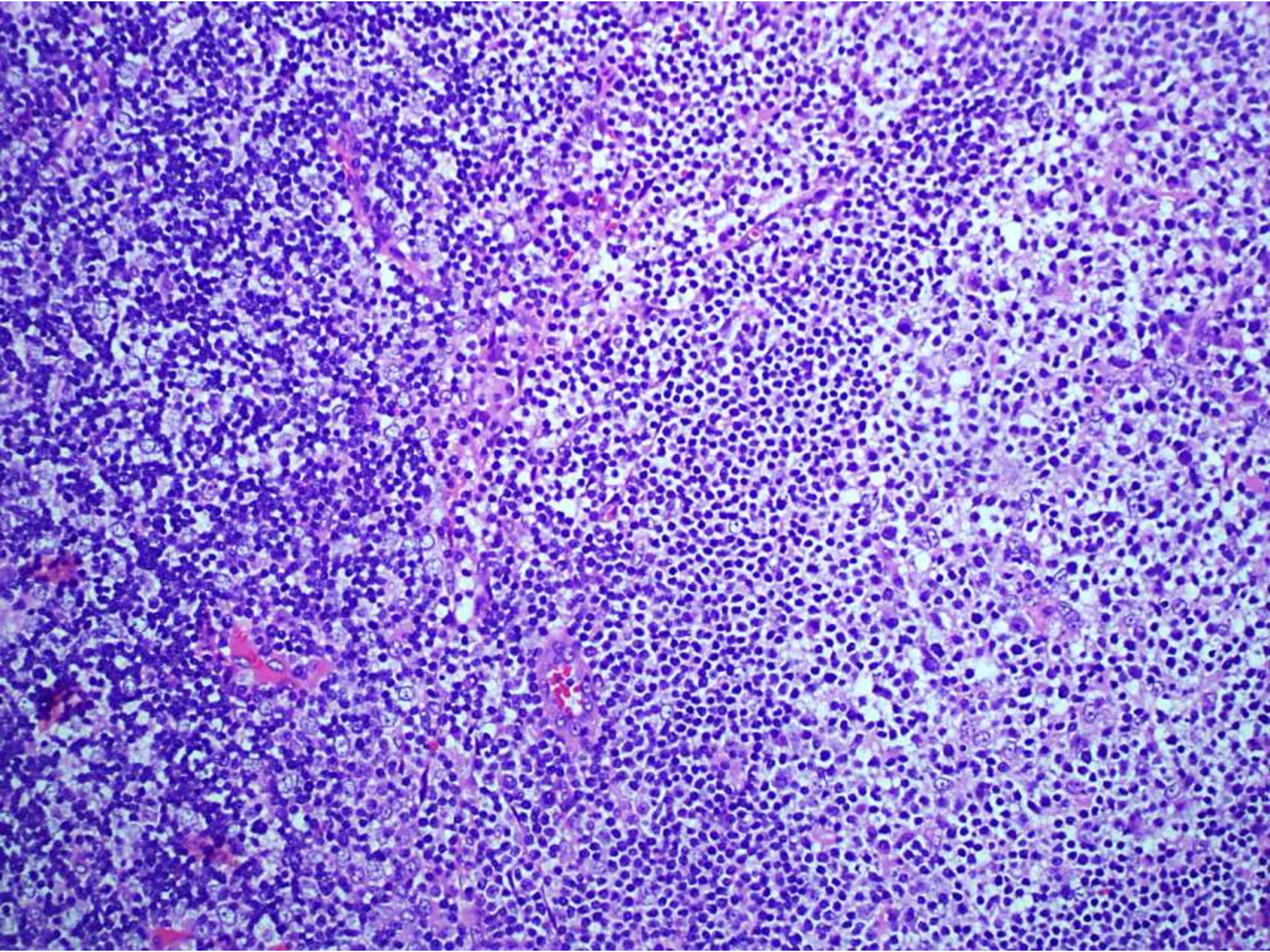
64-year-old woman with
supraclavicular lymphadenopathy.

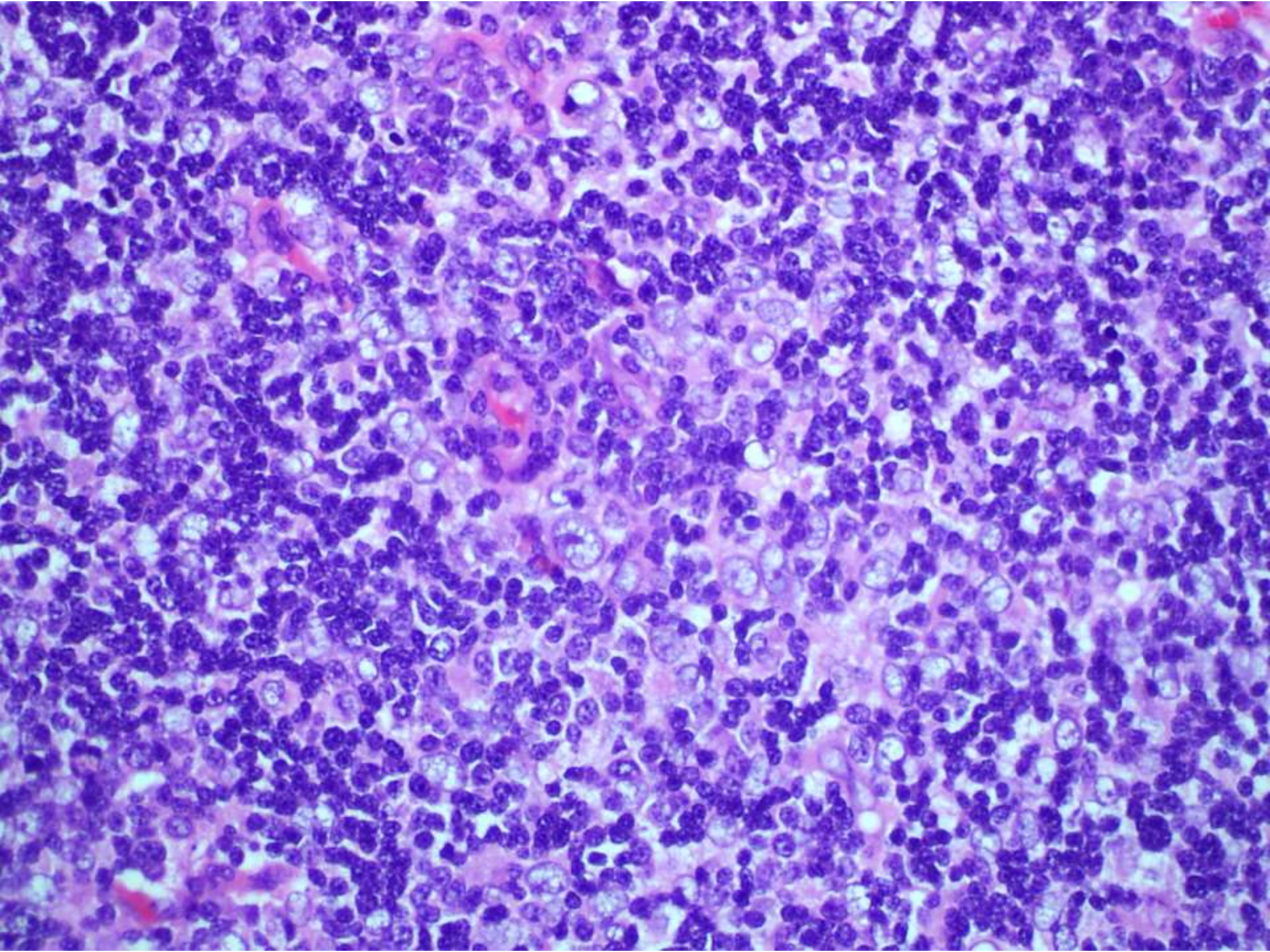




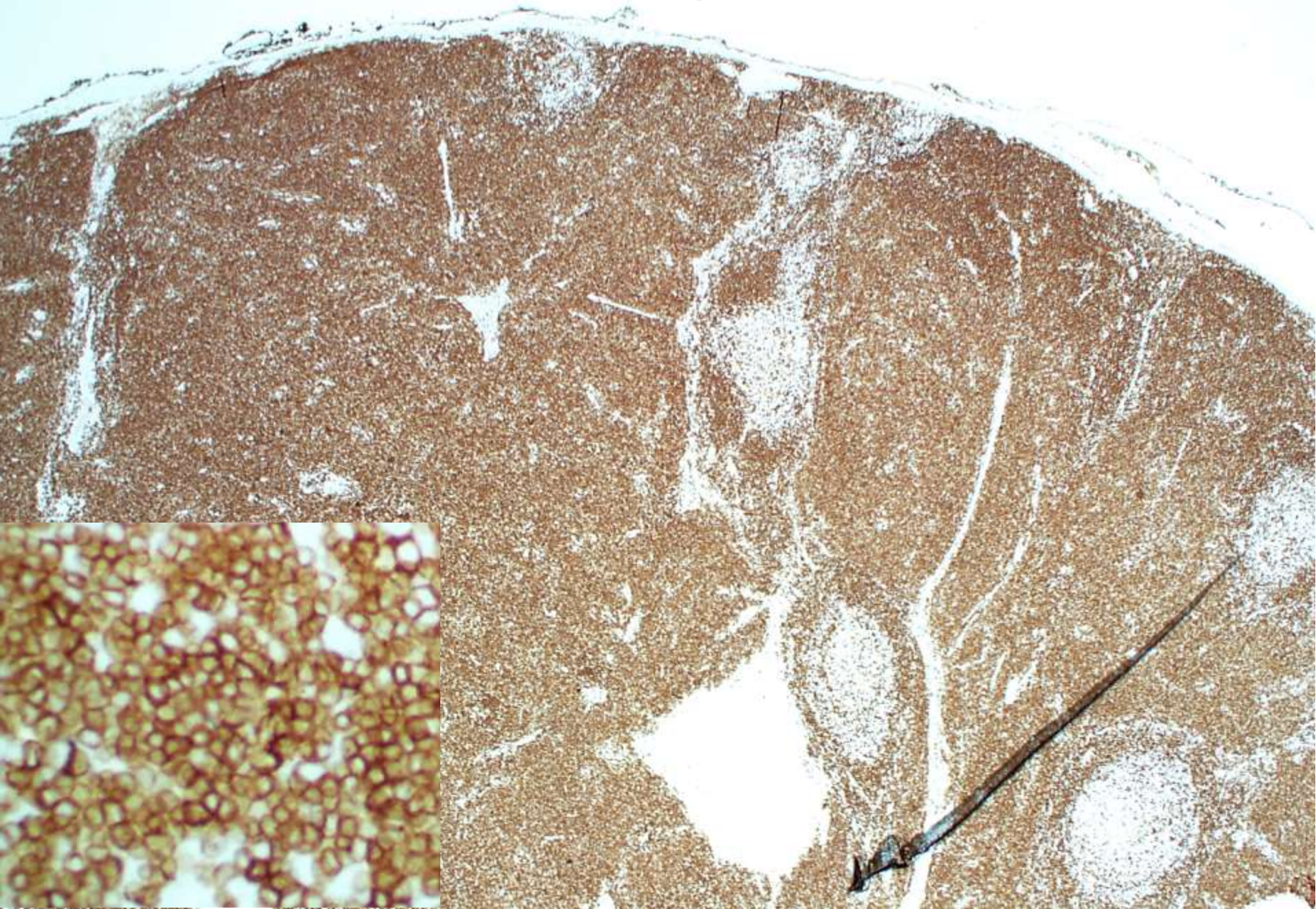




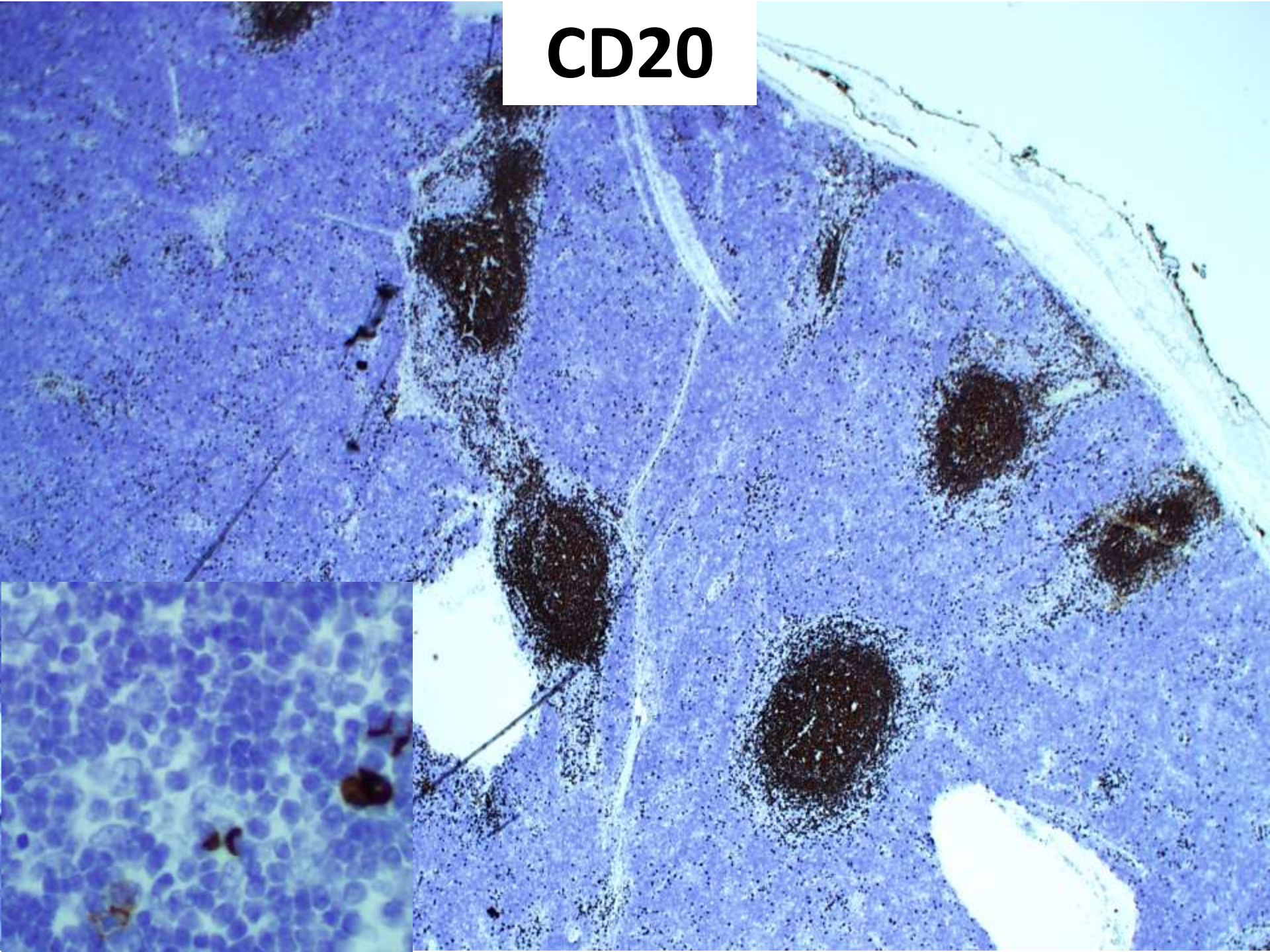




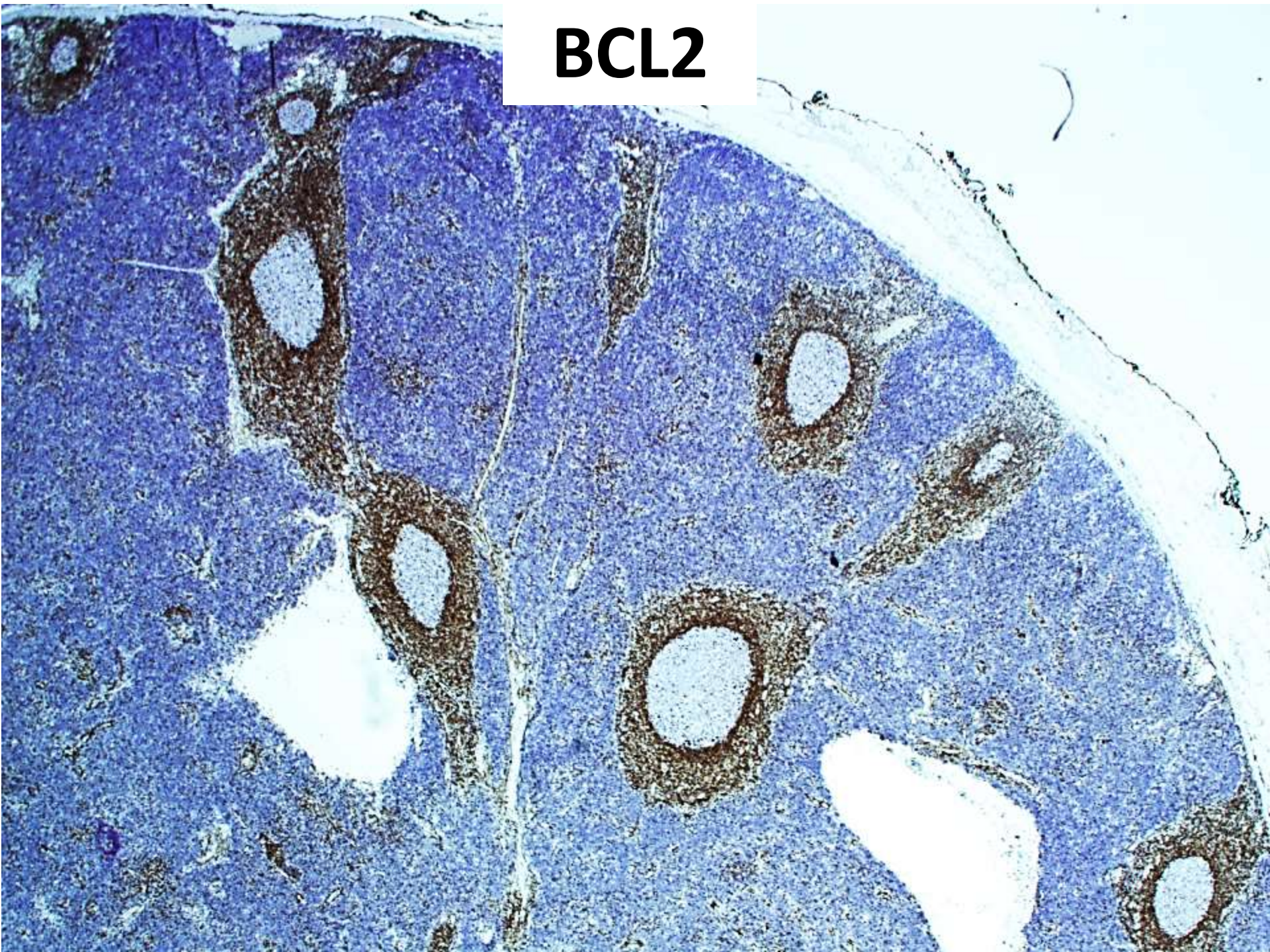
CD3



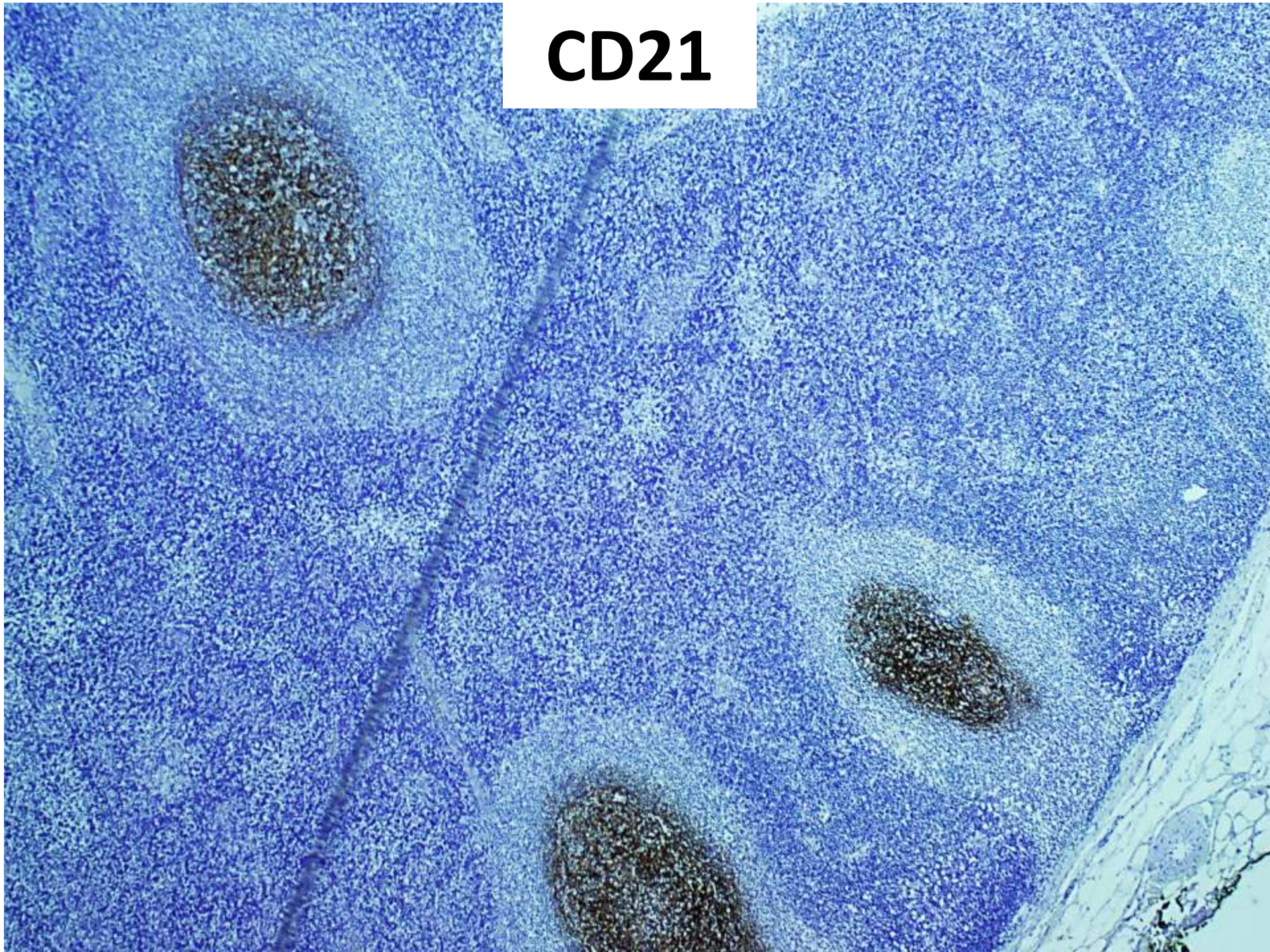
CD20



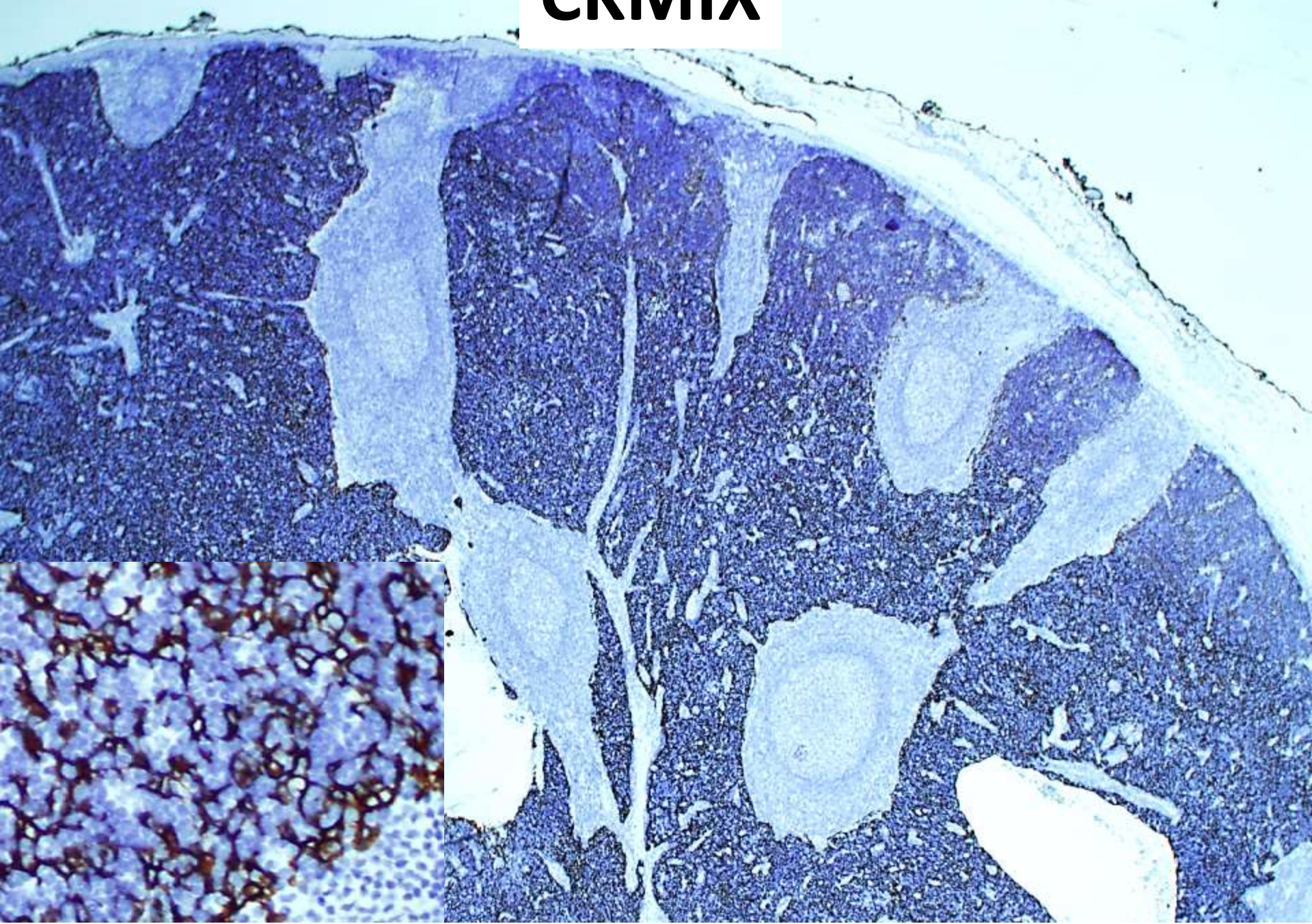
BCL2



CD21



CKMIX

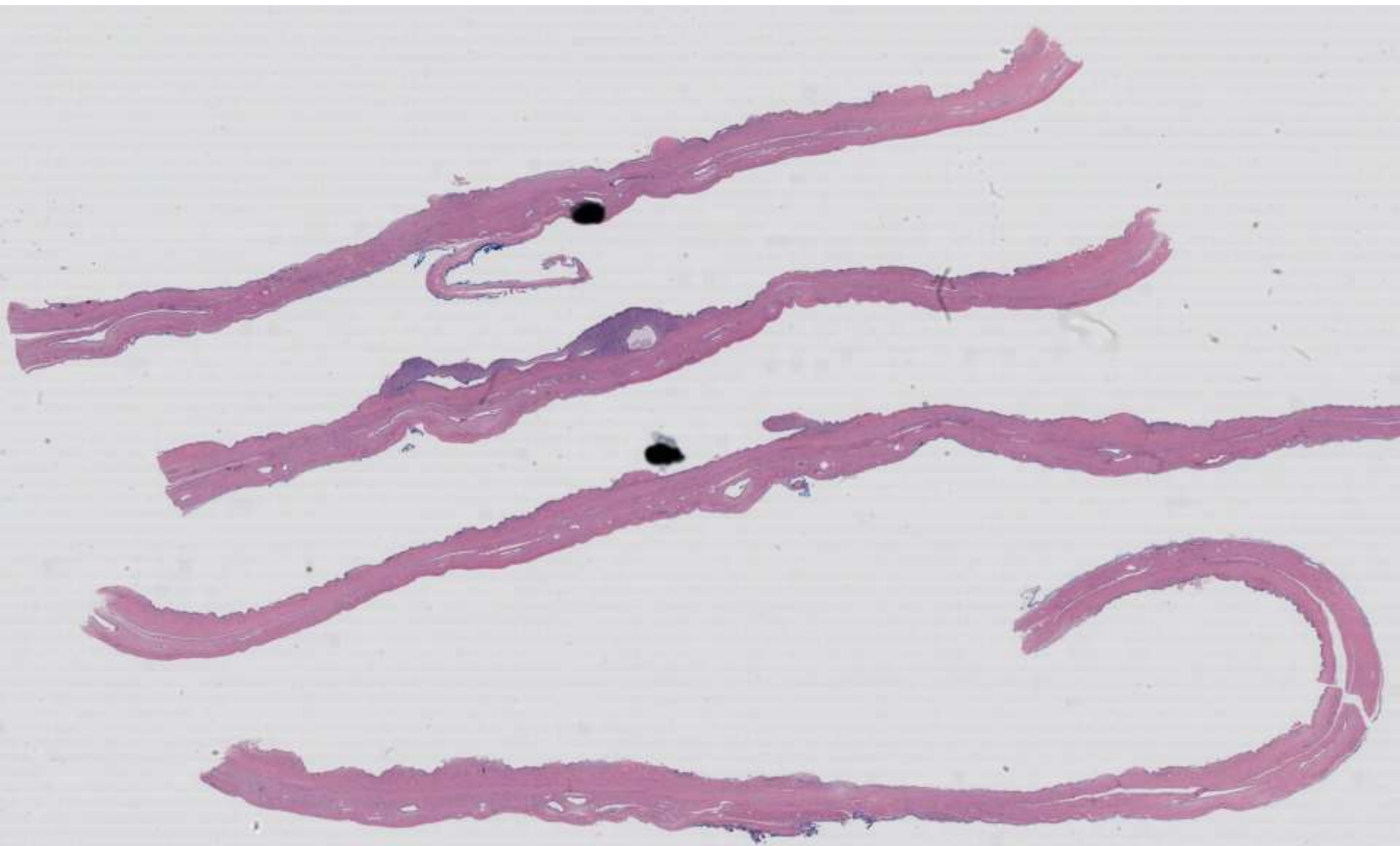

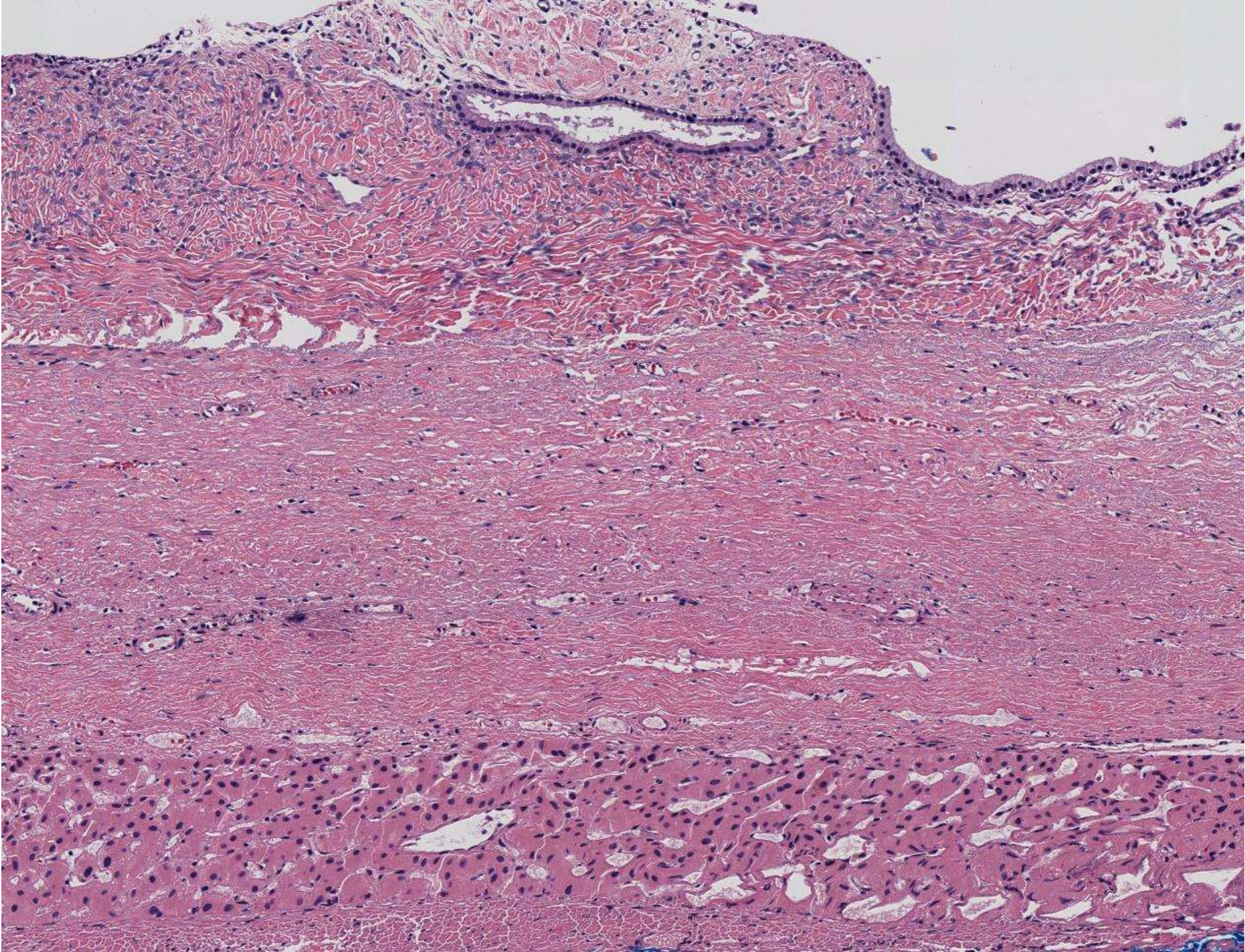
SB 6124

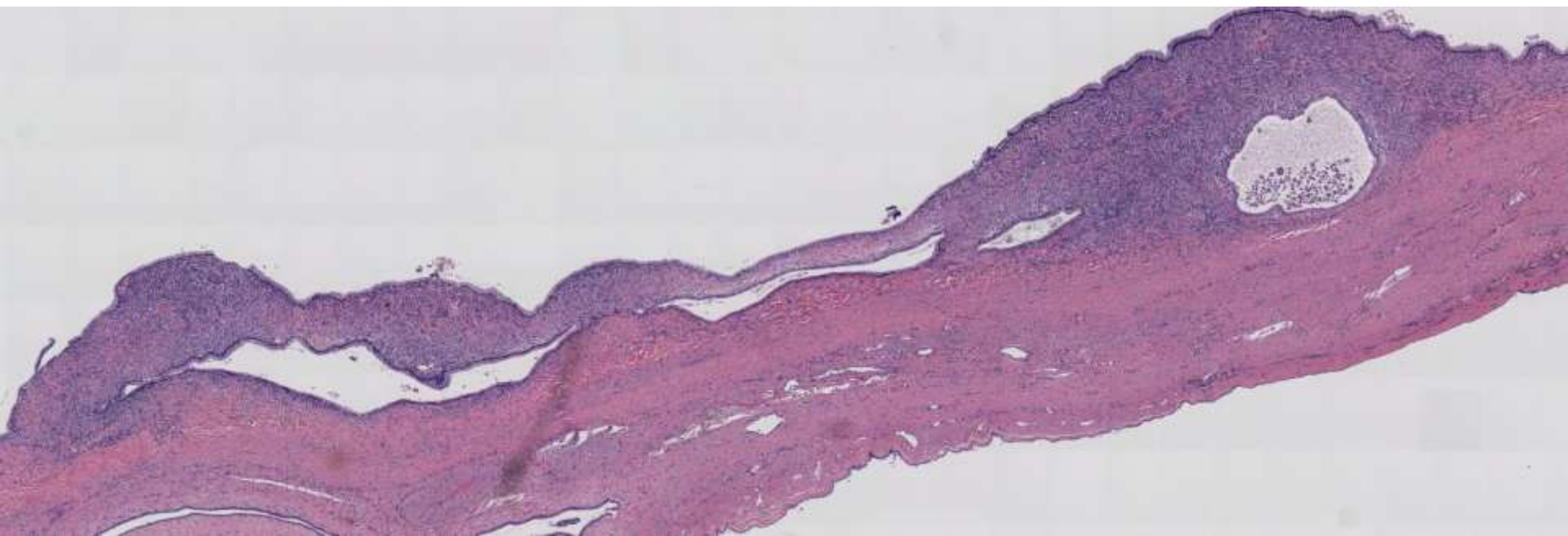
(scanned slide available)

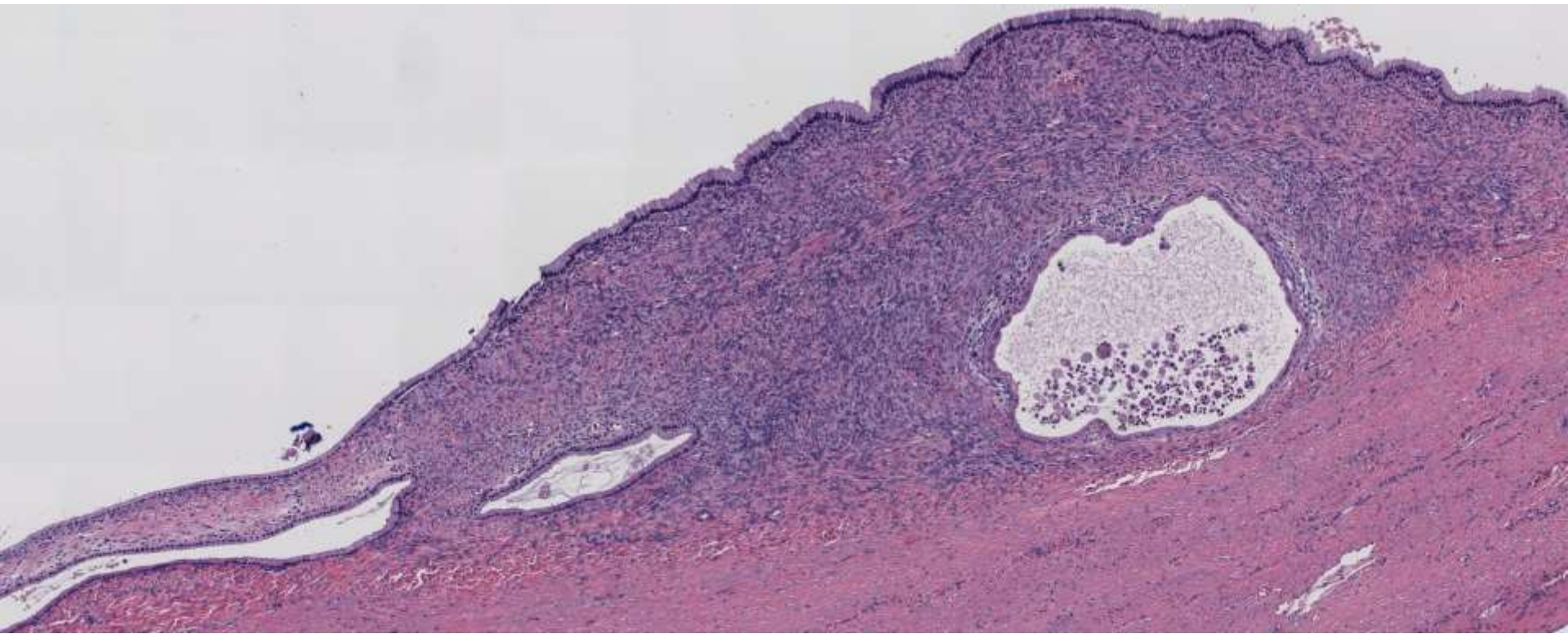
Mahendra Ranchod; Good Samaritan Hospital

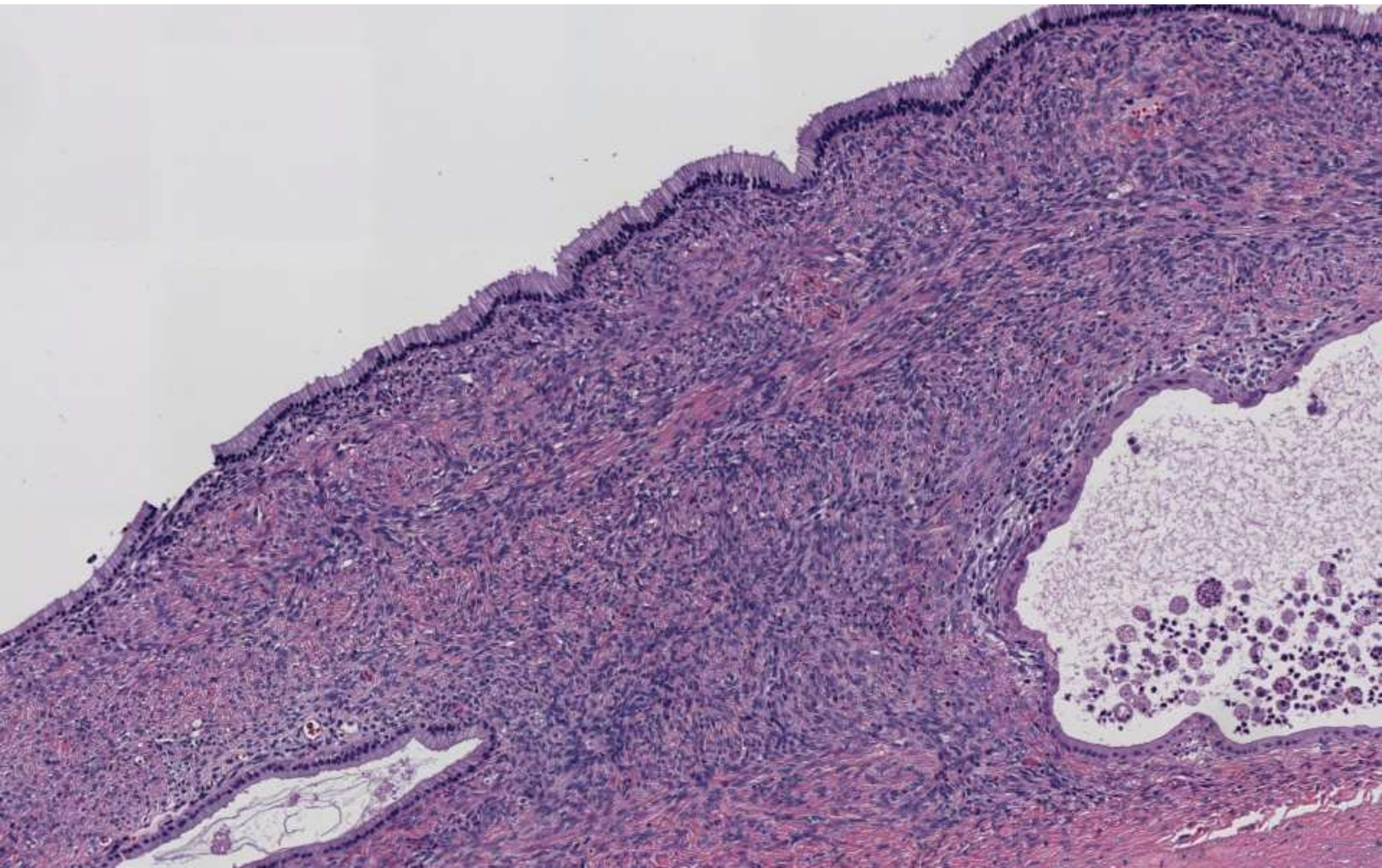
62-year-old woman presented with 1 year history of abdominal pain. A cystic lesion (13cm in maximum dimension) was resected from right lobe of liver.

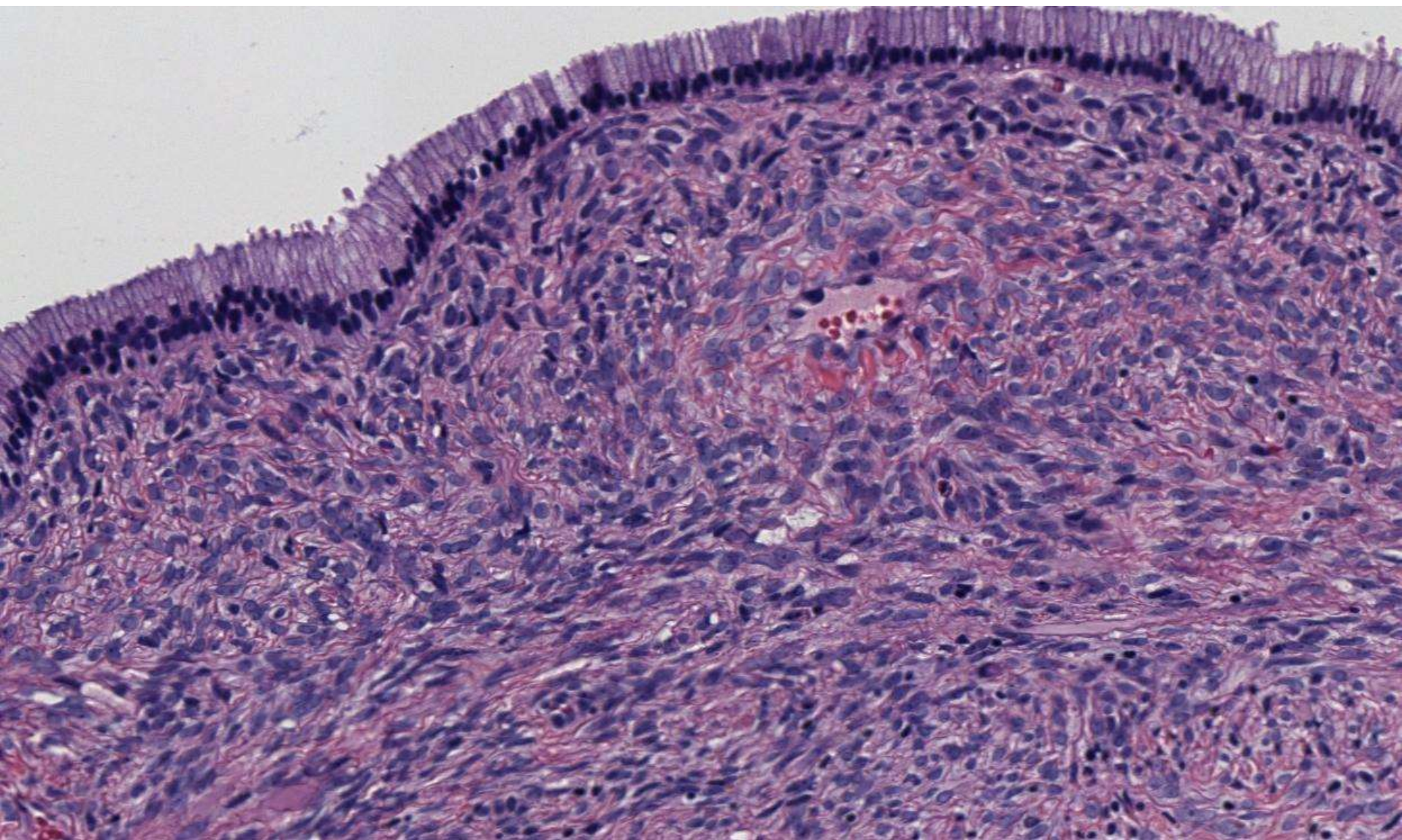










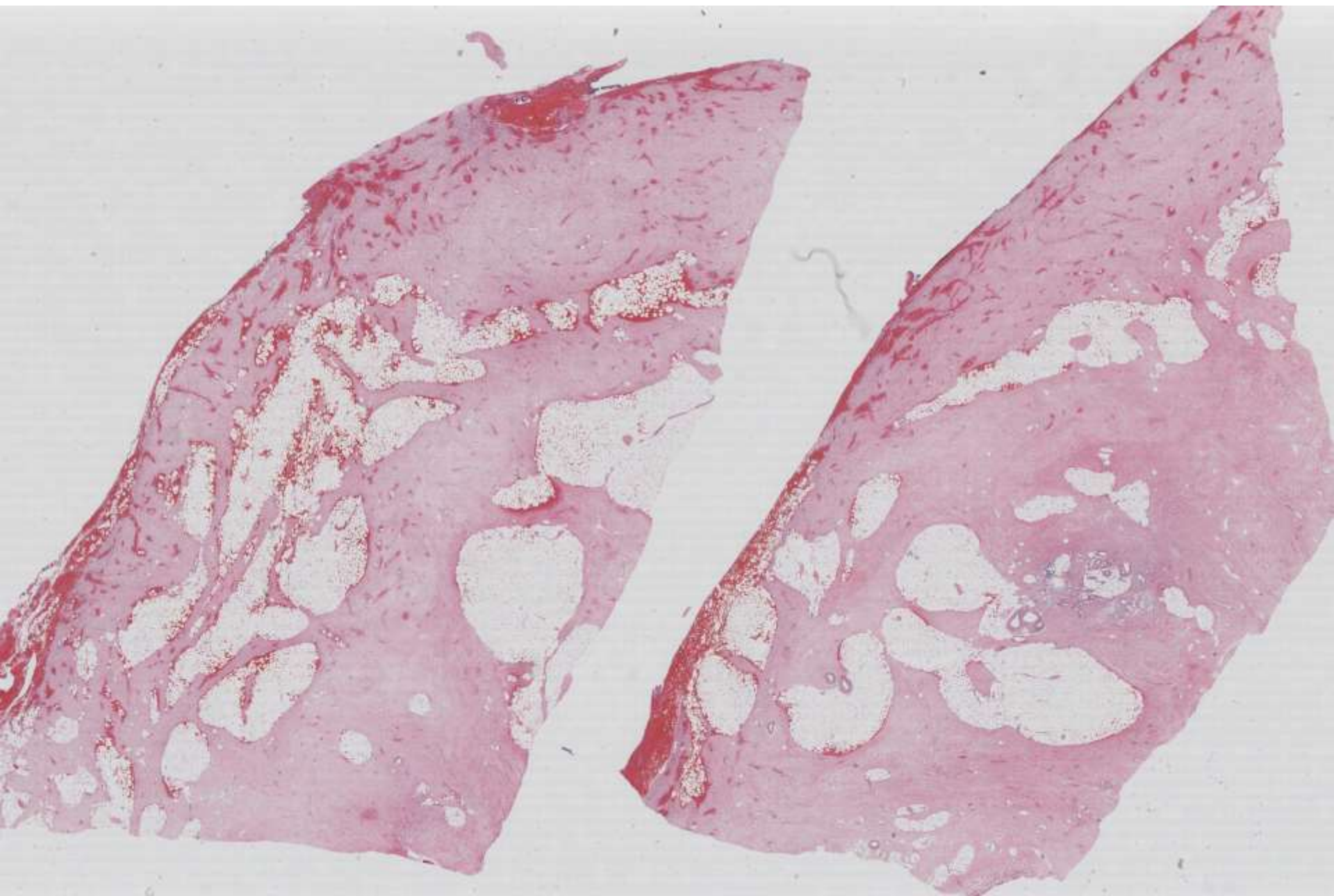


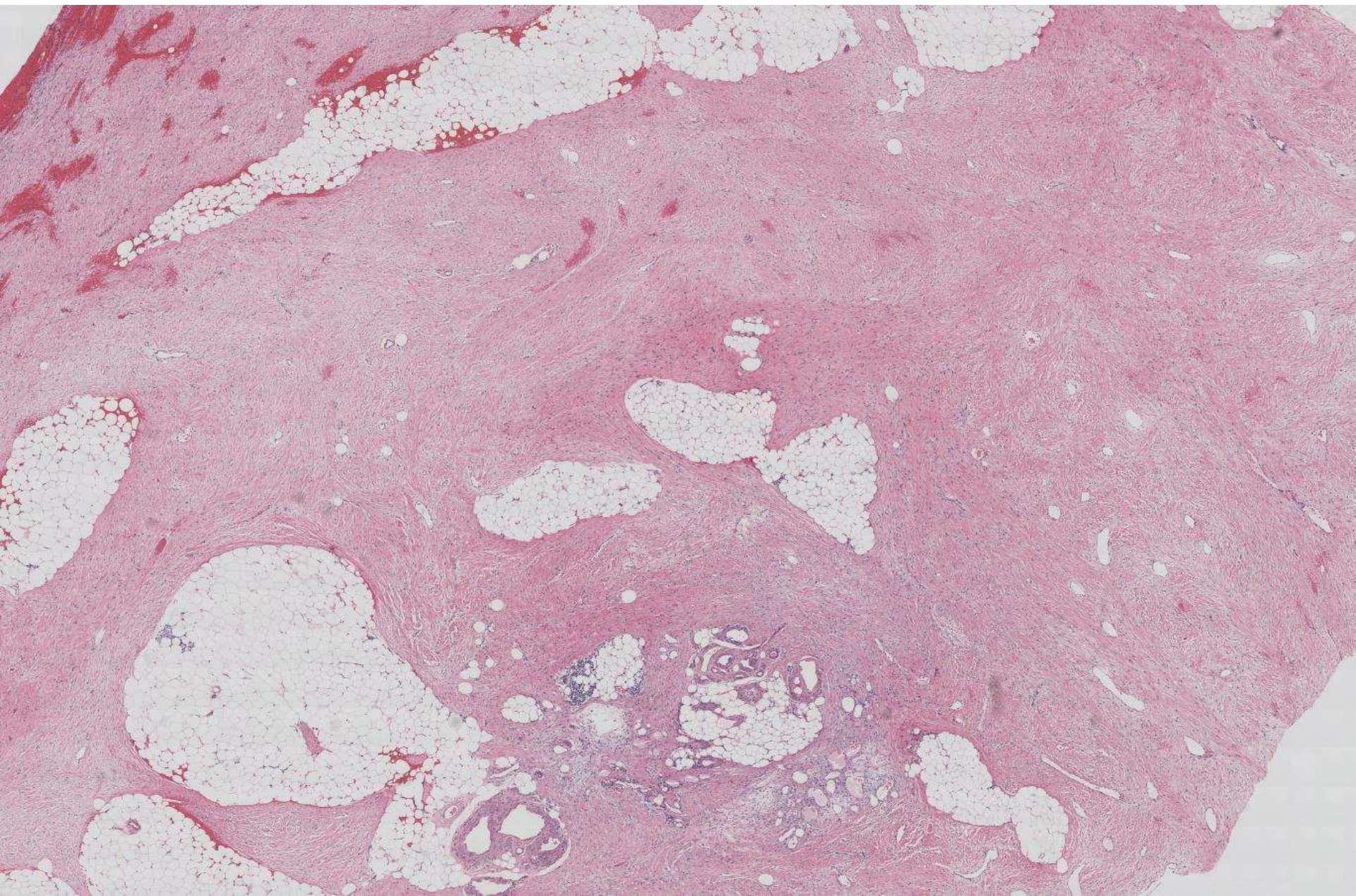
SB 6125

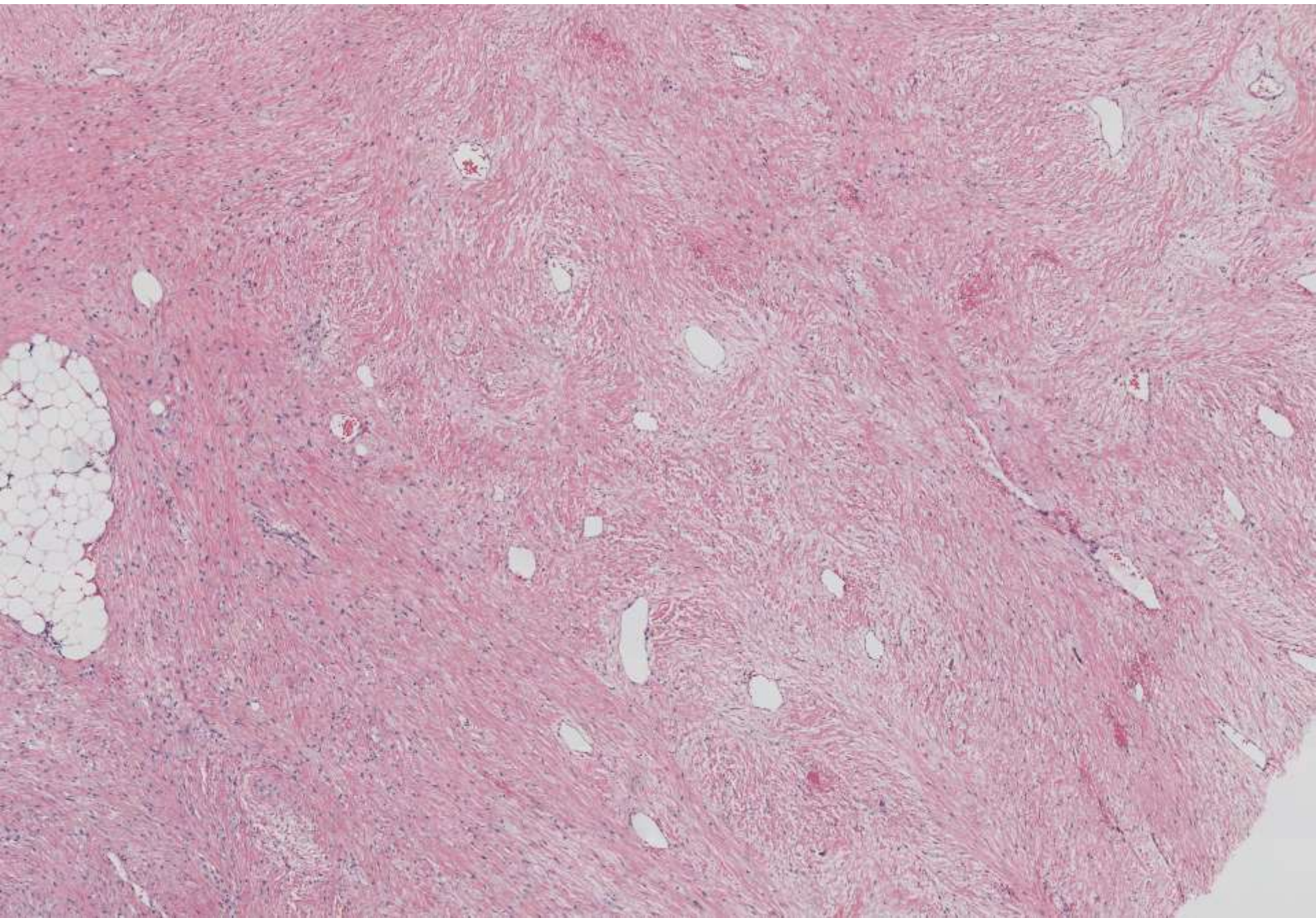
(scanned slide available)

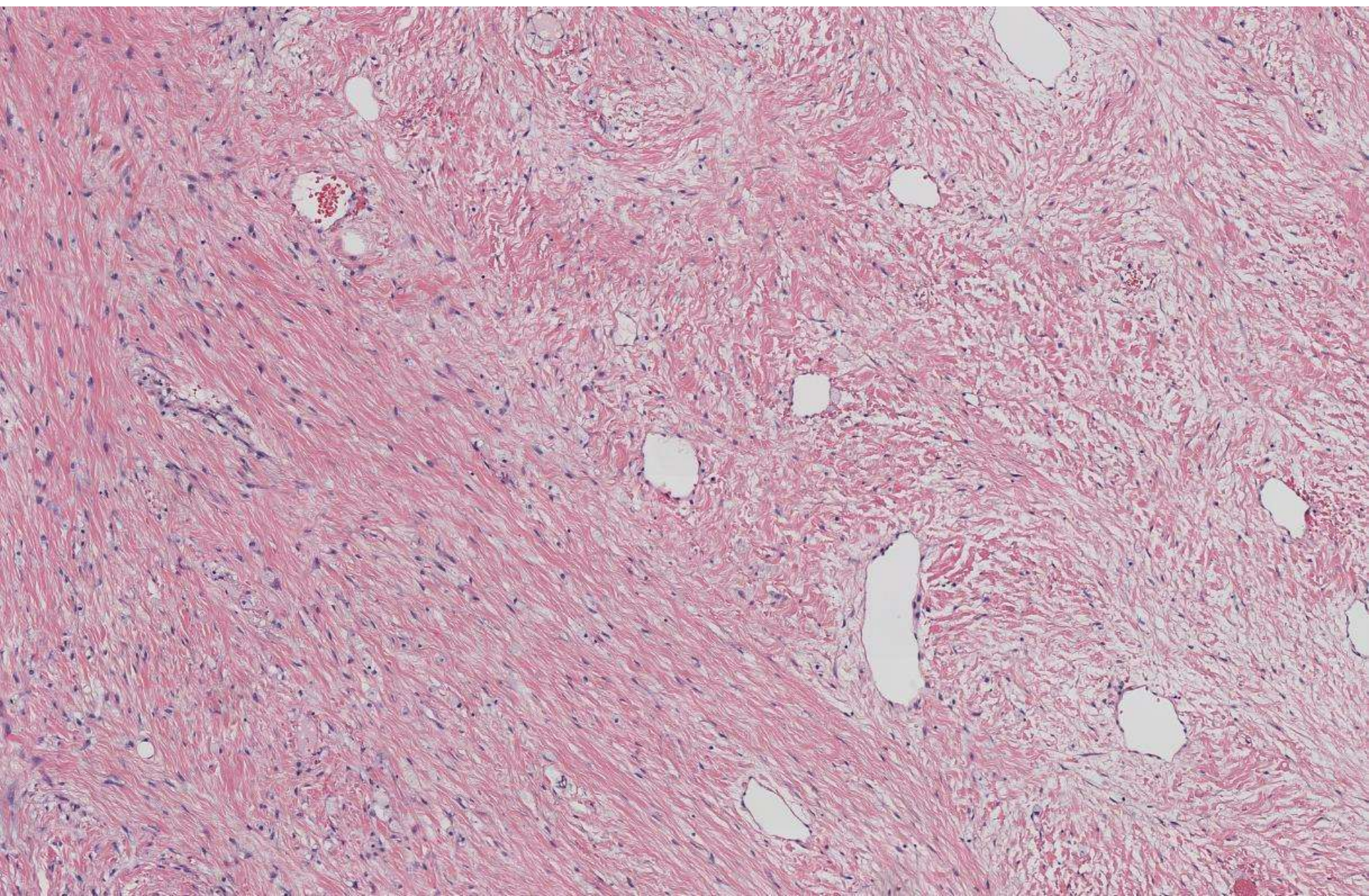
Keith Duncan; Mills-Peninsula Hospital

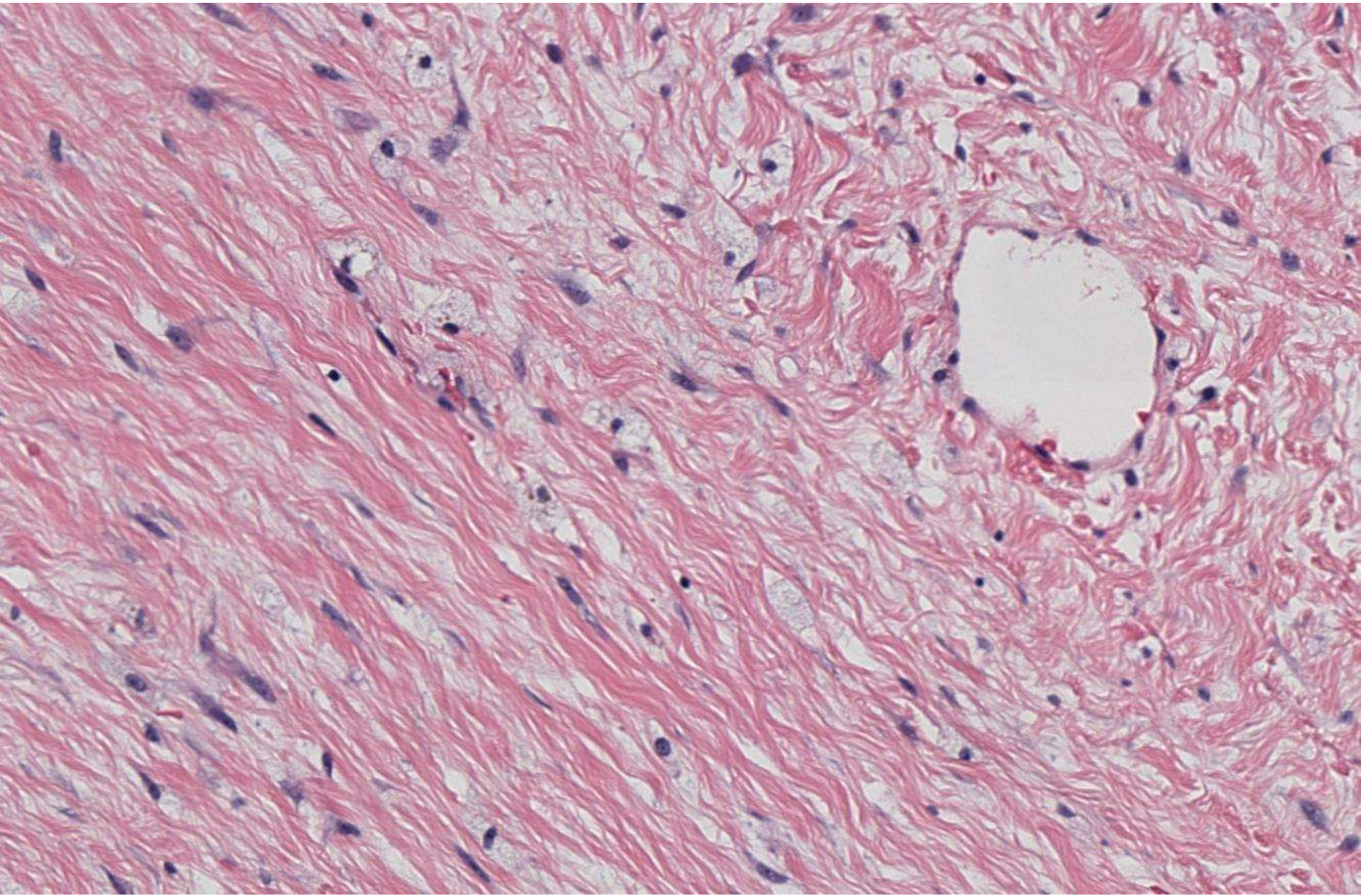
80-year-old woman with small bowel obstruction and 7.5cm firm tan tumor within mesenteric fat. History of prior upper quadrant tumor resection 2 years prior.

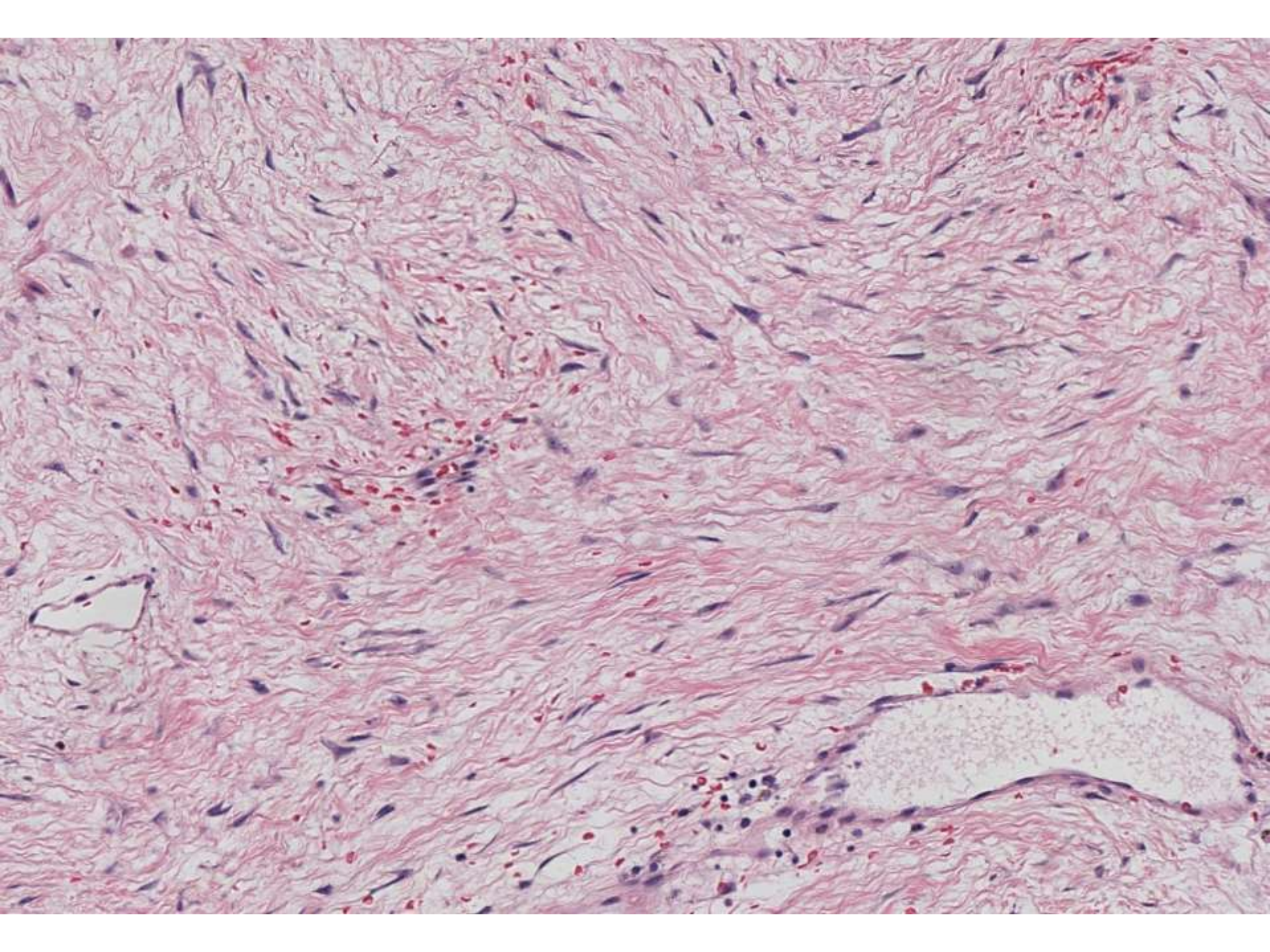


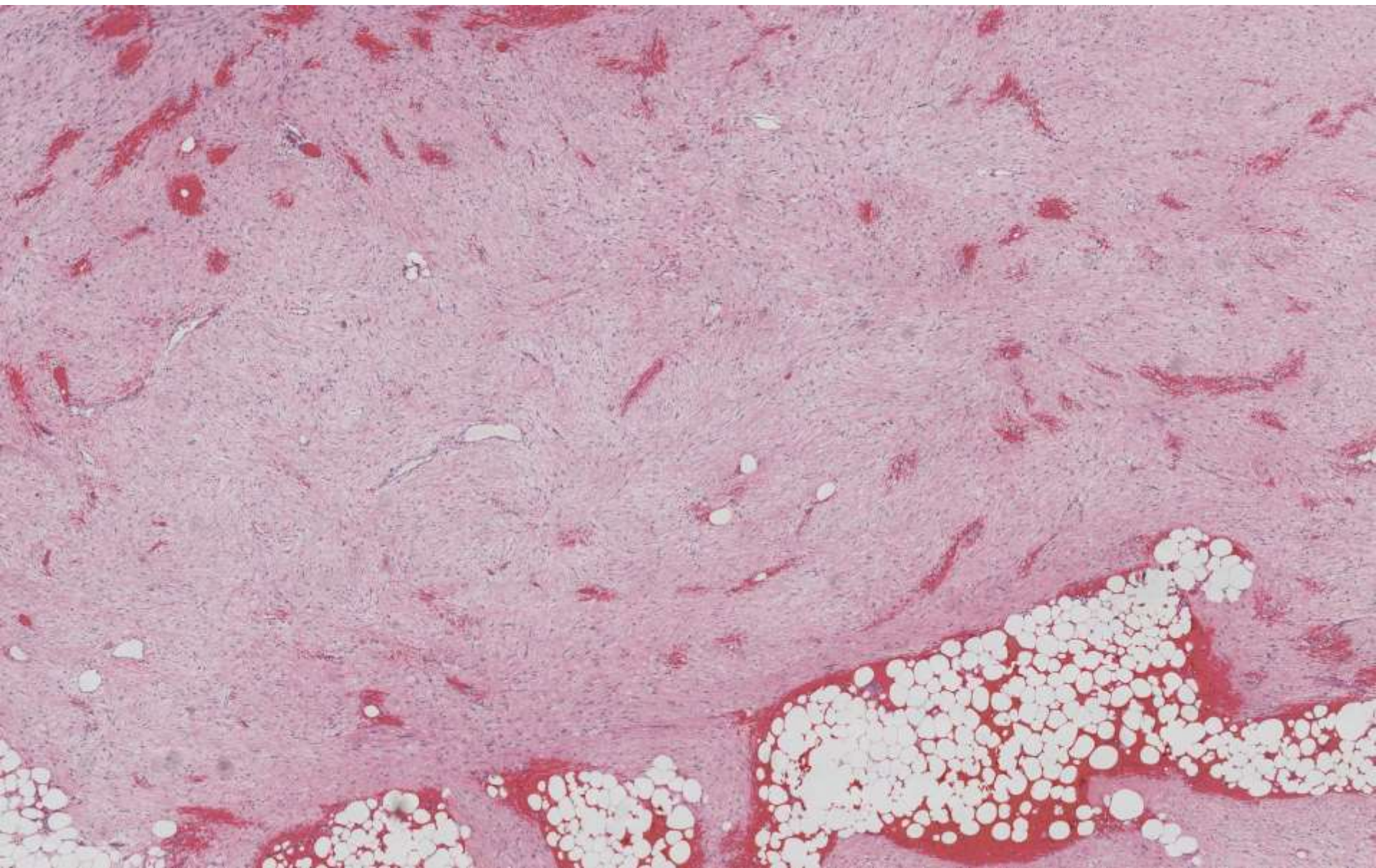


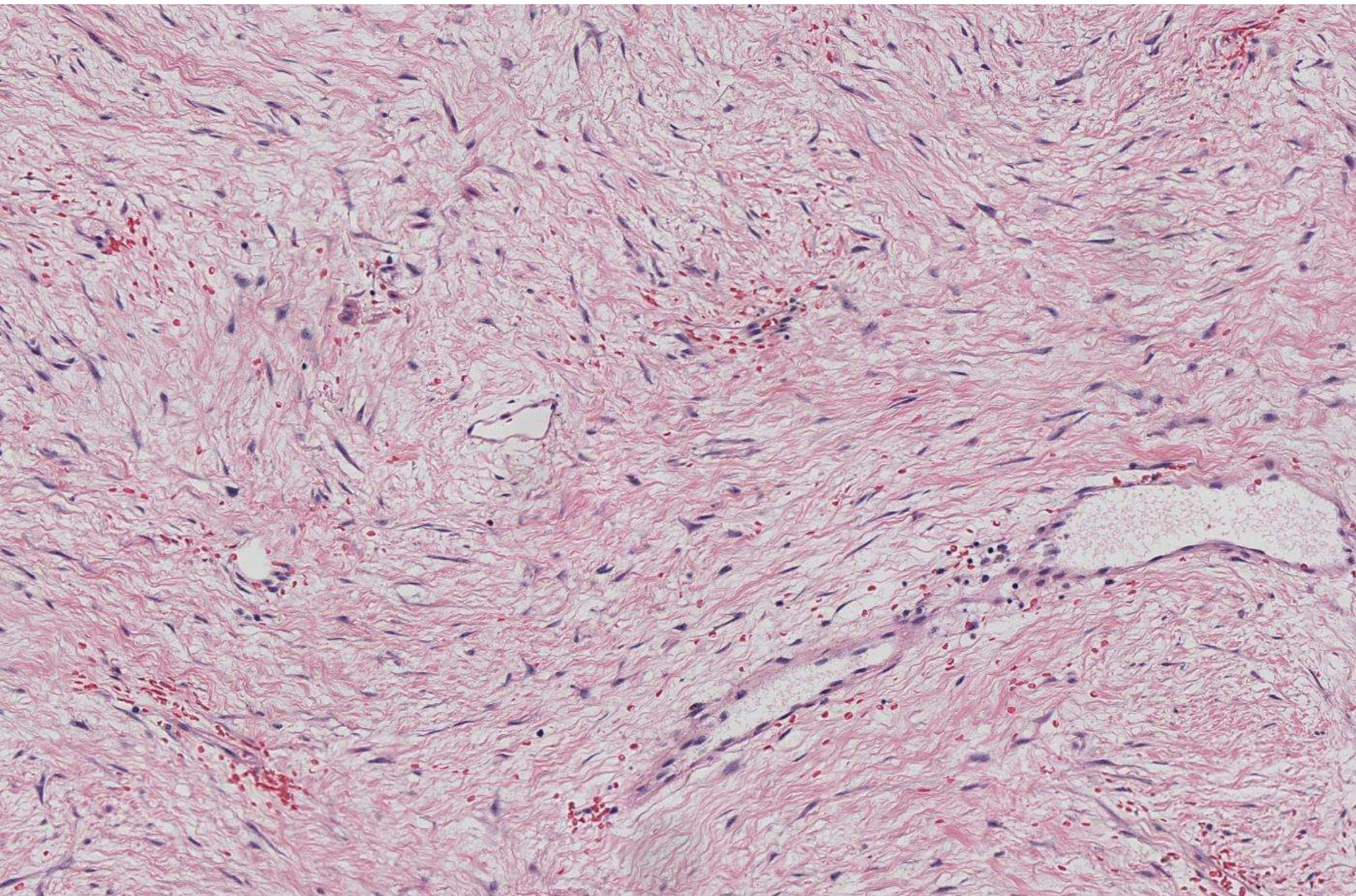






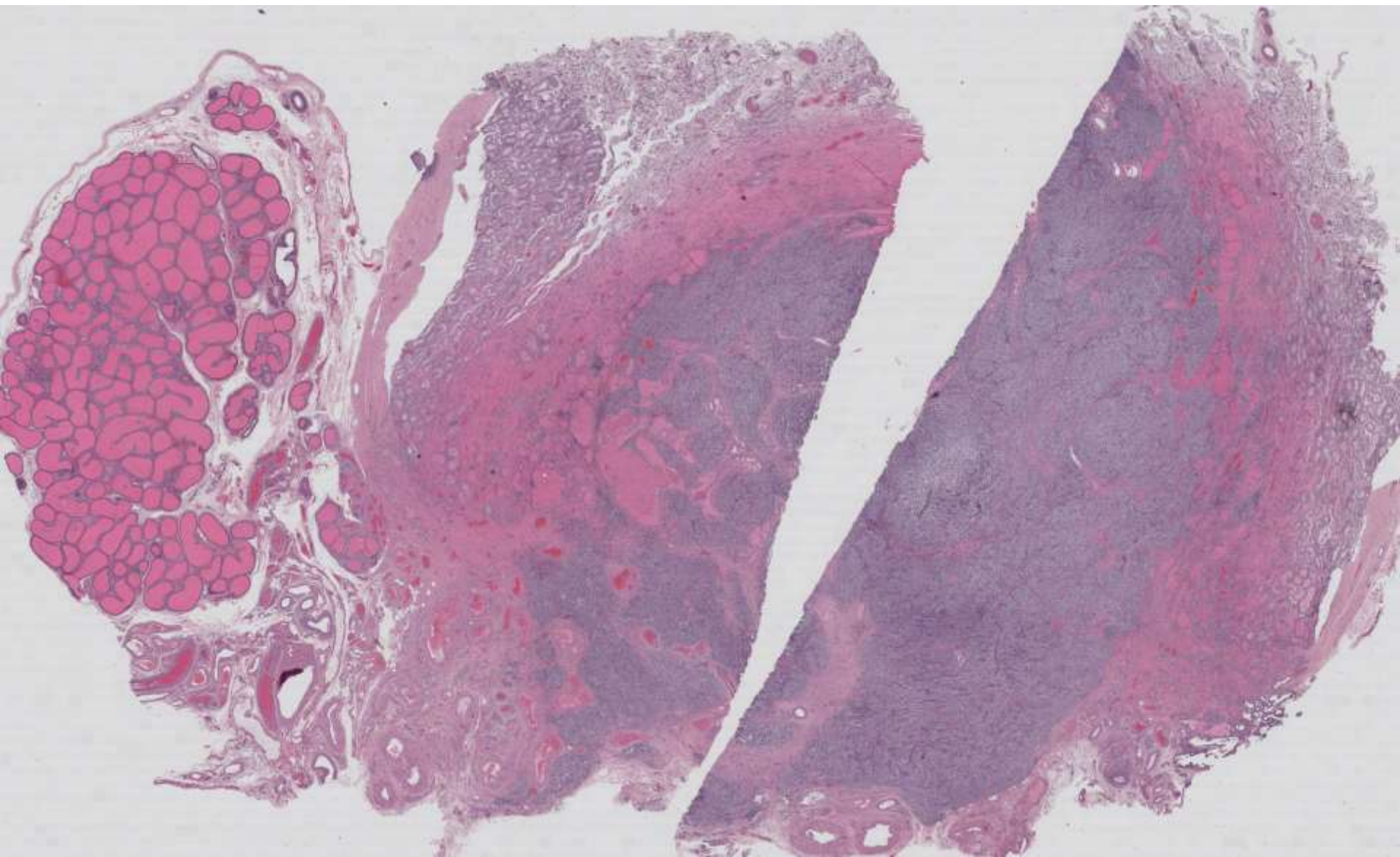


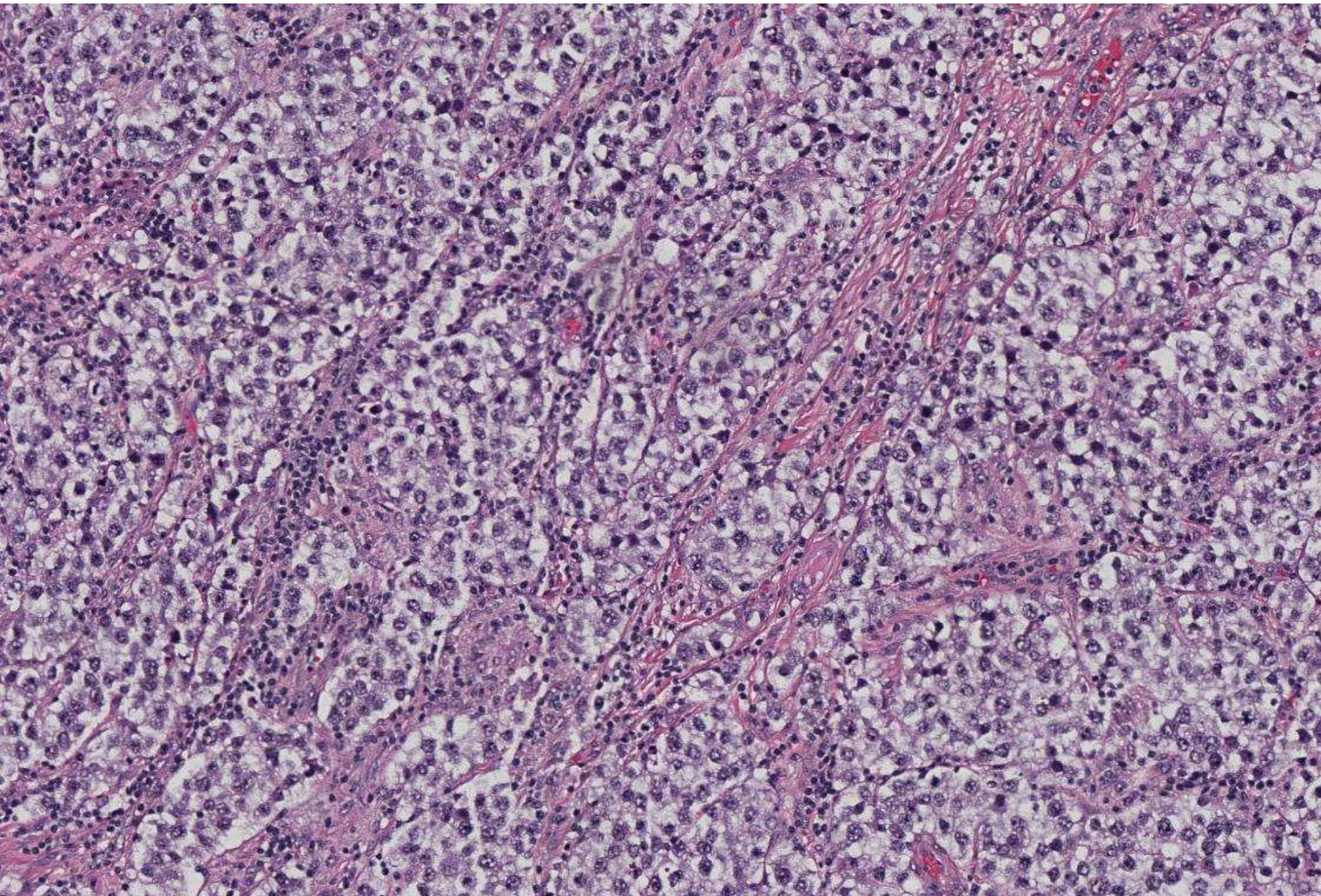


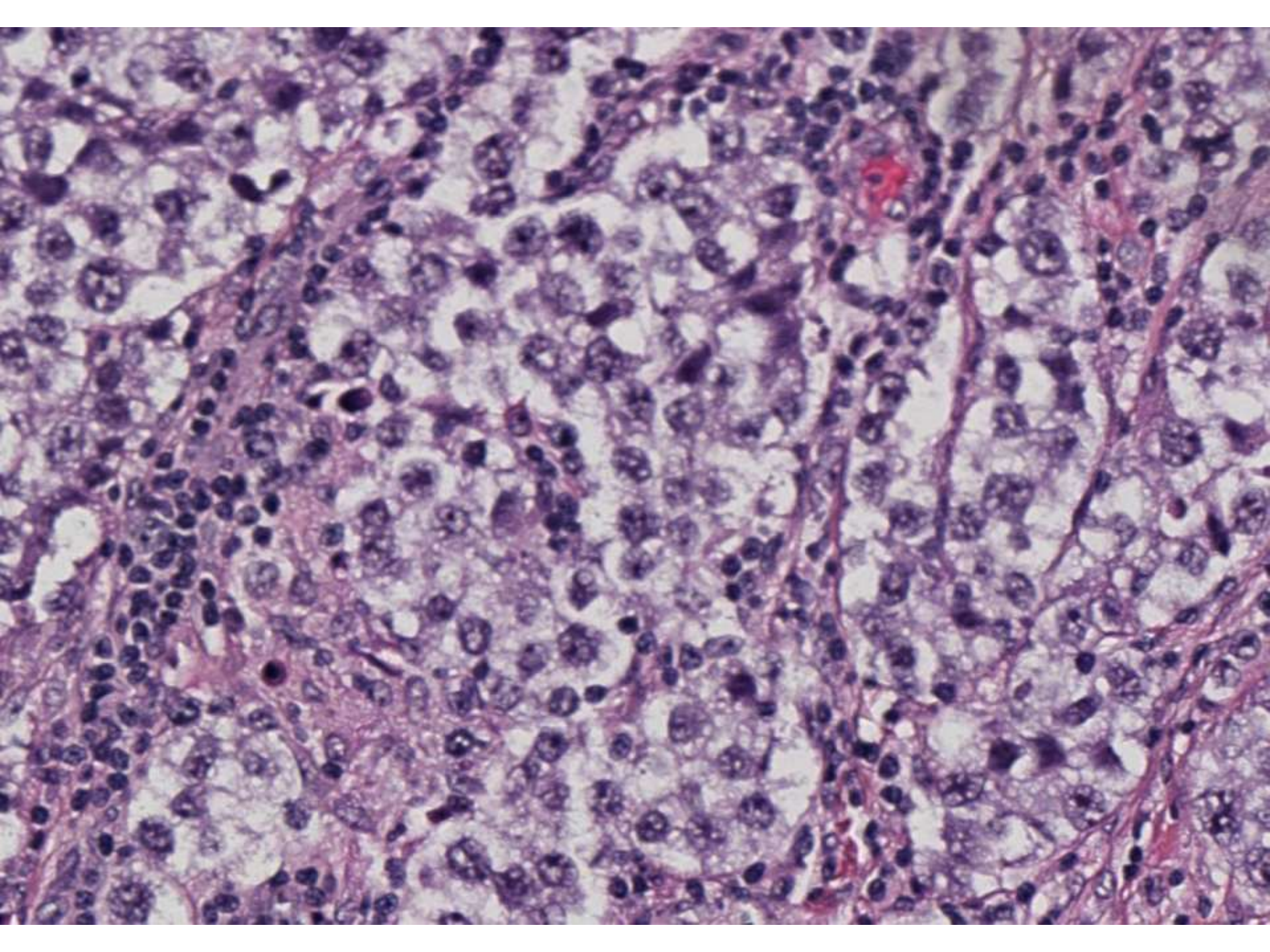


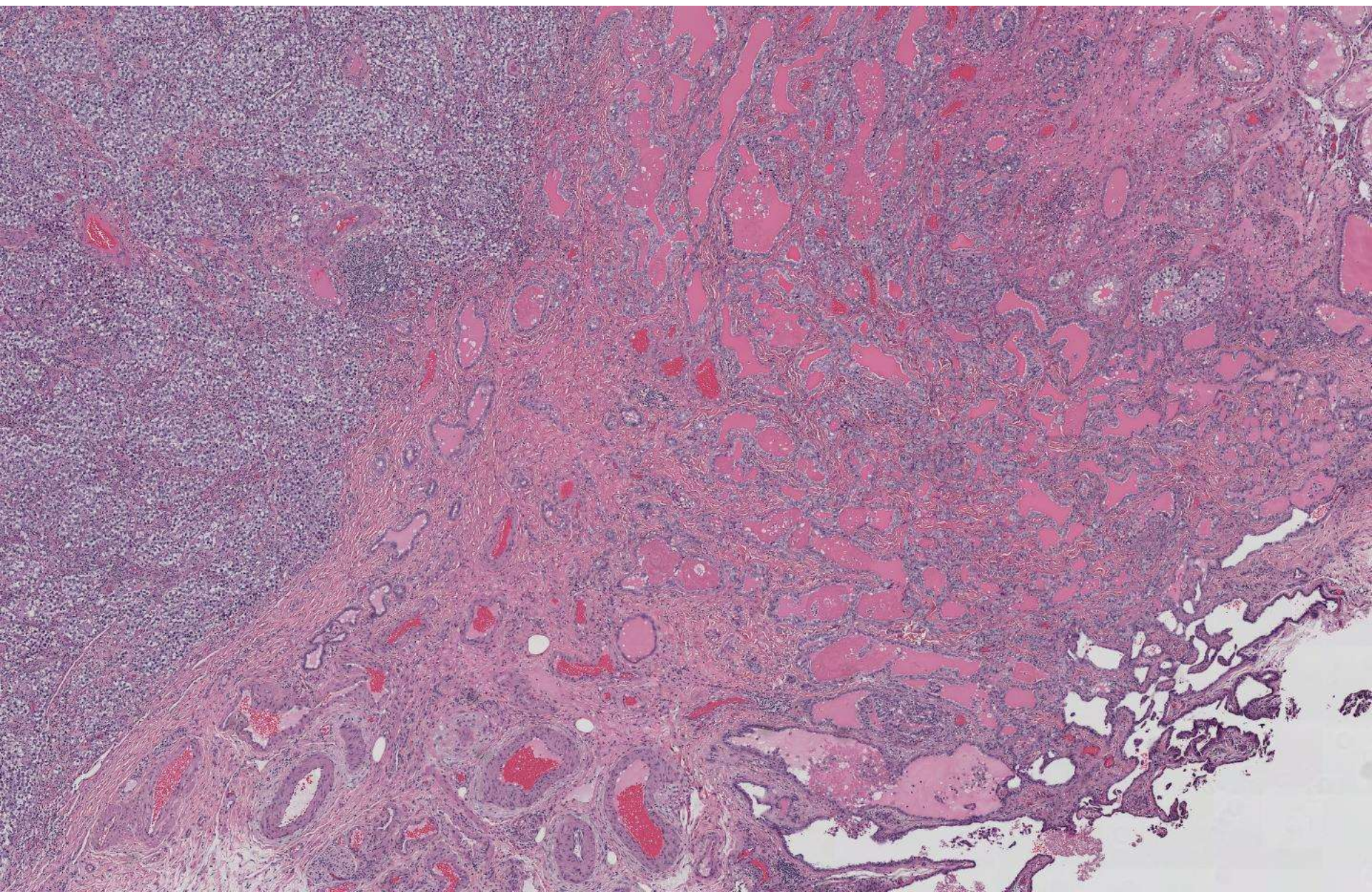
SB 6126 A&B
(scanned slide available)

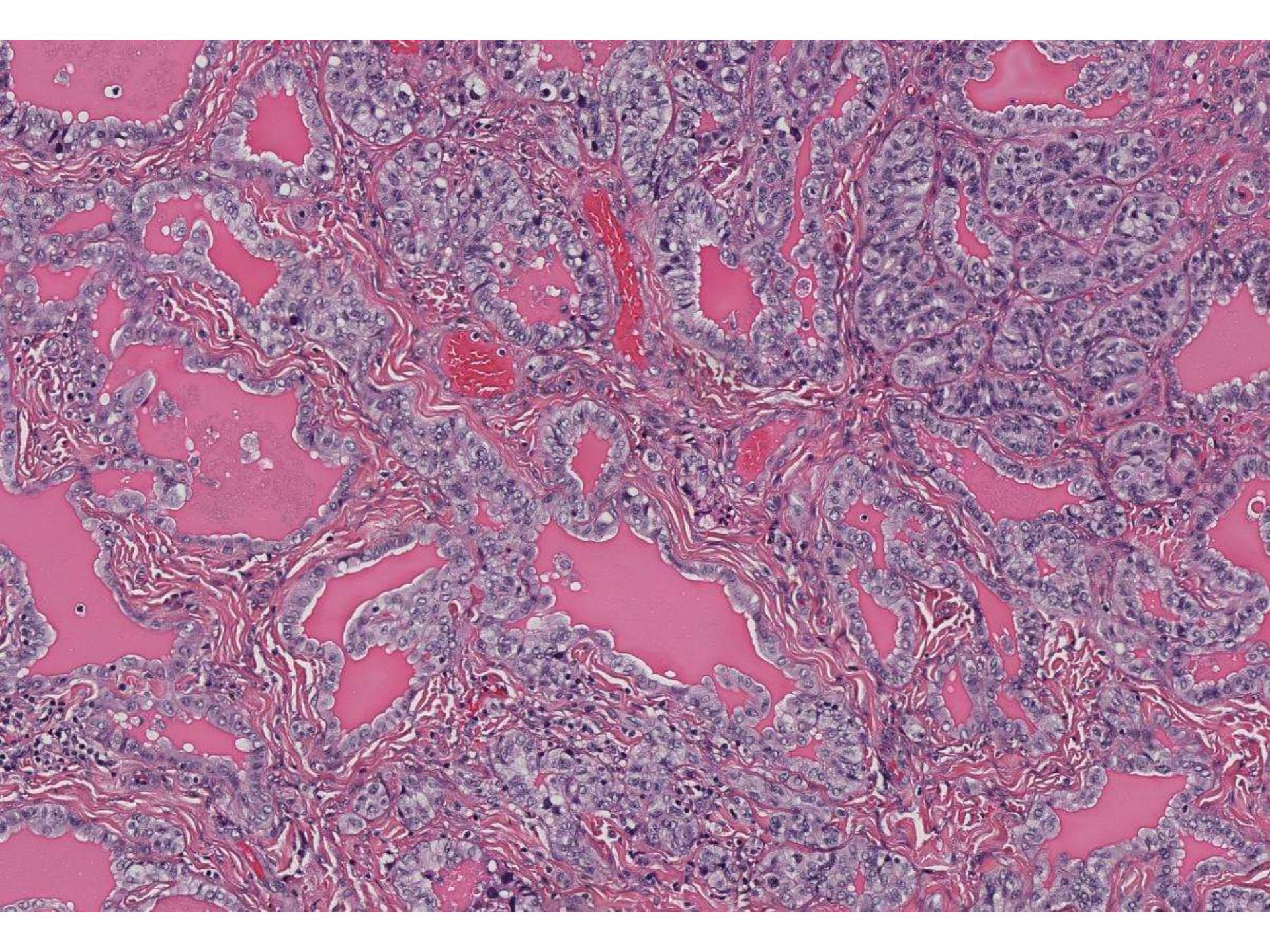
Ankur Sangoi; El Camino Hospital
48-year-old male with testicular mass
and mildly elevated AFP.

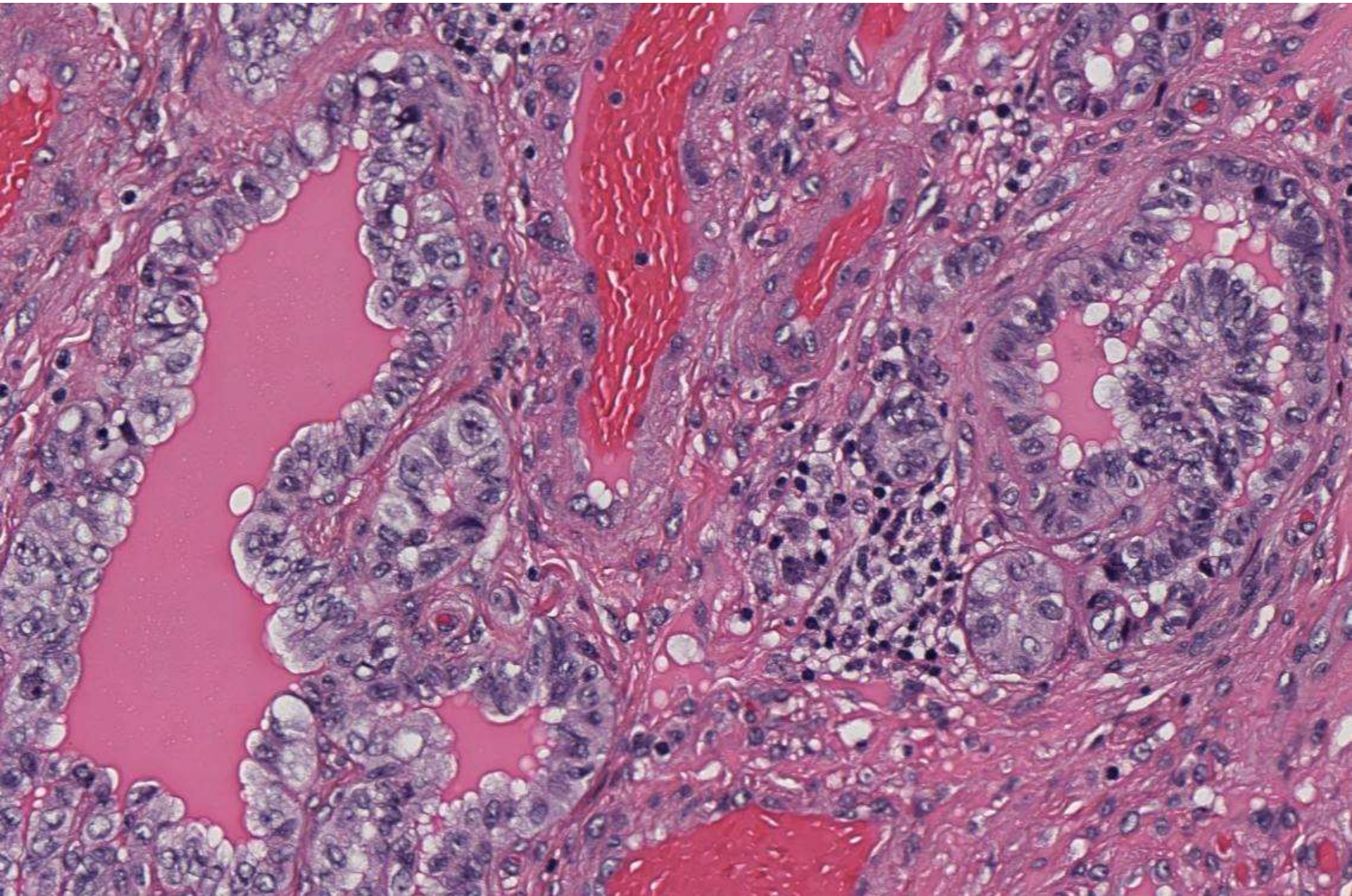


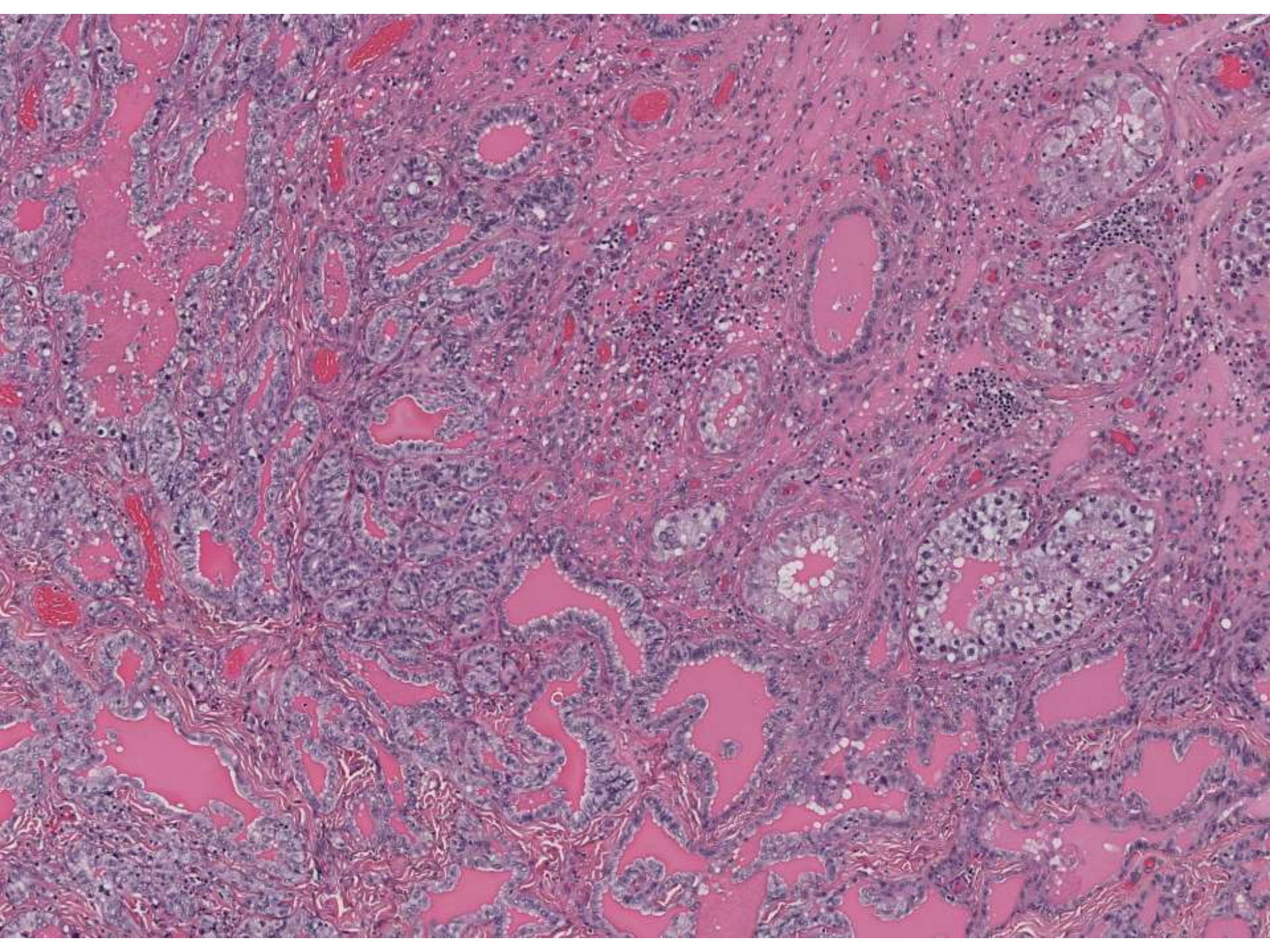


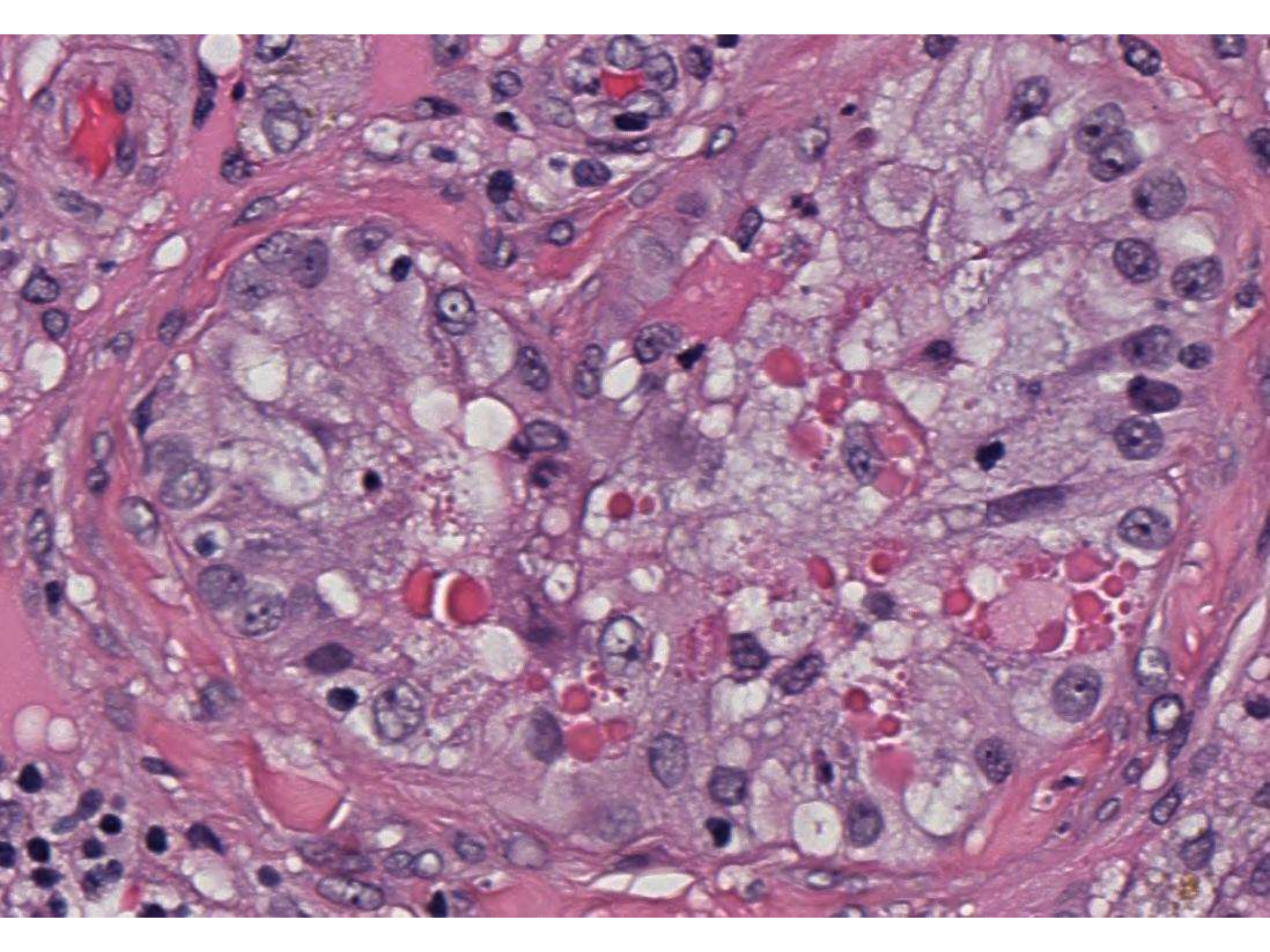


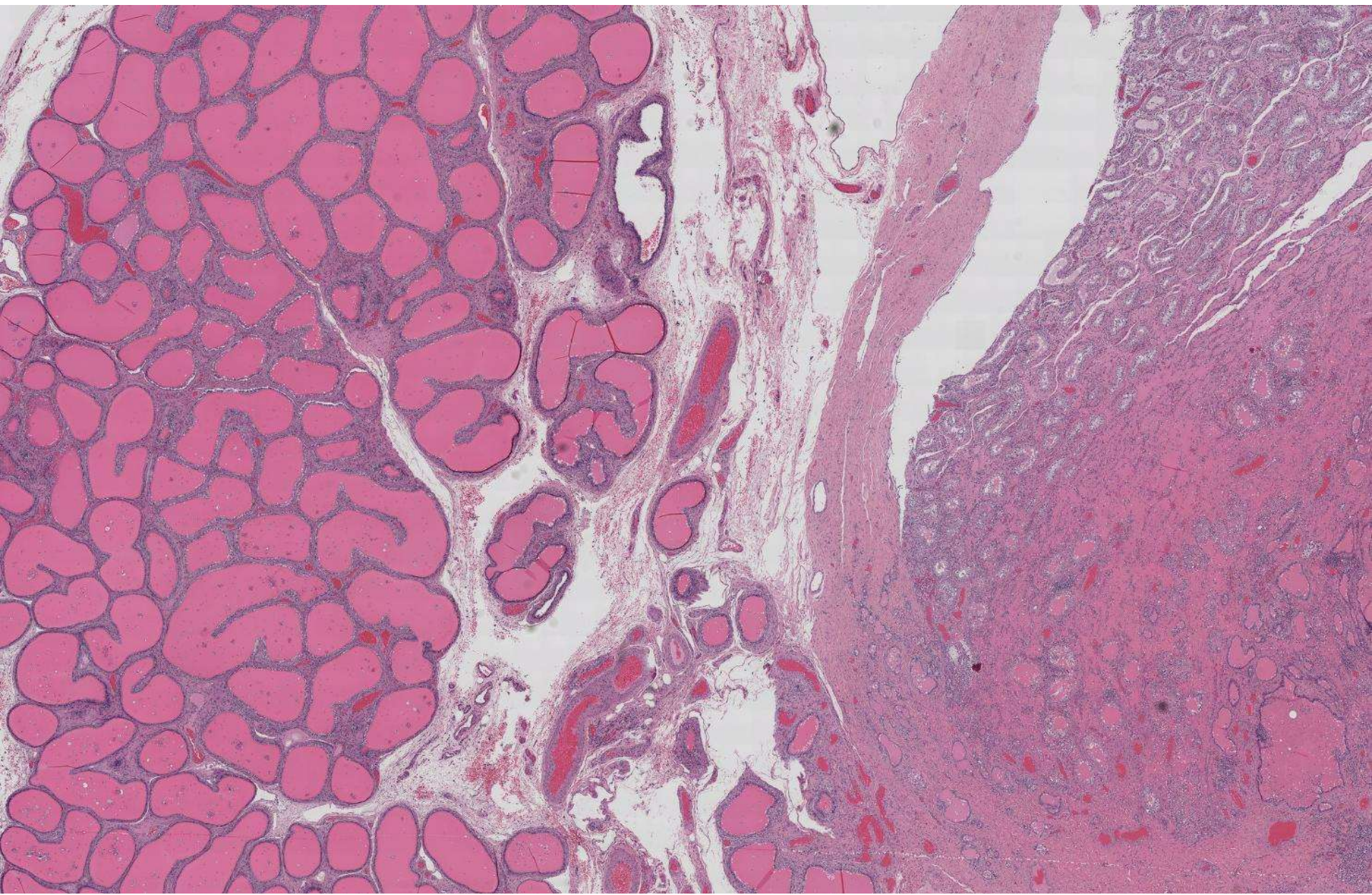


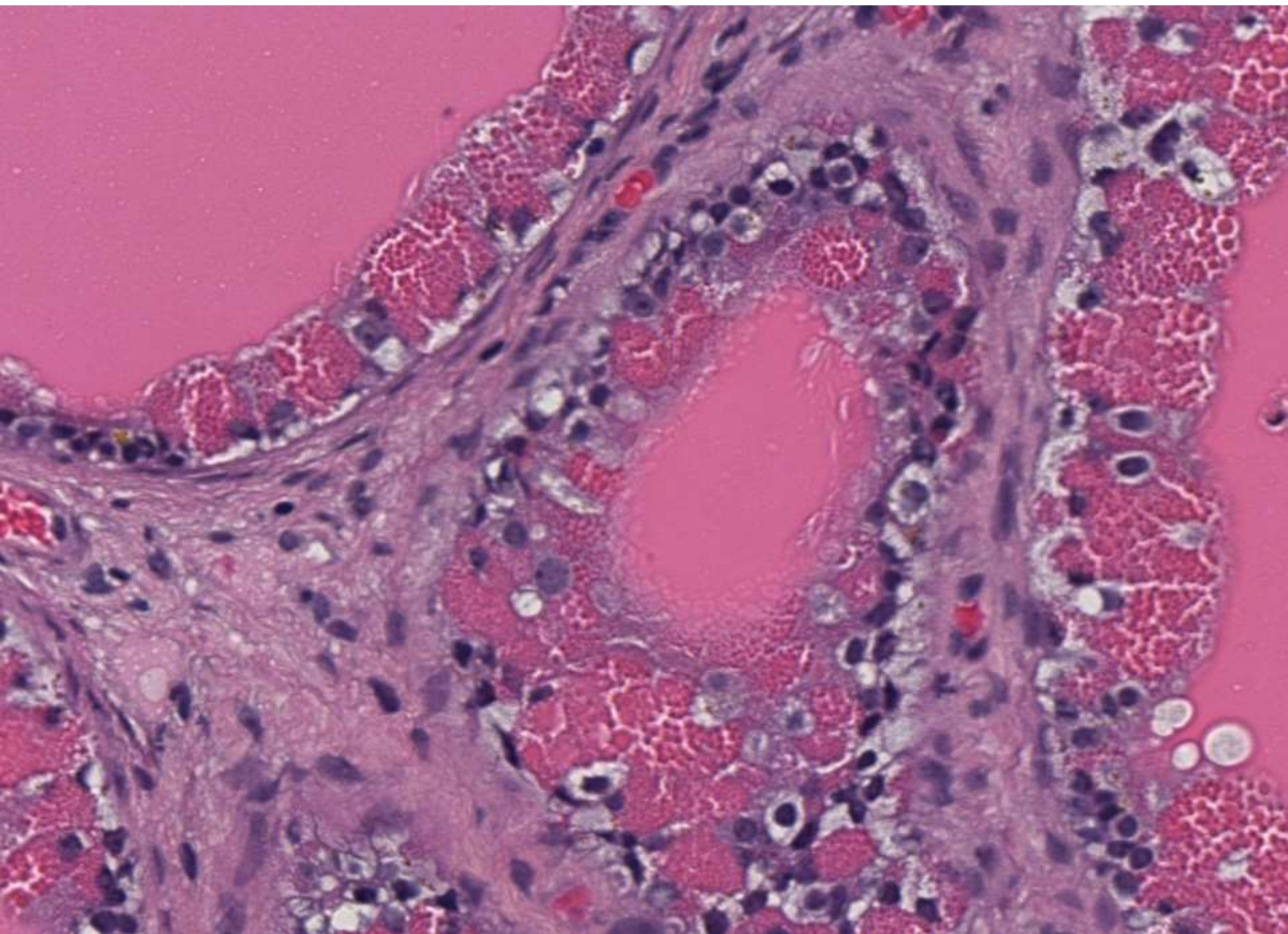


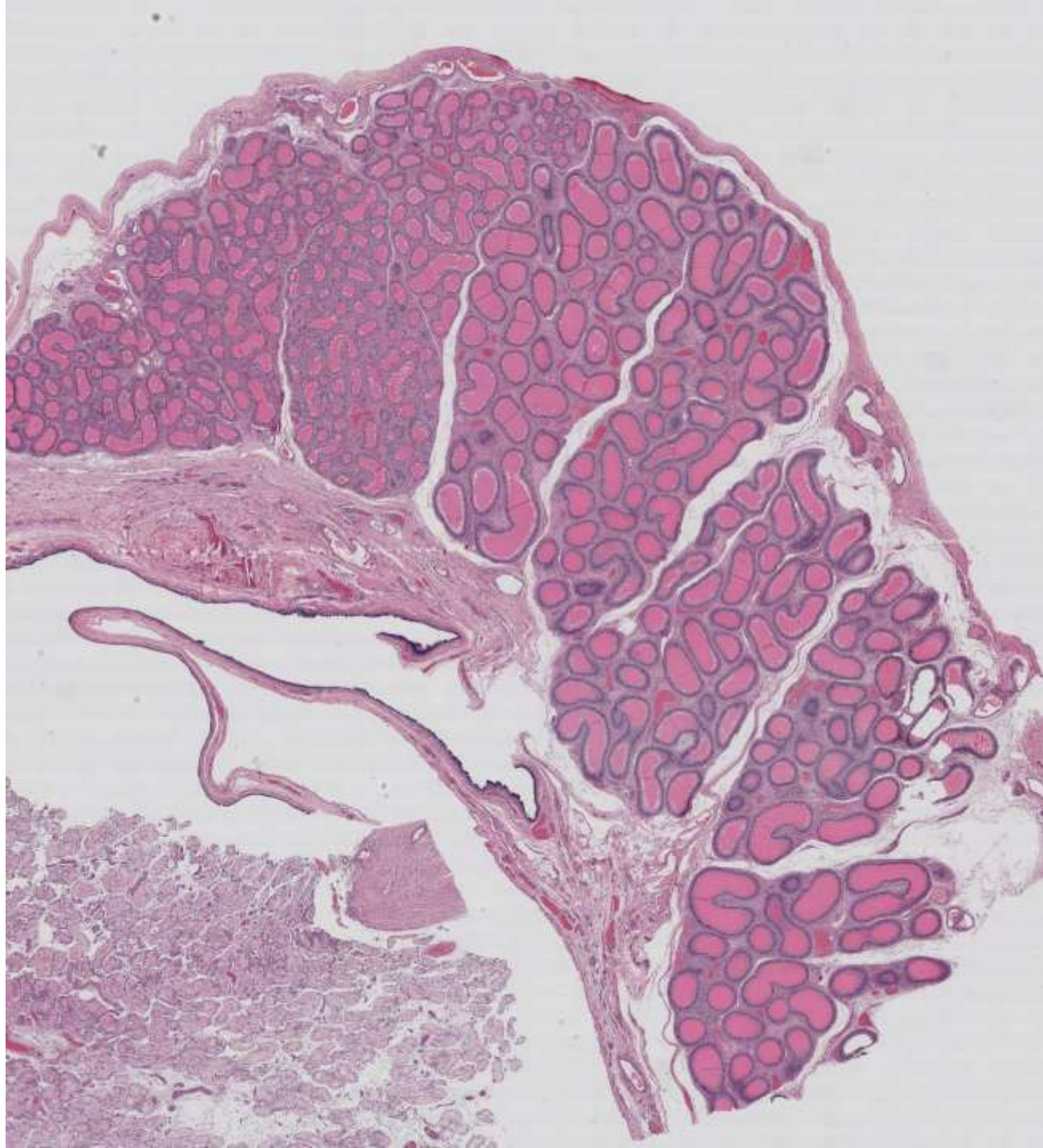


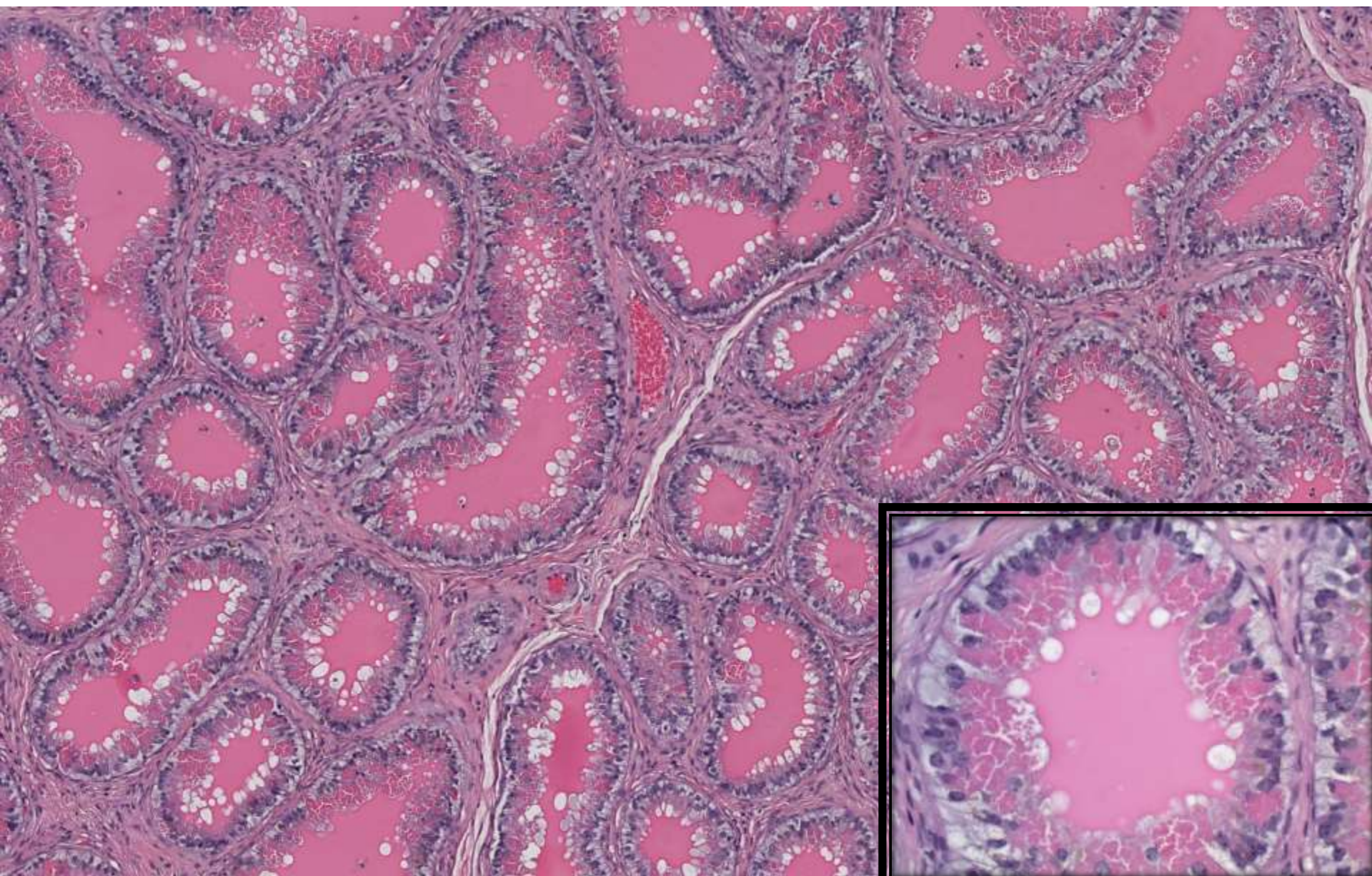






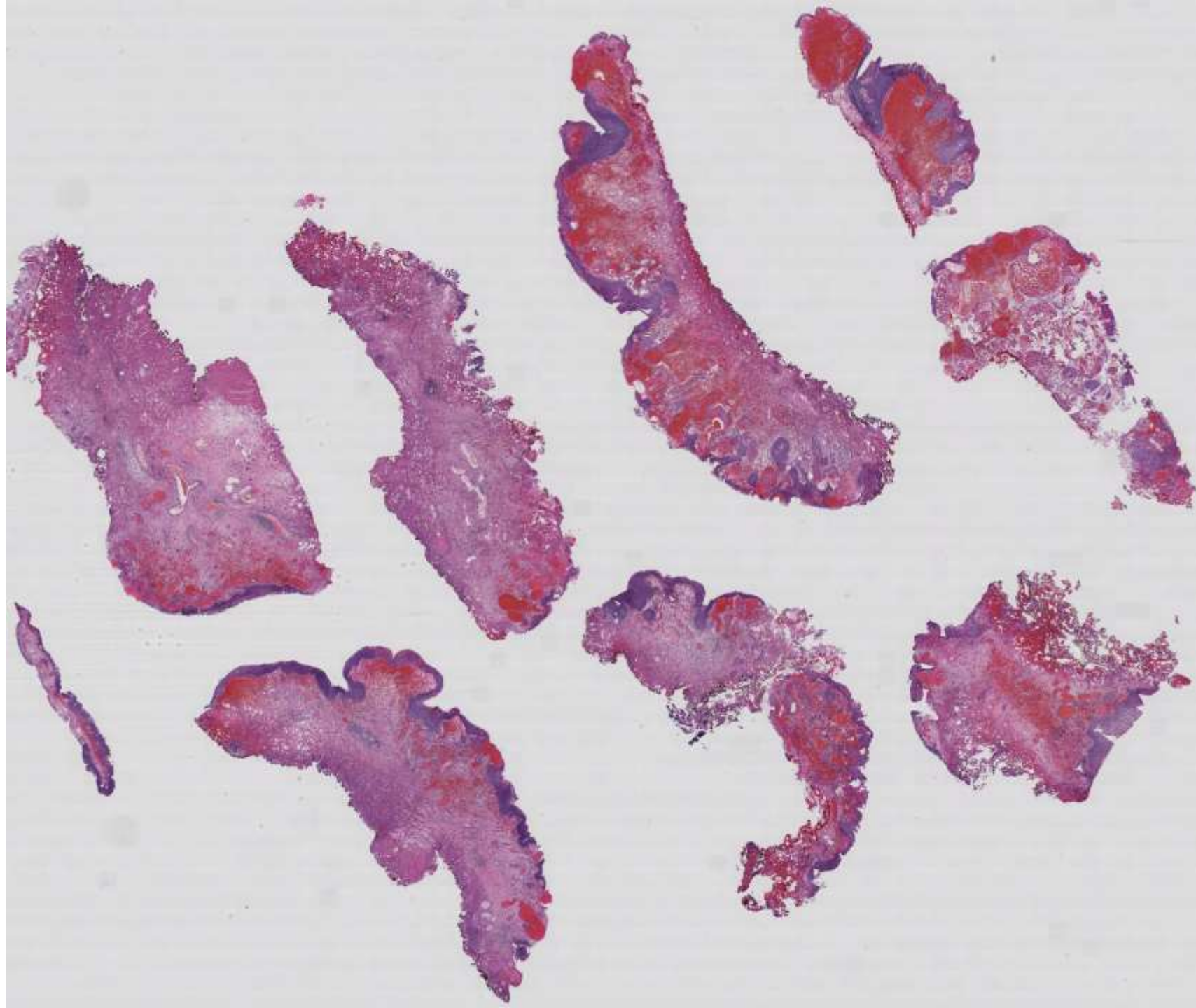


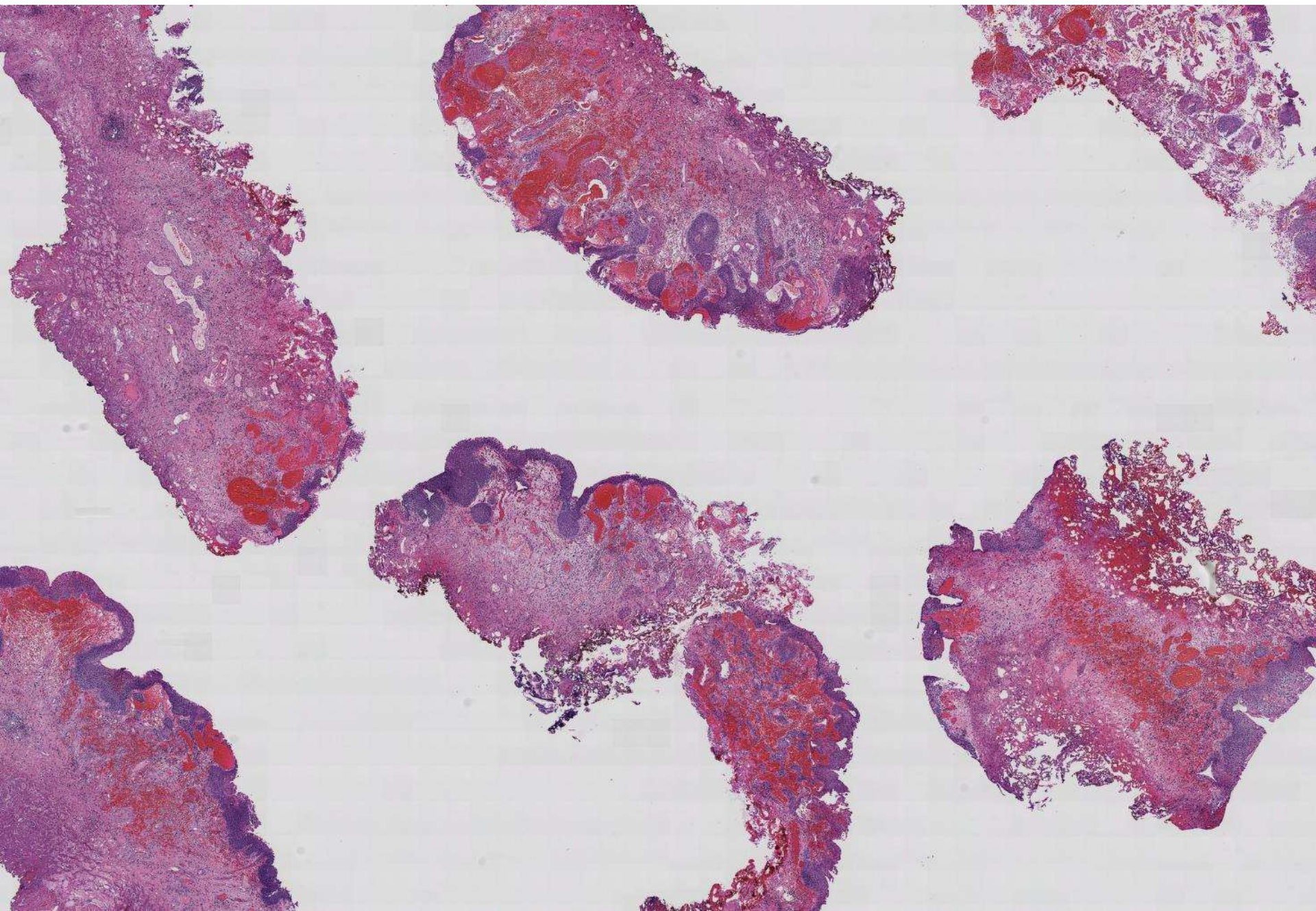


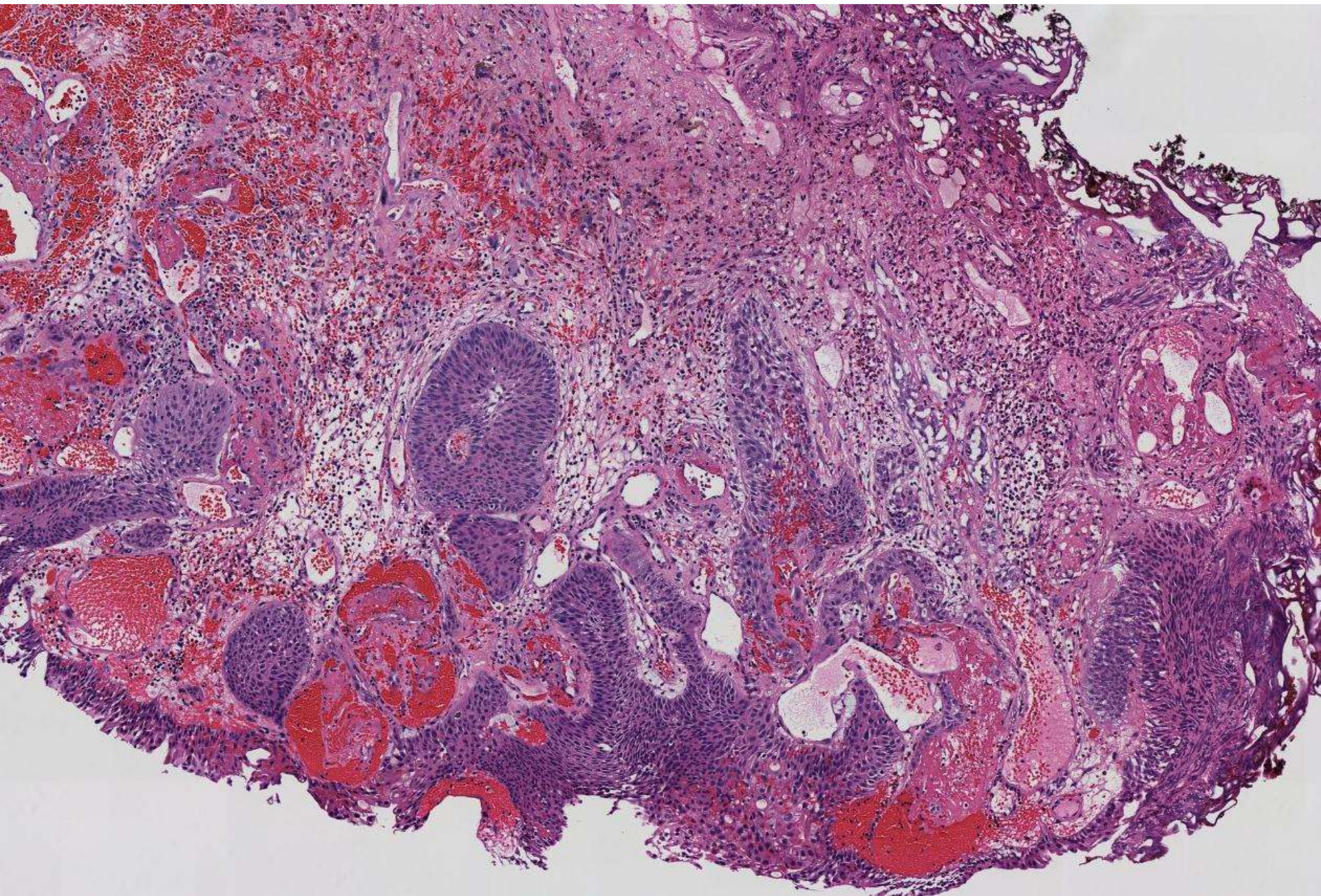


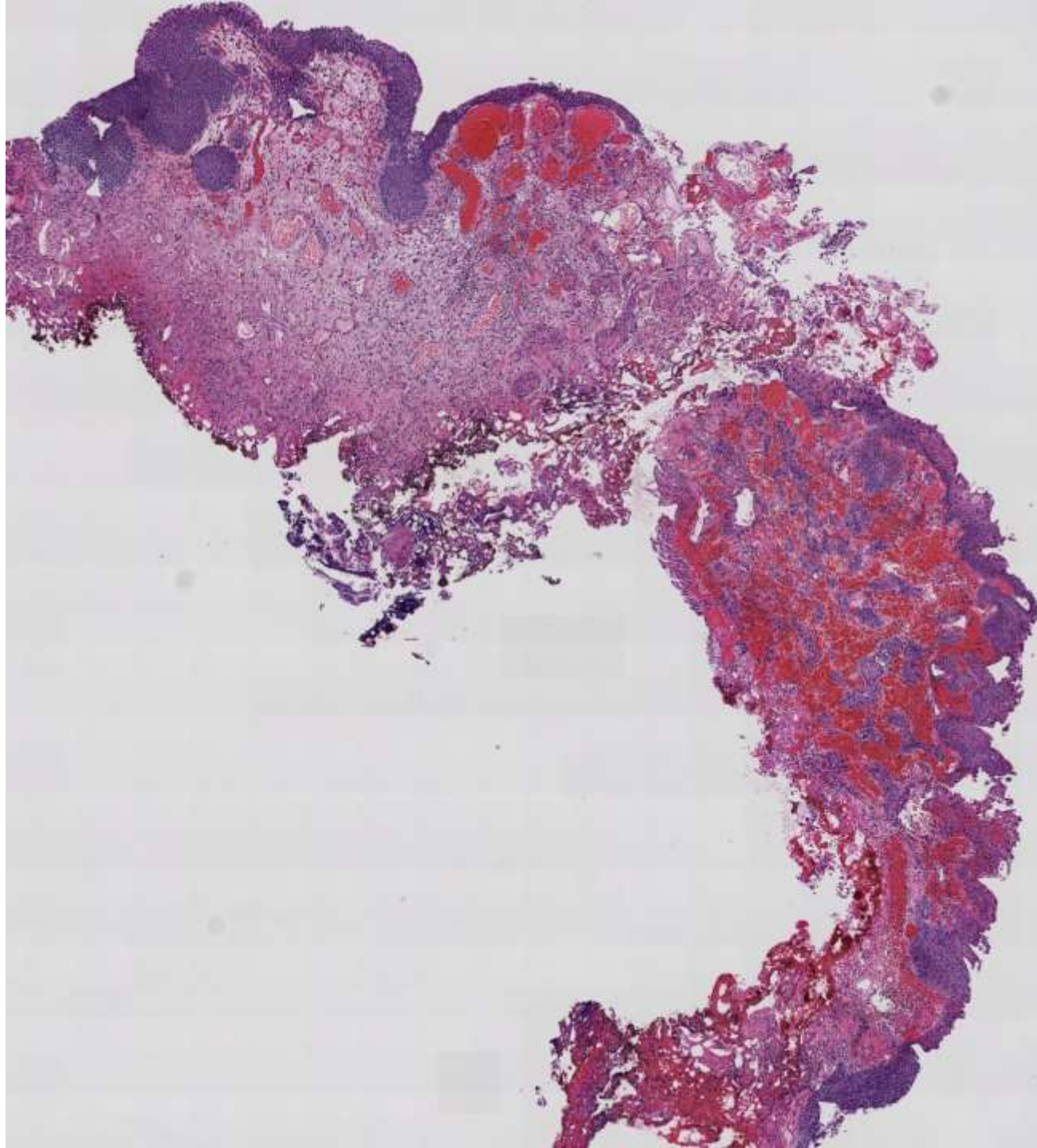
SB 6127
(scanned slide available)

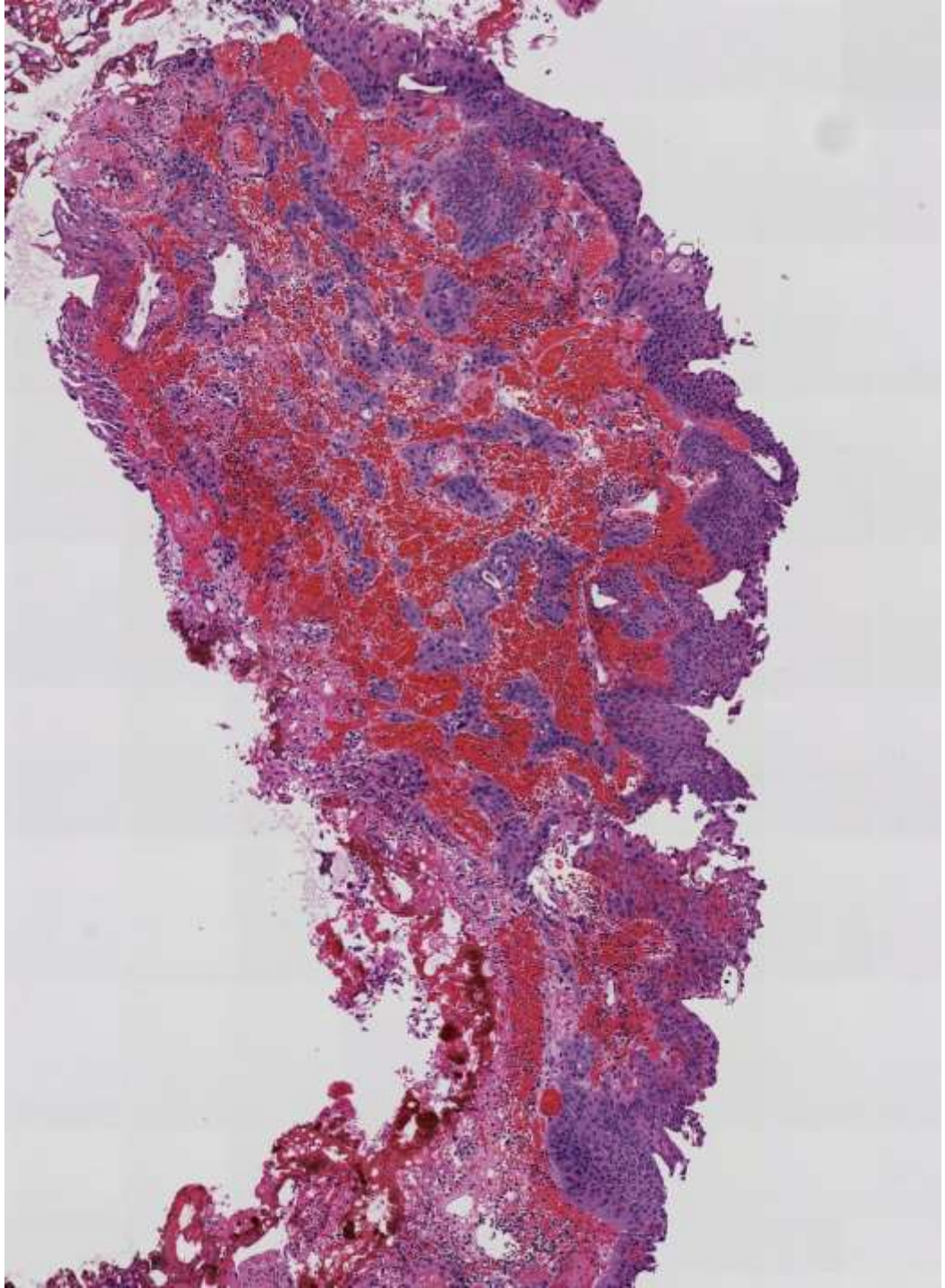
Ankur Sangoi; El Camino Hospital
72-year-old male with bladder lesion
biopsy.

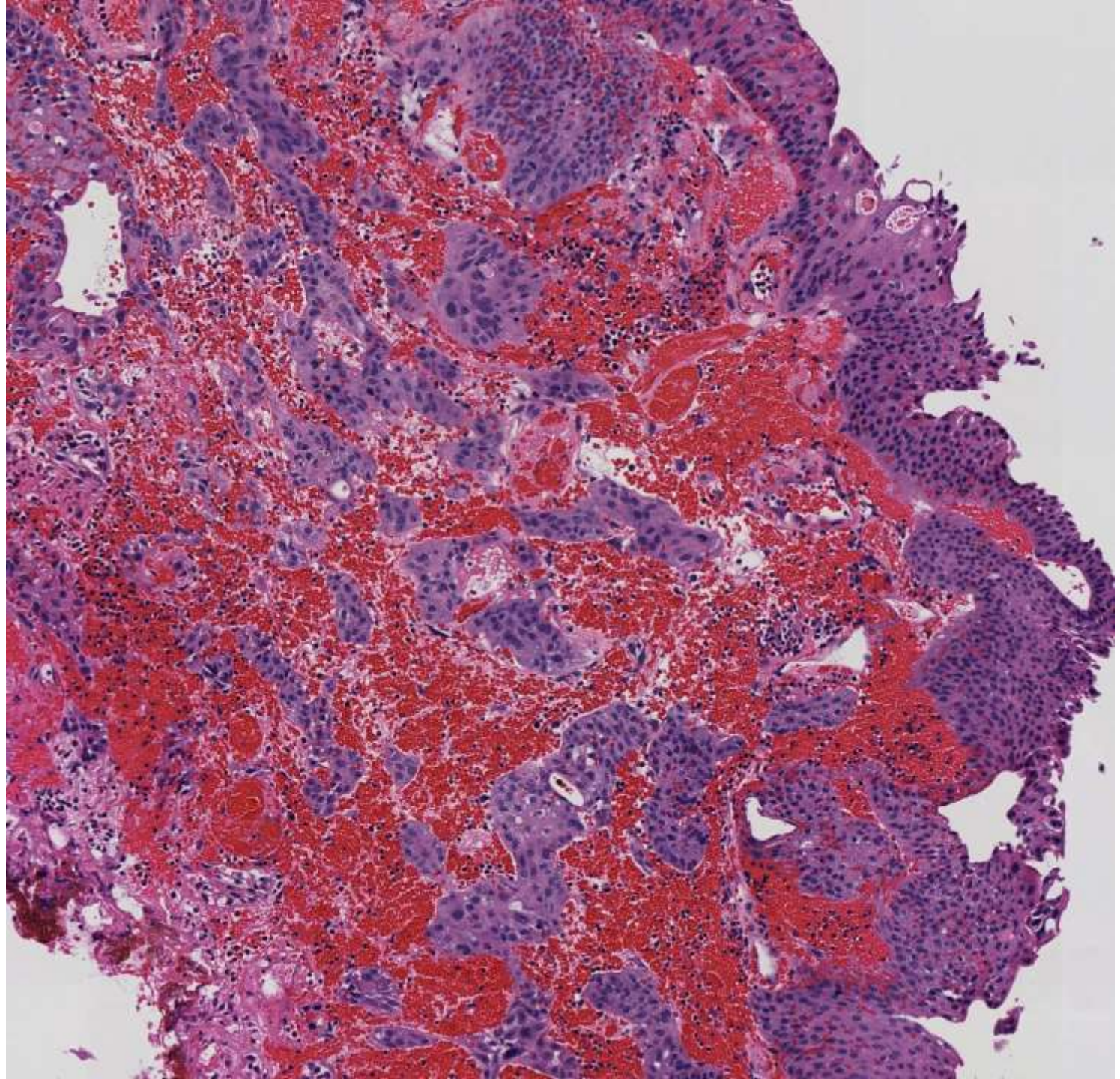


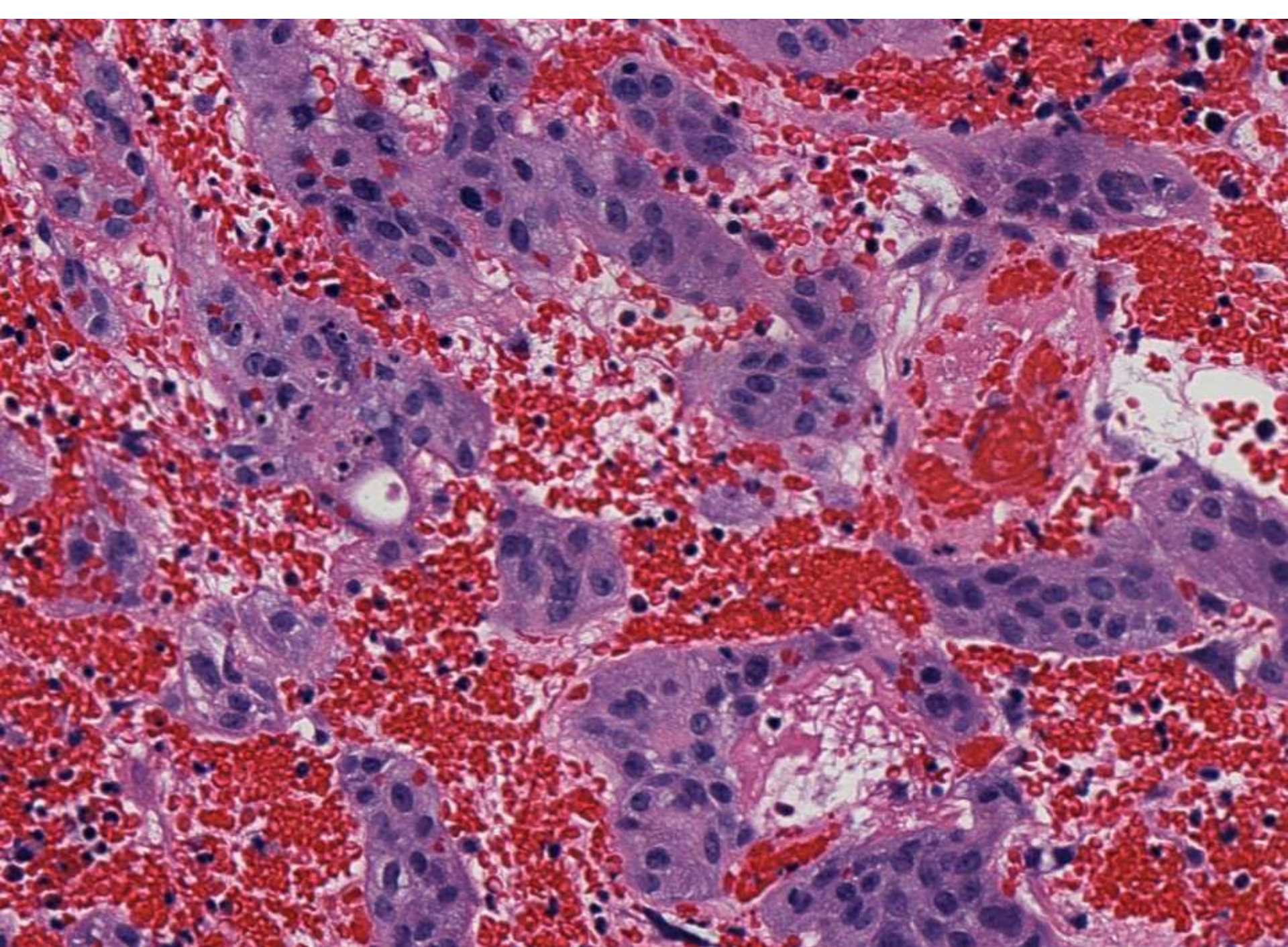


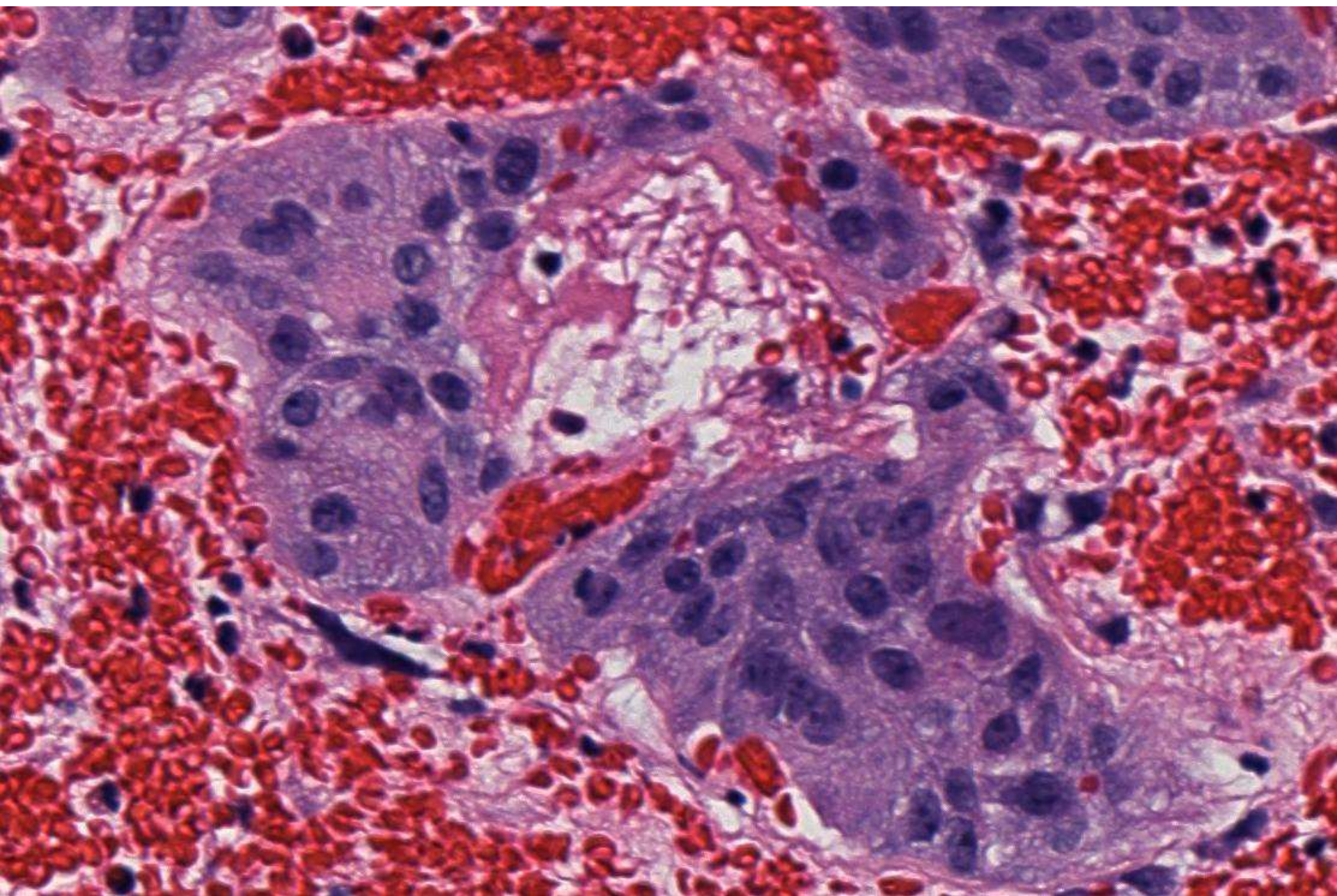


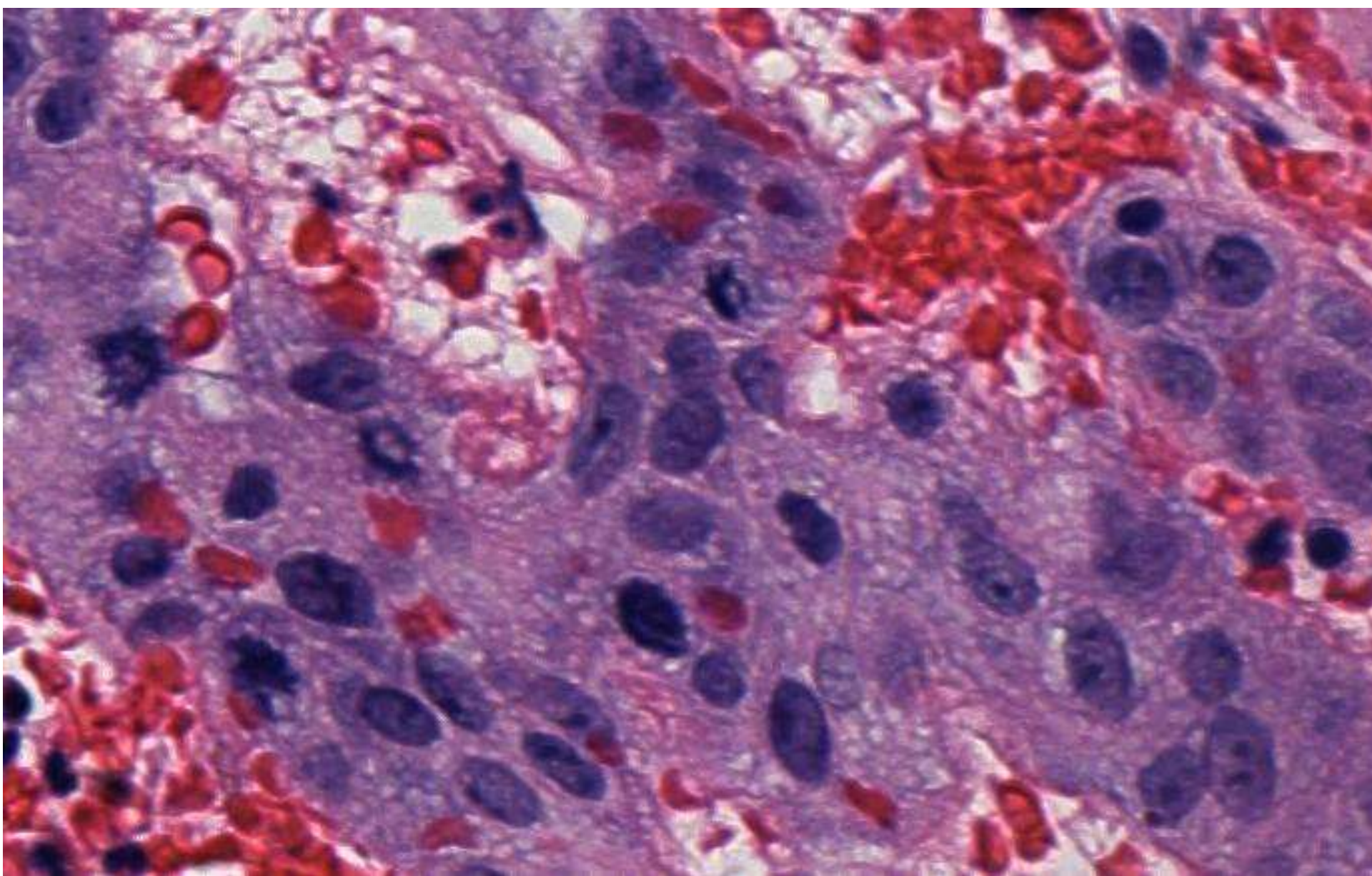










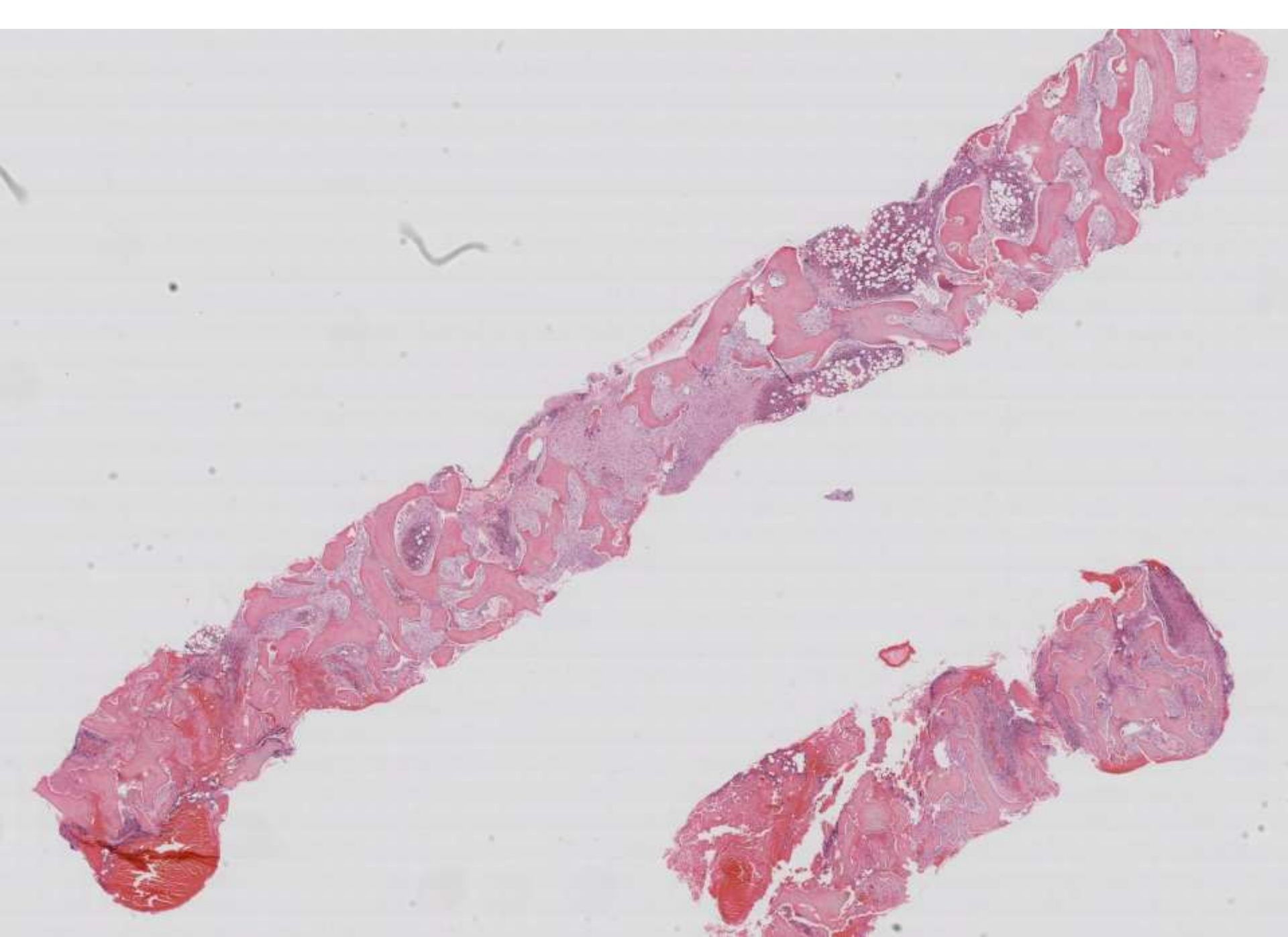


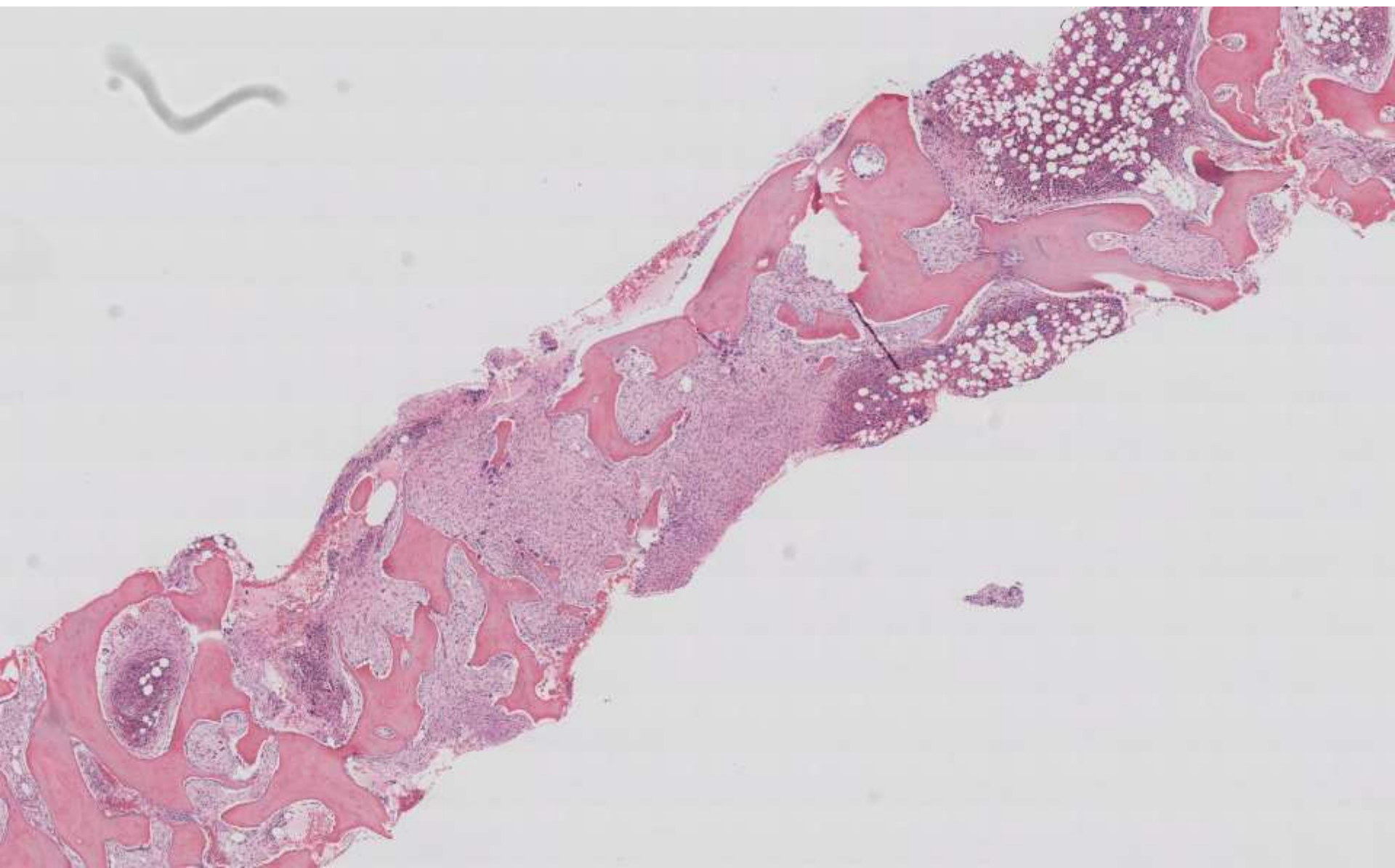
SB 6128

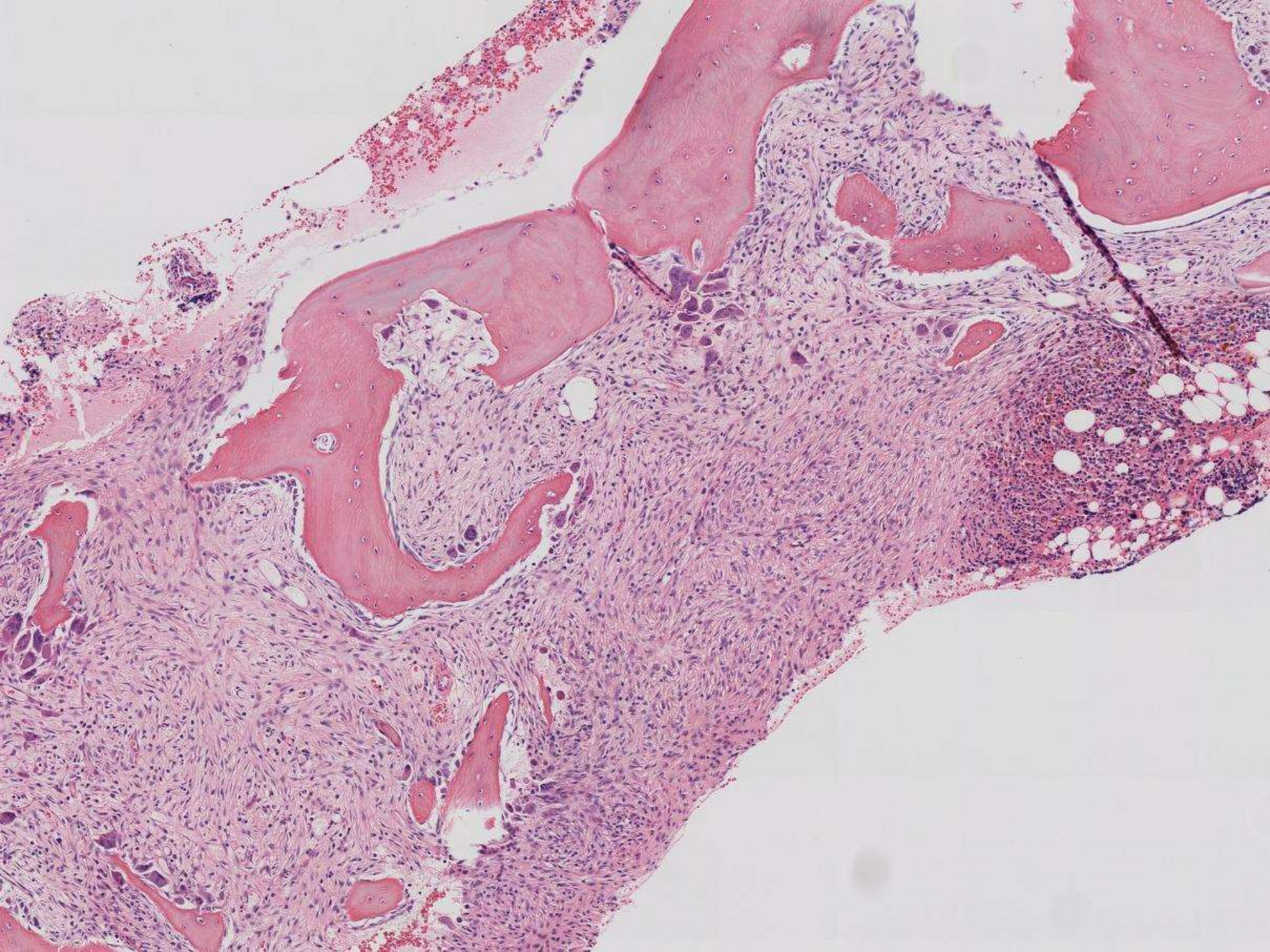
(scanned slide available)

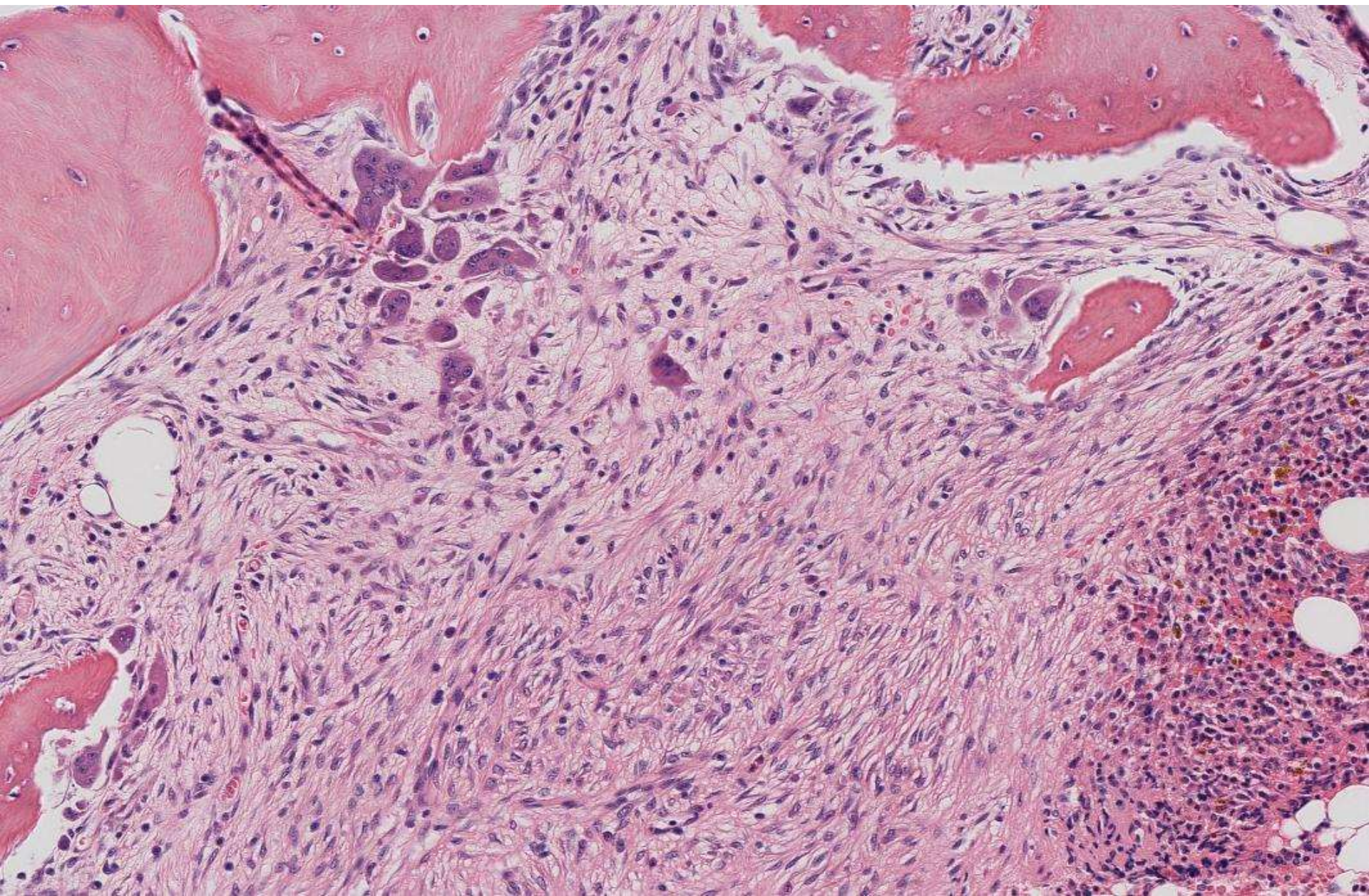
Jenny Hoffman/Dean Fong; Stanford/Palo Alto VA

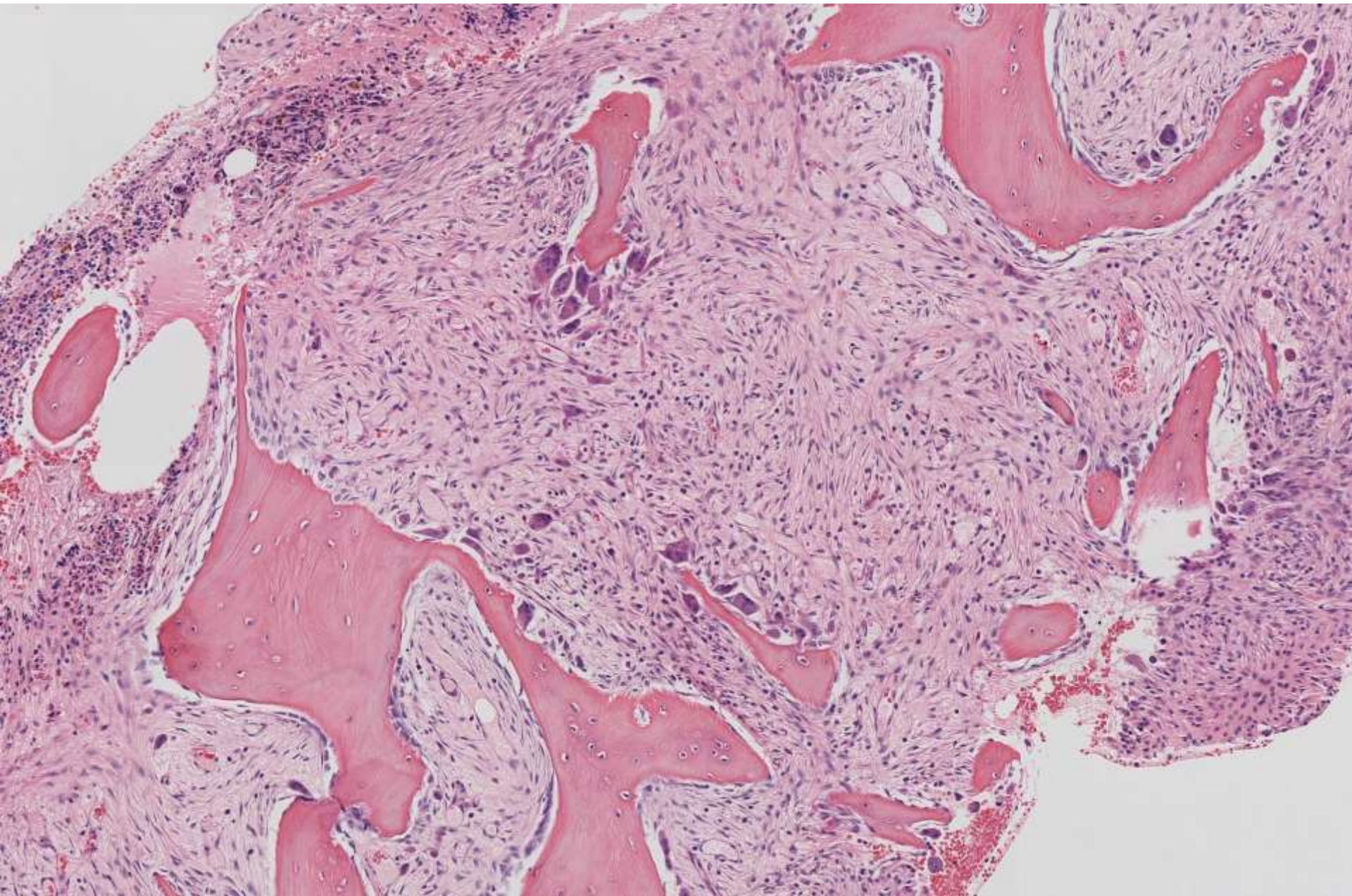
28-year-old man with history of acute pancreatitis, ESRD on HD, and severe pancytopenia. Family history significant for benign familial neutropenia. Bone marrow biopsy performed.

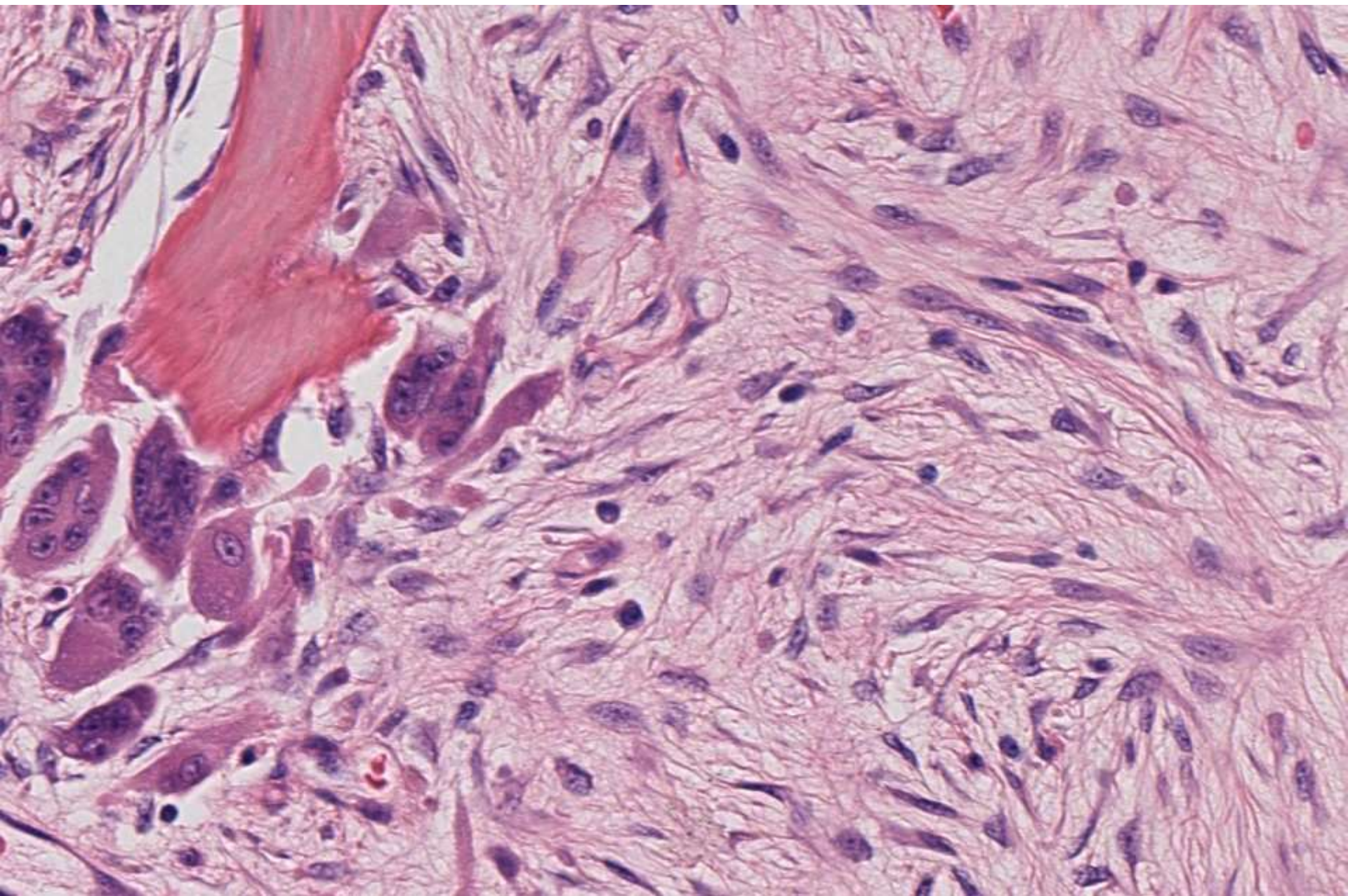


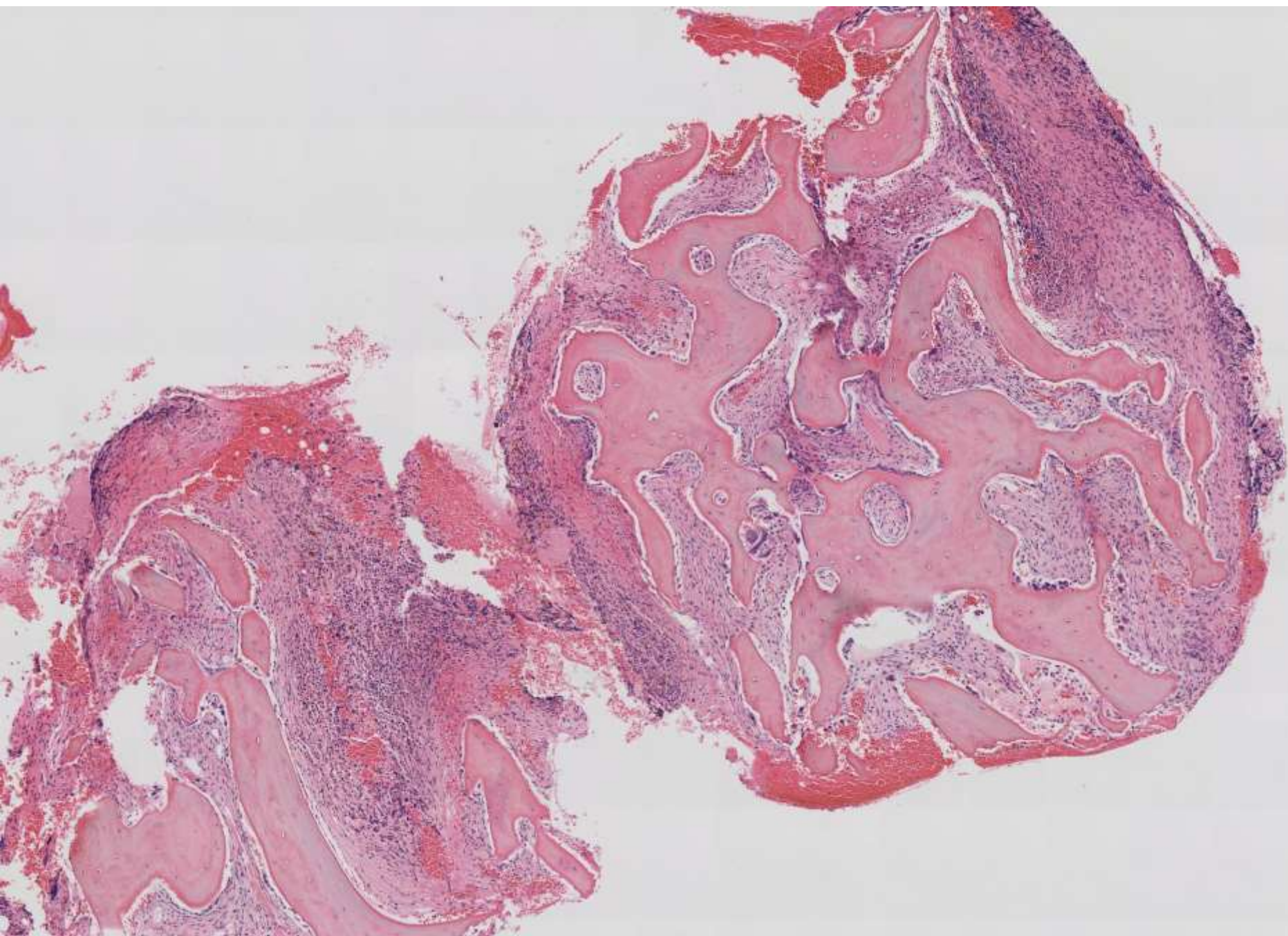


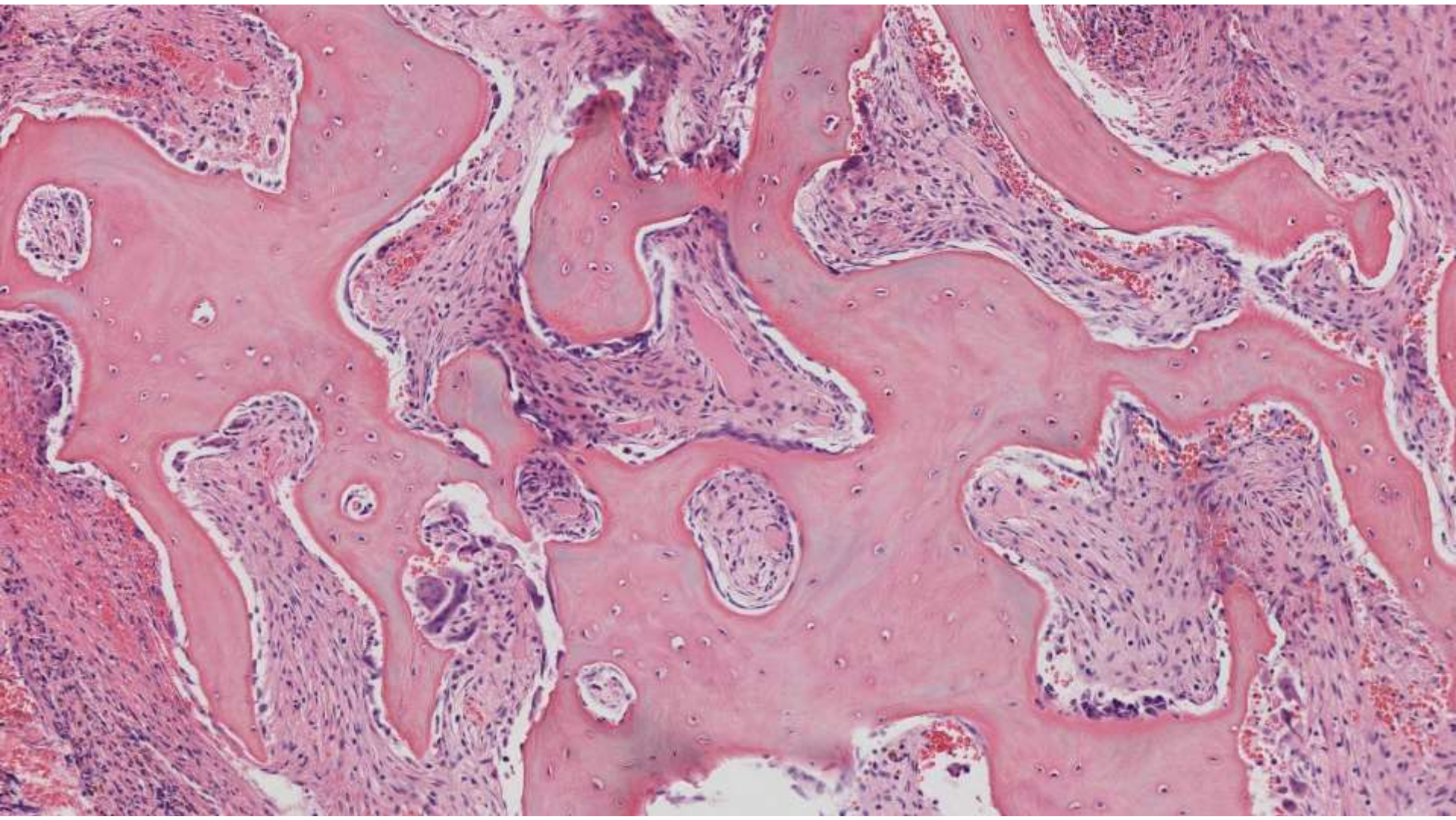








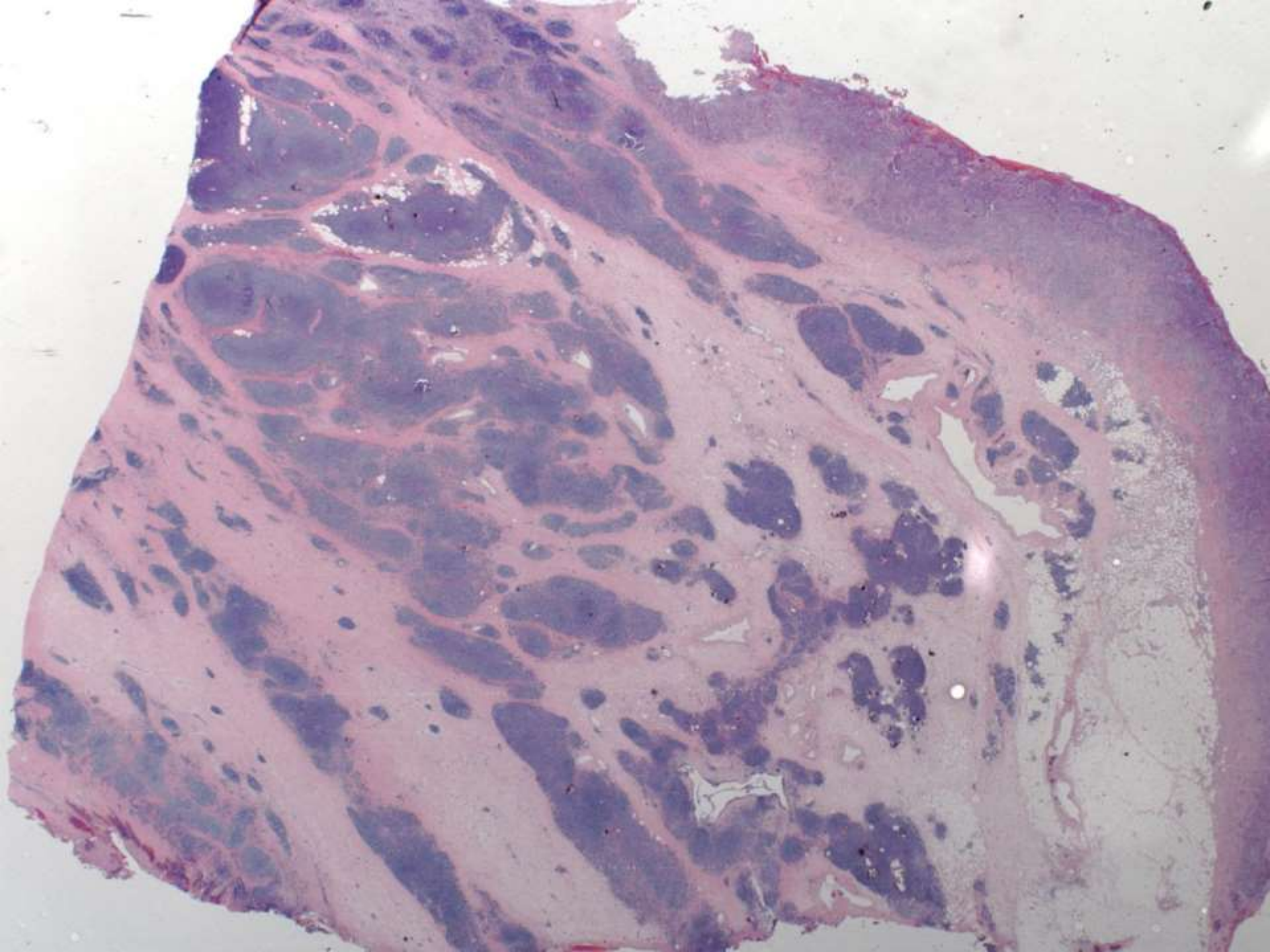


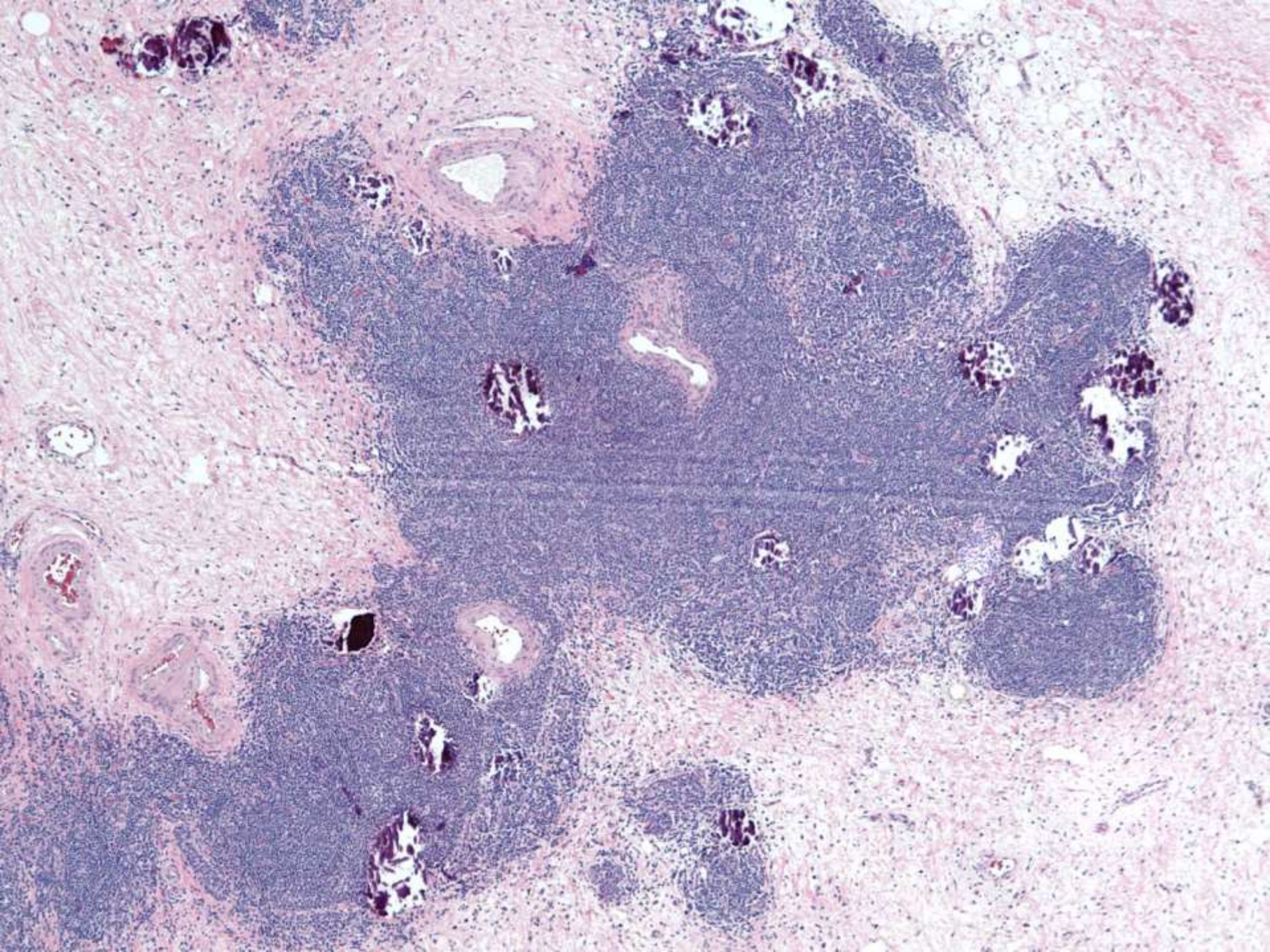


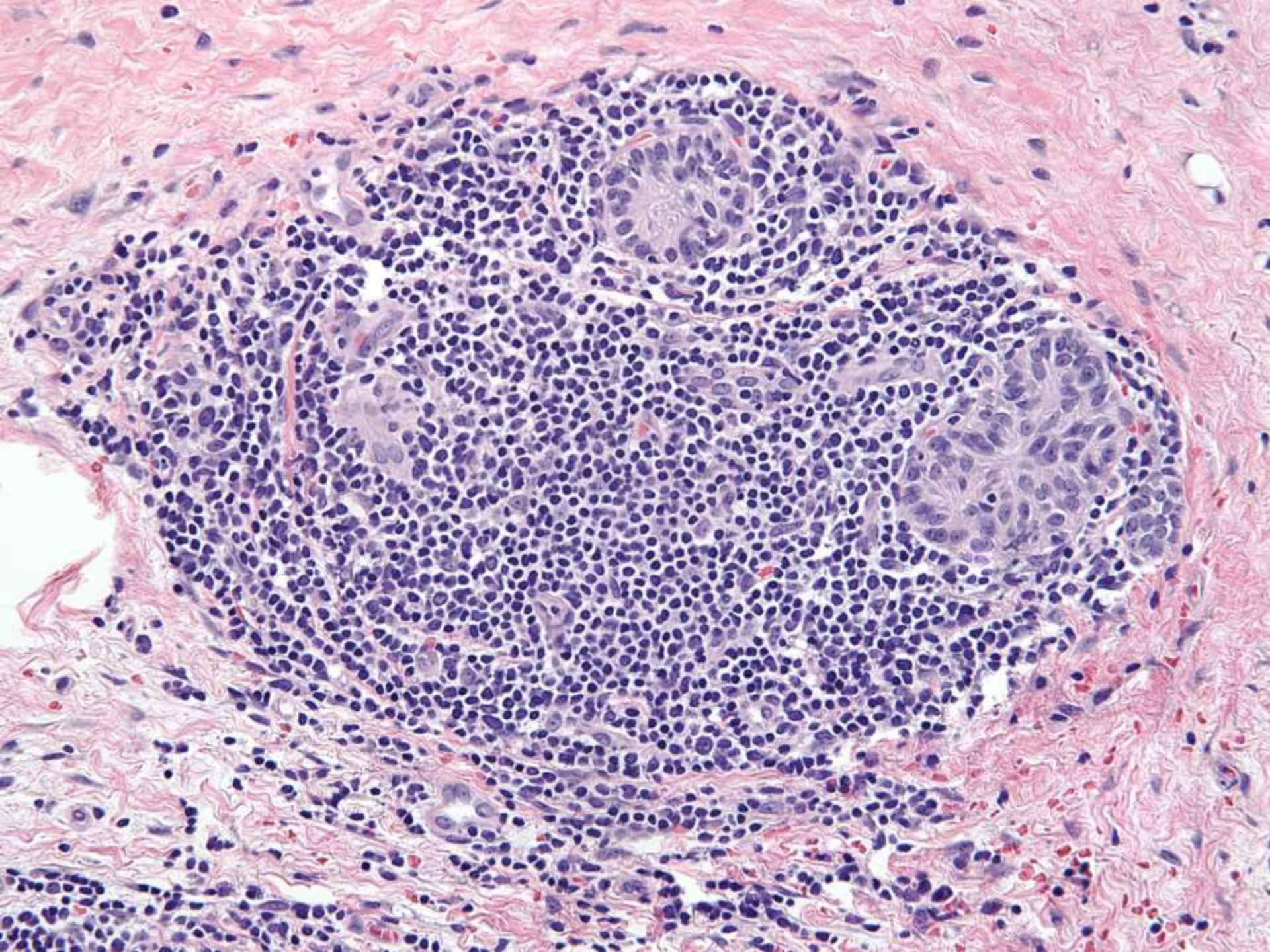
SB 6129

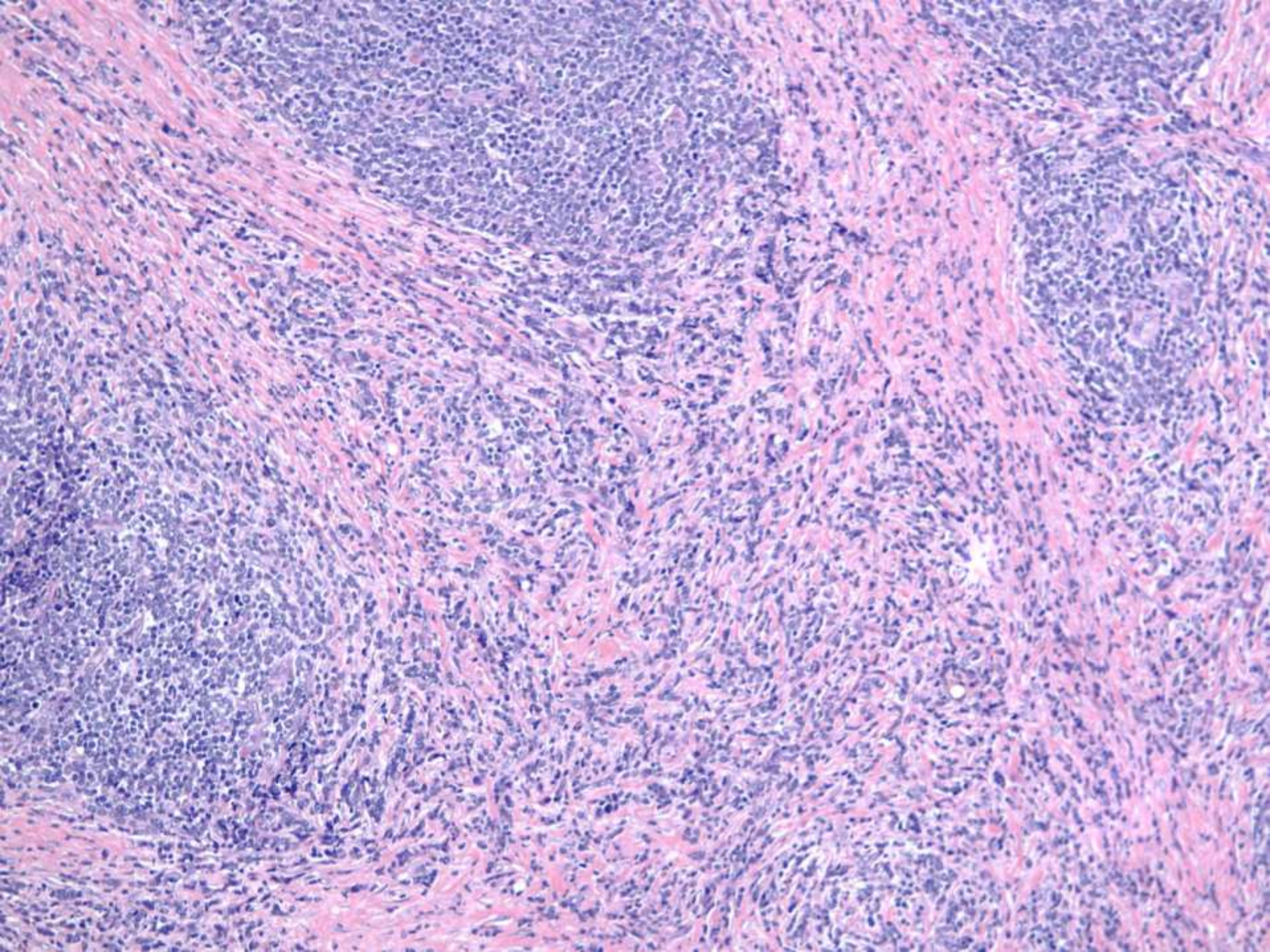
**Jenny Hoffman/Richard Sibley/Robert
Rouse/Robert Ohgami; Stanford**

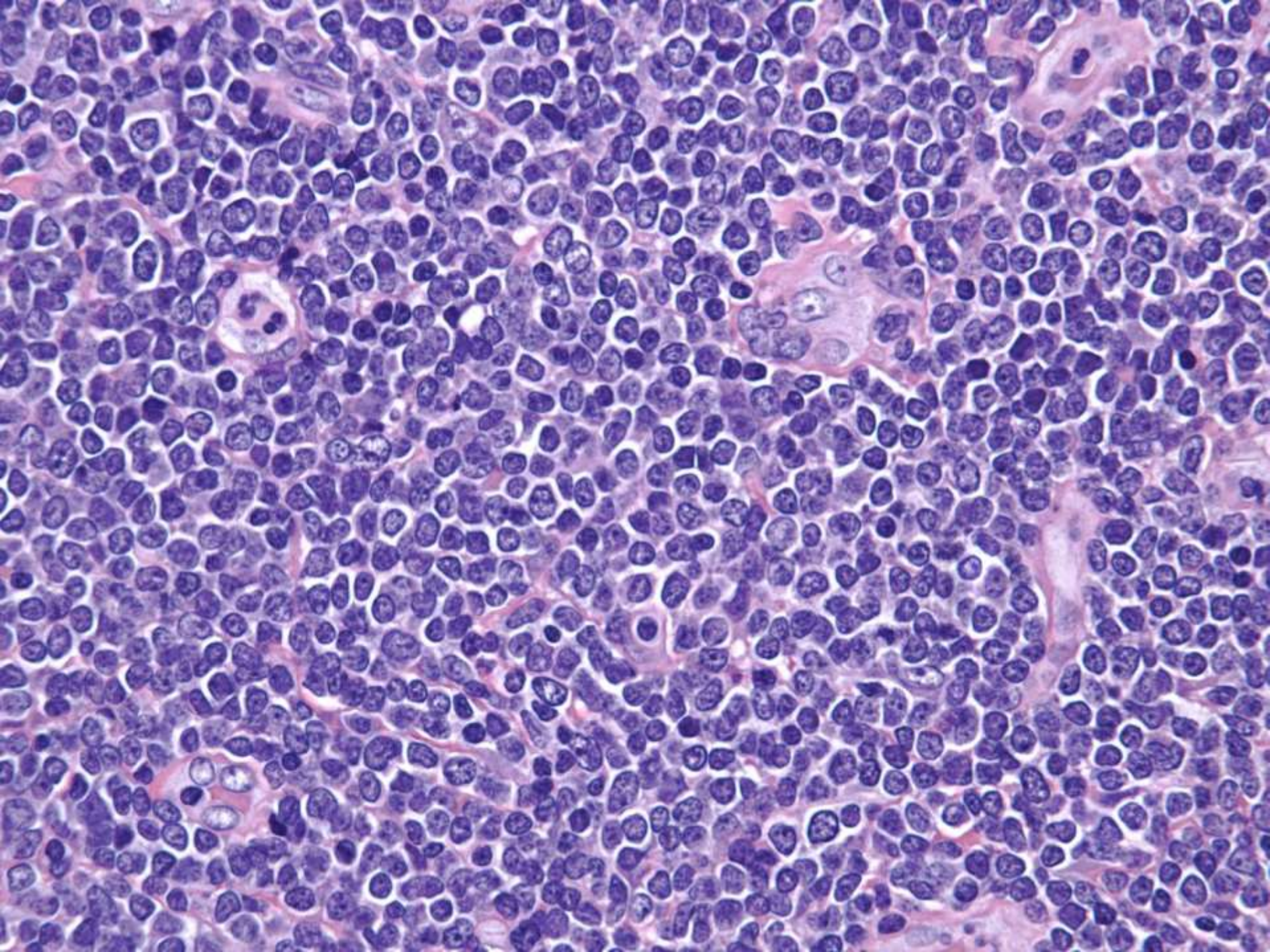
67-year-old man with mediastinal mass
invading into pleural space.





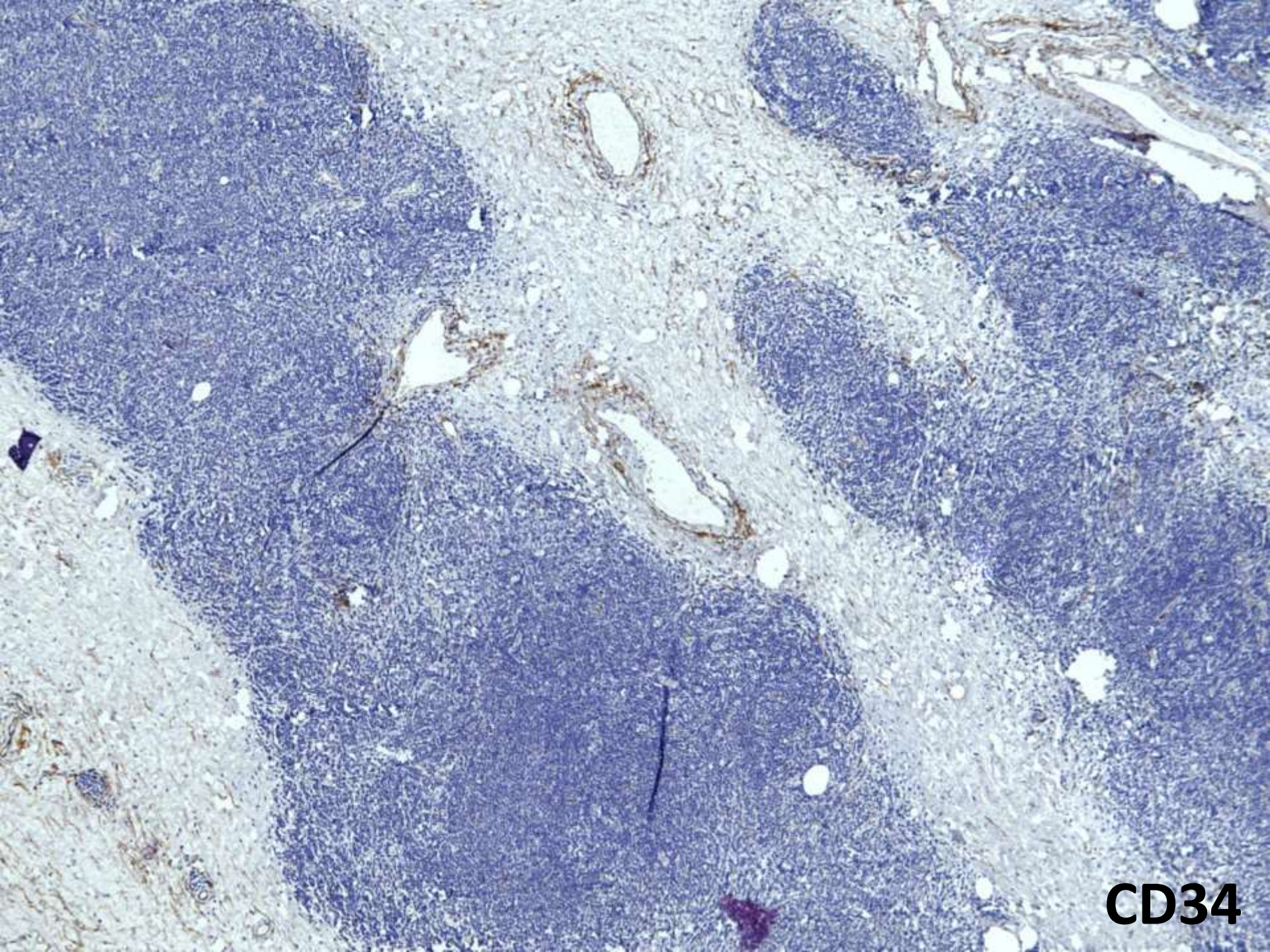




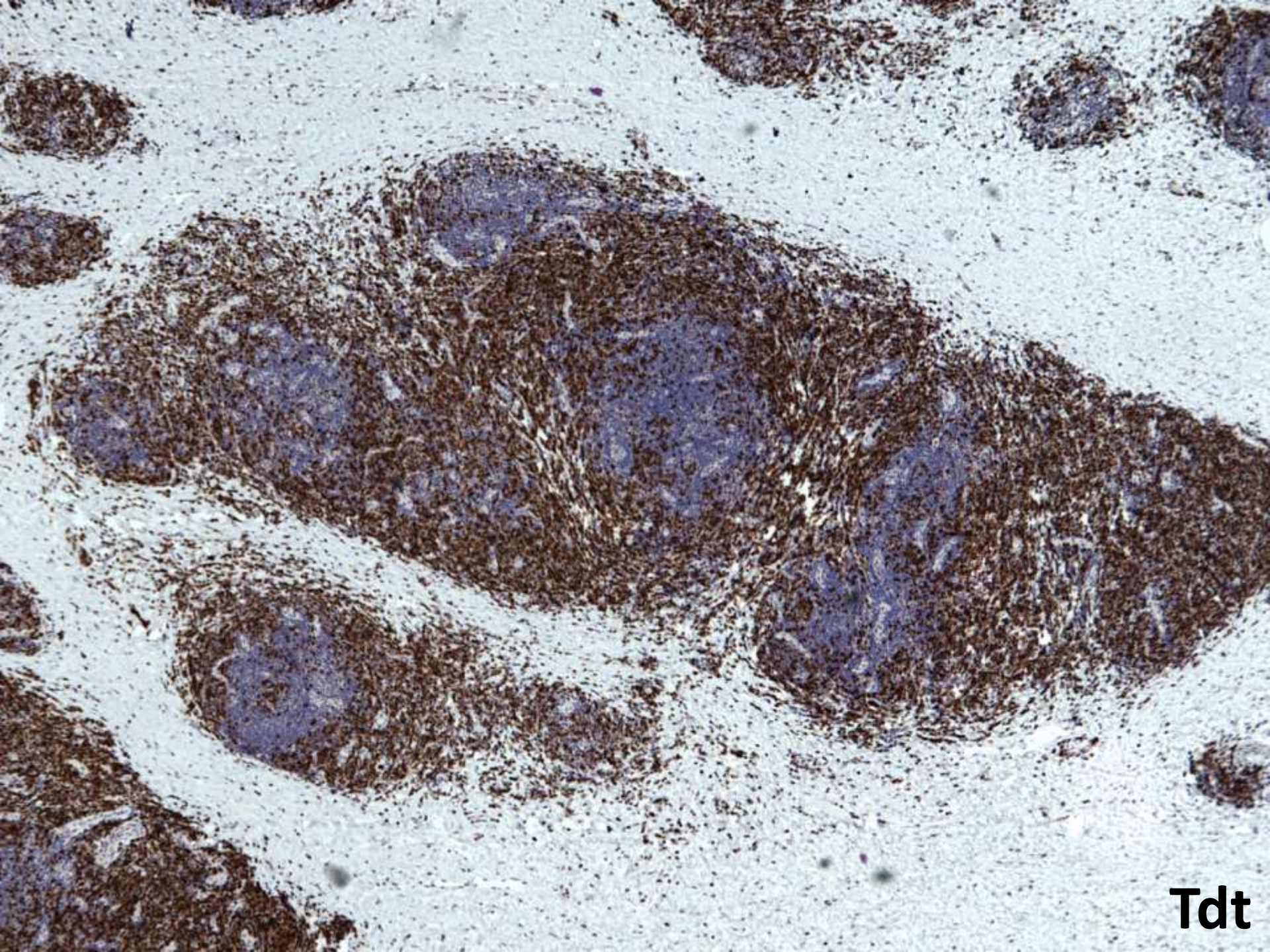




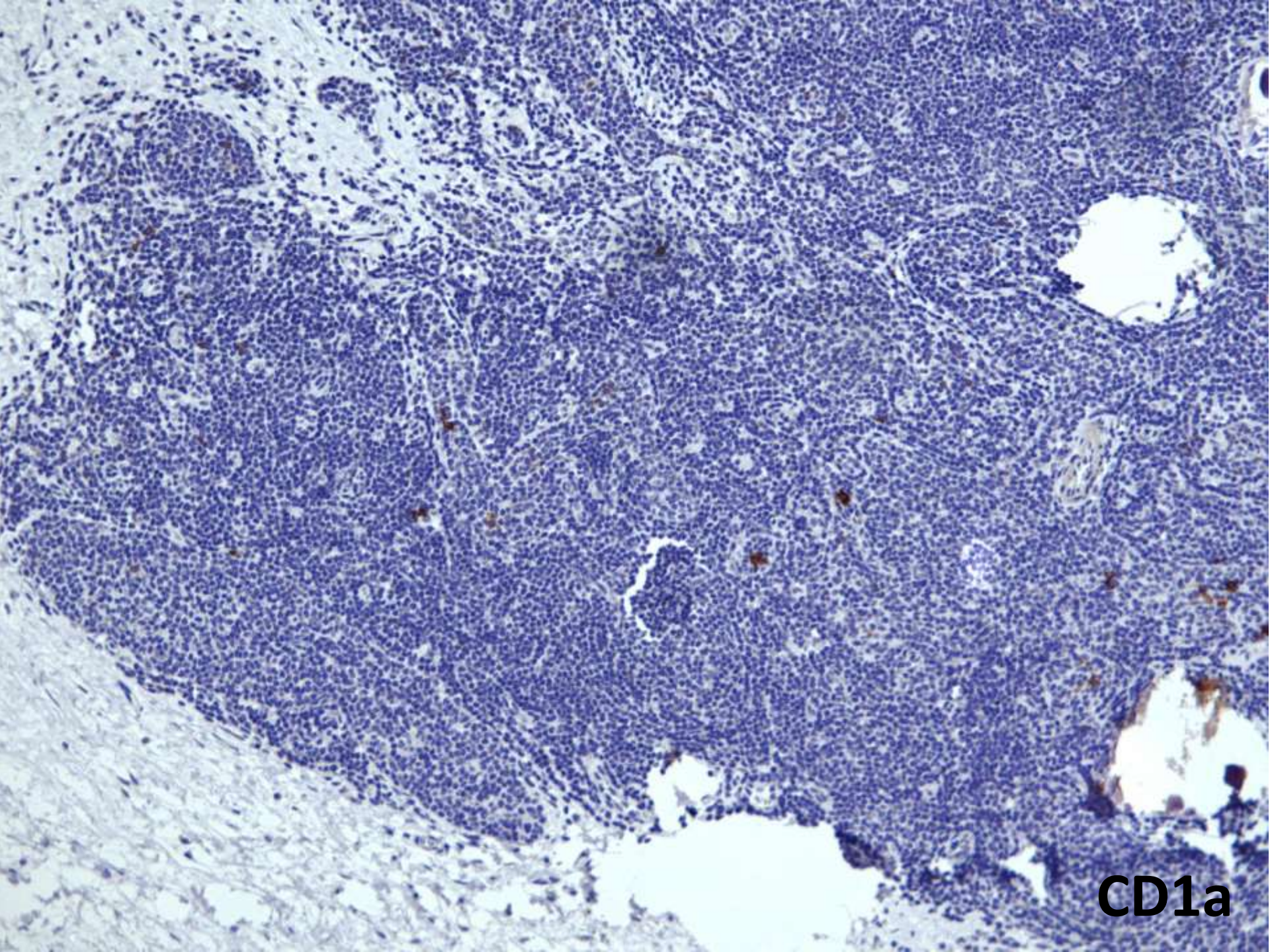
CK 5/6



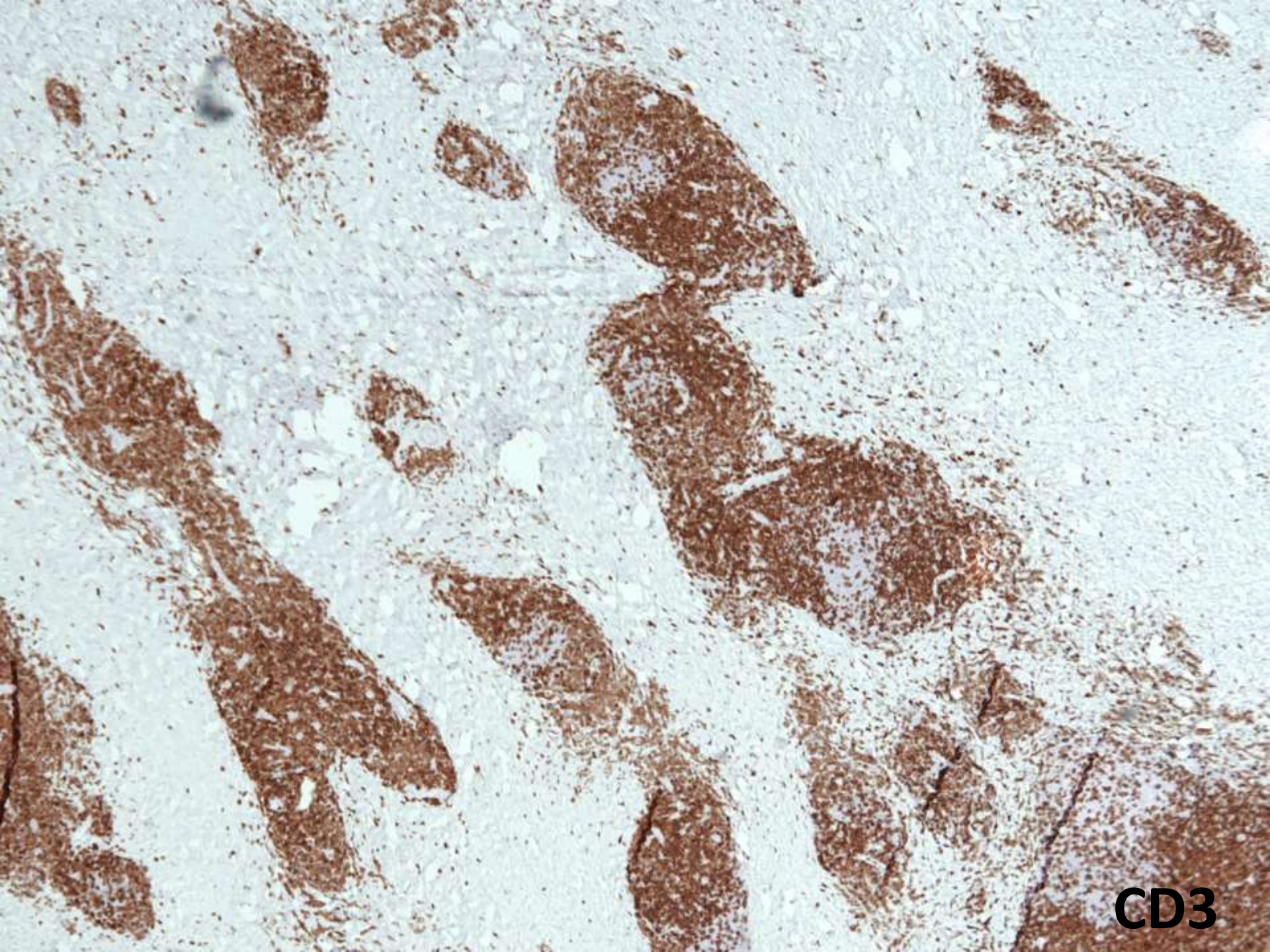
CD34



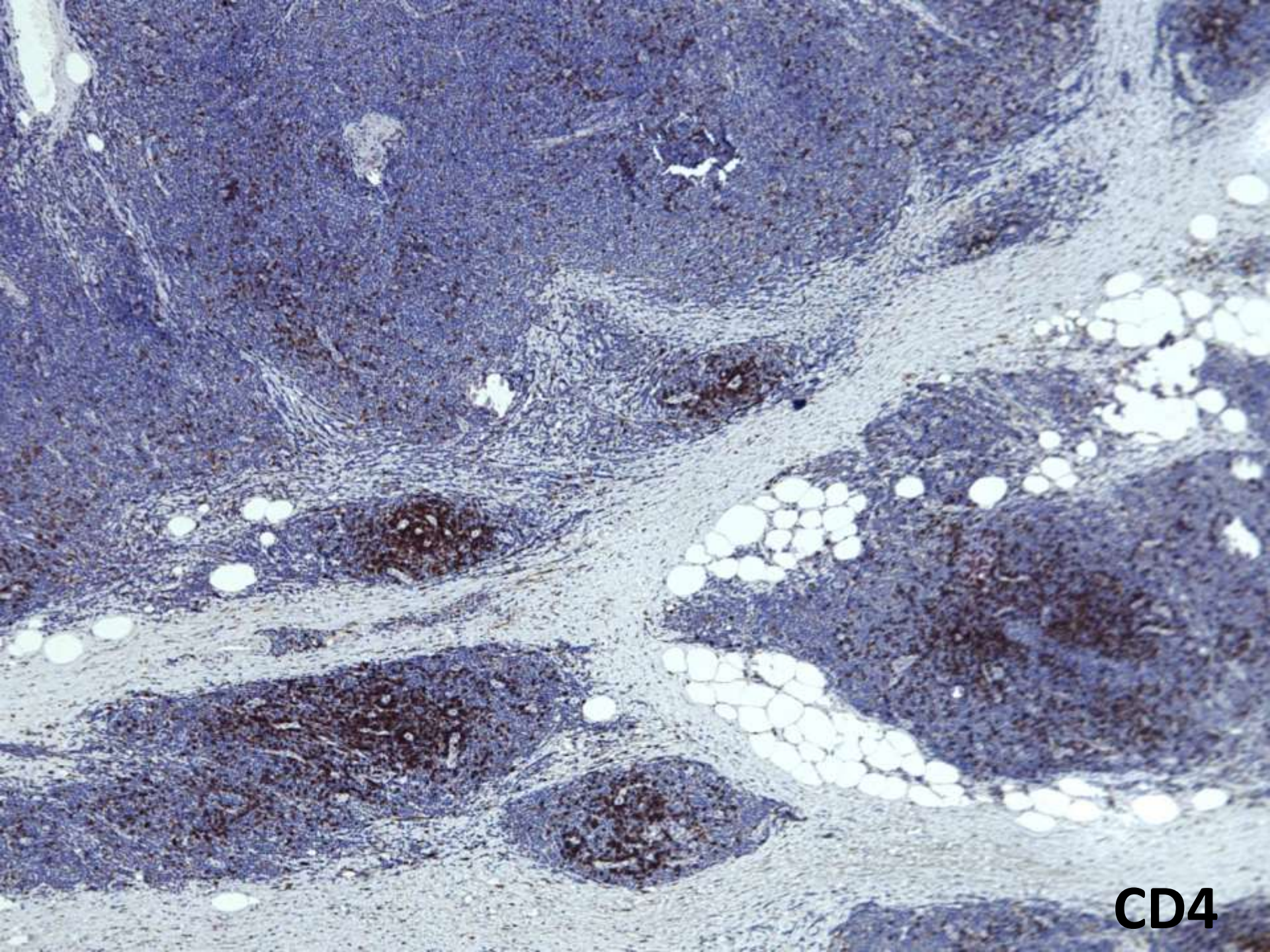
Tdt



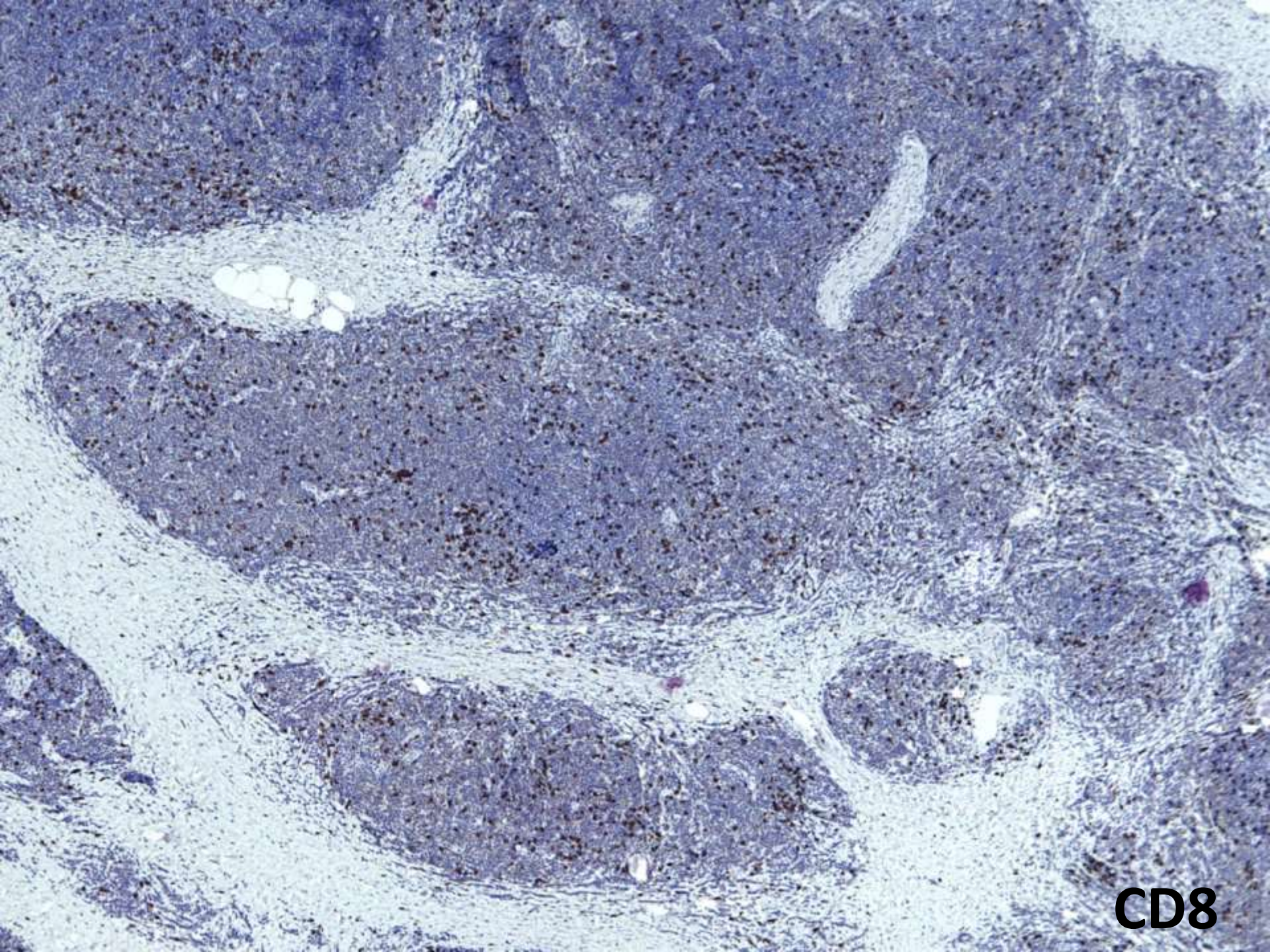
CD1a



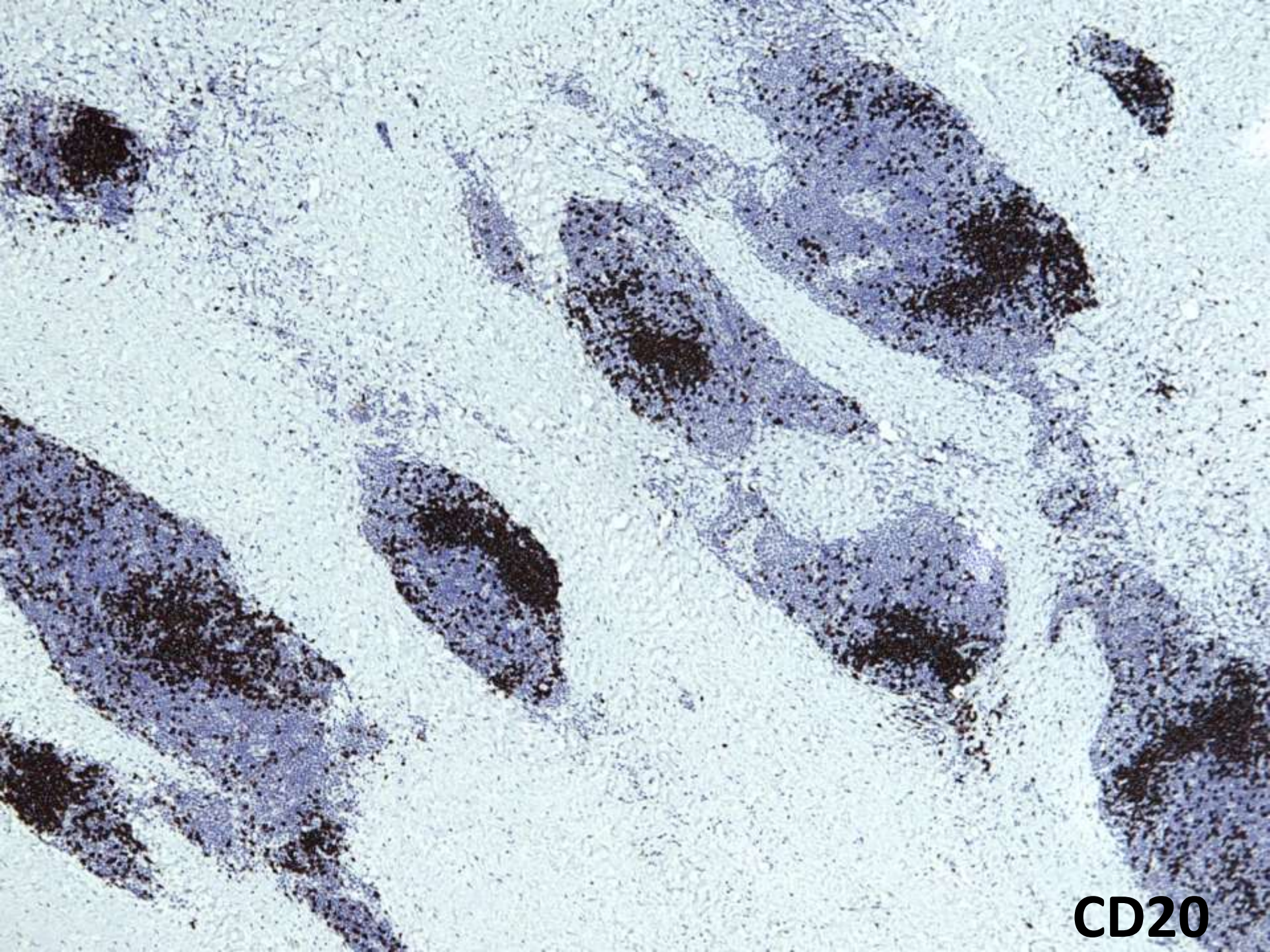
CD3



CD4



CD8



CD20

SB 6130

Natalia Isaza; Kaiser Santa Clara

43-year-old woman with a history of AIS in 2008/2009, with negative or ASCUS Paps since. HPV noted to be positive in 2009 and 2013, but all other years have been negative. Colposcopy in February 2015 was benign. Most recently (February 2016) had a negative Pap, negative endocervical curettage, and negative HPV test. This Pap smear is taken in August 2016.

