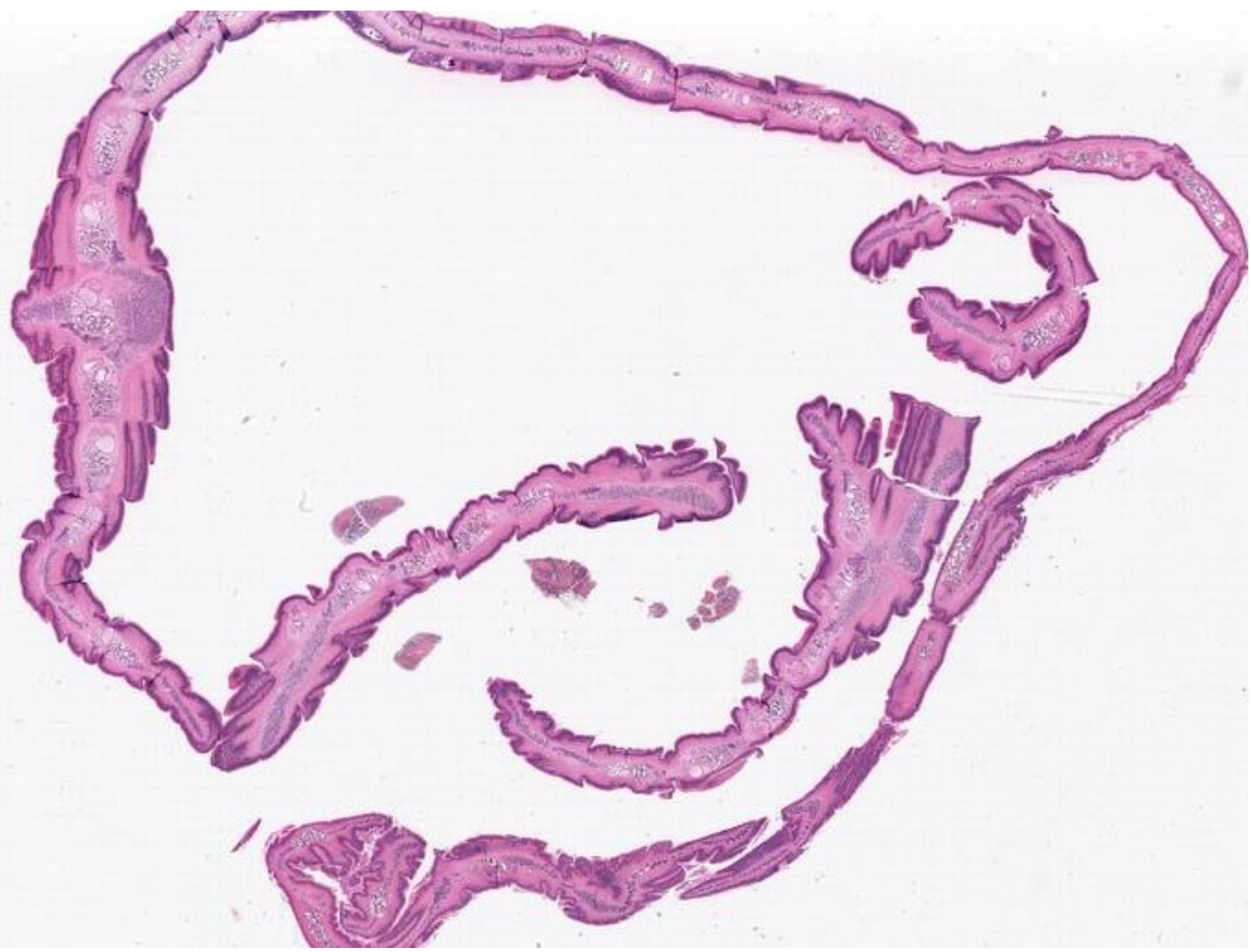
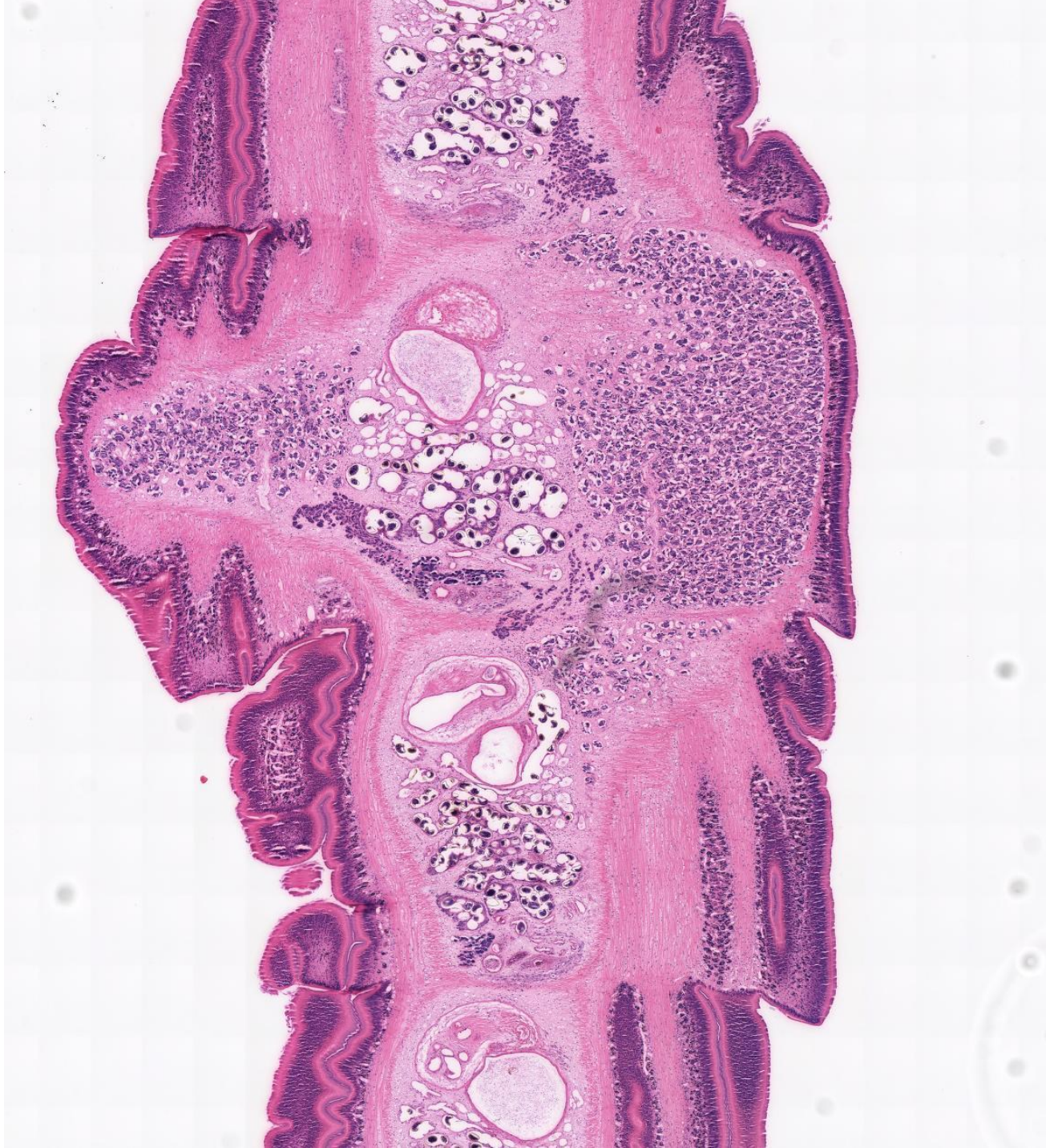

**SB 5891**

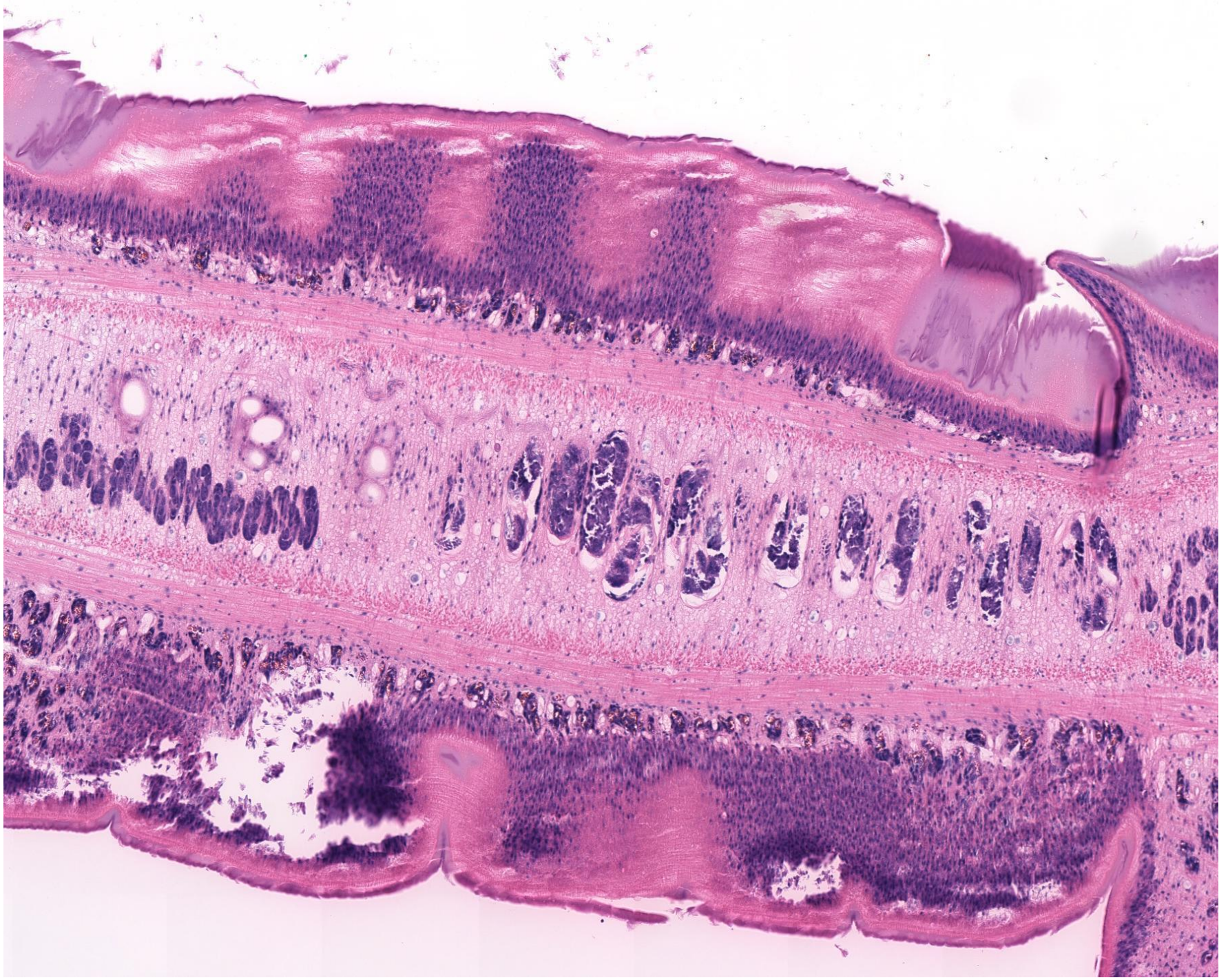**Harris Goodman; Saint Francis  
Memorial Hospital, Oakland, CA**  
68-year-old man who found specimen  
in stool.



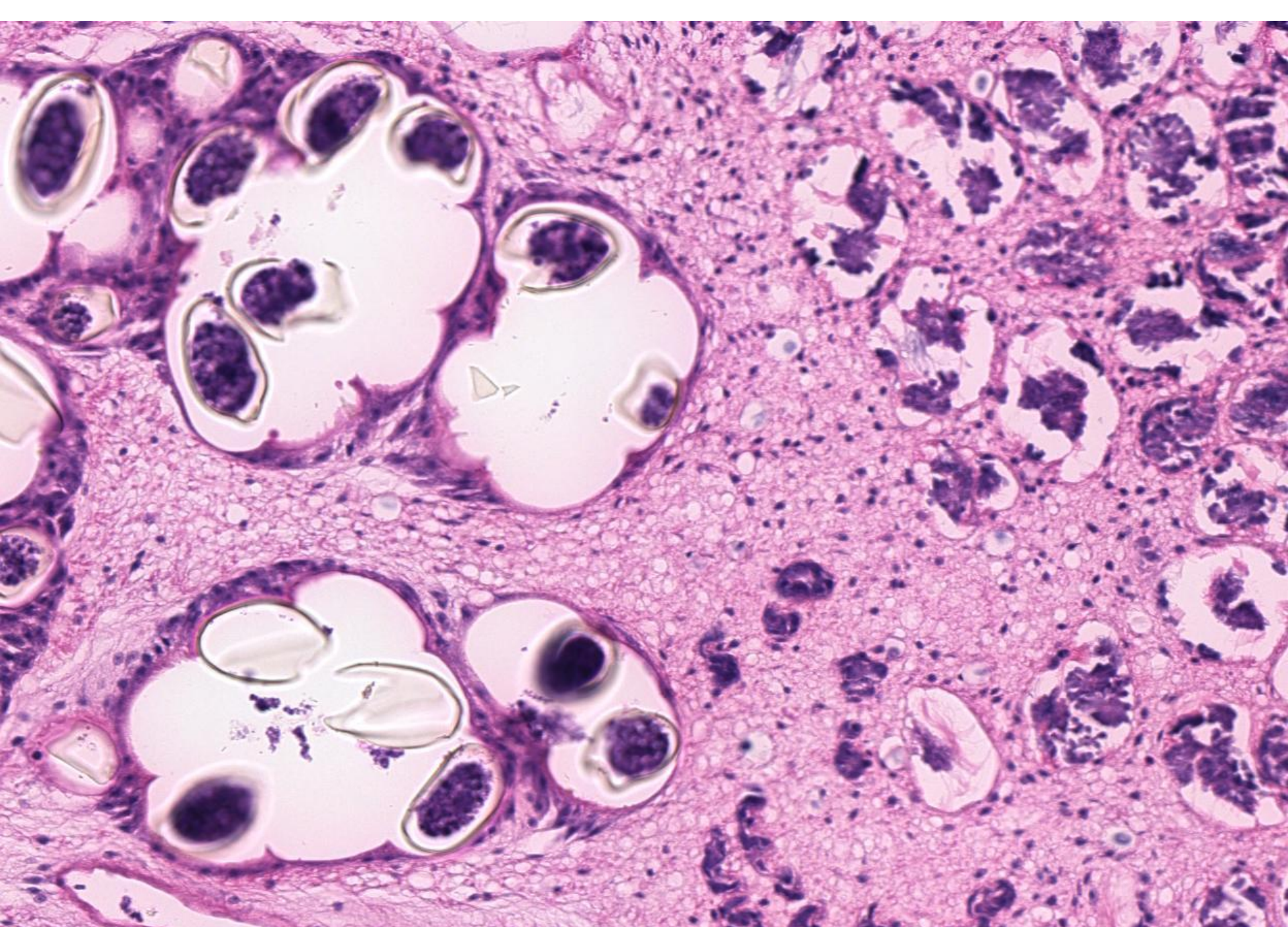




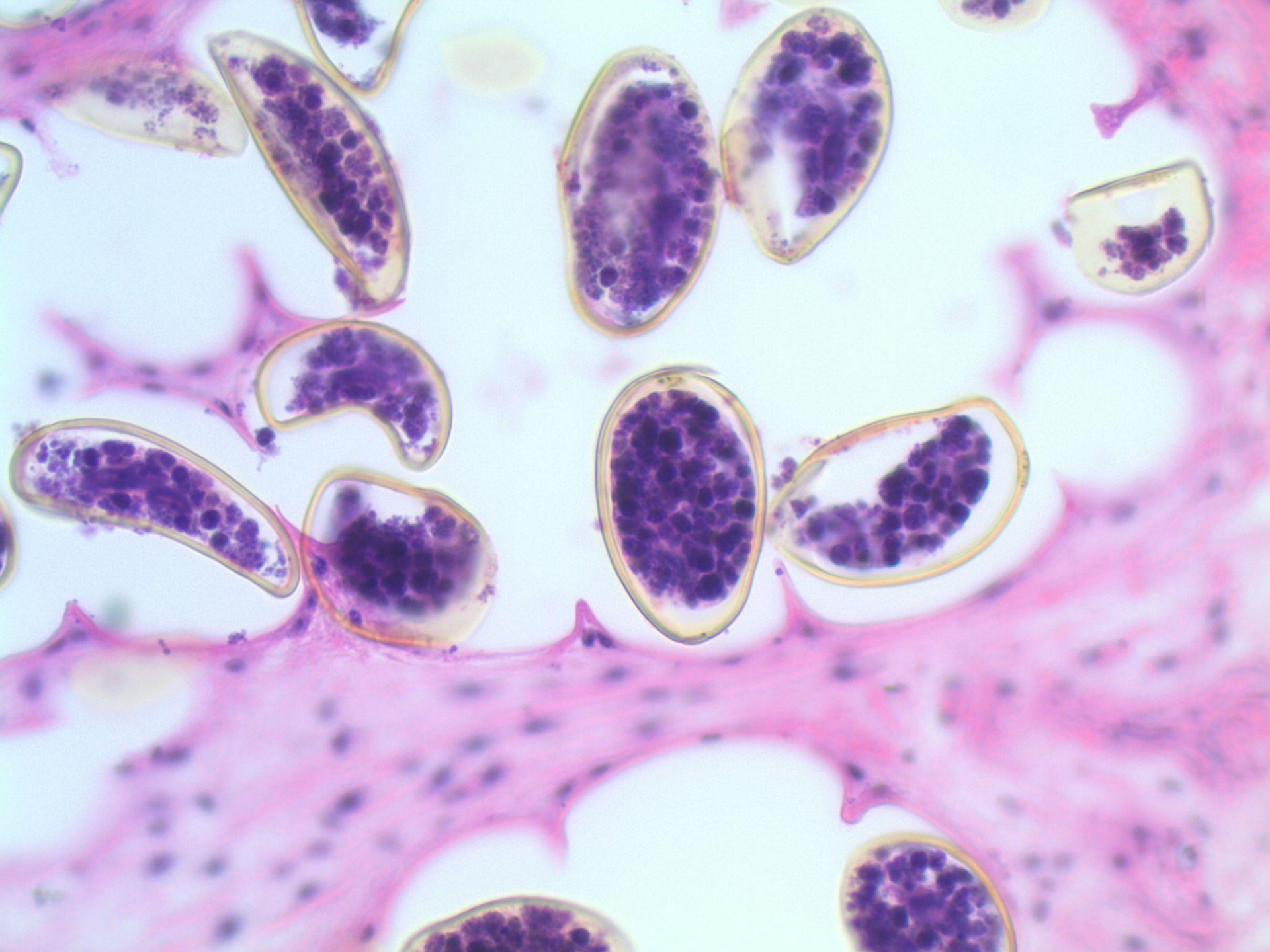




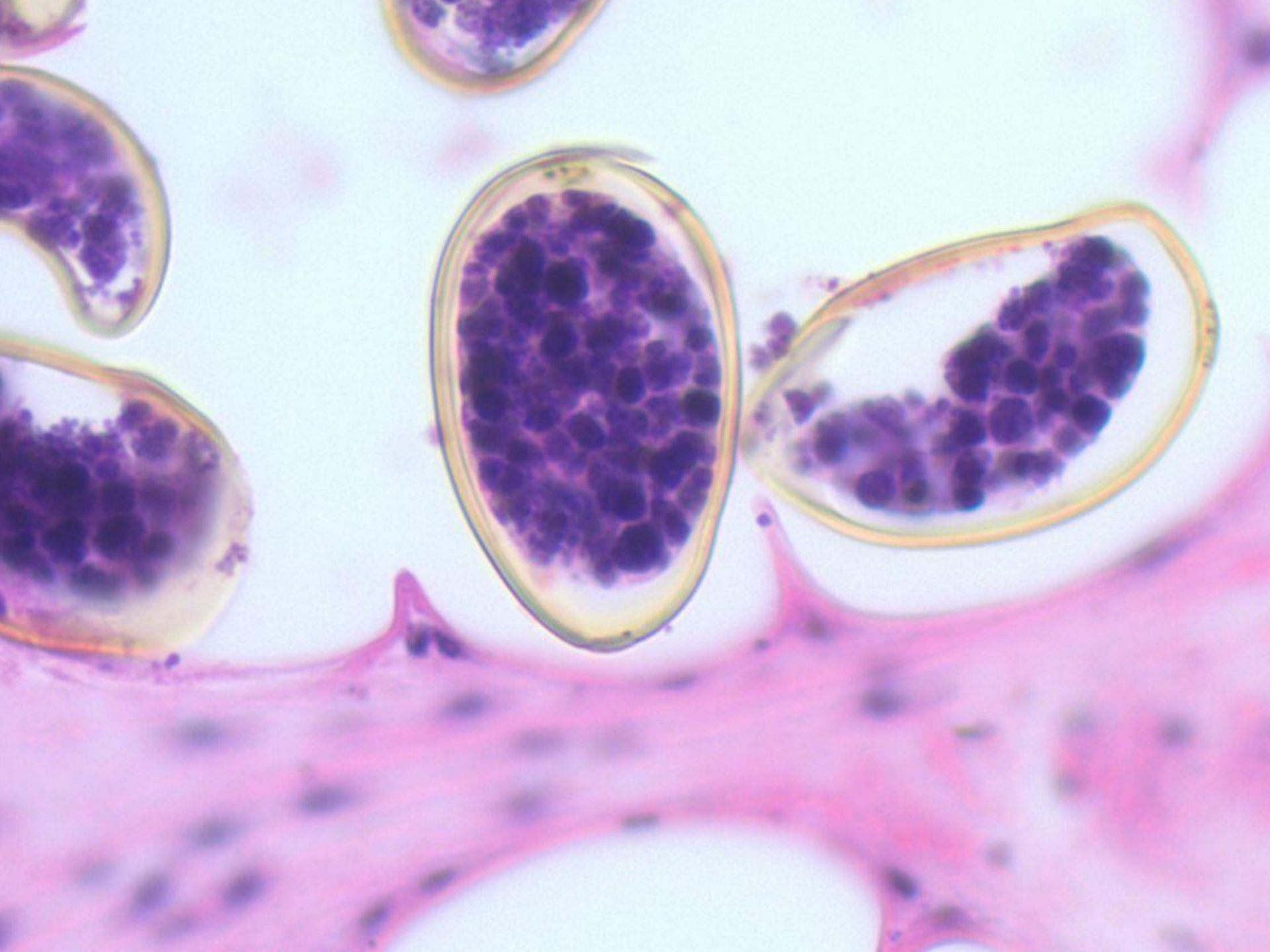










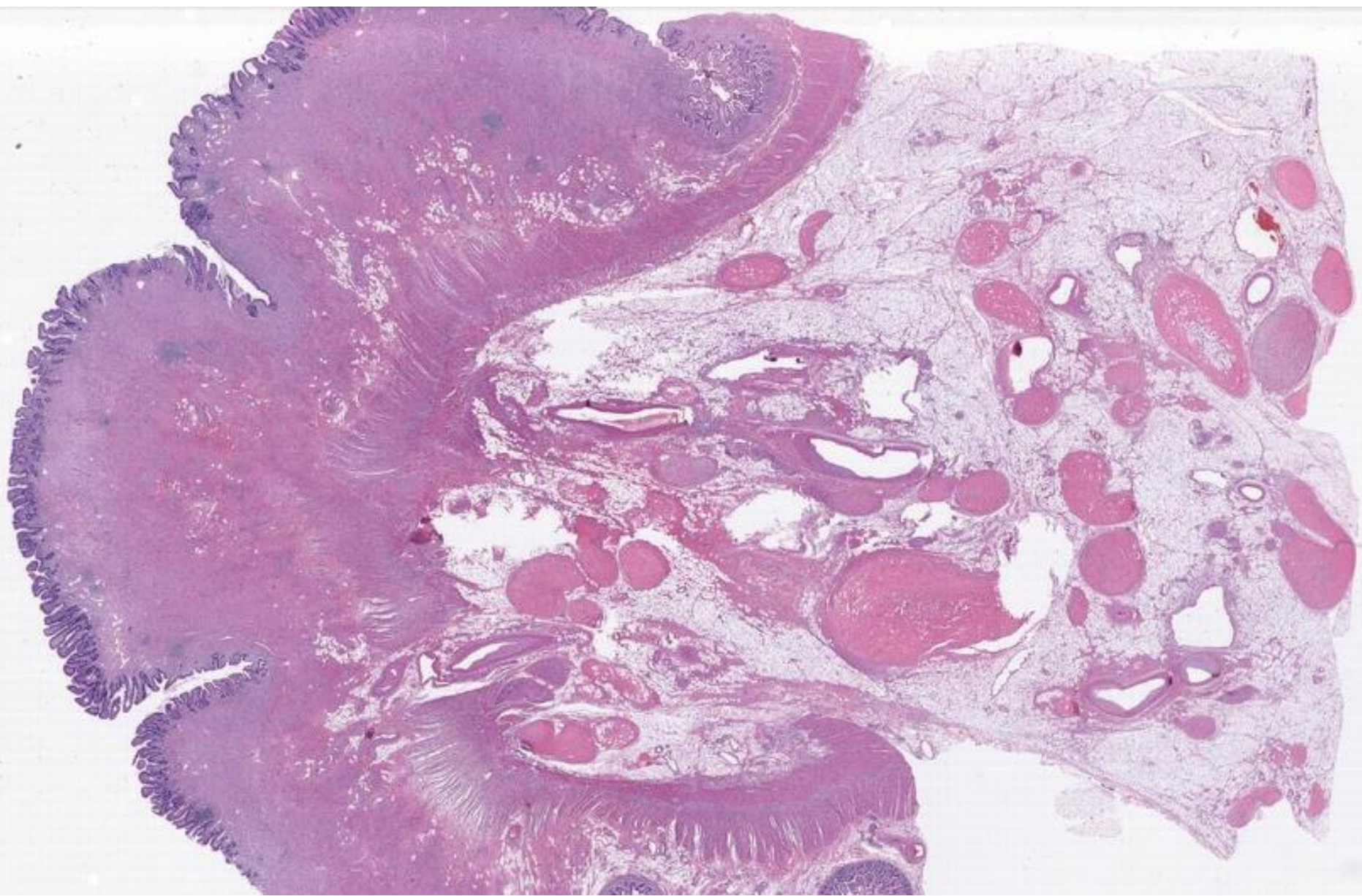


# SB 5892

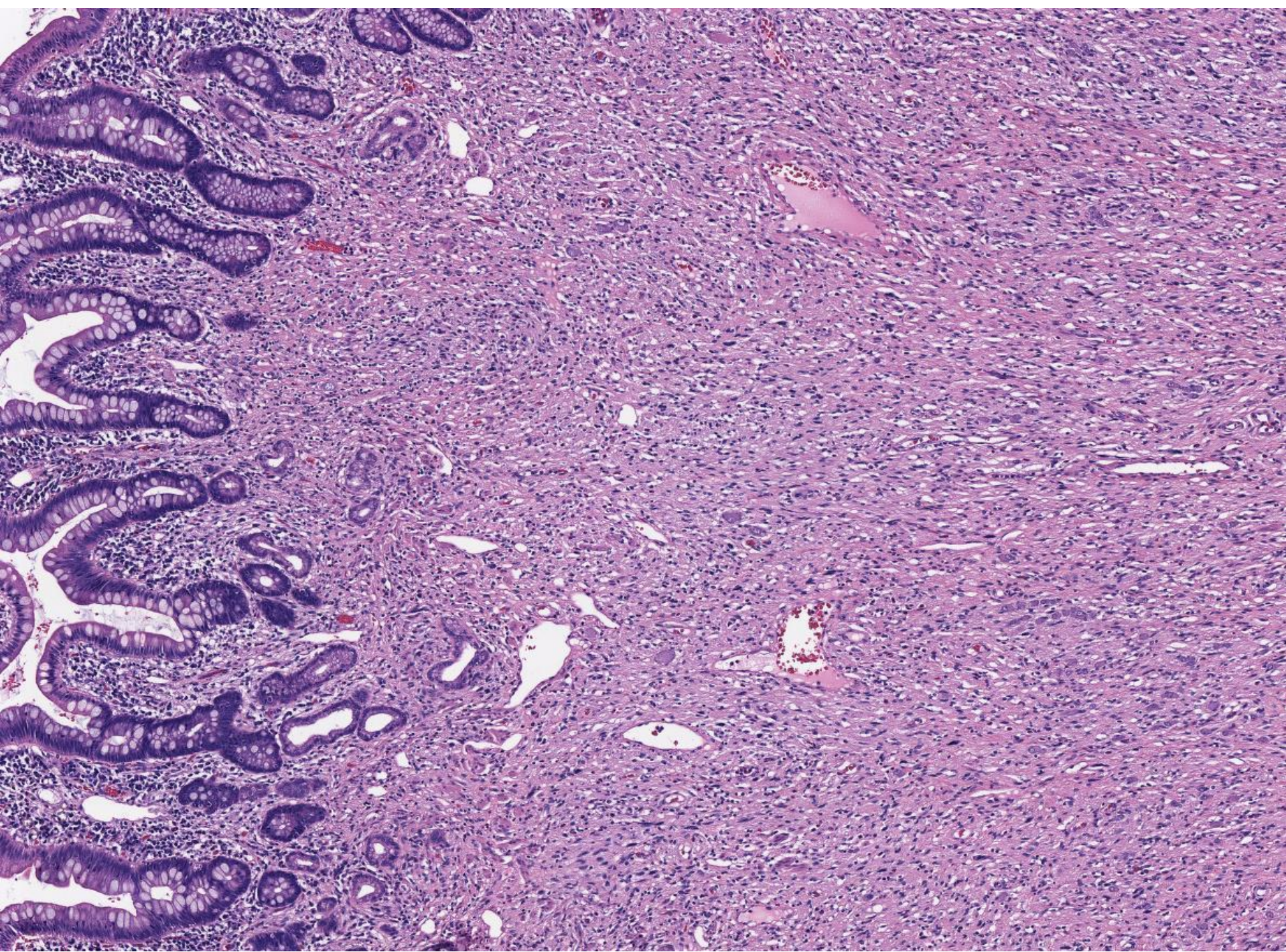
**Mahendra Ranchod; Good Samaritan  
Hospital, San Jose, CA**

53-year-old presented with acute intestinal obstruction. Segment of thickened small intestine resected.

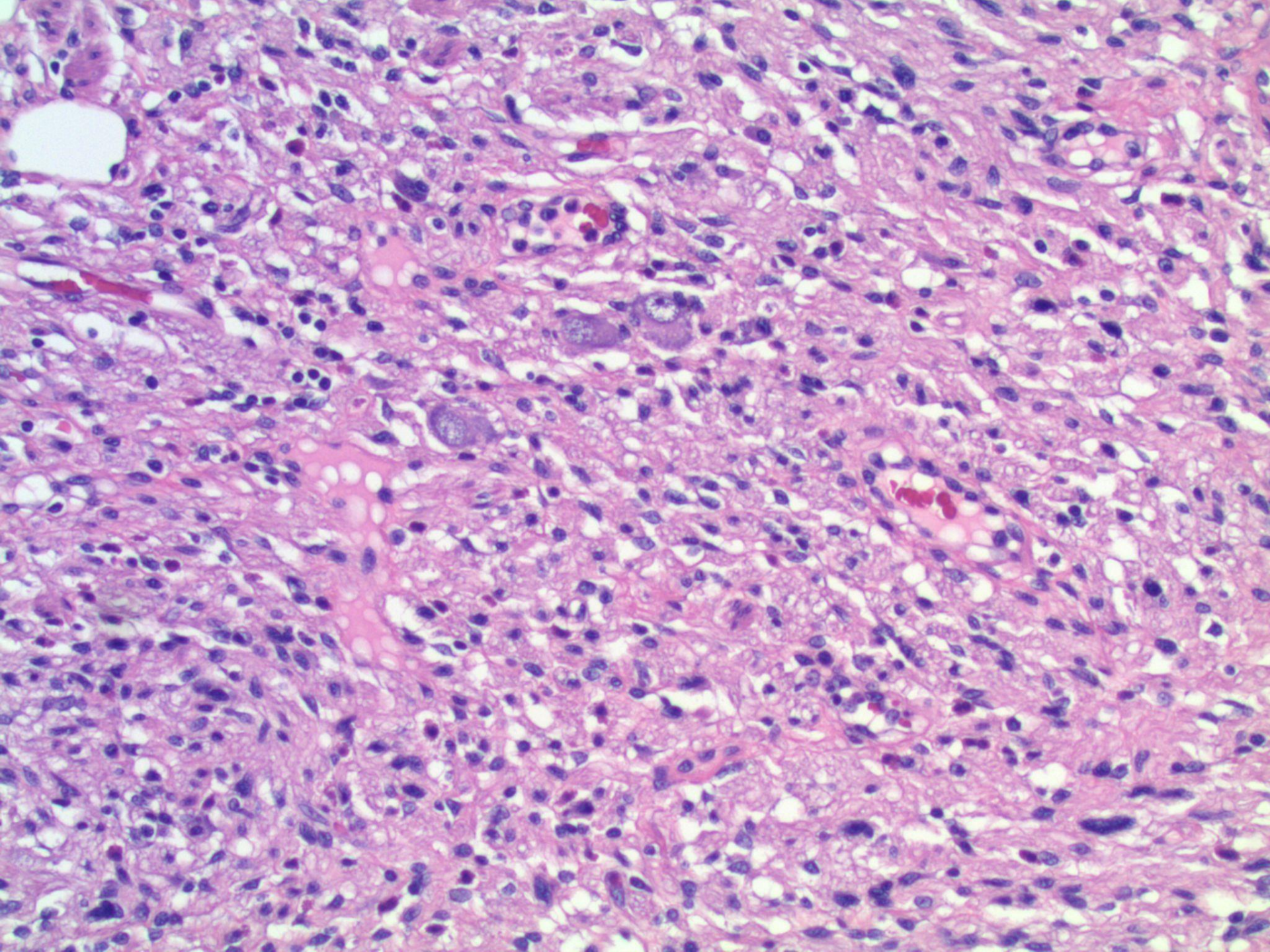




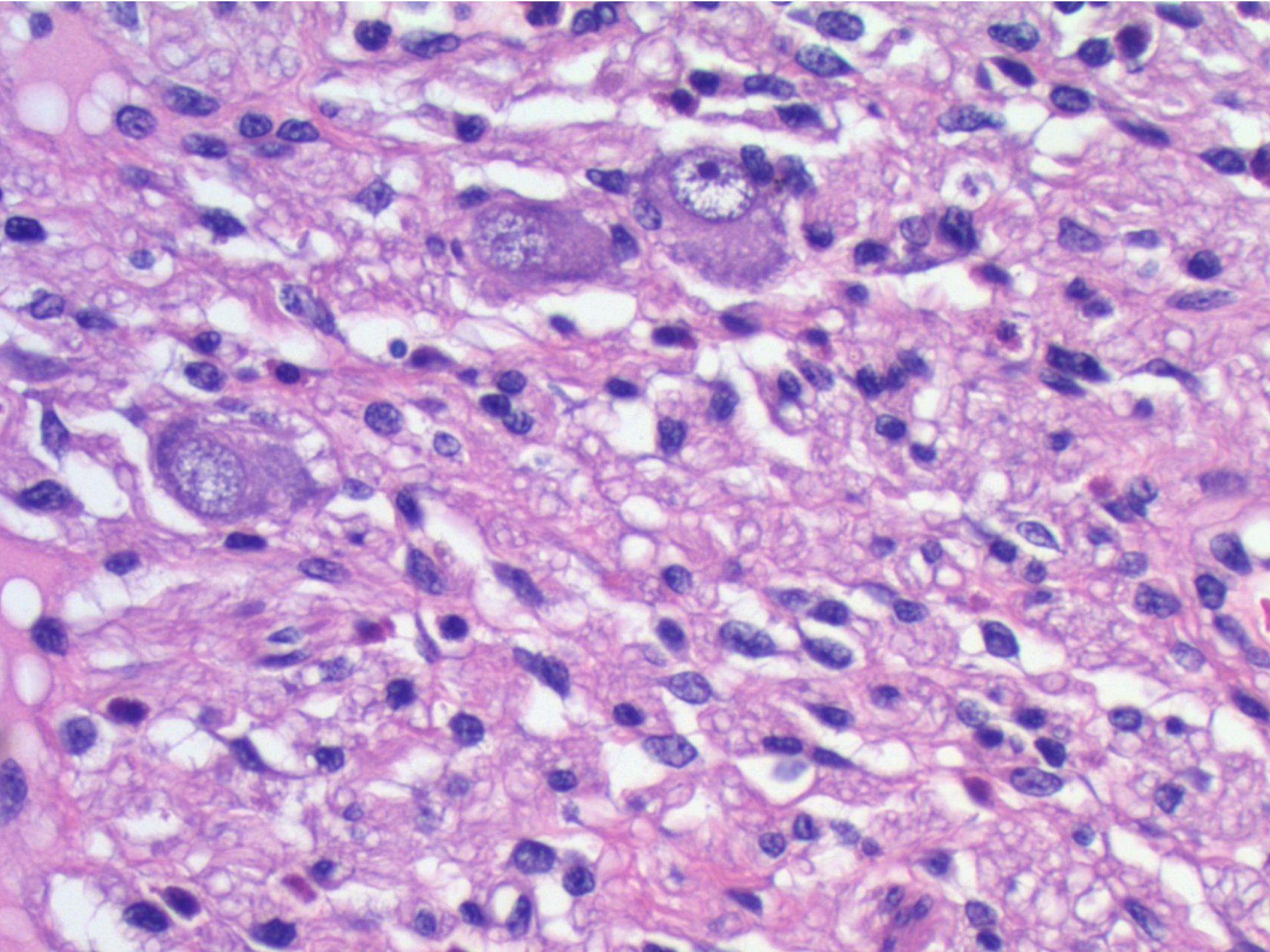




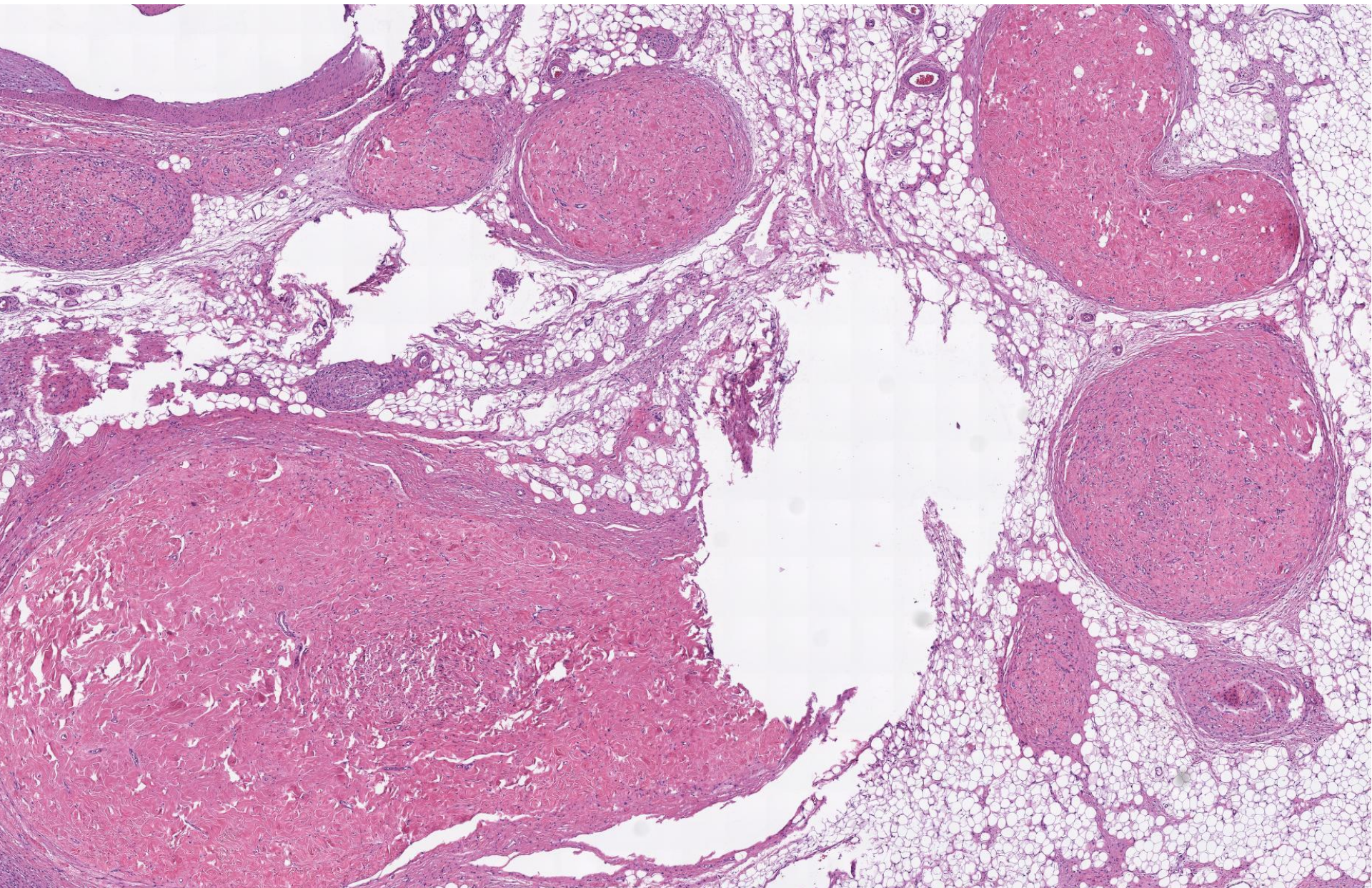




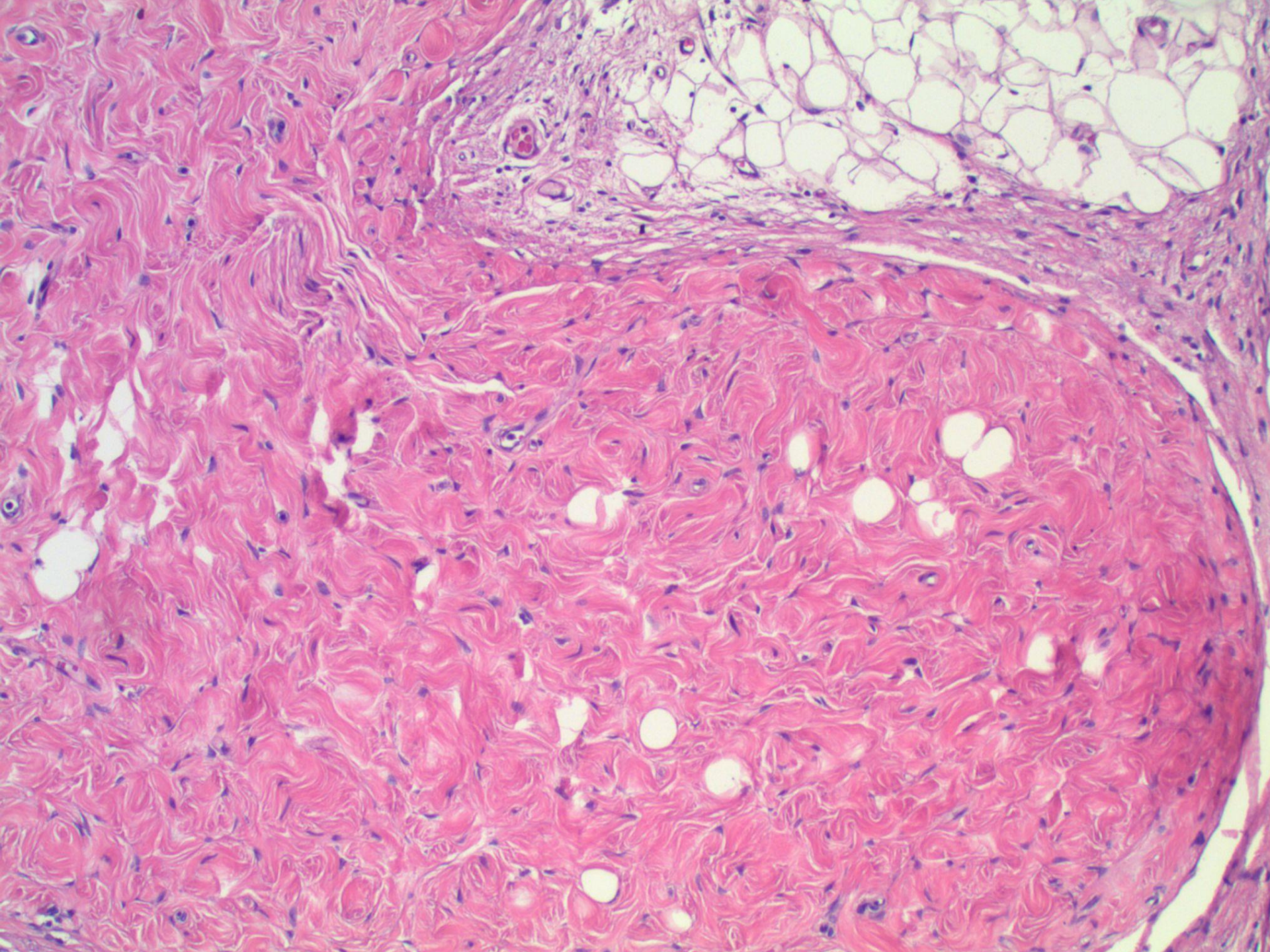




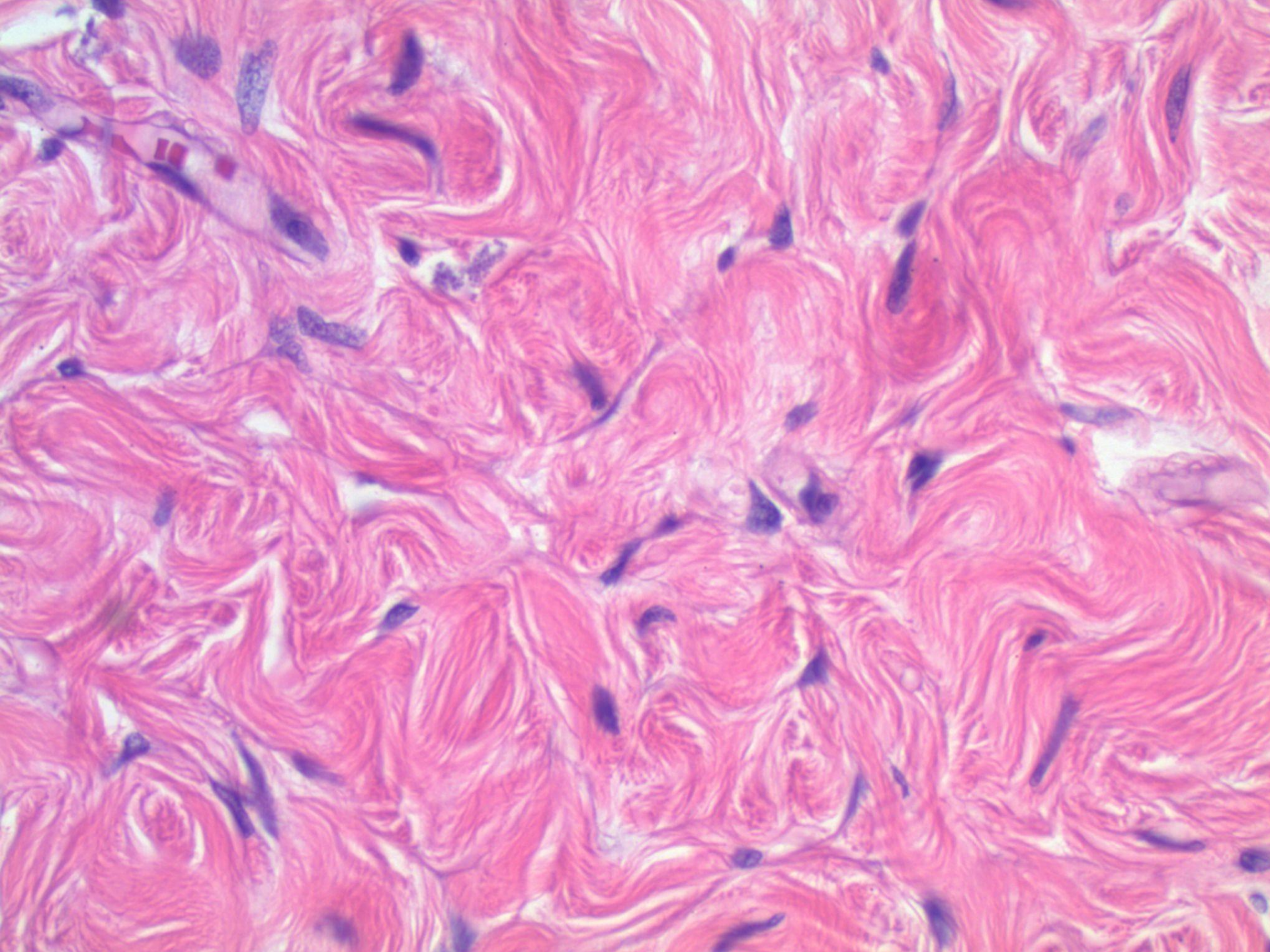












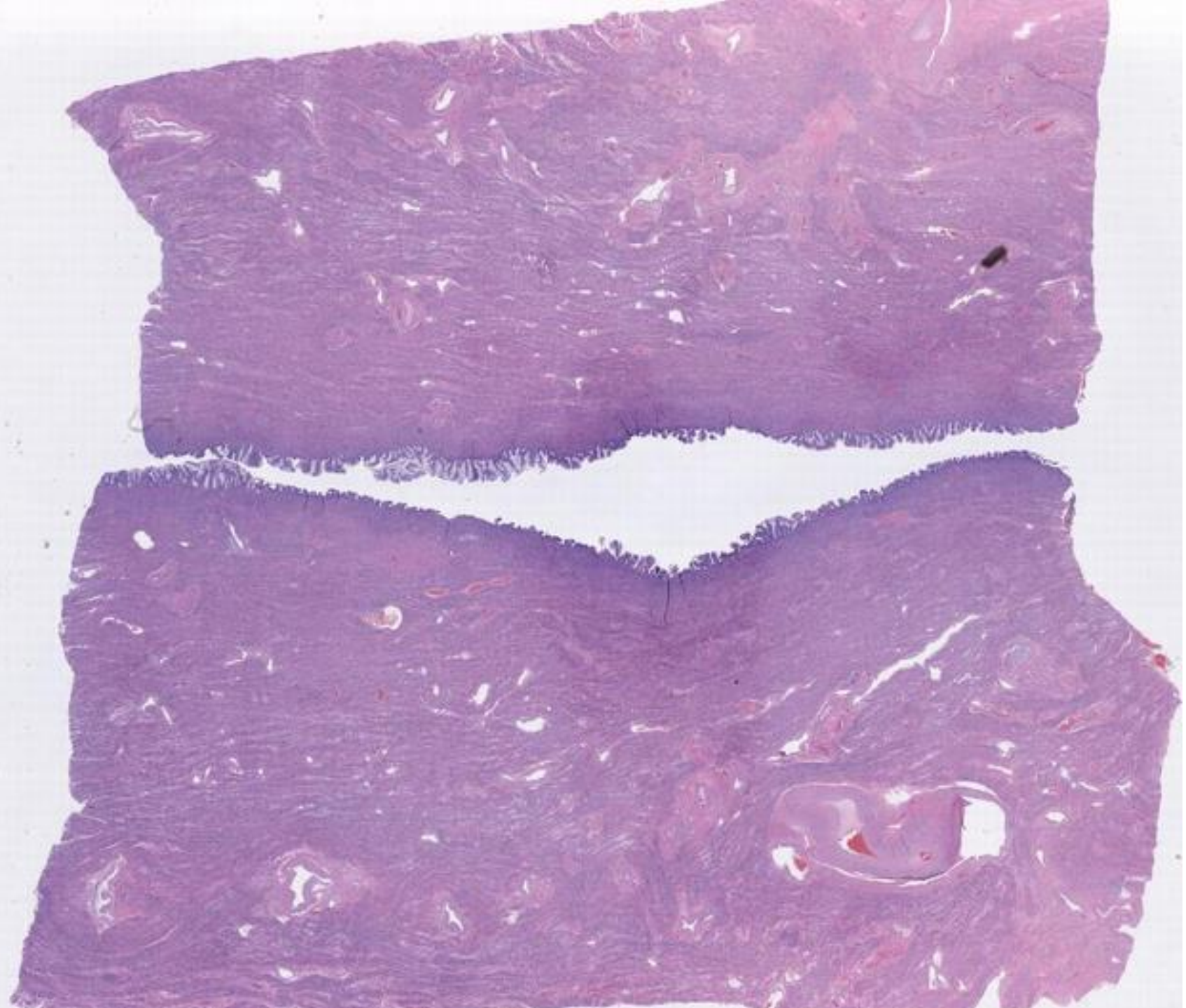


**SB 5893**

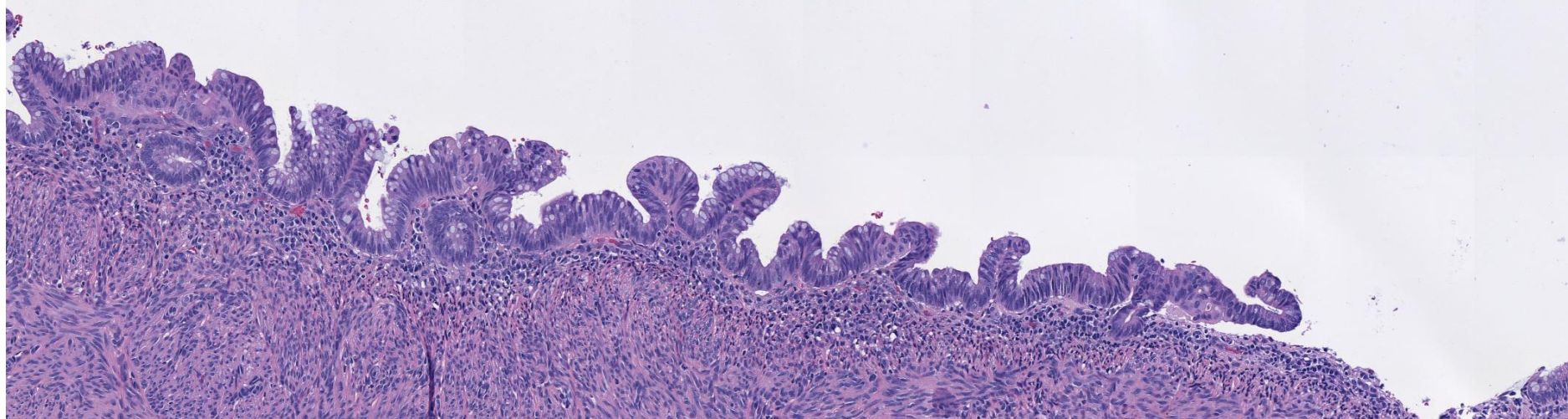
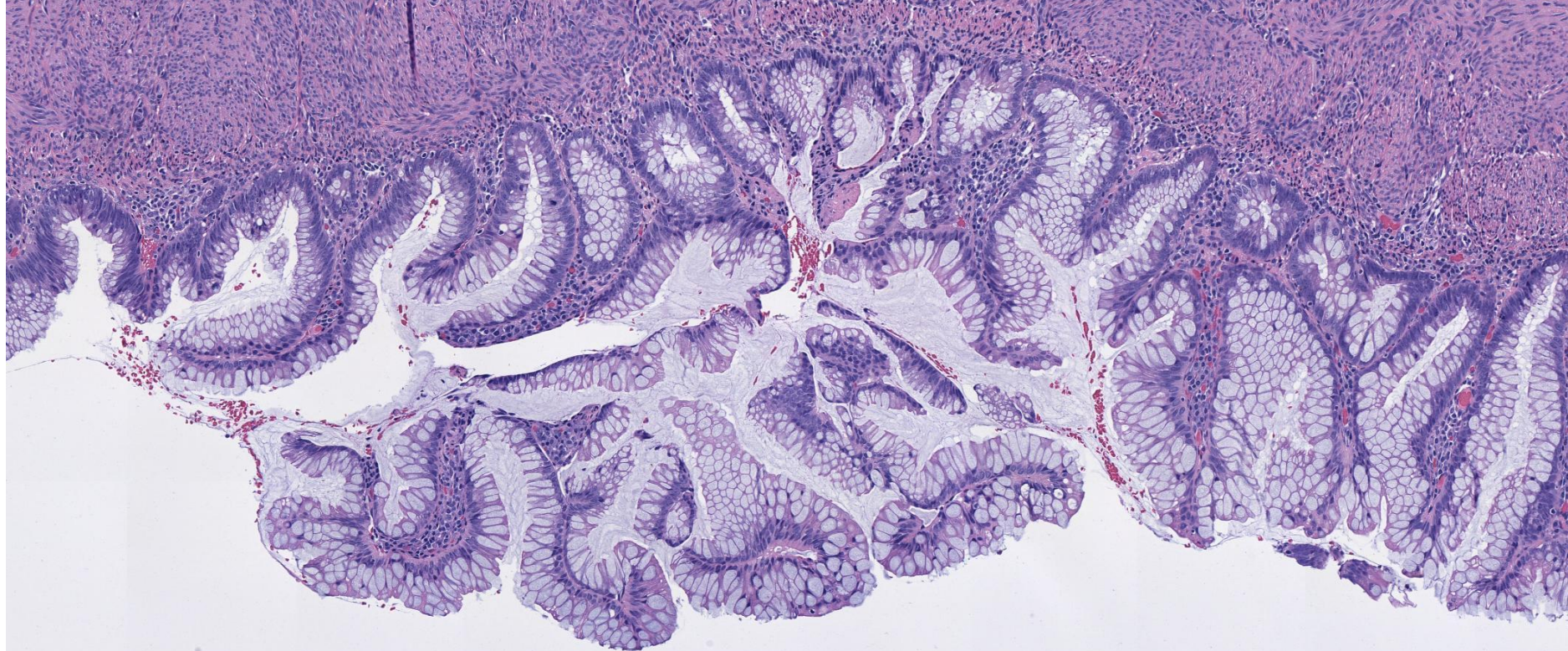
**Mahendra Ranchod; Good Samaritan  
Hospital, San Jose, CA**

66-year-old woman had TAH/BSO for right  
tubo-ovarian abscess. Sections of  
endometrium submitted.

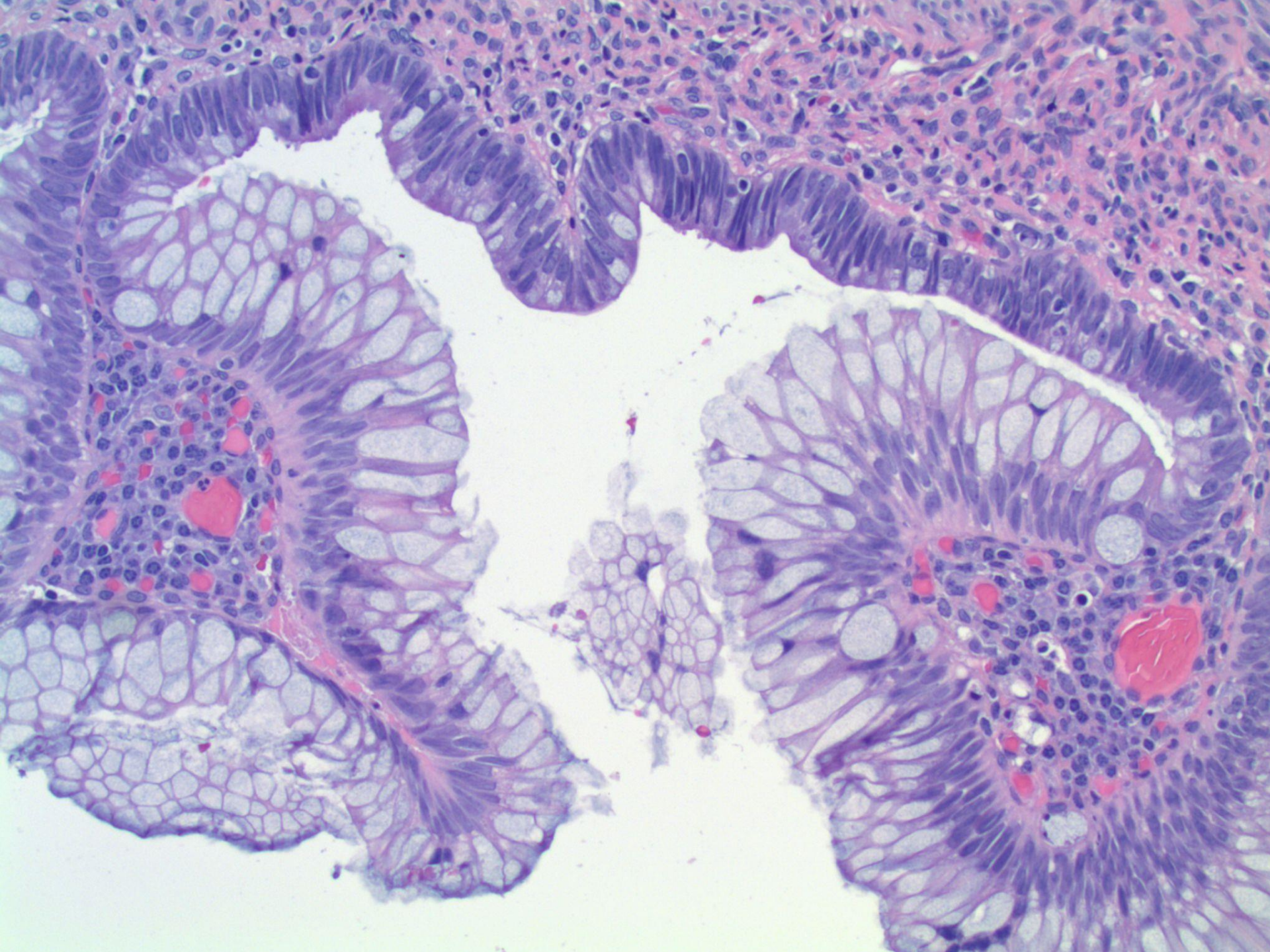




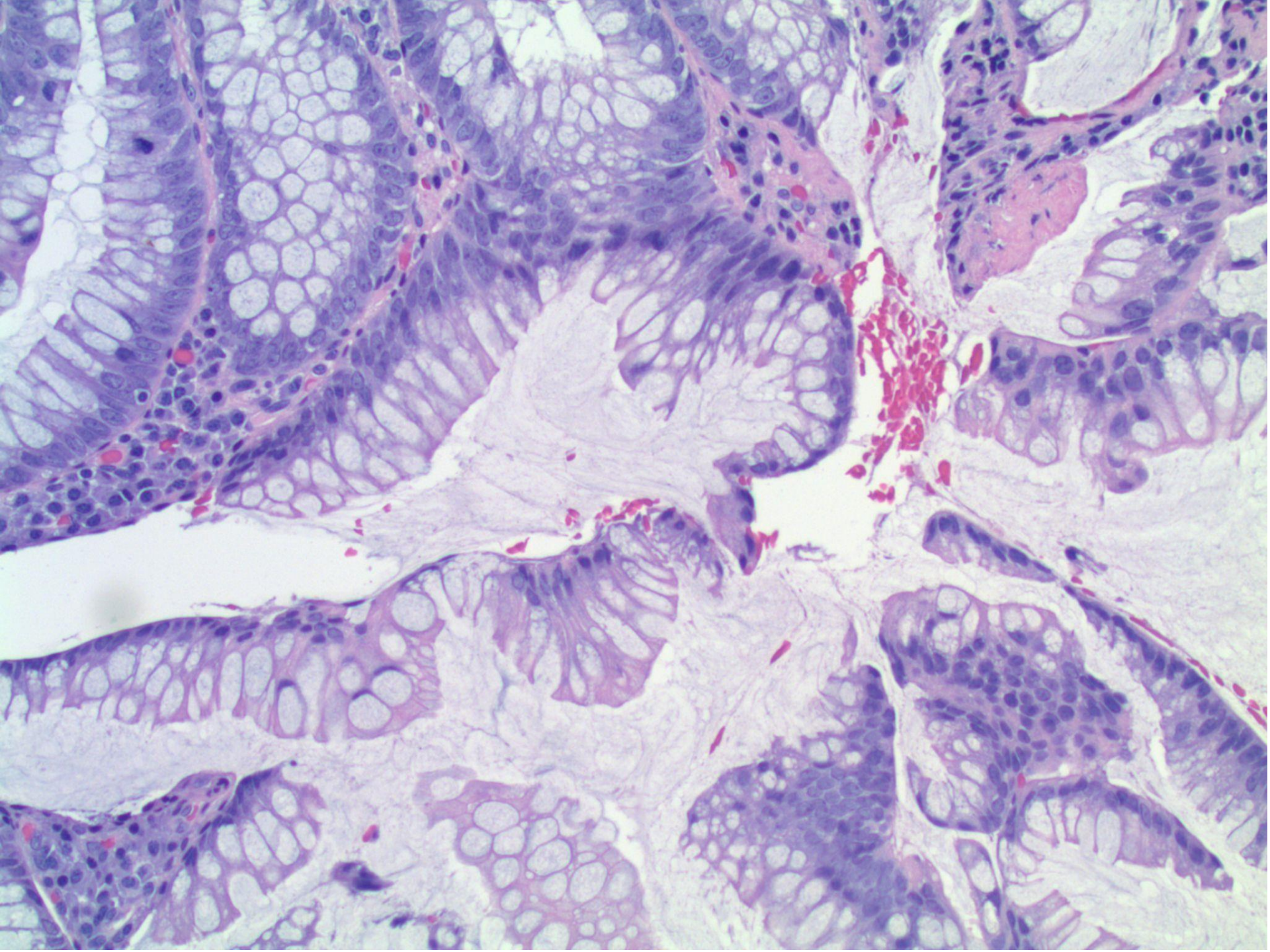












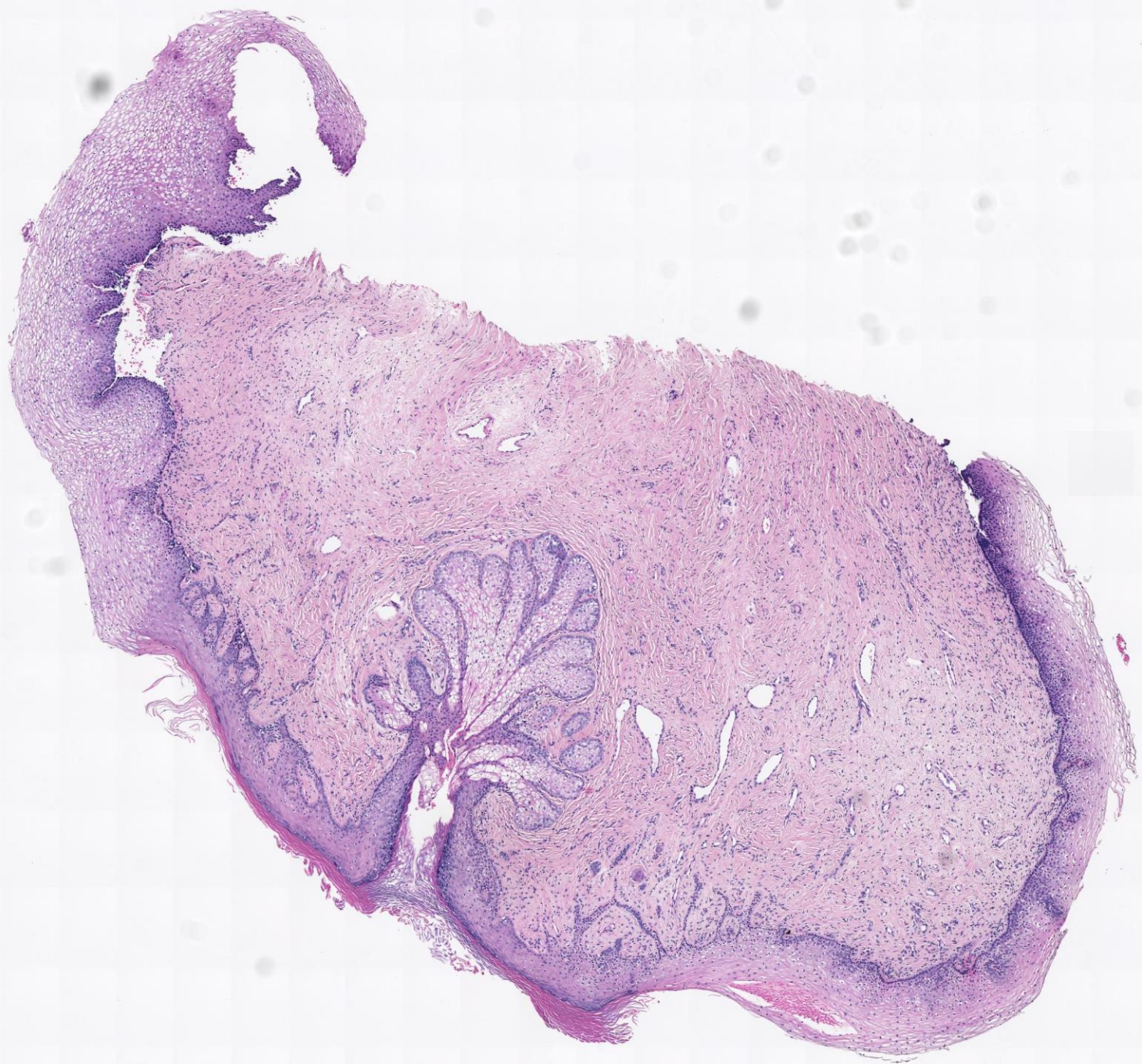


# SB 5894

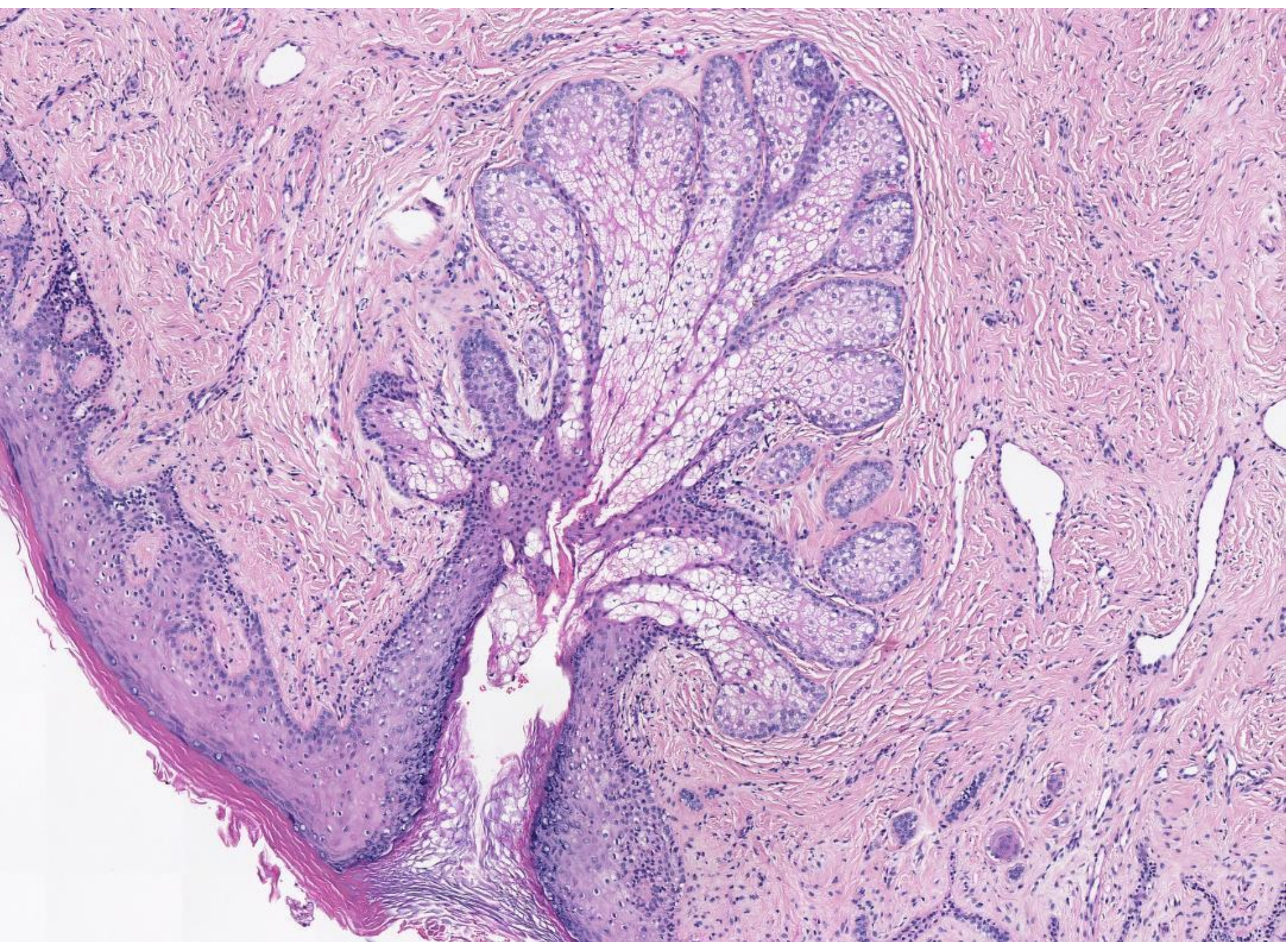
**Ray Azzi; SCVMC, Santa Clara, CA**

53-year-old woman with abnormal paps since 2009 ASCUS, HPV+ pap in 2014, and colposcopy consistent with mild dysplasia.

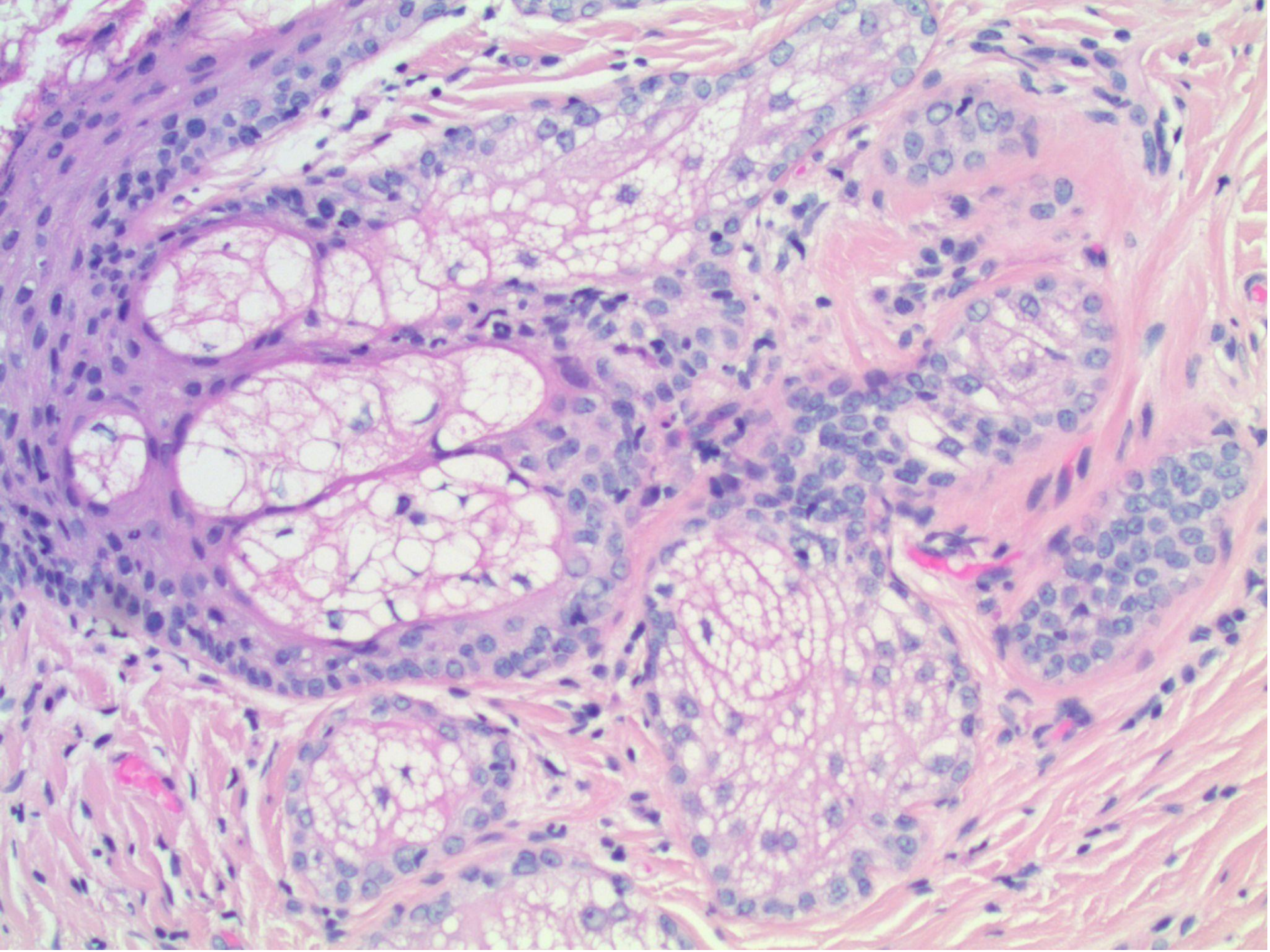




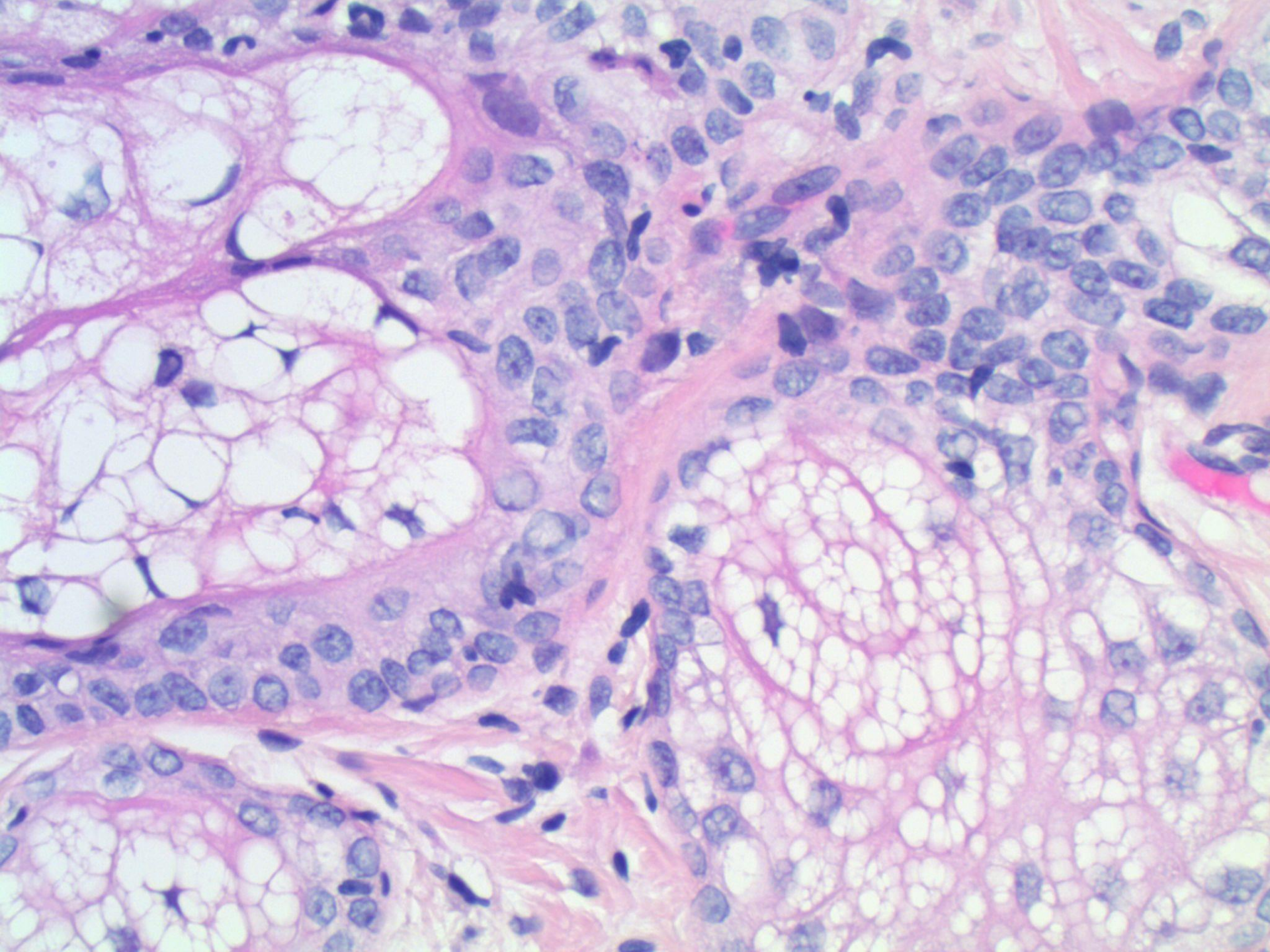












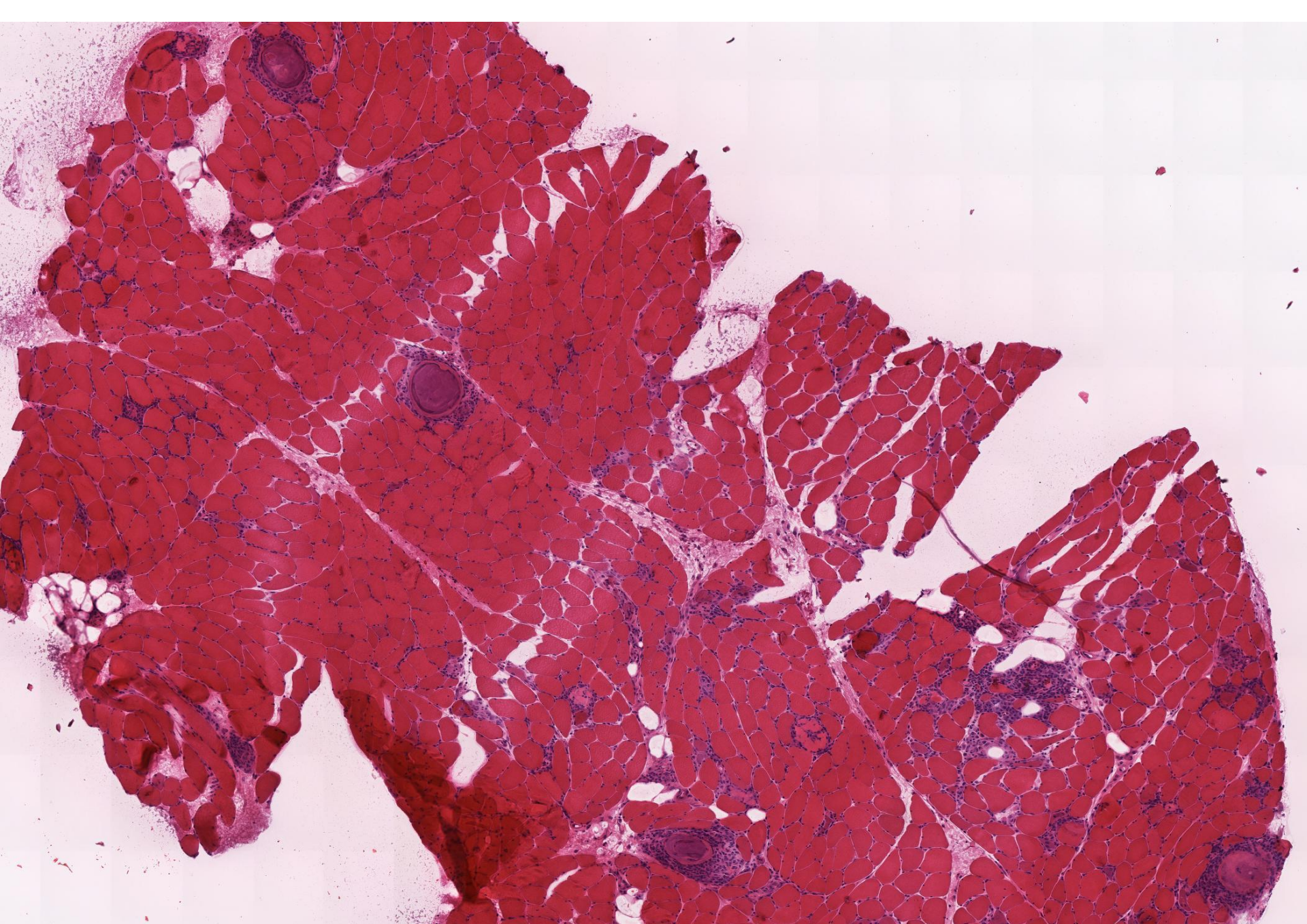


# SB 5895

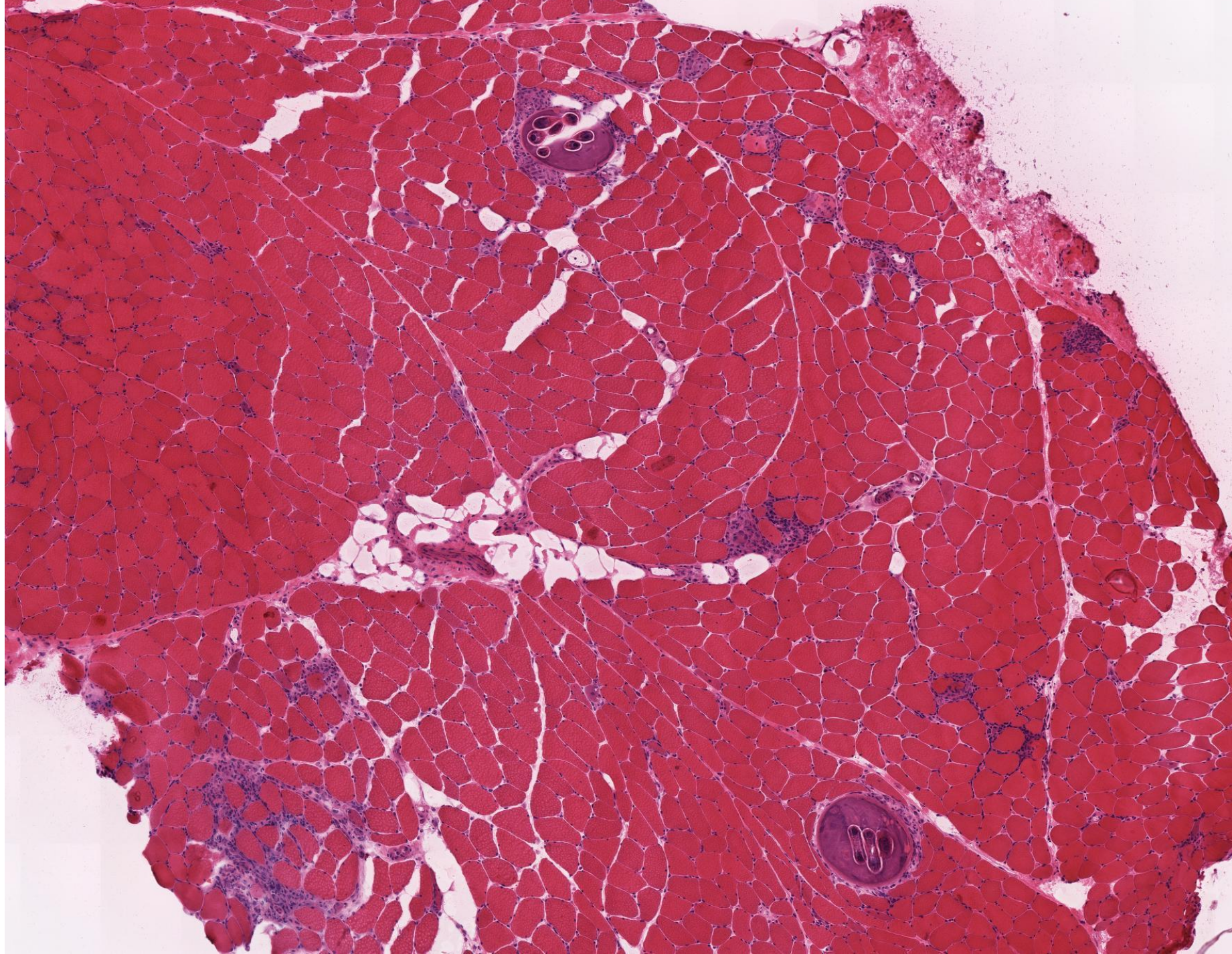
**Jason Karamchandani; McGill University  
Health Centre; Montreal, Quebec**

47-year-old woman with muscle pain and  
elevated CK (around 740). Muscle biopsy  
performed.

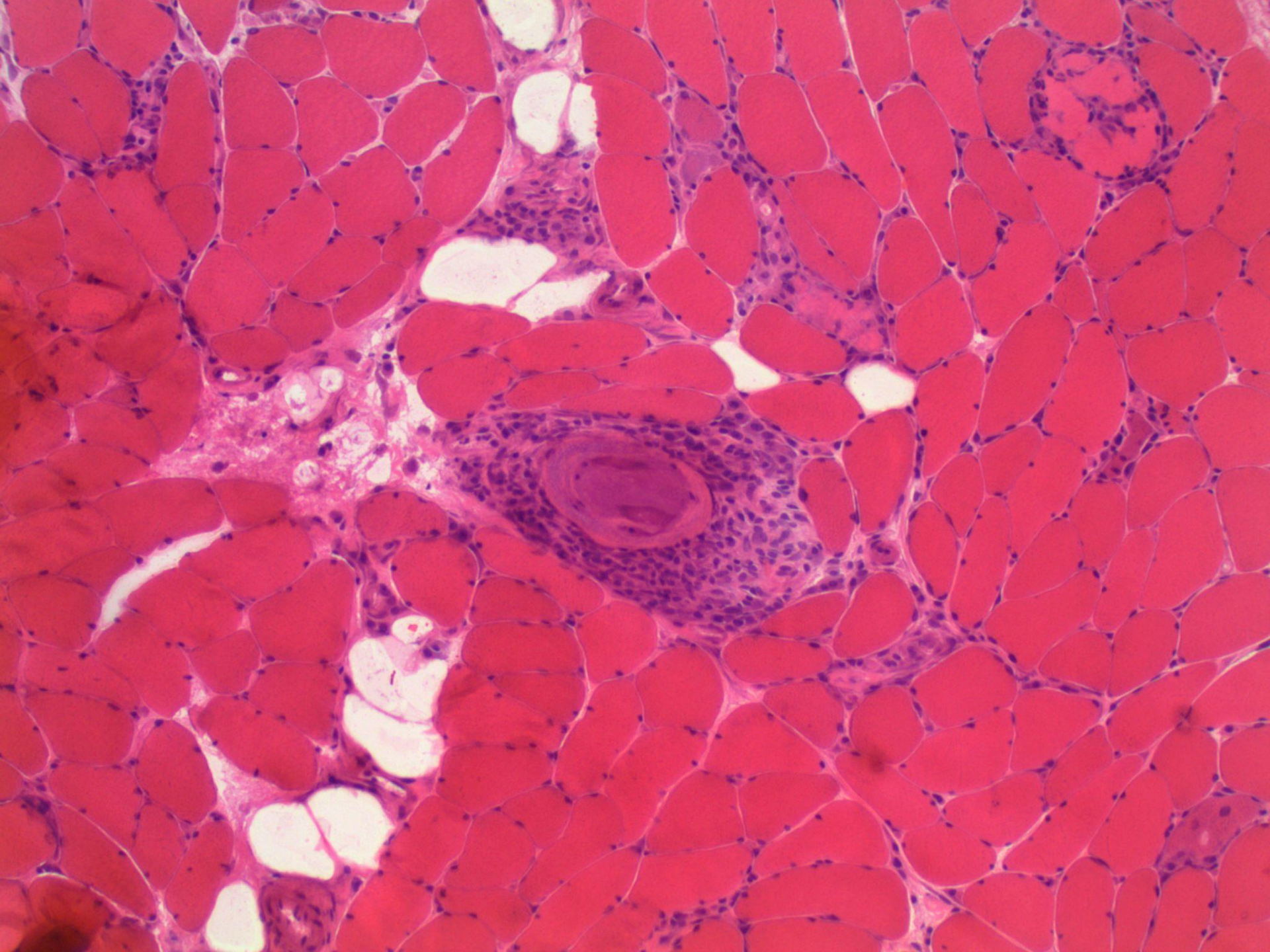




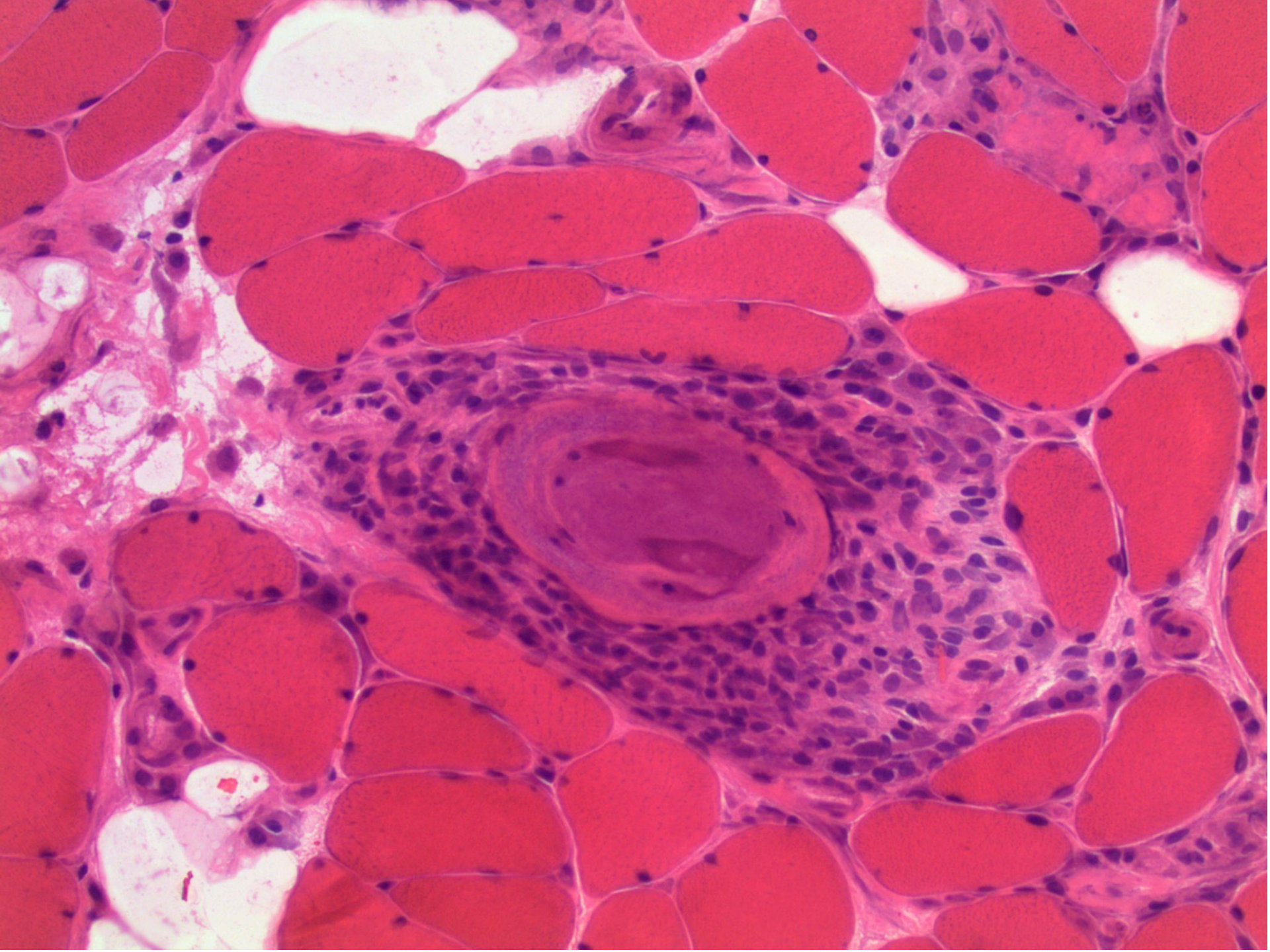




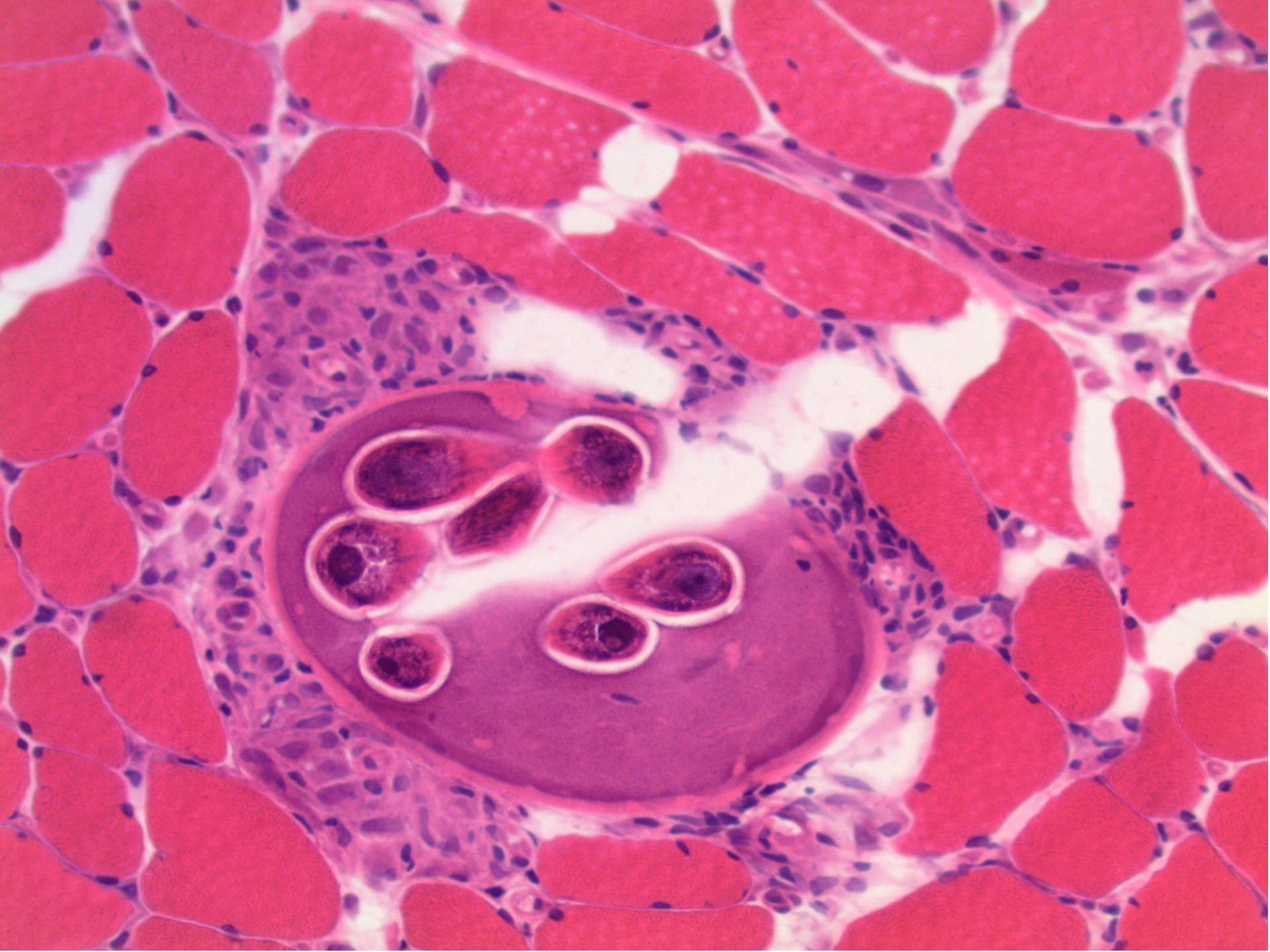




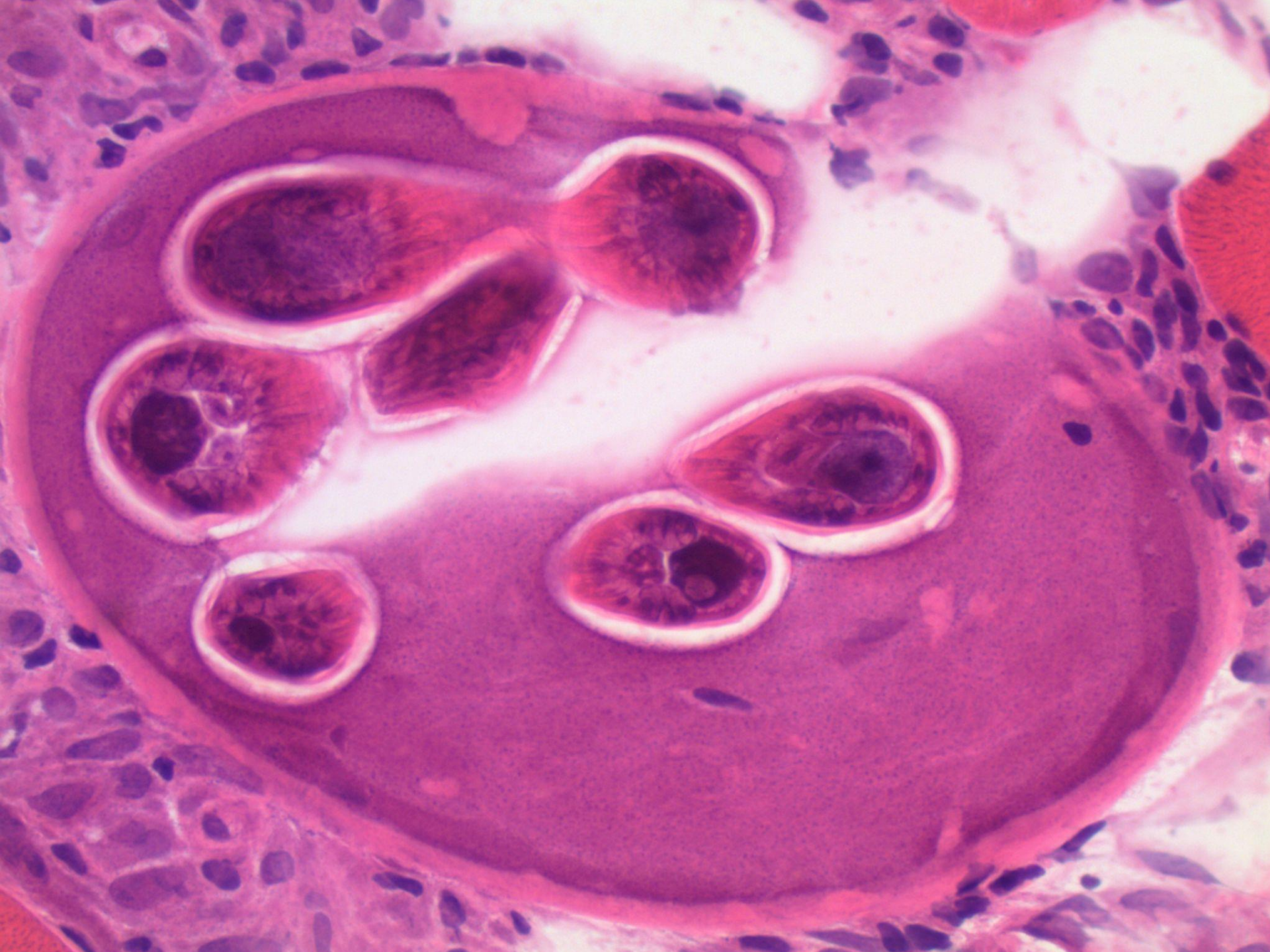












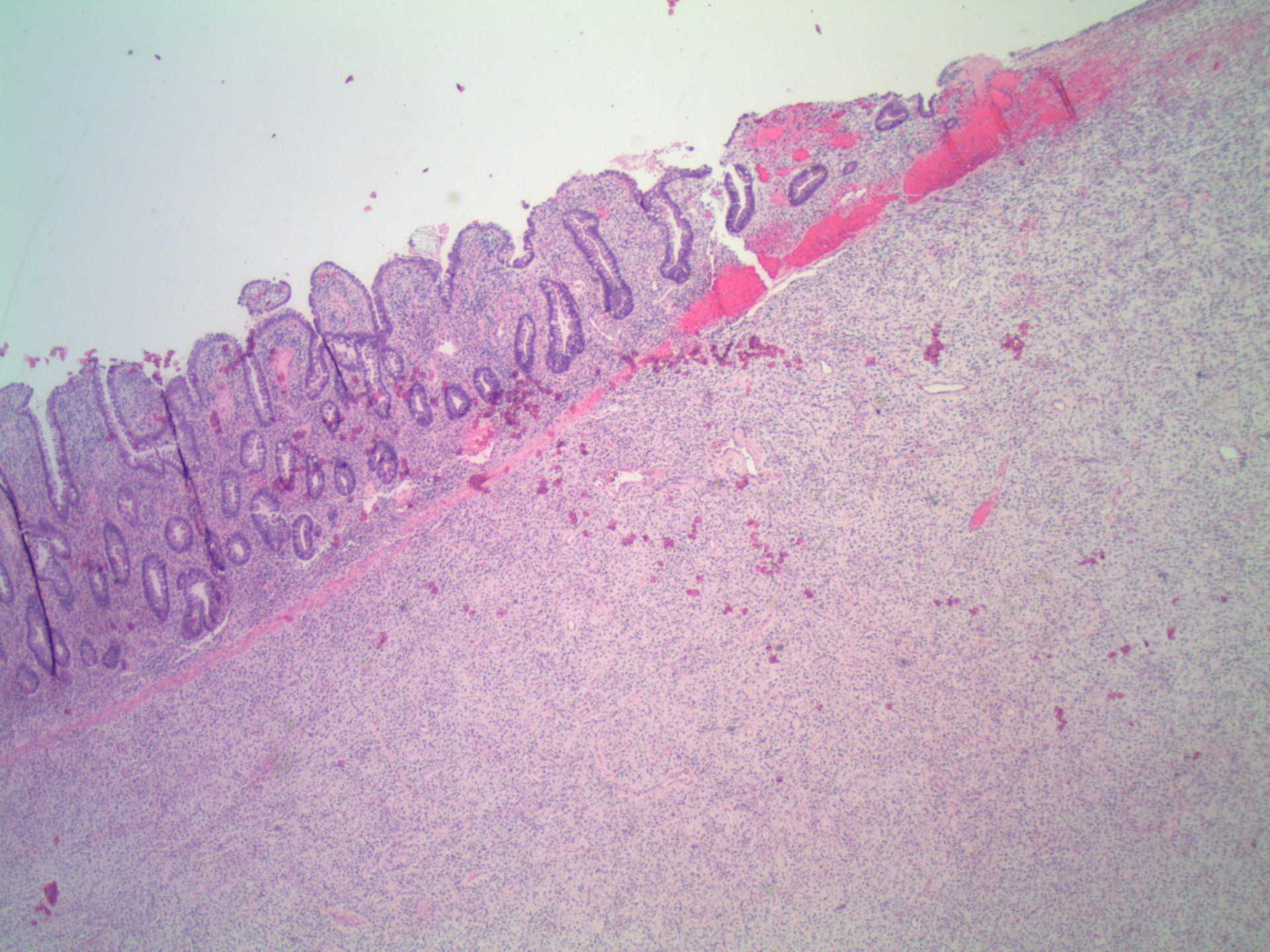


# SB 5896

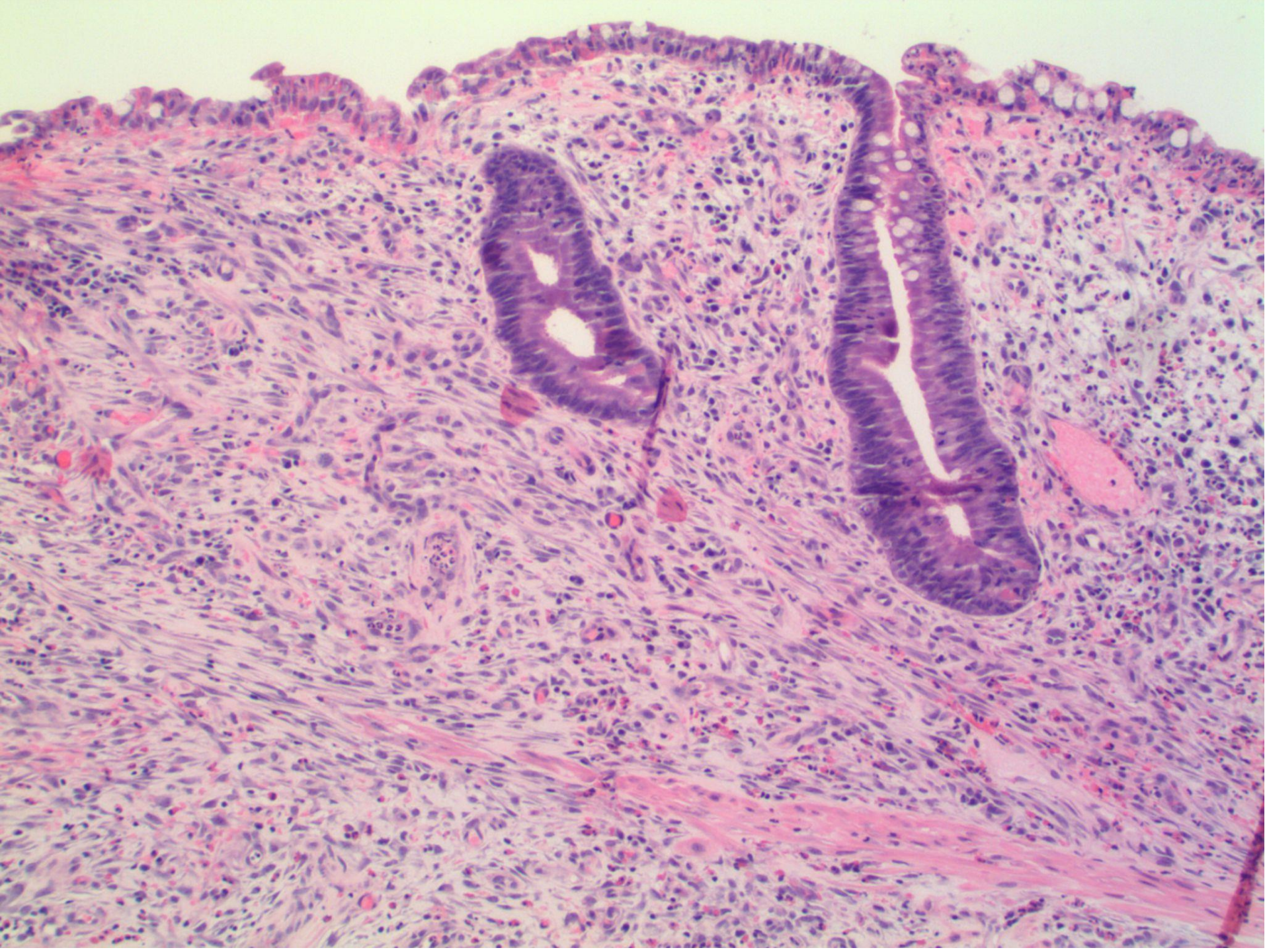
**Laura Hofmeister; Santa Clara Kaiser; Santa Clara,  
CA**

17-year-old with history of intermittent right lower quadrant pain found by imaging to have small bowel obstruction. At surgery, ileal intussusception caused by a polyp was found.

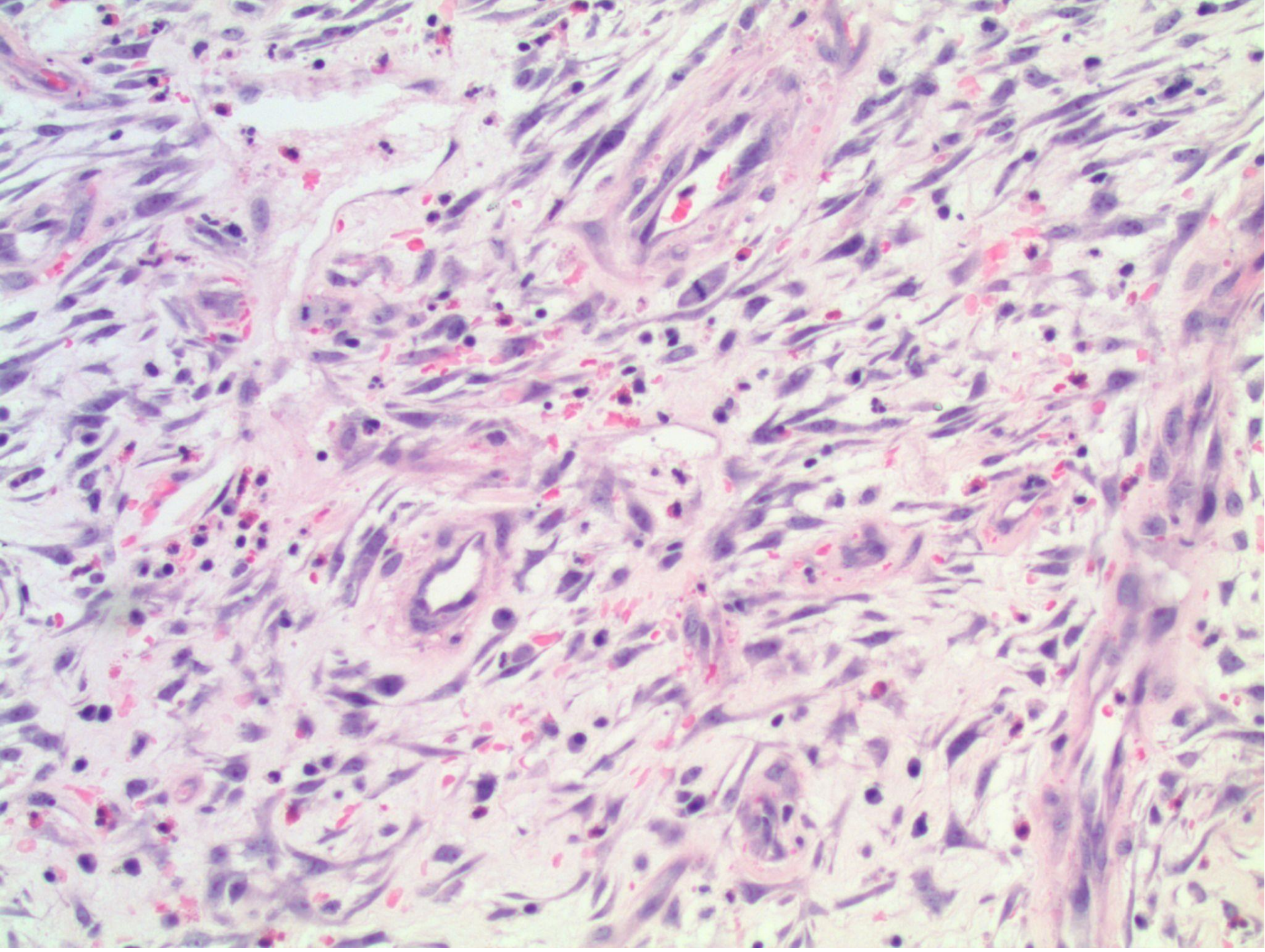




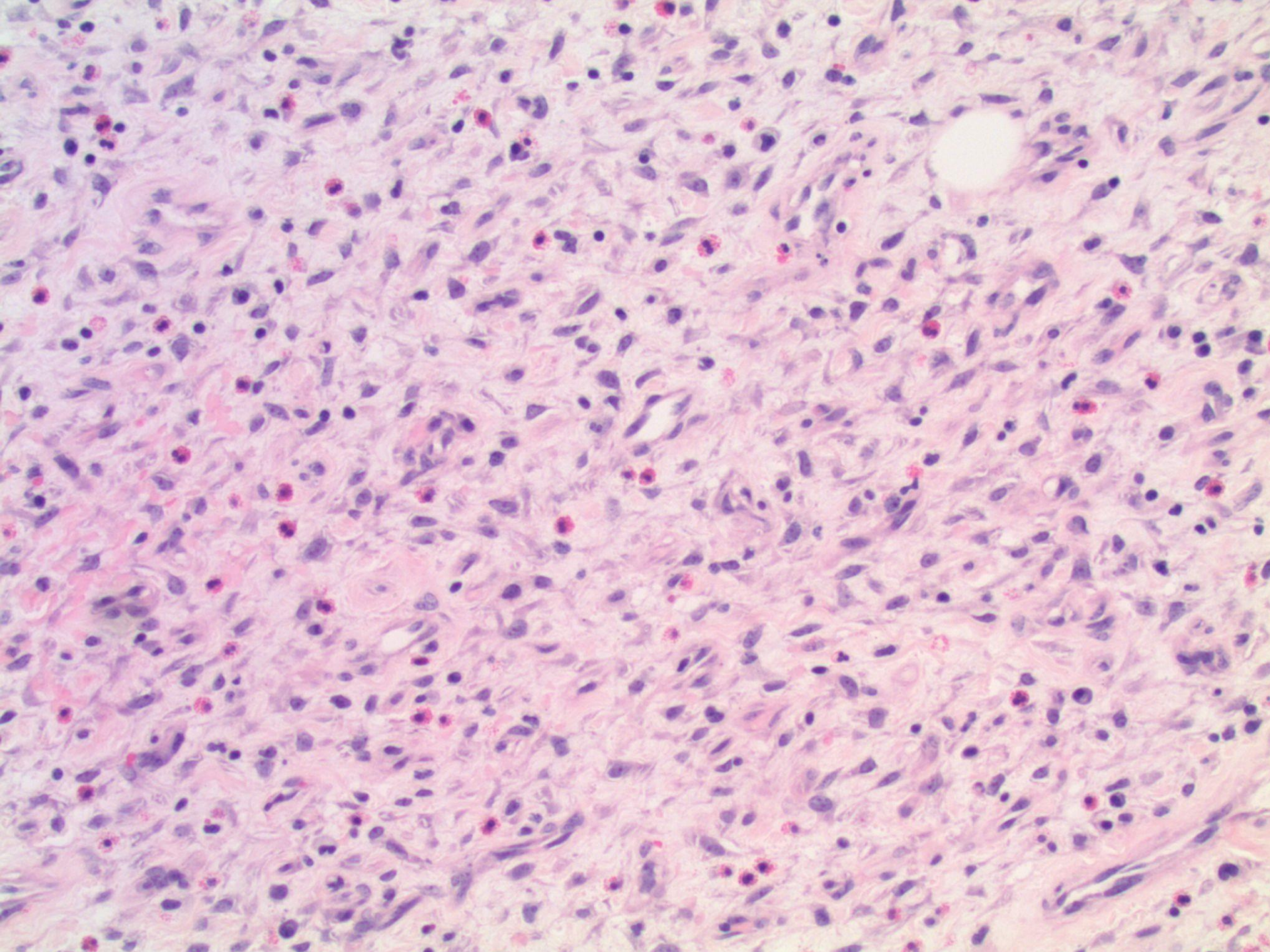




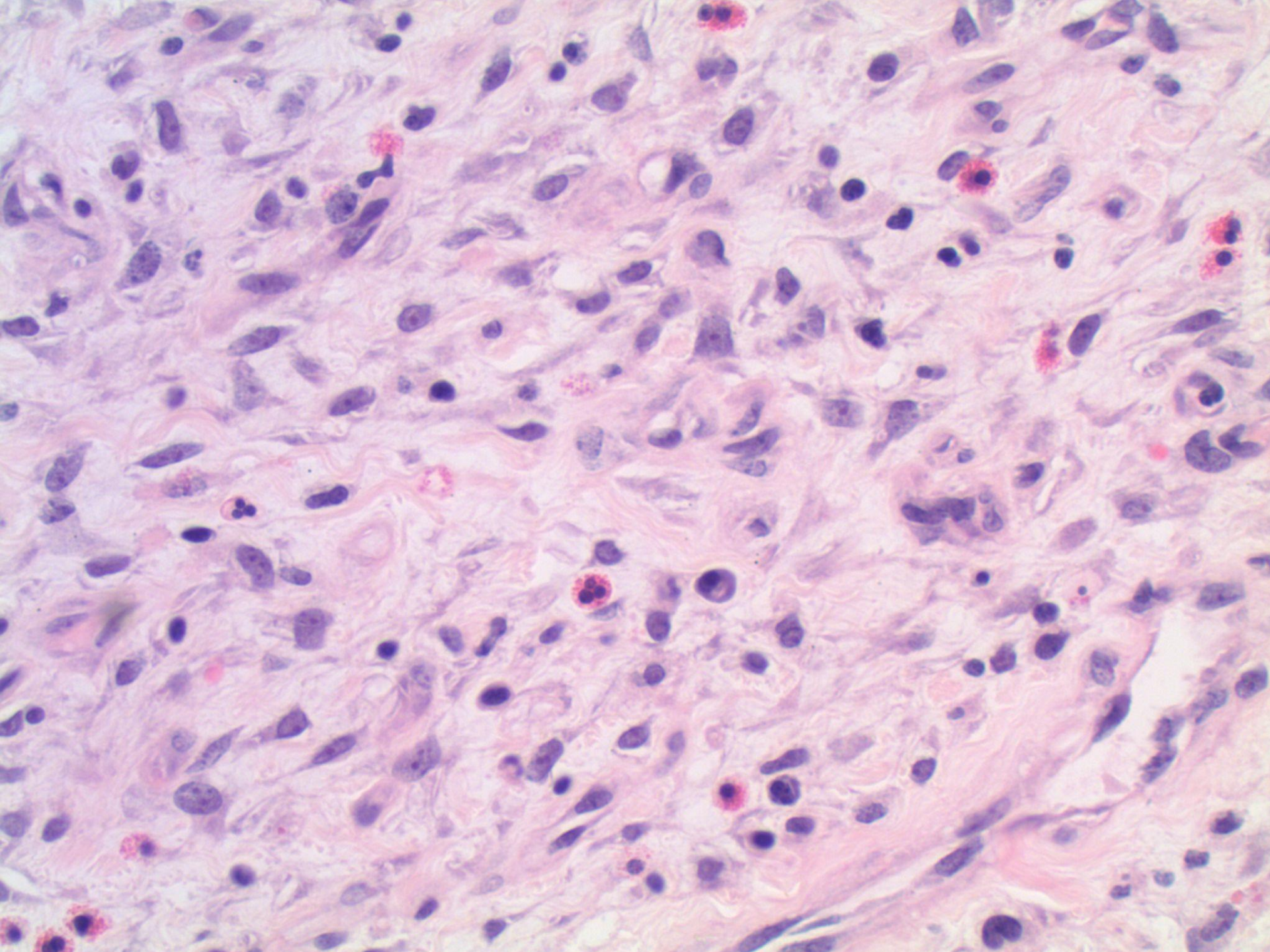












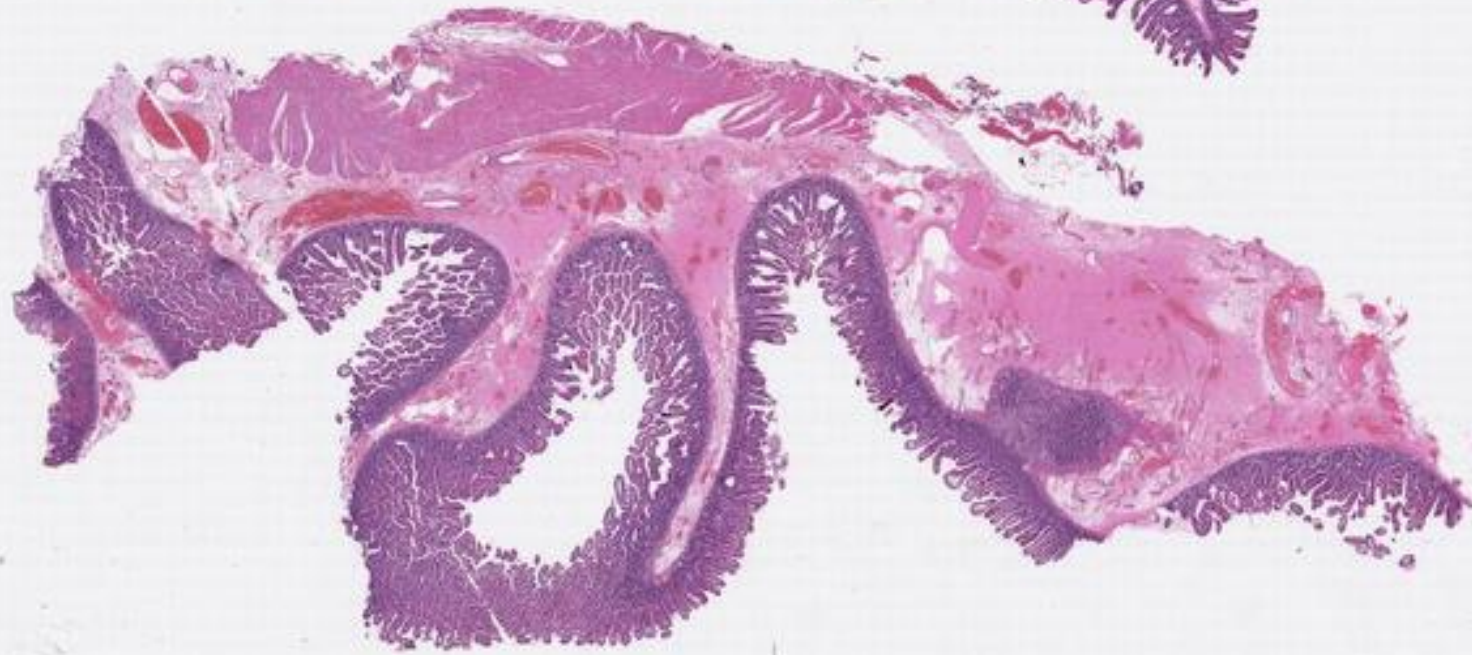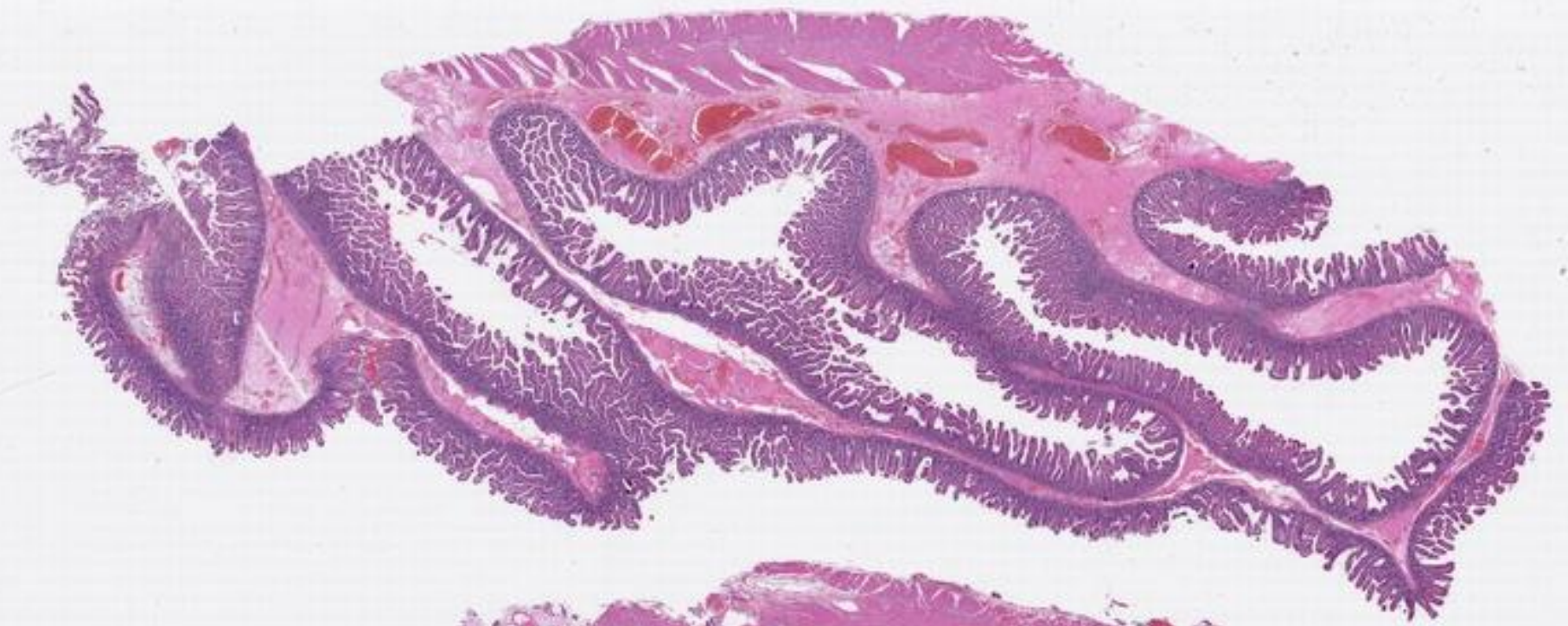


# SB 5897

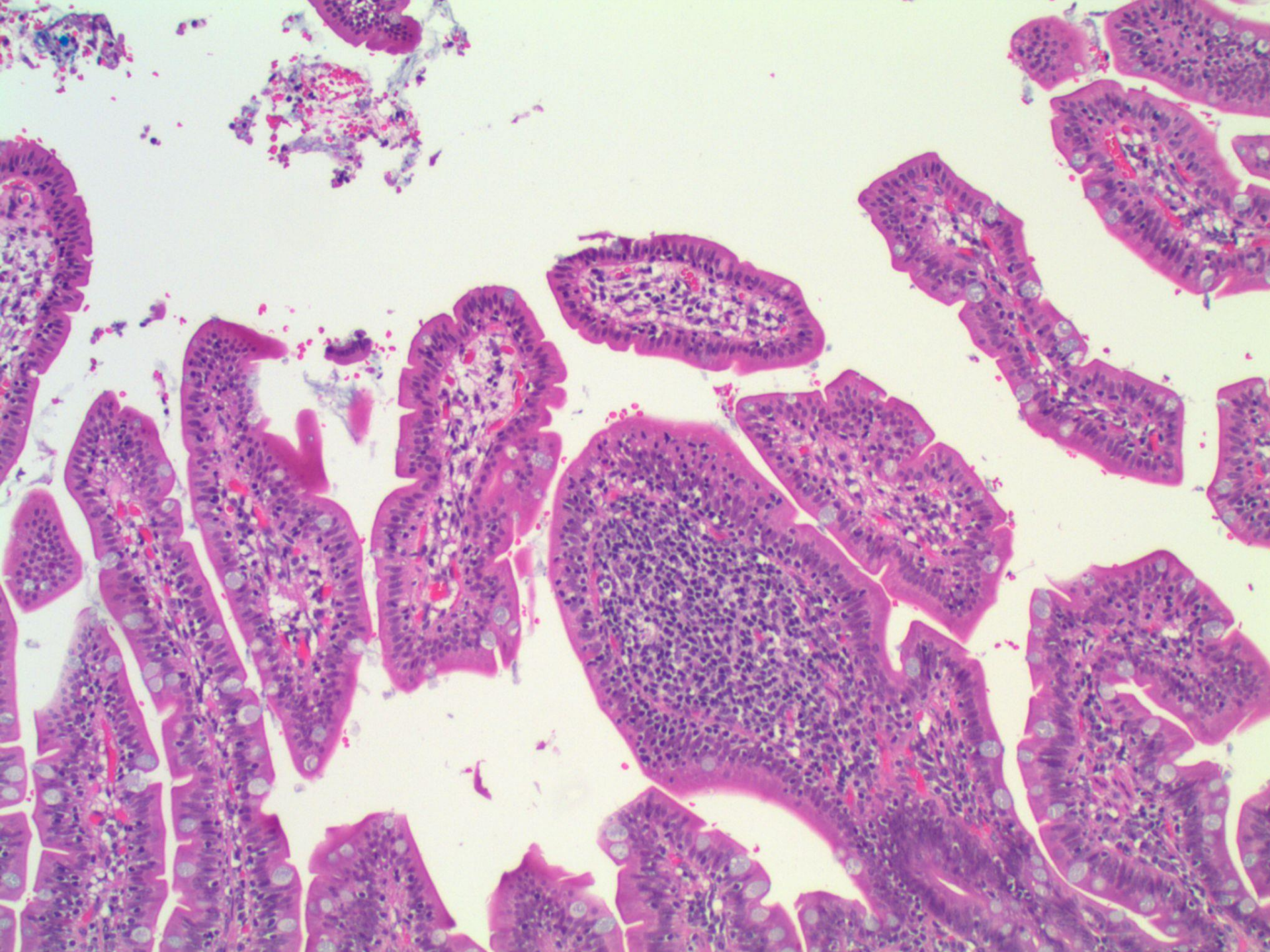
**Ankur Sangoi; El Camino Hospital,  
Mountain View, CA**

38-year-old woman with portion of jejunum  
resection during morbid obesity surgery.

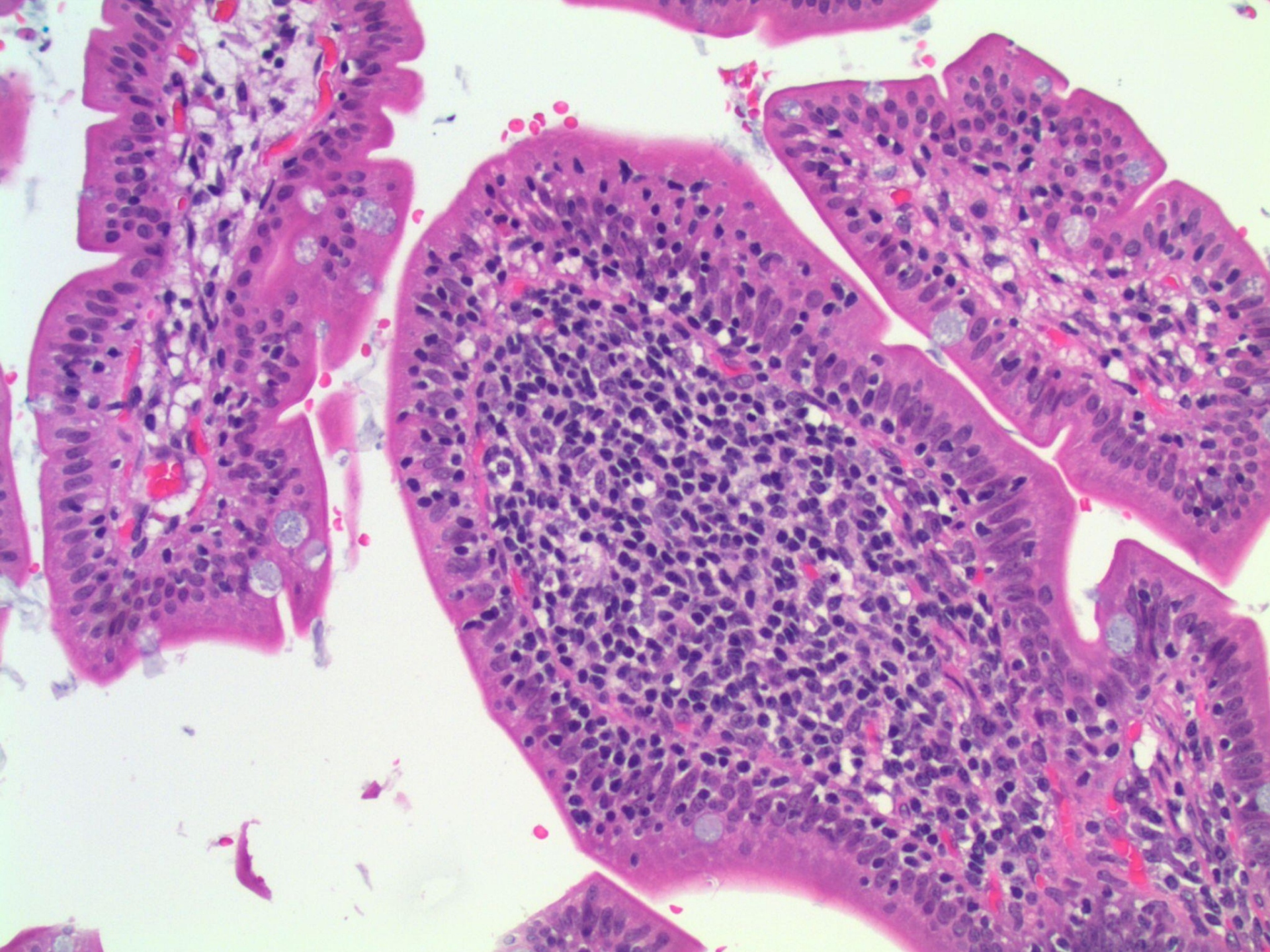




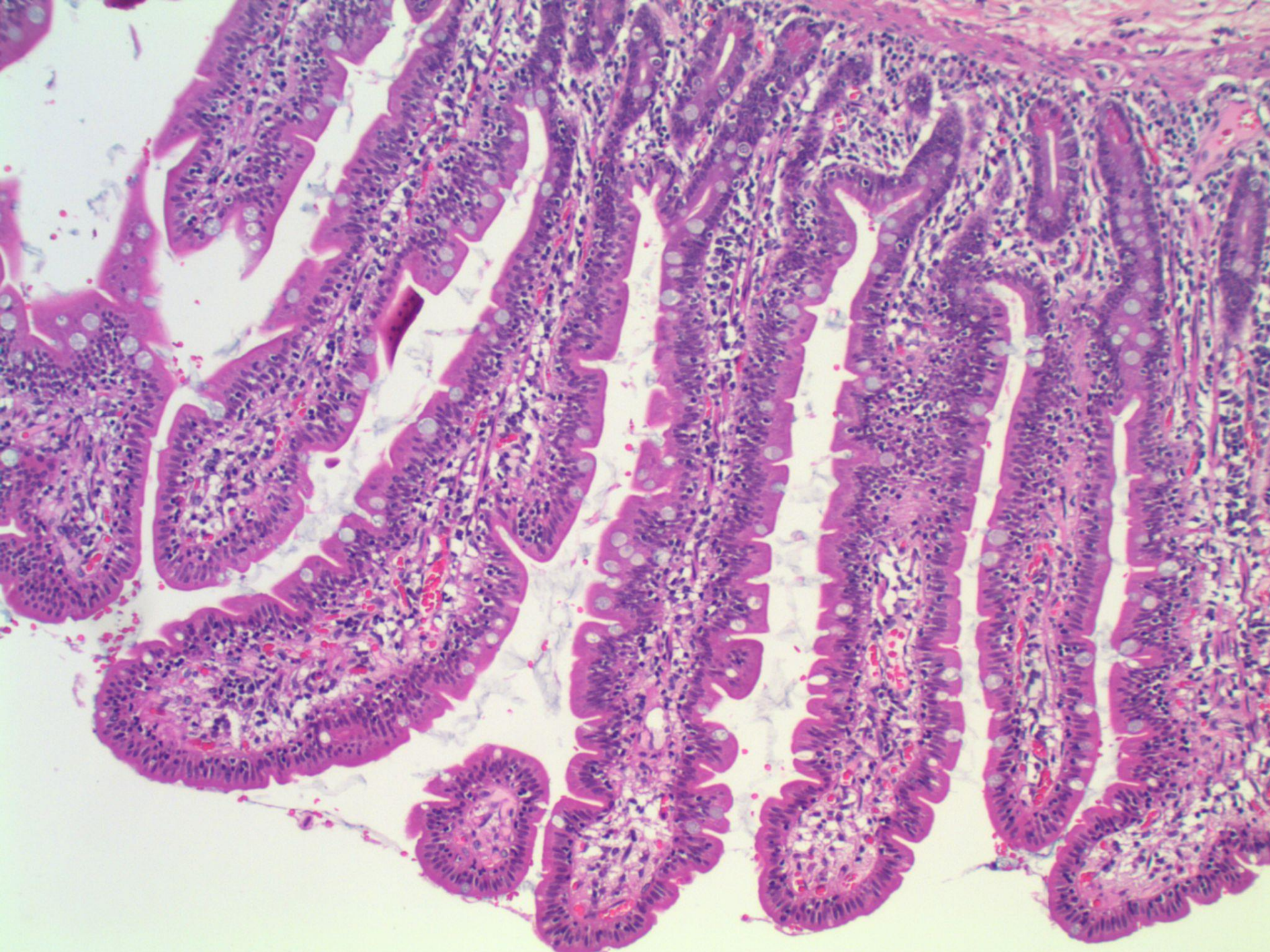




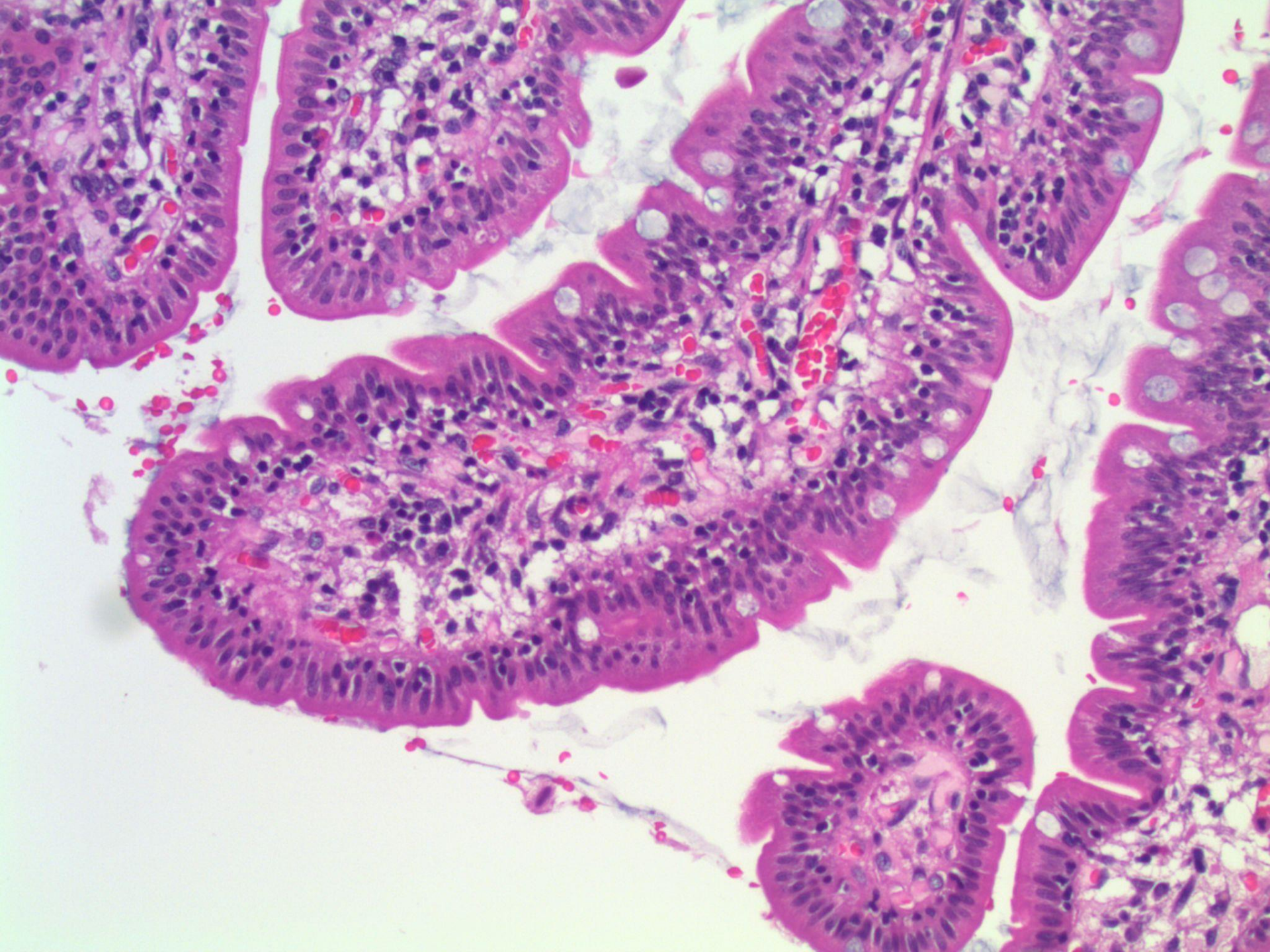




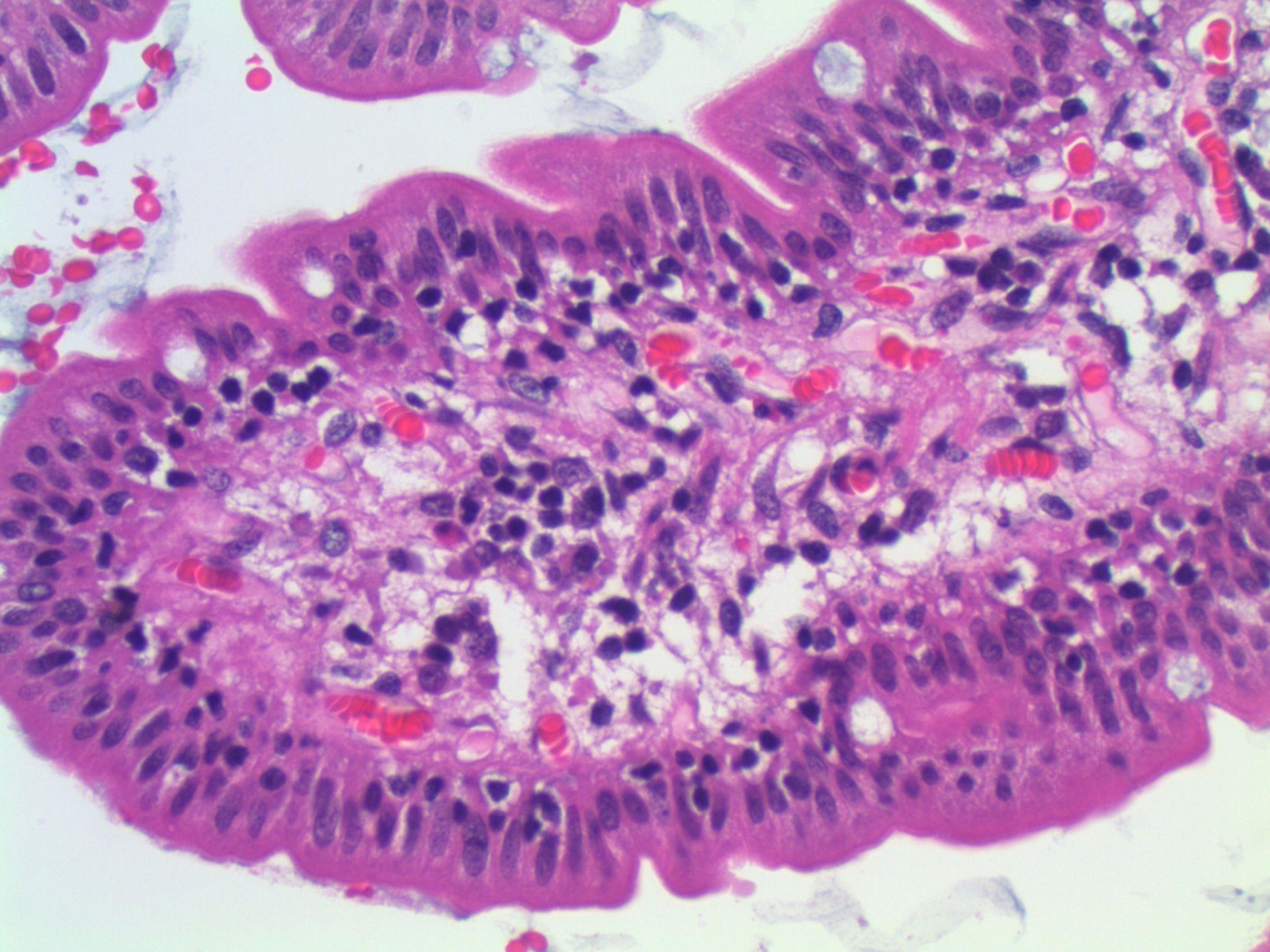












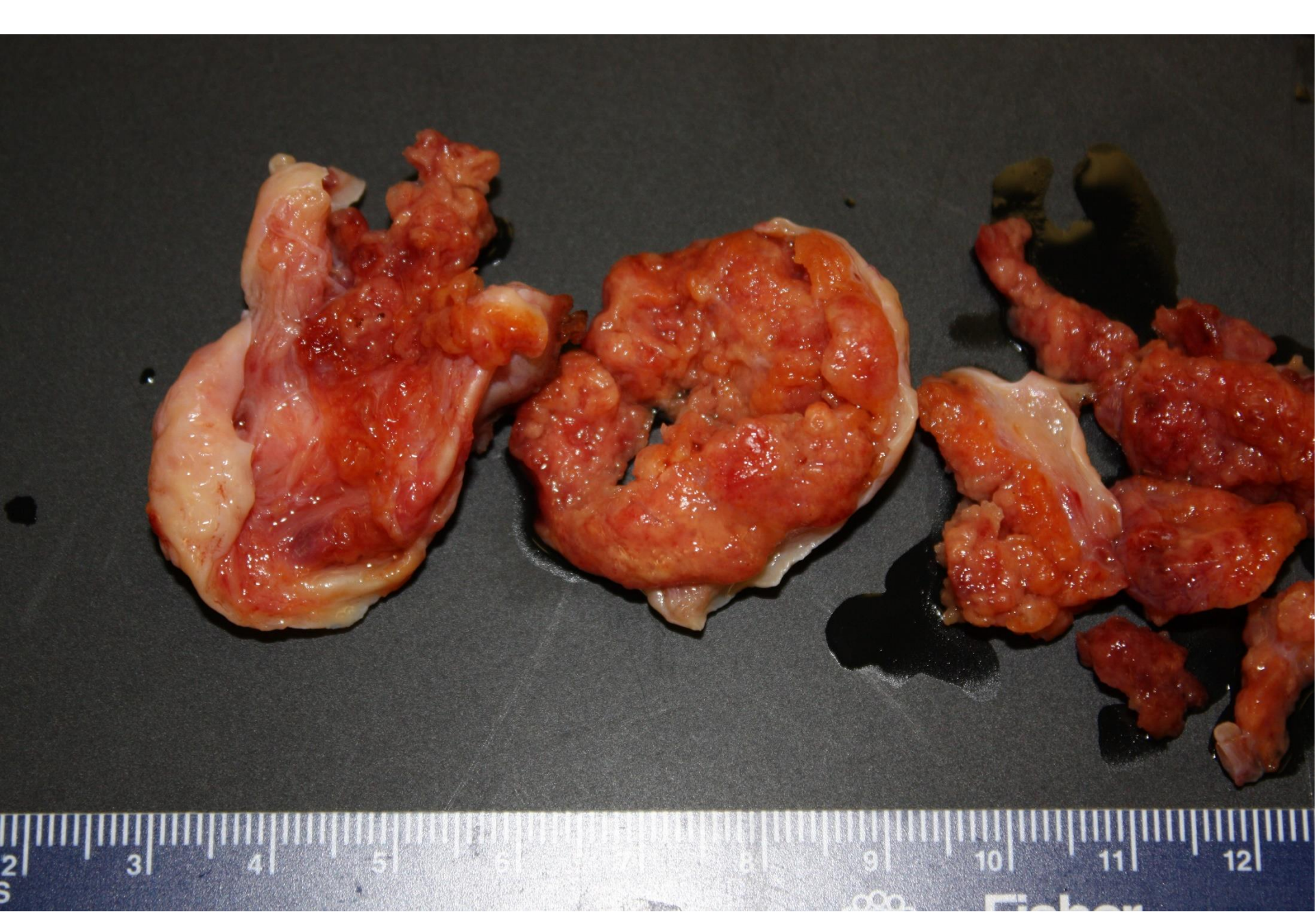


**SB 5898**

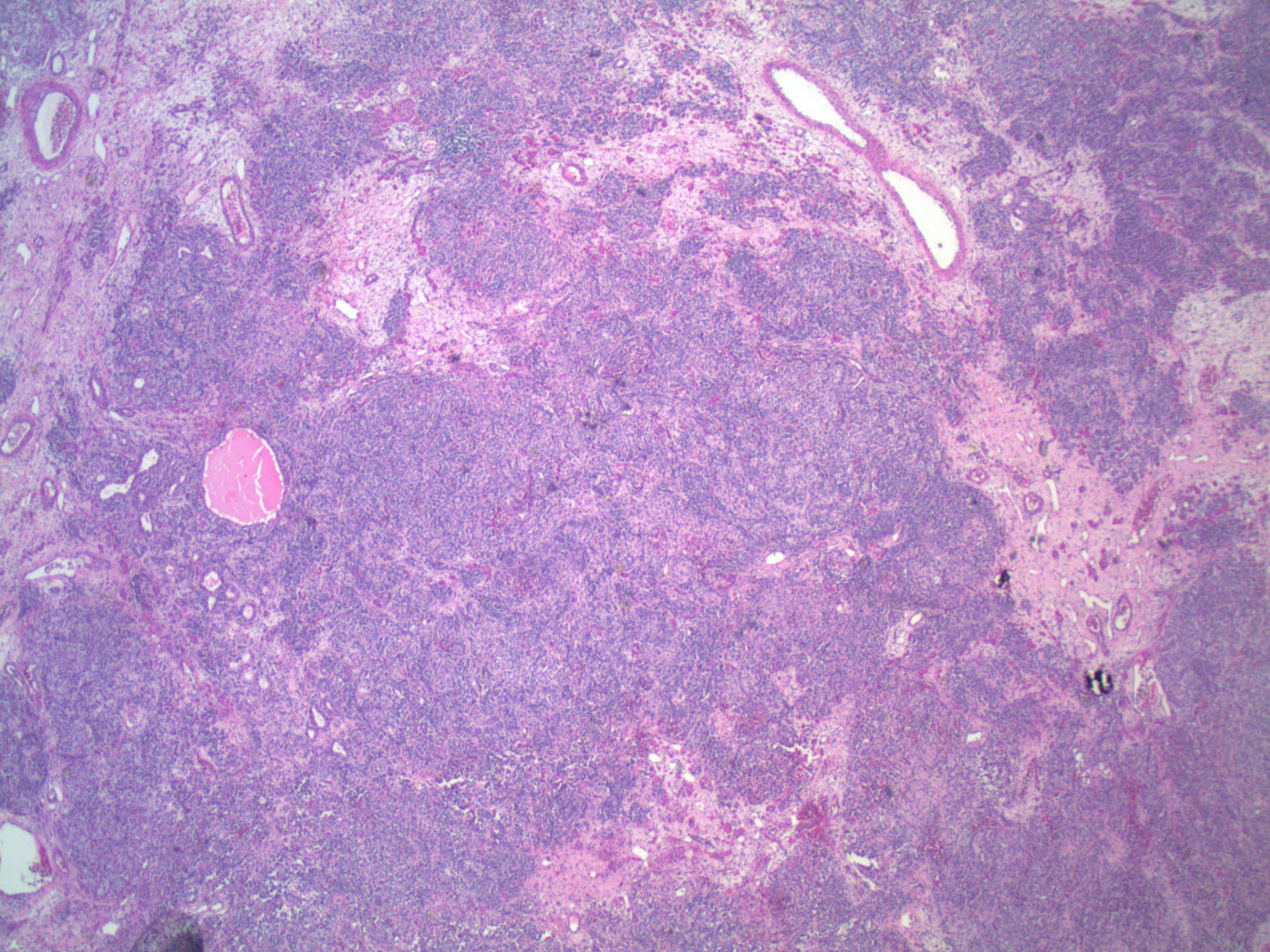
**Ankur Sangoi; El Camino Hospital,  
Mountain View, CA**

16-year-old girl with hirsutism and right  
ovarian mass. Serum AFP within normal  
limits.

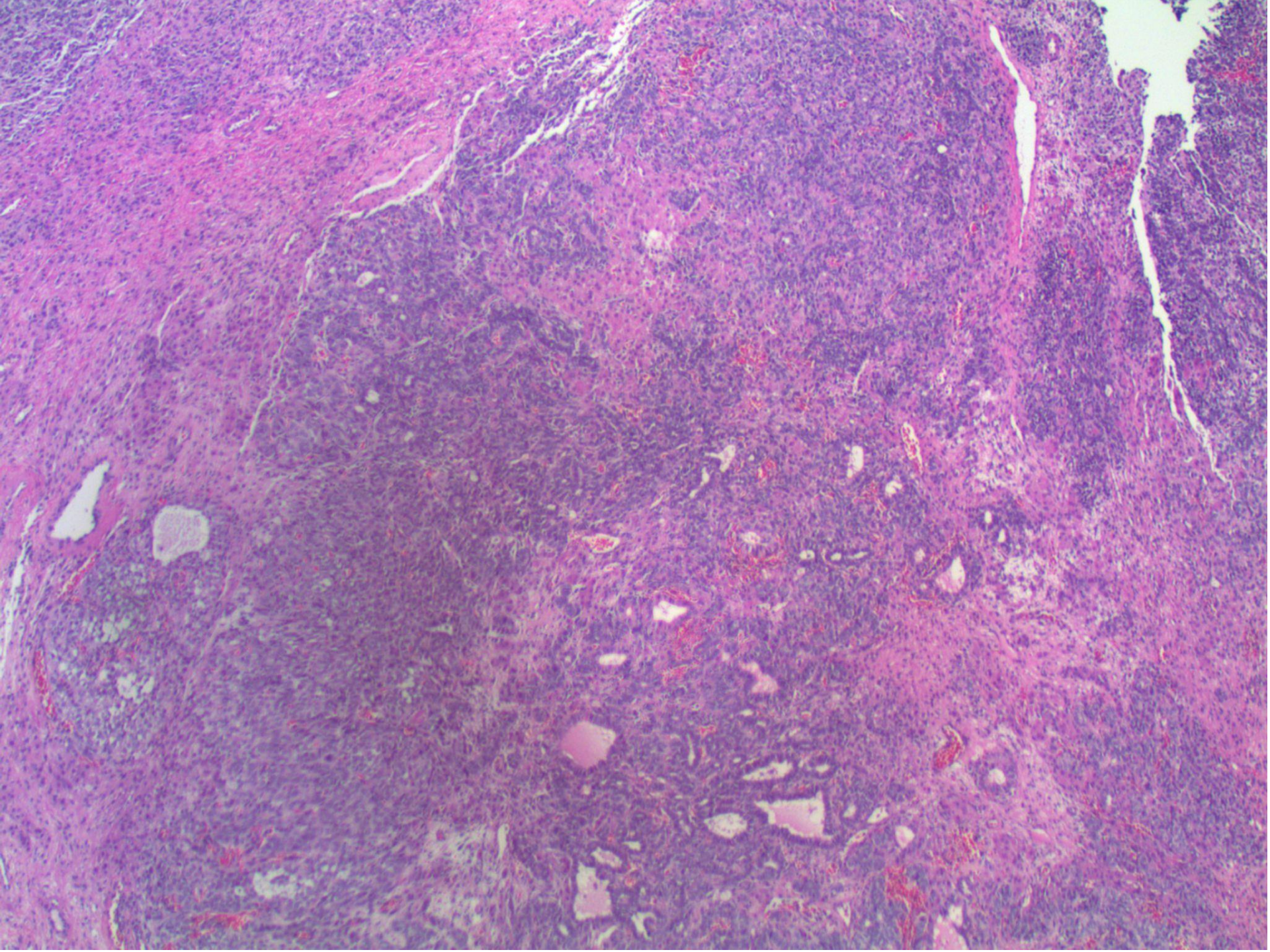




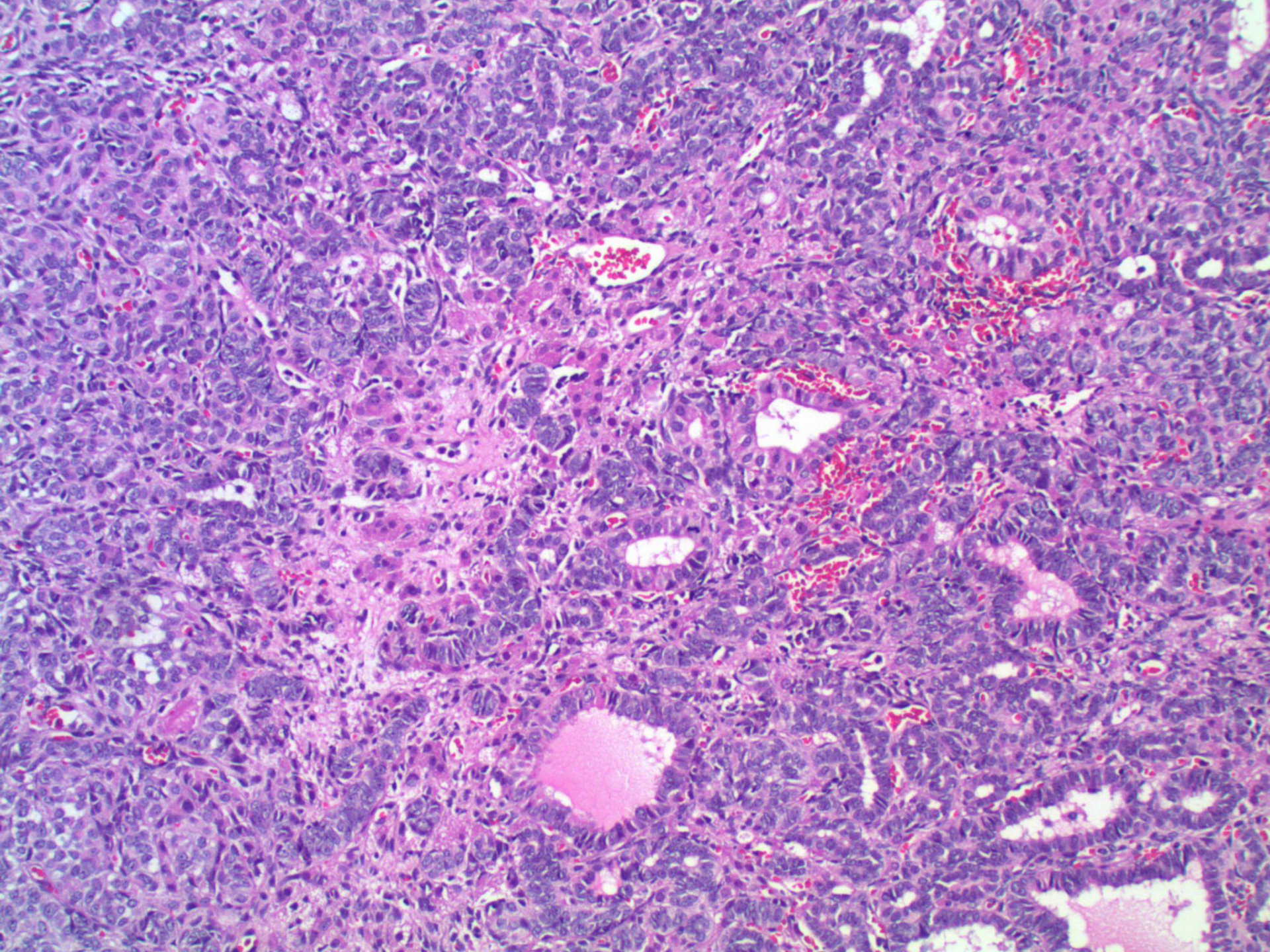




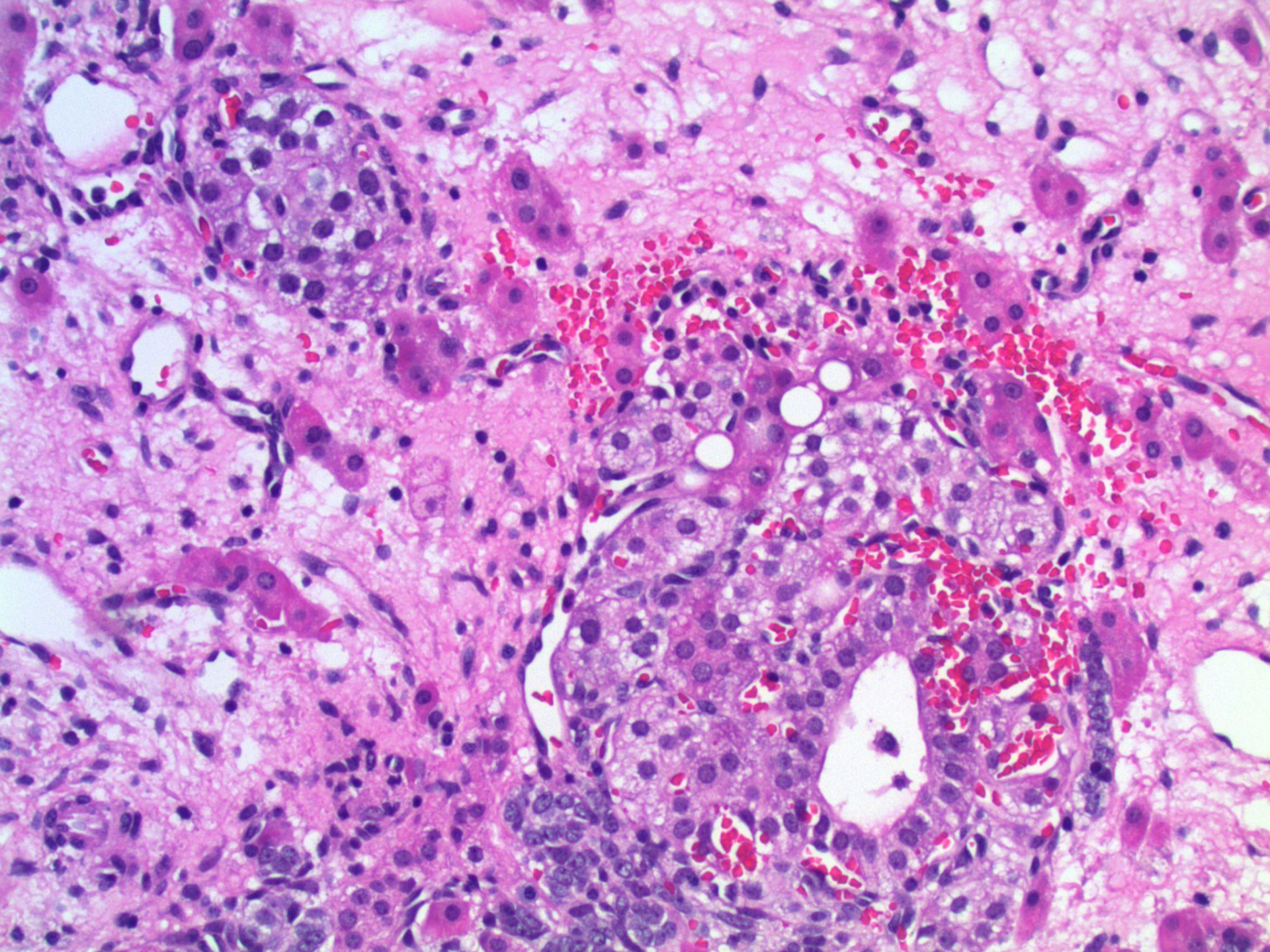












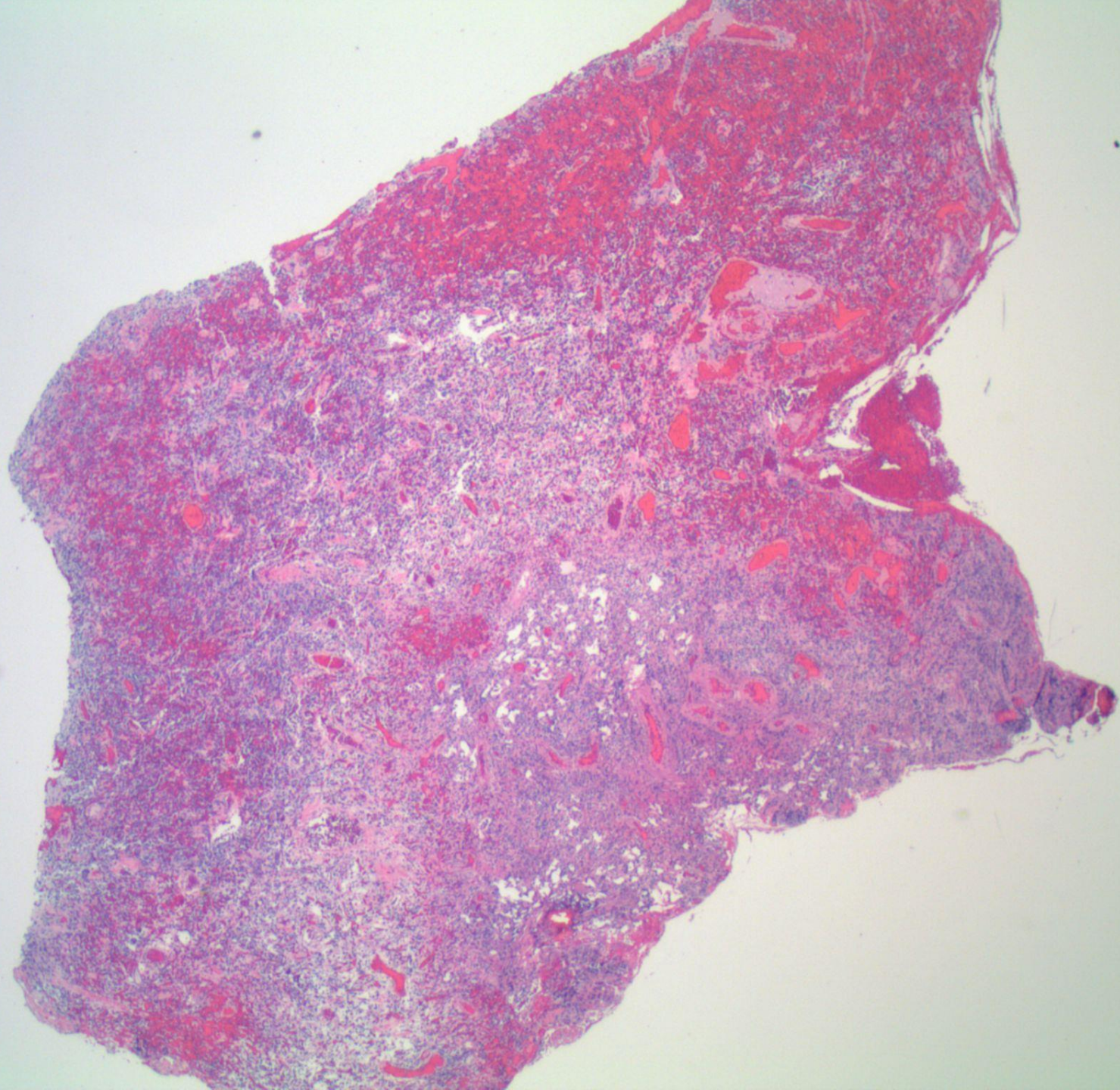


**SB 5899**

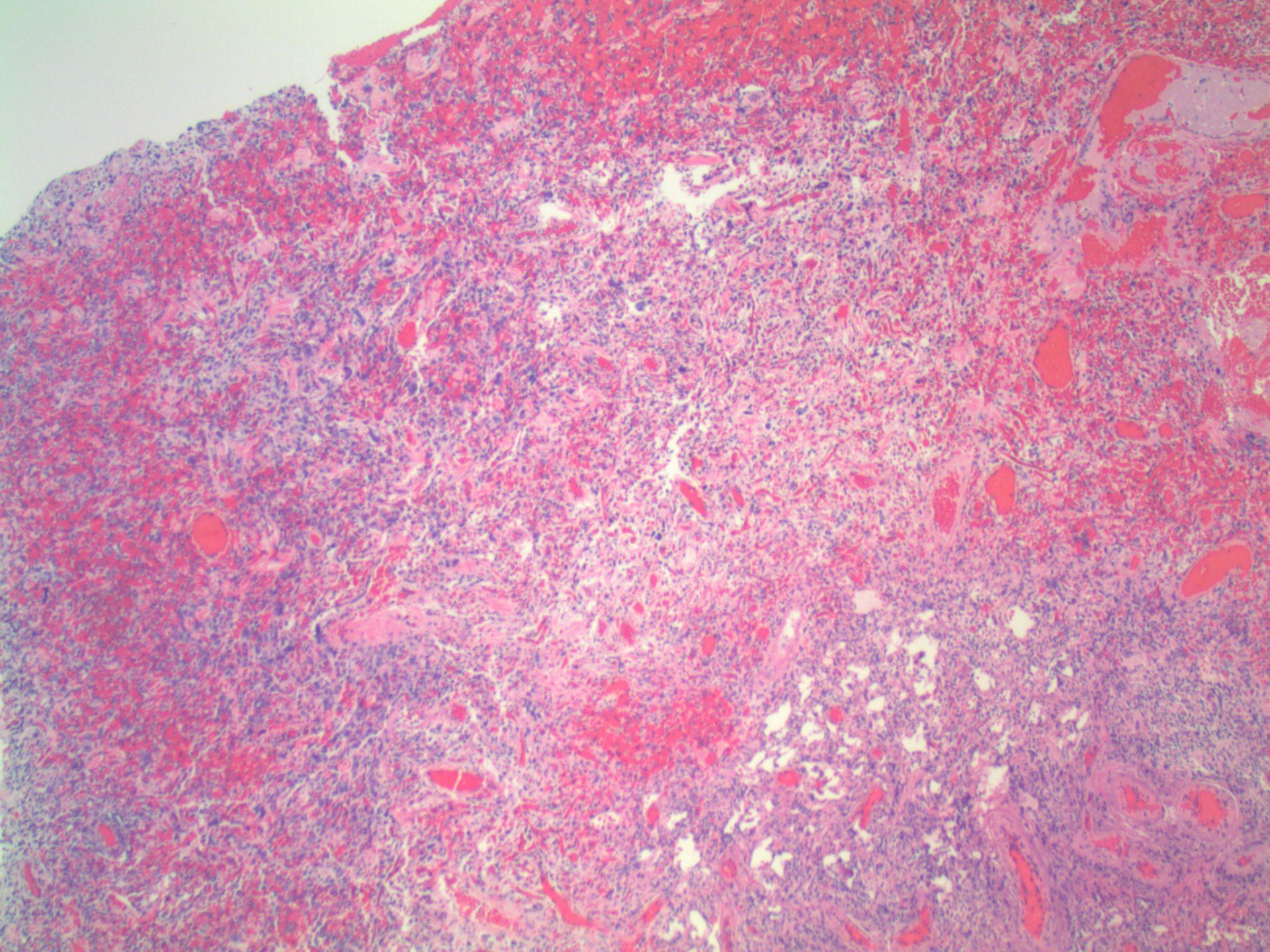
**Jennifer Ziskin/Ed Plowey; Stanford,  
Stanford, CA**

42-year-old man with an extraconal  
inferior orbital soft tissue tumor.

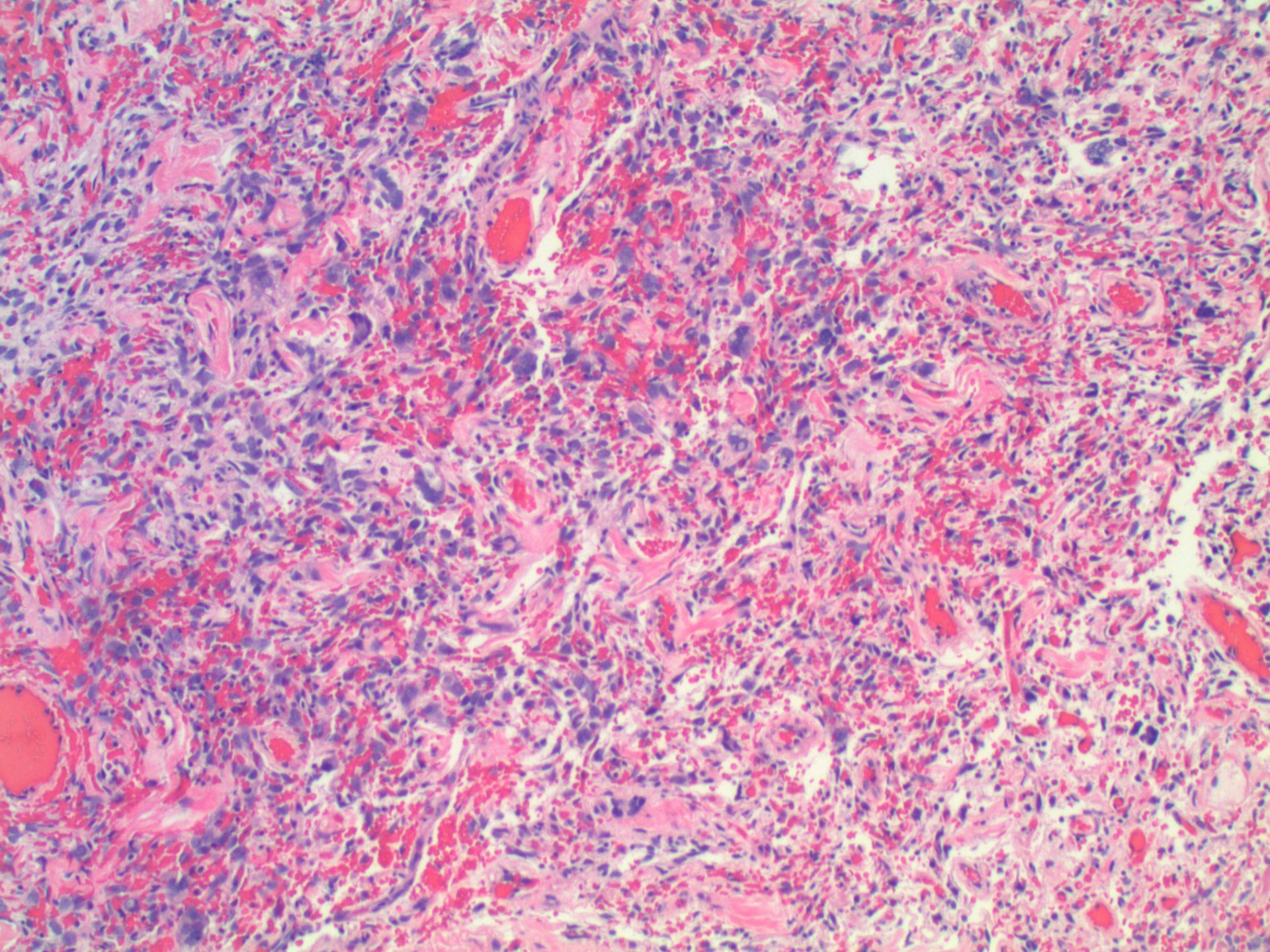




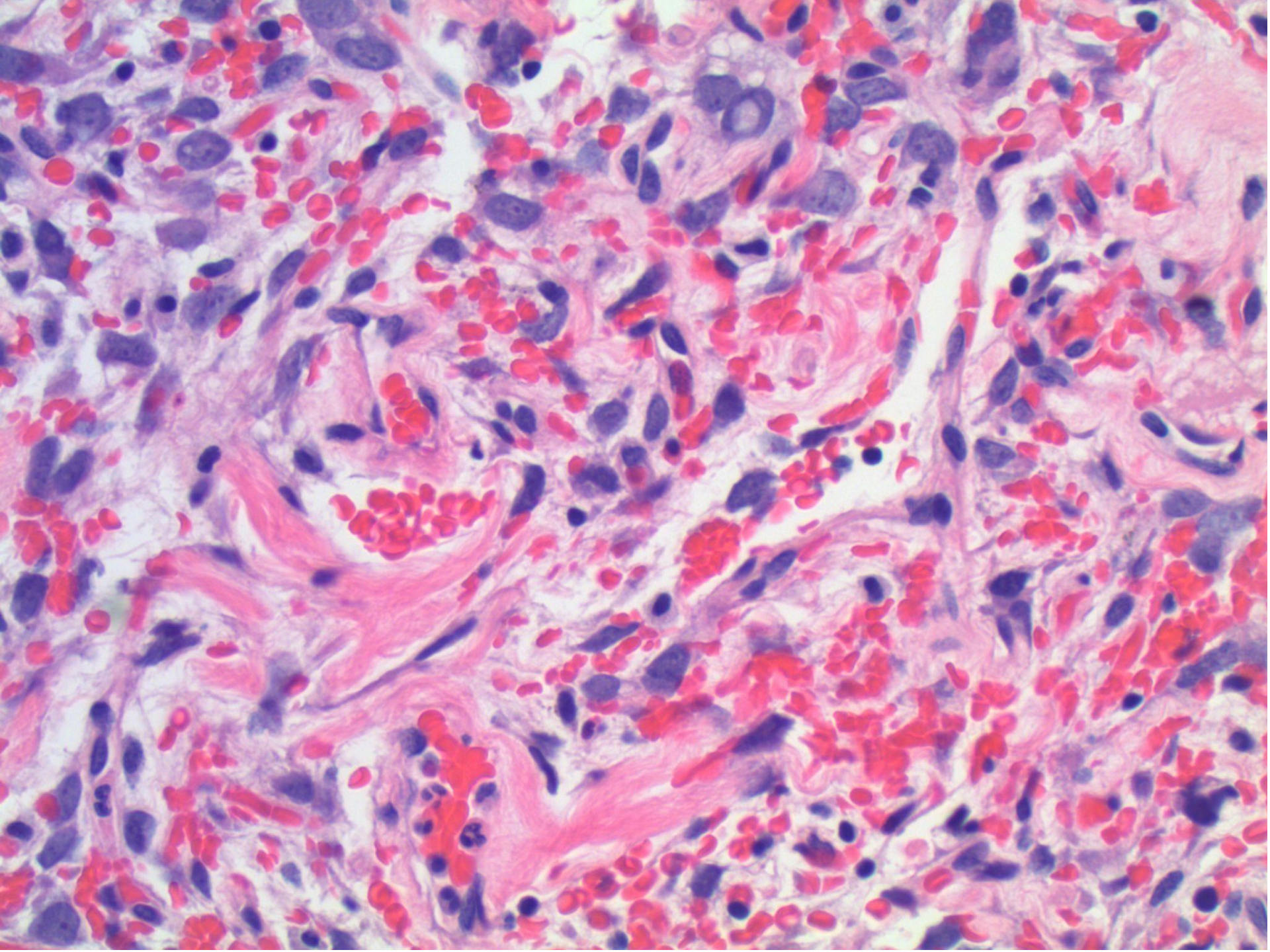




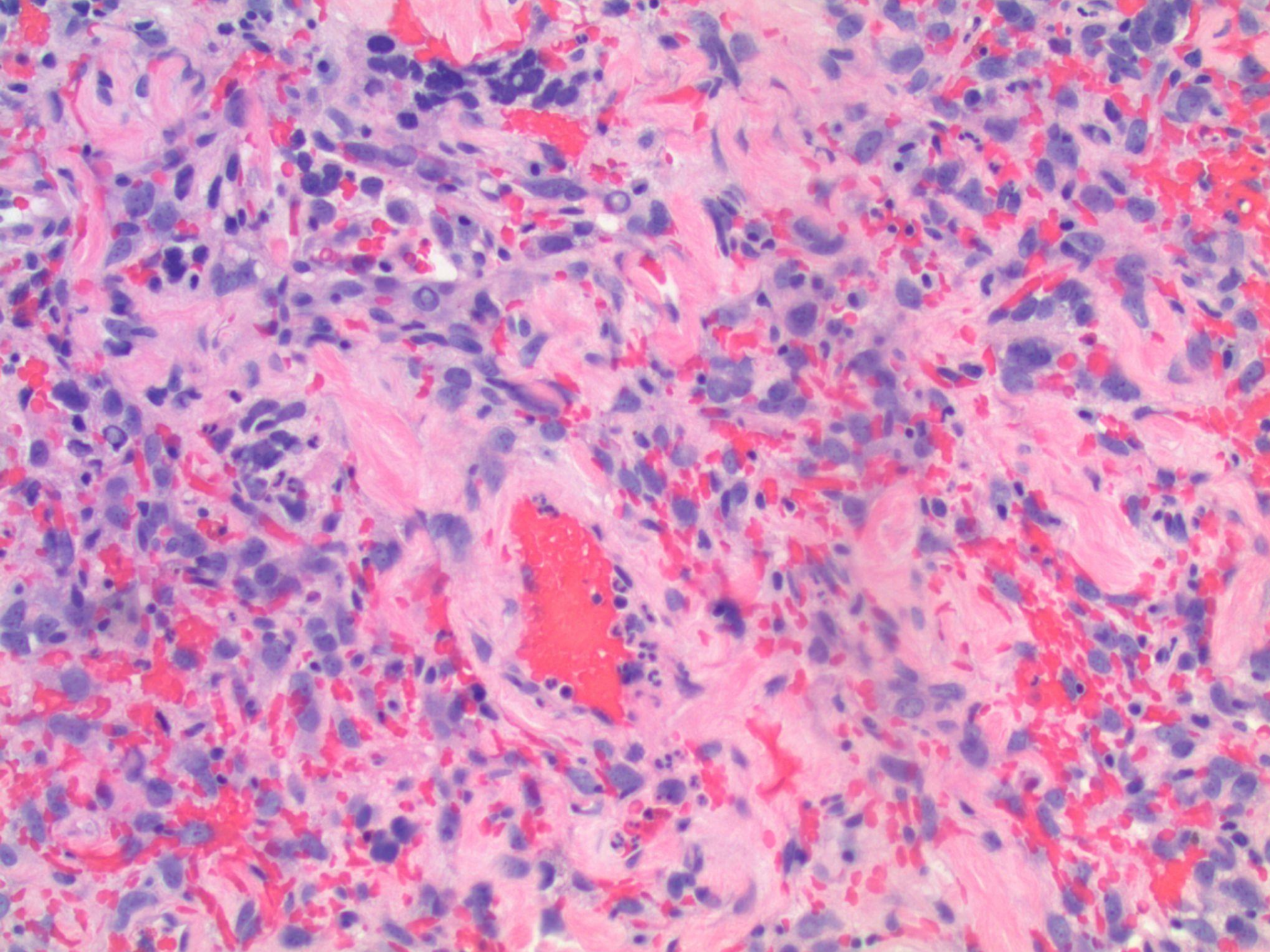




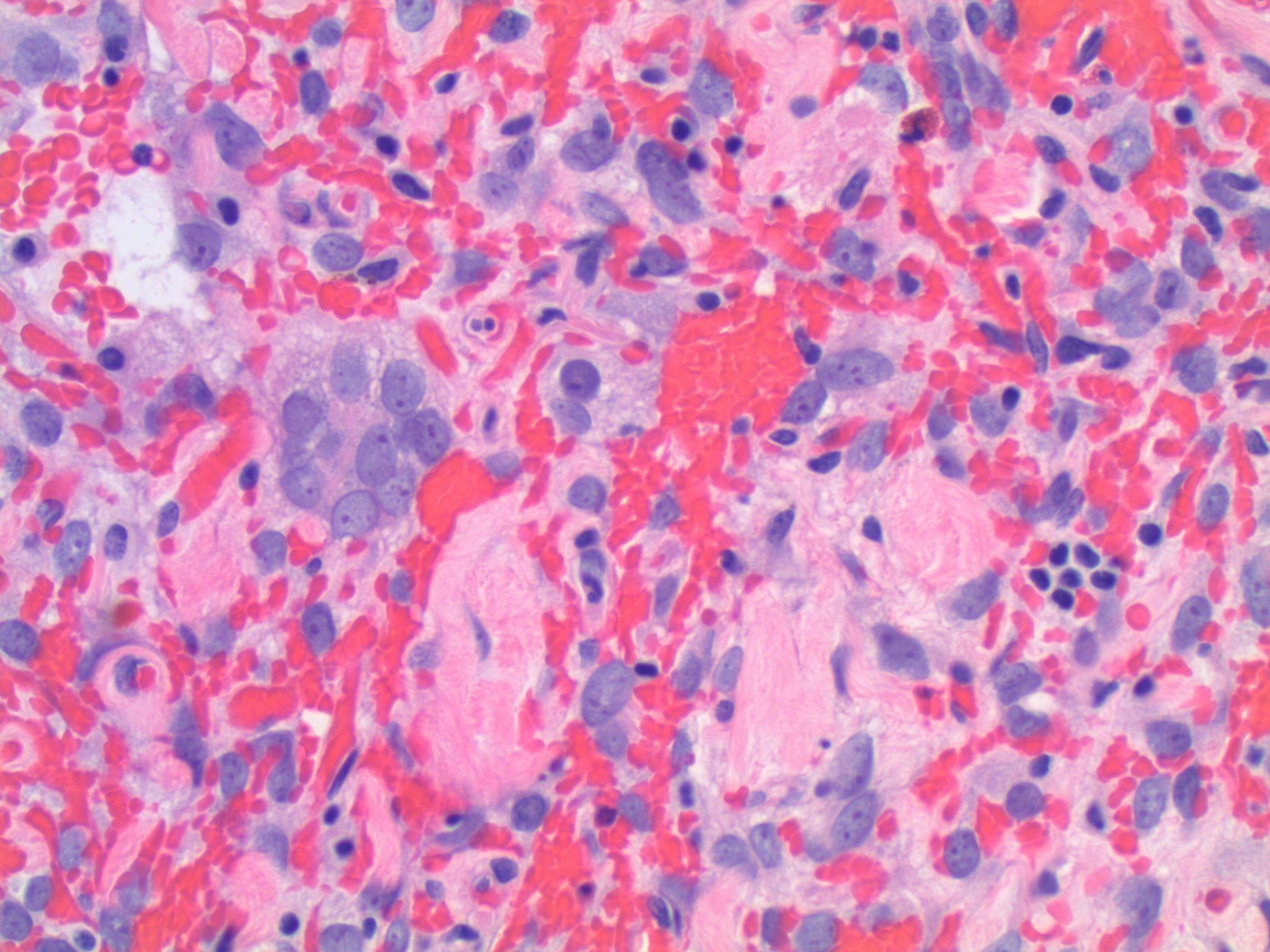














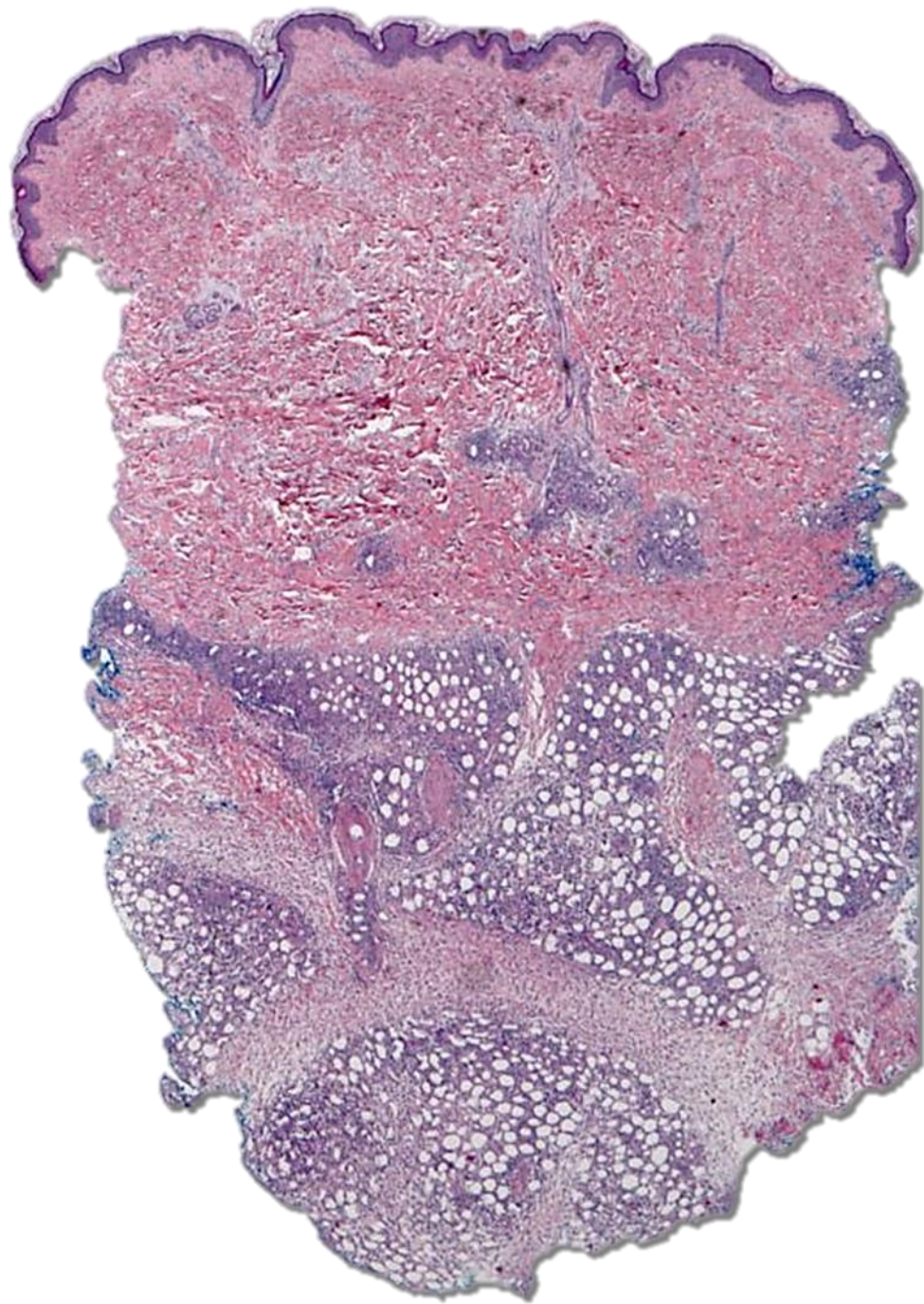
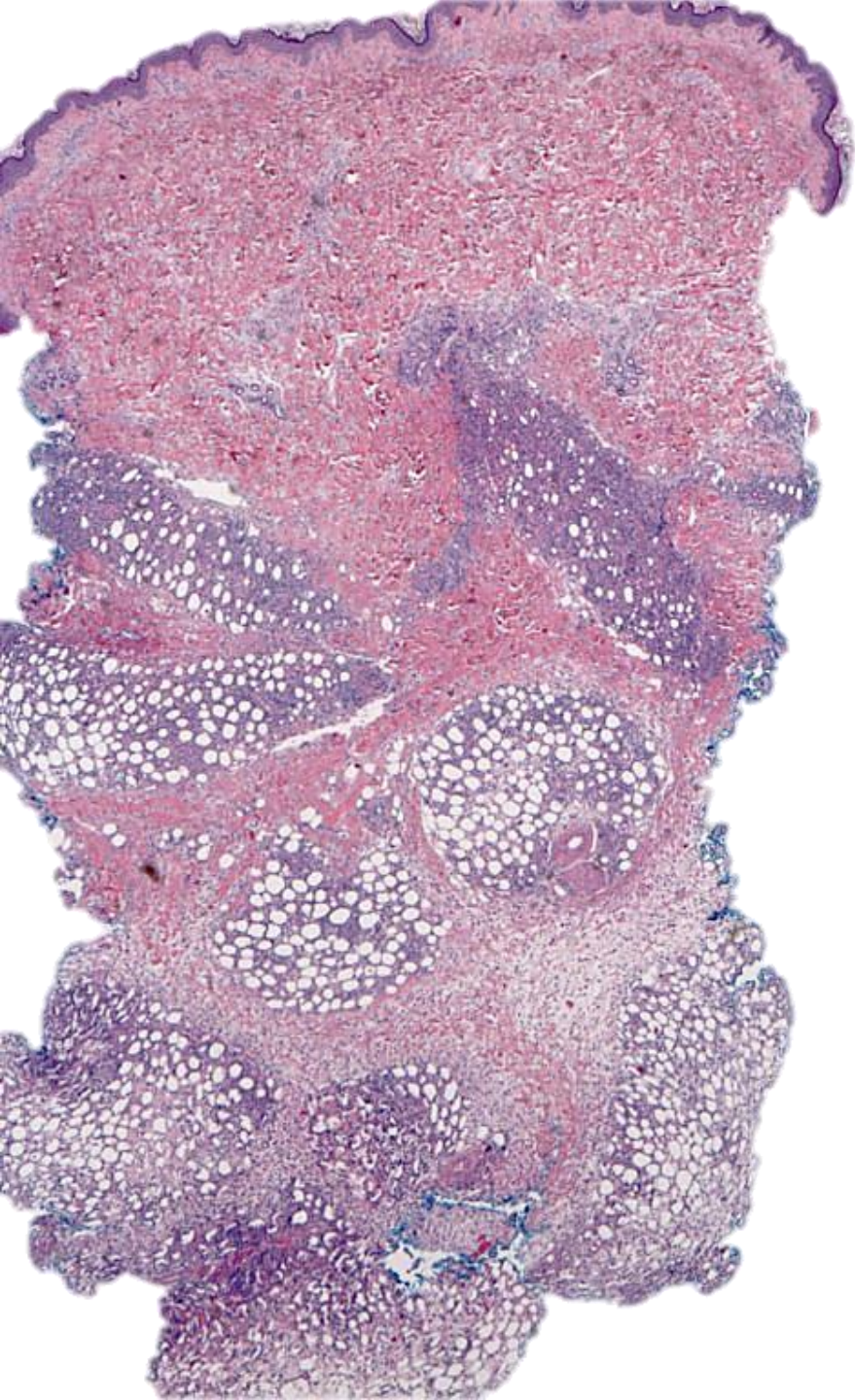
# SB 5887

## (from November 2014)

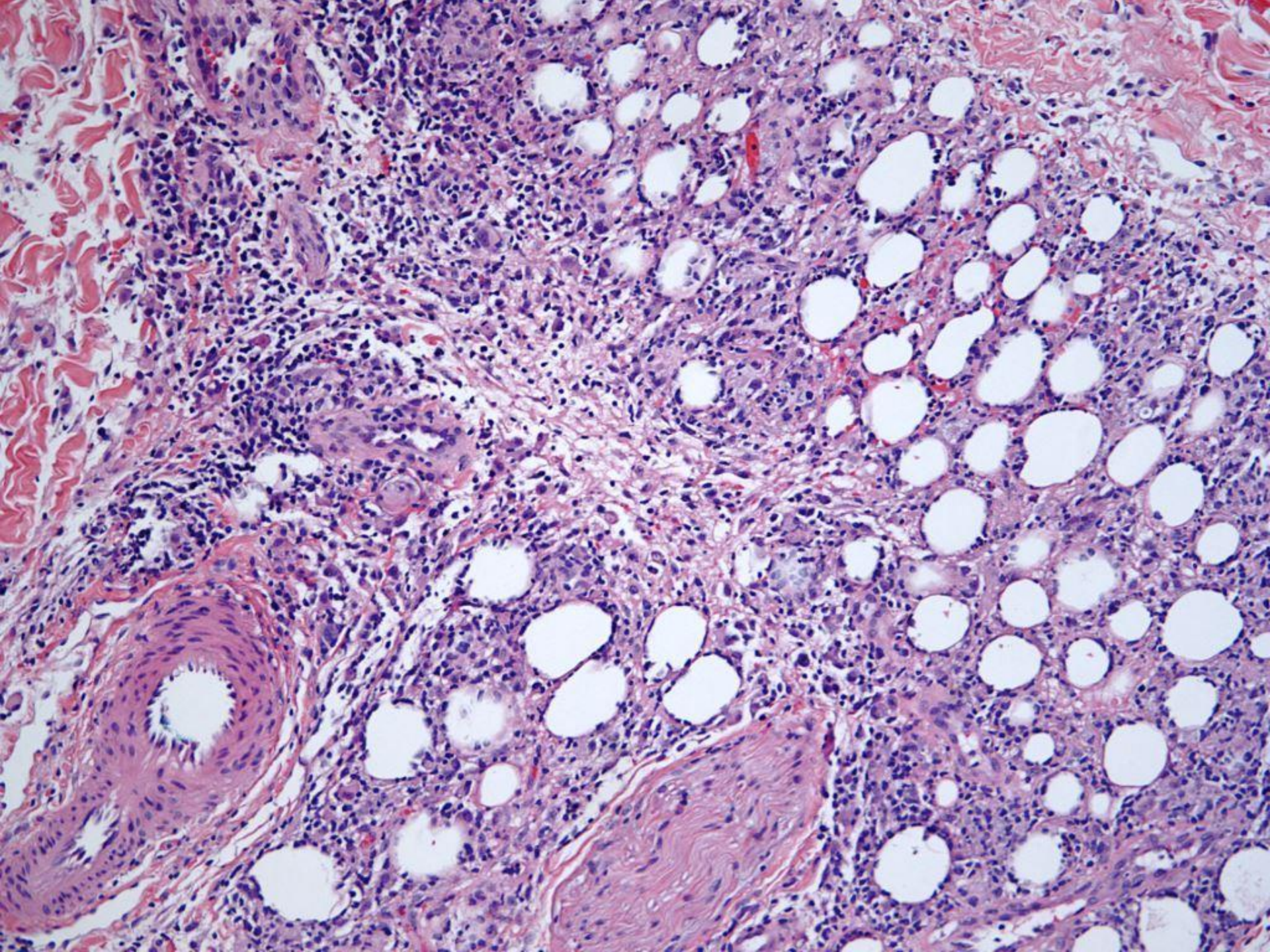
**(from November 2014) Robert LeBlanc/Jinah Kim;  
Stanford, Stanford, CA**

14-year-old female with fever, fatigue, and a several week history of tender, erythematous and ill-defined subcutaneous nodules on her arm, chin, and lower abdomen.

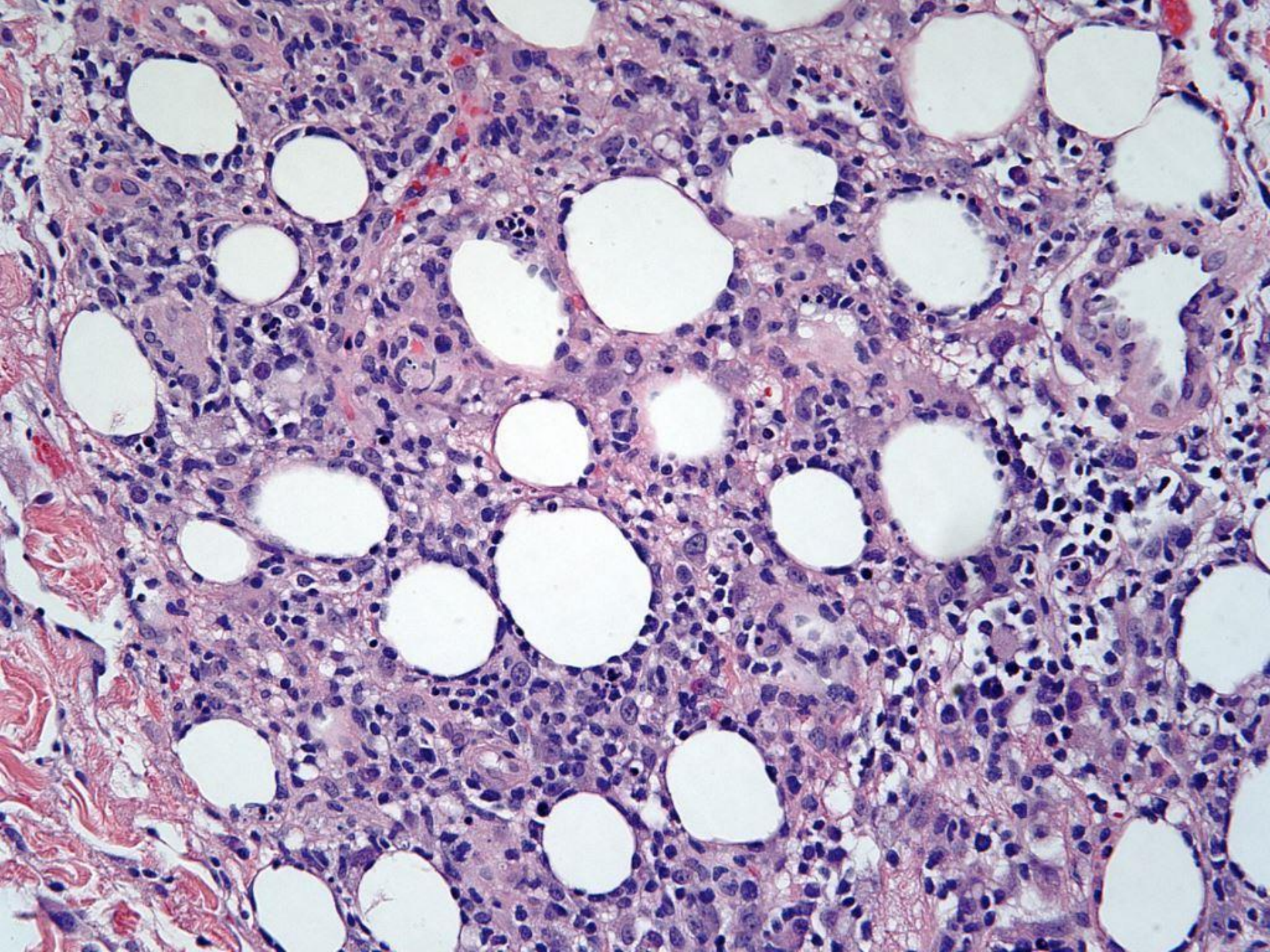




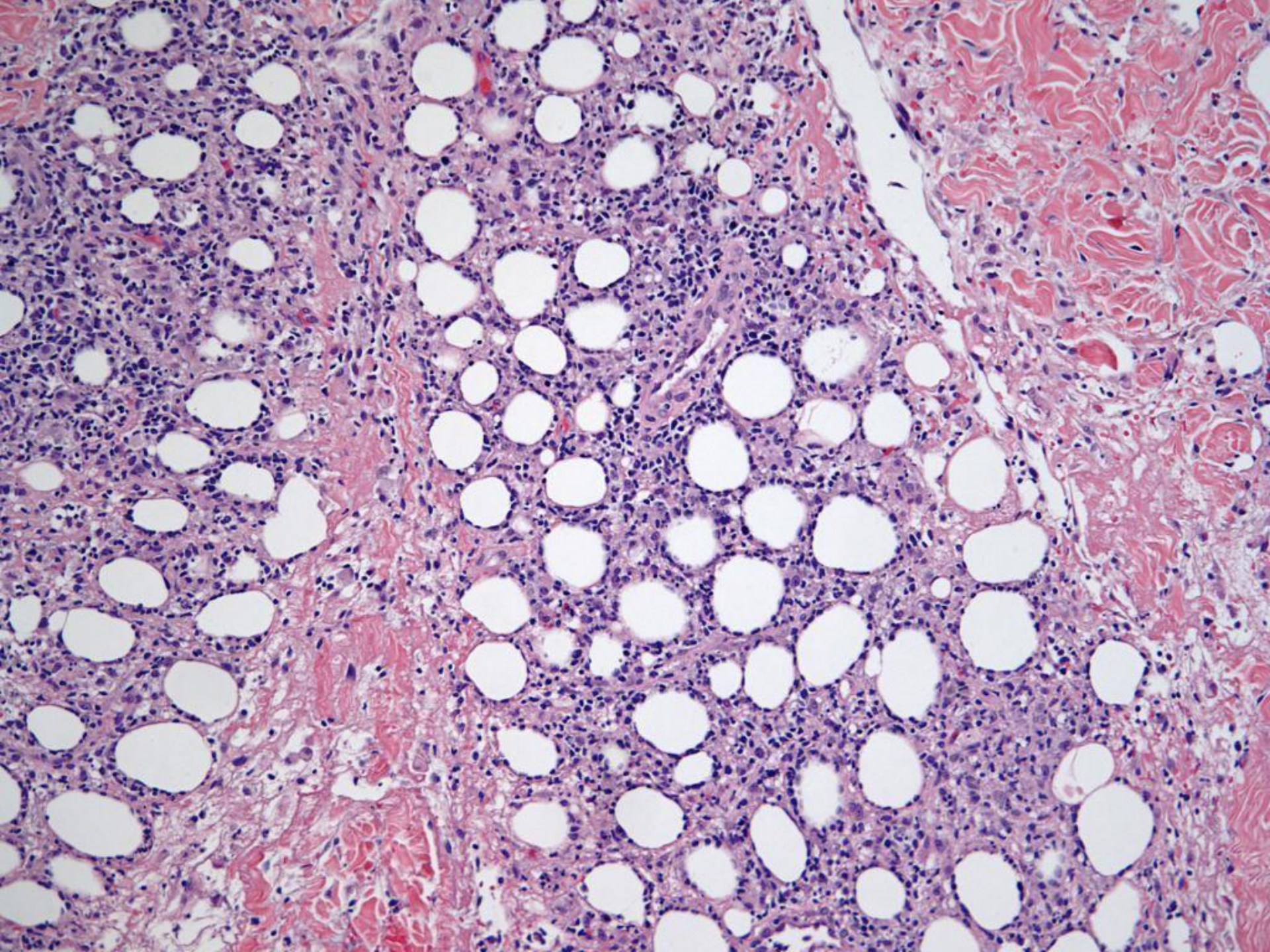




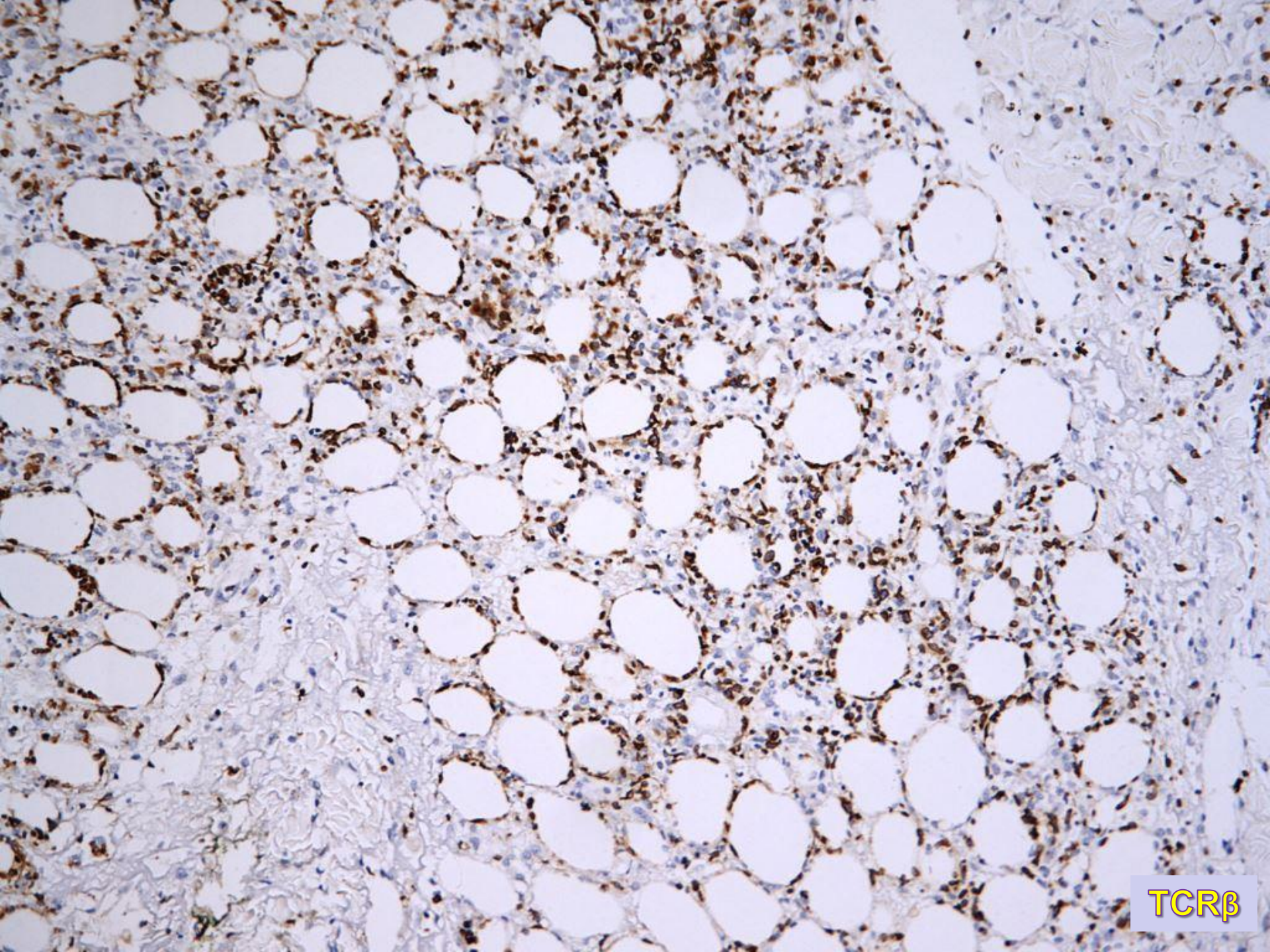






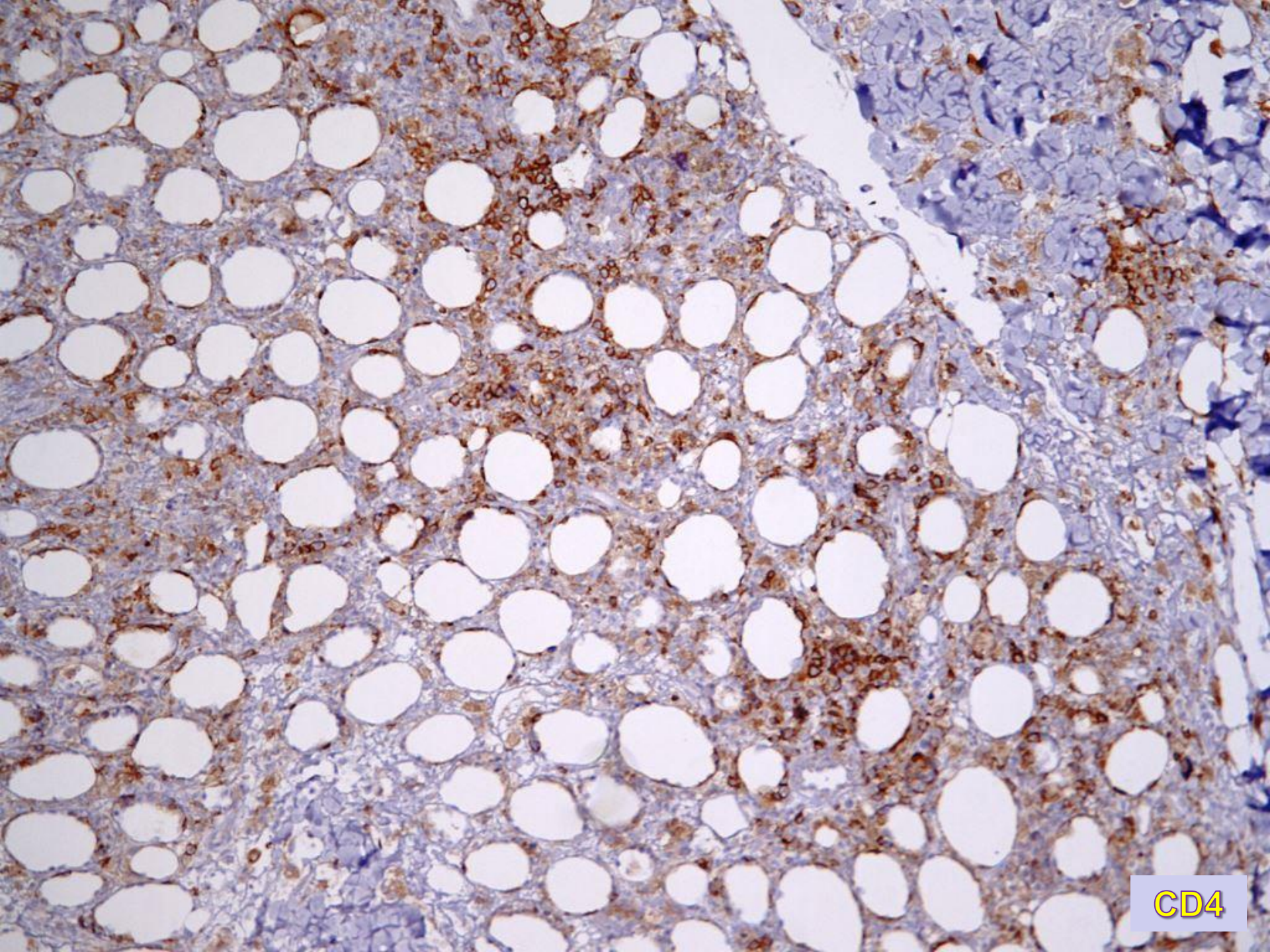






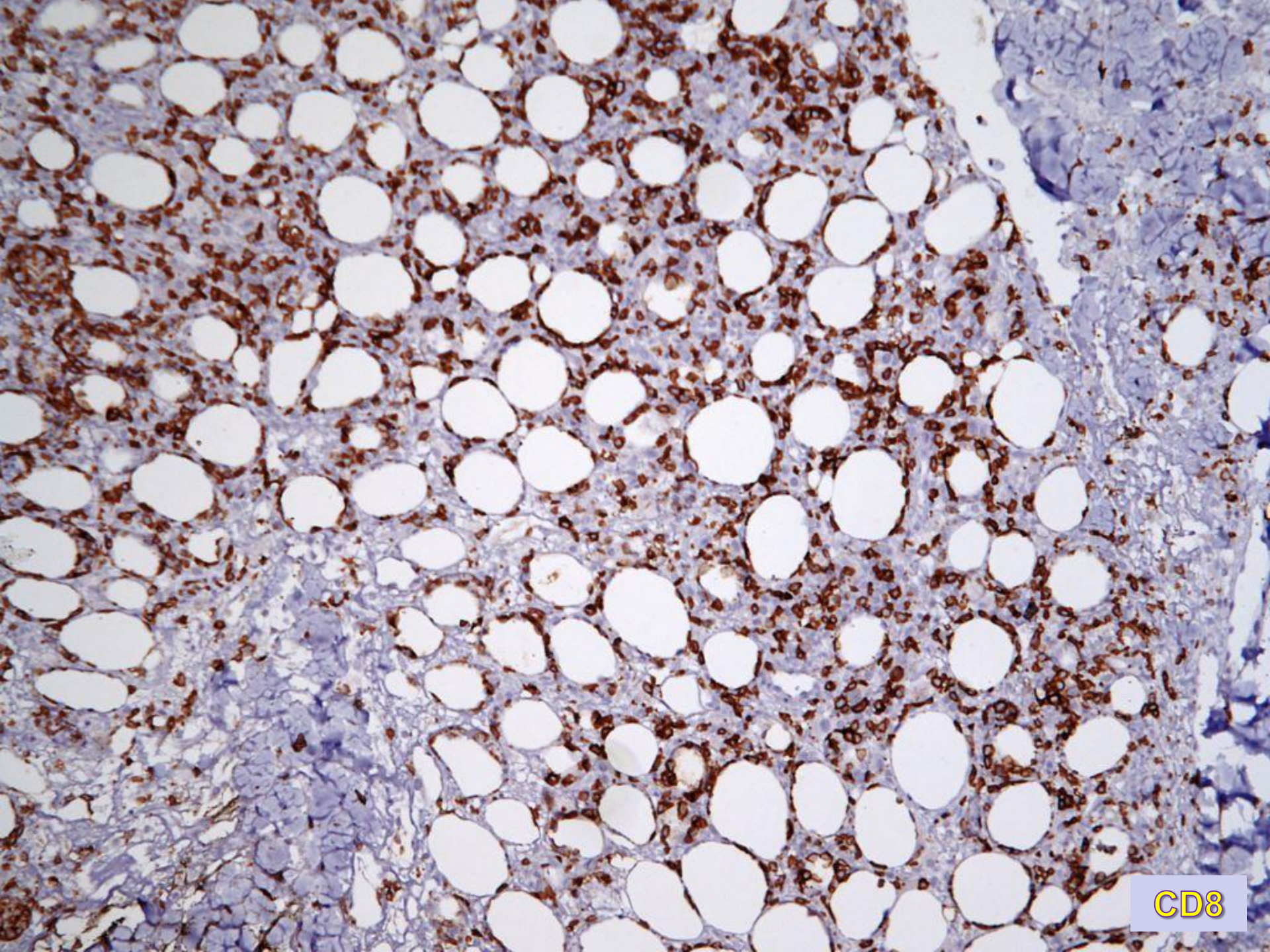
TCRβ





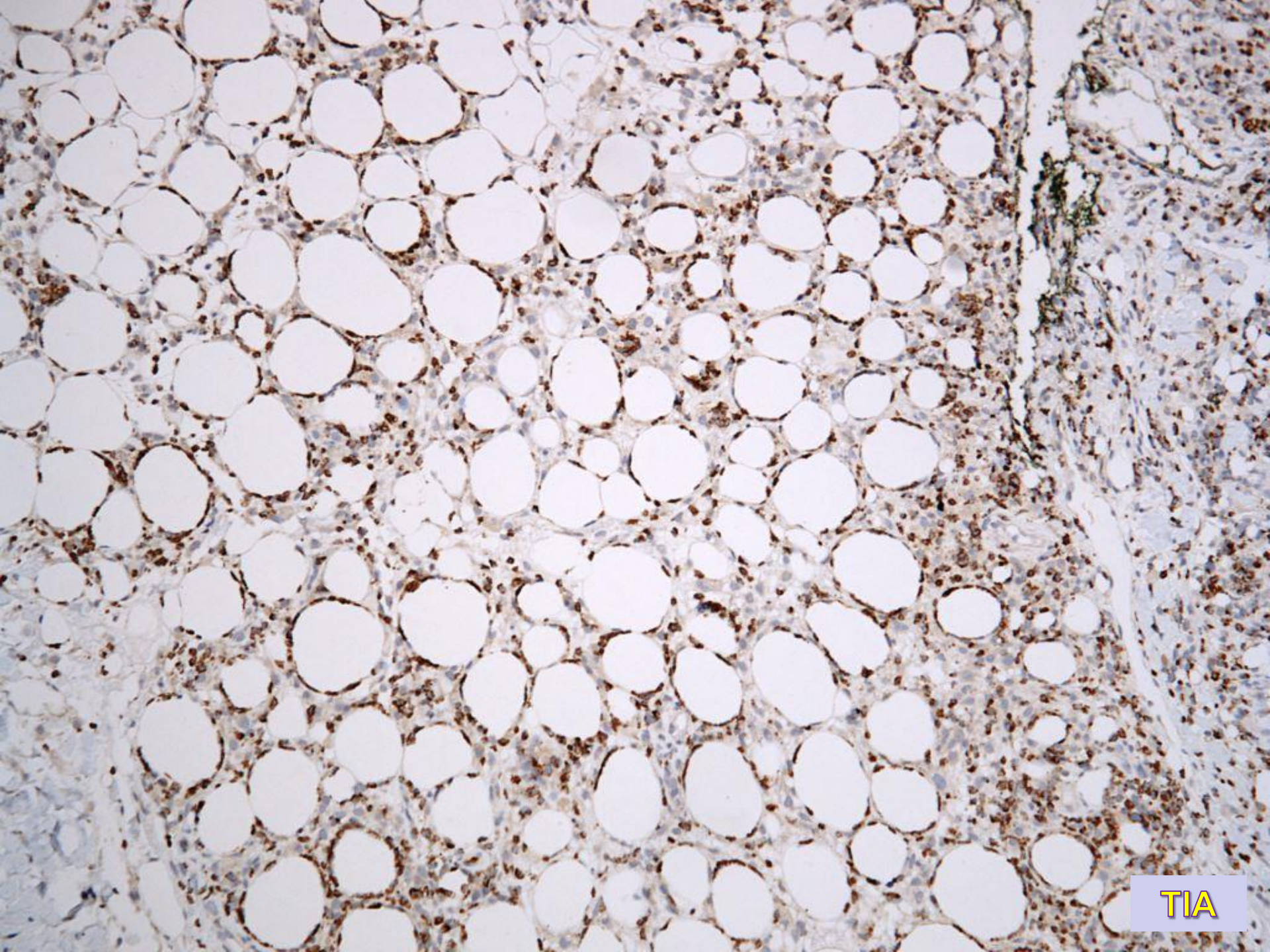
CD4





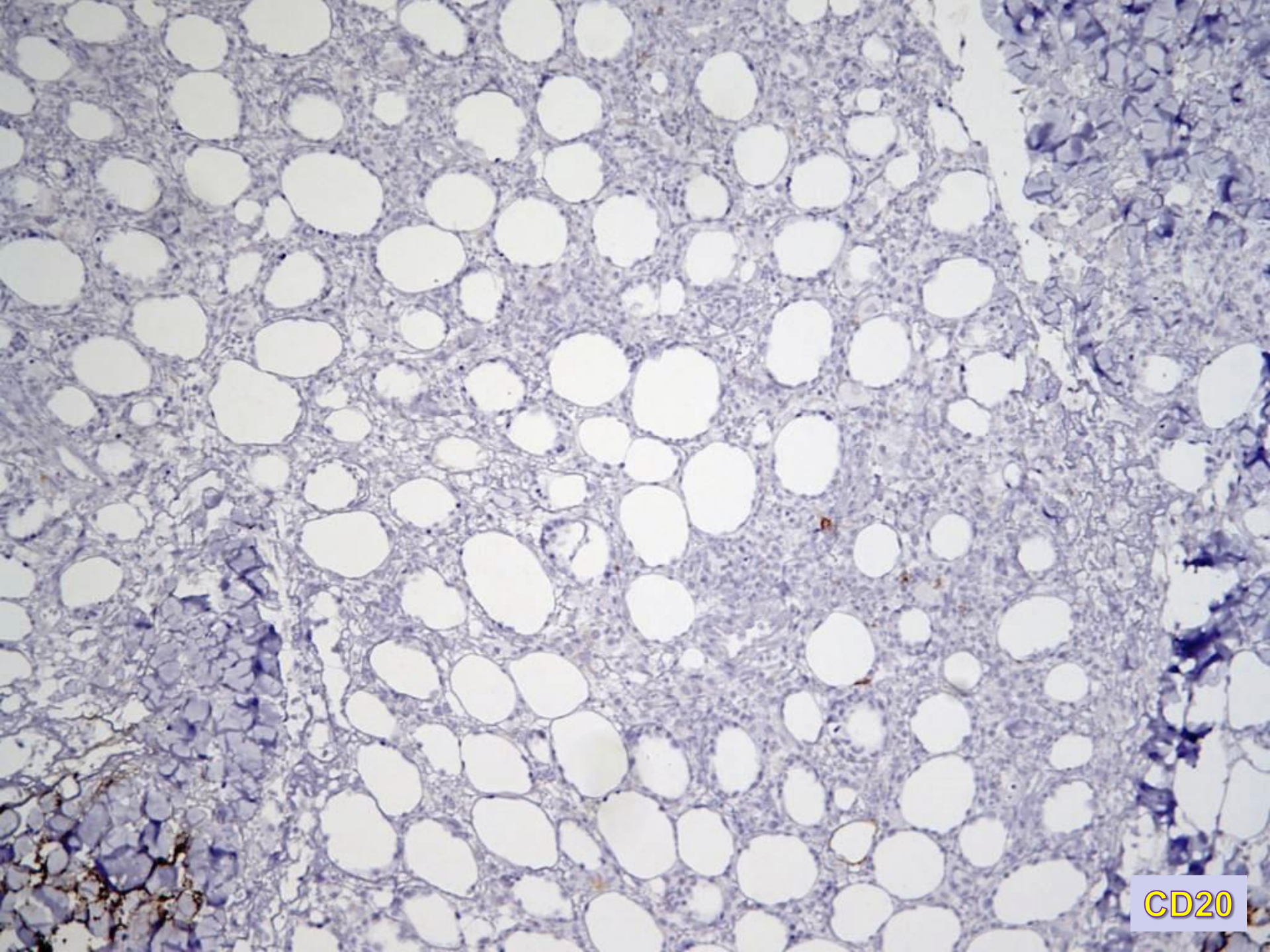
CD8





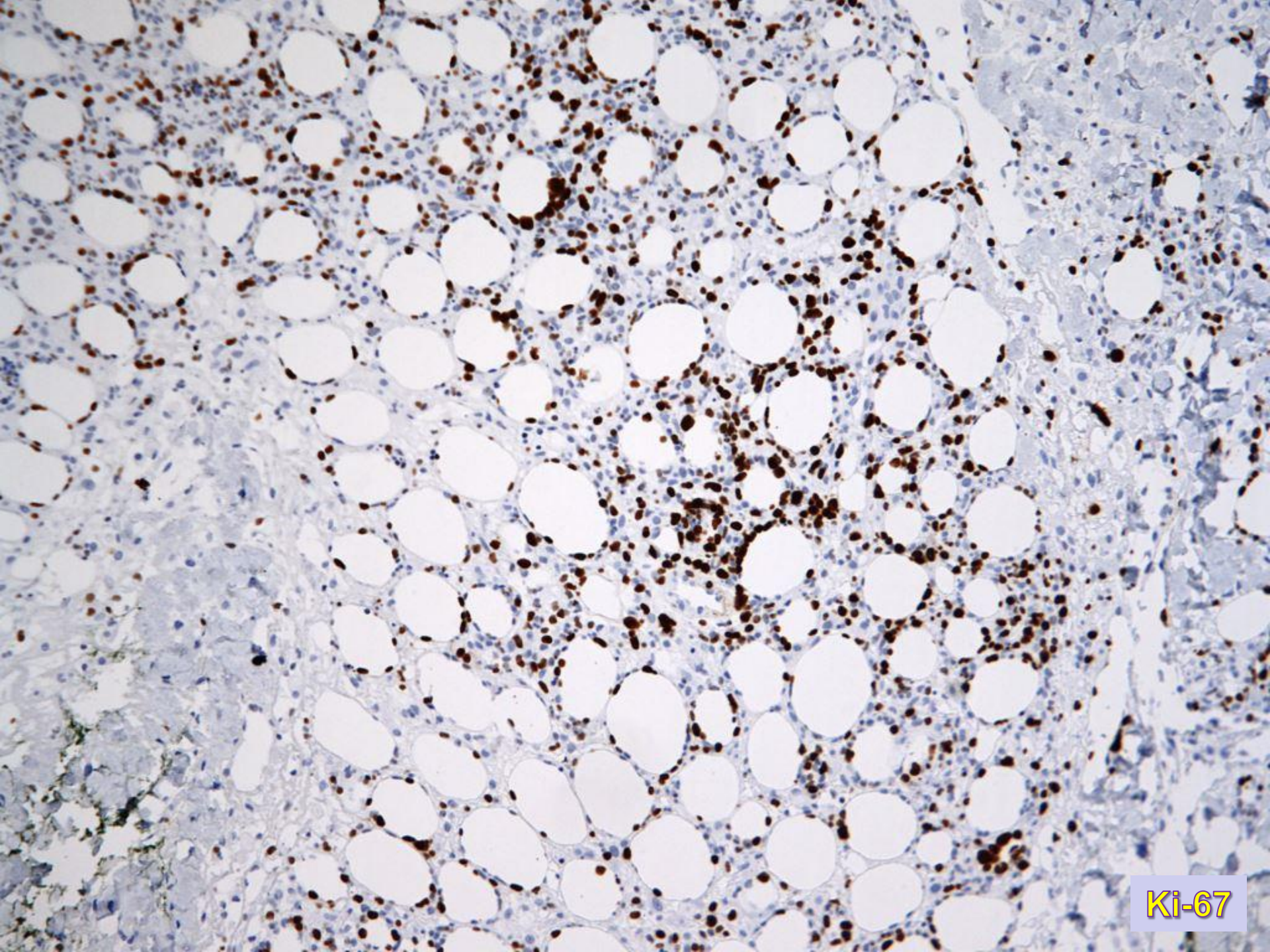
TIA





CD20





Ki-67





Ki-67