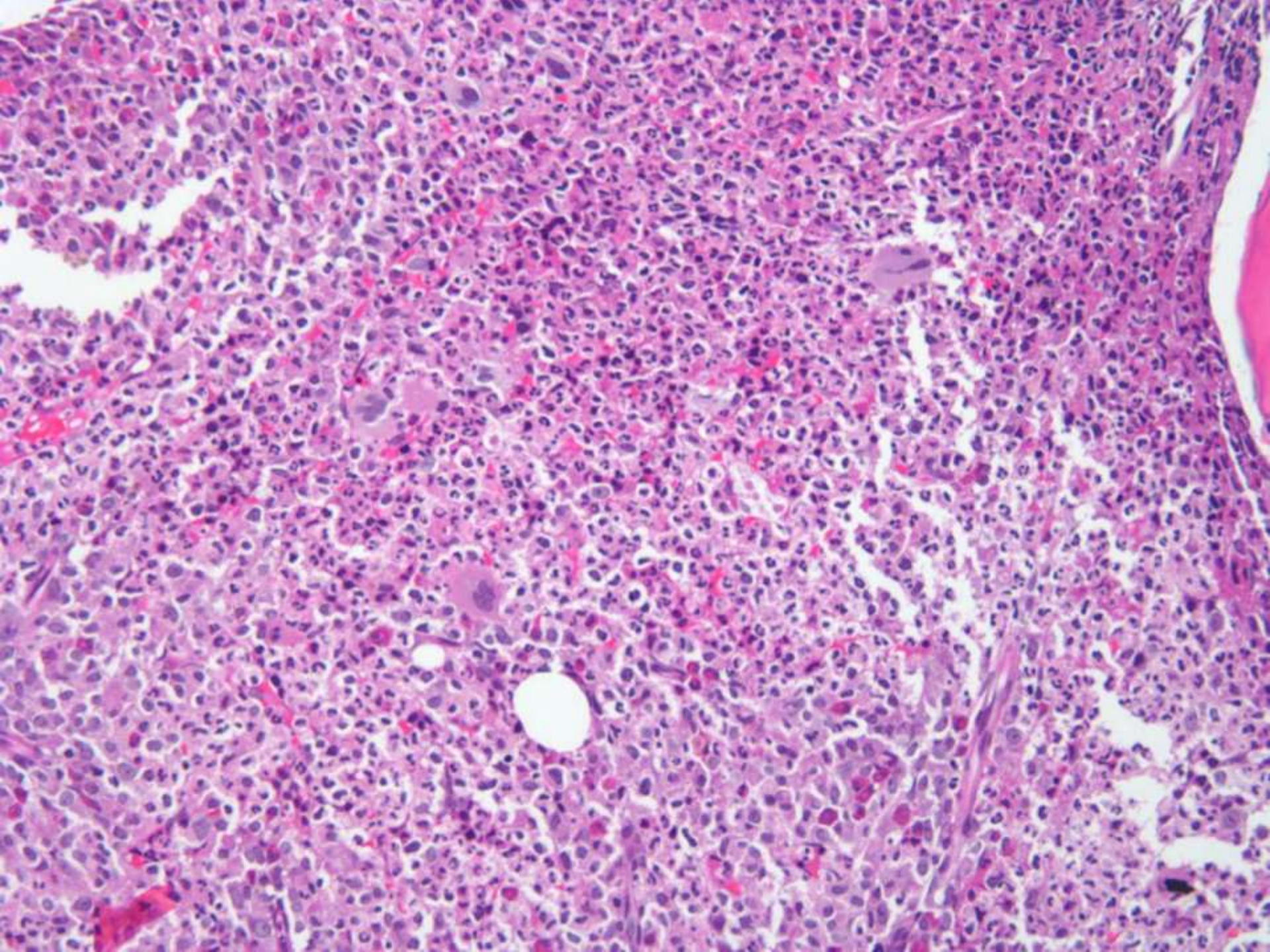


# South Bay Pathology Society

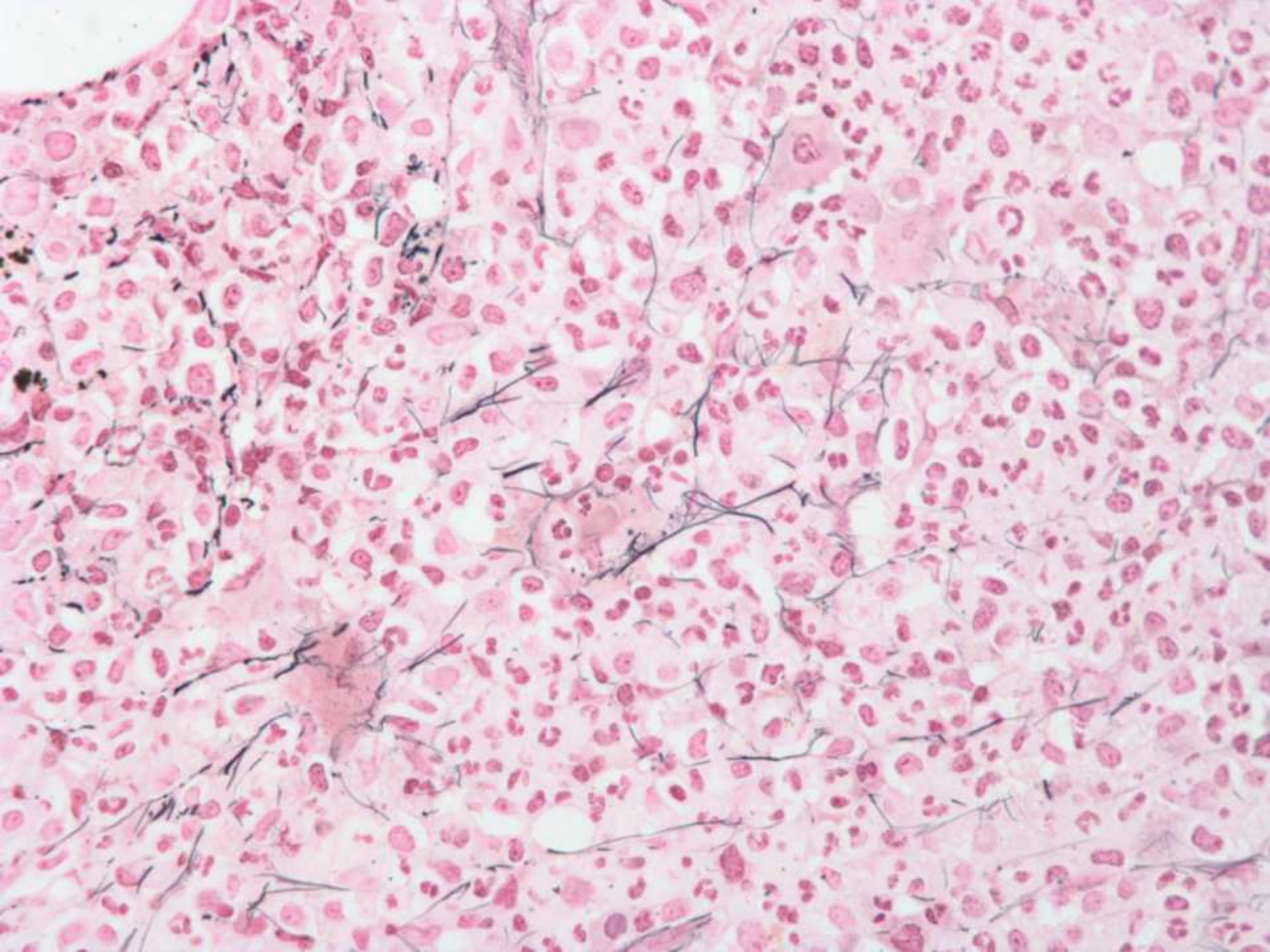
November 3, 2014

# 5881

- 58-year-old man presents with leukocytosis (WBC 20K, 81% neutrophils, plt 271K, H/H 11/35). Bone marrow biopsy performed.
- **Charles Lombard; El Camino Hospital**



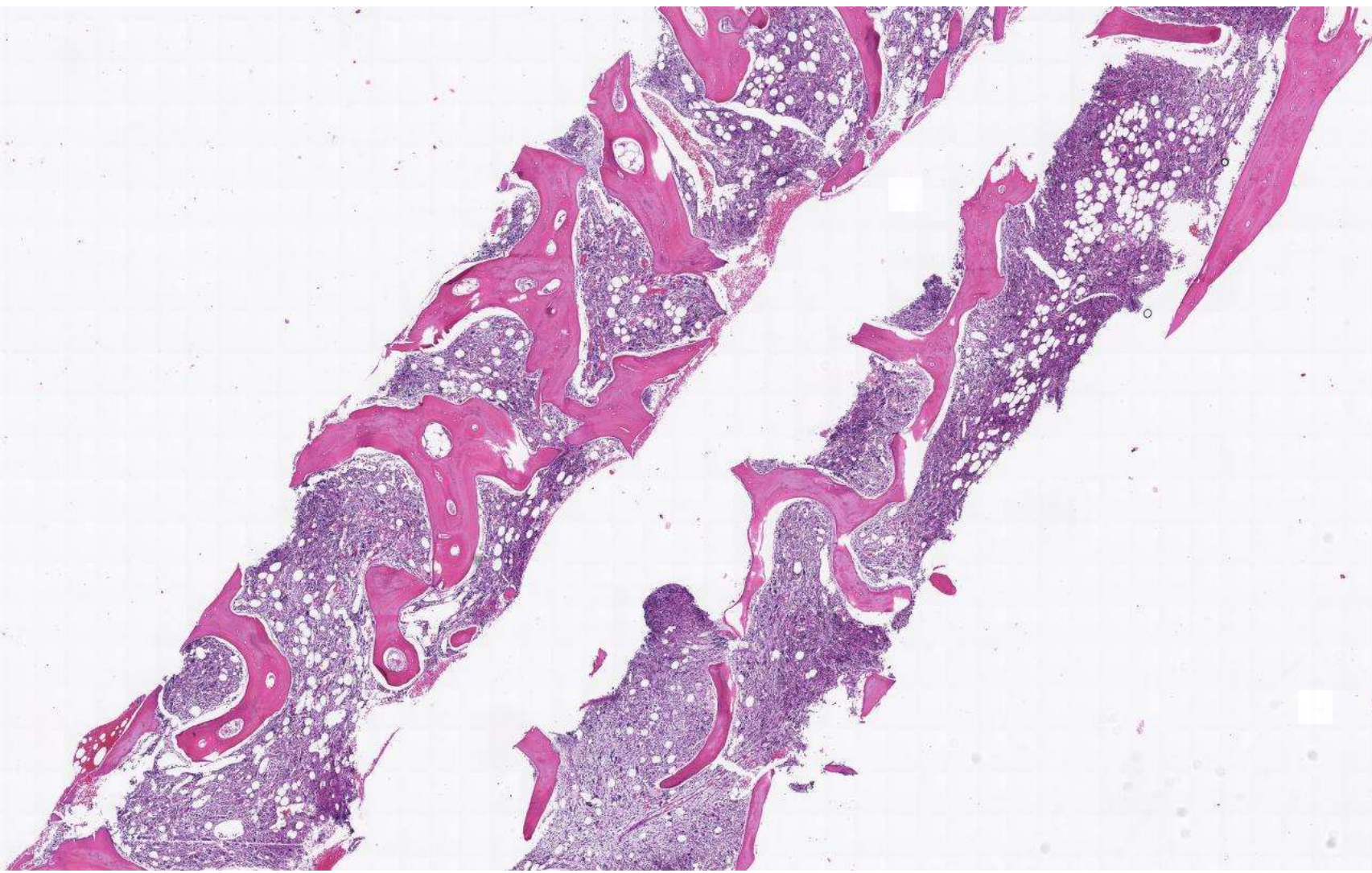




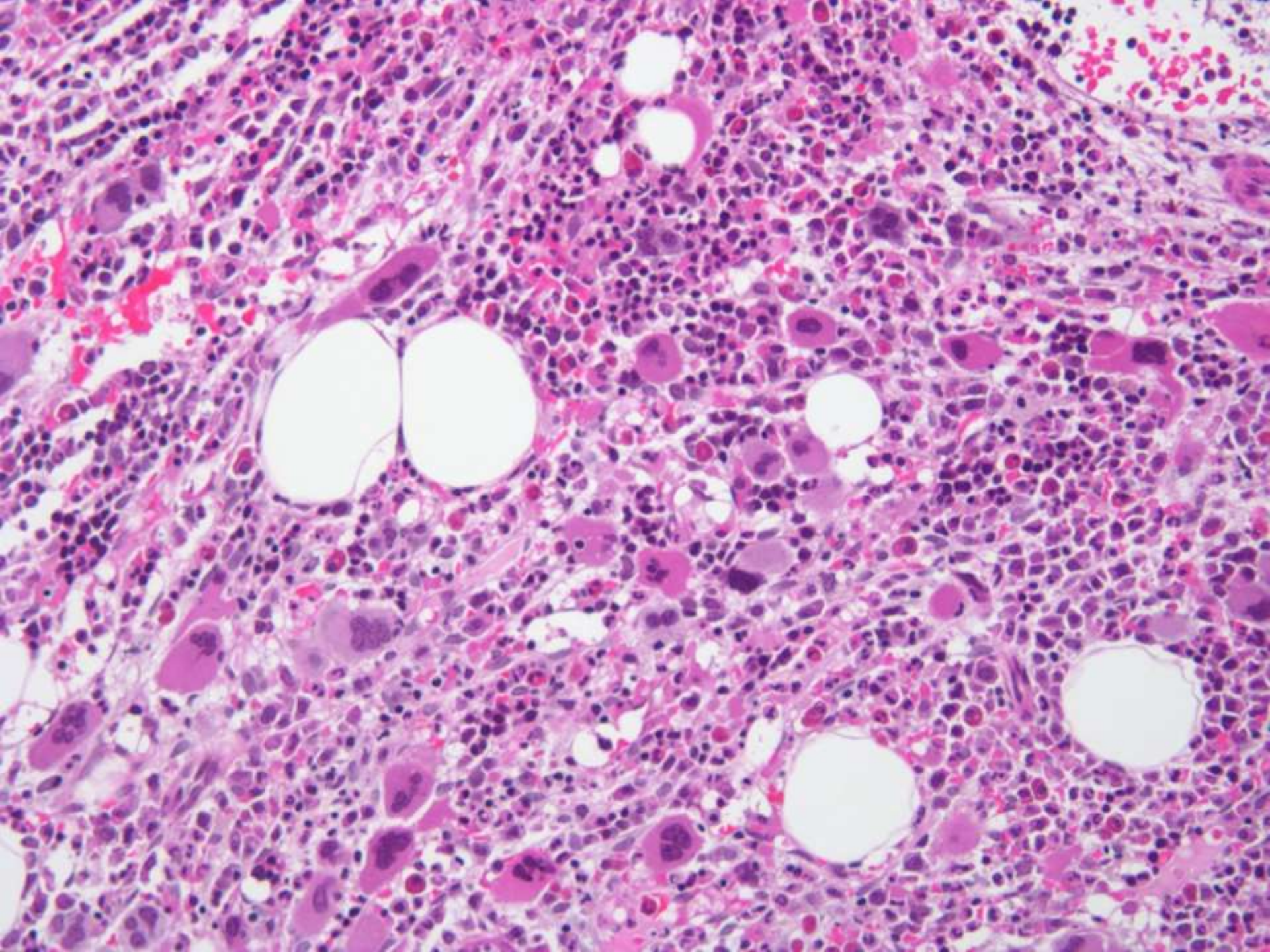


# Summary

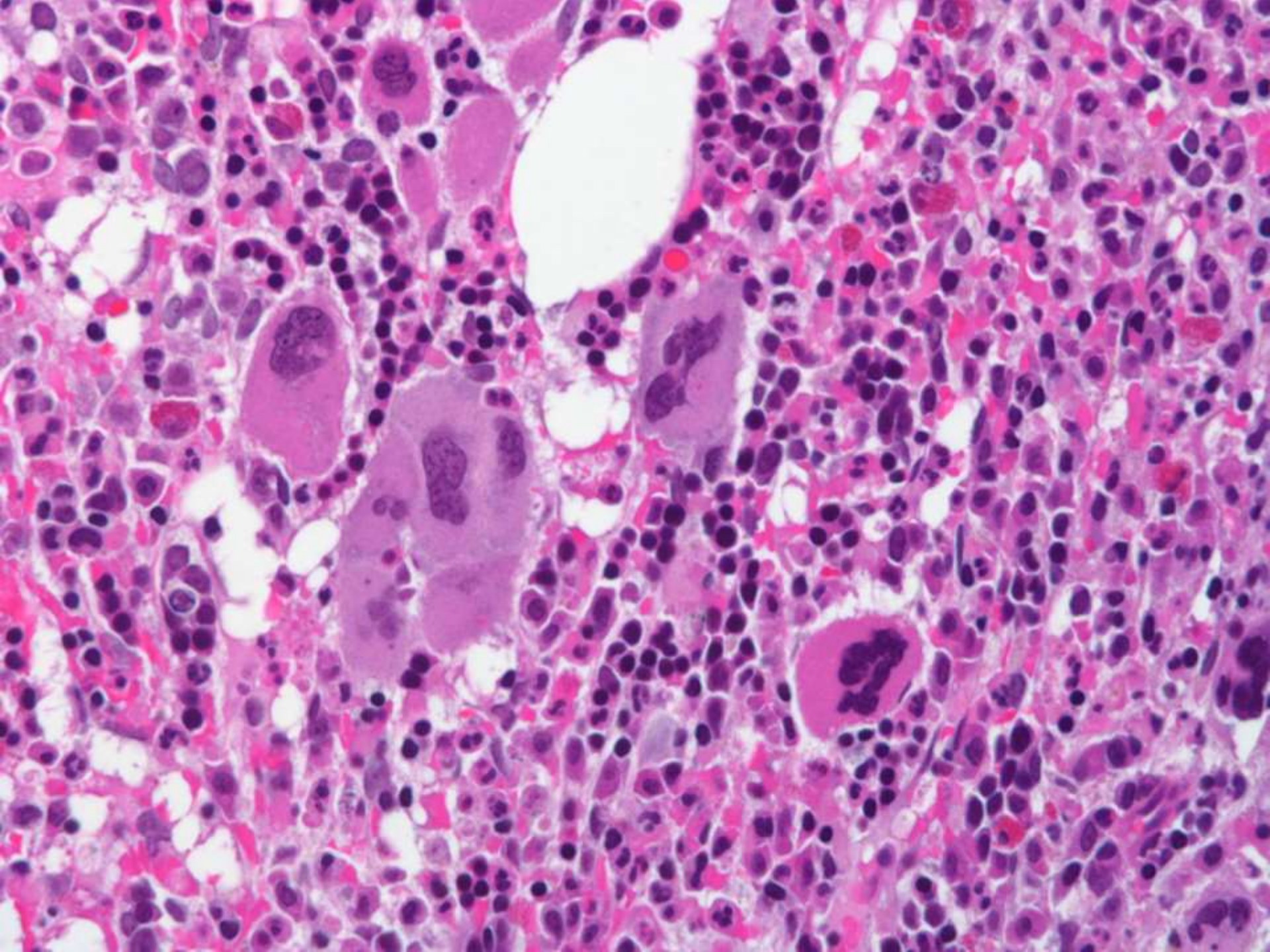
- Cytogenetics: Philadelphia chromosome
- FISH: Bcr/Abl translocation detected in 95% of cells
- JAK2: not detected in BM
- Patient treated with Sprycell for 7 months
- Peripheral blood “normalized”
- Follow up BM biopsy



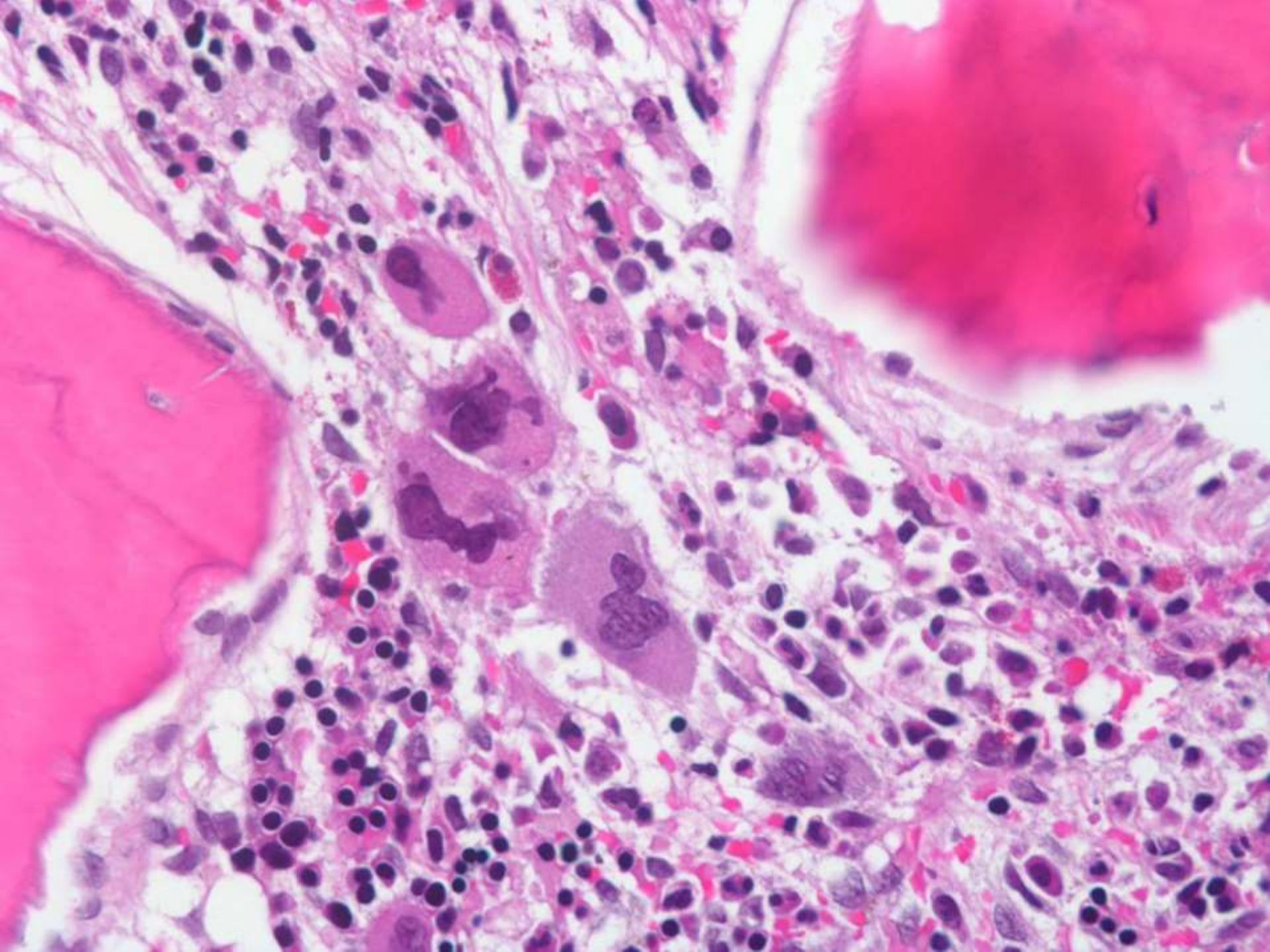




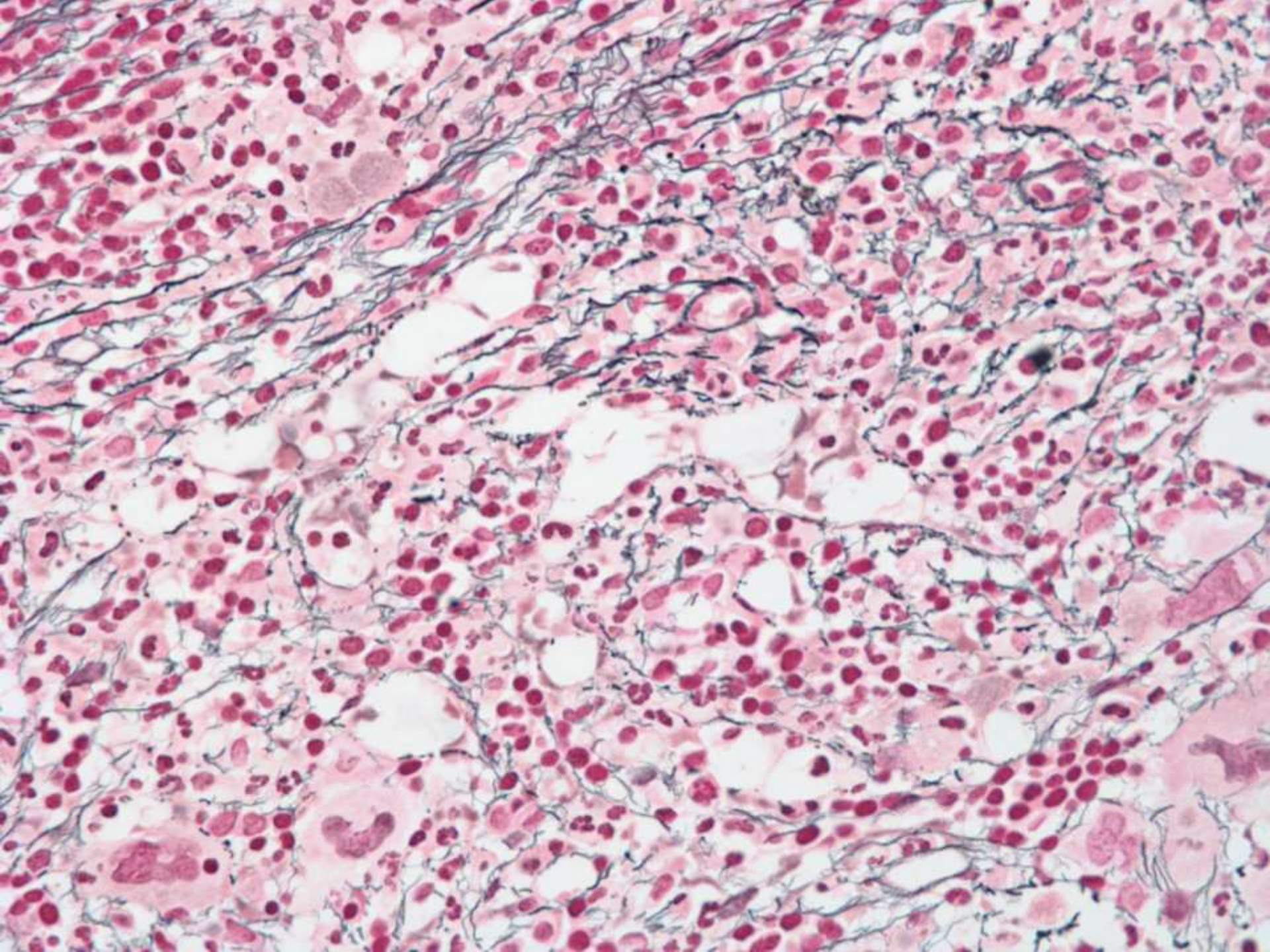








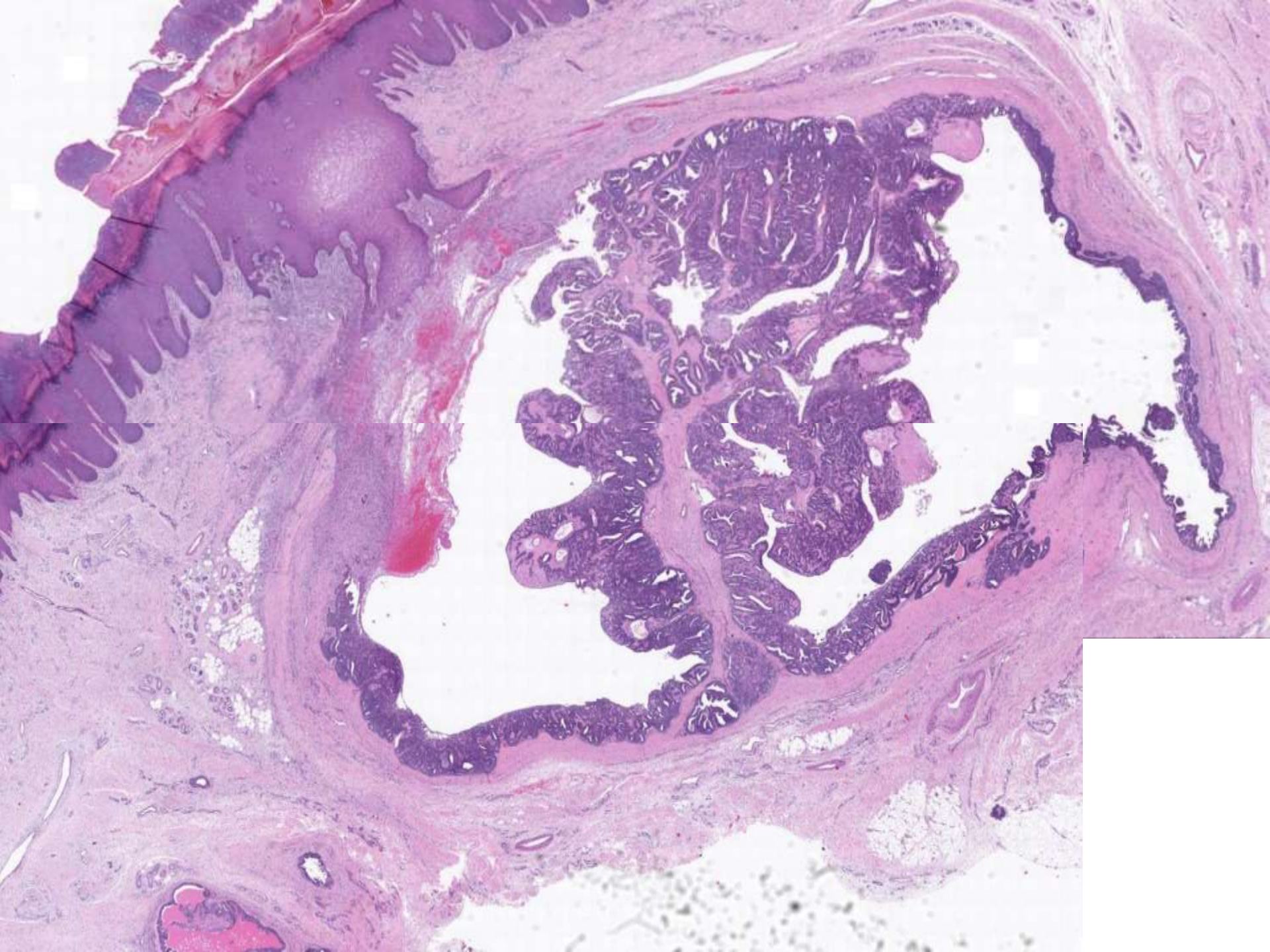




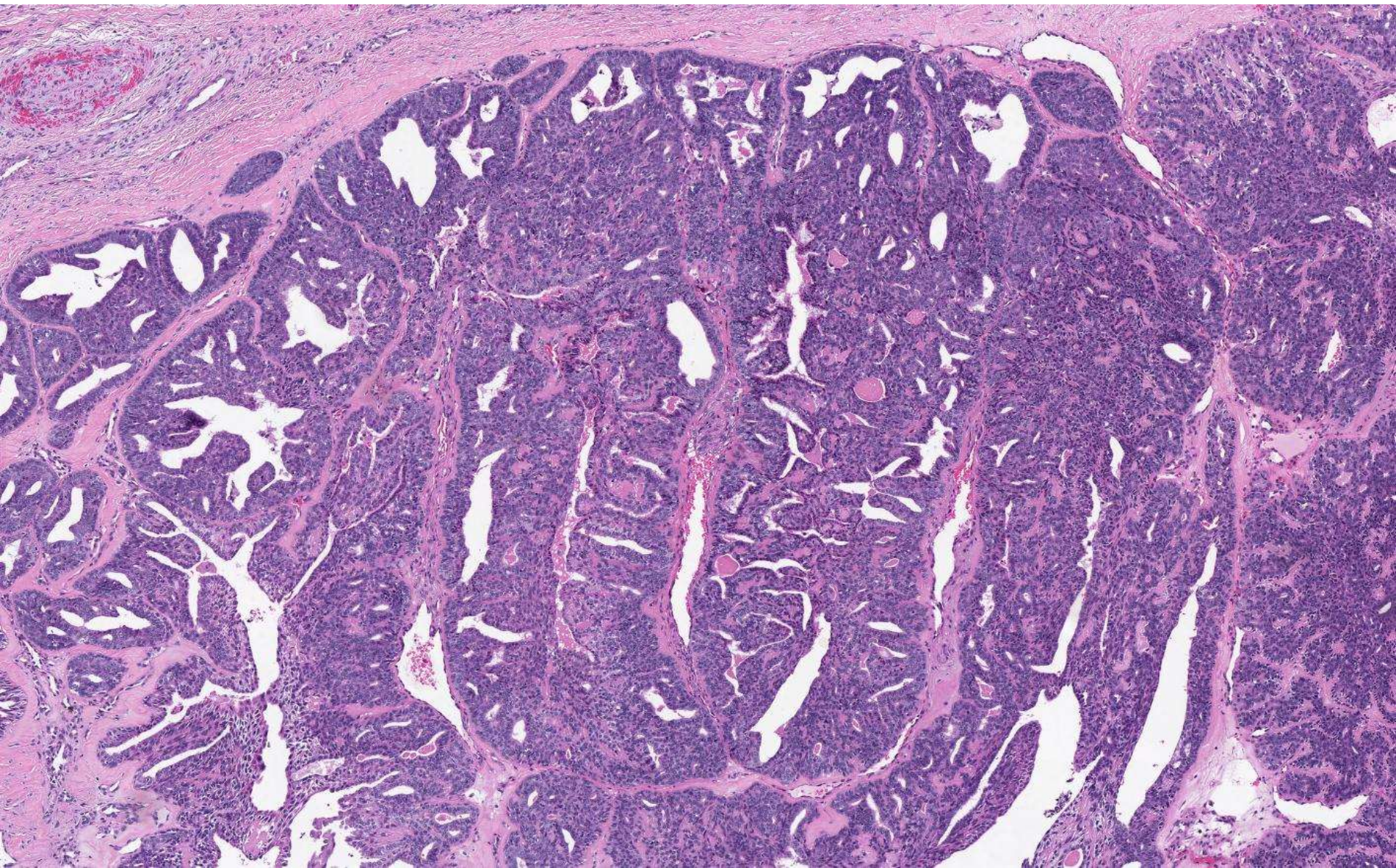


# 5882

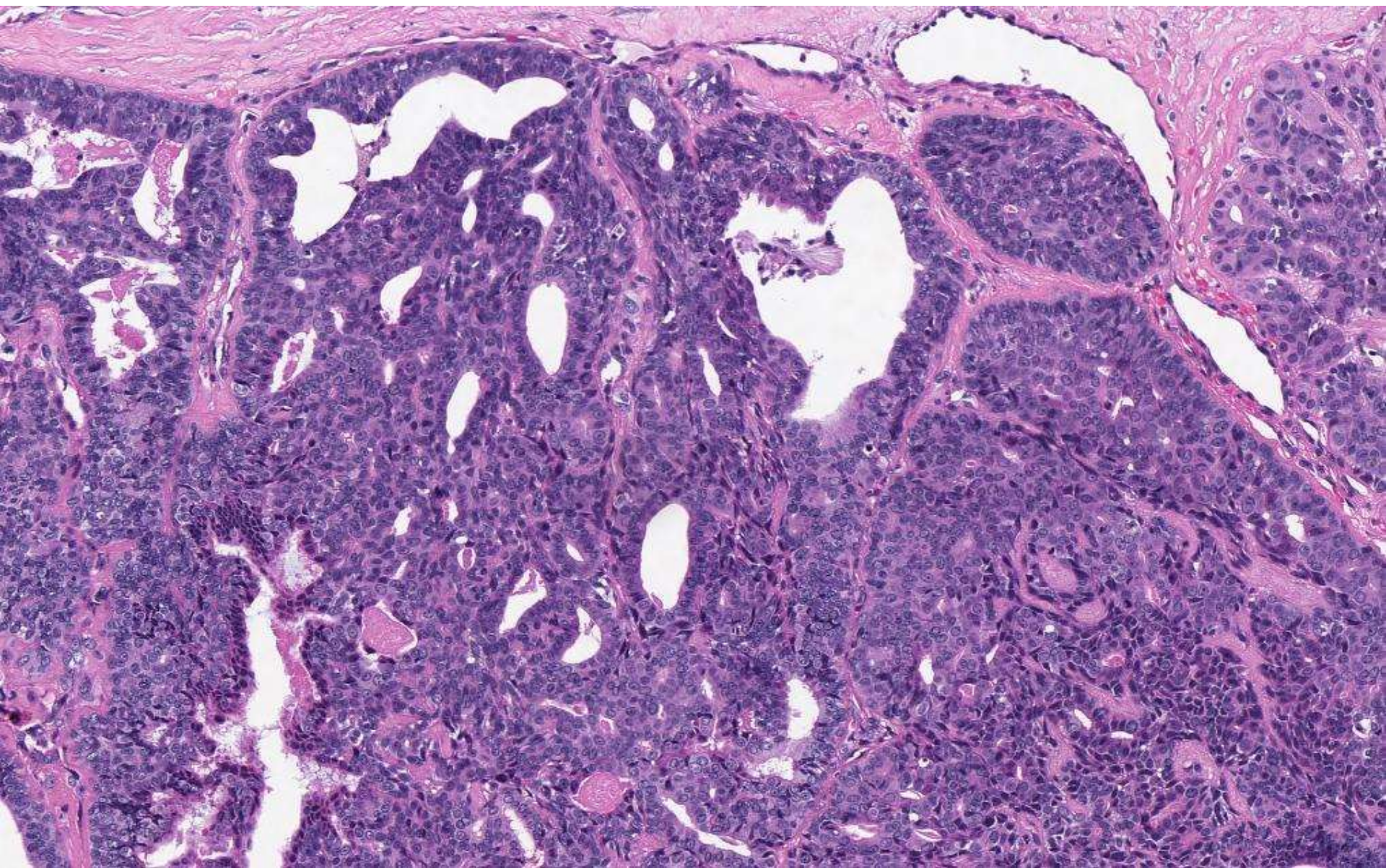
- 62-year-old man with right thumb mass. Excision performed.
- **Bob Freedman; El Camino Hospital**



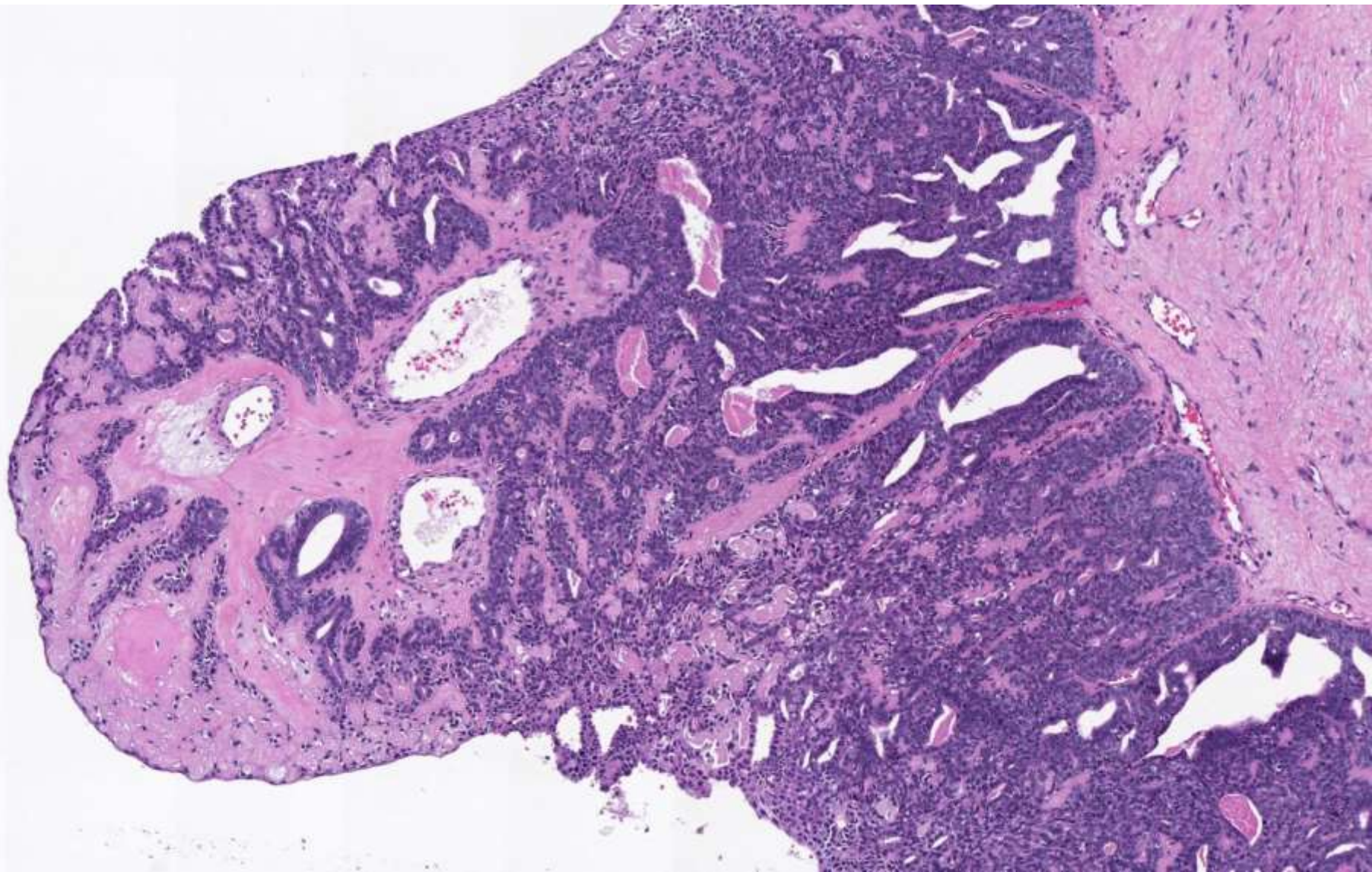




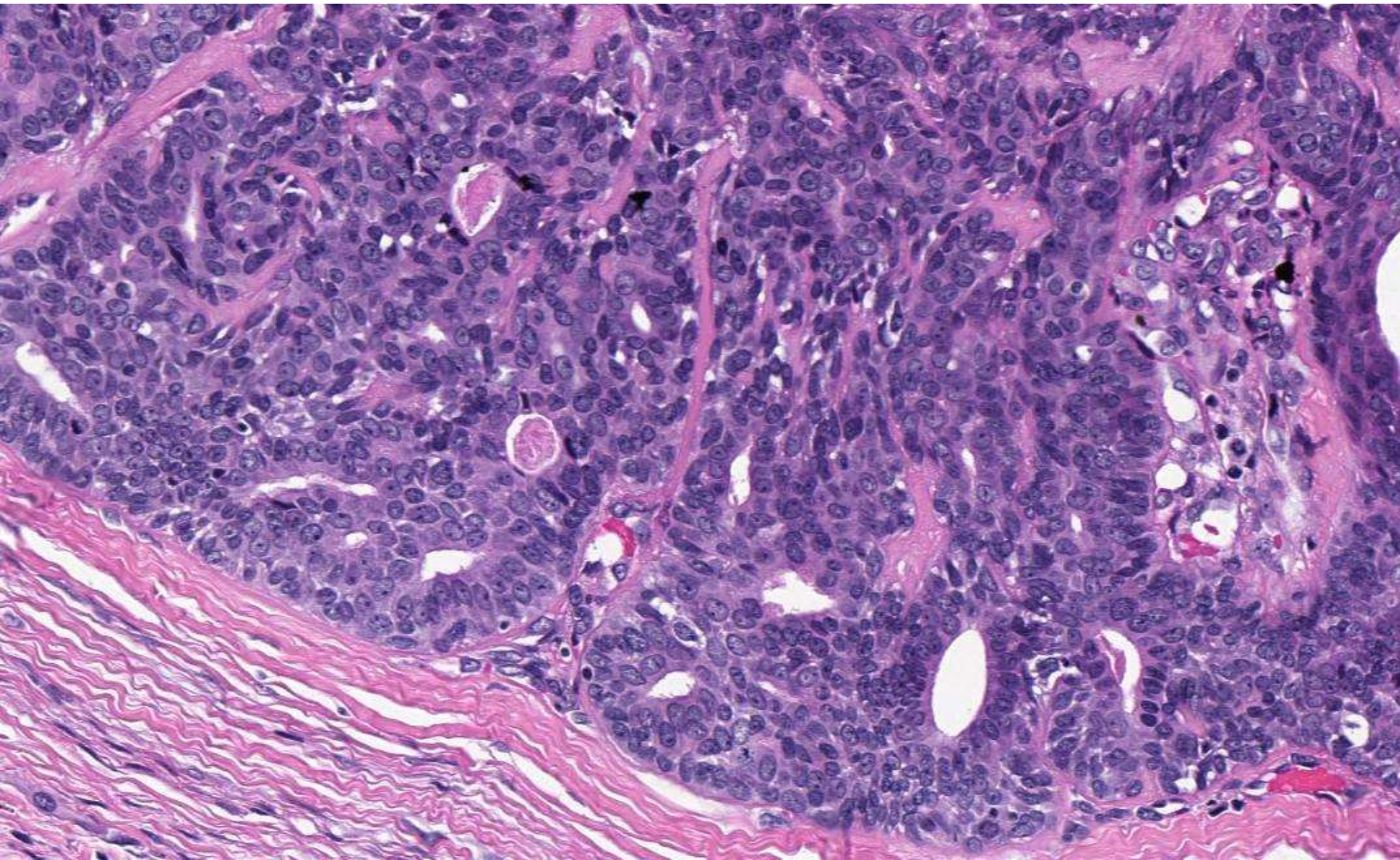










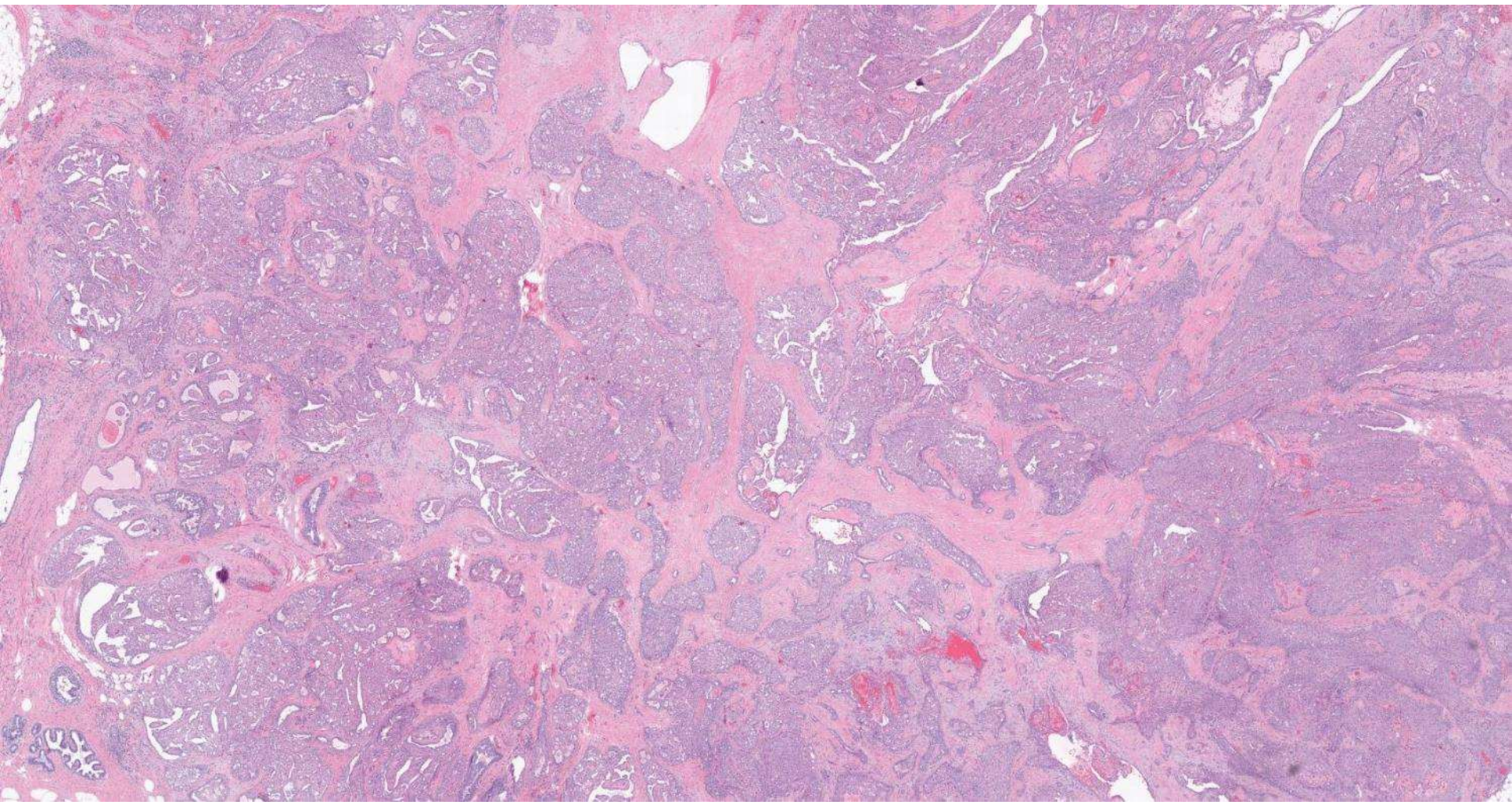




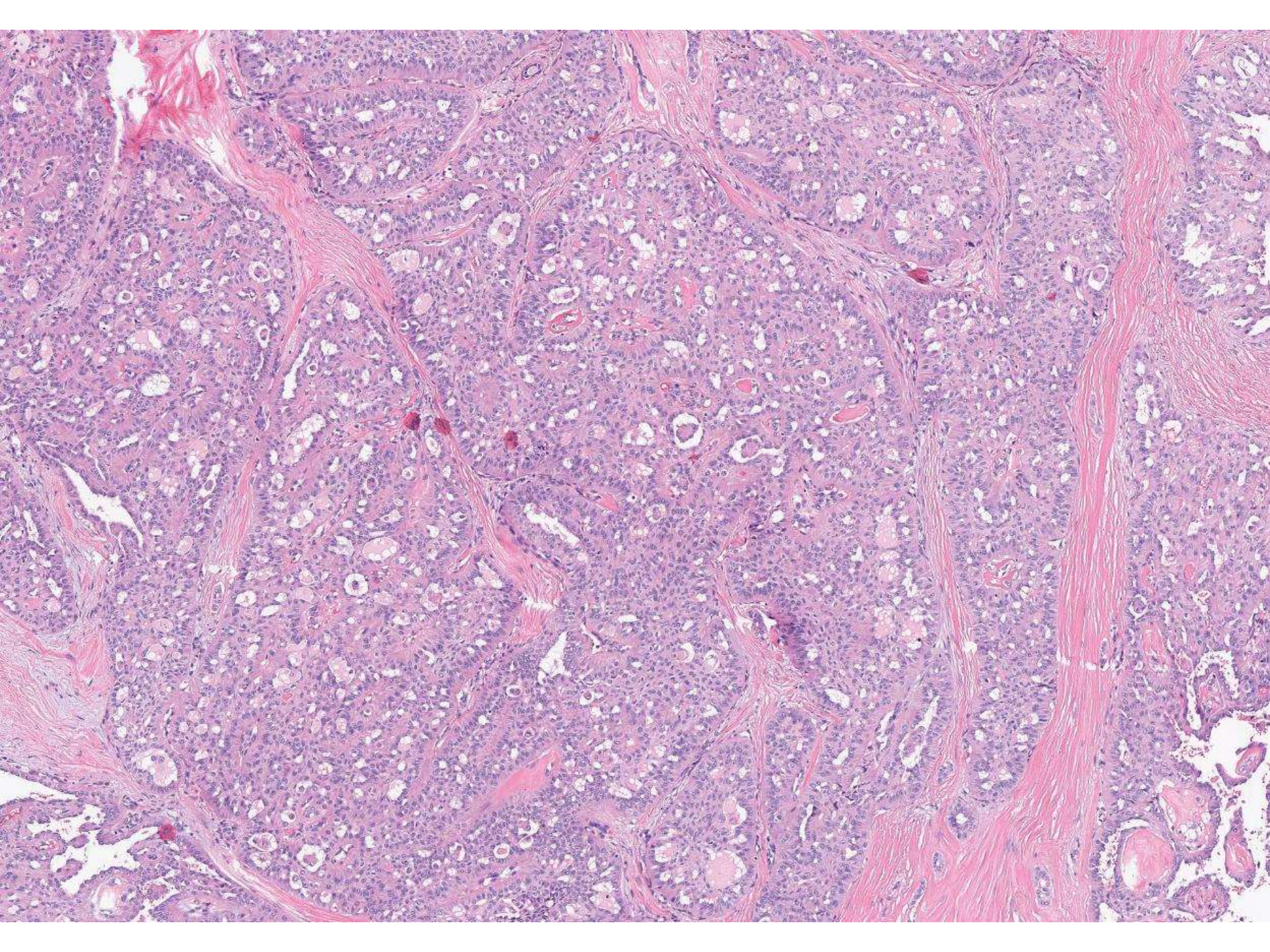
# 5883

- 60-year-old woman with needle biopsy of breast showing invasive ductal carcinoma with cribriform features, Nottingham grade 1. She underwent an excision of a 2.6cm mass.
- **Walden Browne; Kaiser-Antioch**

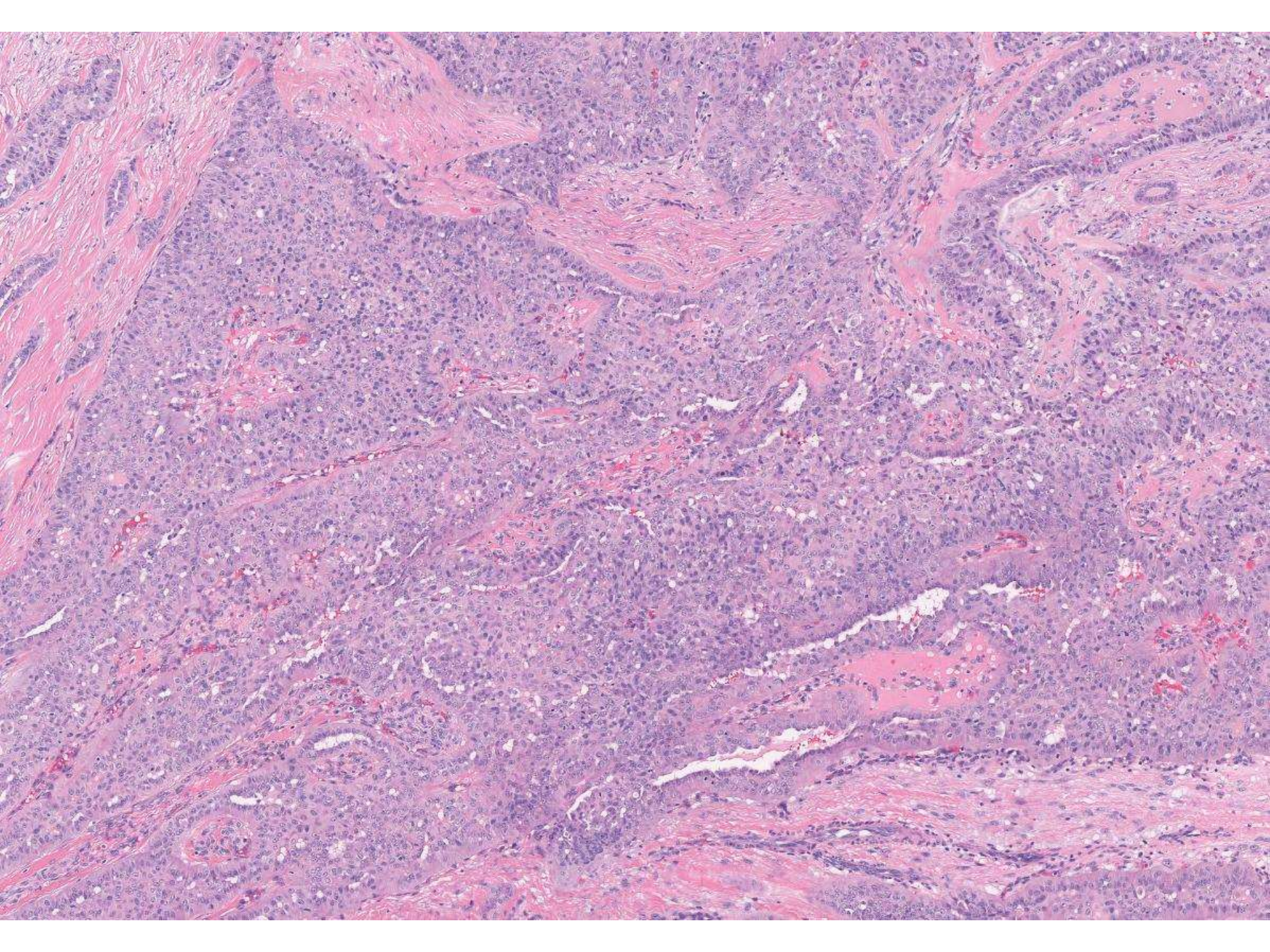




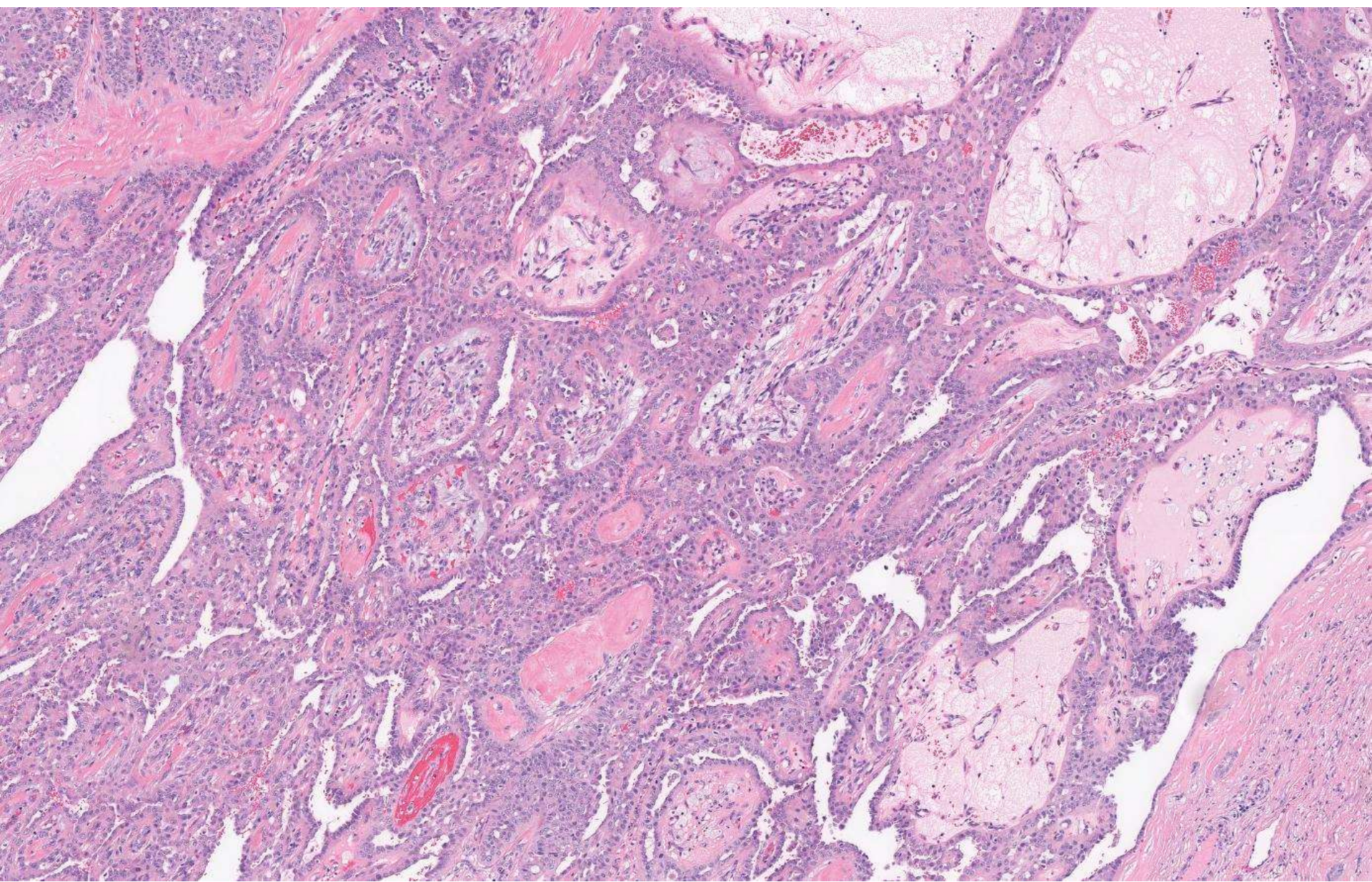




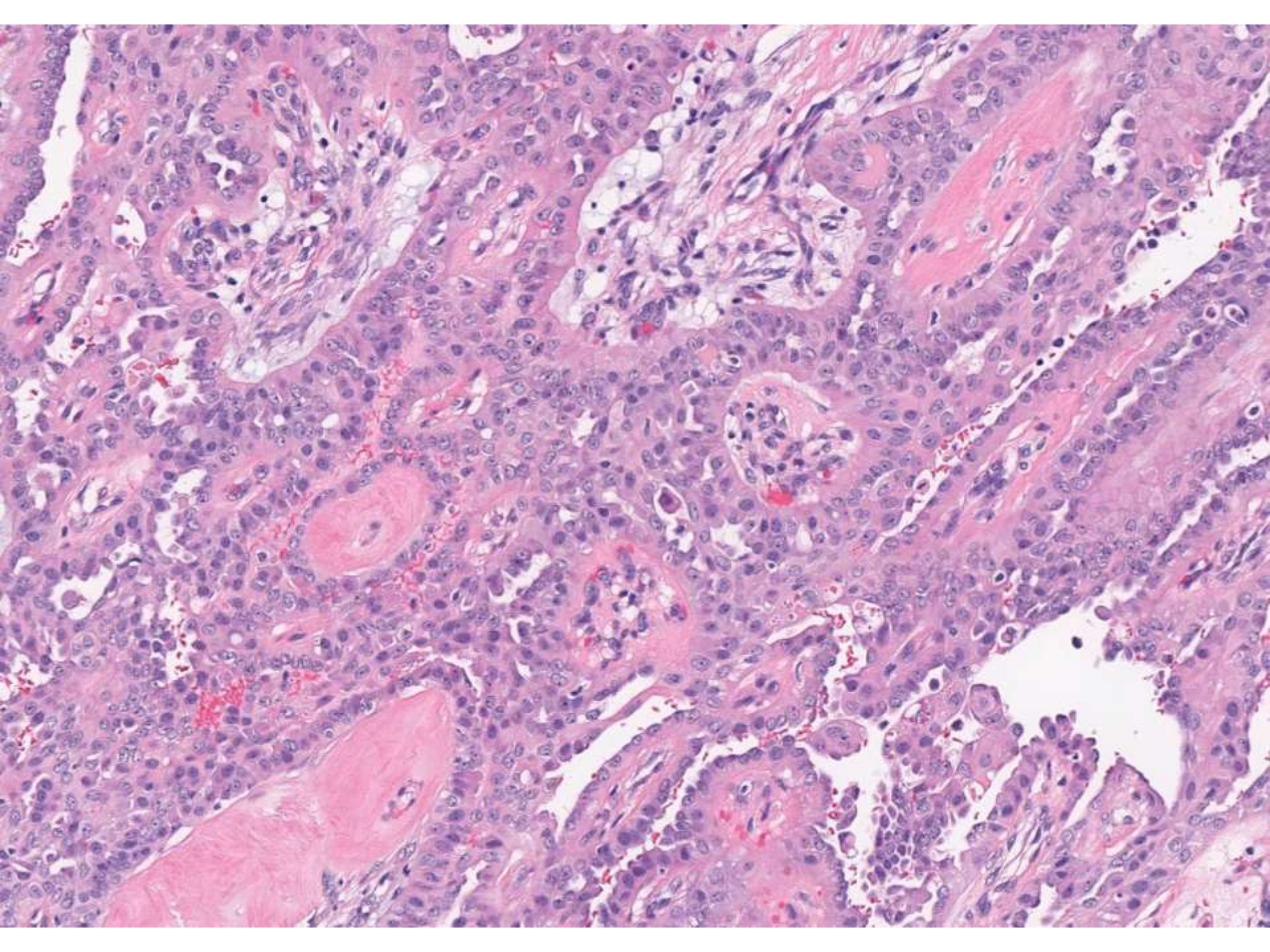




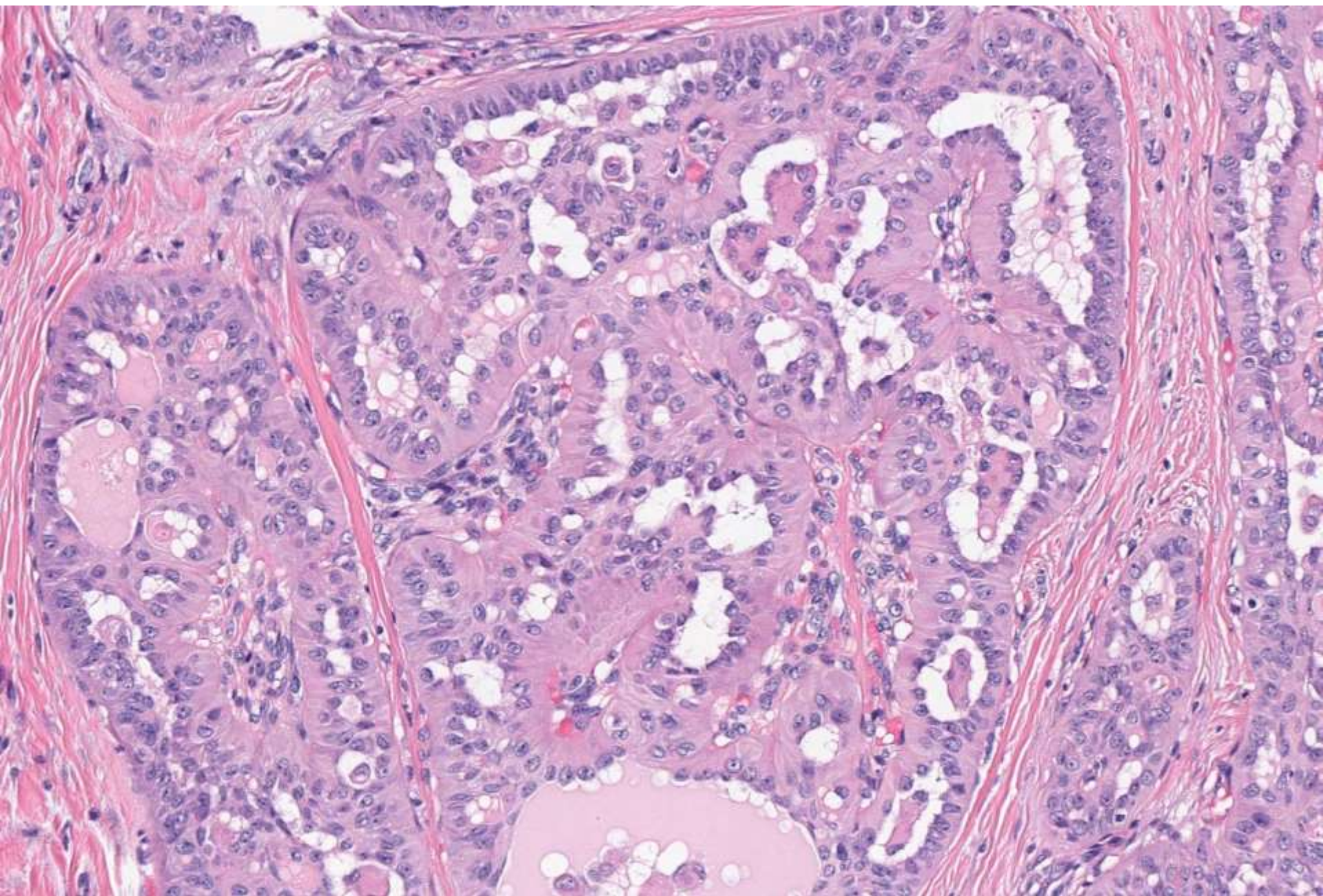




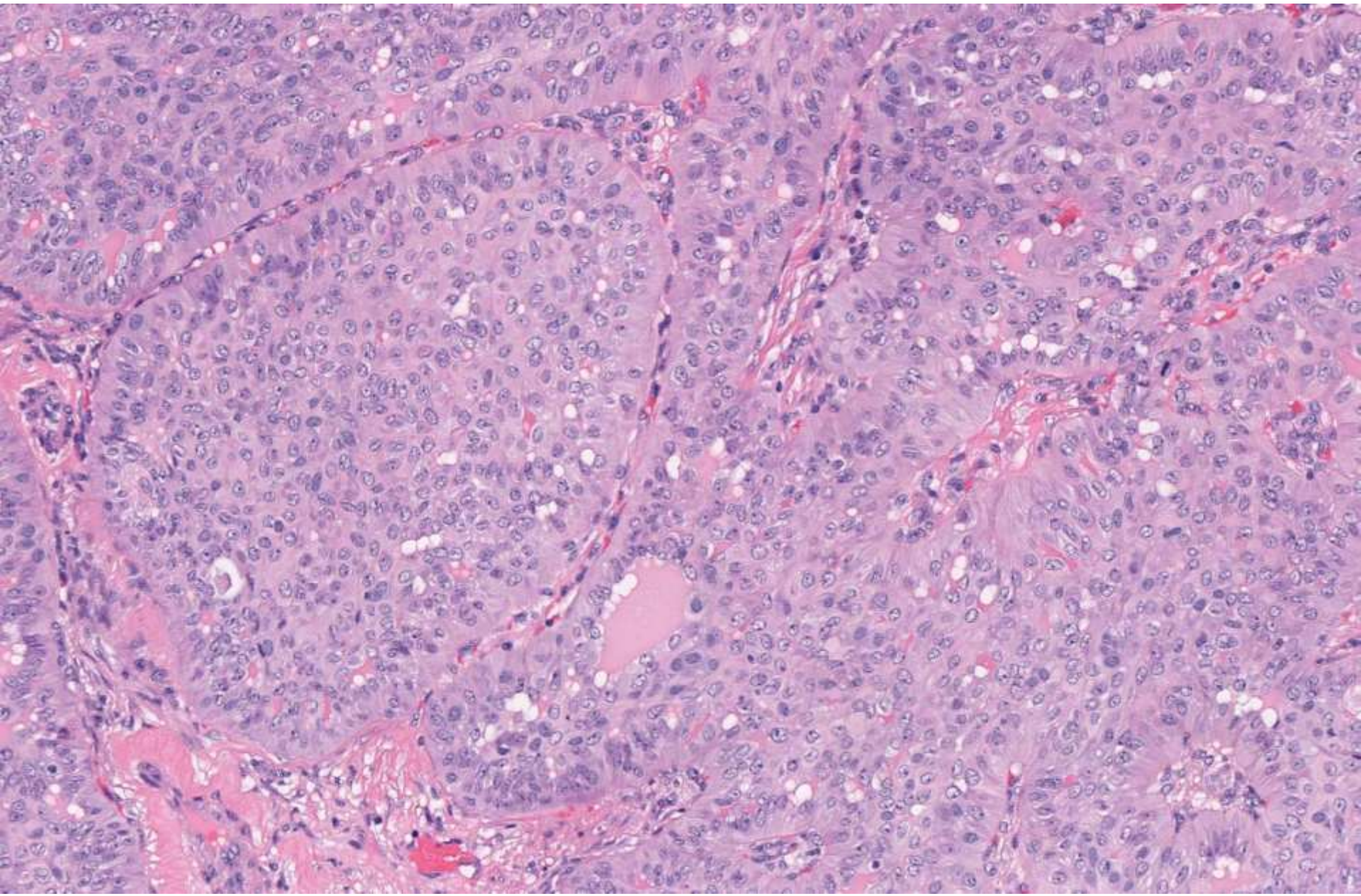










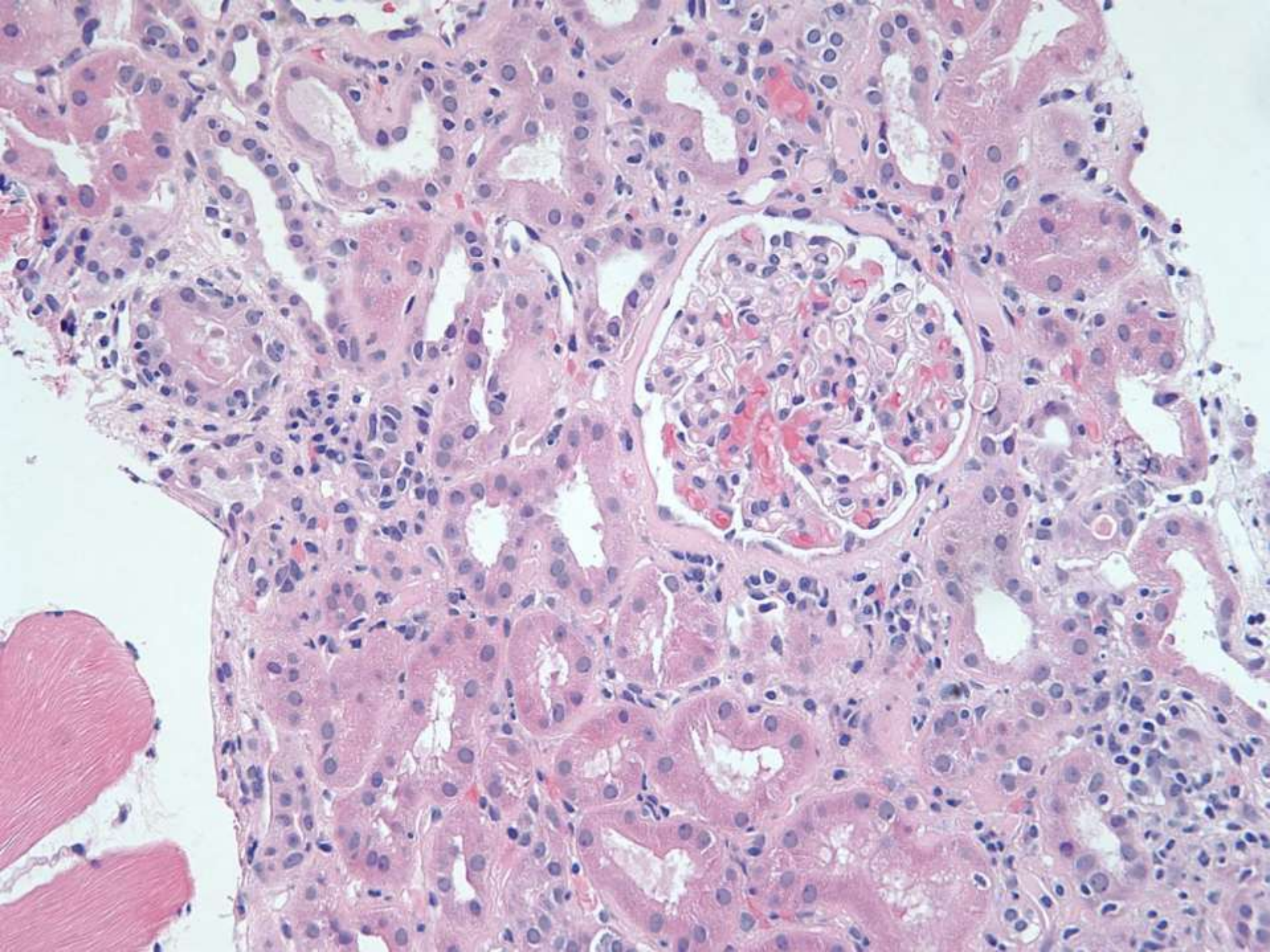




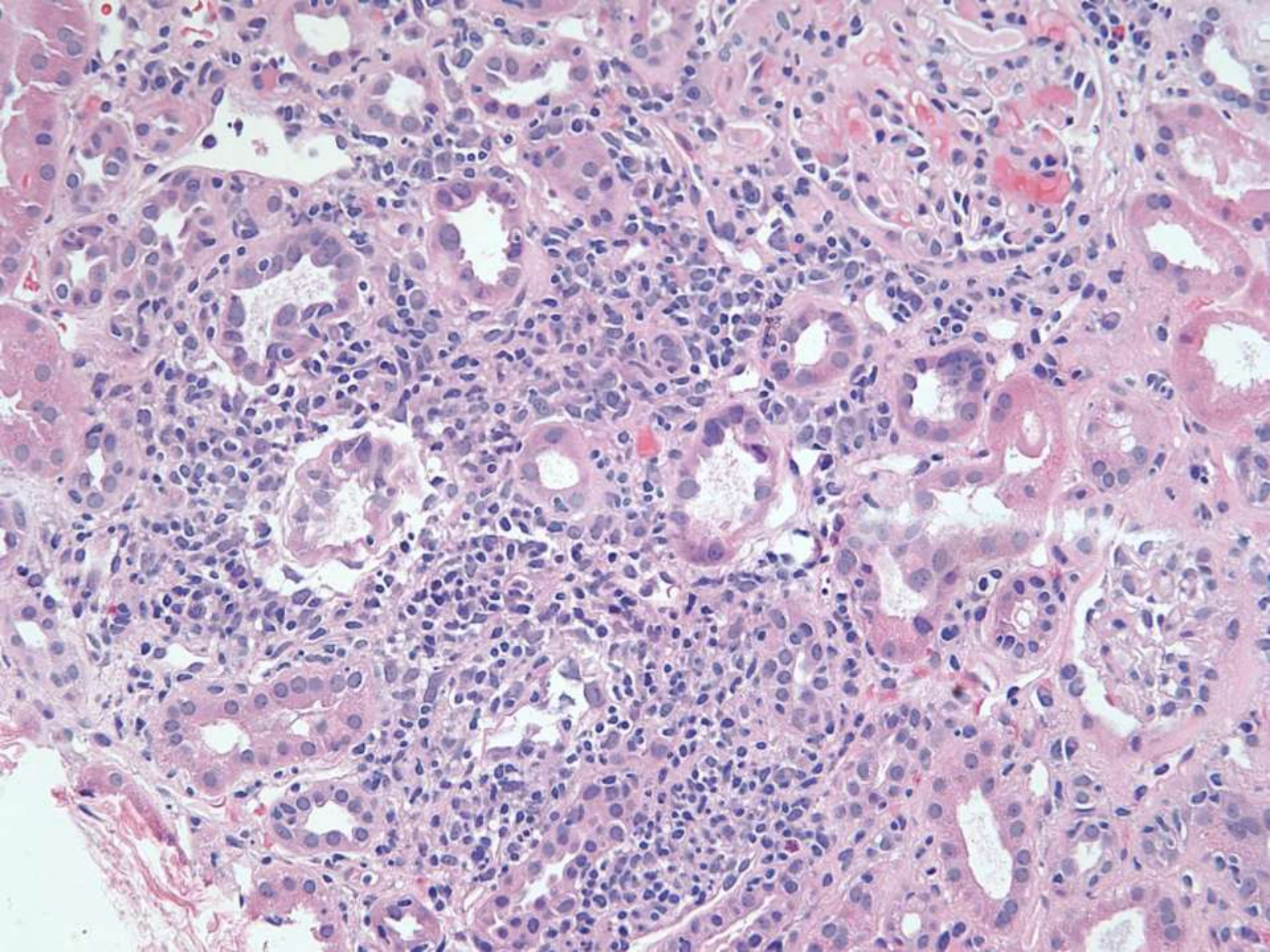
# 5884

- 19-year-old female who underwent living related donor transplant in August 2013. She has had refractory rejection with a rising creatinine from 2-3 in spite of antithymocyte globulin. Kidney biopsy performed.
- **Mike DiMaio/John Higgins; Stanford**

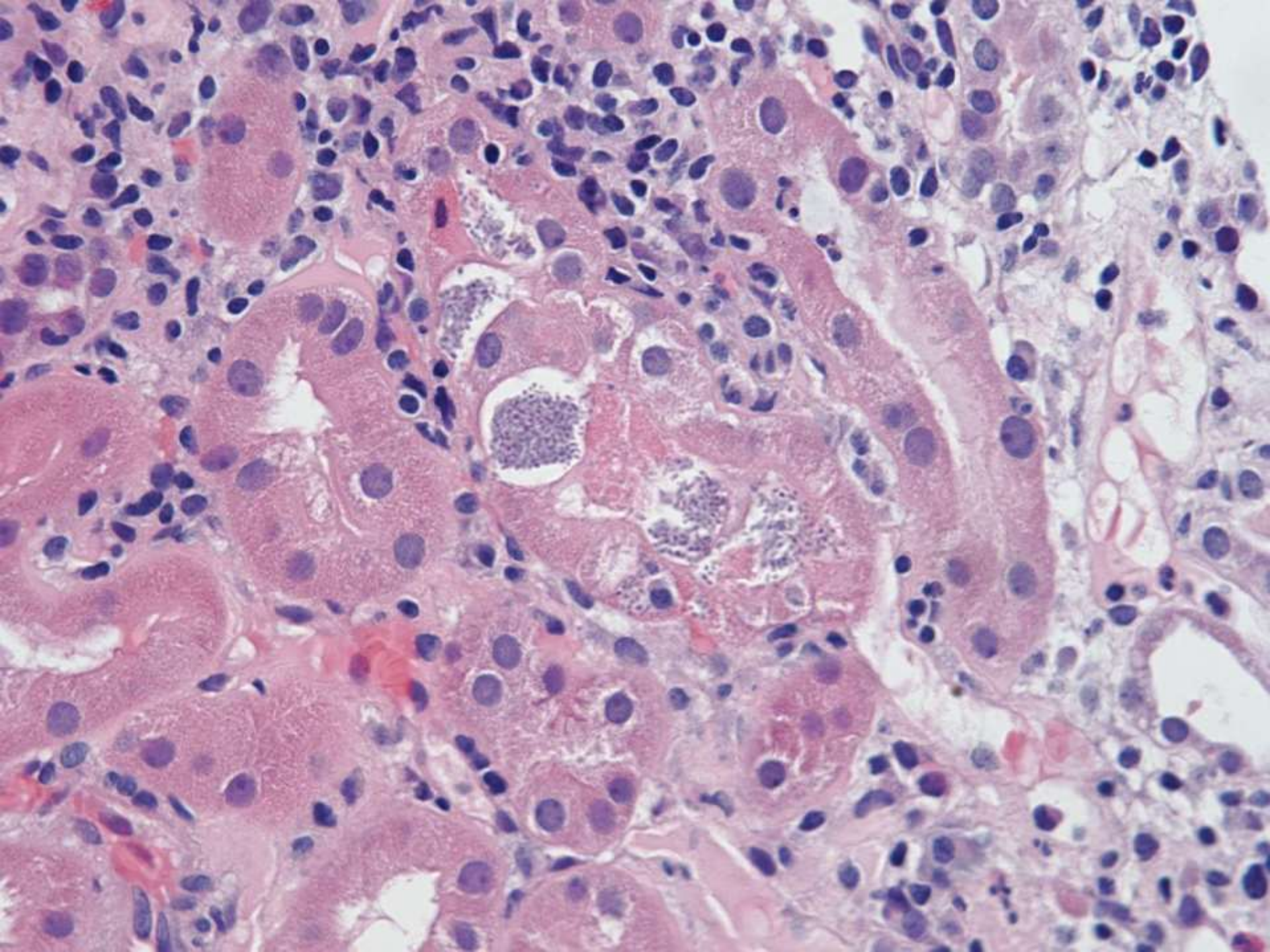




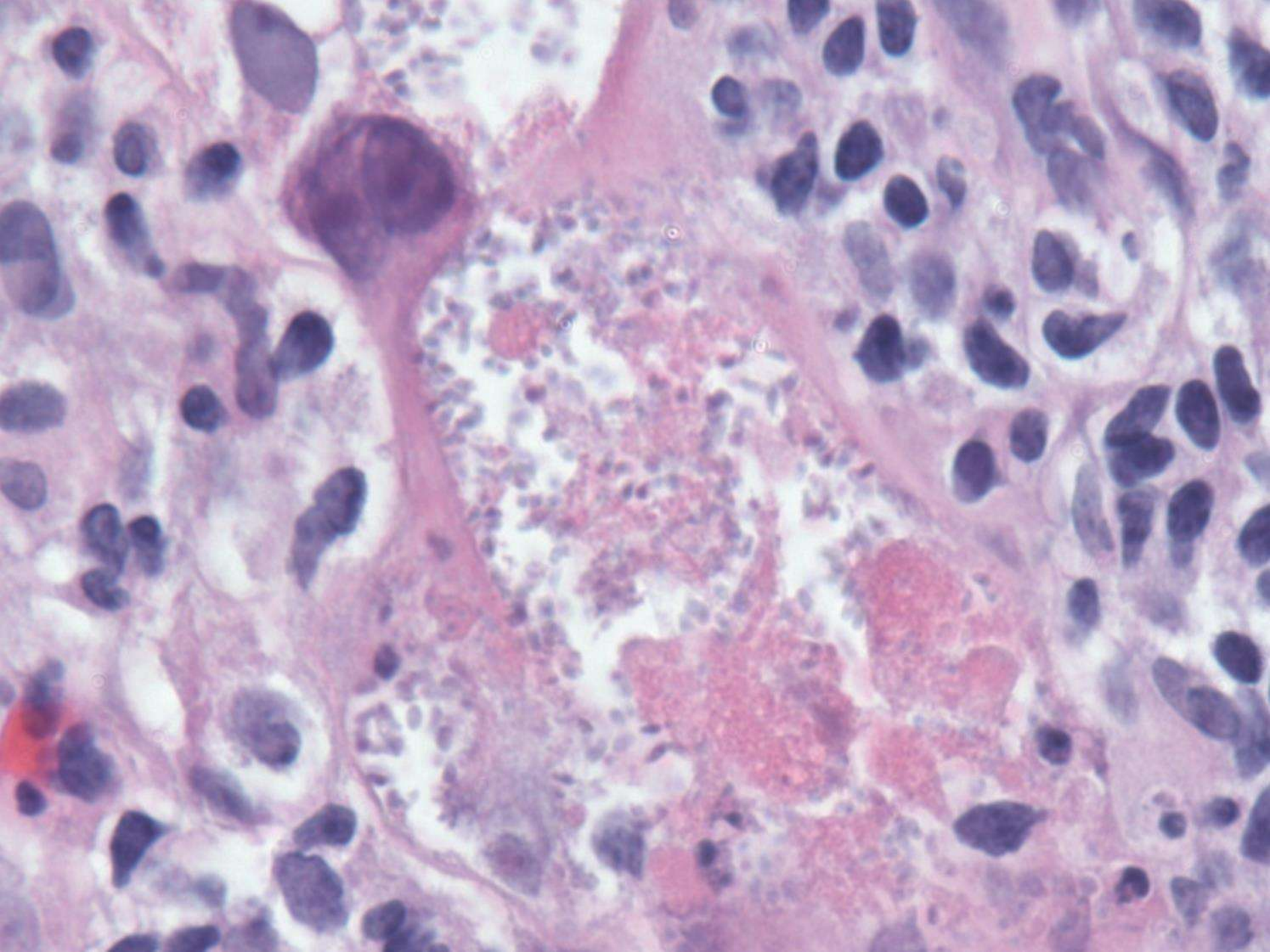










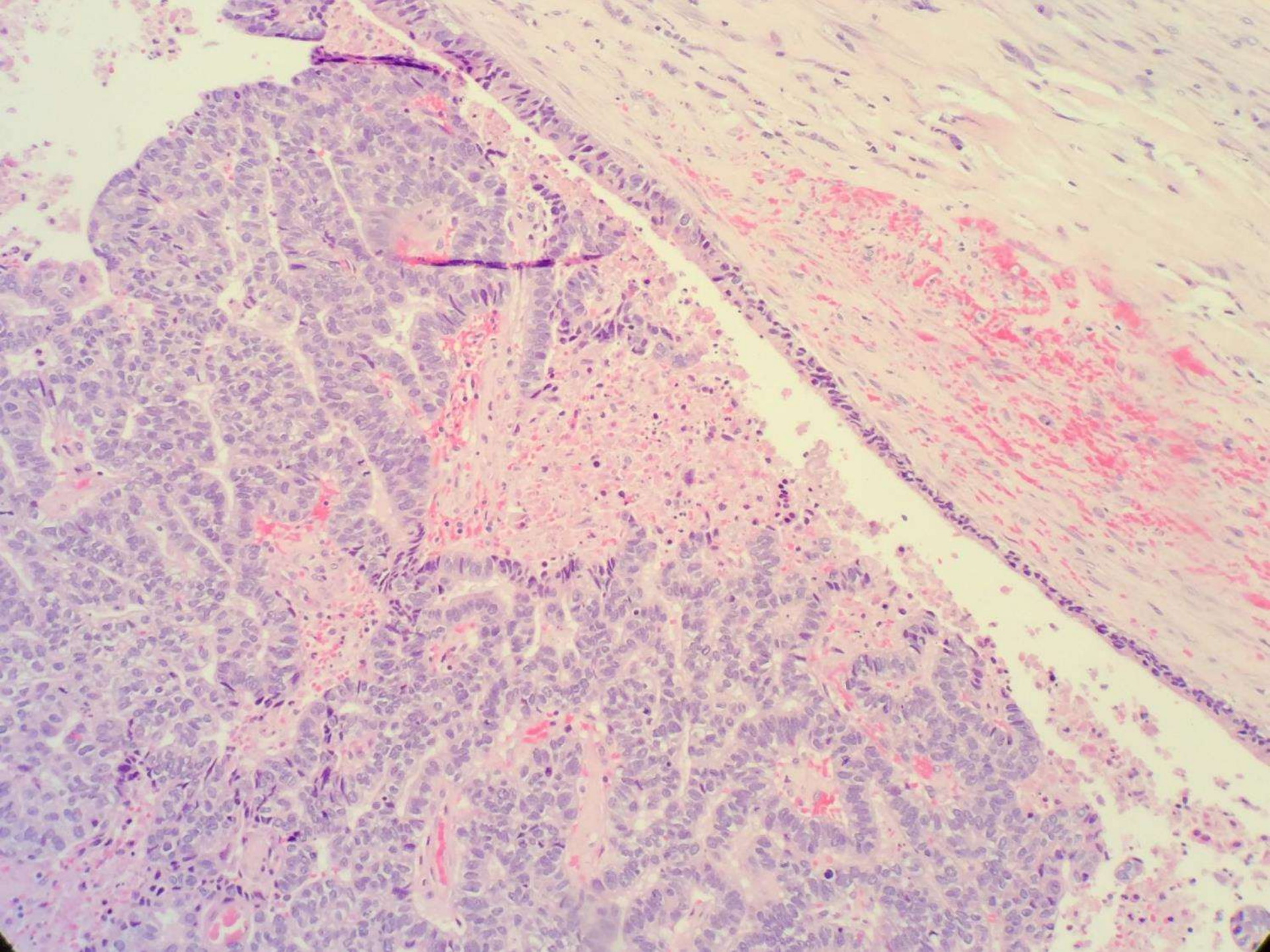




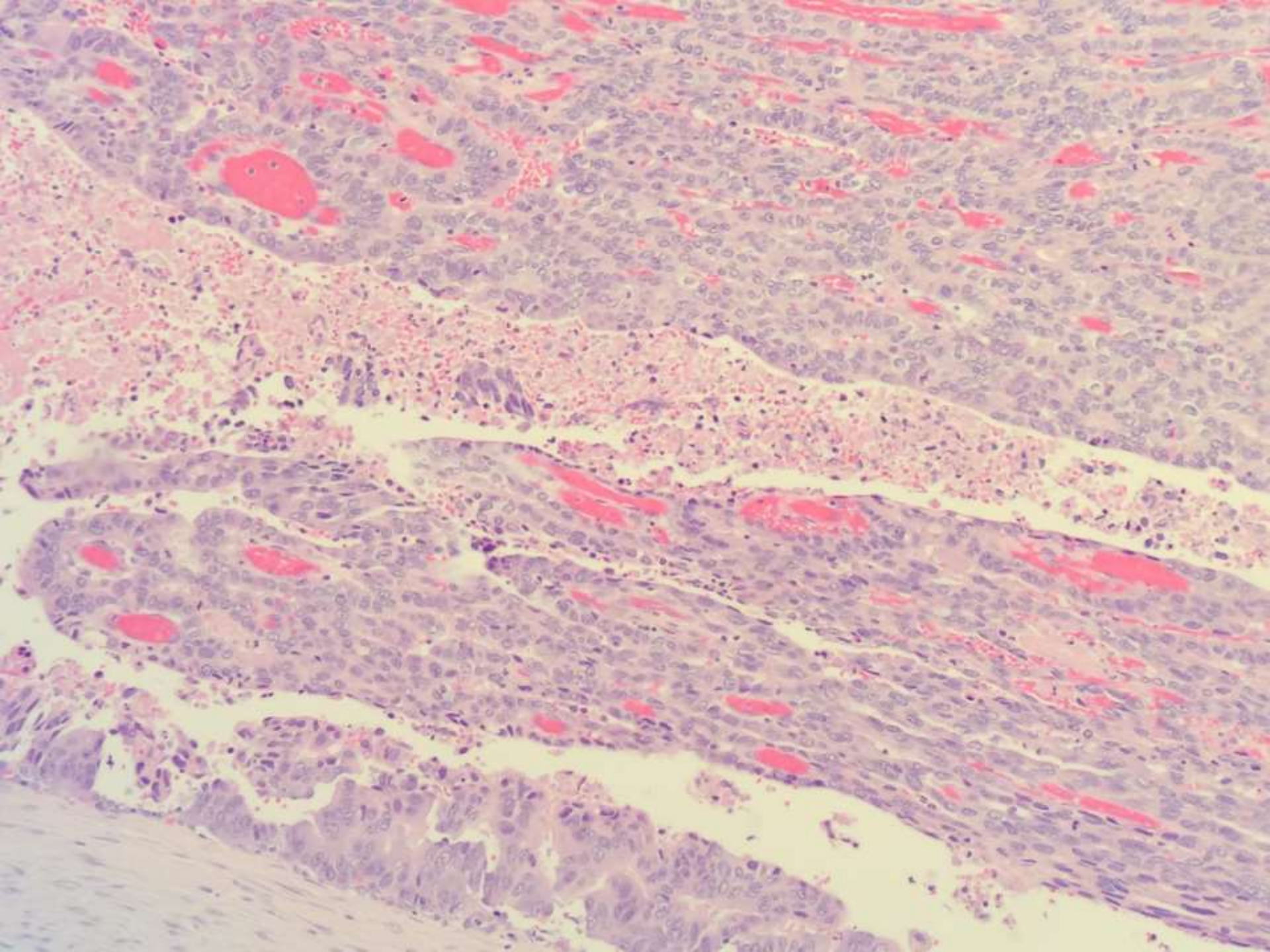
# 5885

- 76-year-old female with pancreatic mass in the uncinate process. Whipple procedure performed.
- **Mike DiMaio/Teri Longacre; Stanford**

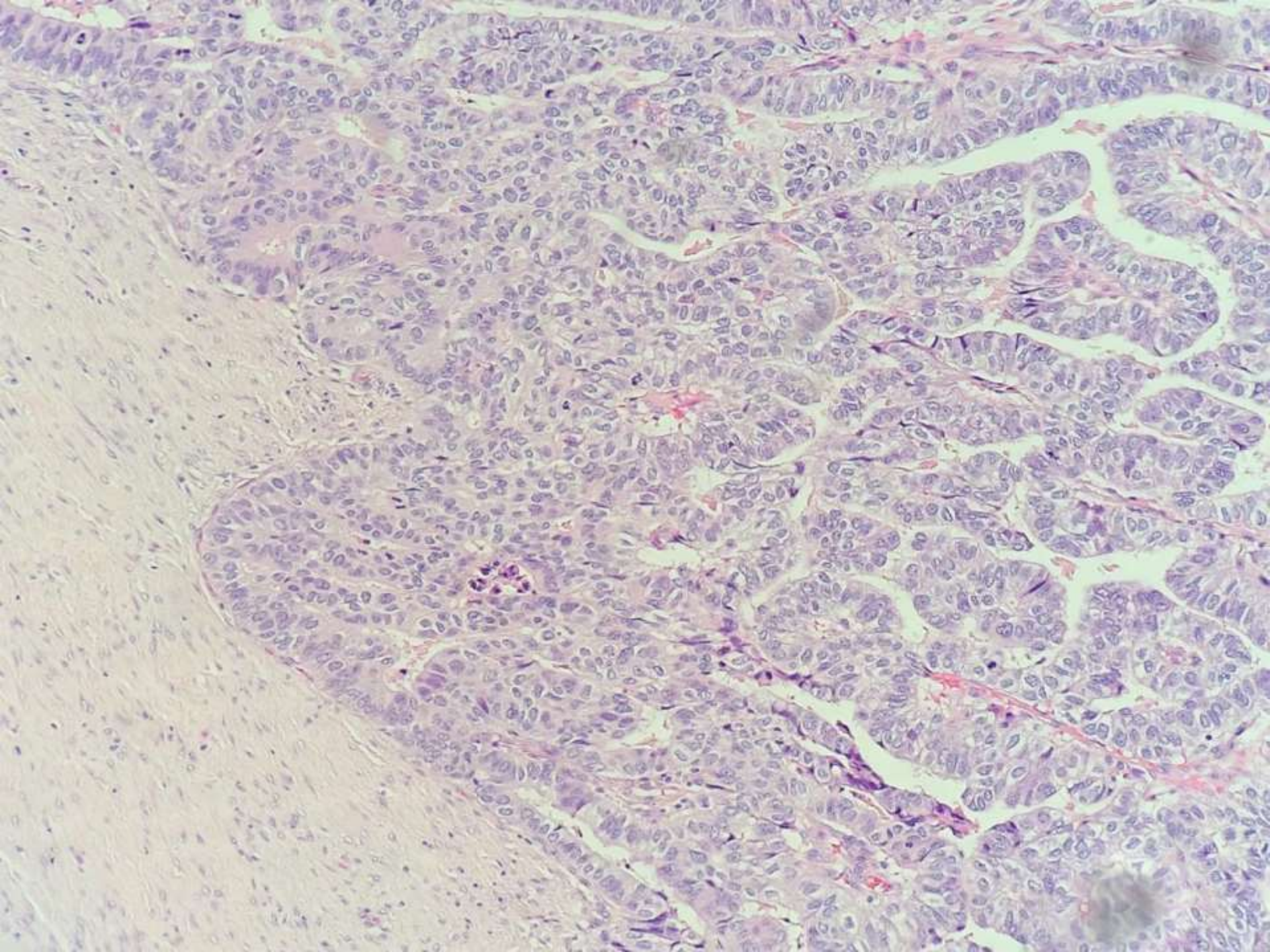




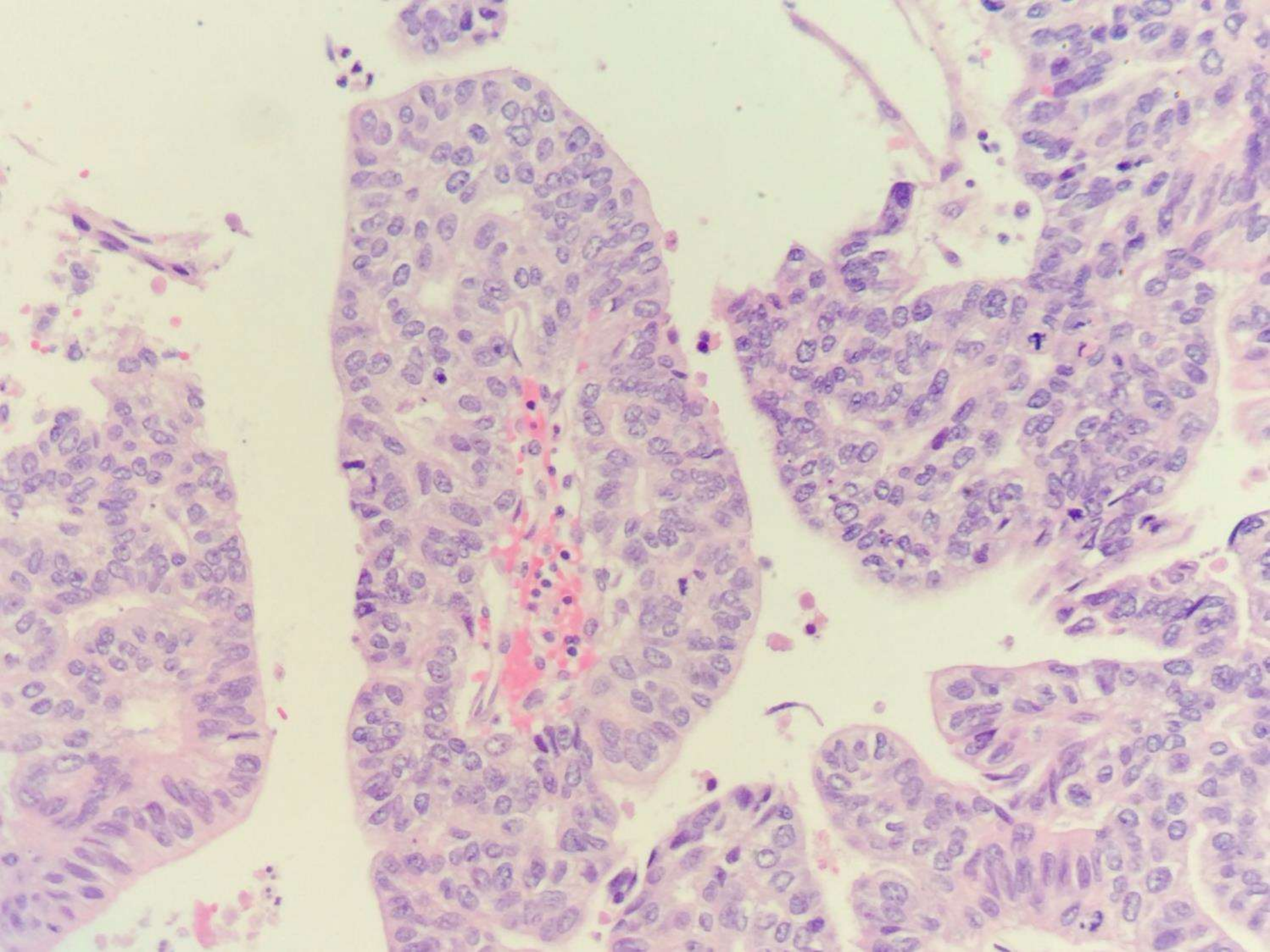




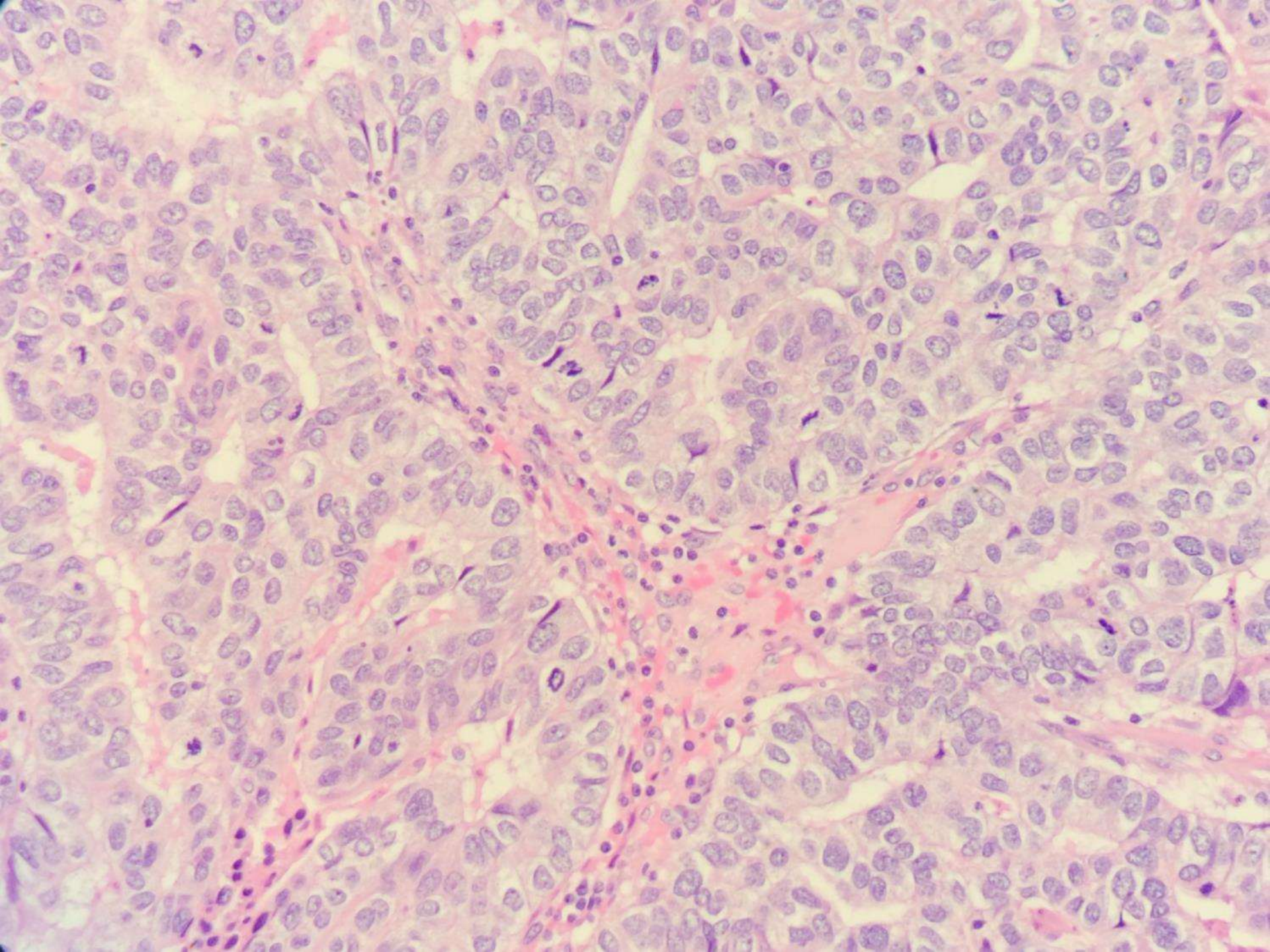




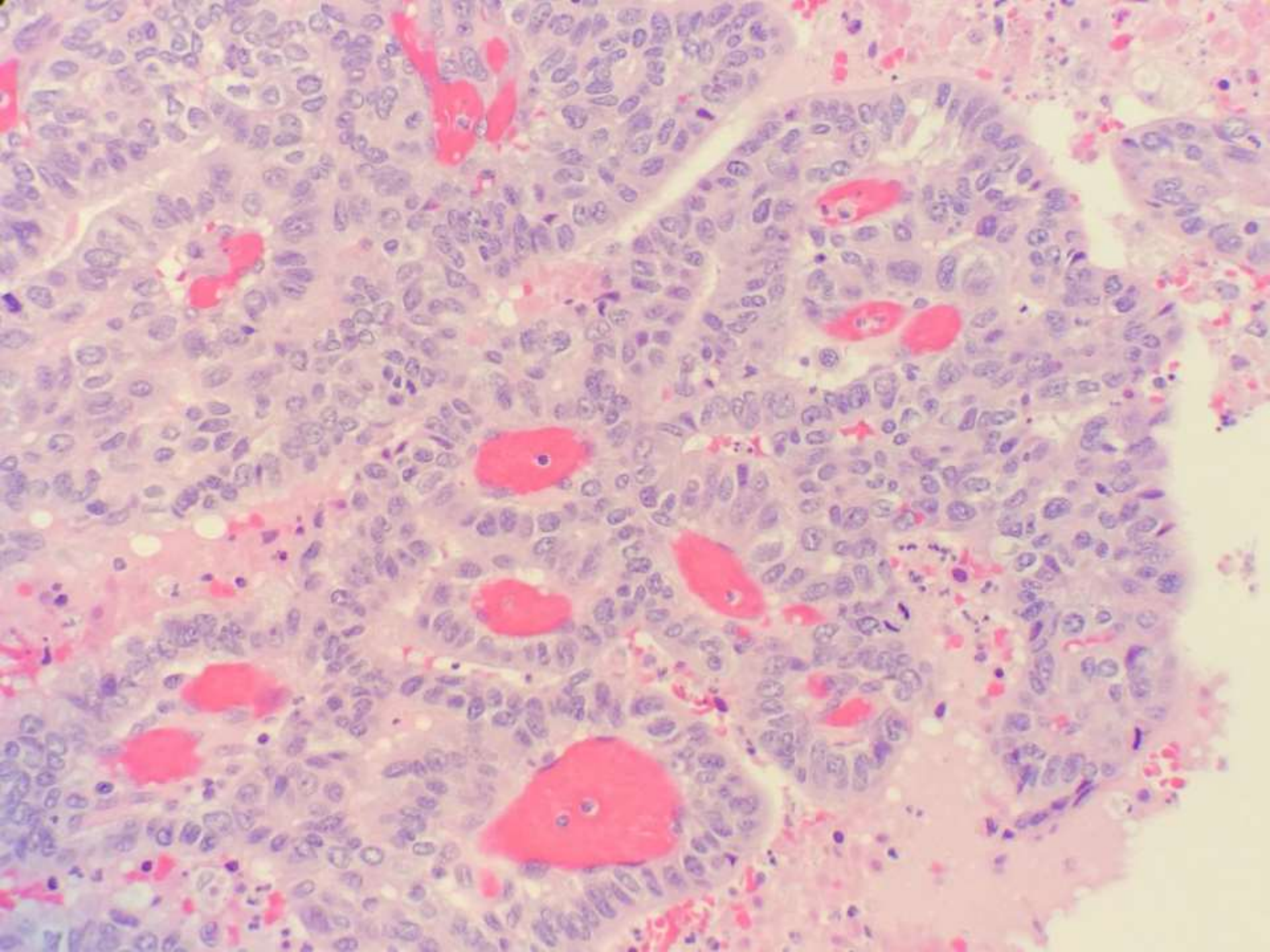




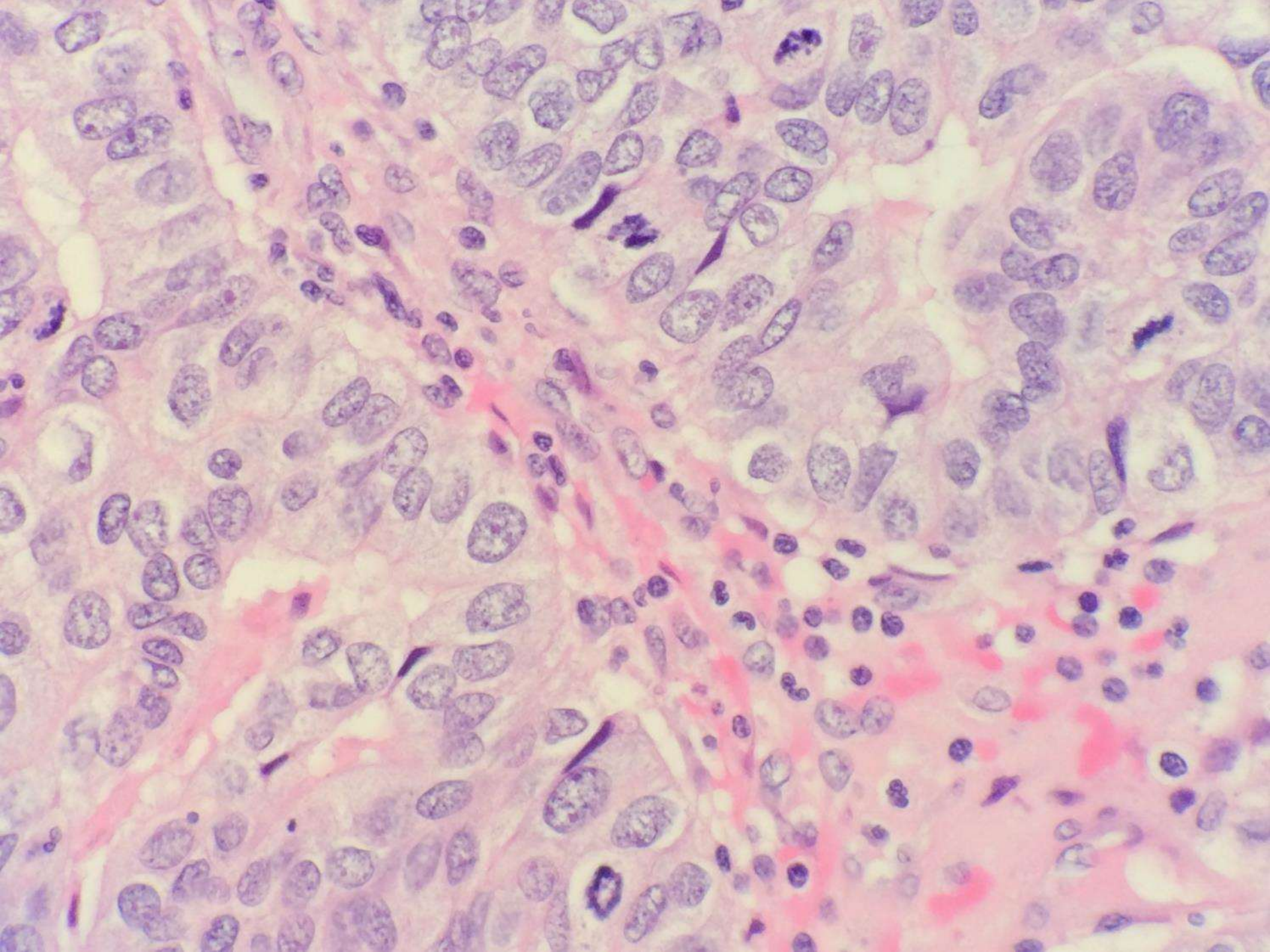










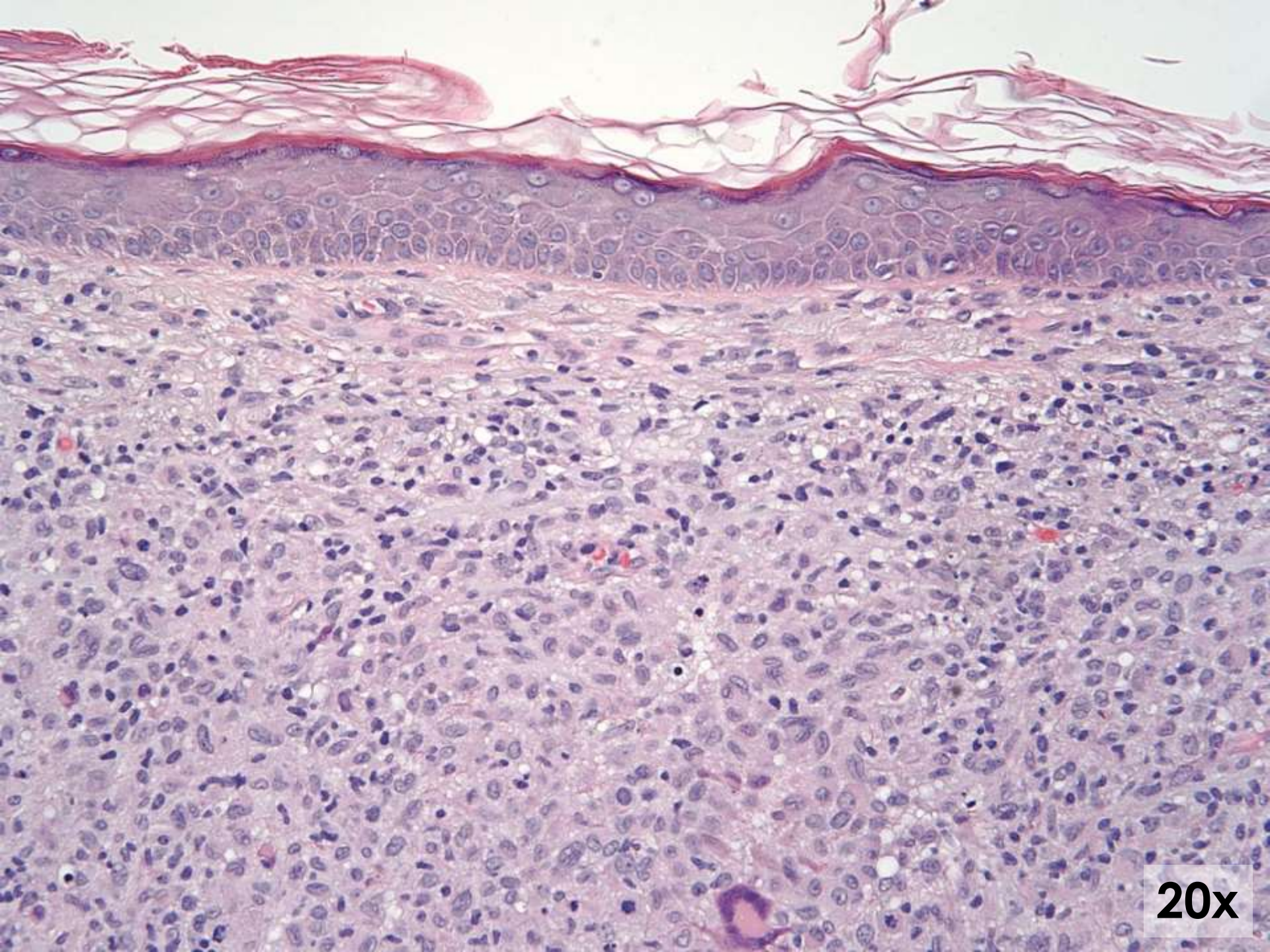




# 5886

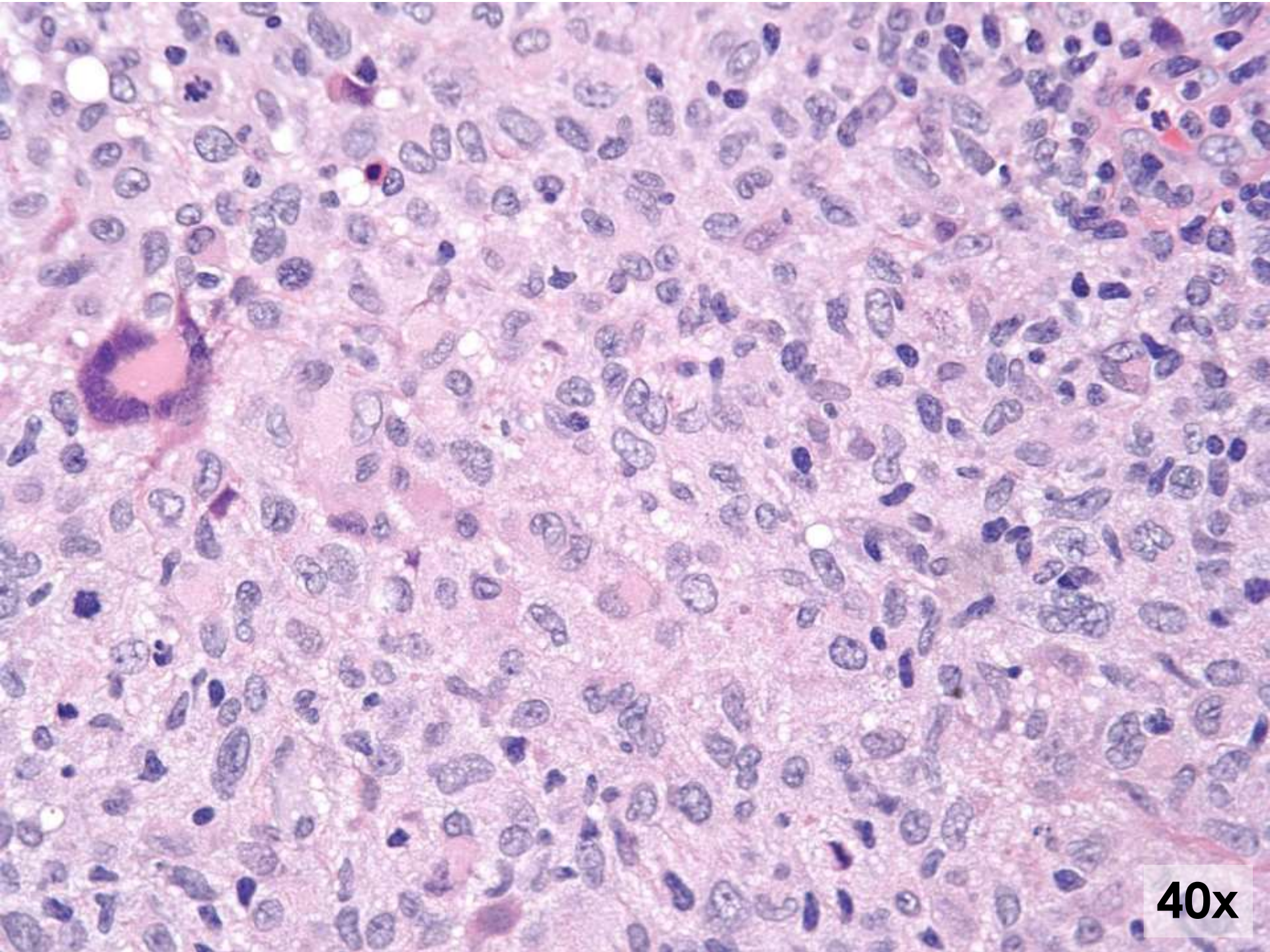
- 62-year-old female with 30+year history of papulonodular reddish-brown lesions involving face, chest, back, and extremities.
- **Ryanne Brown/Kerri Rieger/Jinah Kim;  
Stanford**





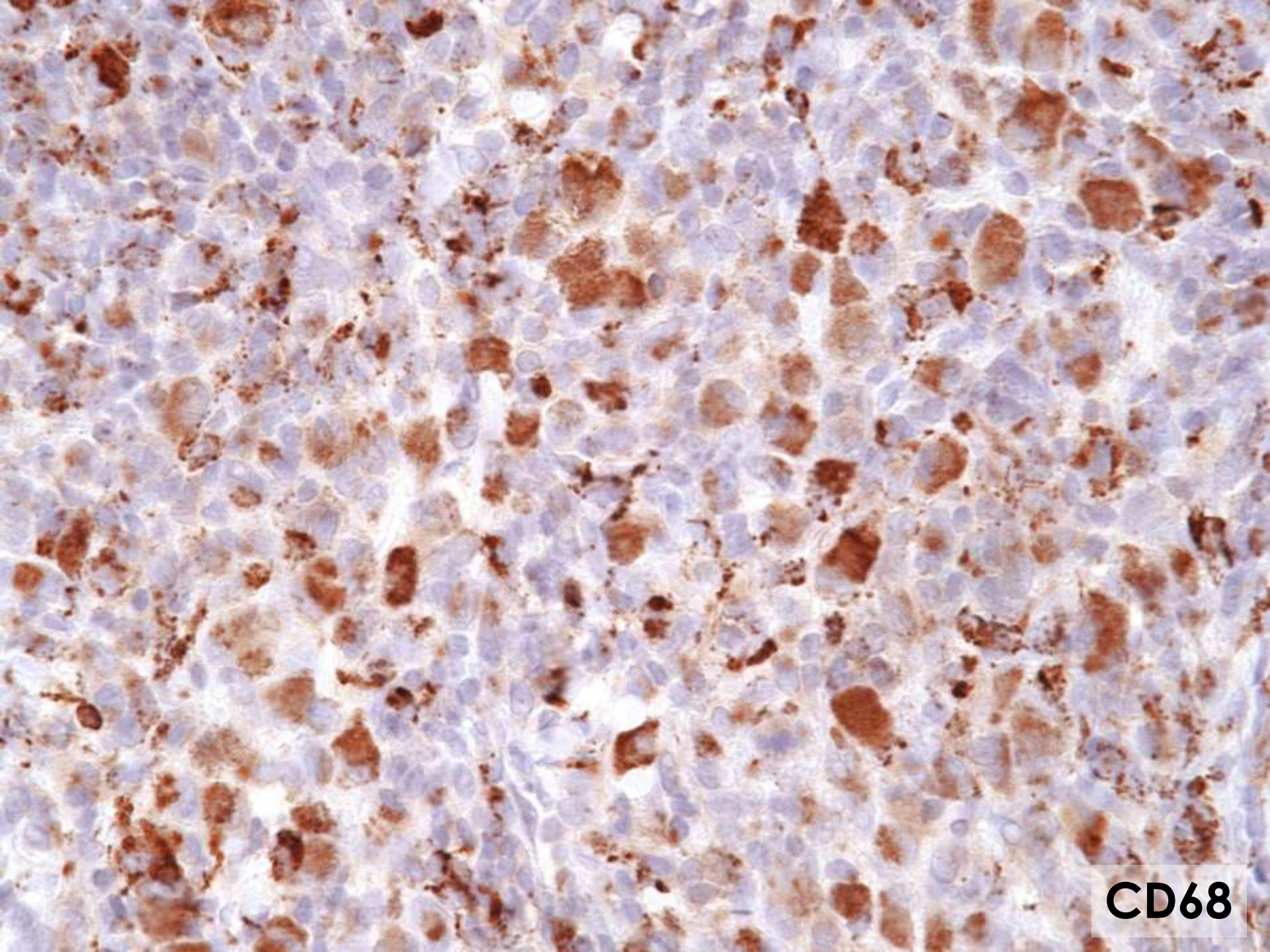
20x





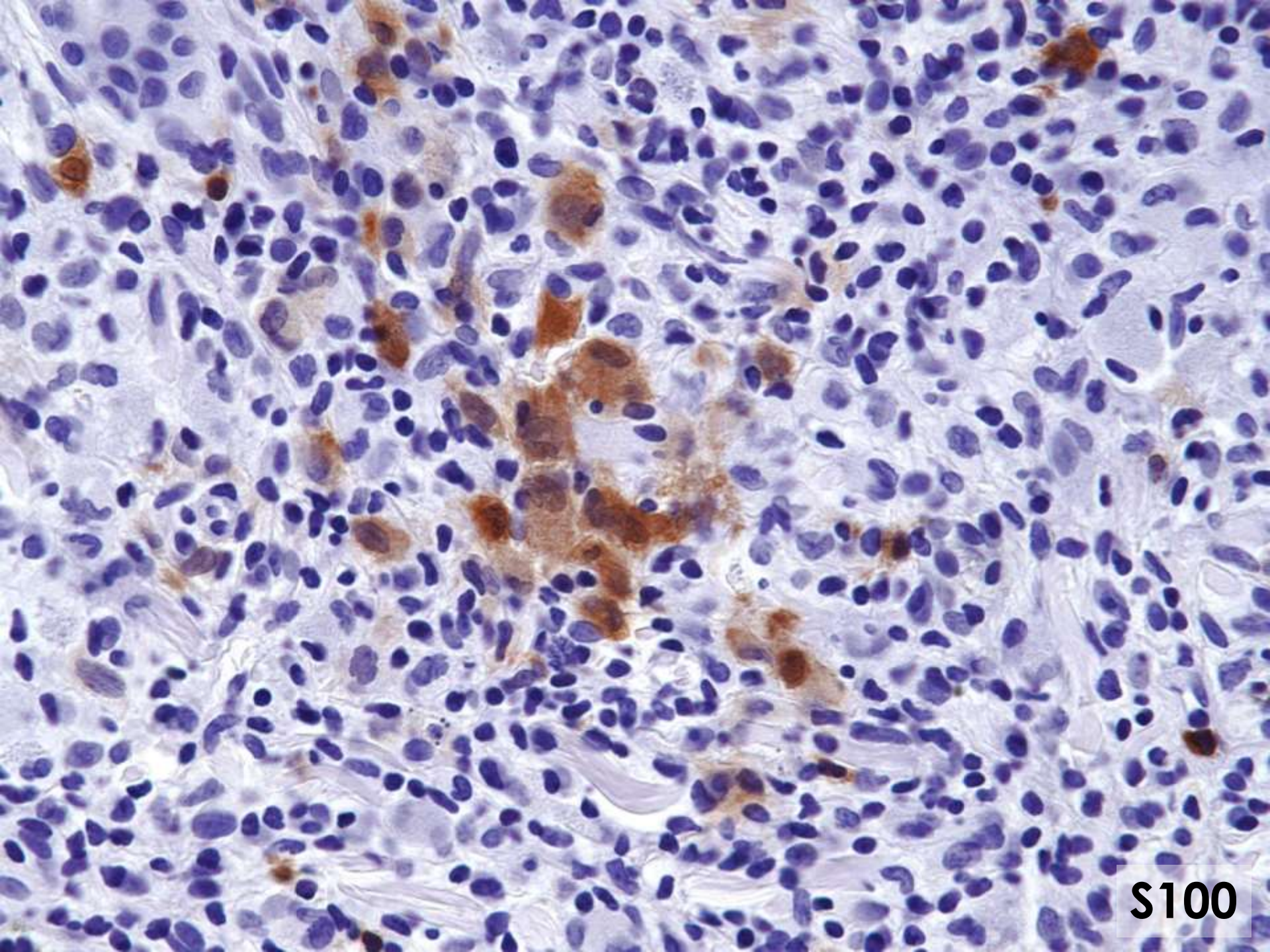
40x





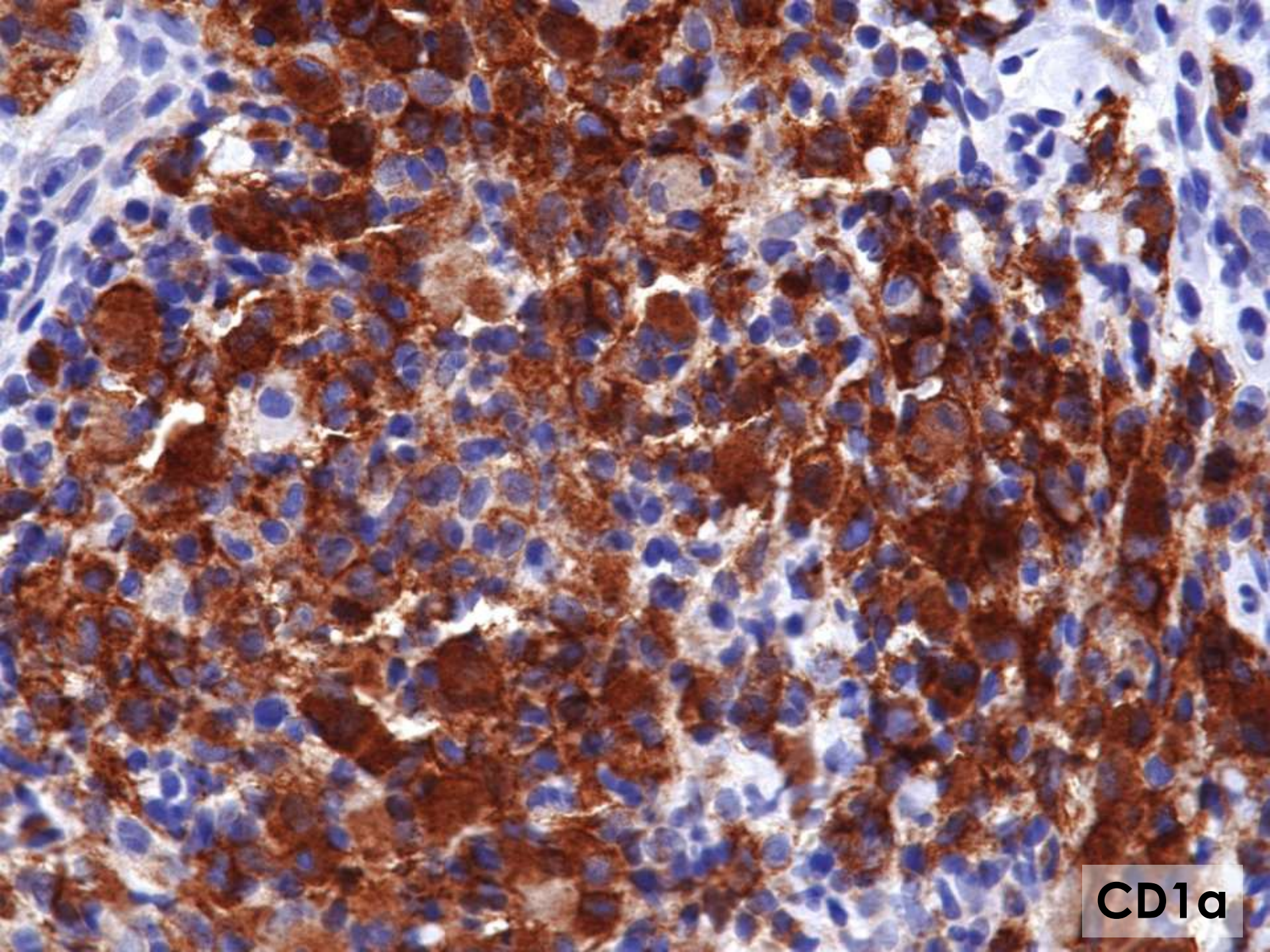
**CD68**





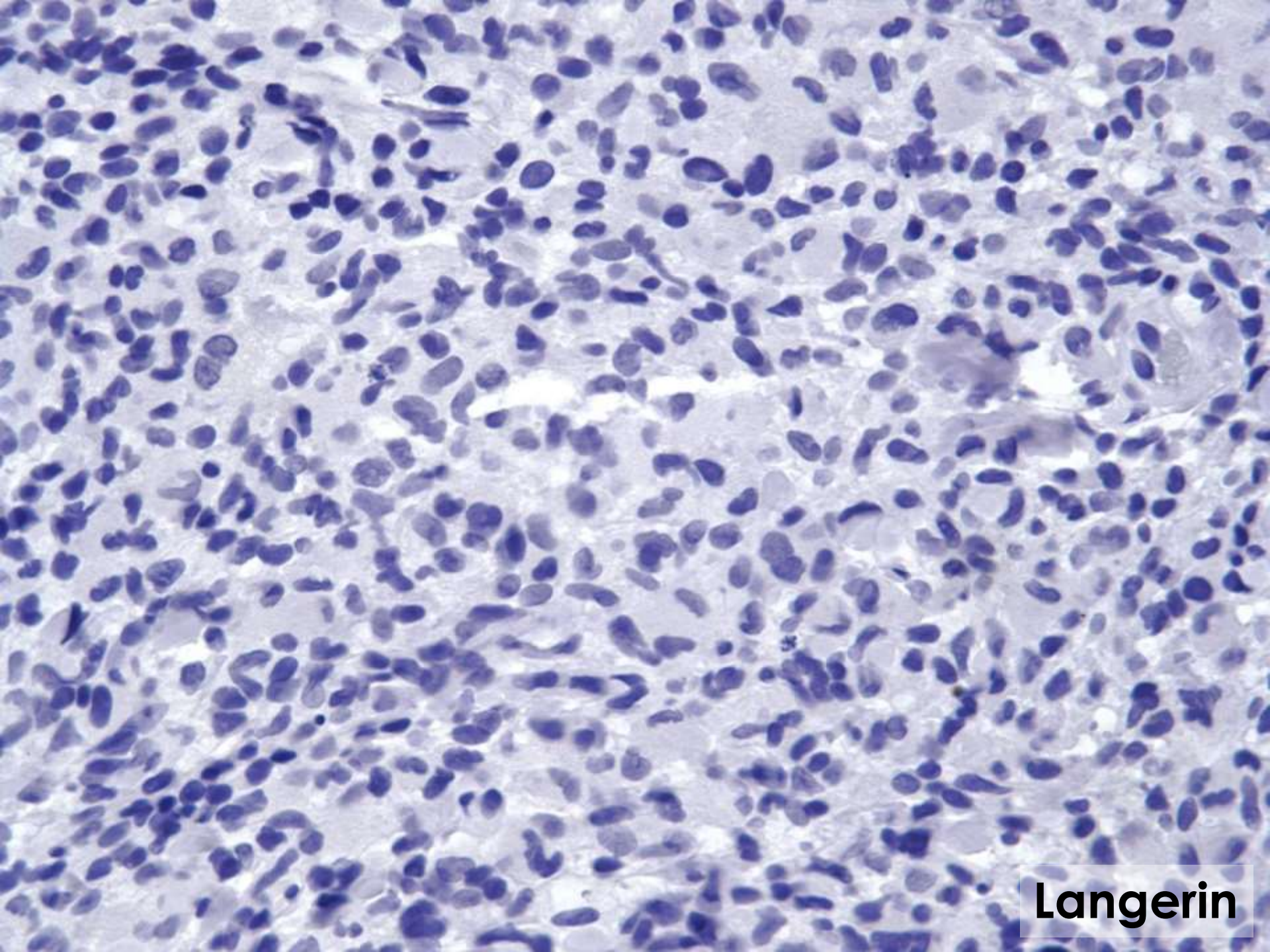
**S100**





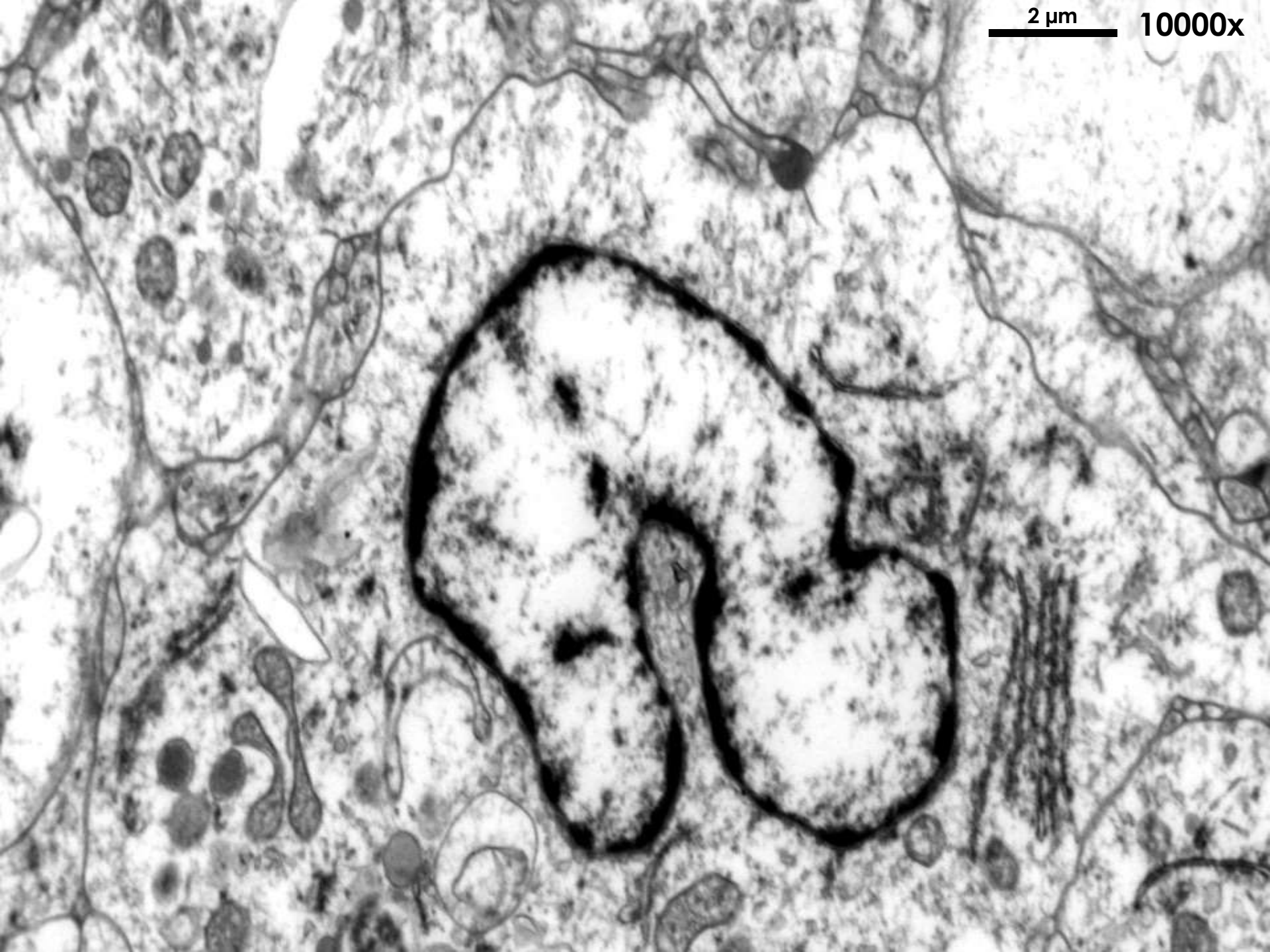
CD1a





Langerin





2  $\mu$ m

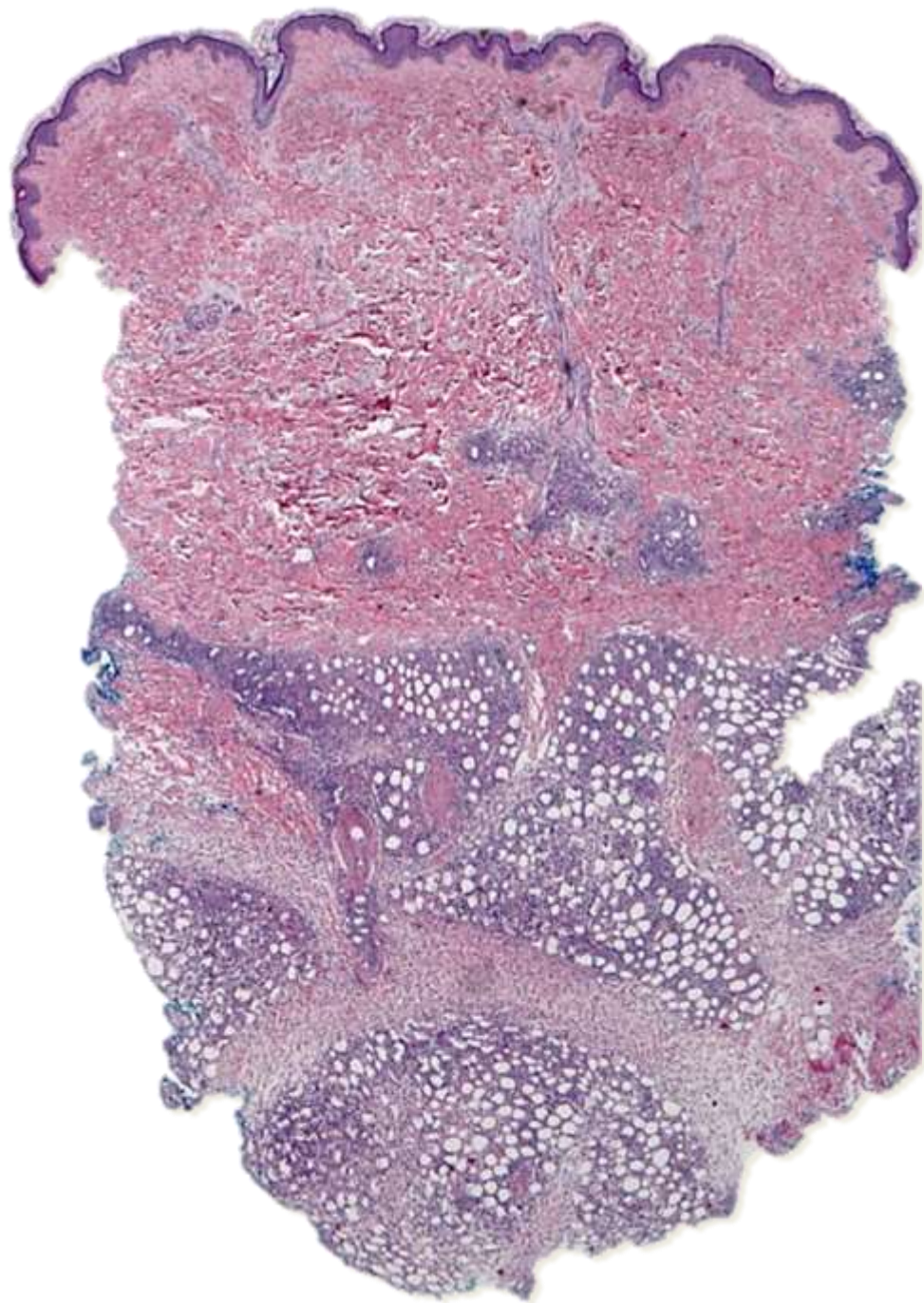
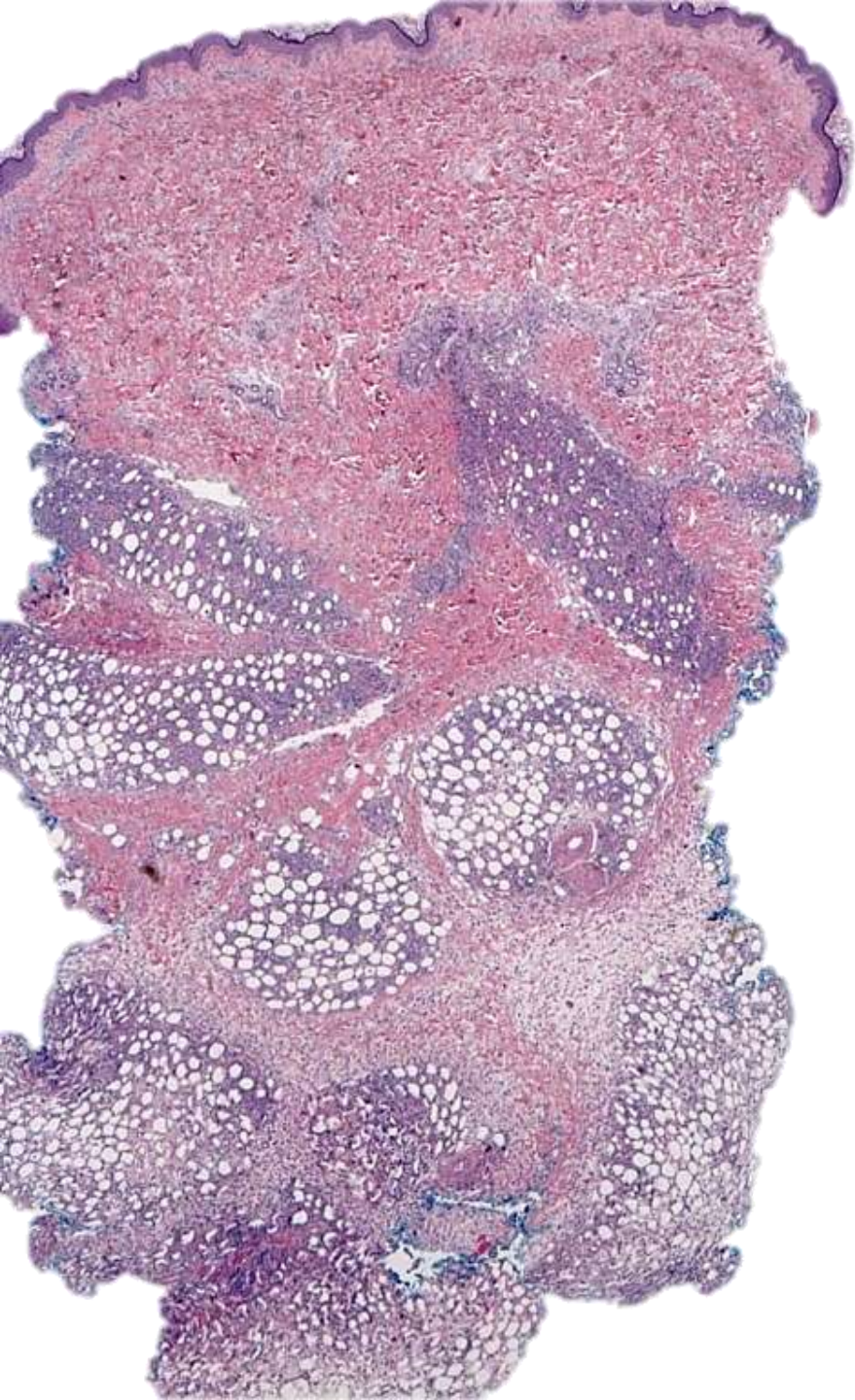
10000x



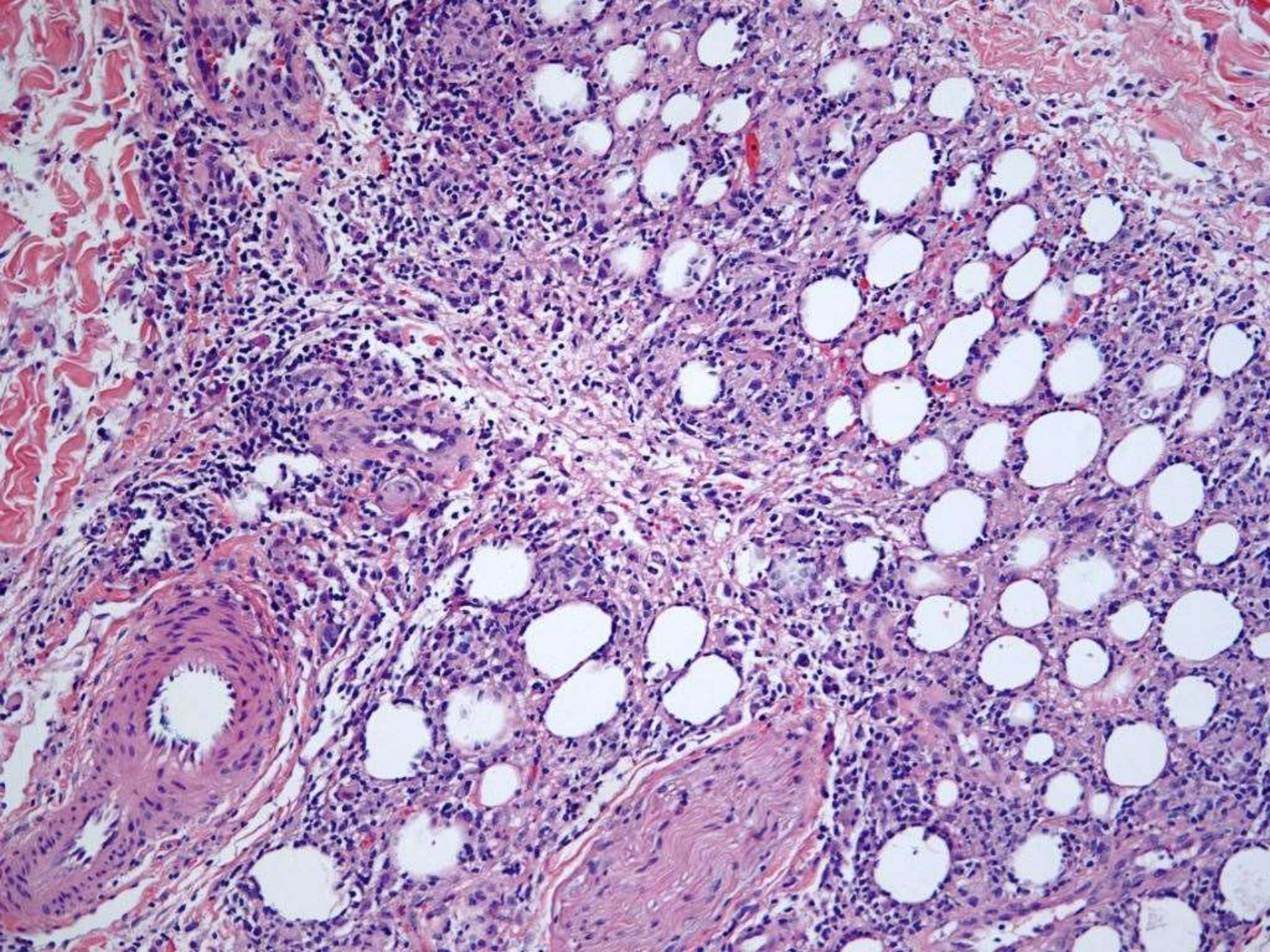
# 5887

- 14-year-old female with fever, fatigue, and a several week history of tender, erythematous and ill-defined subcutaneous nodules on her arm, chin, and lower abdomen.
- **Robert LeBlanc/Jinah Kim; Stanford**

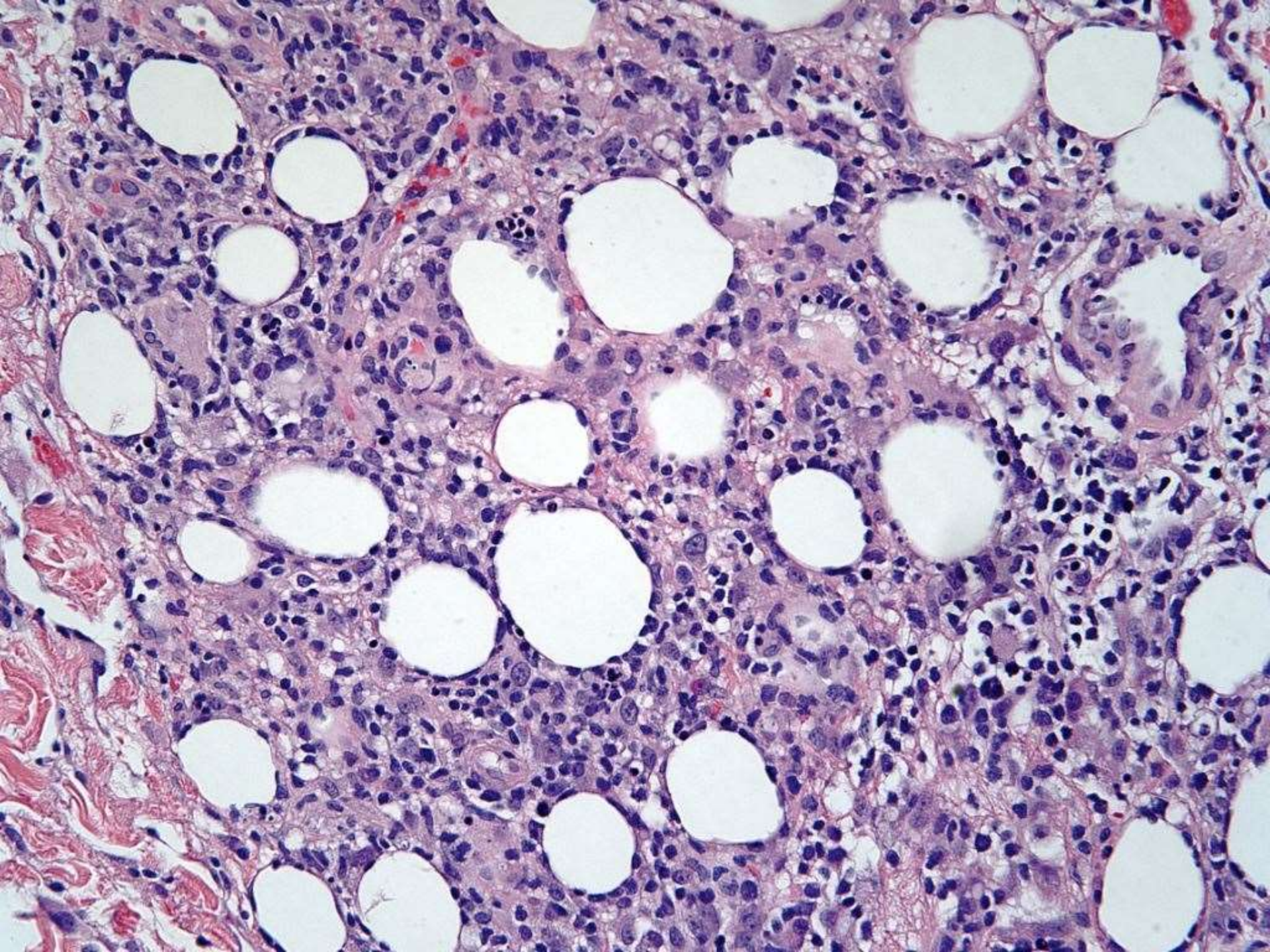




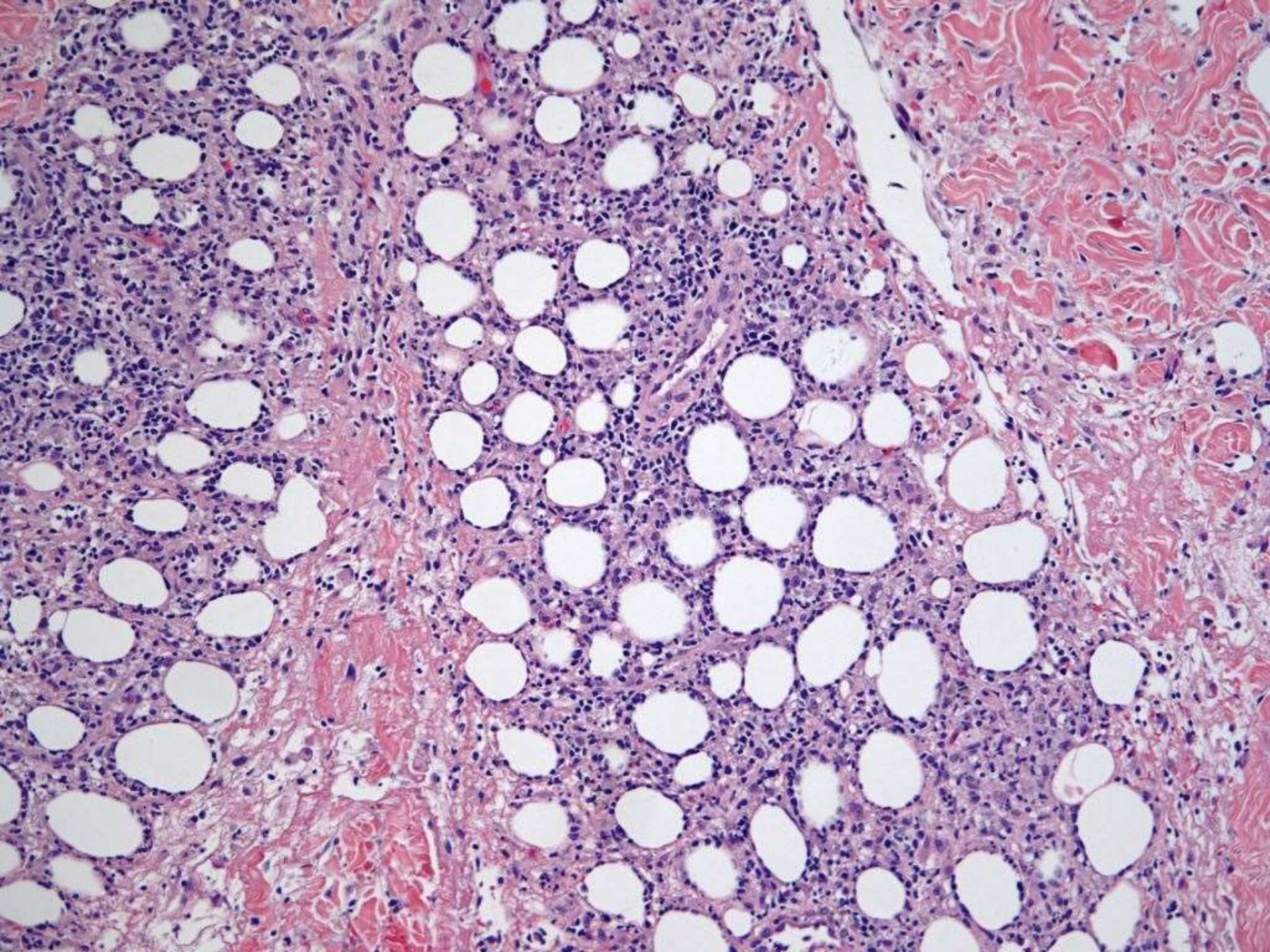




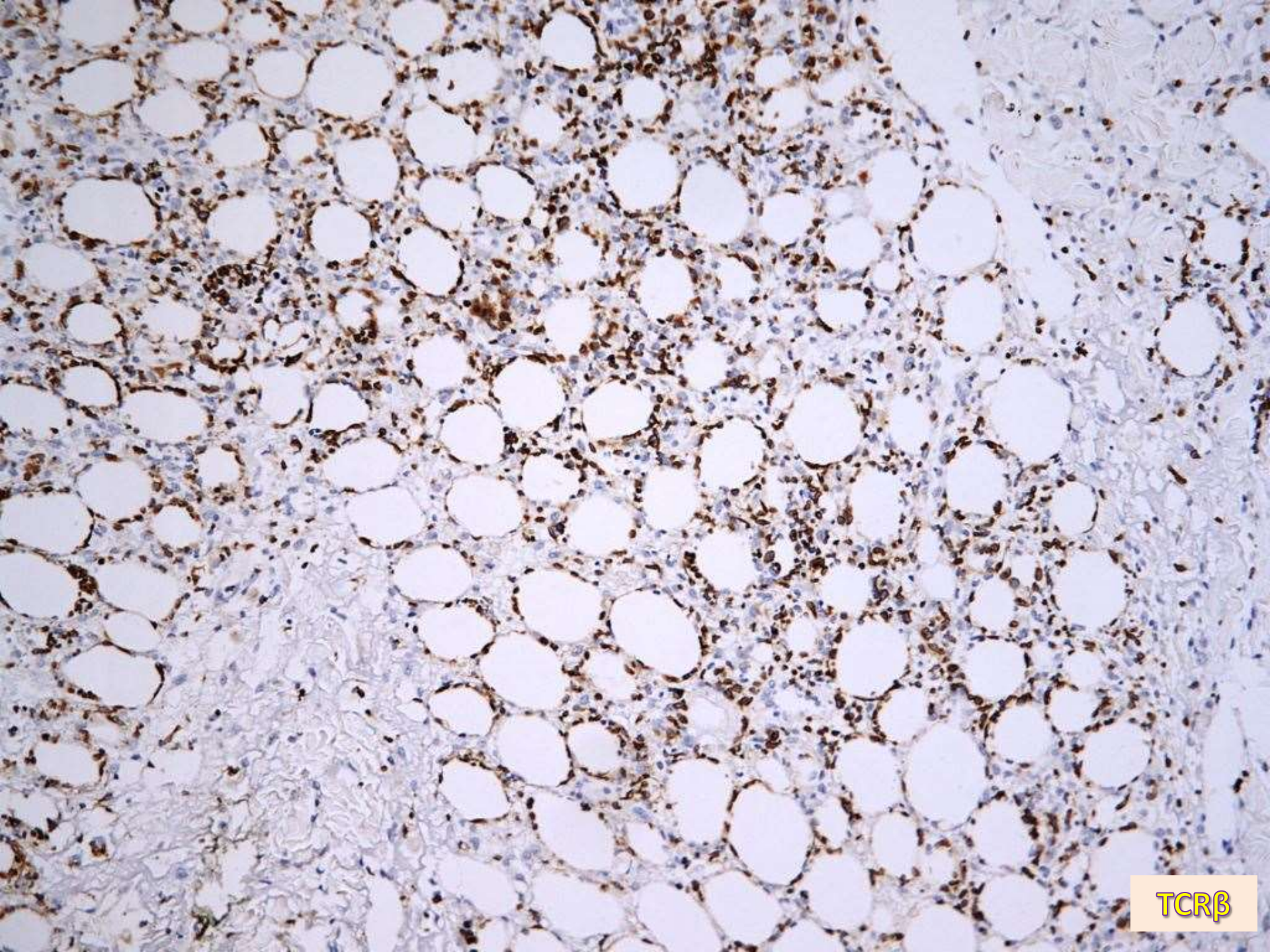






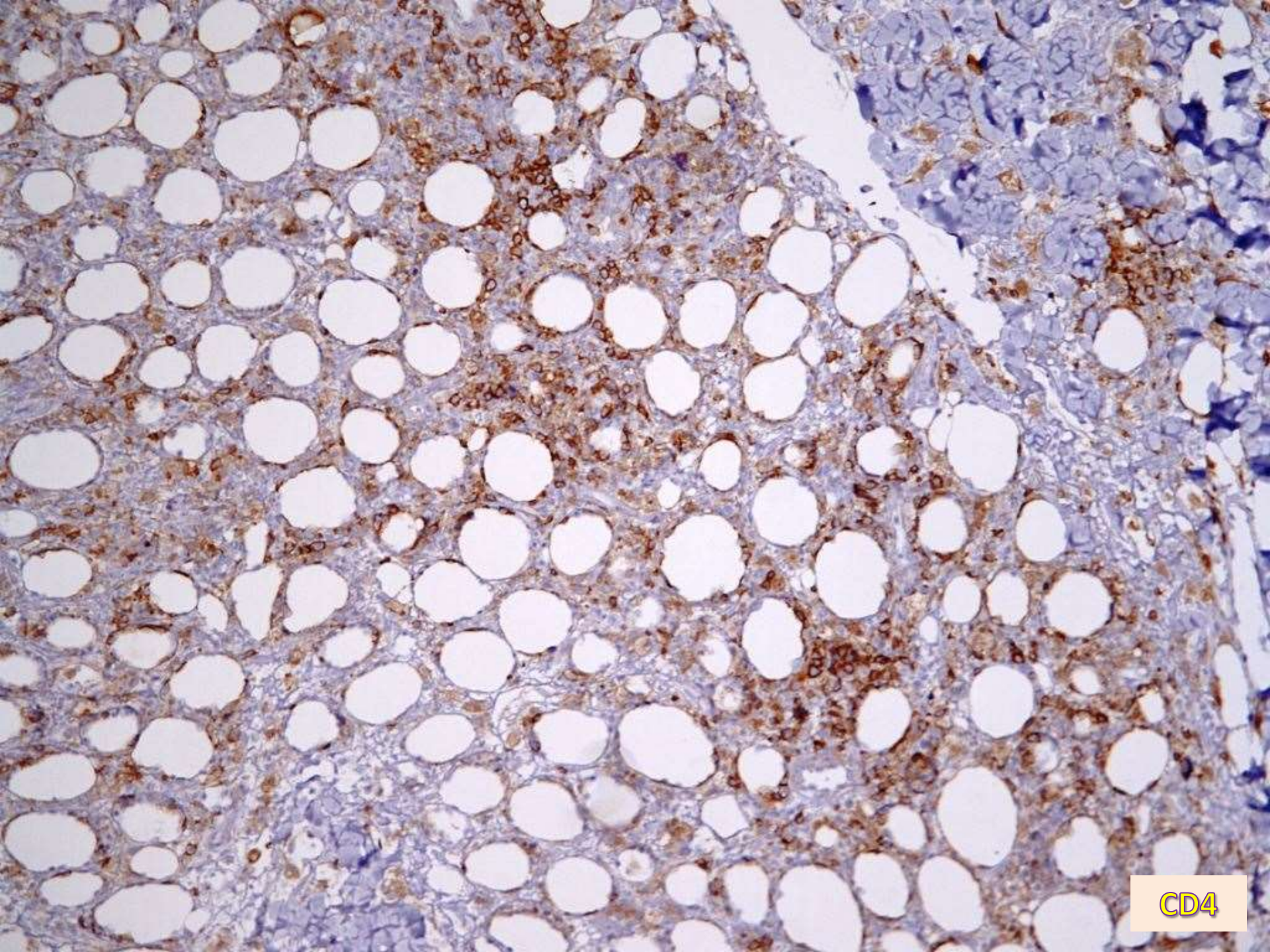






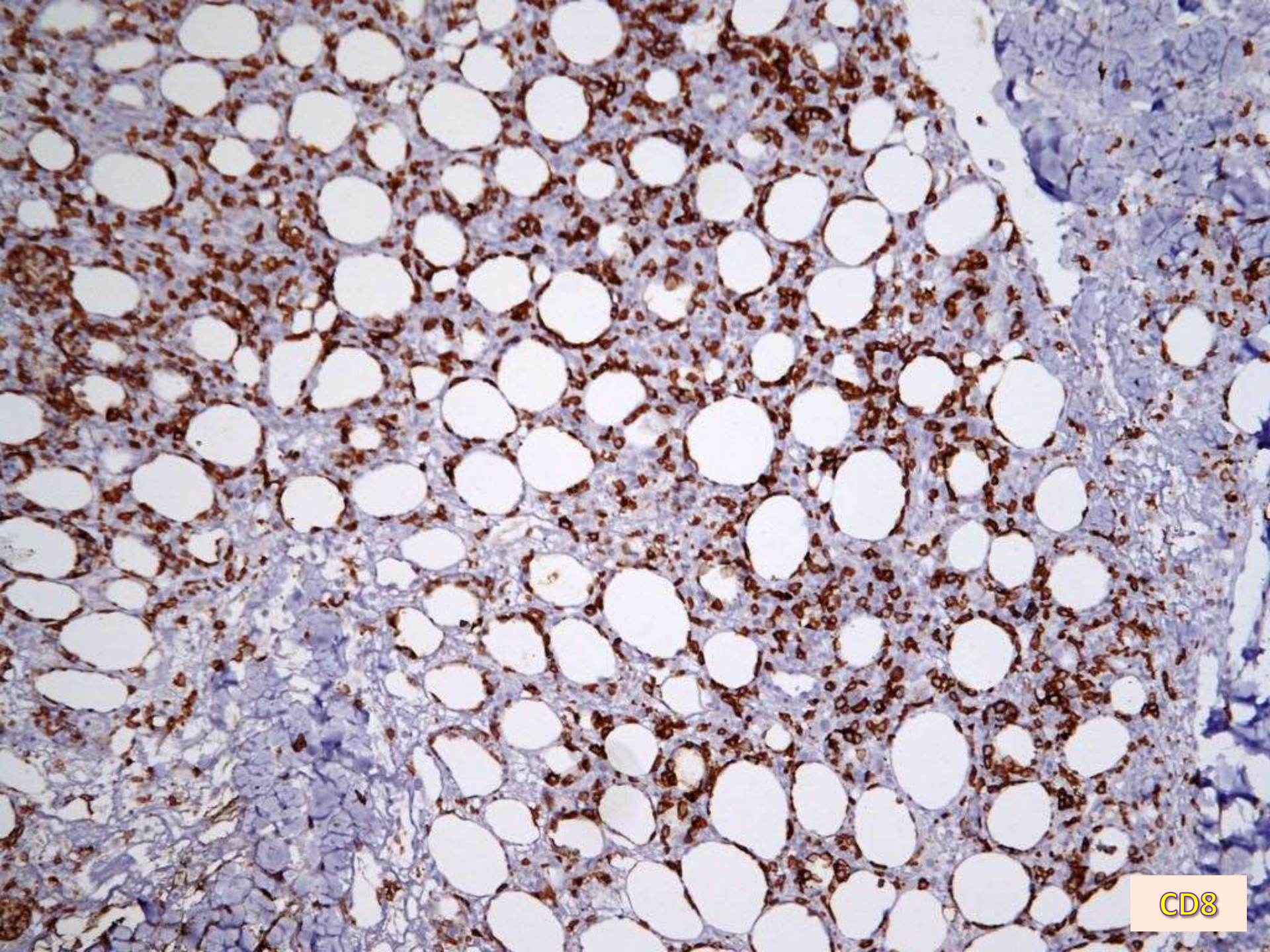
TCRβ





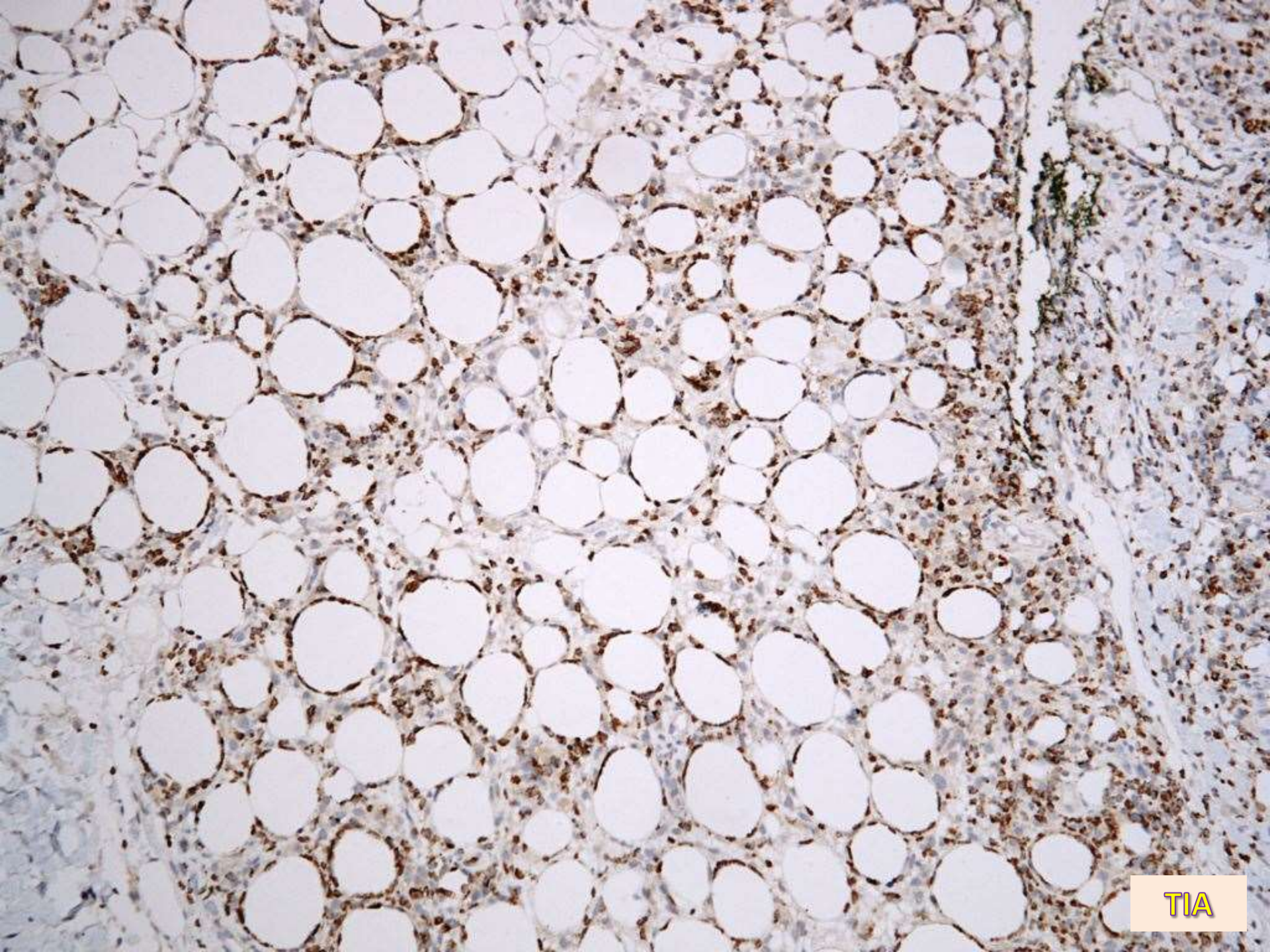
CD4





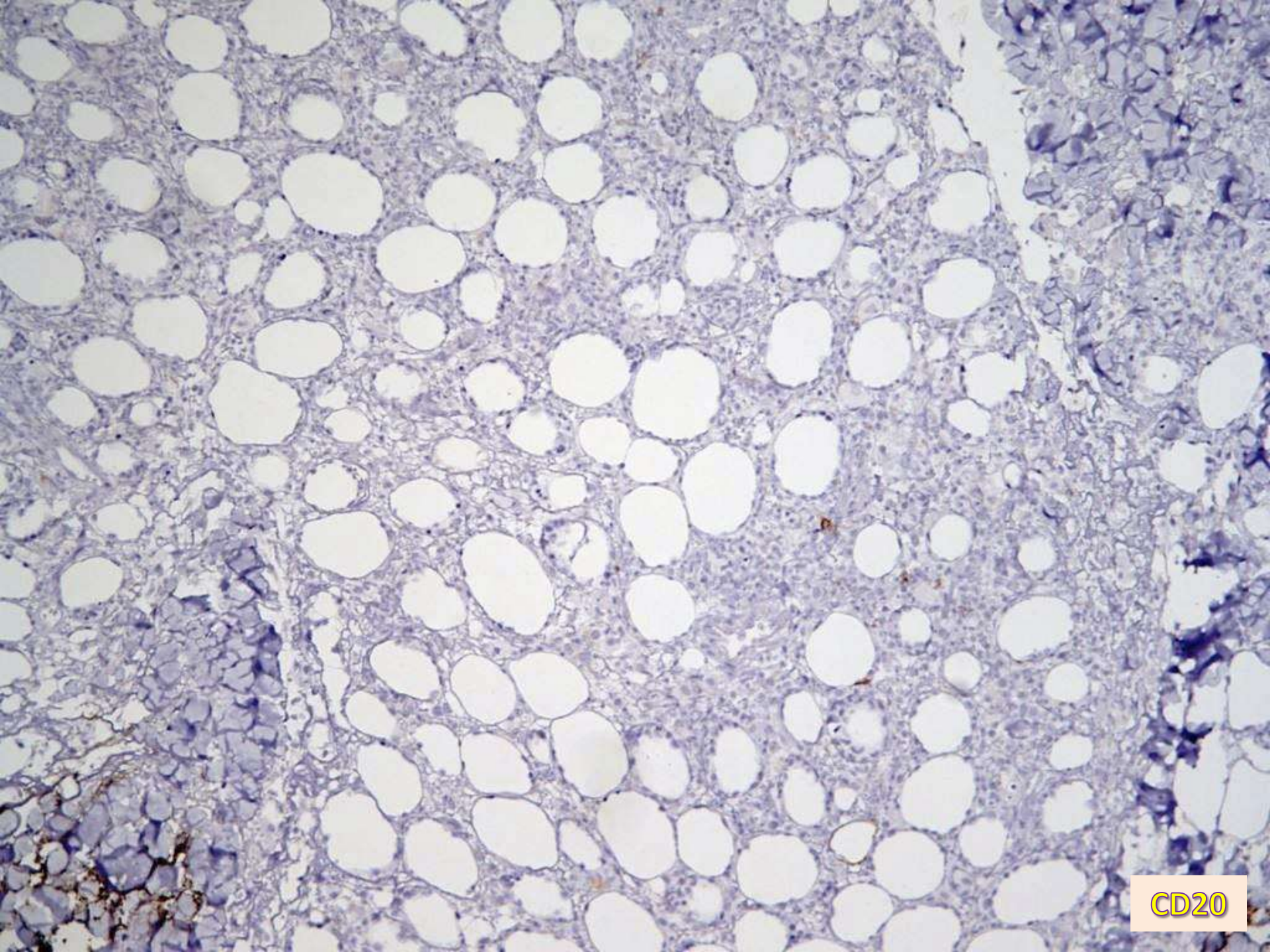
CD8





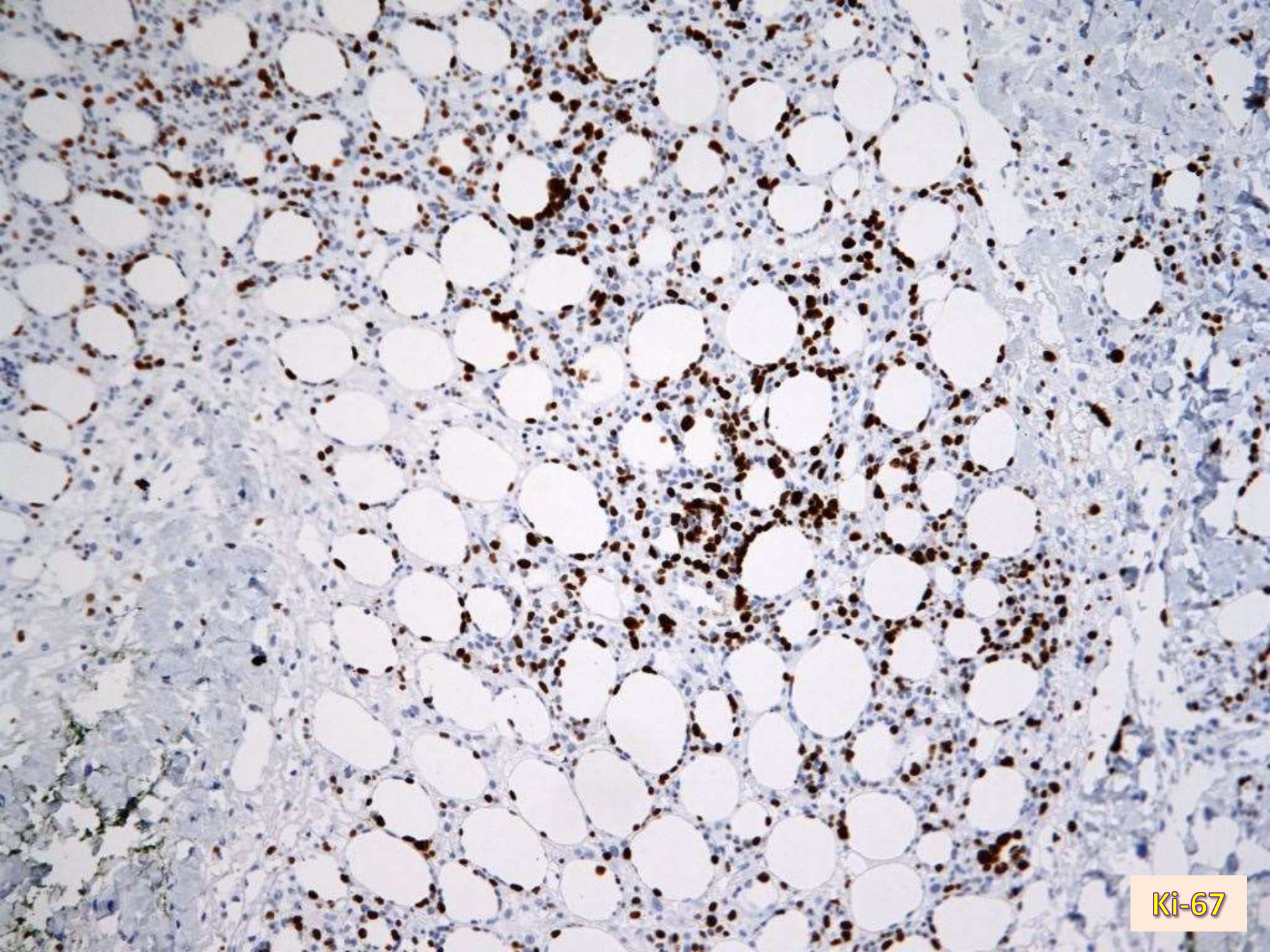
TIA





CD20





Ki-67





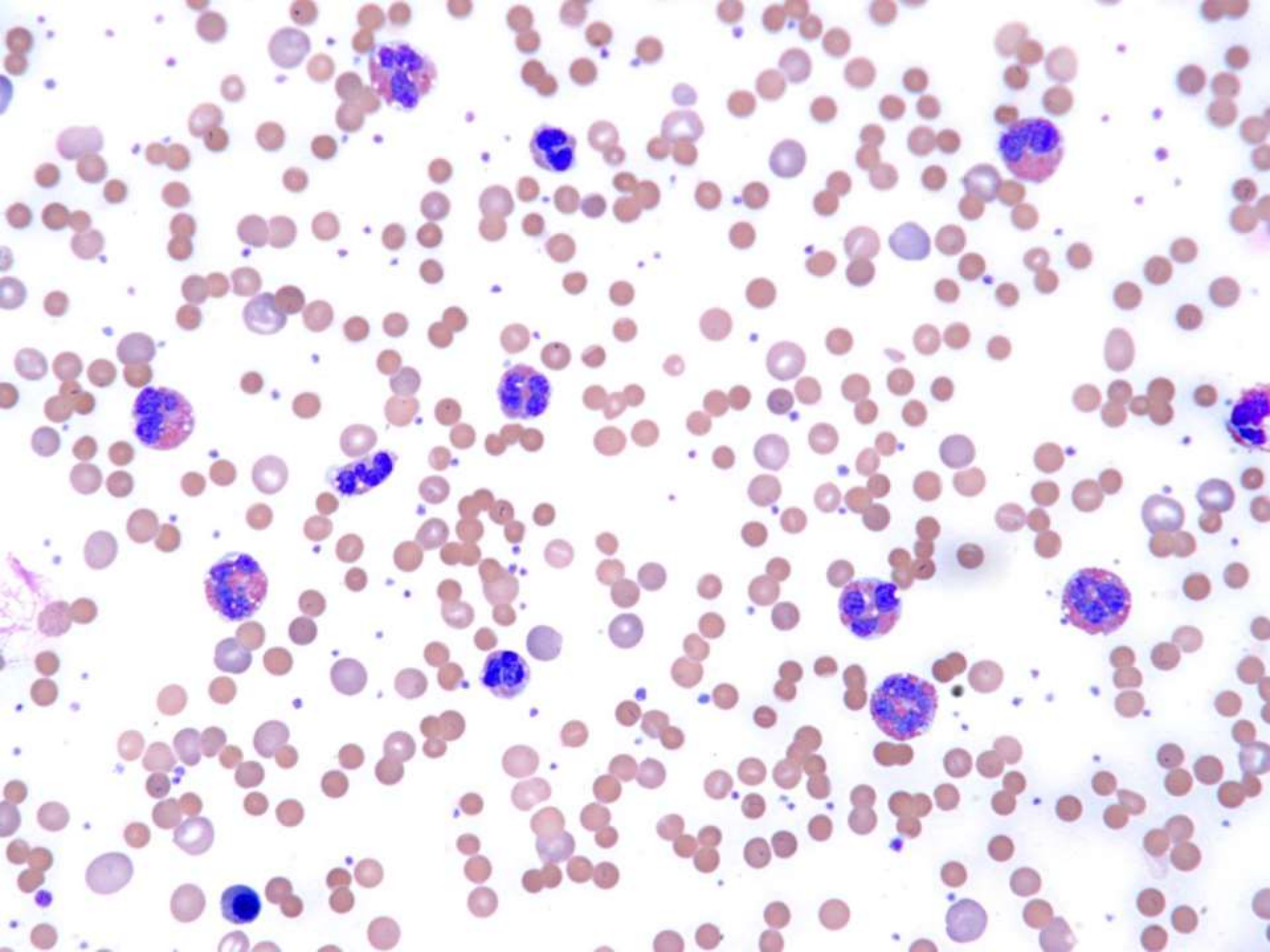
Ki-67



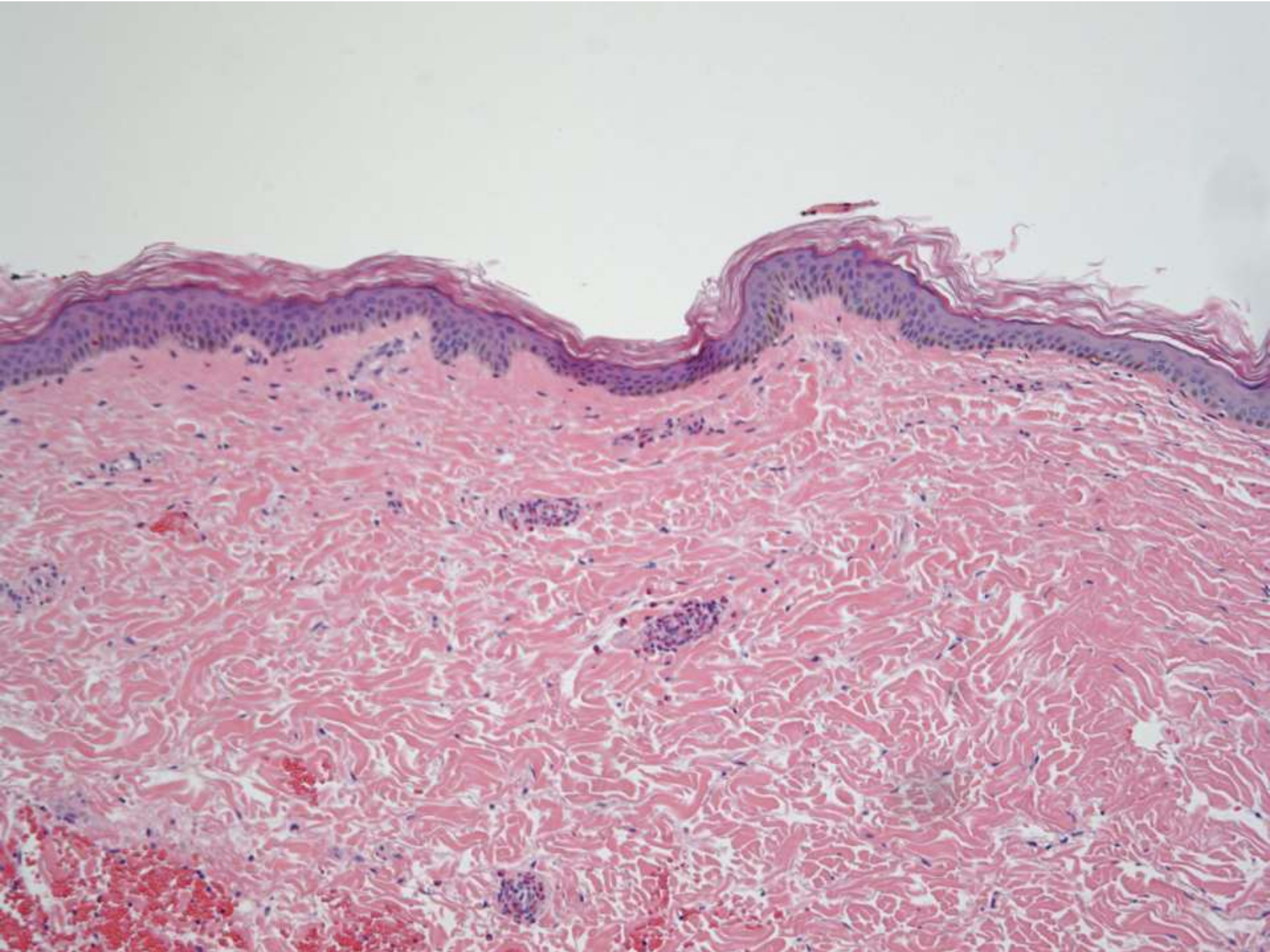
# 5888

- 29-year-old female with history of asthma and 3 week history of progressive fatigue, shortness of breath, non-productive cough, upper abdominal pain, vomiting, diarrhea, and lower extremity edema. Skin examination revealed multiple urticarial plaques on the thighs.
- **Christopher Soon/Jinah Kim; Stanford**

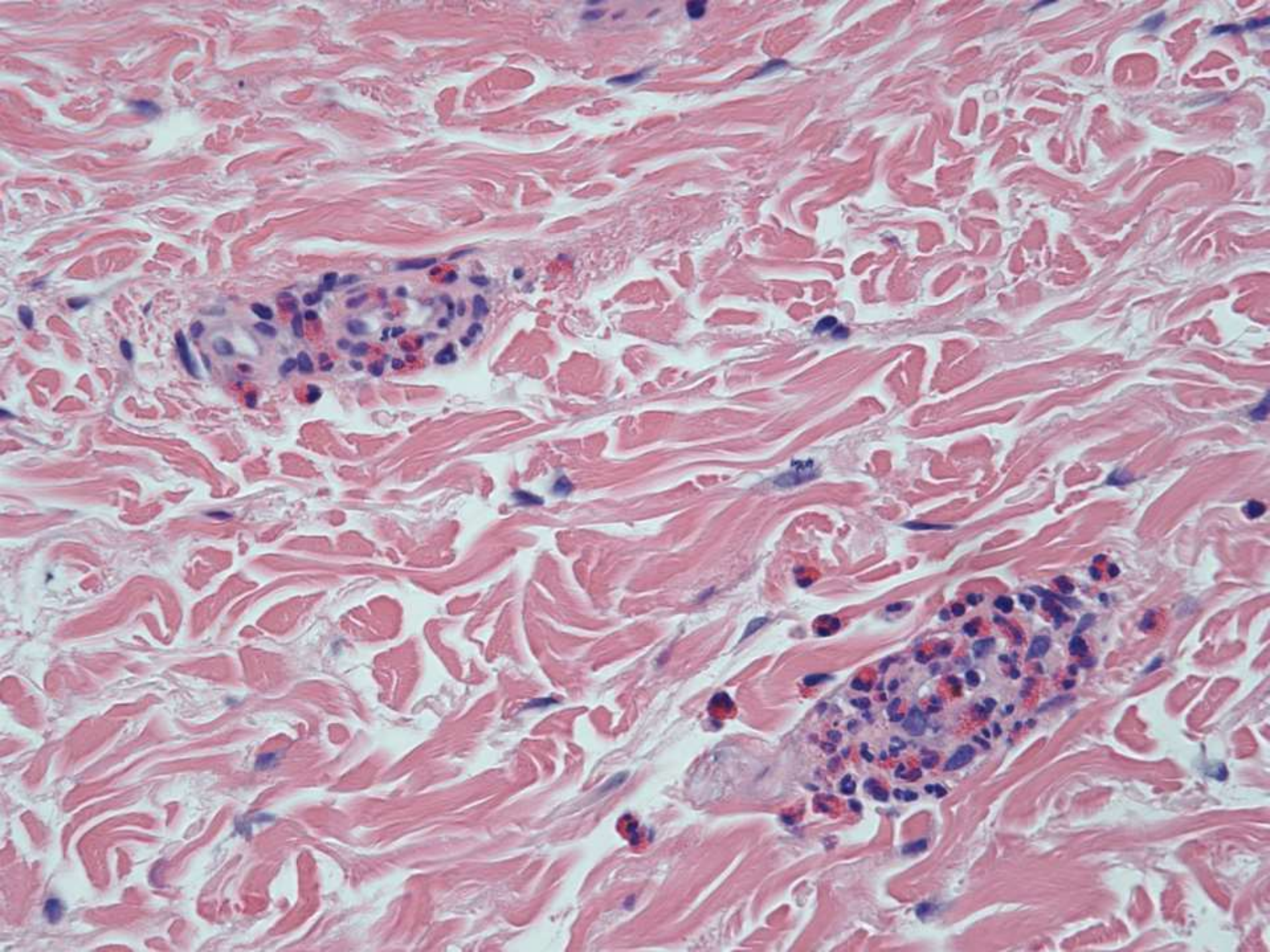




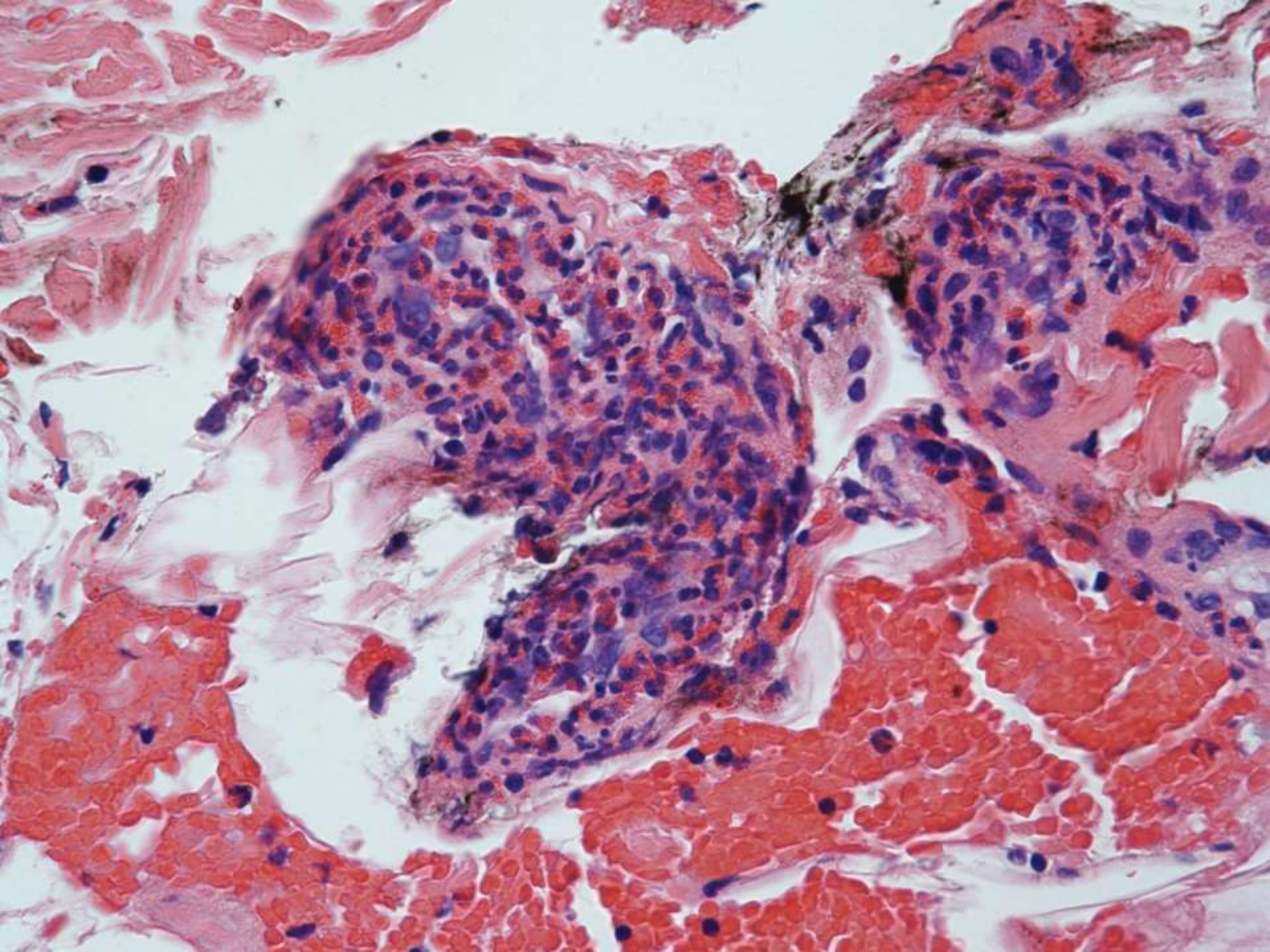




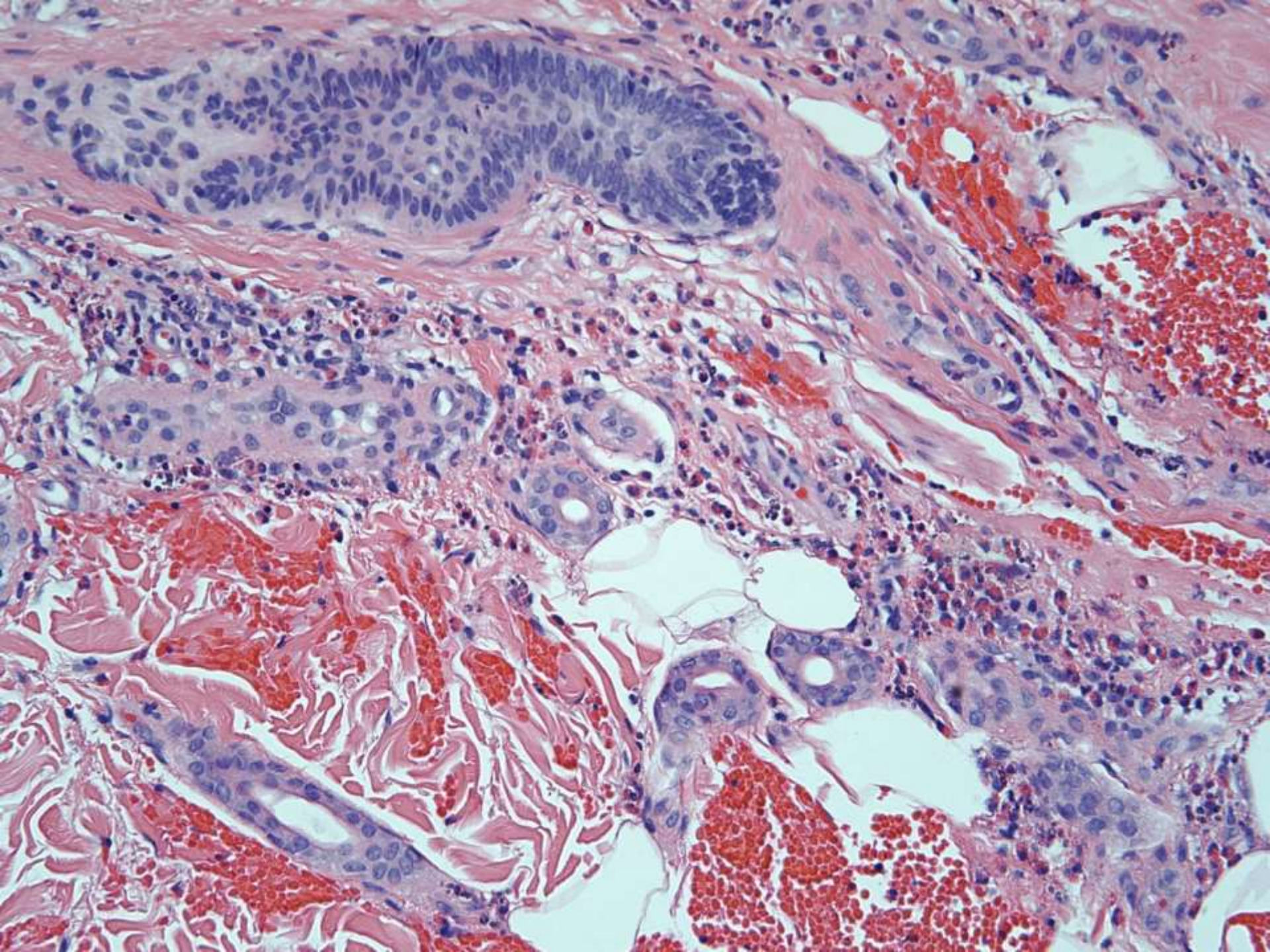










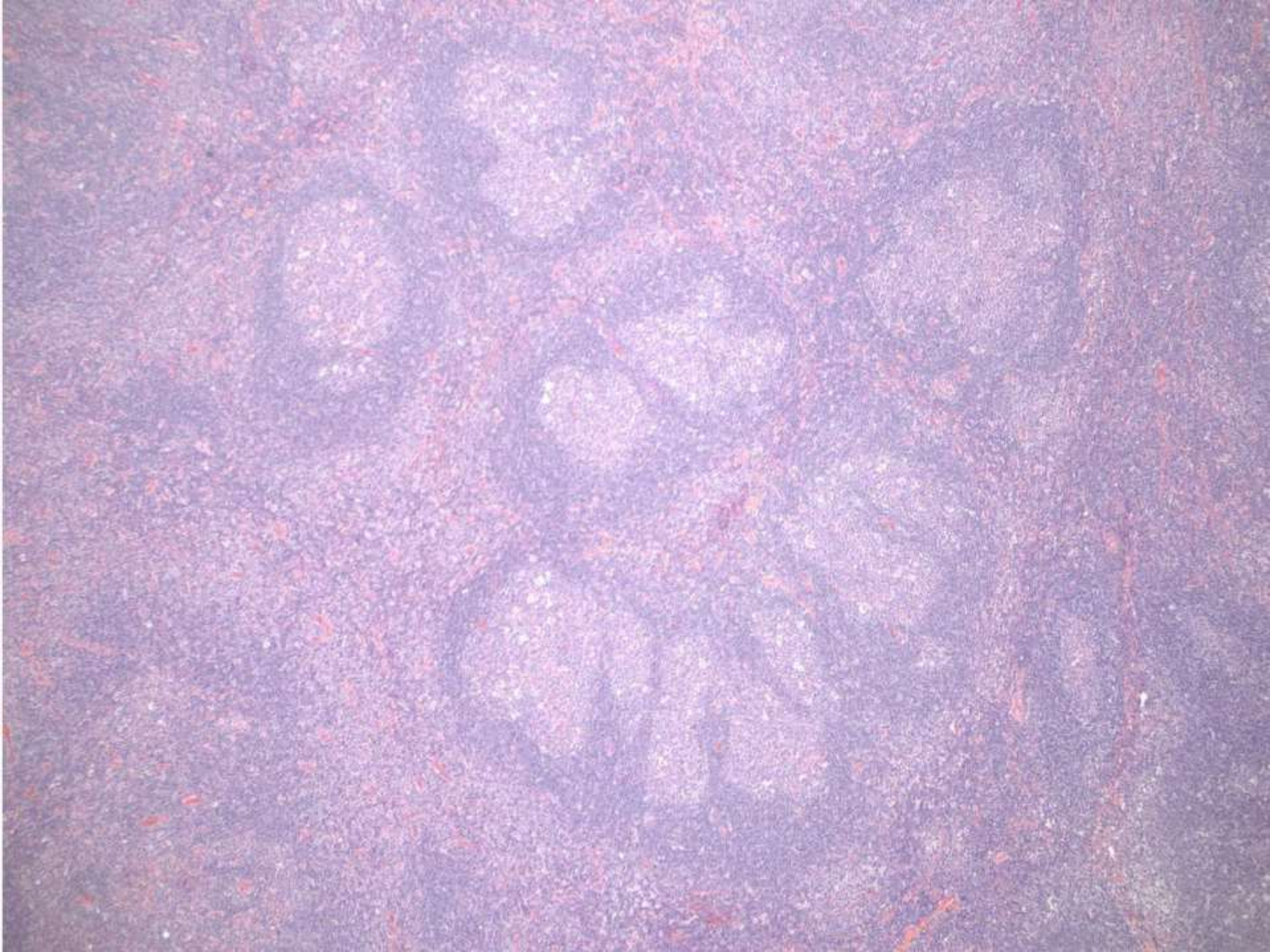




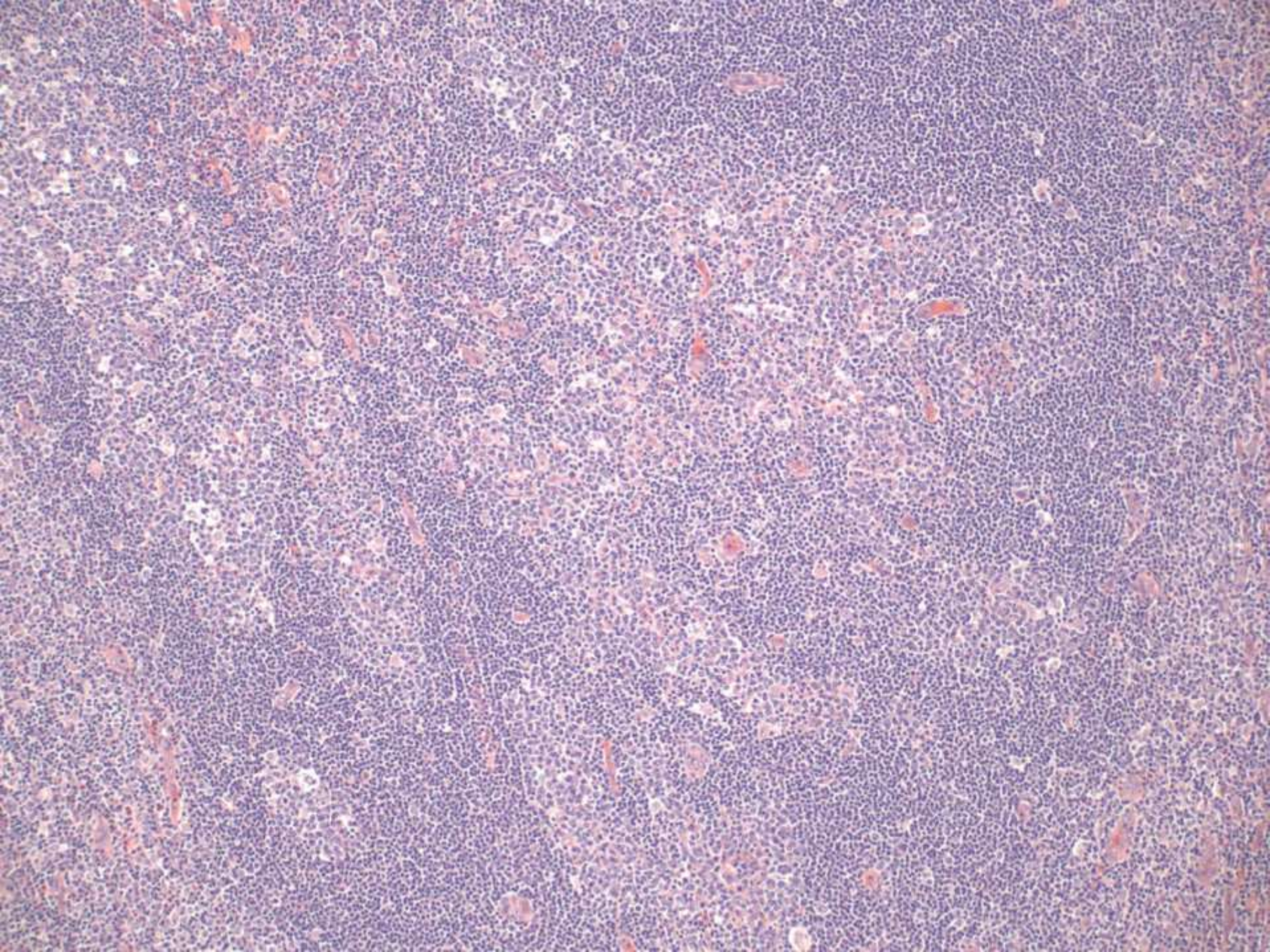
# 5889

- 54-year-old man with CML and chronic lymphadenopathy for more than 1 year. Axillary lymph node submitted.
- **Michael Ozawa/Dita Gratzinger; Stanford**

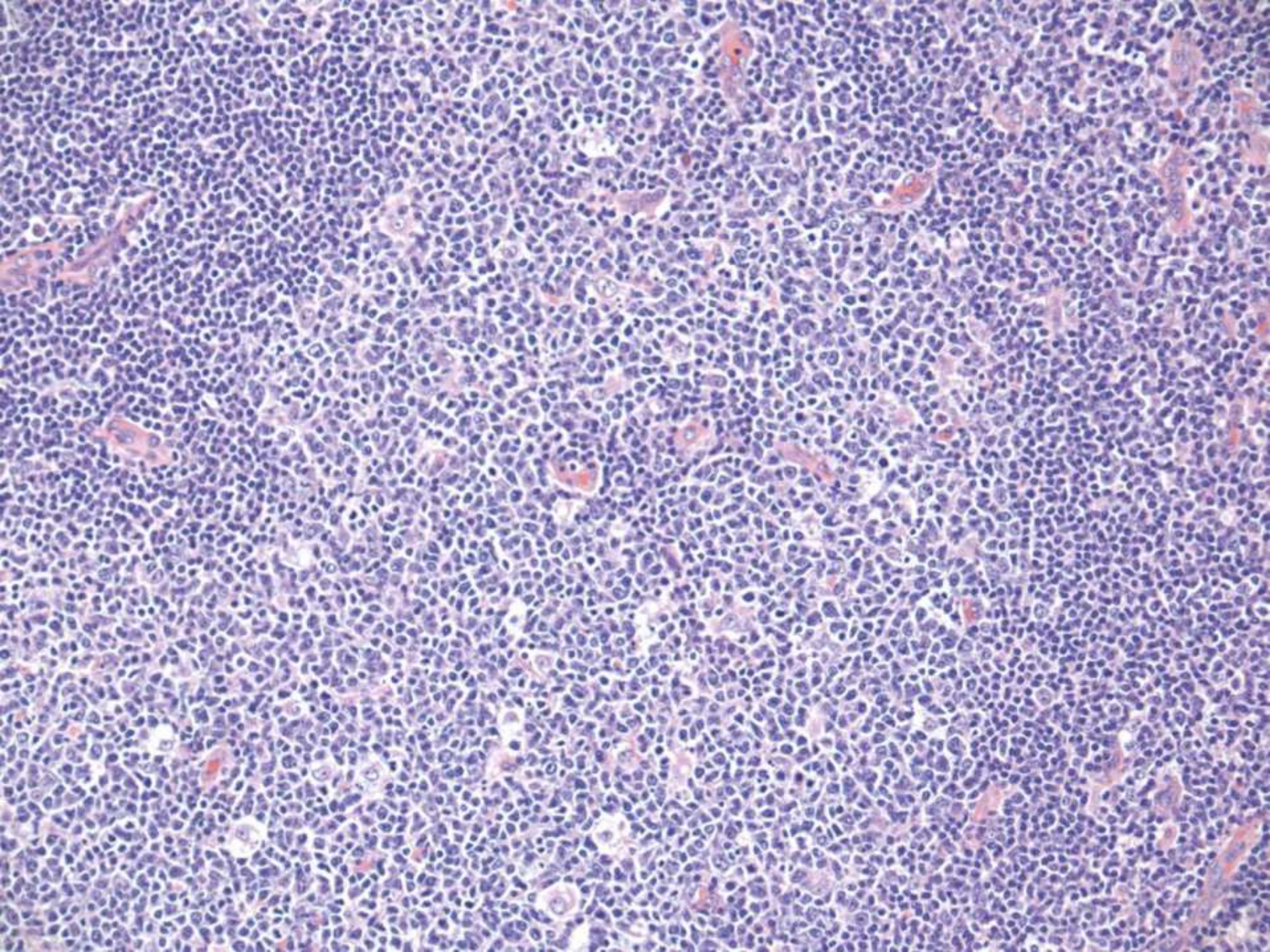




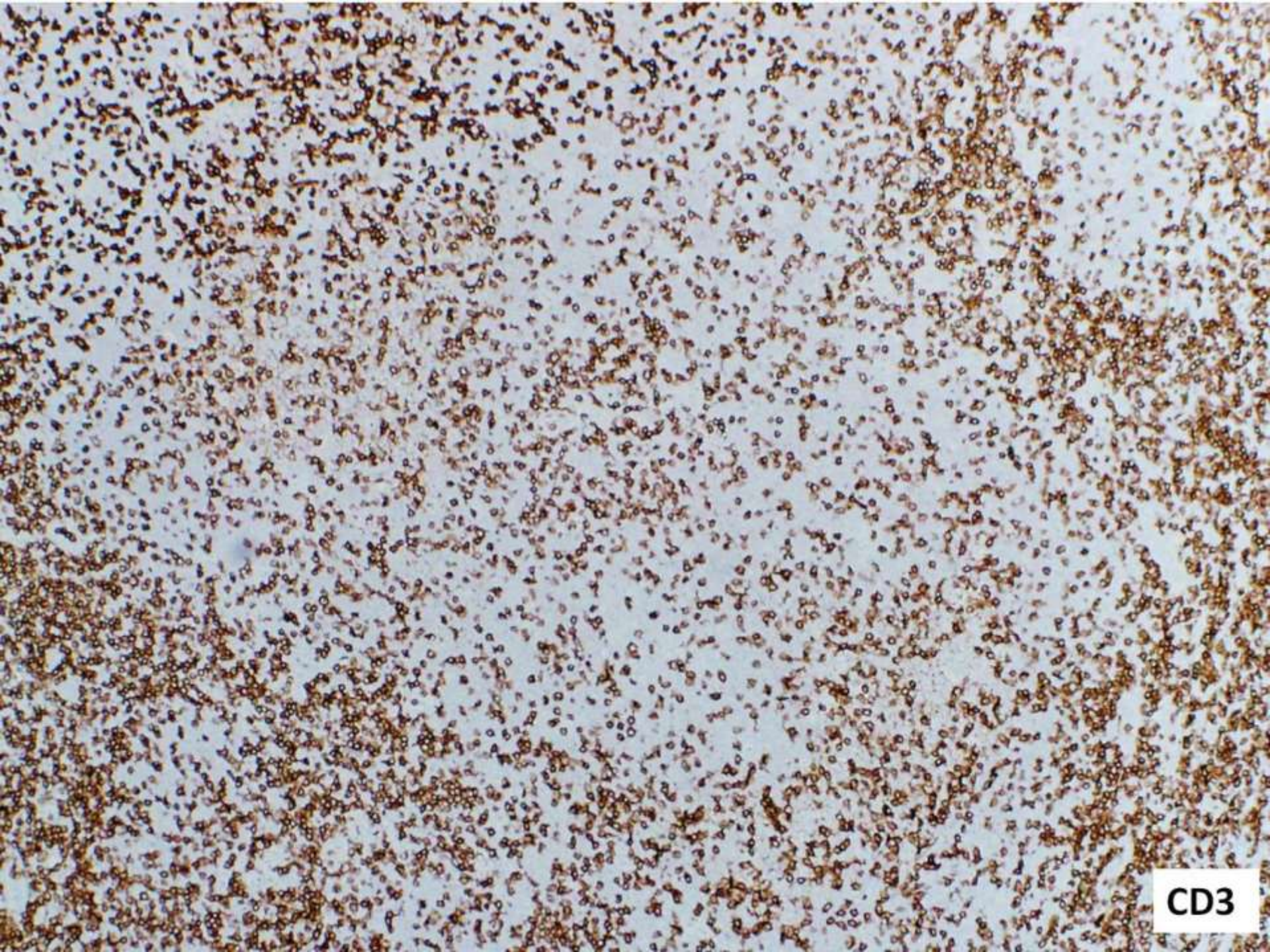






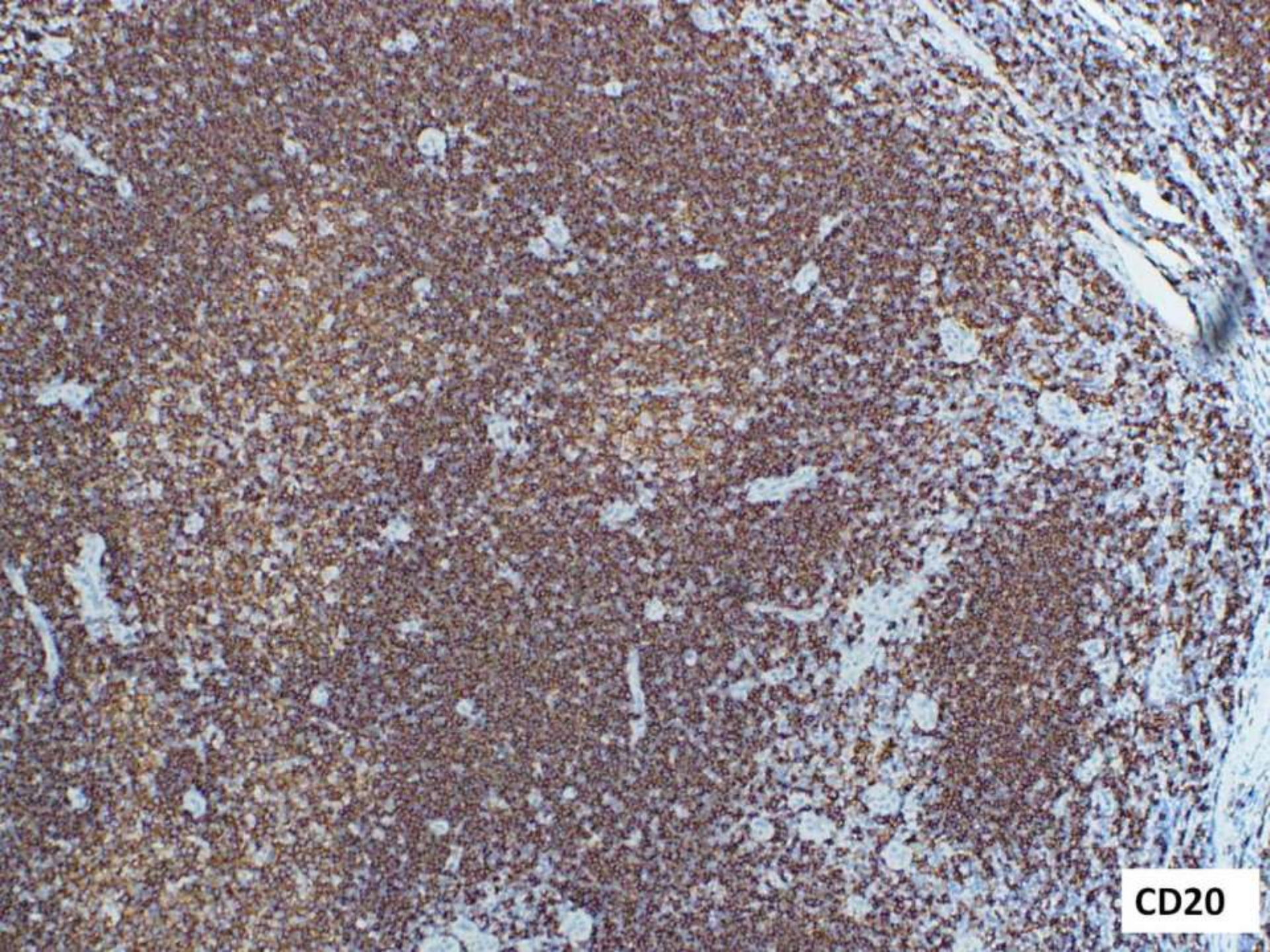






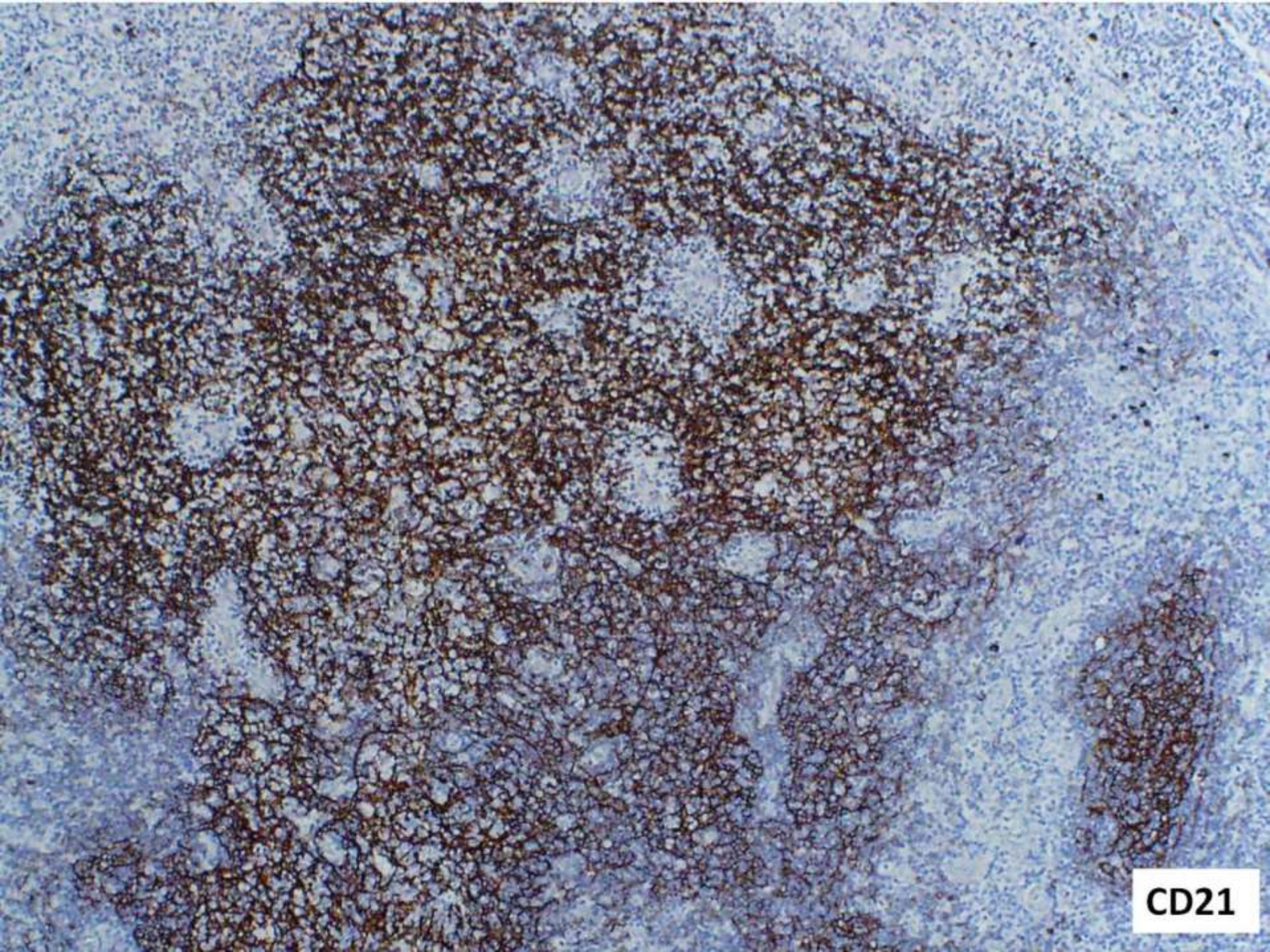
CD3





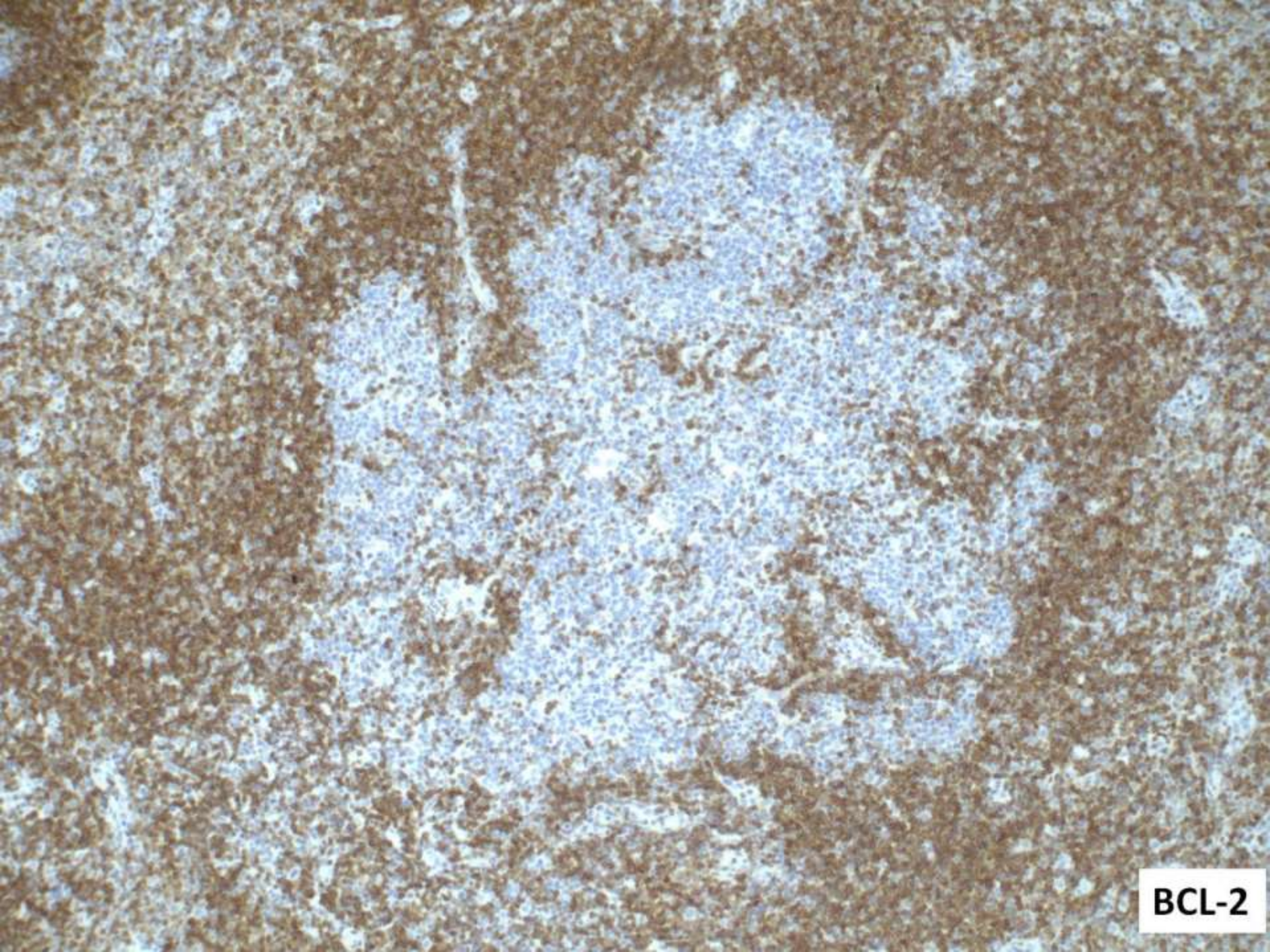
CD20





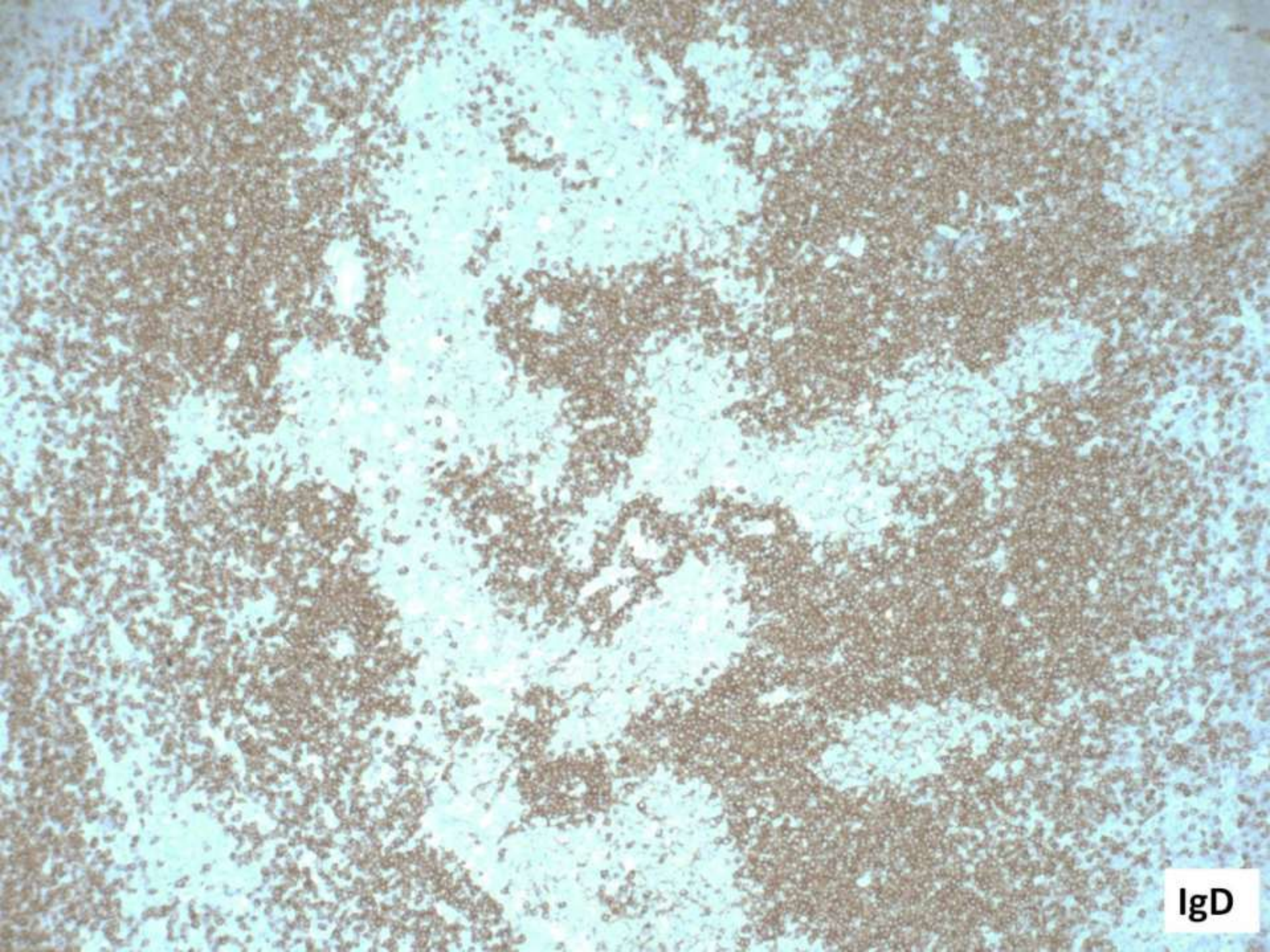
CD21





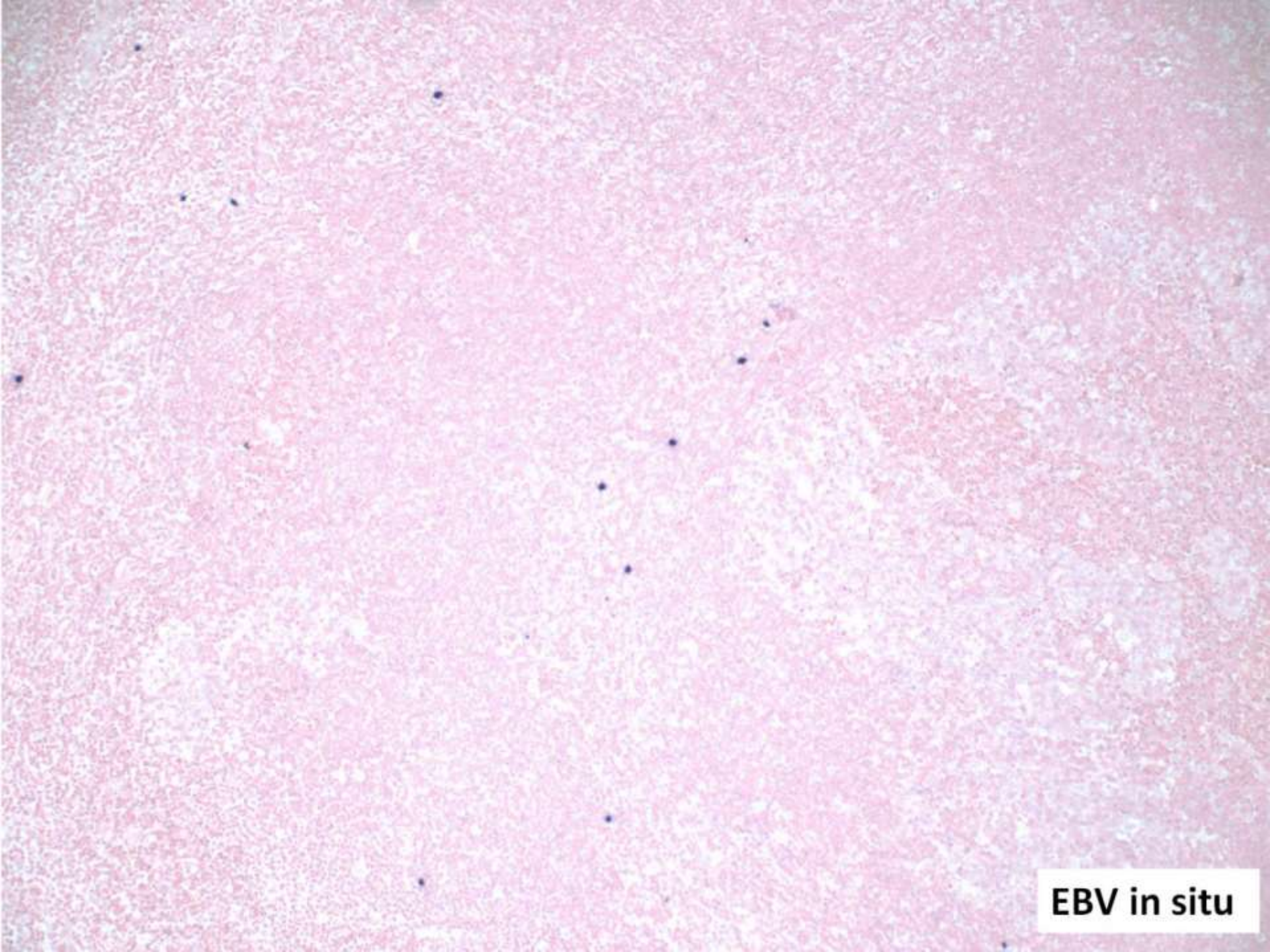
**BCL-2**





IgD





**EBV in situ**

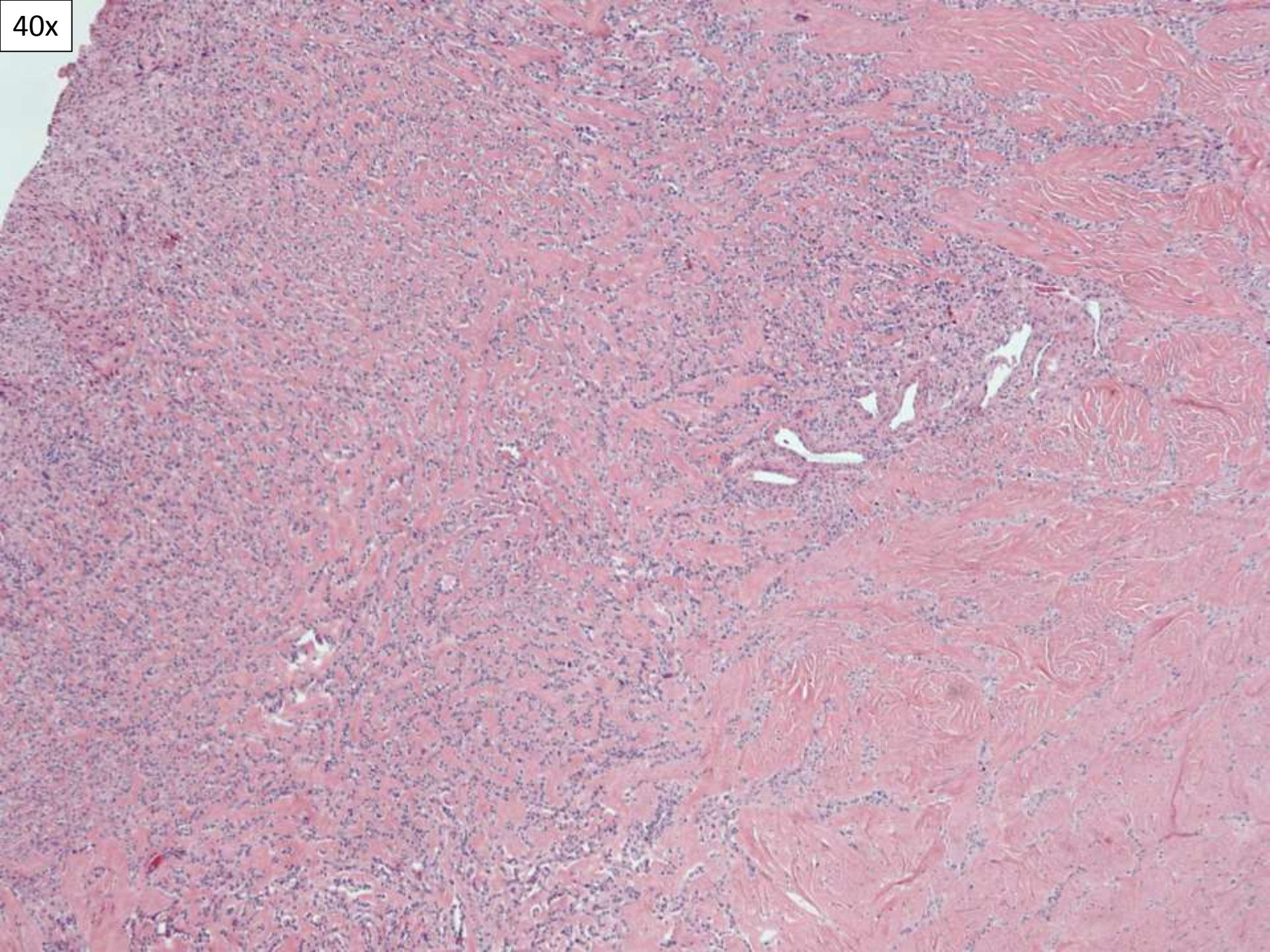


# 5890

- 65-year-old woman with 2.8cm enhancing exophytic lesion from left midpole kidney.
- **Sebastian Fernandez-Pol/Florette Hazard;  
Stanford**

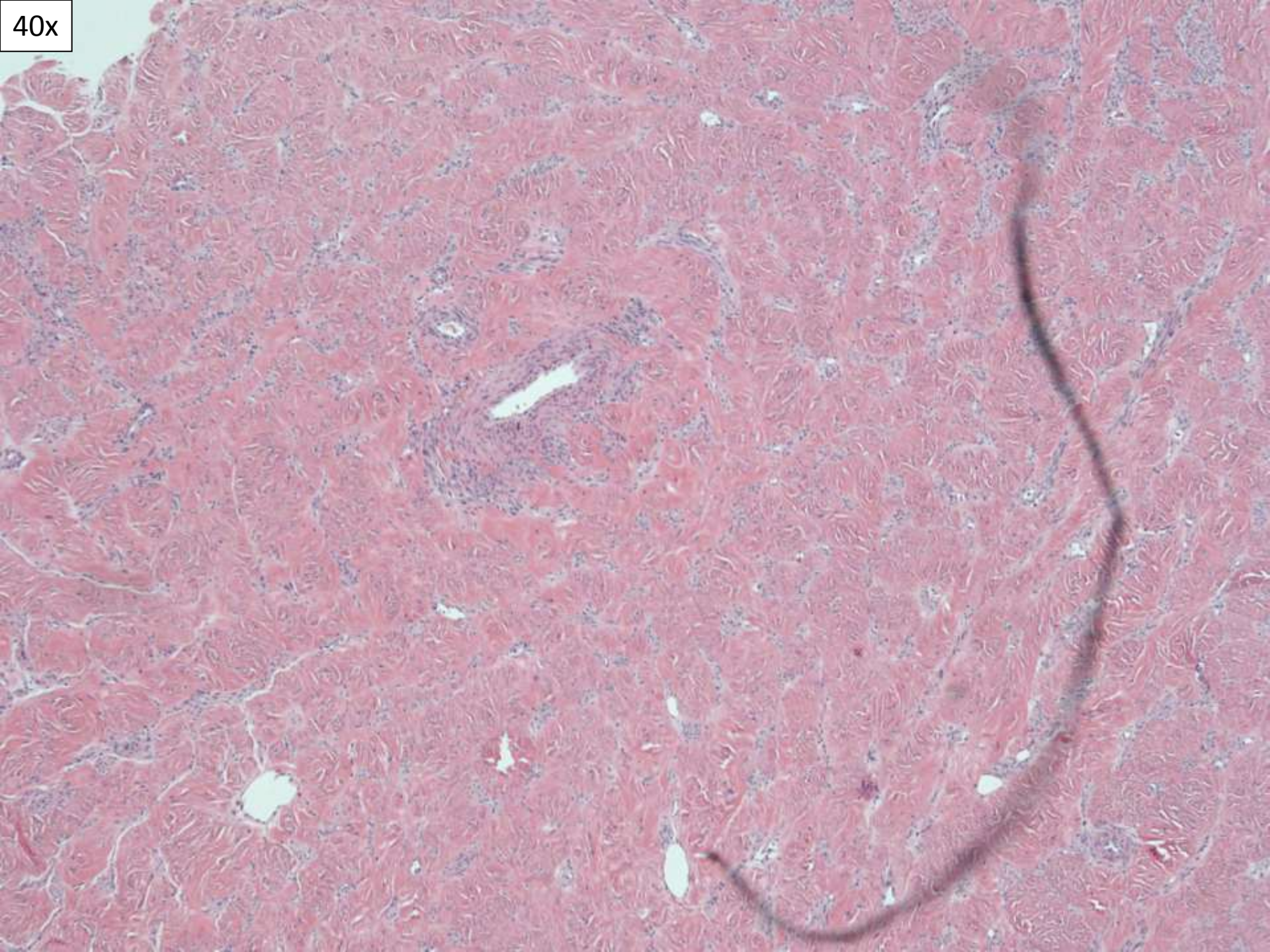


40x



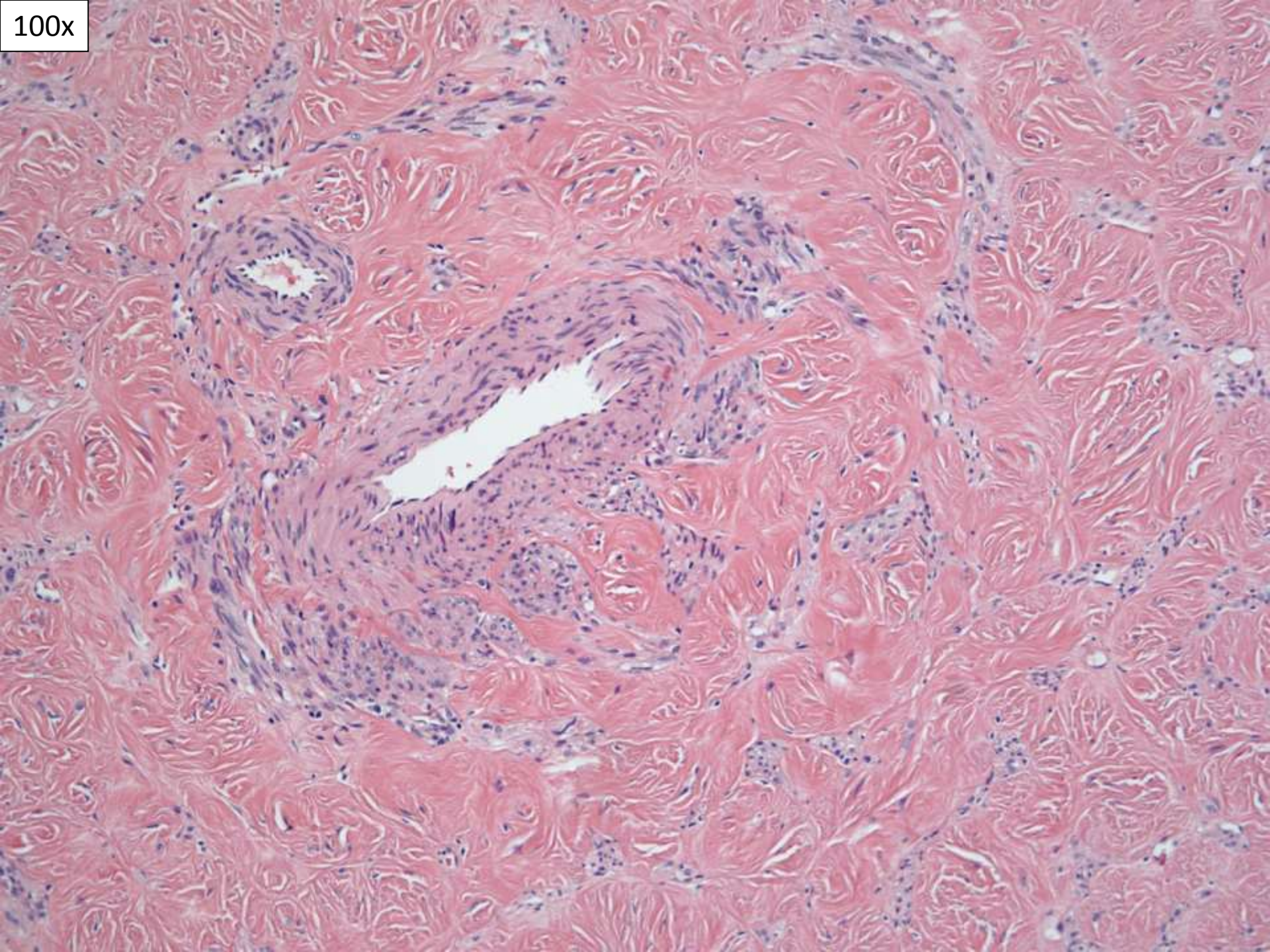


40x



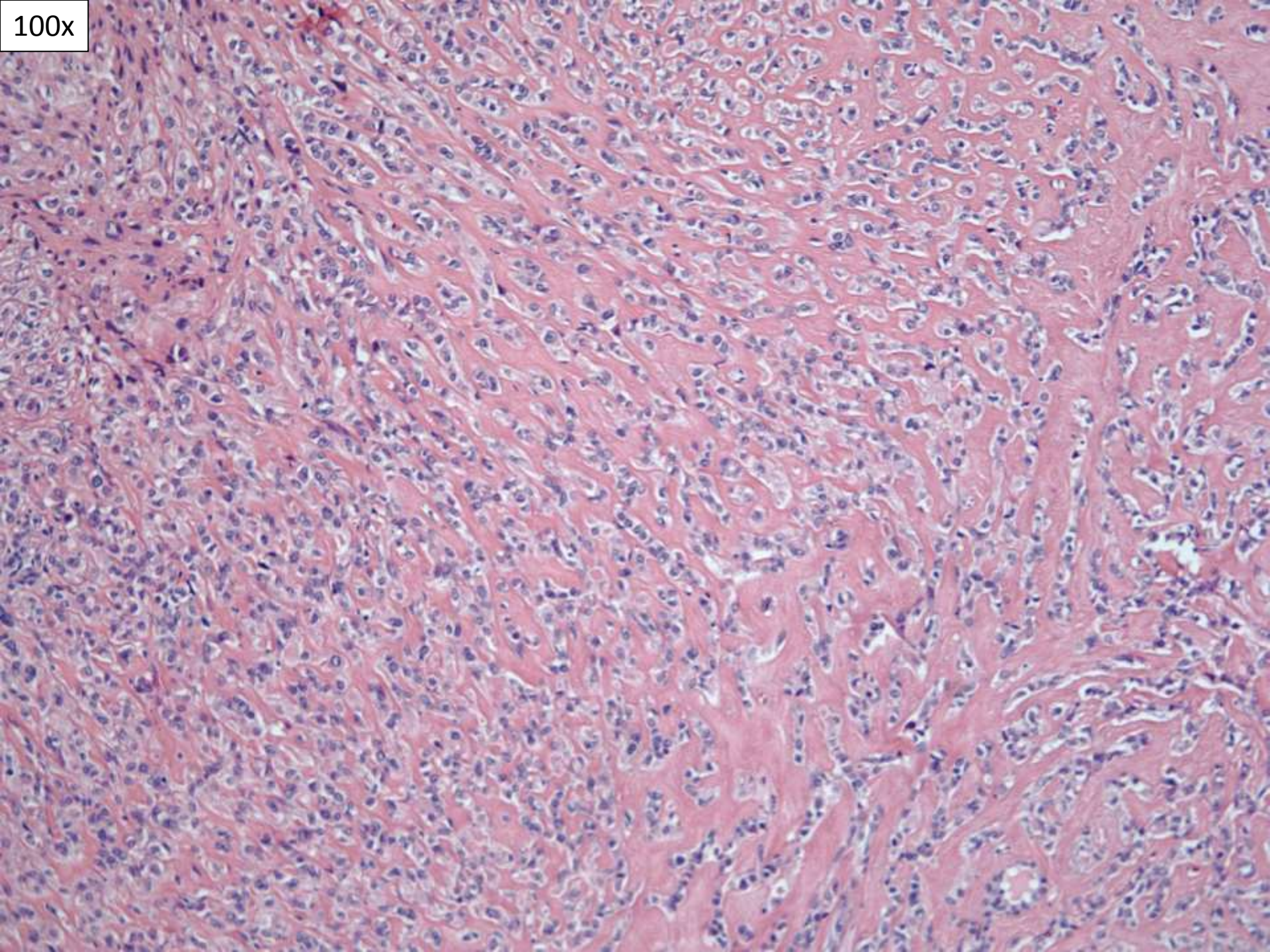


100x



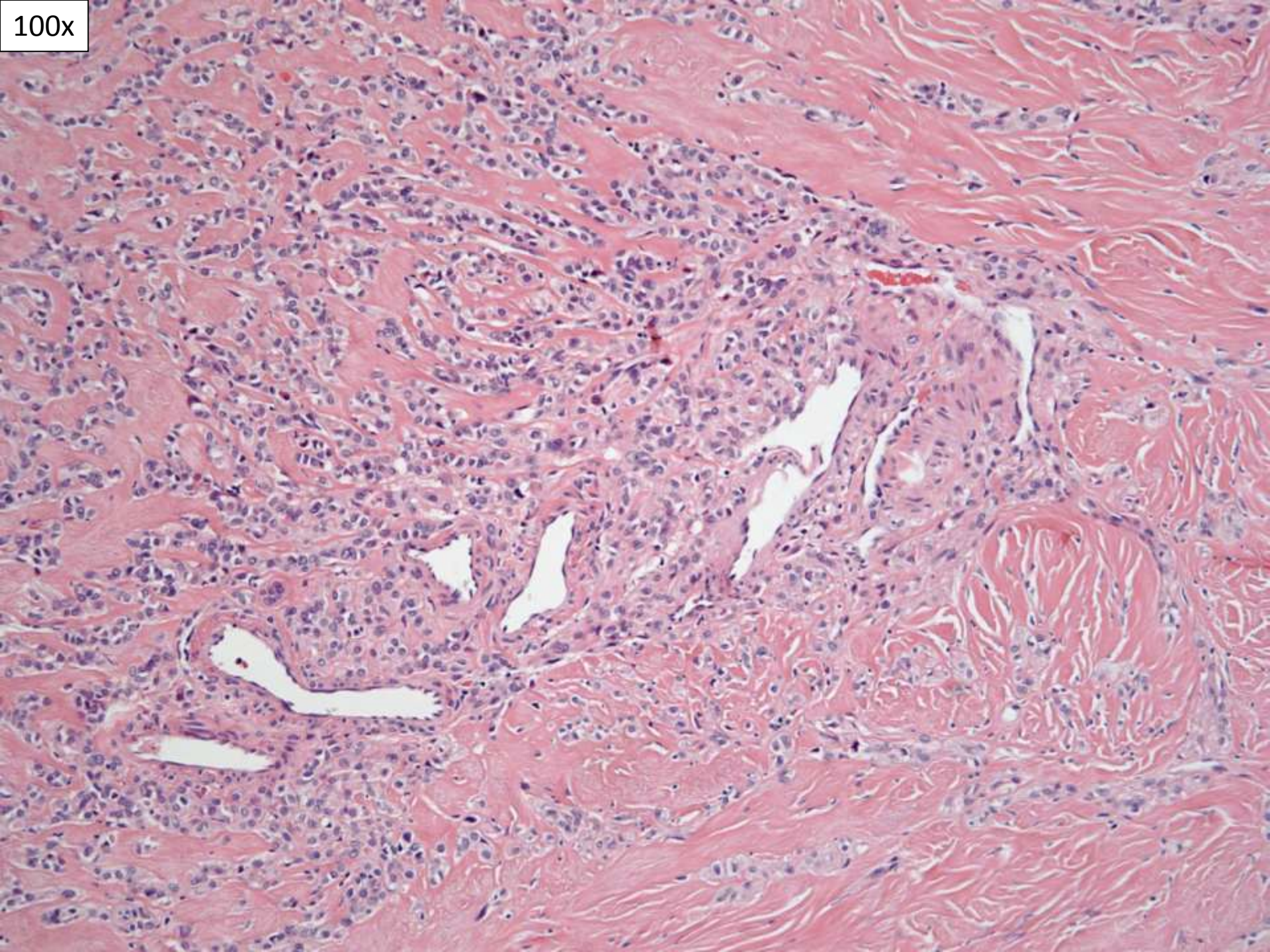


100x

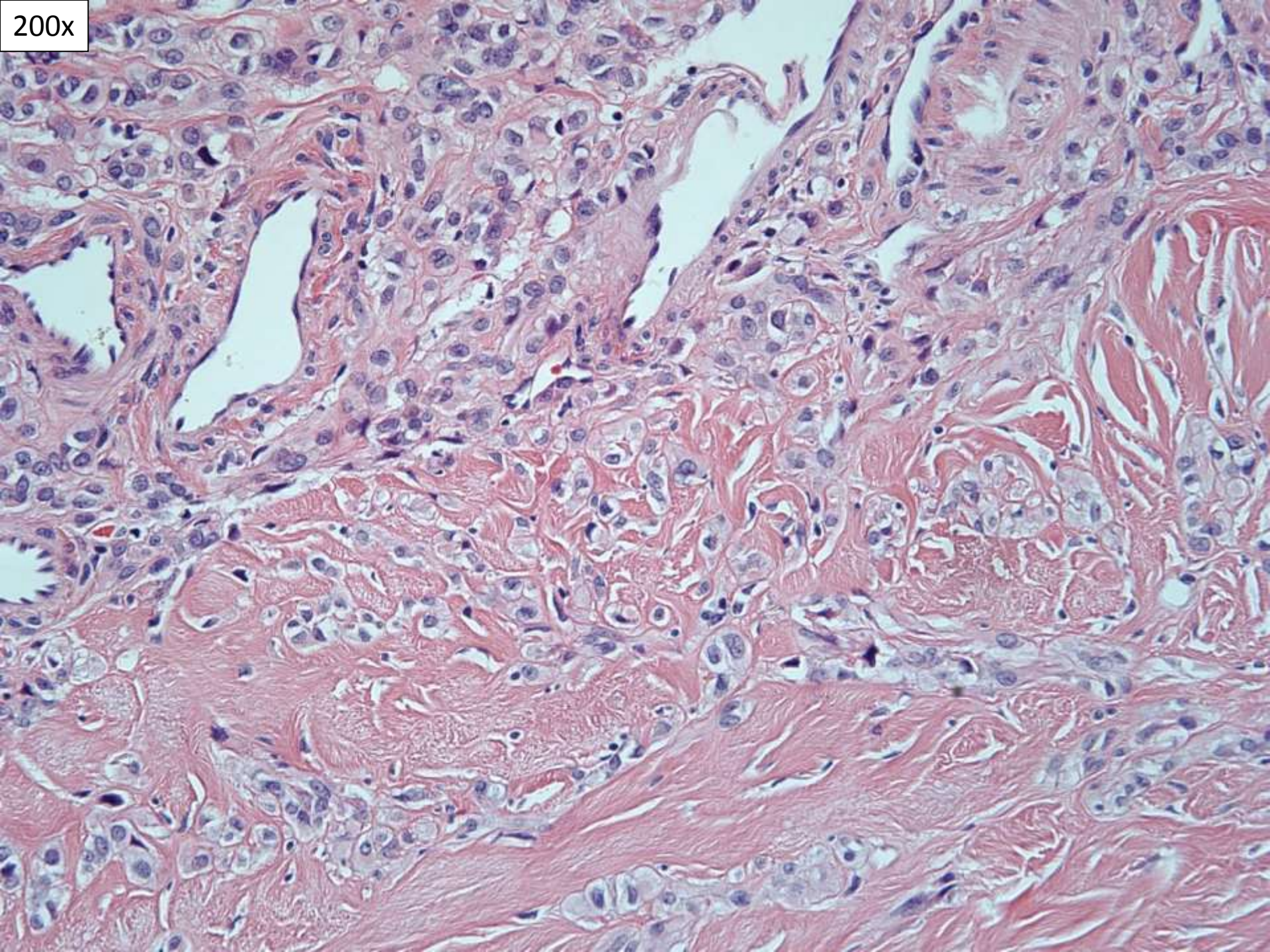




100x



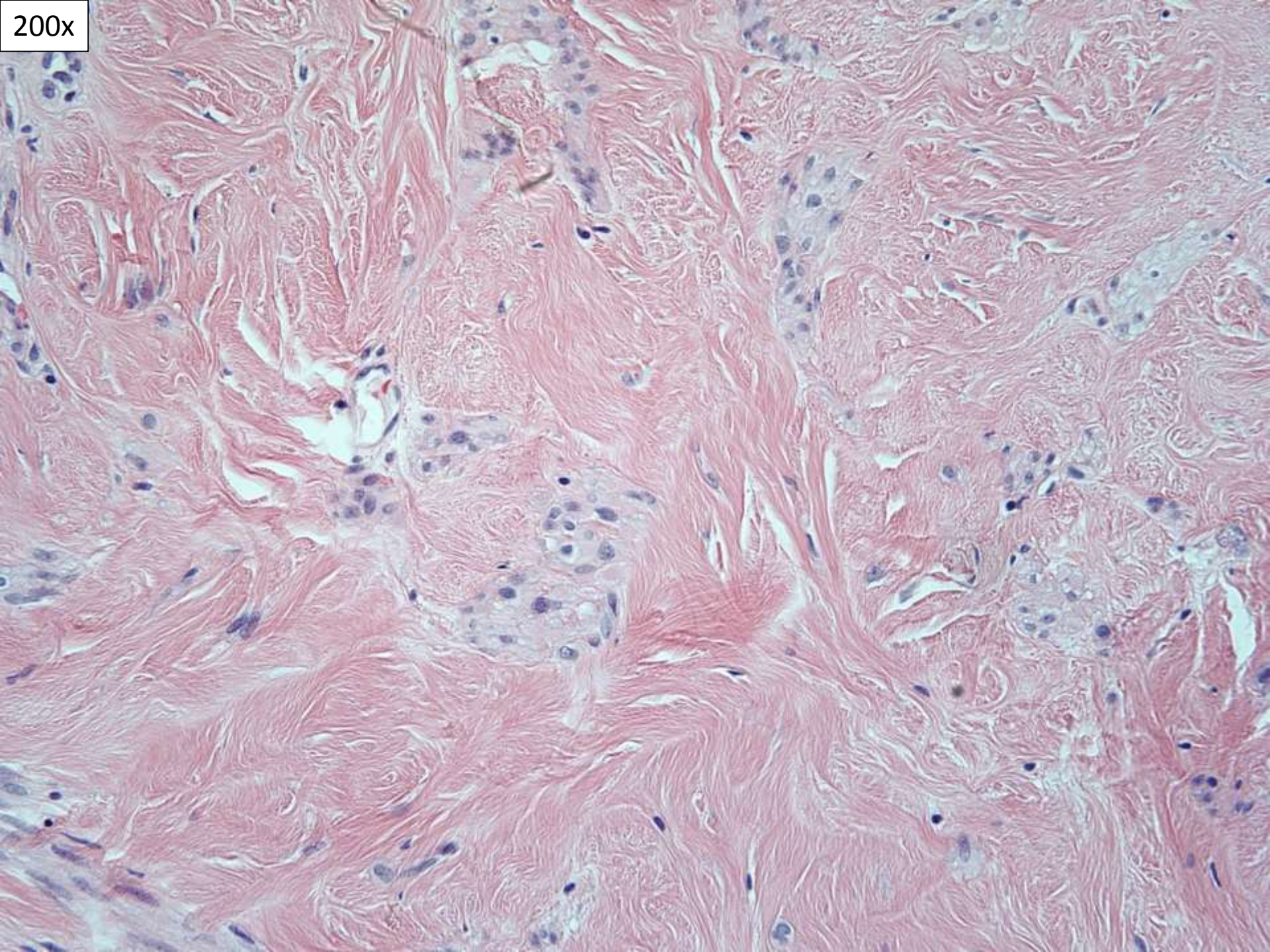




200x



200x





400x

