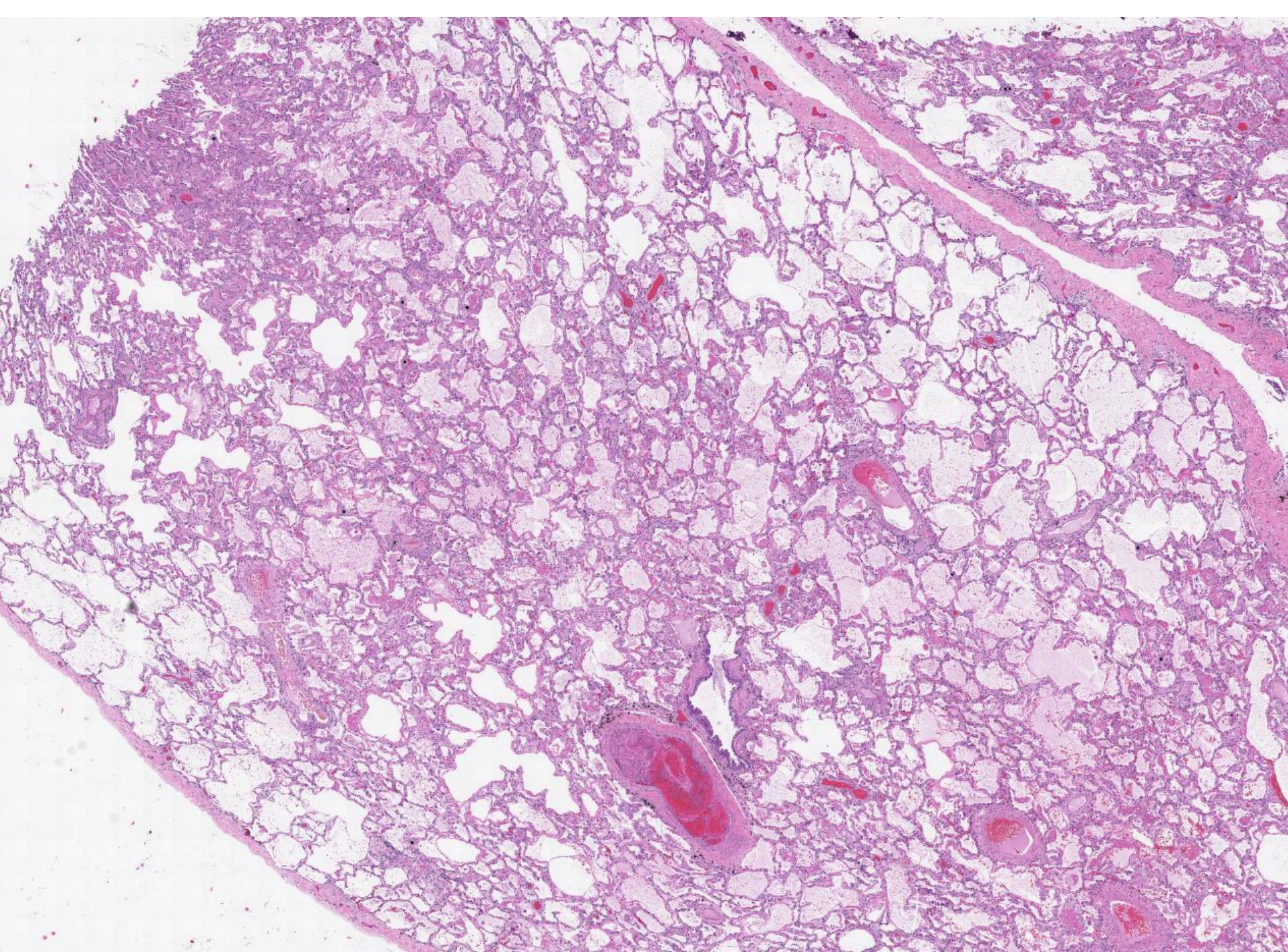


# SB 5871

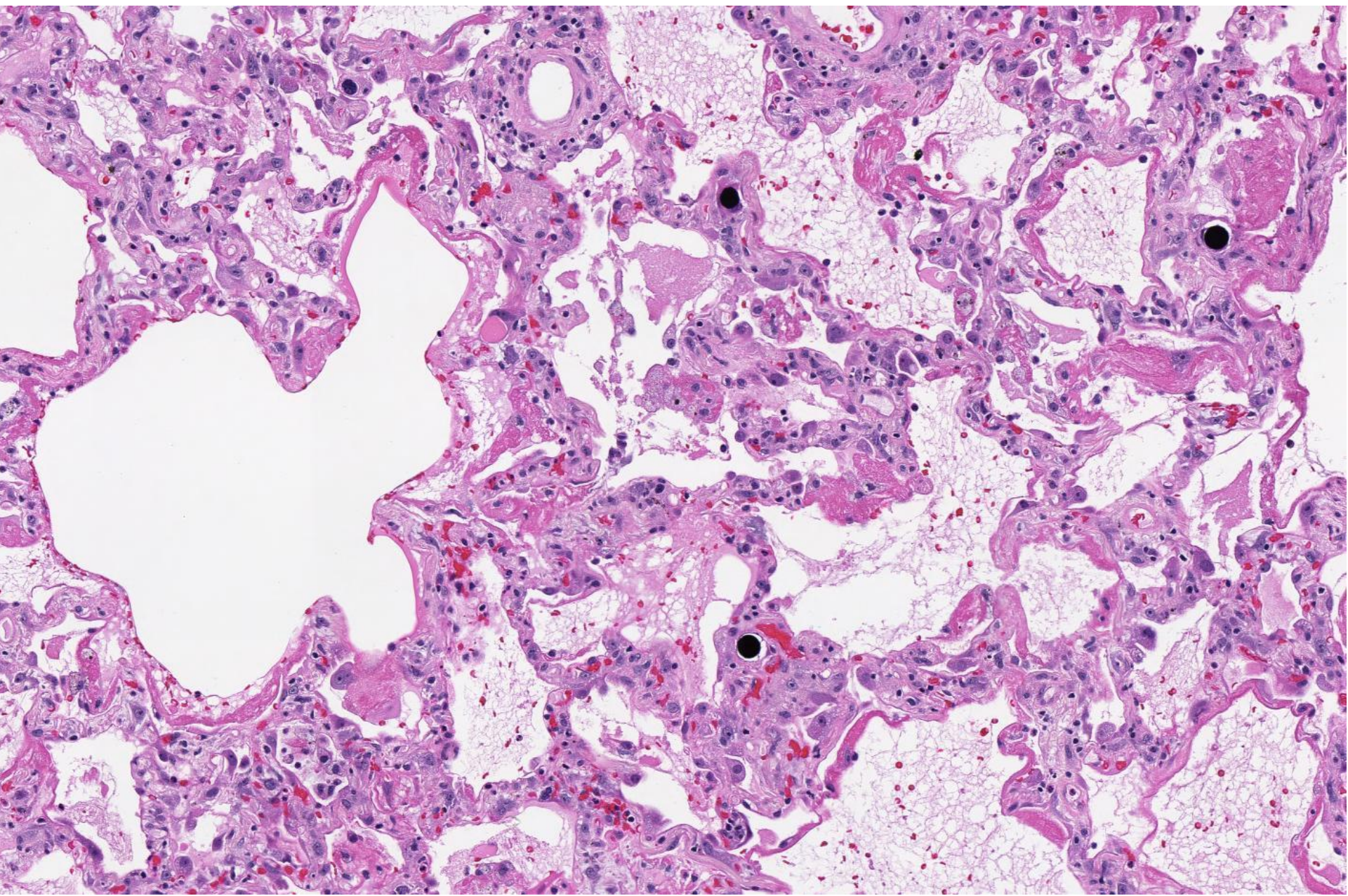
46-year-old man with acute dyspnea and cough. He had a diagnosis of GIST with hepatic metastasis, known 7 months prior to presentation. He had a history of being treated with Gleevec. Lung biopsy performed.

Tom Colby; Mayo Clinic Scottsdale

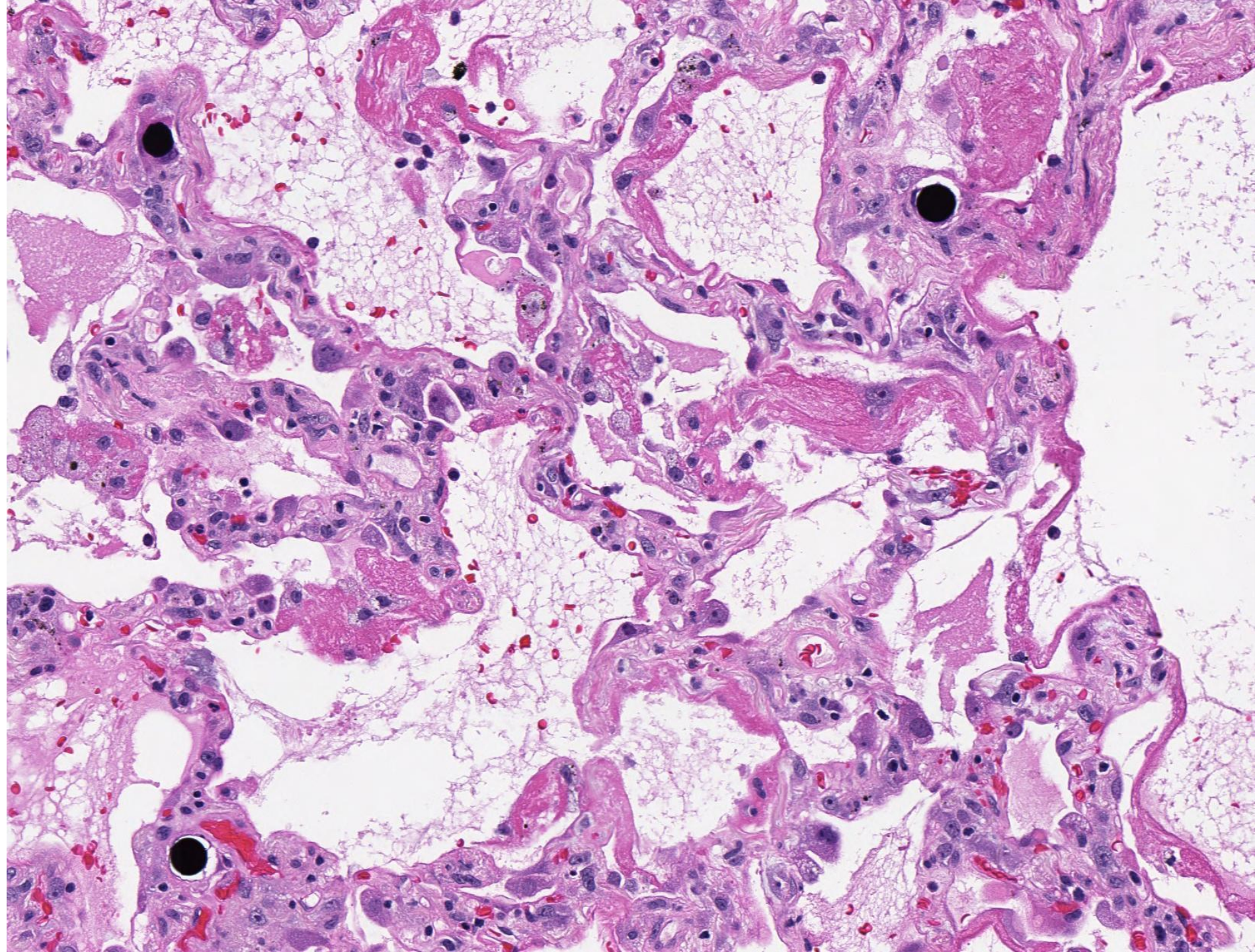




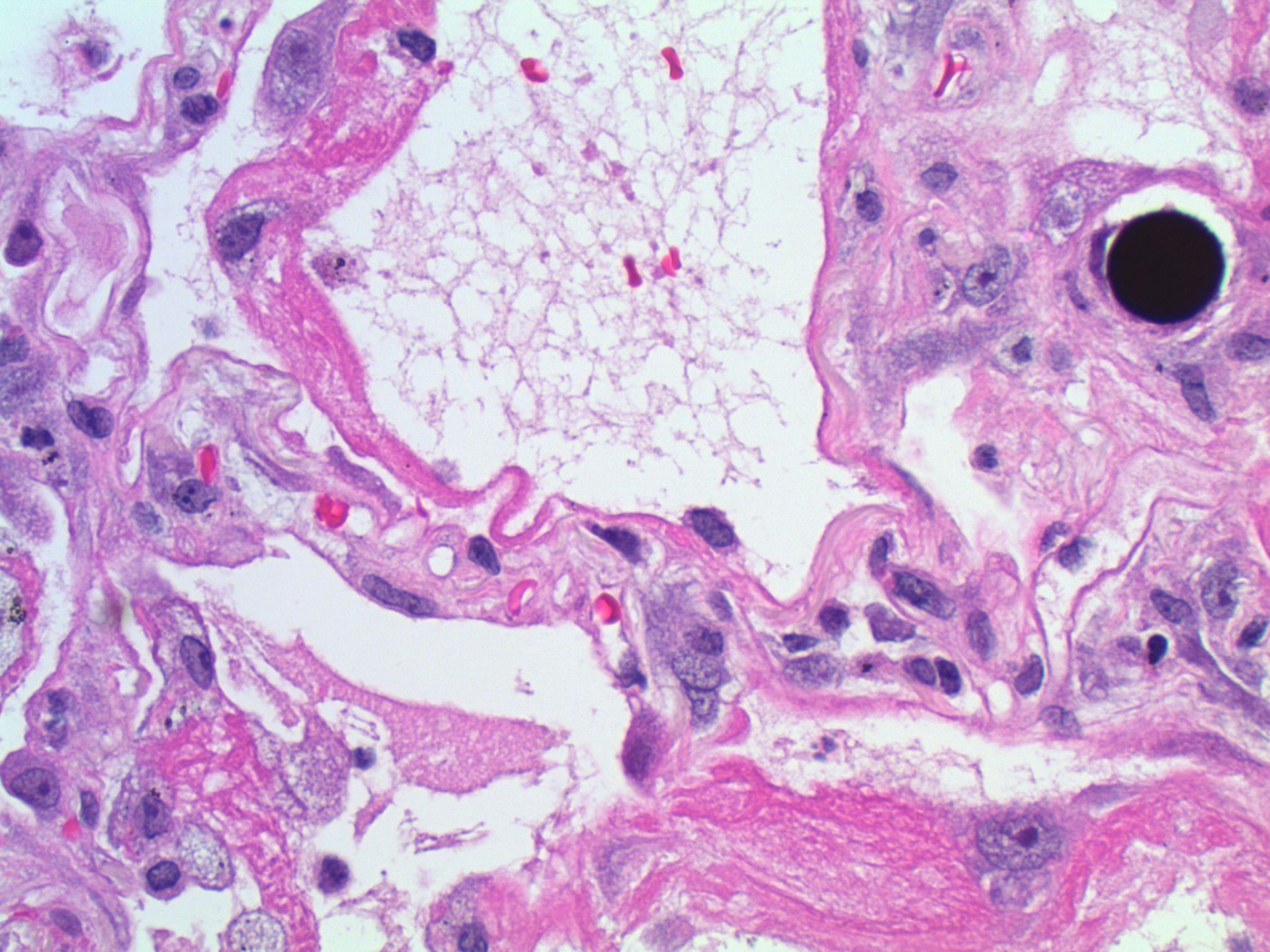














# SB 5872

67-year-old man presents with general malaise and DOE. Marked peripheral lymphocytosis noted (WBC 30K; 90% lymphocytes), small IgM gammopathy, enlarged spleen (13.5cm), fatty infiltration of liver on CT, and enlarged portohepatic / portocaval / celiac axis lymph nodes (1.6cm) without other lymphadenopathy. Peripheral blood smear and bone marrow biopsy performed.

Charles Lombard; El Camino Hospital



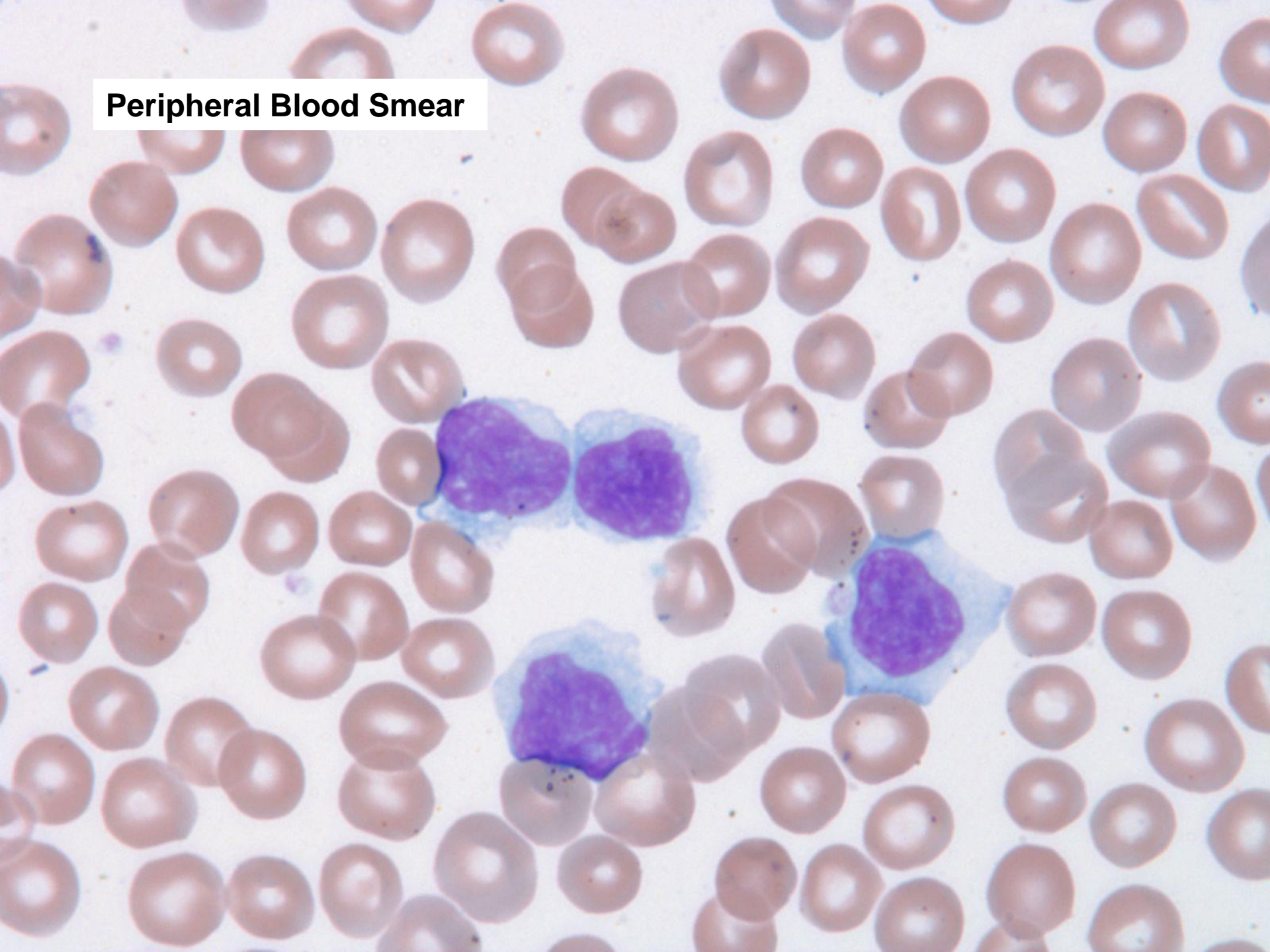
# 67 yo M

Presents with general malaise and DOE

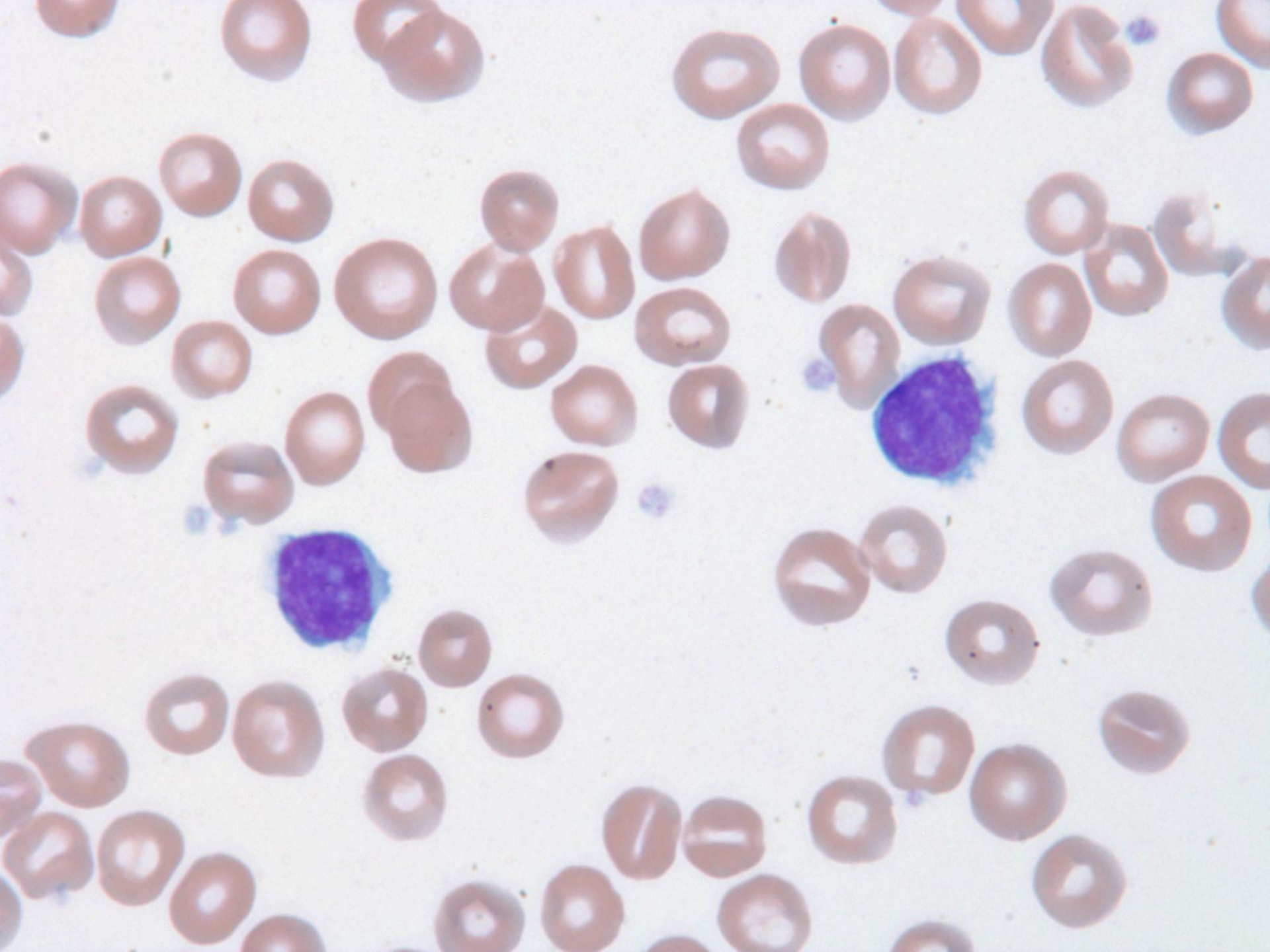
- Marked peripheral lymphocytosis
  - WBC 30 K; 90% lymphs
- Small Ig M gammopathy
- Enlarged spleen 13.5 cm
- Fatty infiltration of liver on CT
- Enlarged (1.6 cm) LN's
  - Portohepatic, portocaval, celiac axis
  - No other lymphadenopathy
- Bone Marrow Biopsy Performed



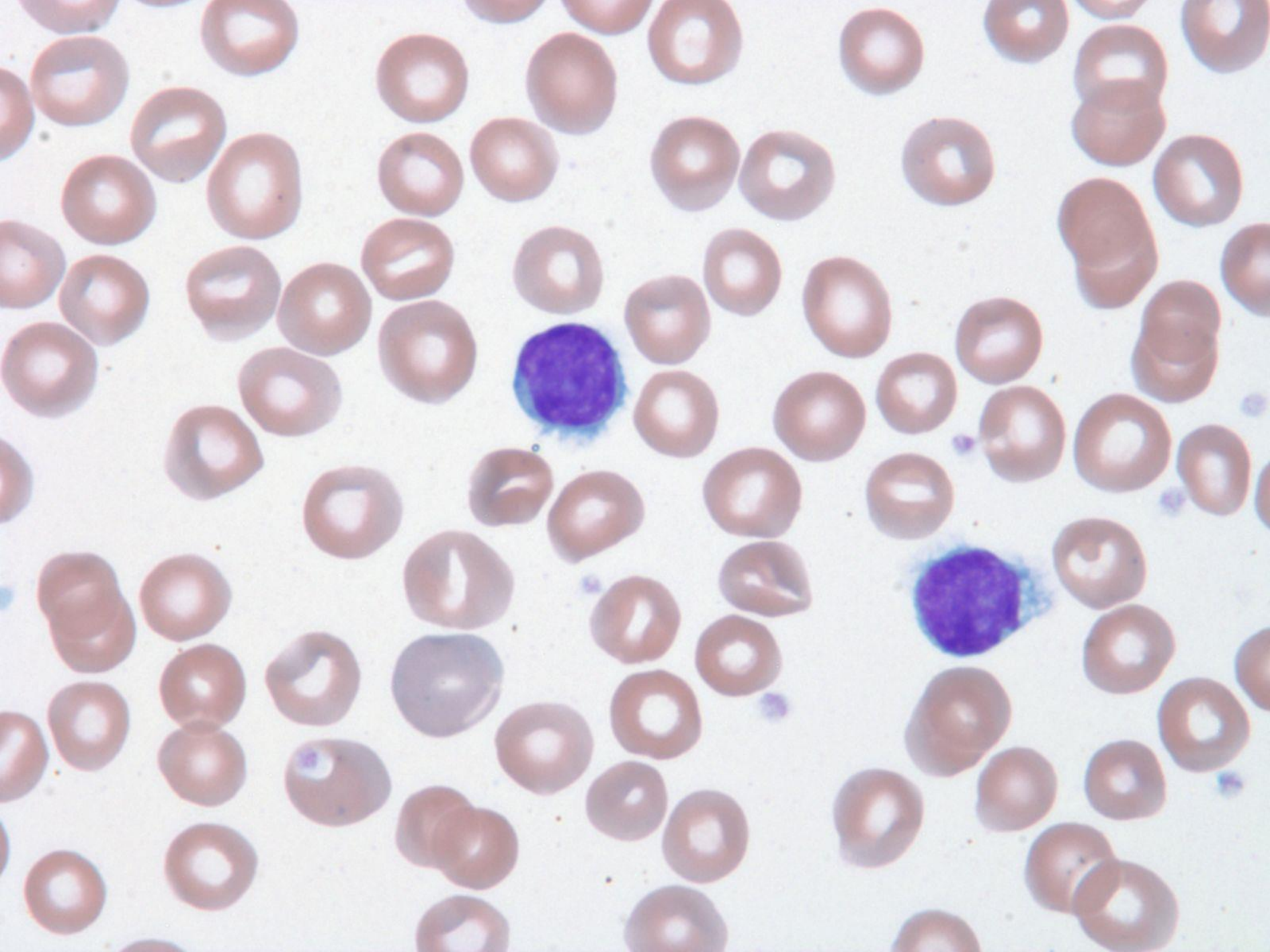
## Peripheral Blood Smear



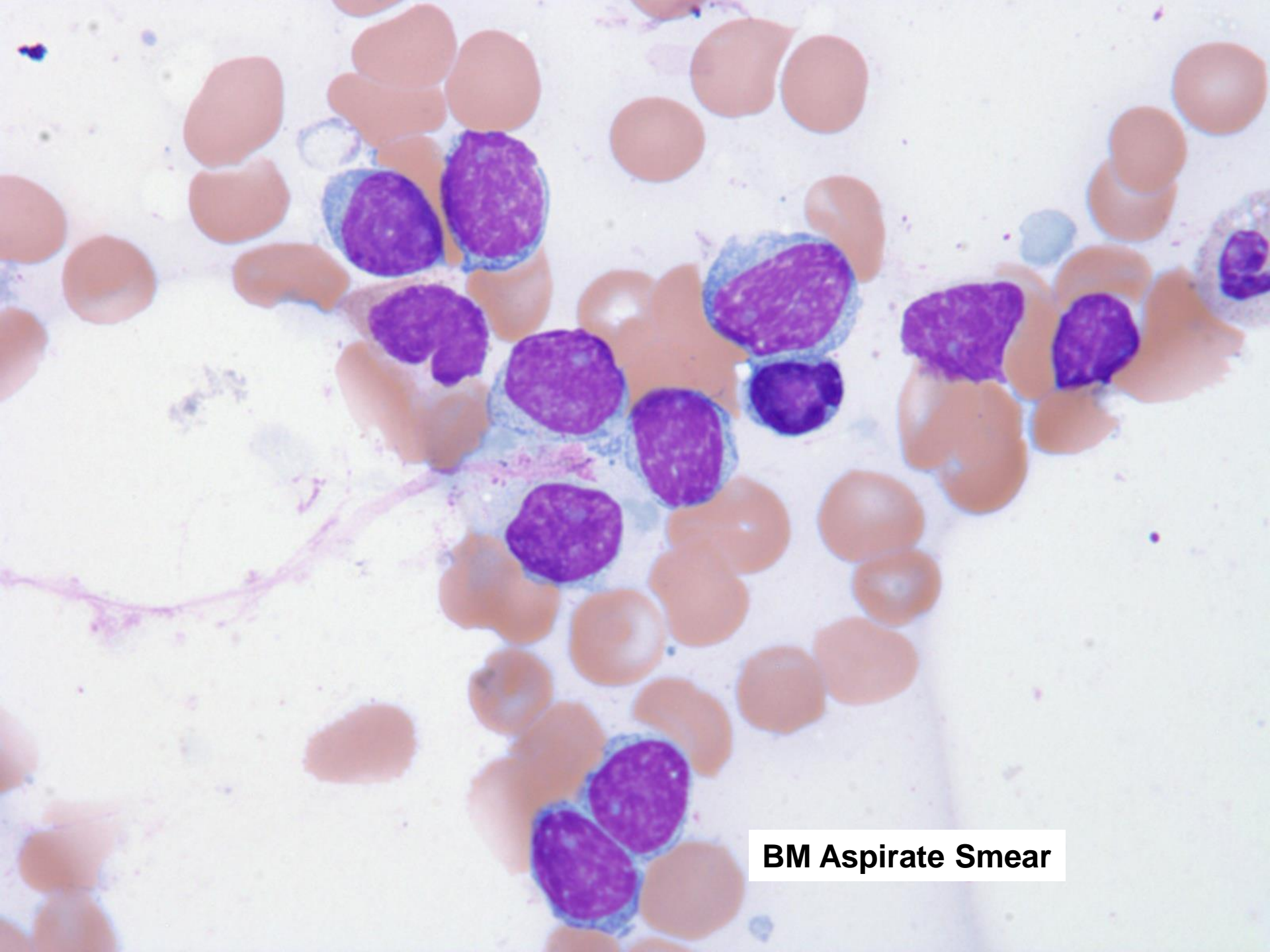






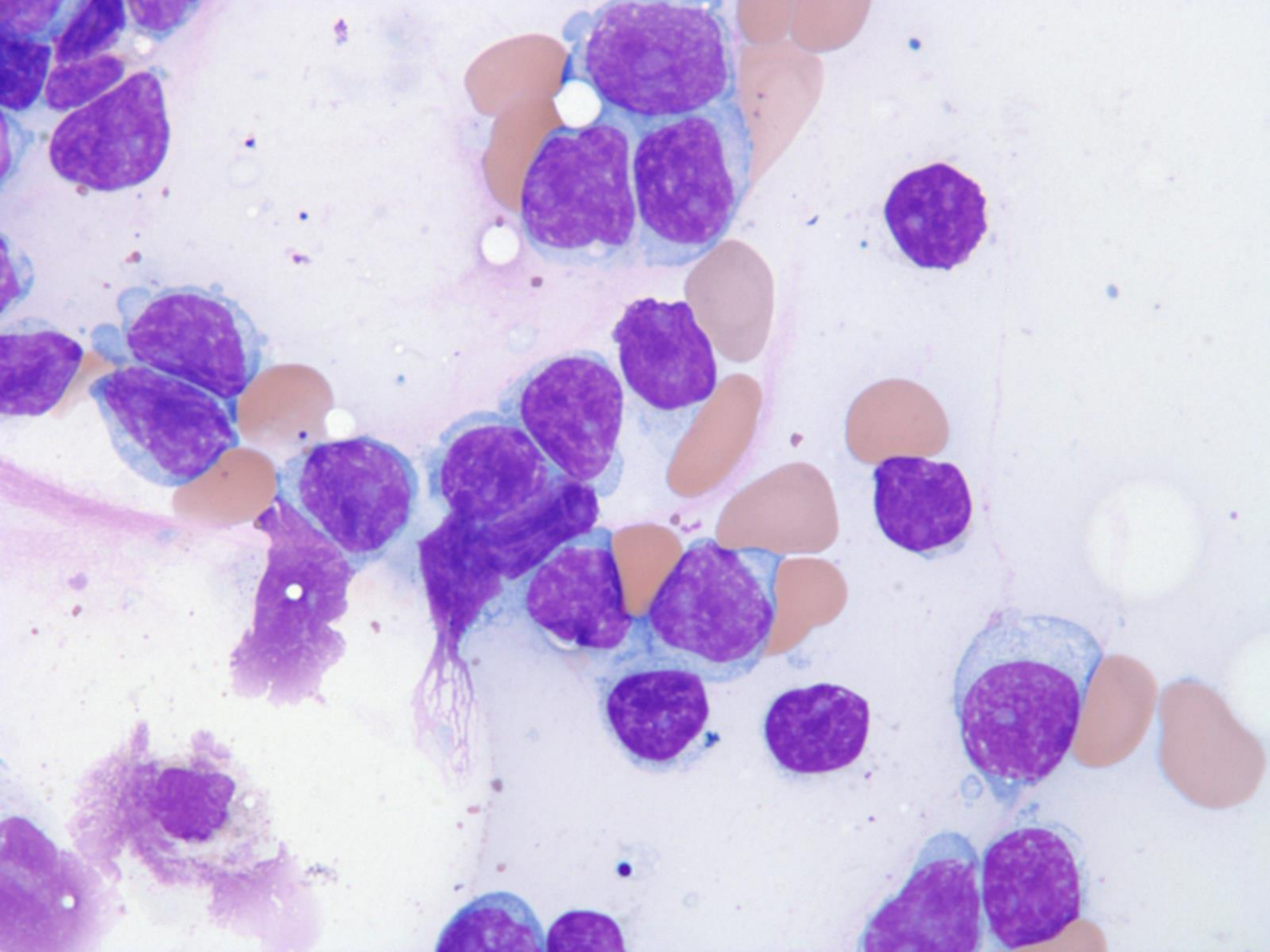




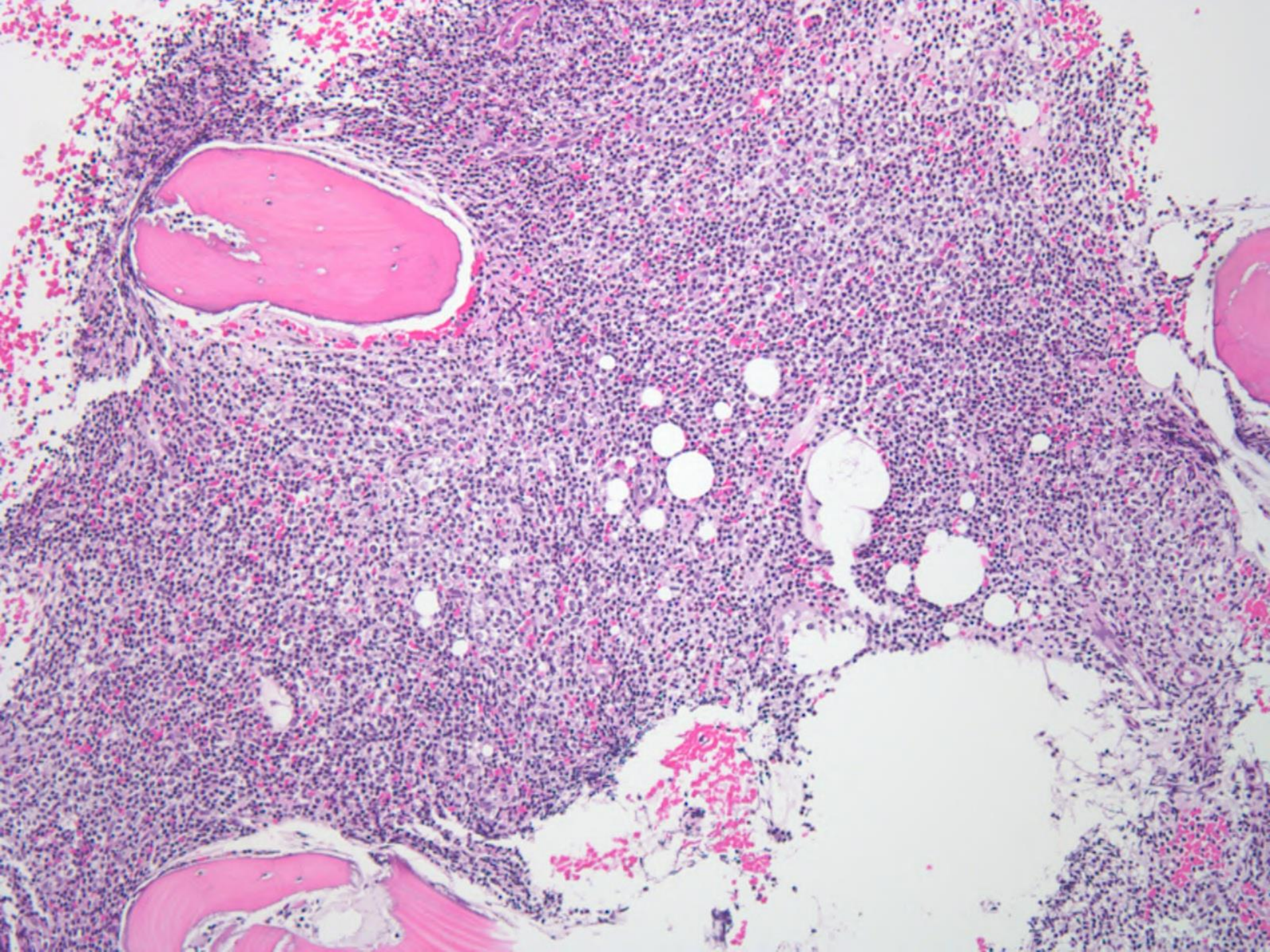


**BM Aspirate Smear**

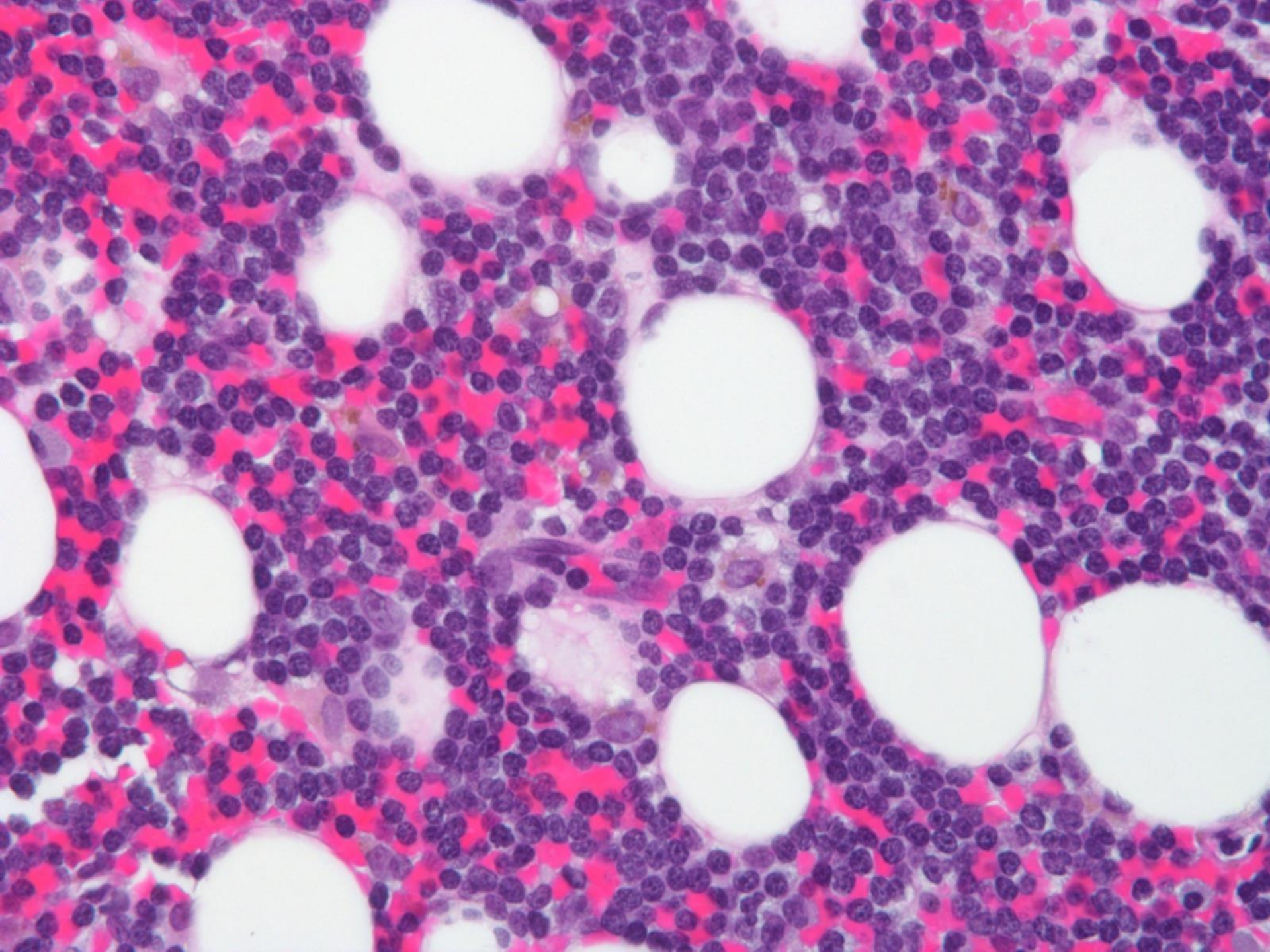




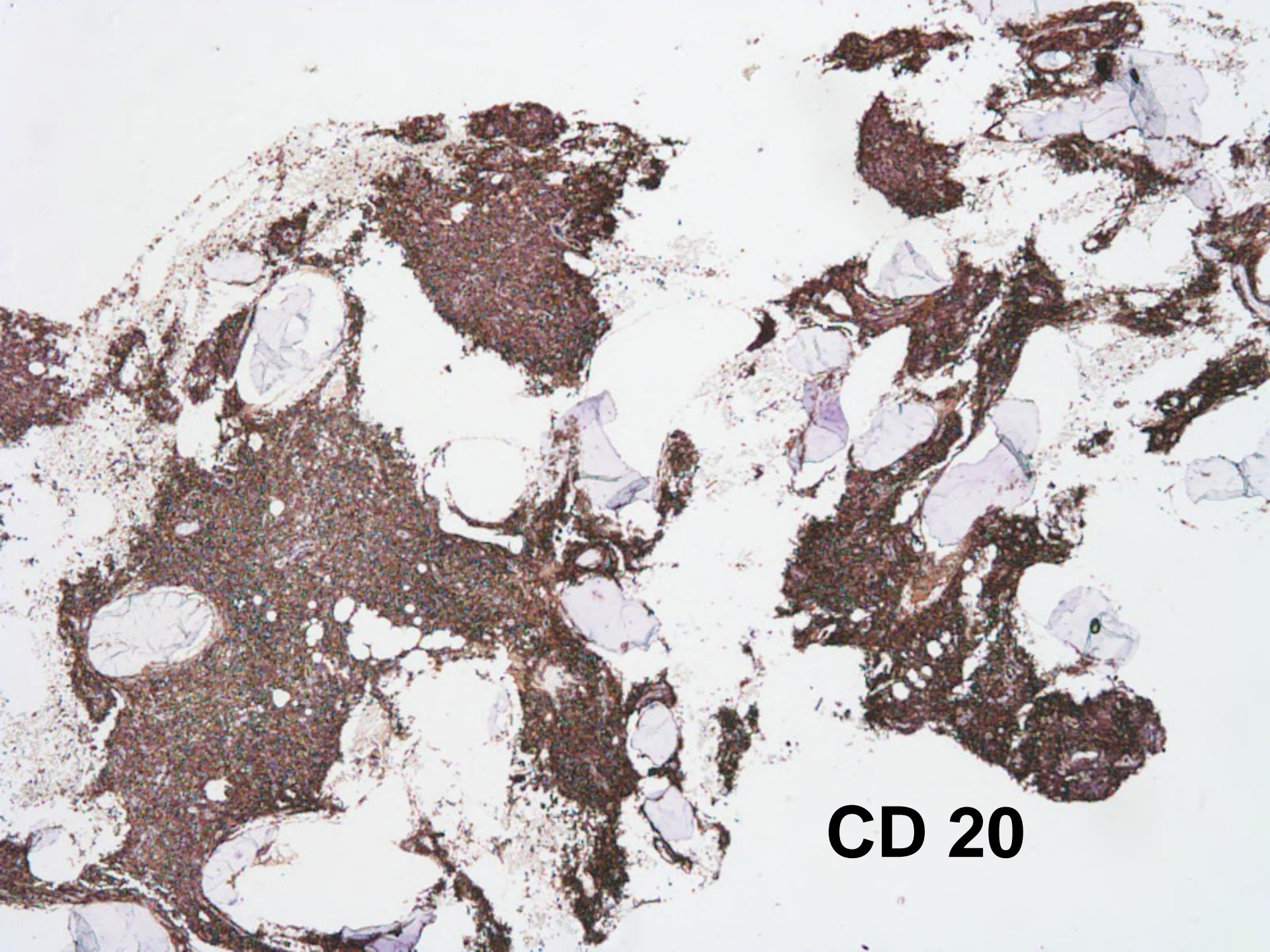






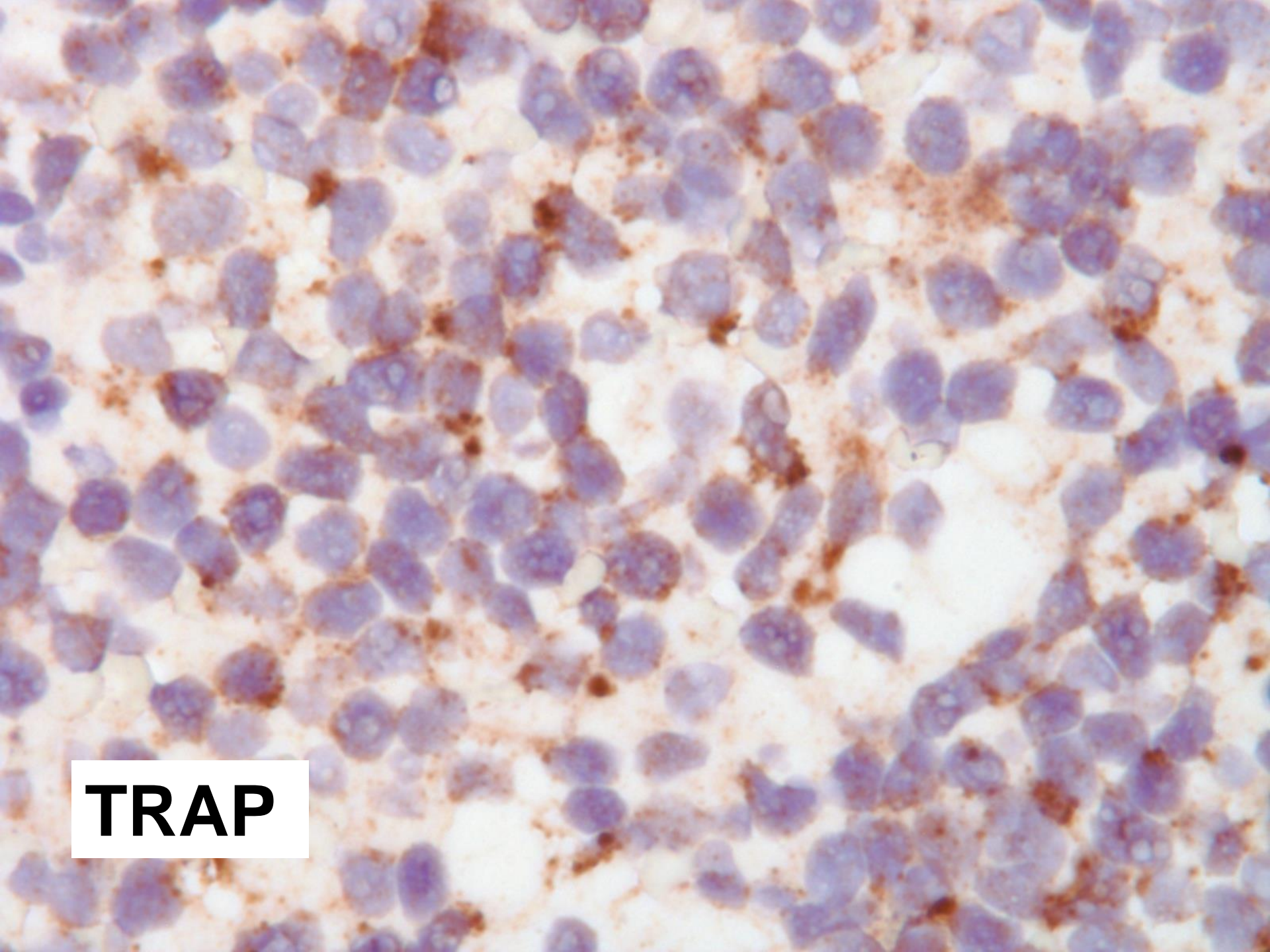






**CD 20**





**TRAP**

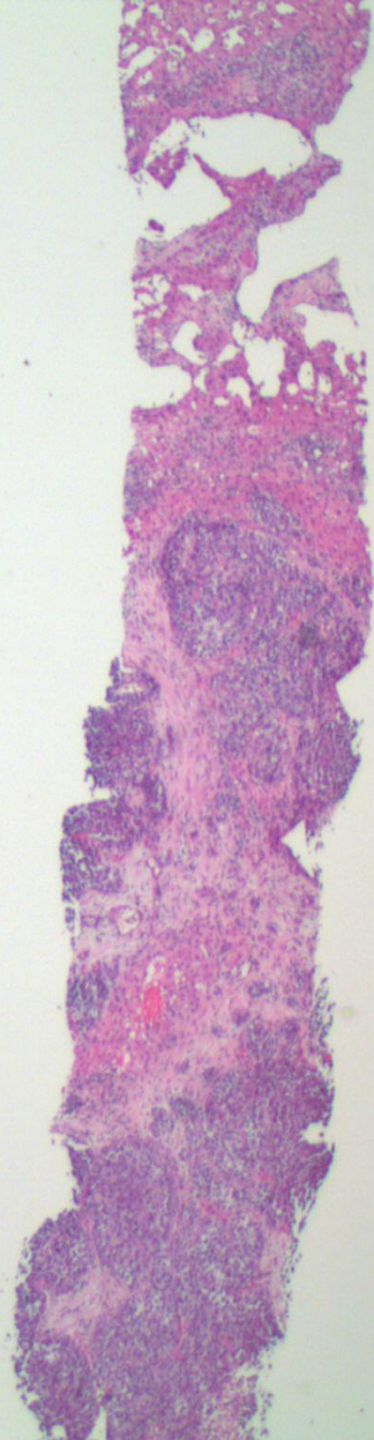
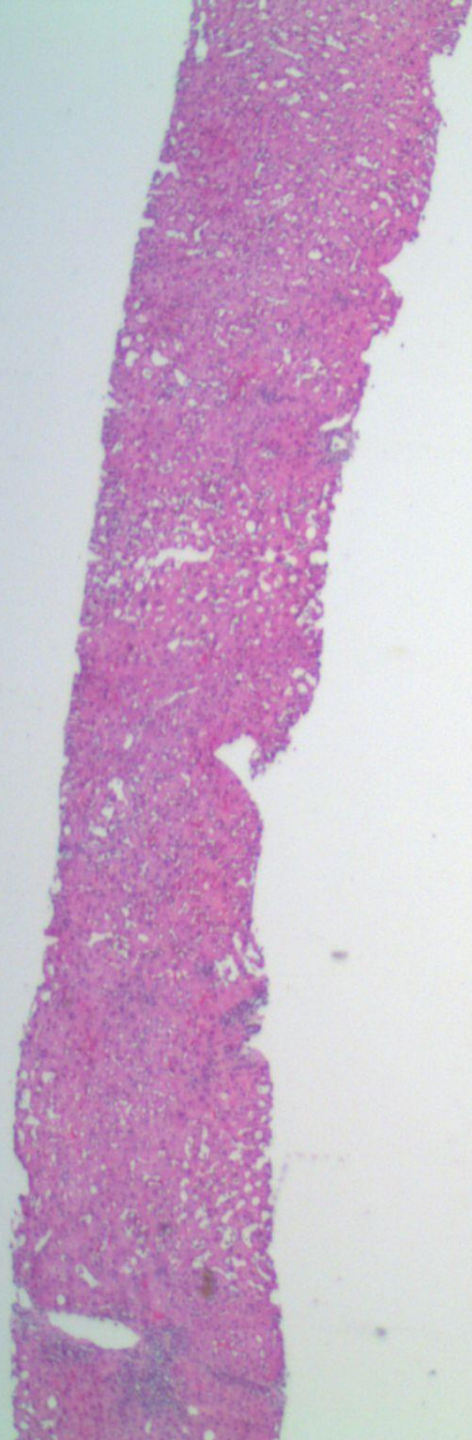


# SB 5873

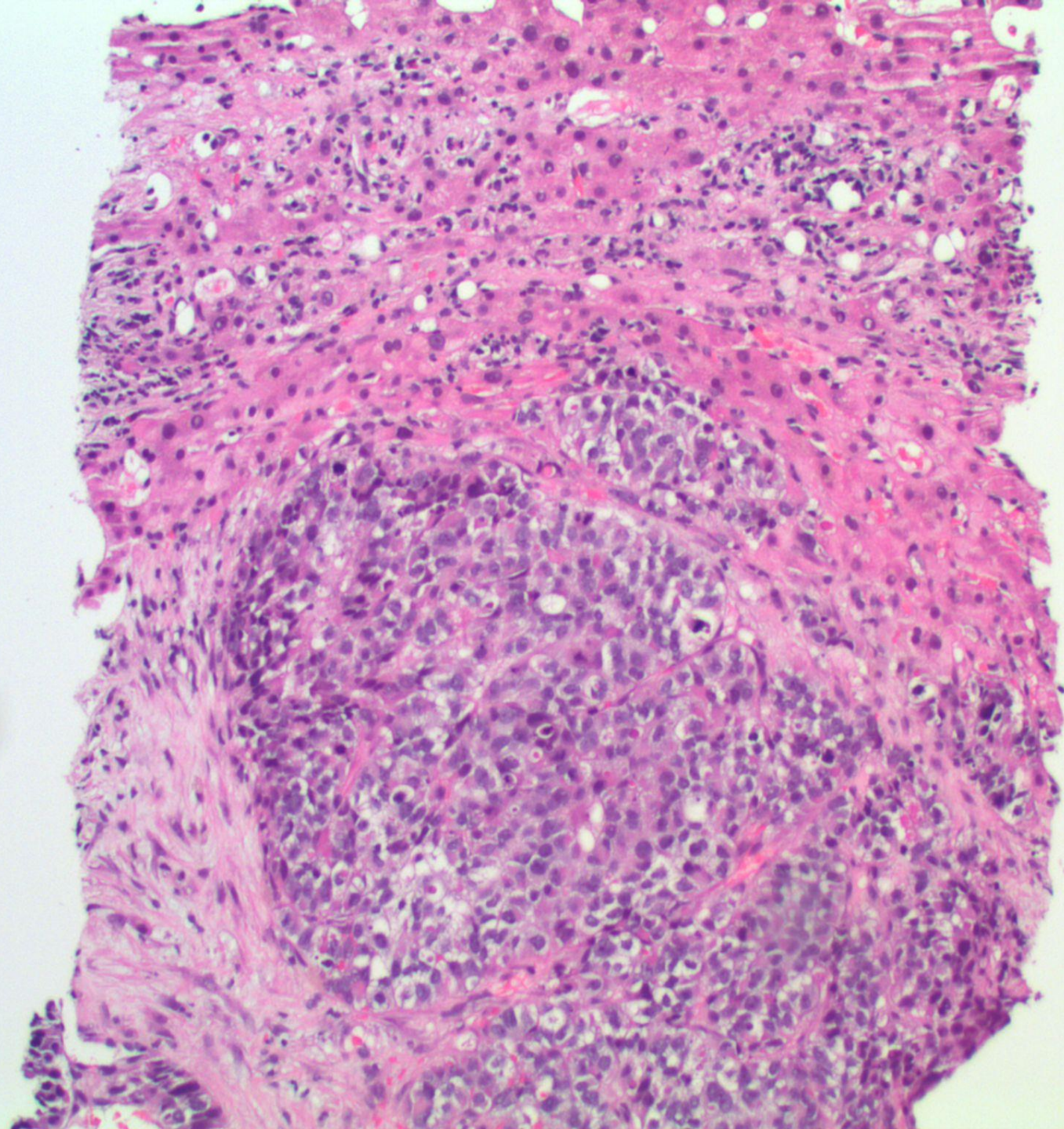
71-year-old man with liver mass. Core biopsy performed.

Ankur Sangoi/John Collin; El Camino Hospital

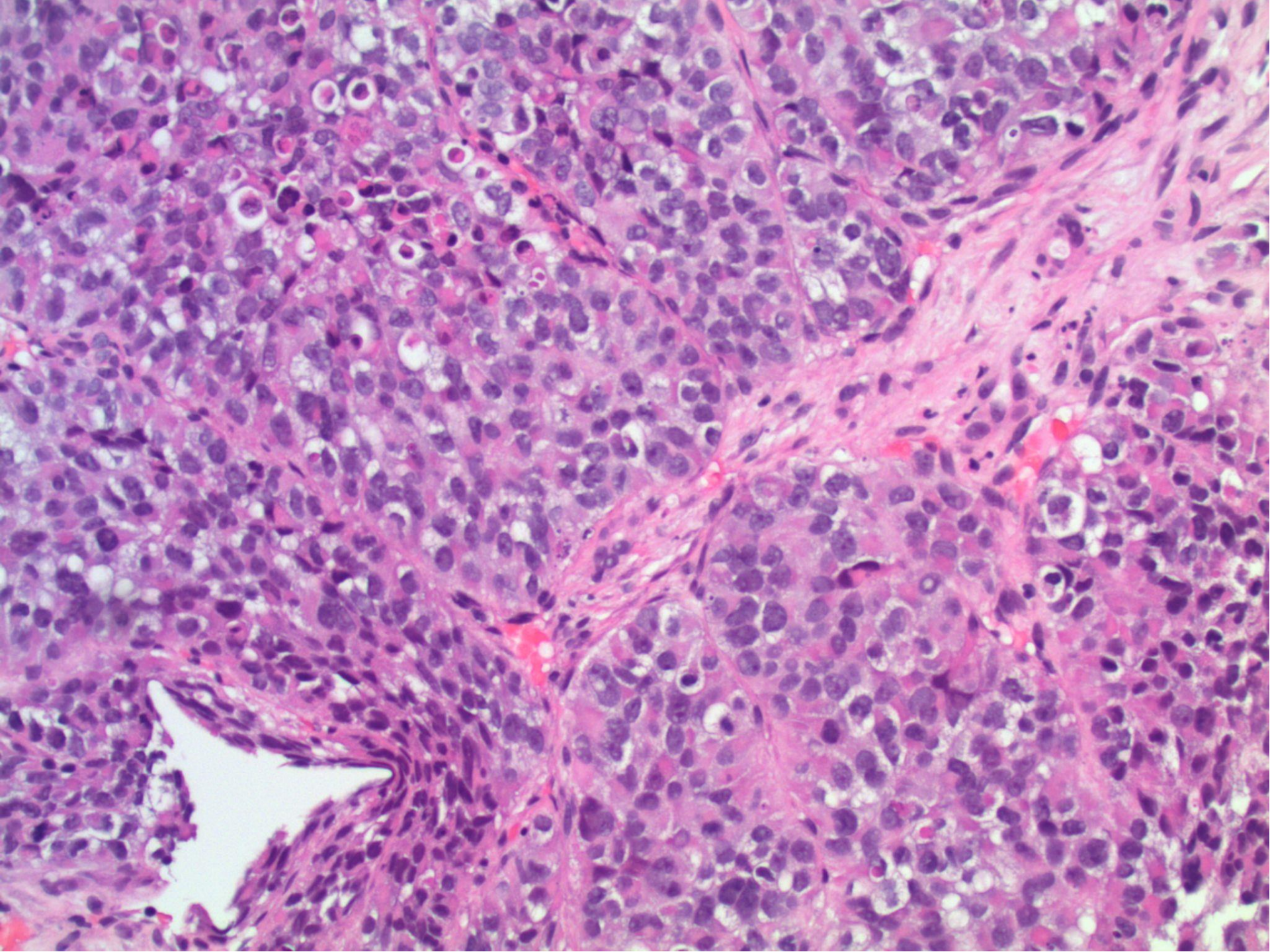




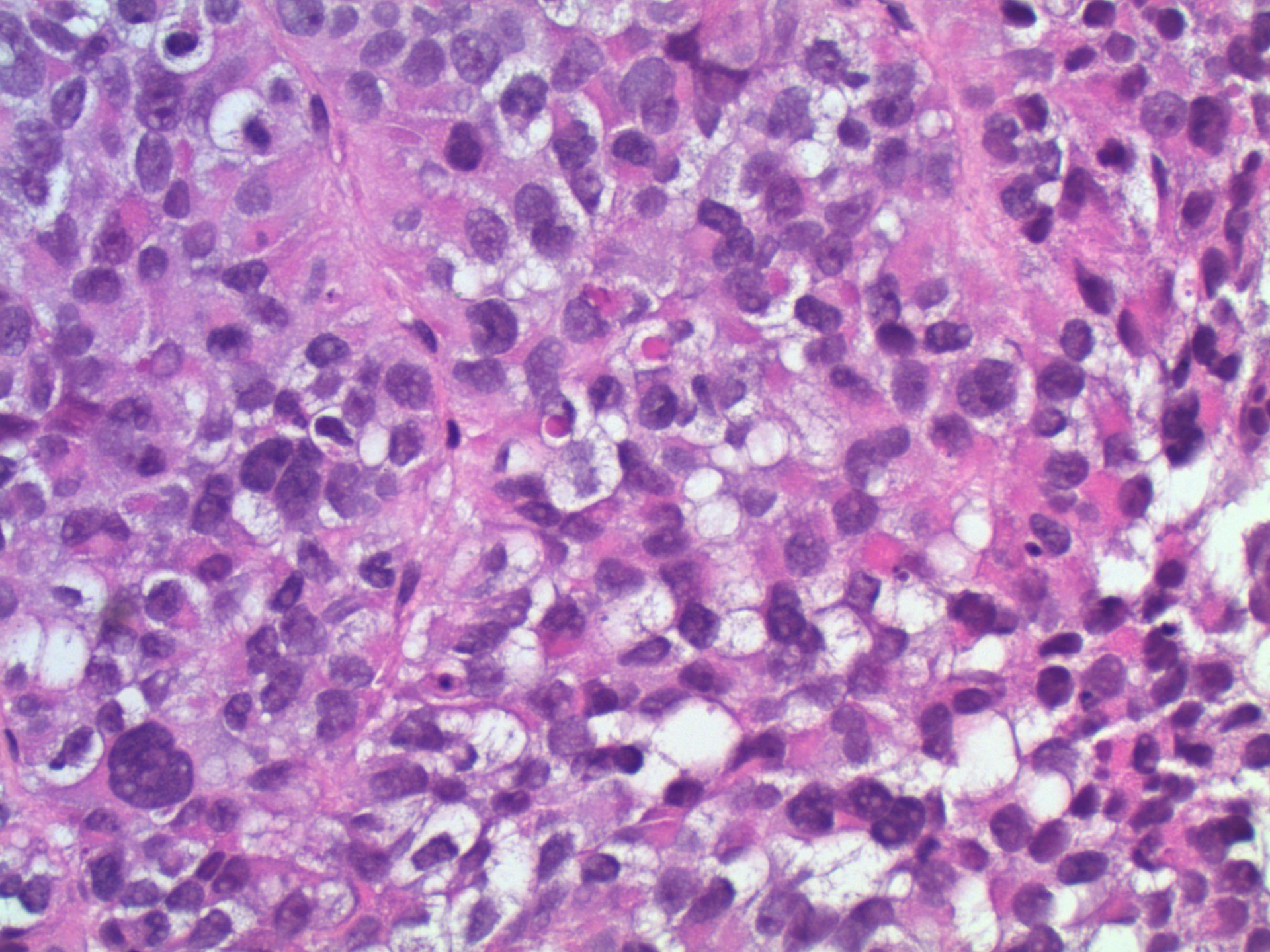












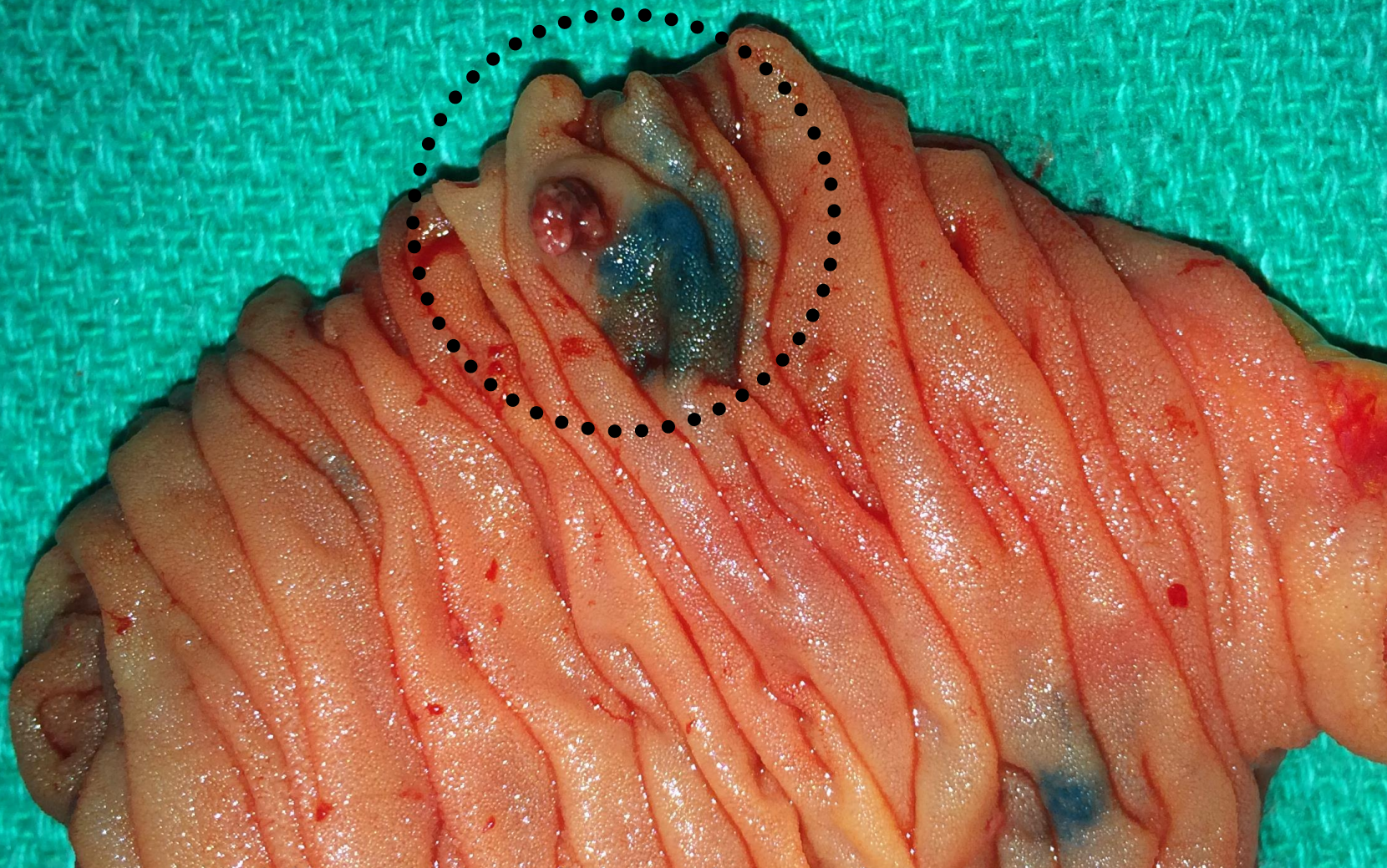


# SB 5874

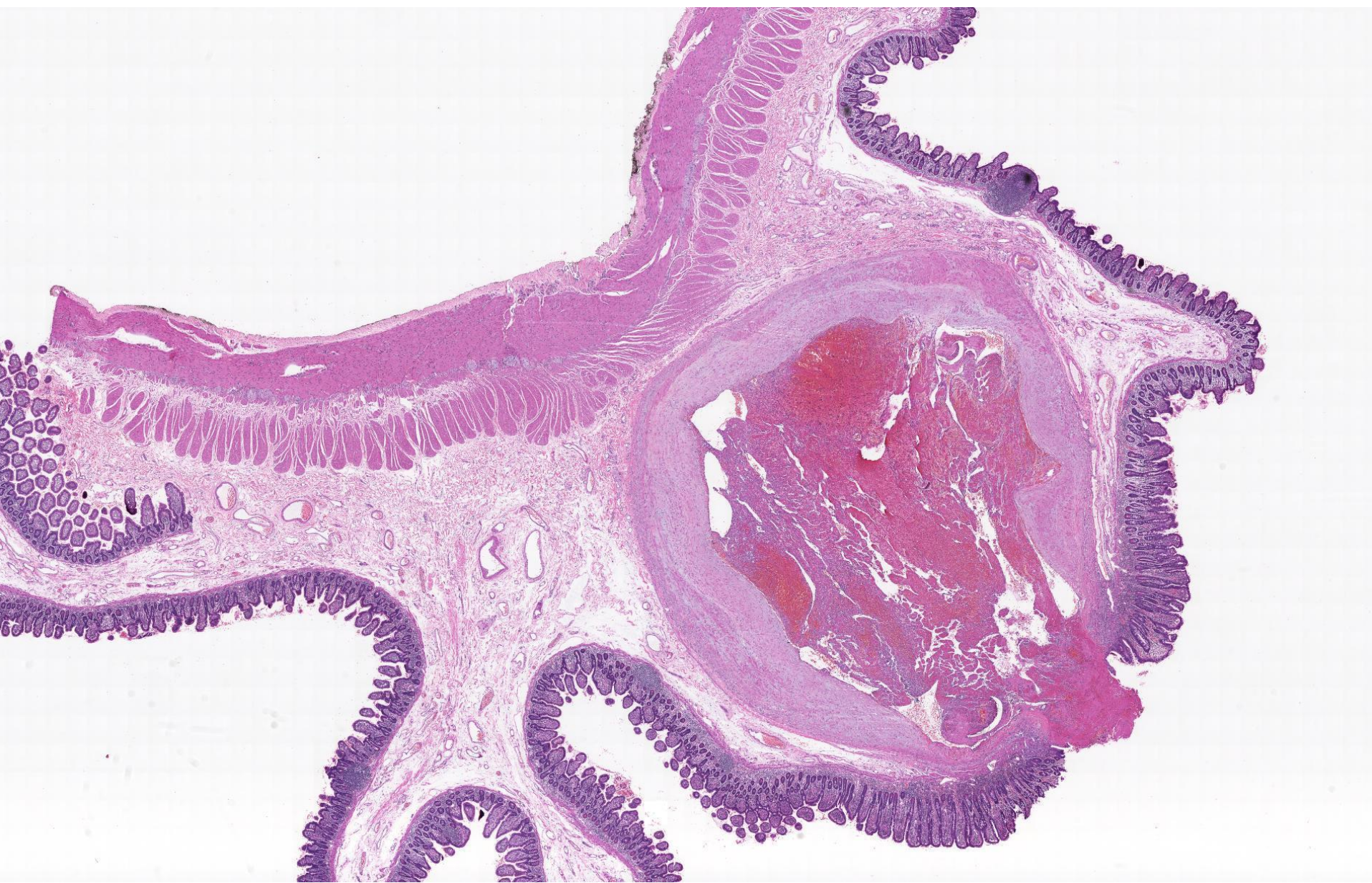
65-year-old man with severe GI bleeding.  
Jejunum resection performed.

Ankur Sangoi; El Camino Hospital

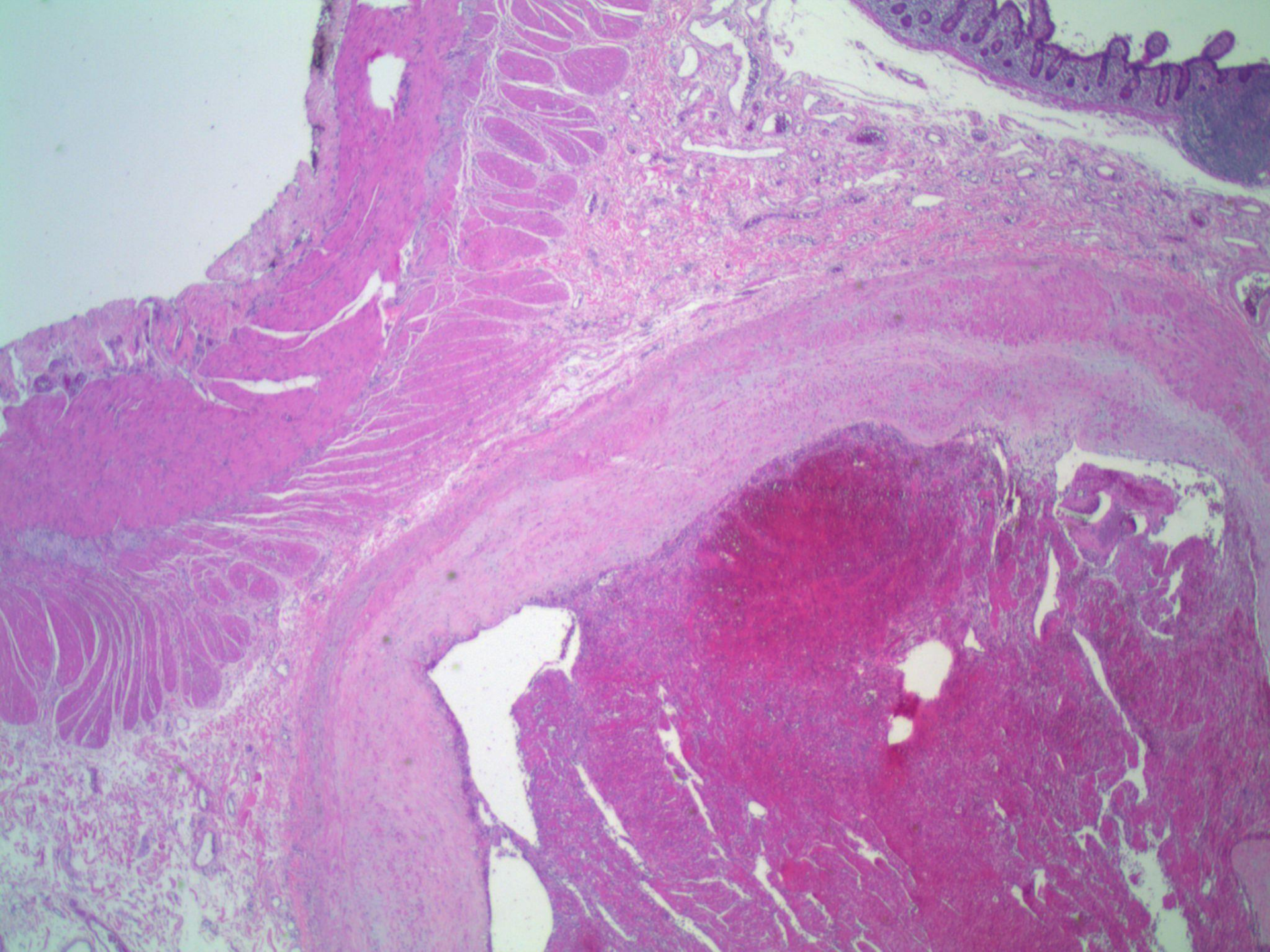




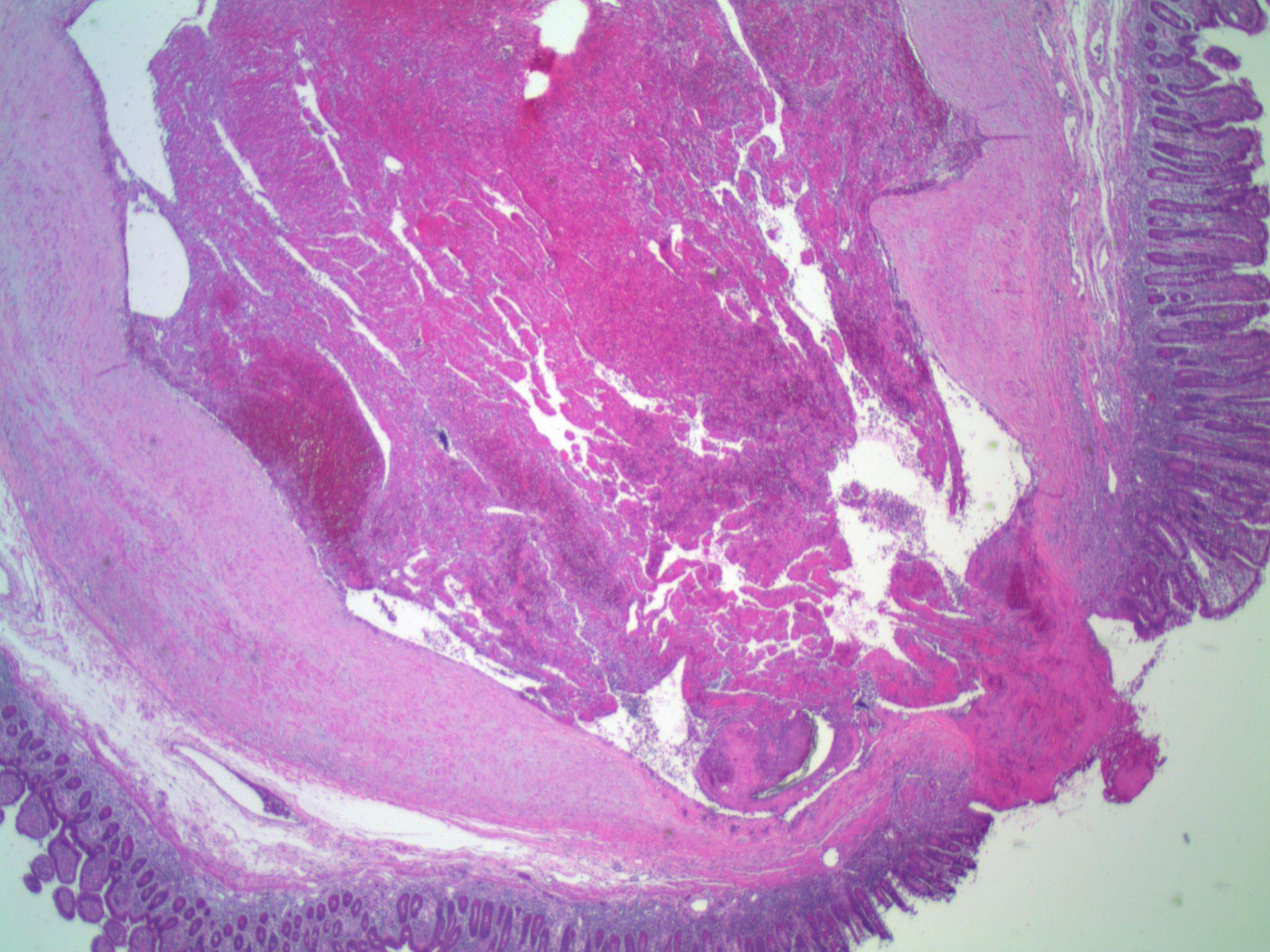




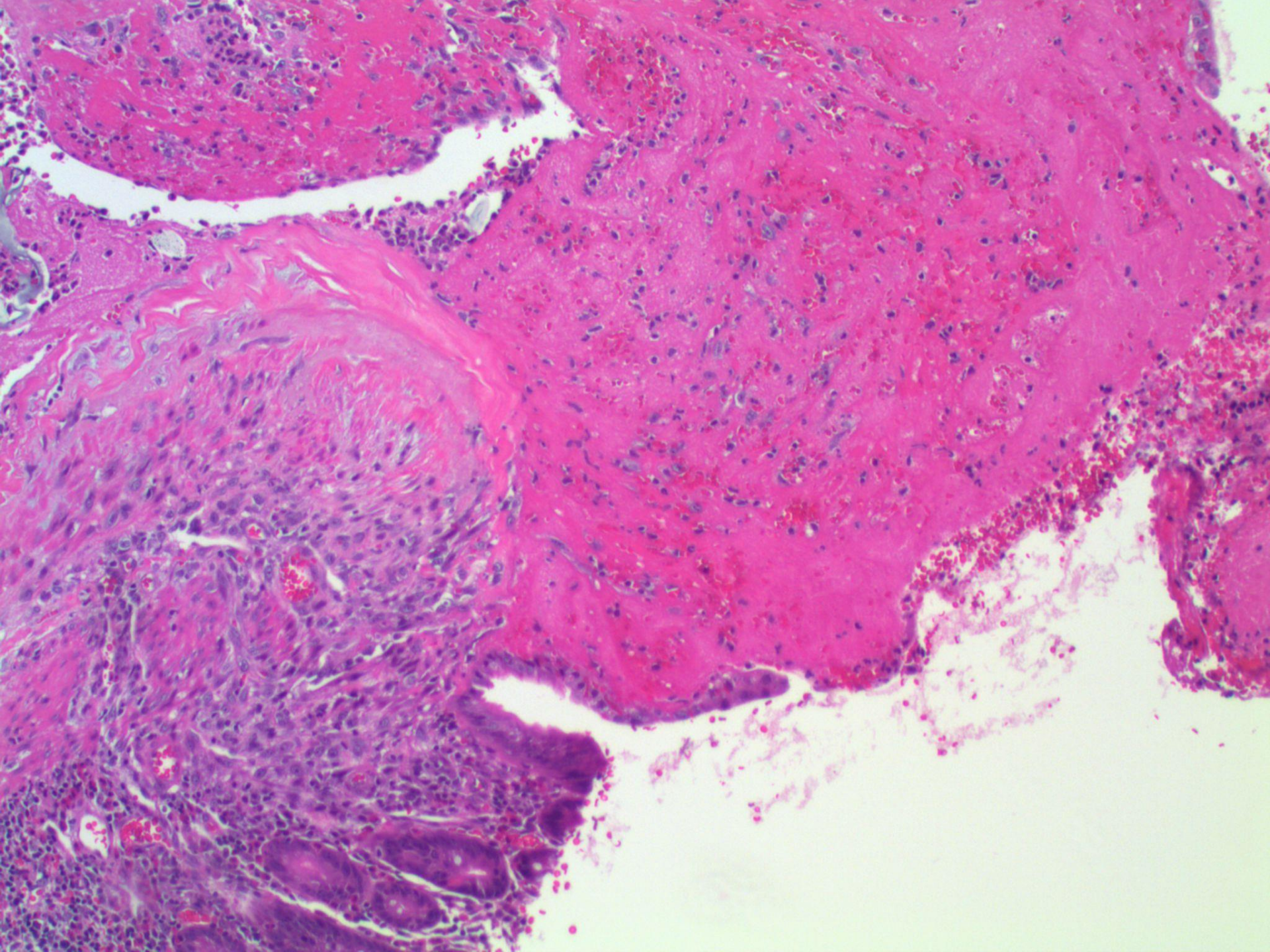




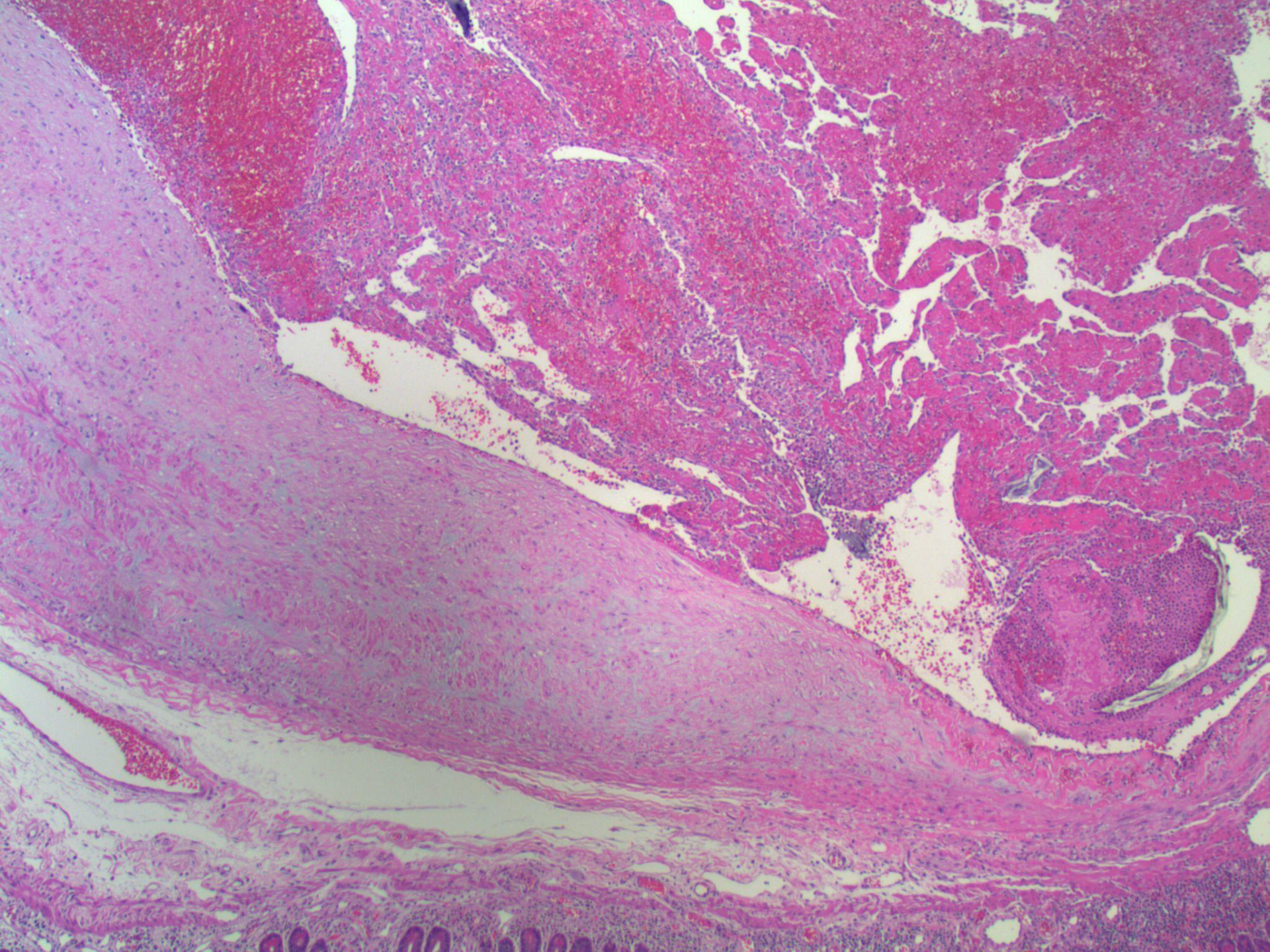




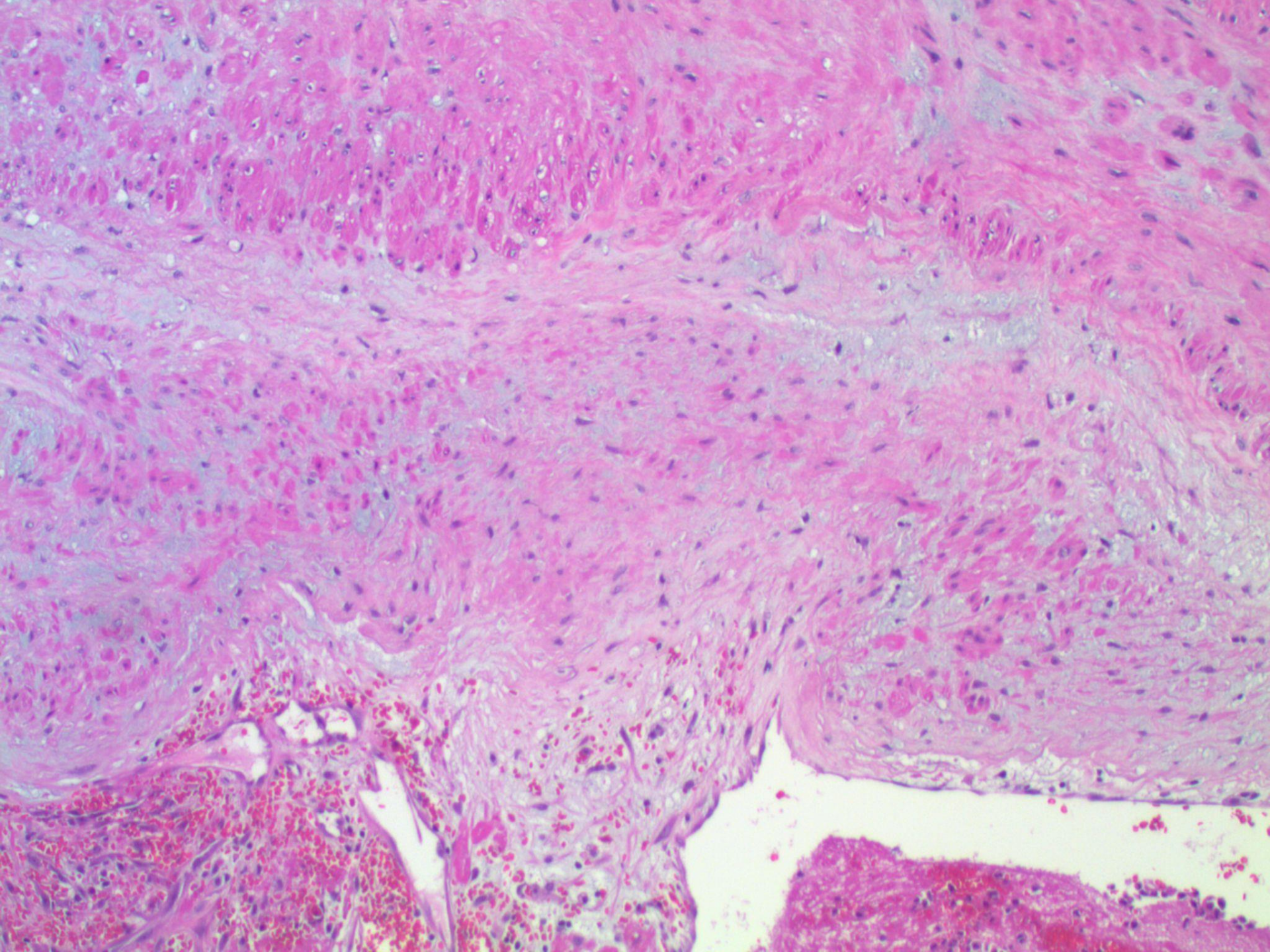












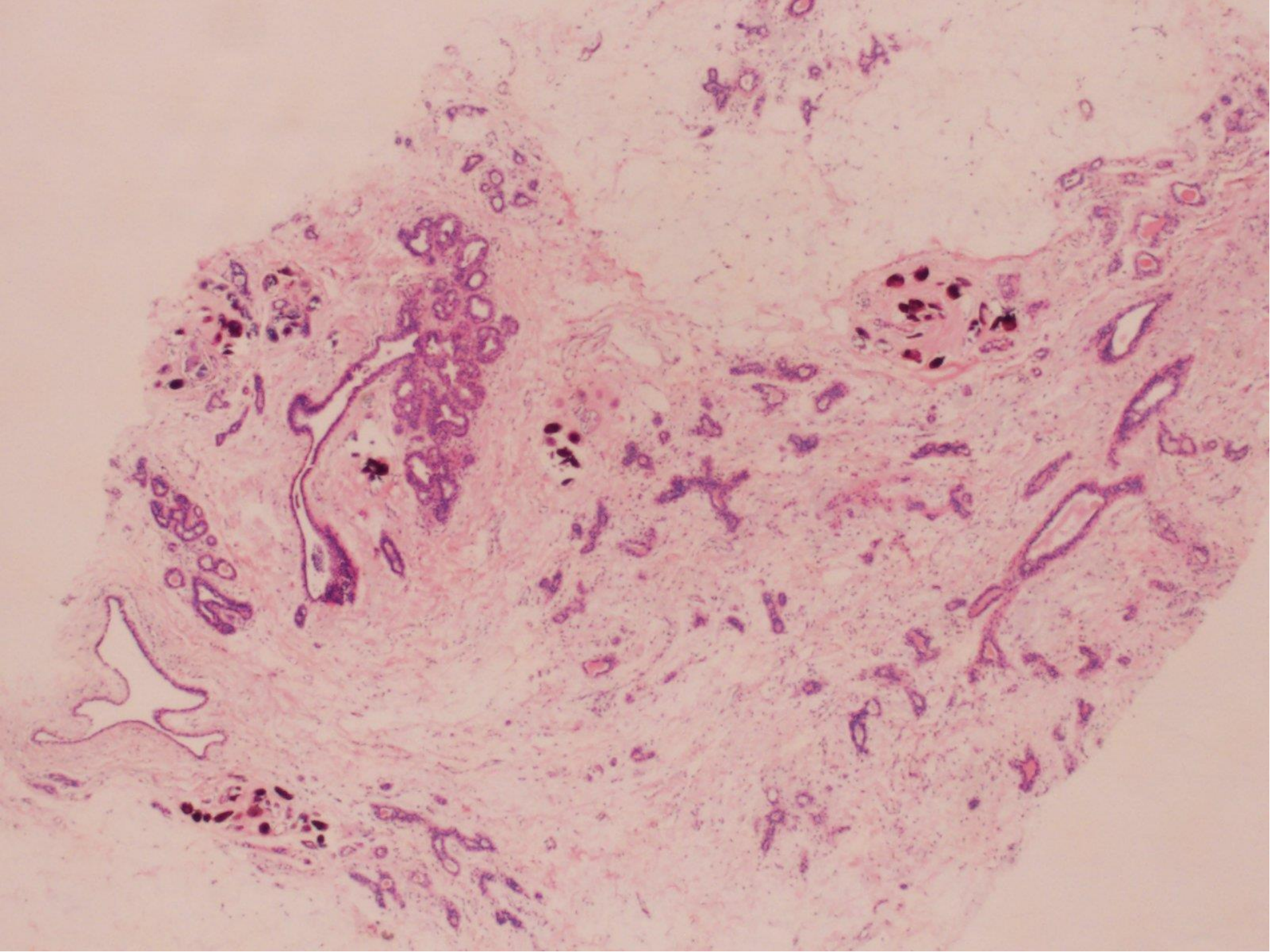


# SB 5875

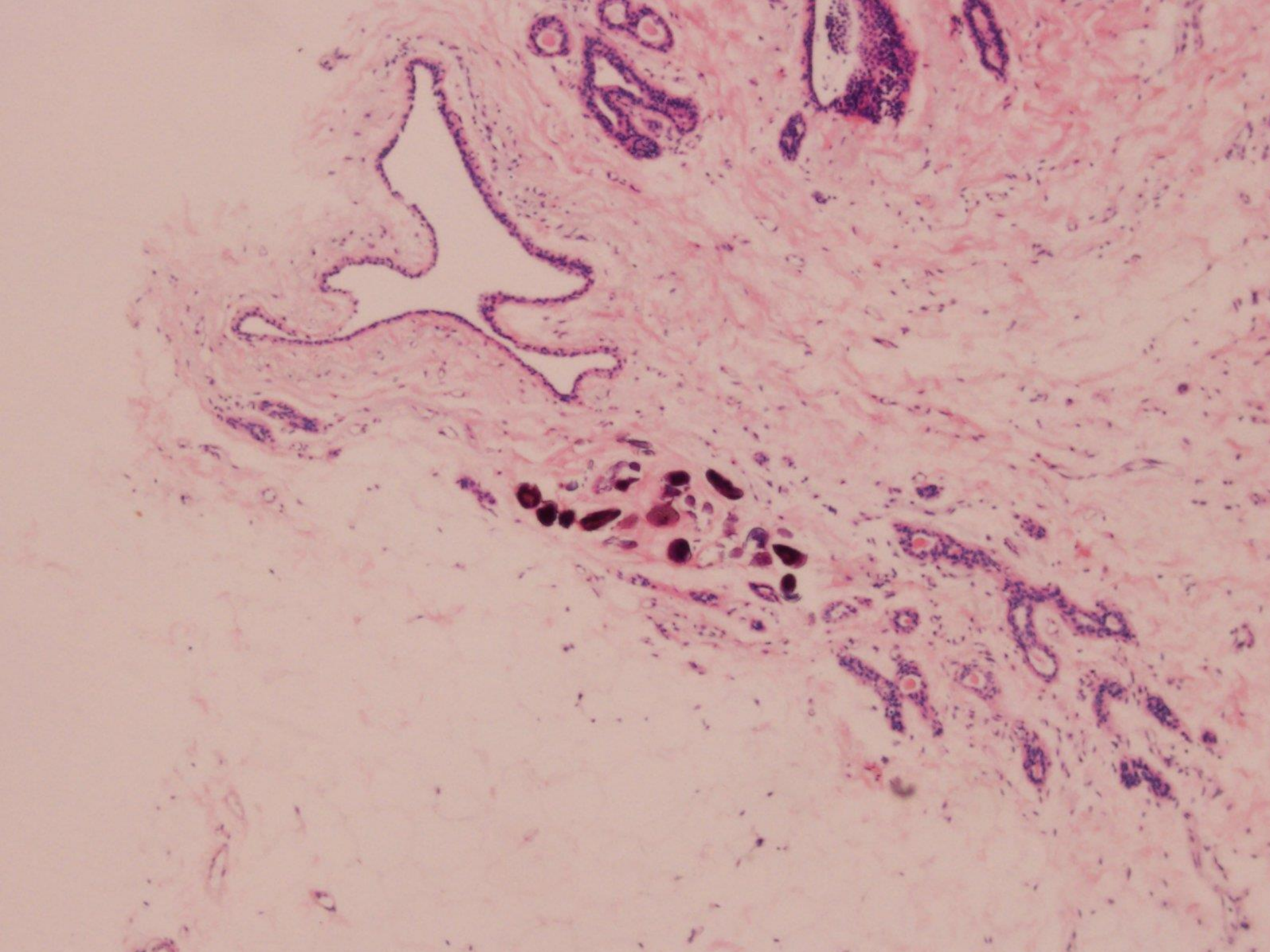
57-year-old woman with clusters of calcifications identified on left breast screening mammogram.

Sarah Cherny; Kaiser SF

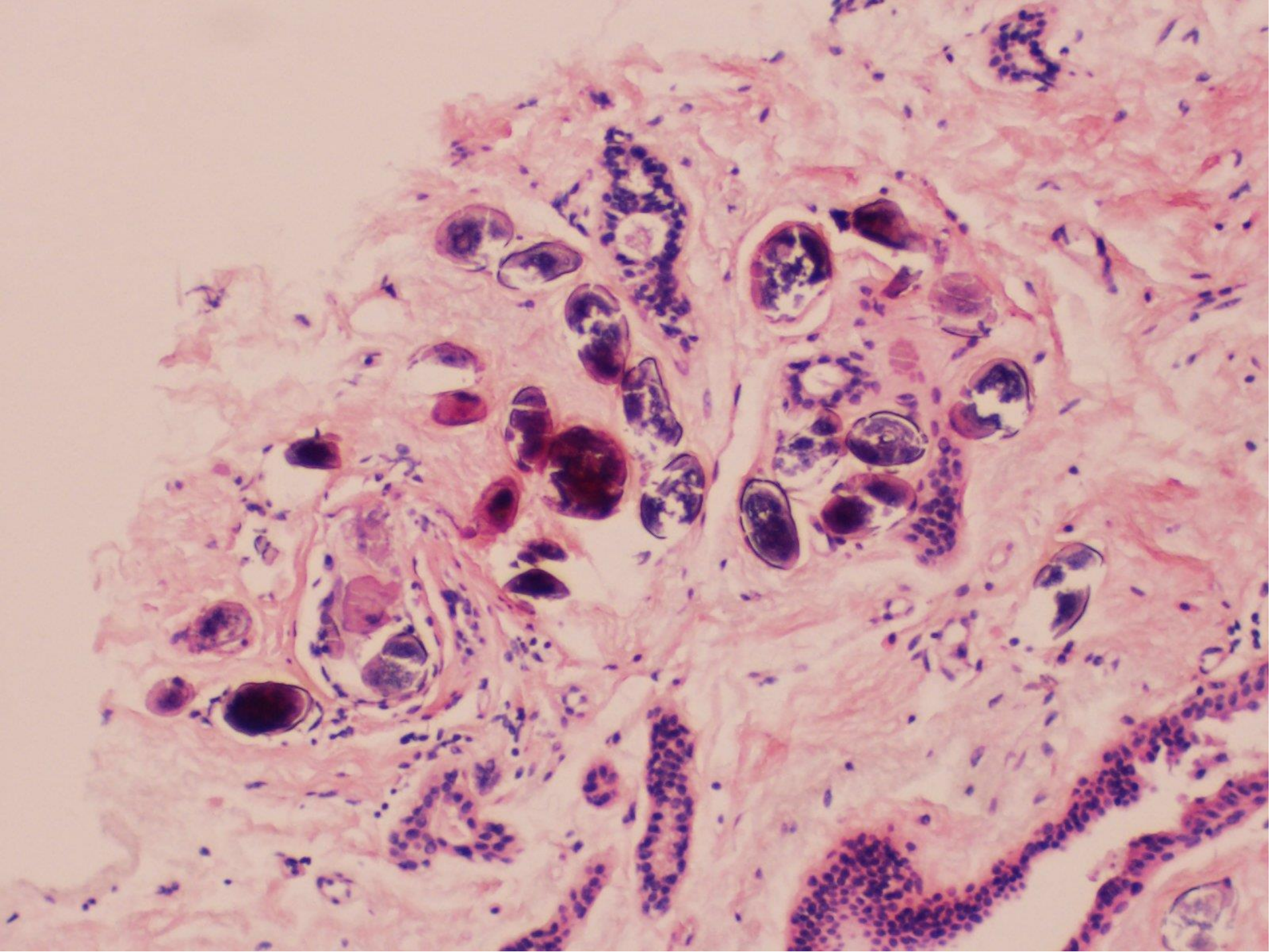




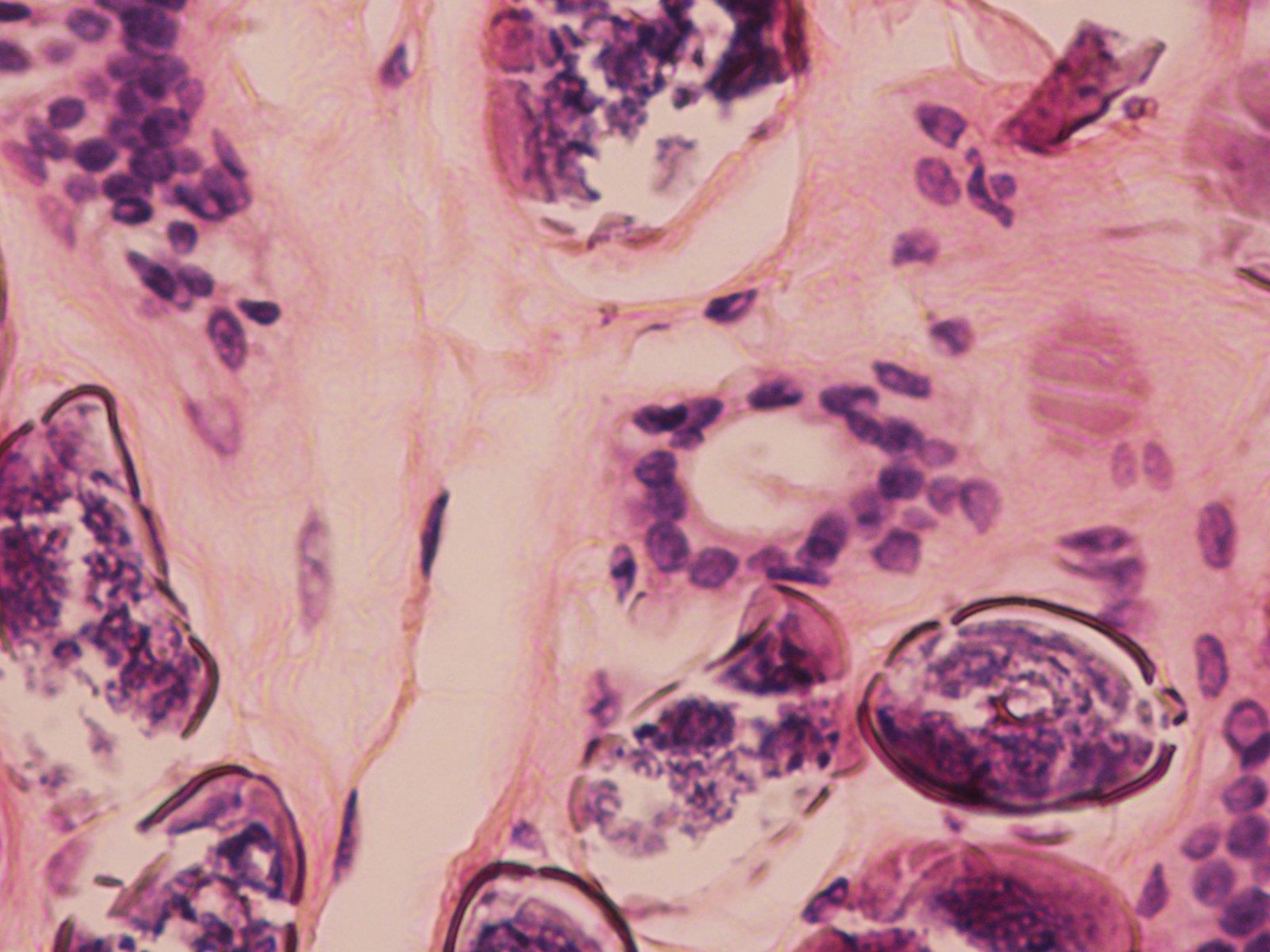












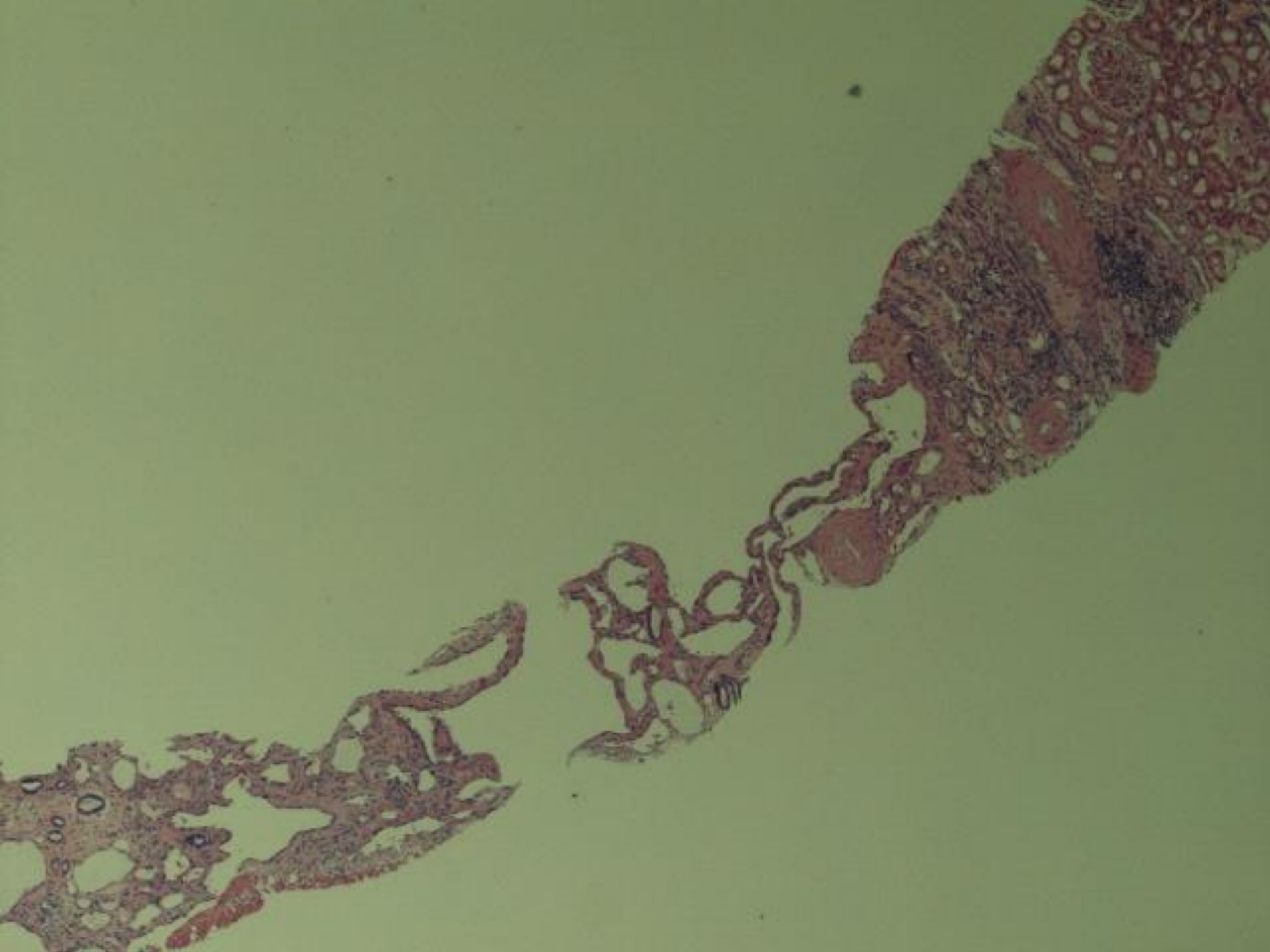


# SB 5876

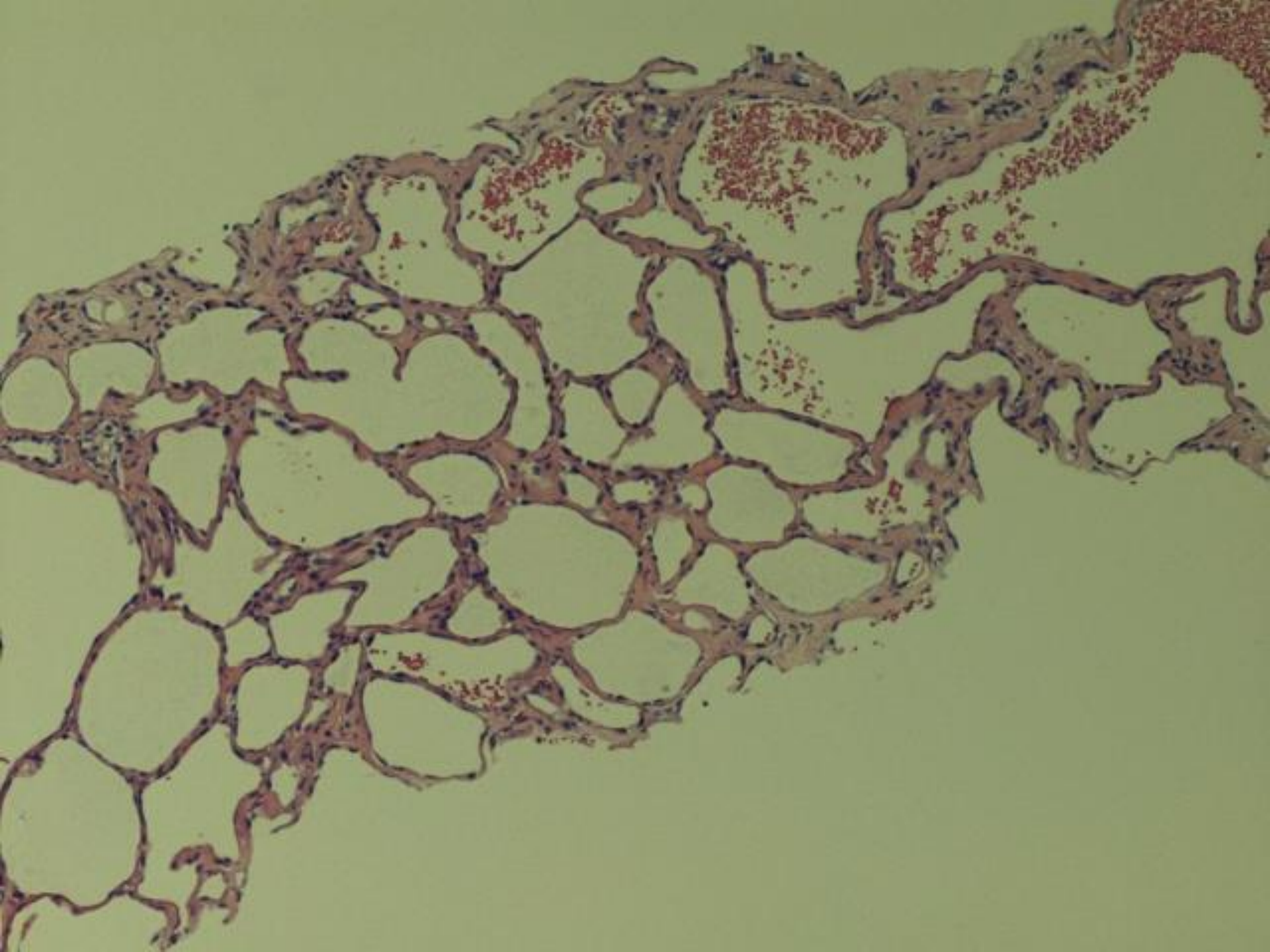
62-year-old woman with 3cm “vague” mass in right mid kidney. CT-guided core biopsy performed.

Gloria Yu/Tom Chu  
O'Connor Hospital

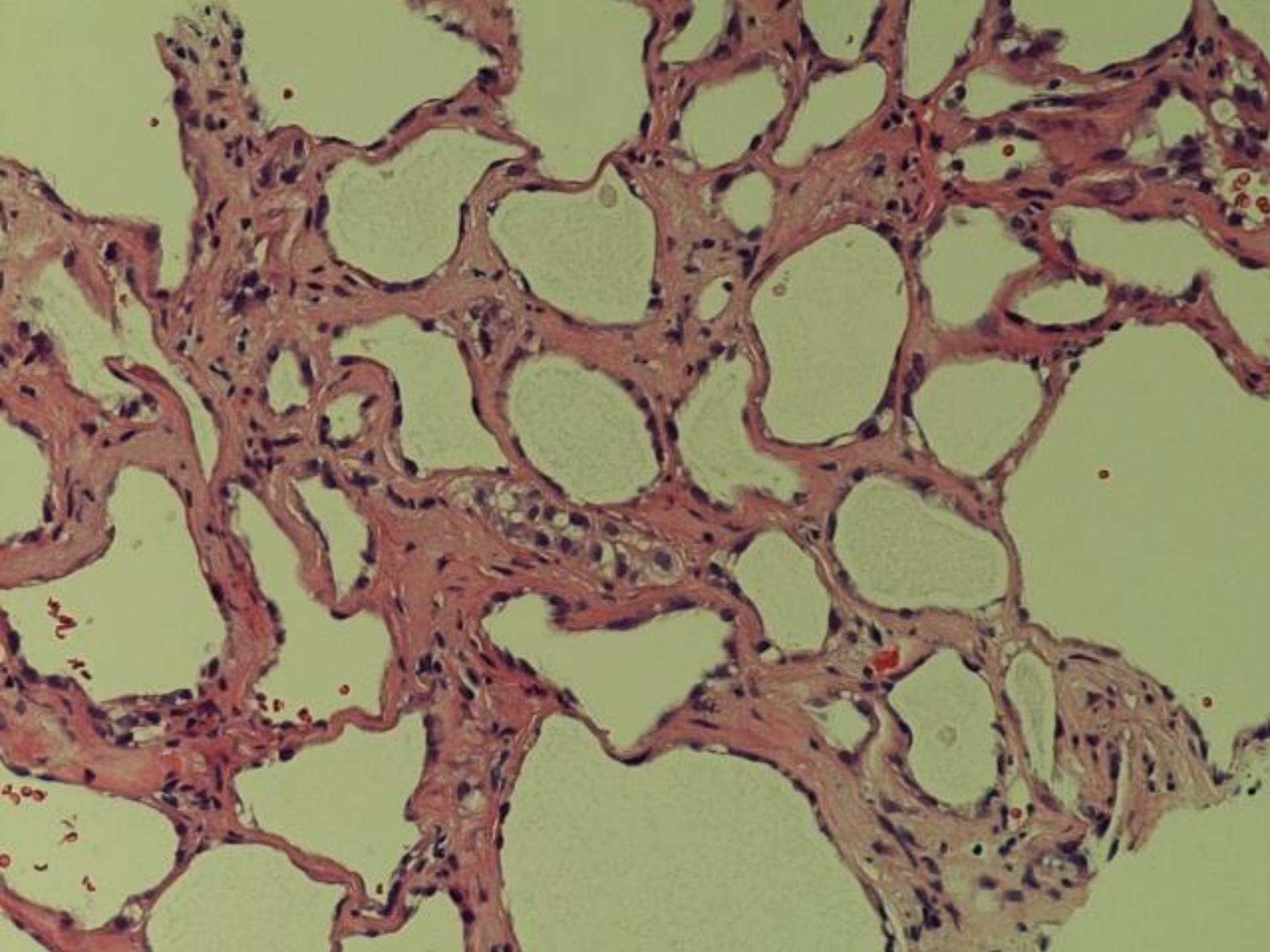




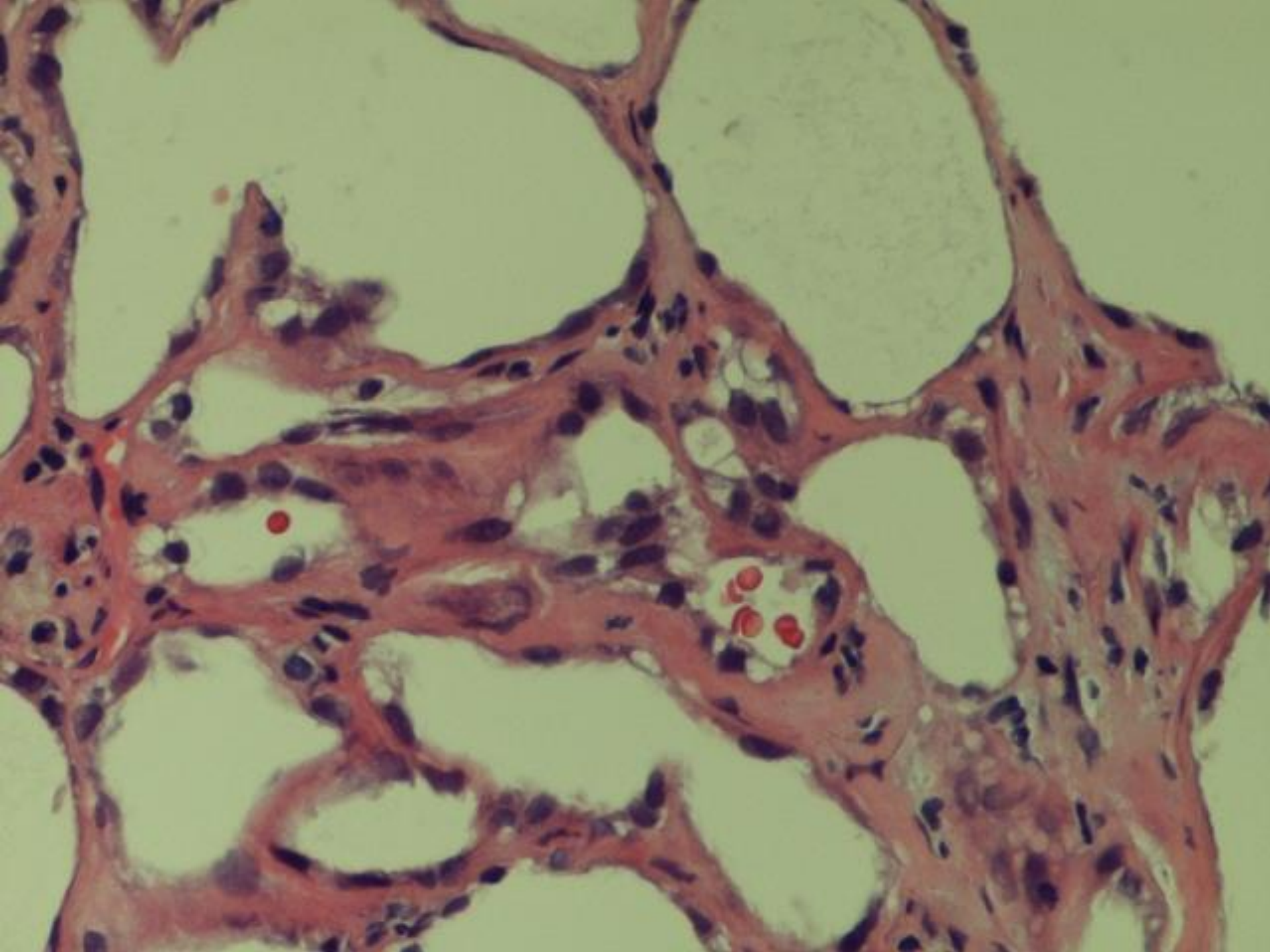












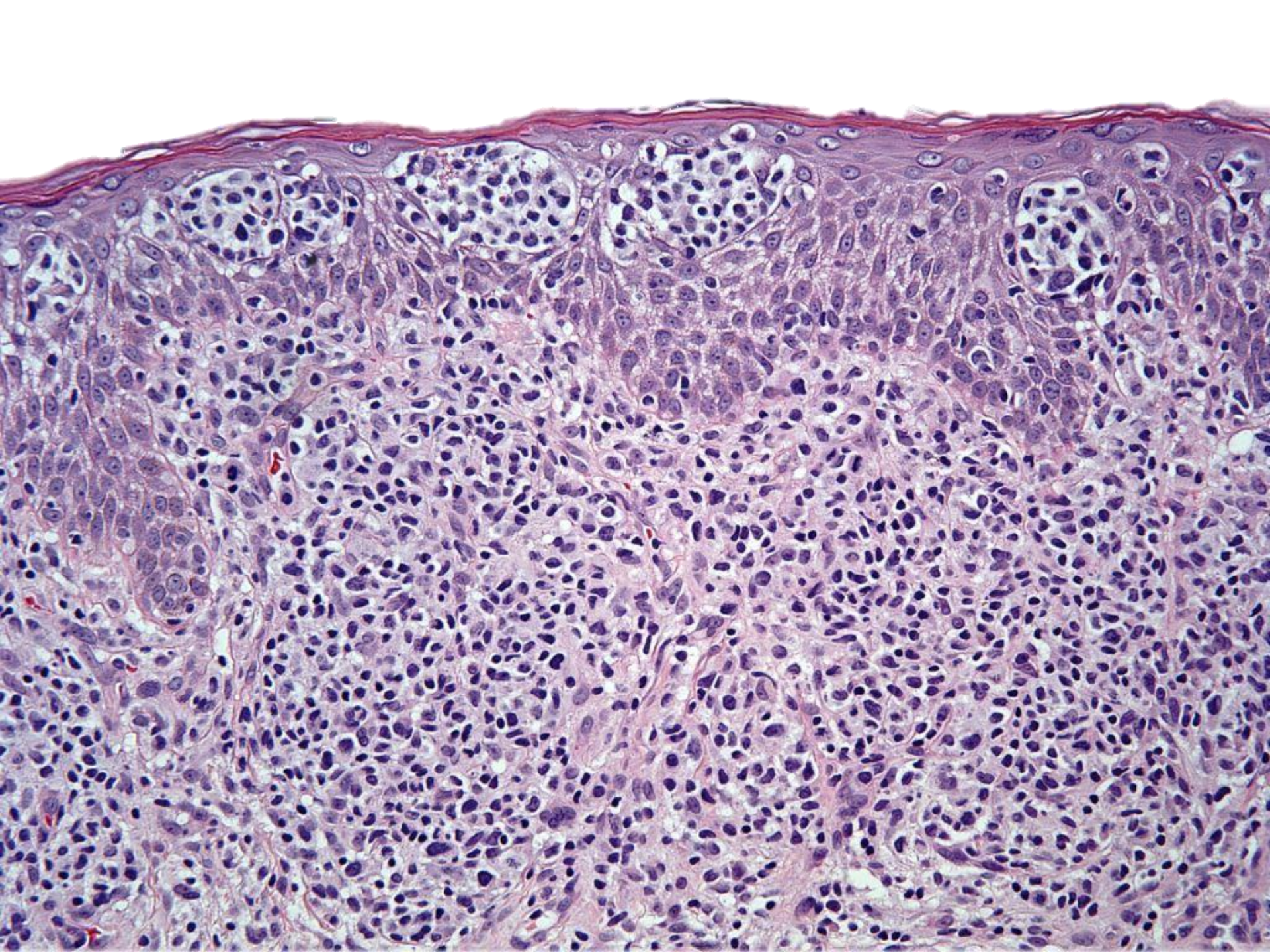


# SB 5877

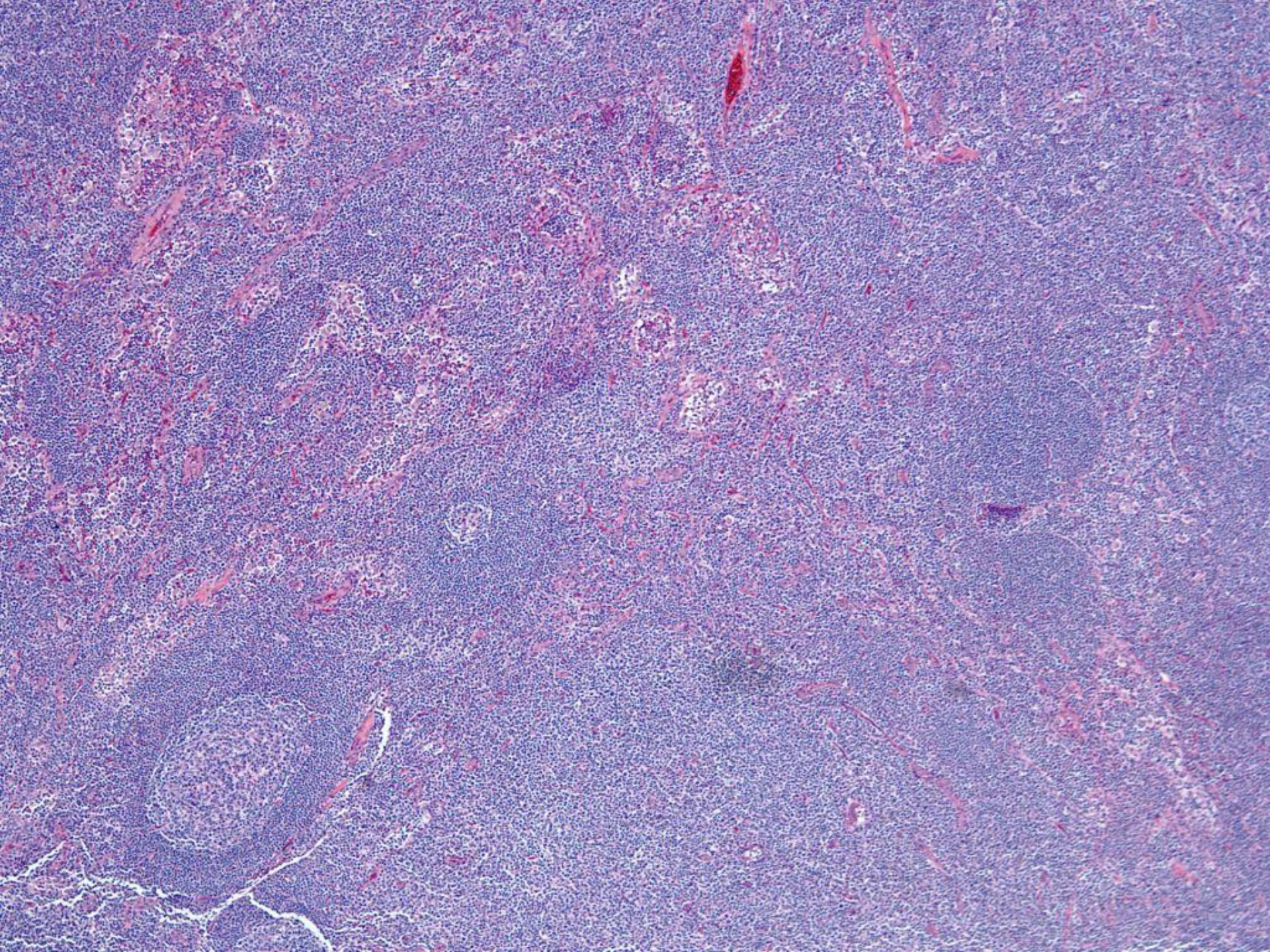
54-year-old man with mycosis fungoides had cutaneous disease progression and developed generalized lymphadenopathy. Skin and lymph node biopsy performed.

Robert LeBlanc/Dita Gratzinger; Stanford

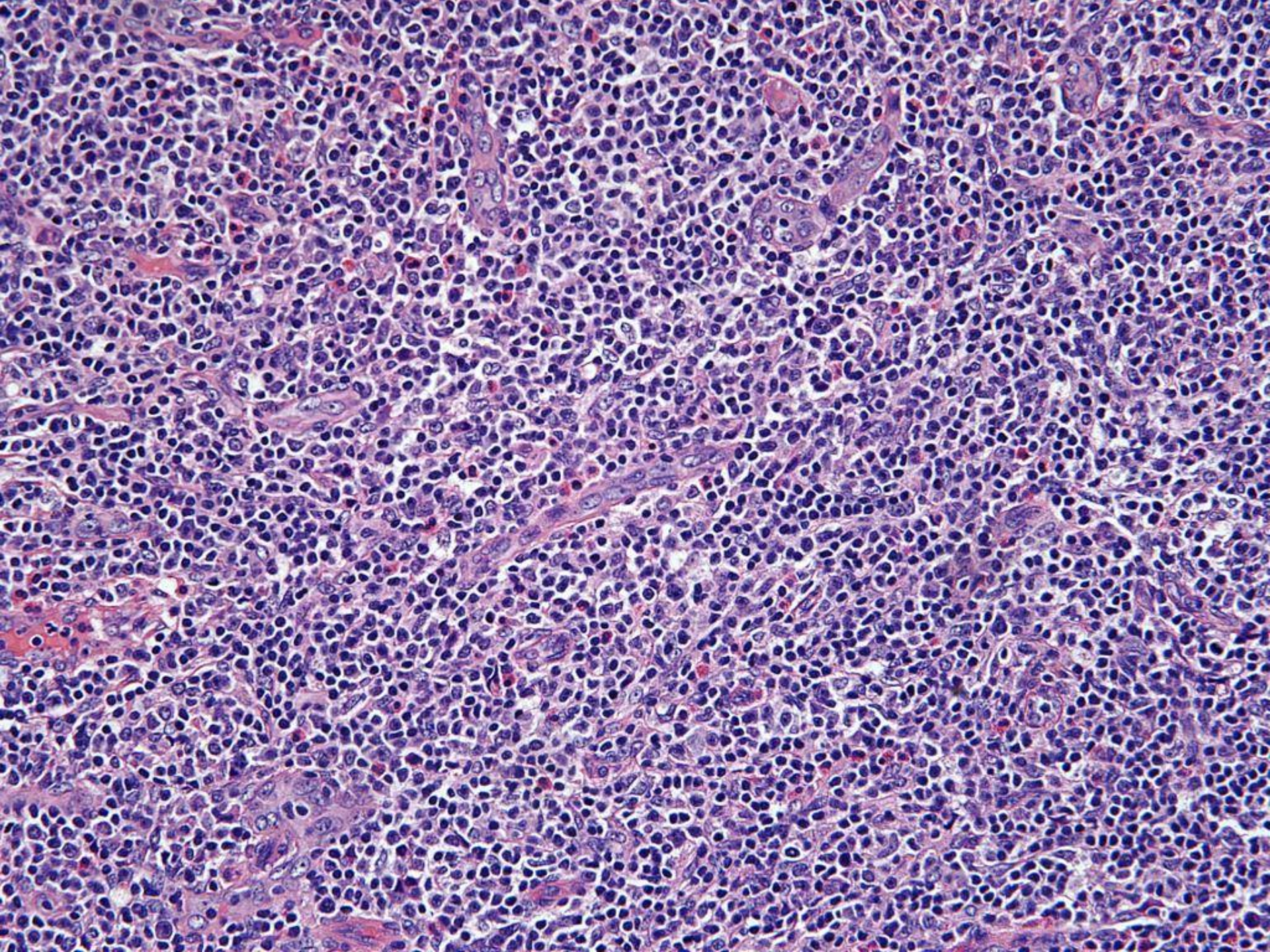




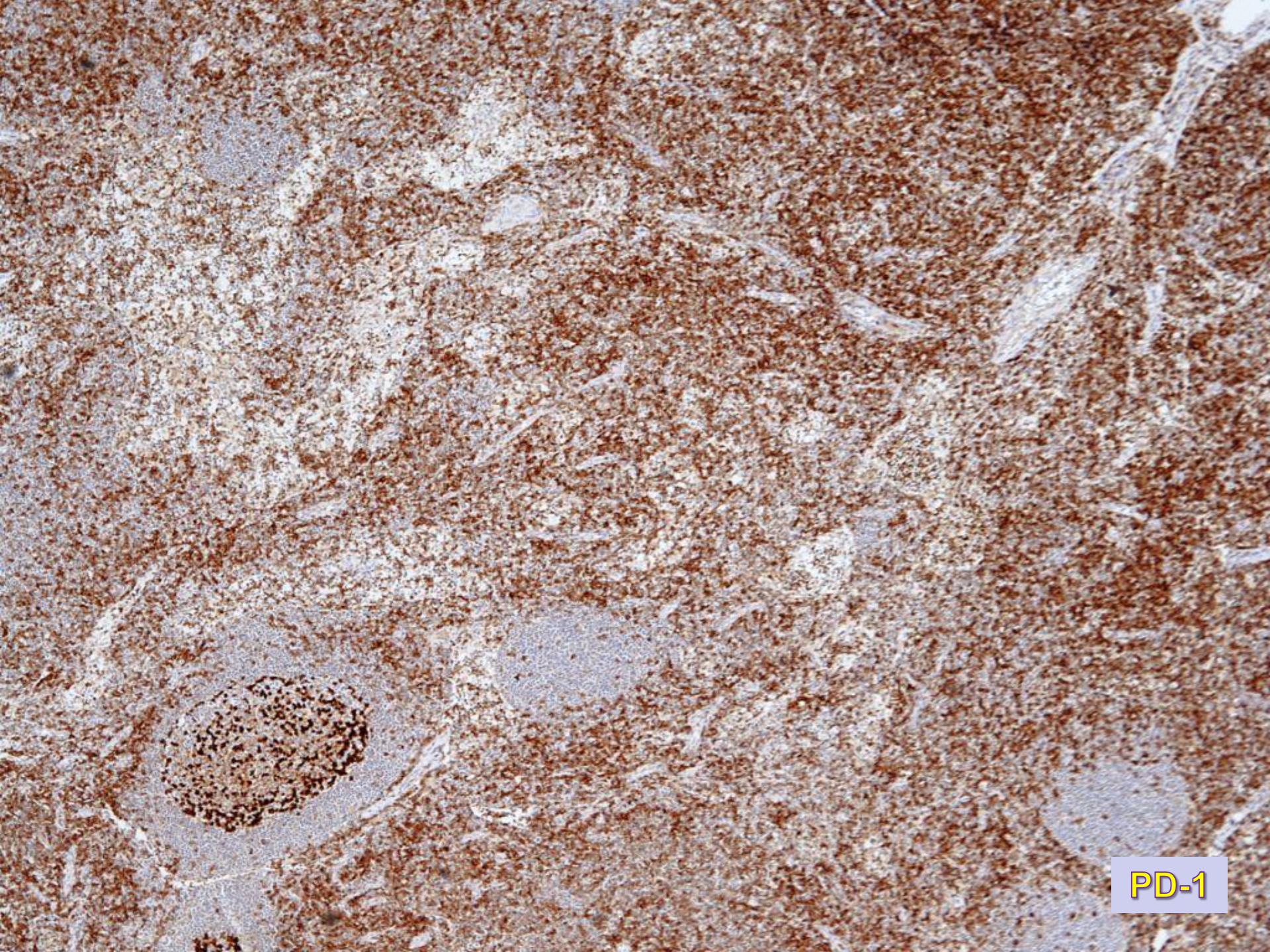






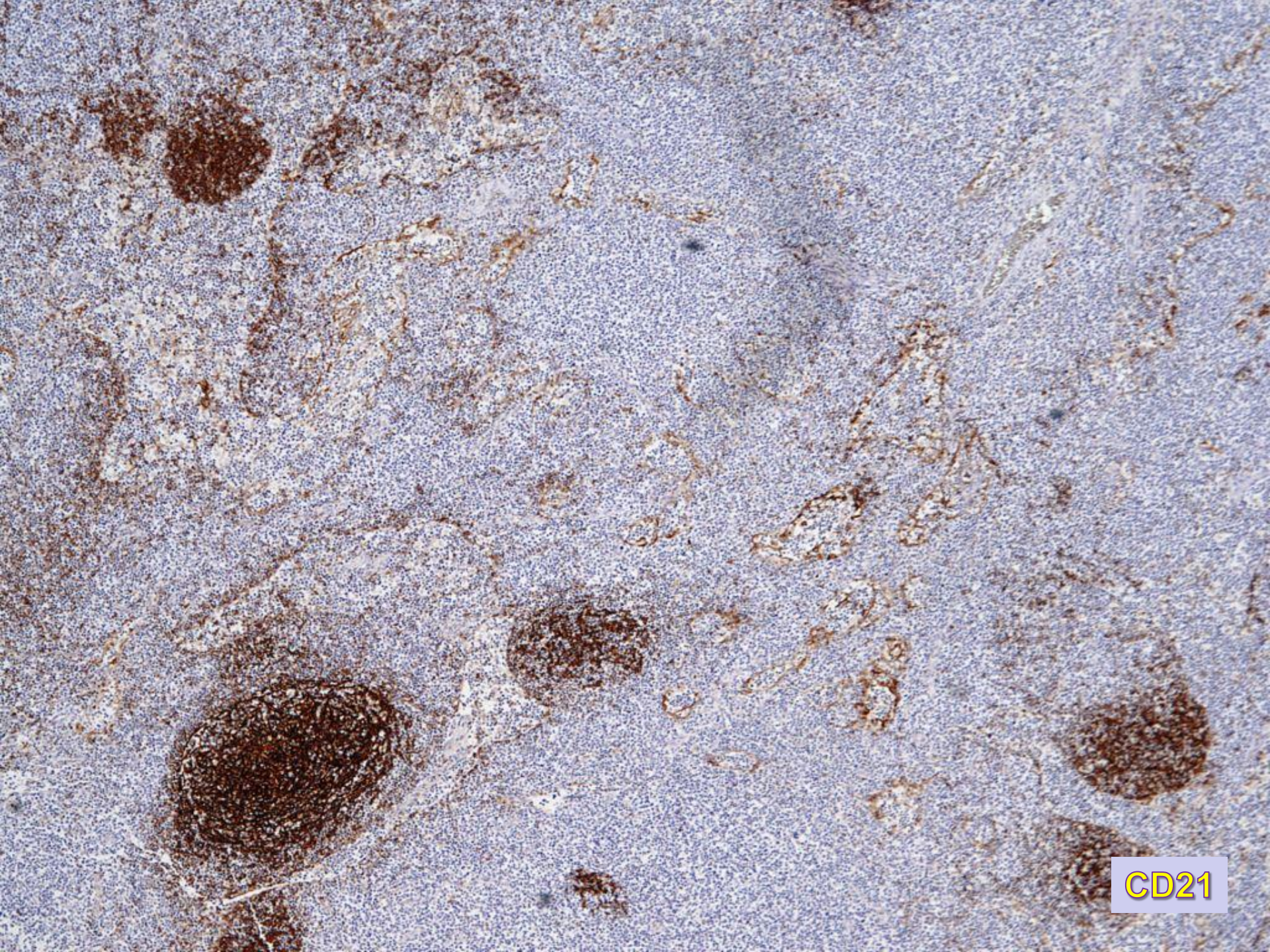






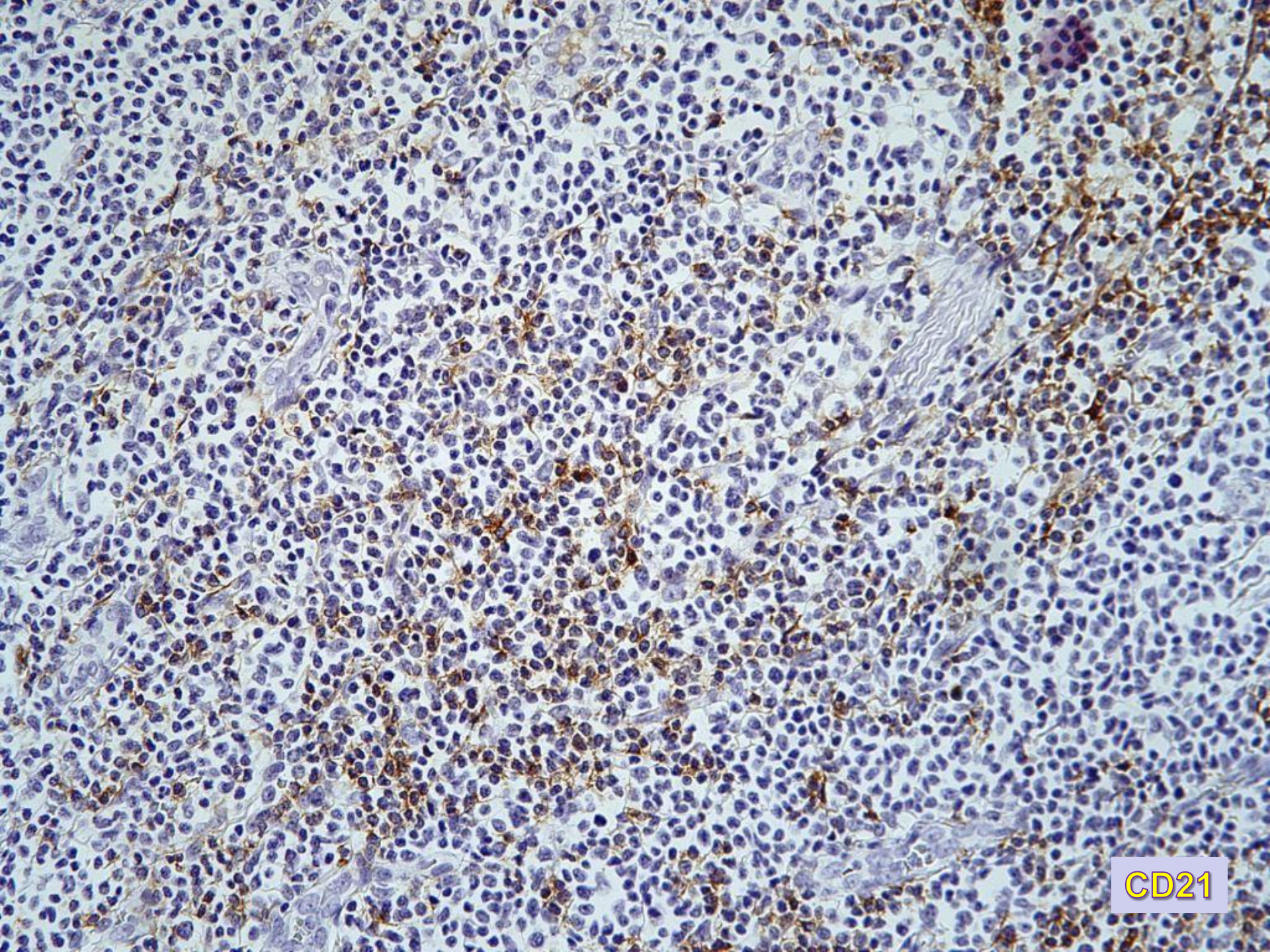
PD-1





CD21





CD21

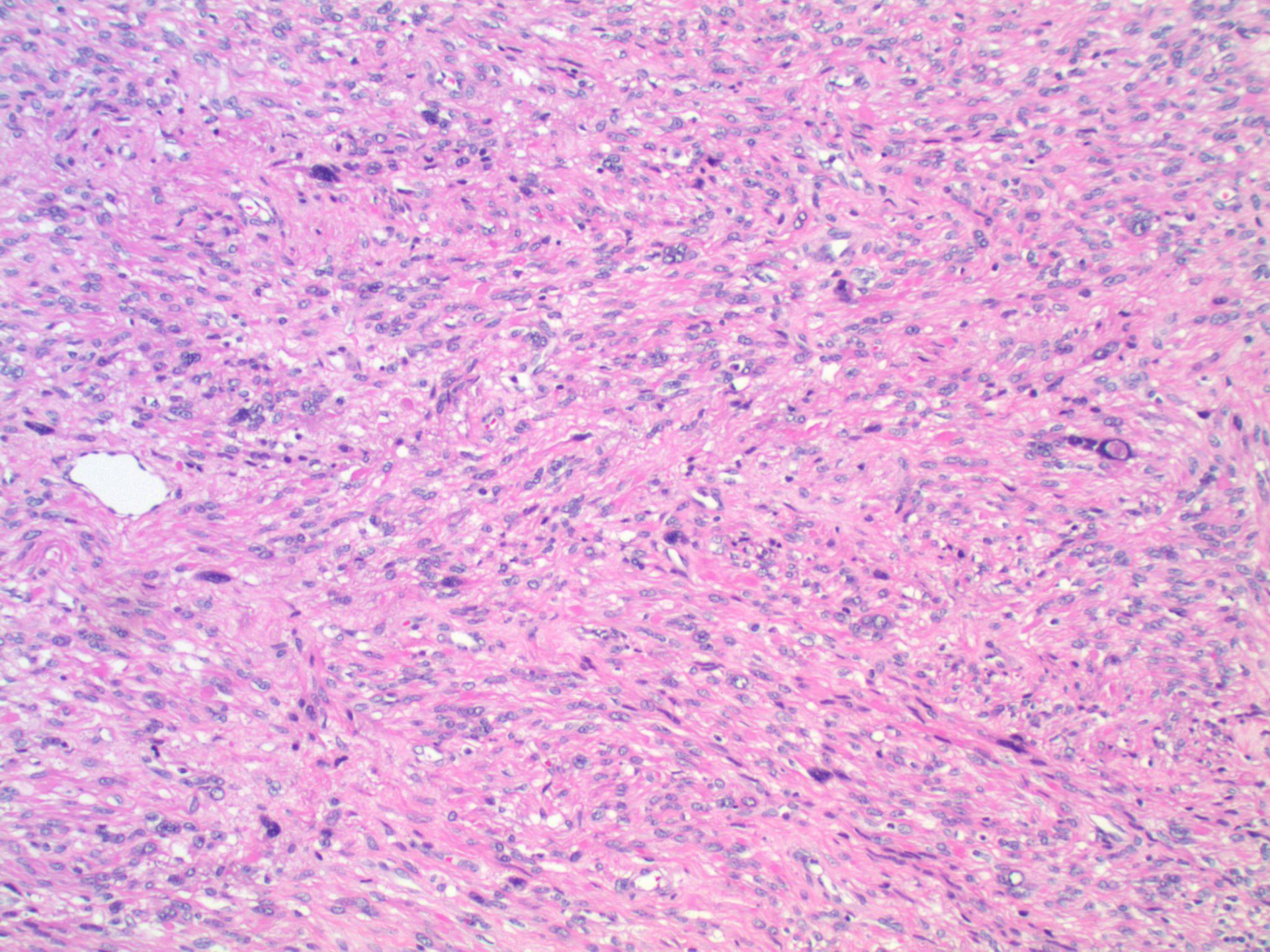


# SB 5878

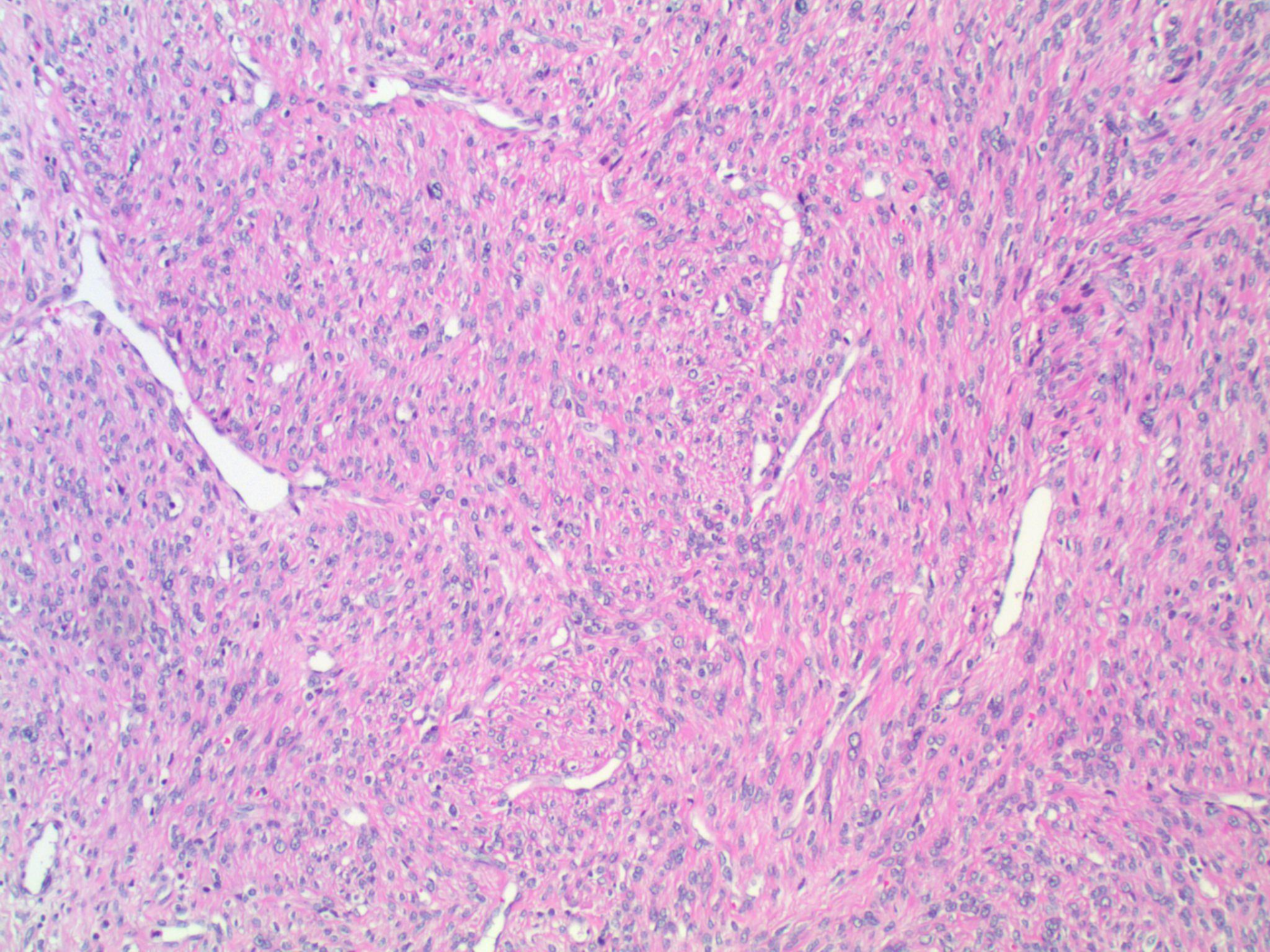
38-year-old woman who underwent laparoscopic morcellated hysterectomy. Per gross report, the specimen was received in multiple fragments and measured 20cm in aggregate and weighed 352g.

Ben Buelow/Karuna Garg; UCSF

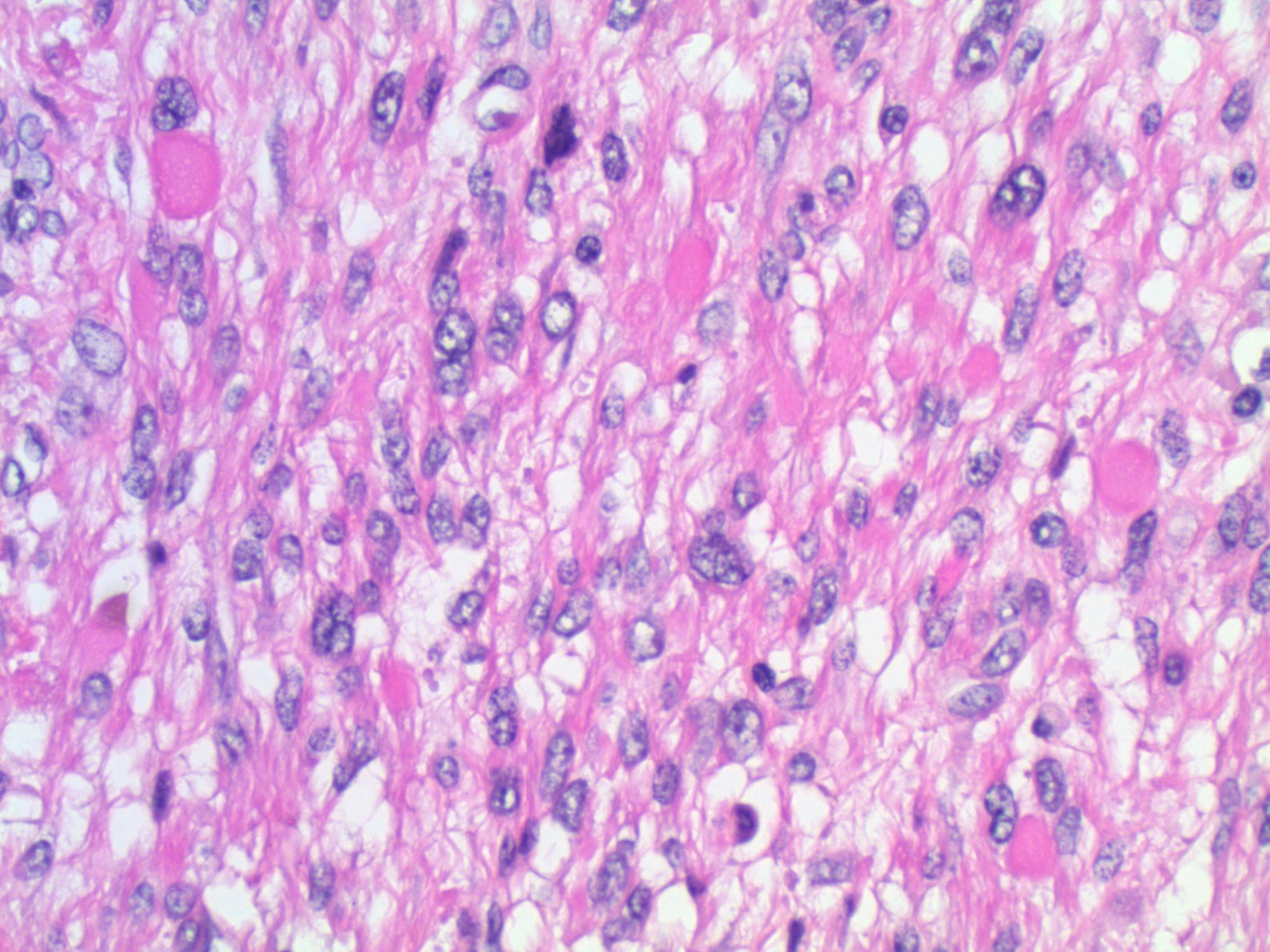




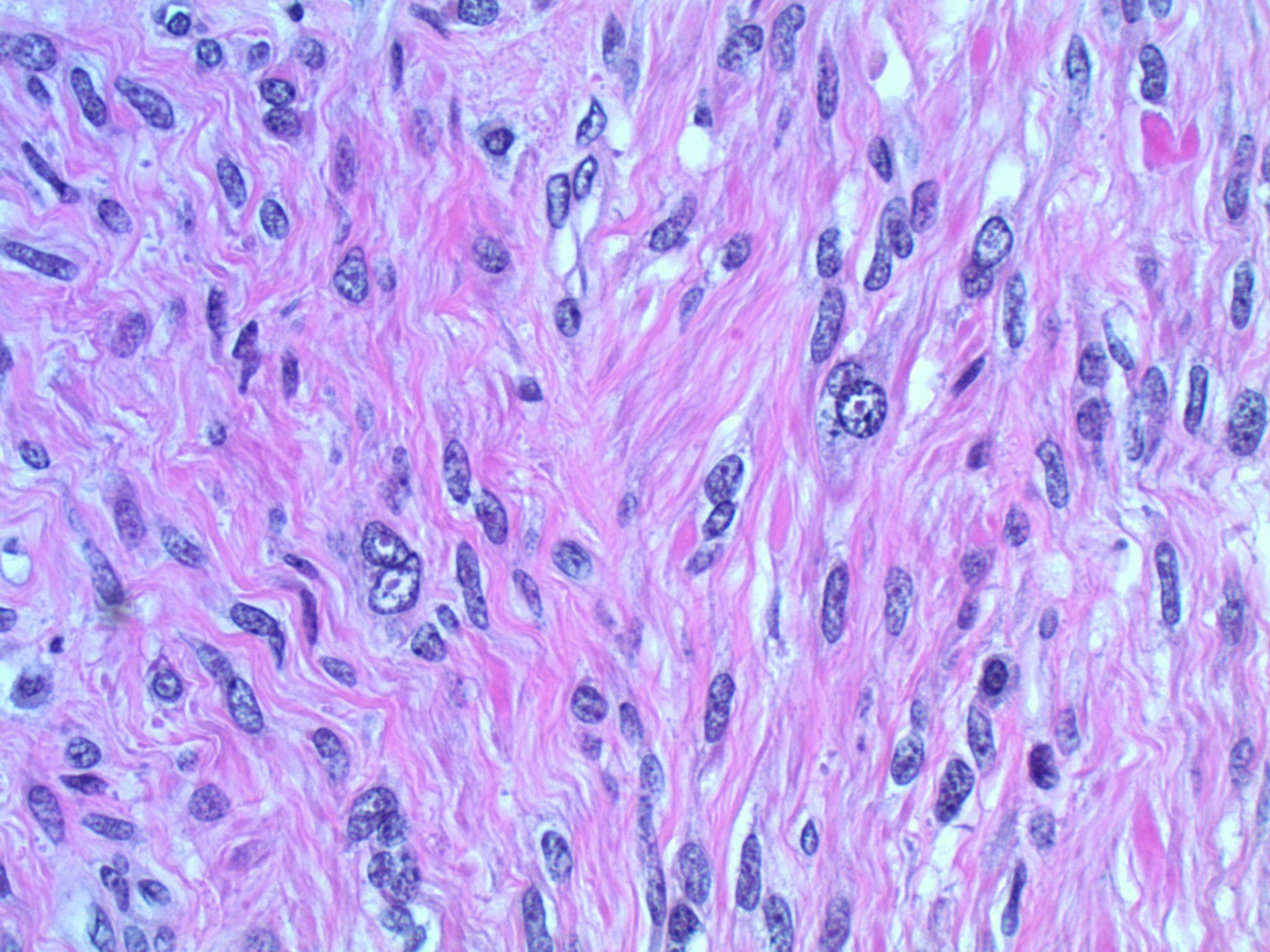




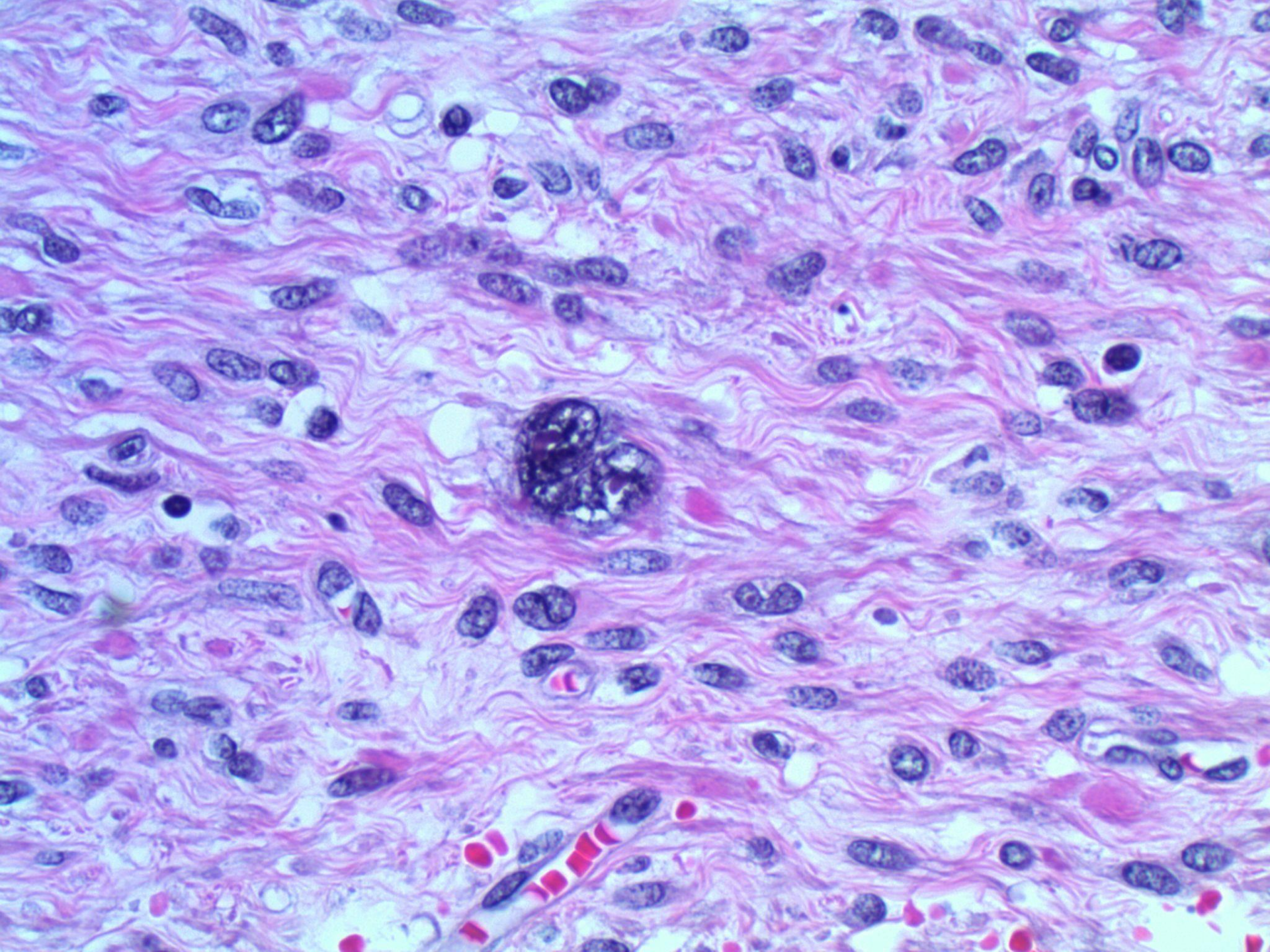












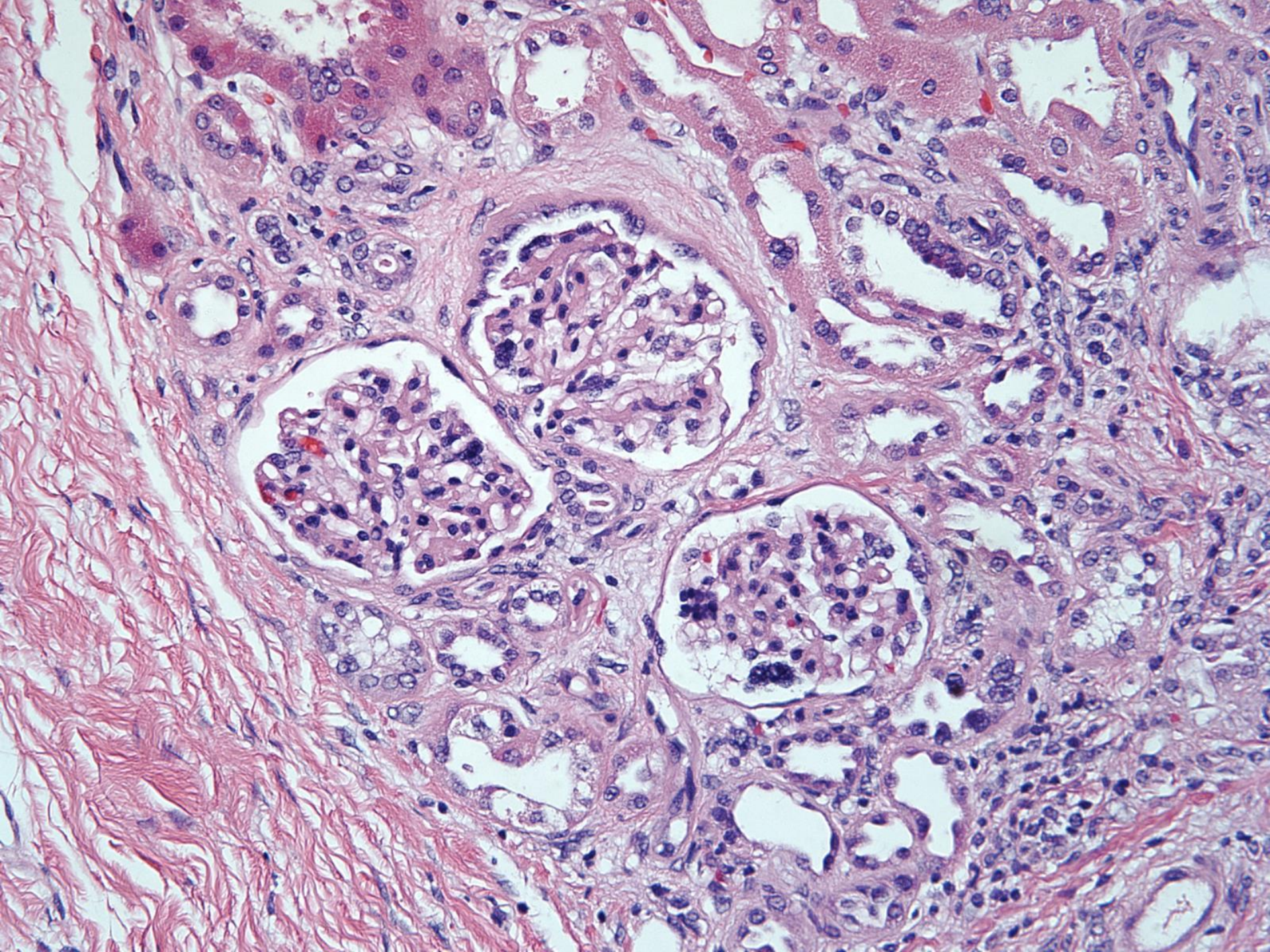


# SB 5879

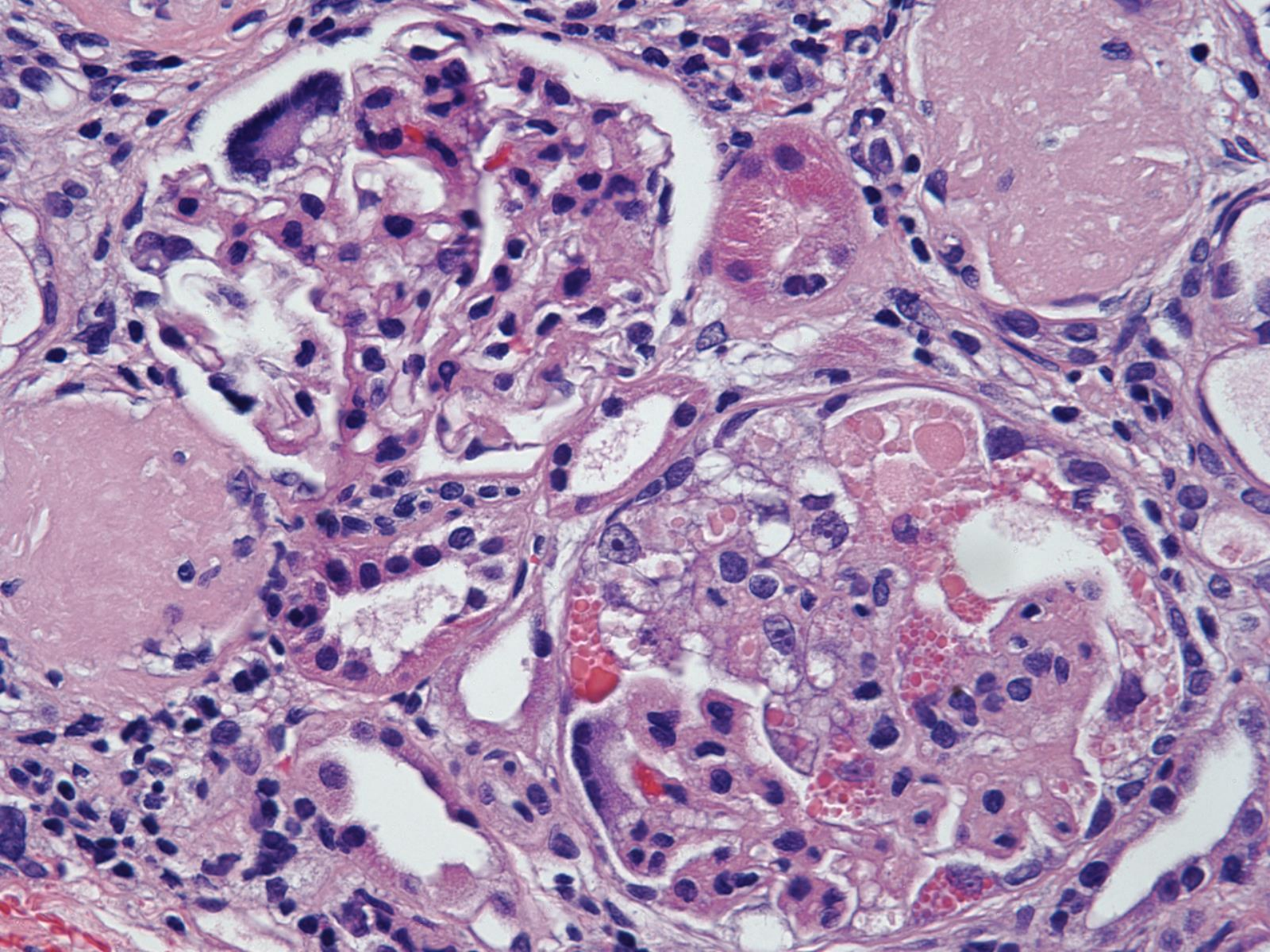
7-year-old male with polyuria.  
Nephrectomy submitted.

Adam Gomez/Richard Sibley; Stanford

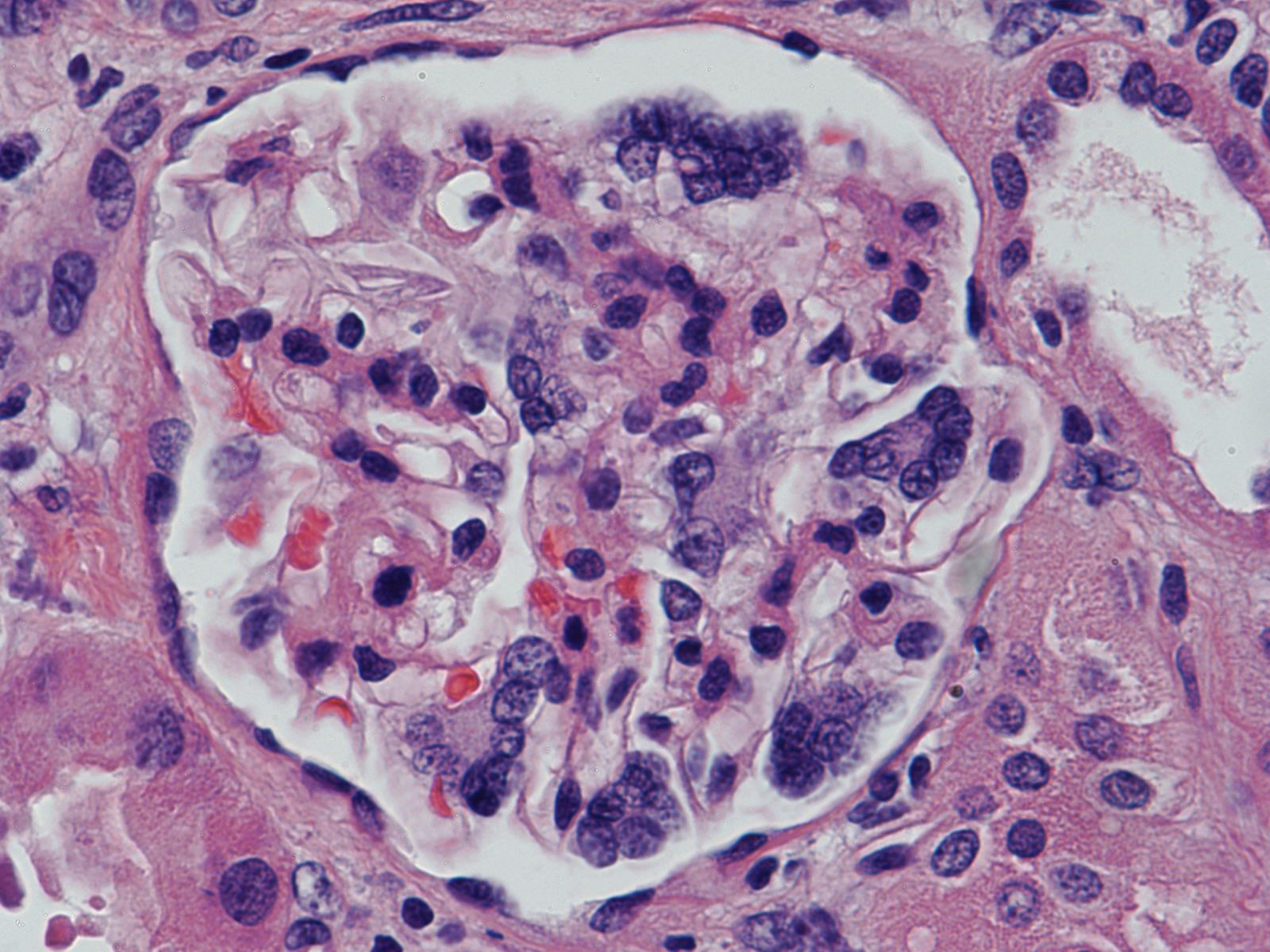




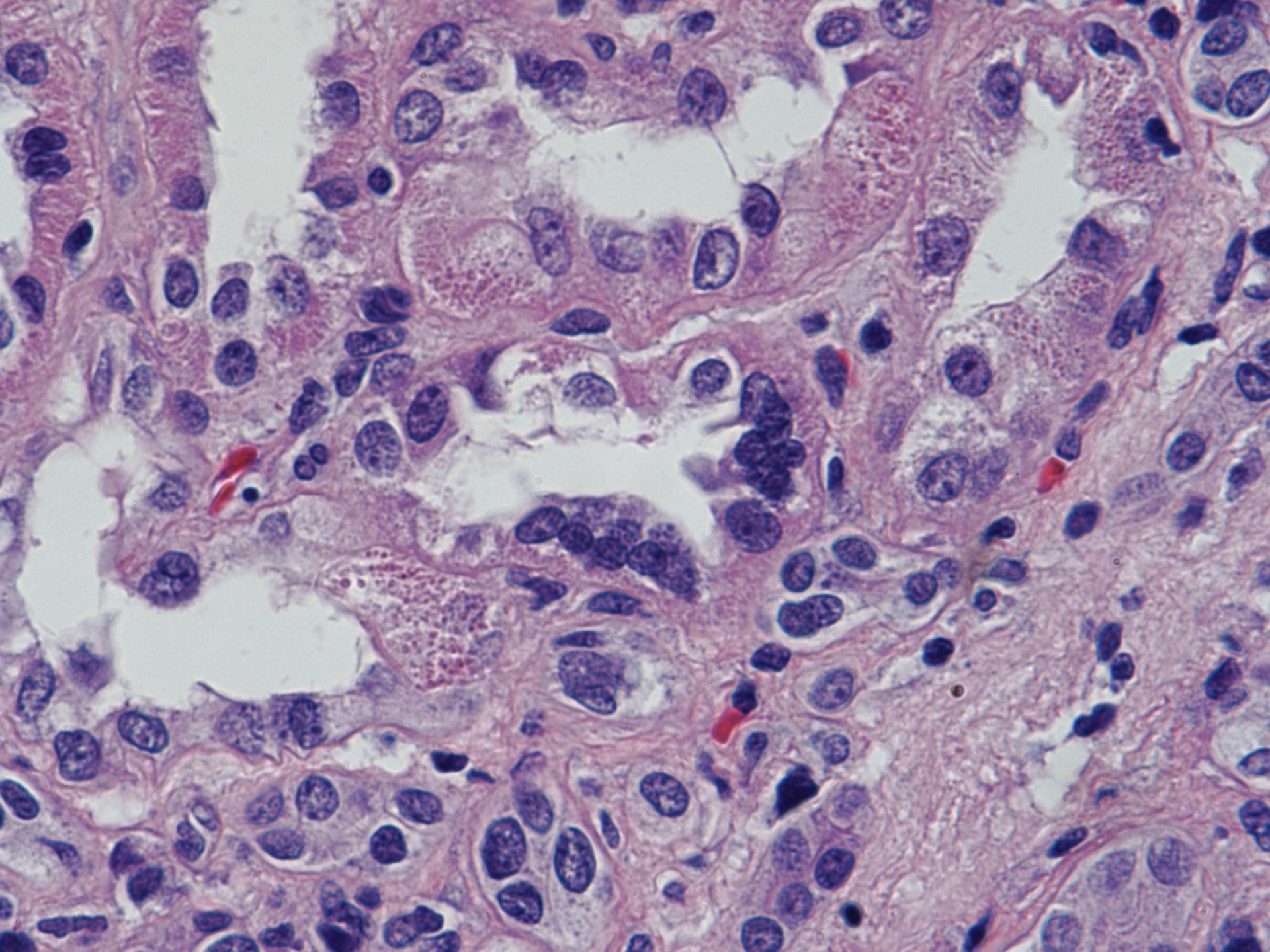




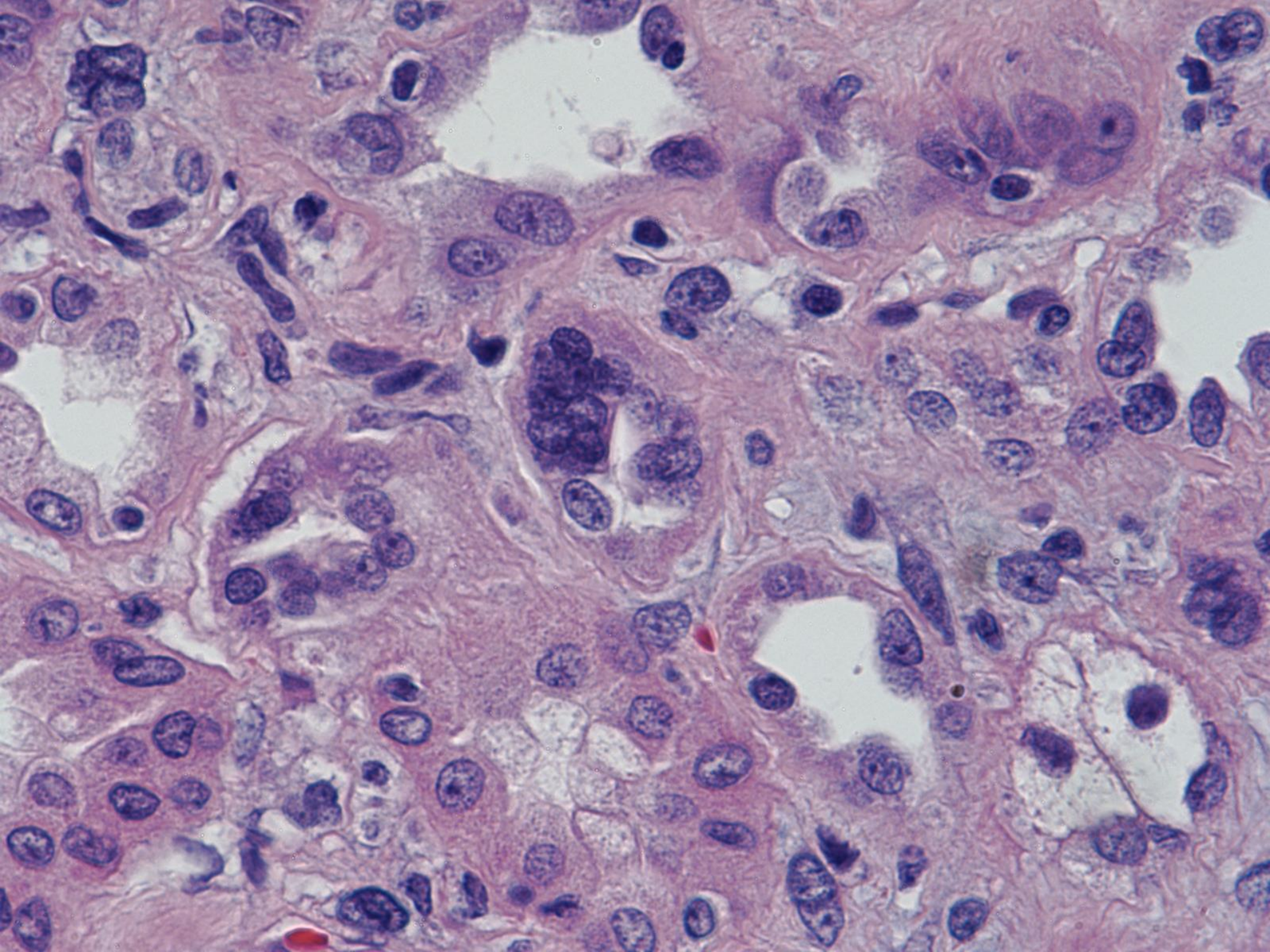




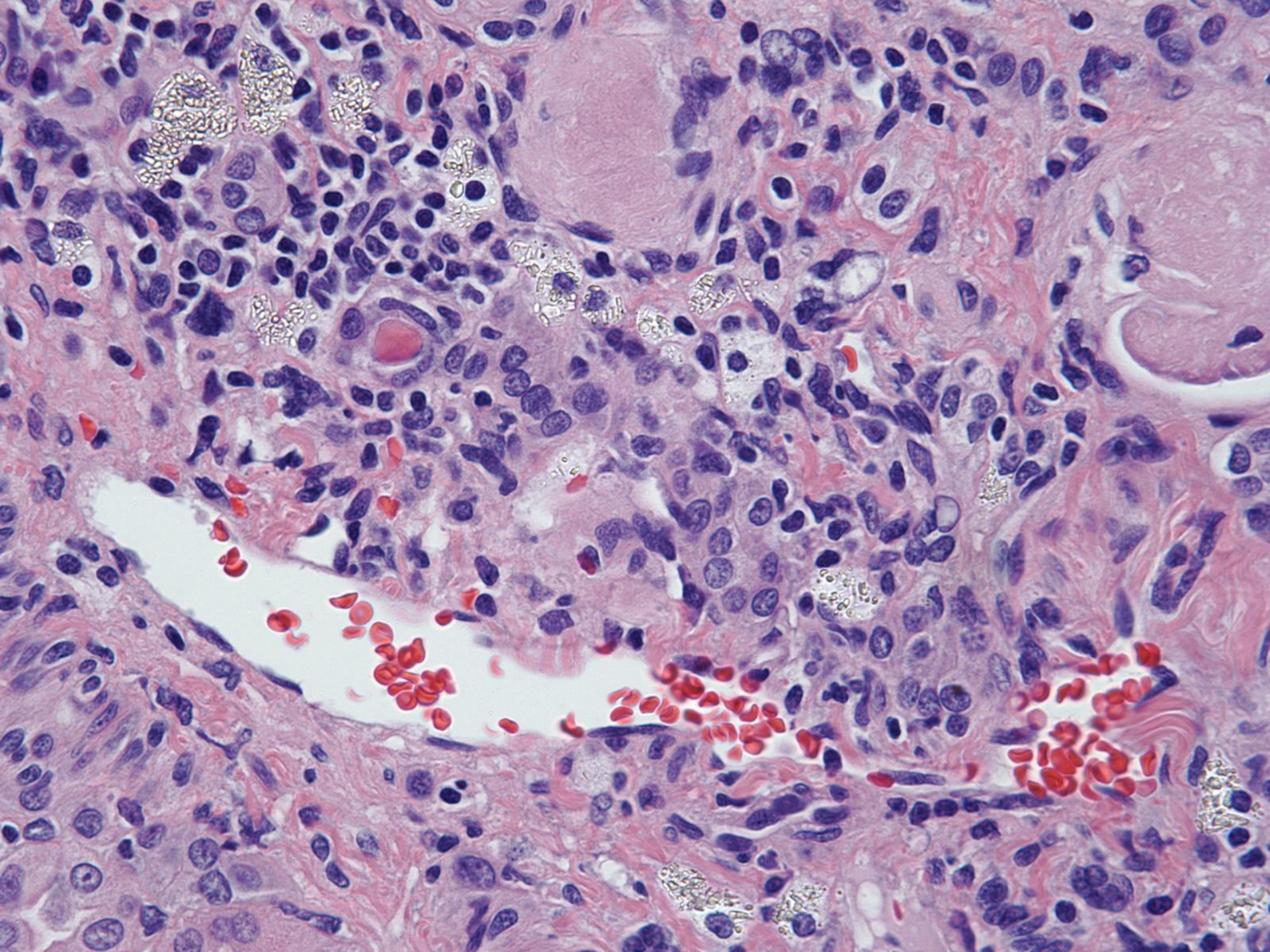




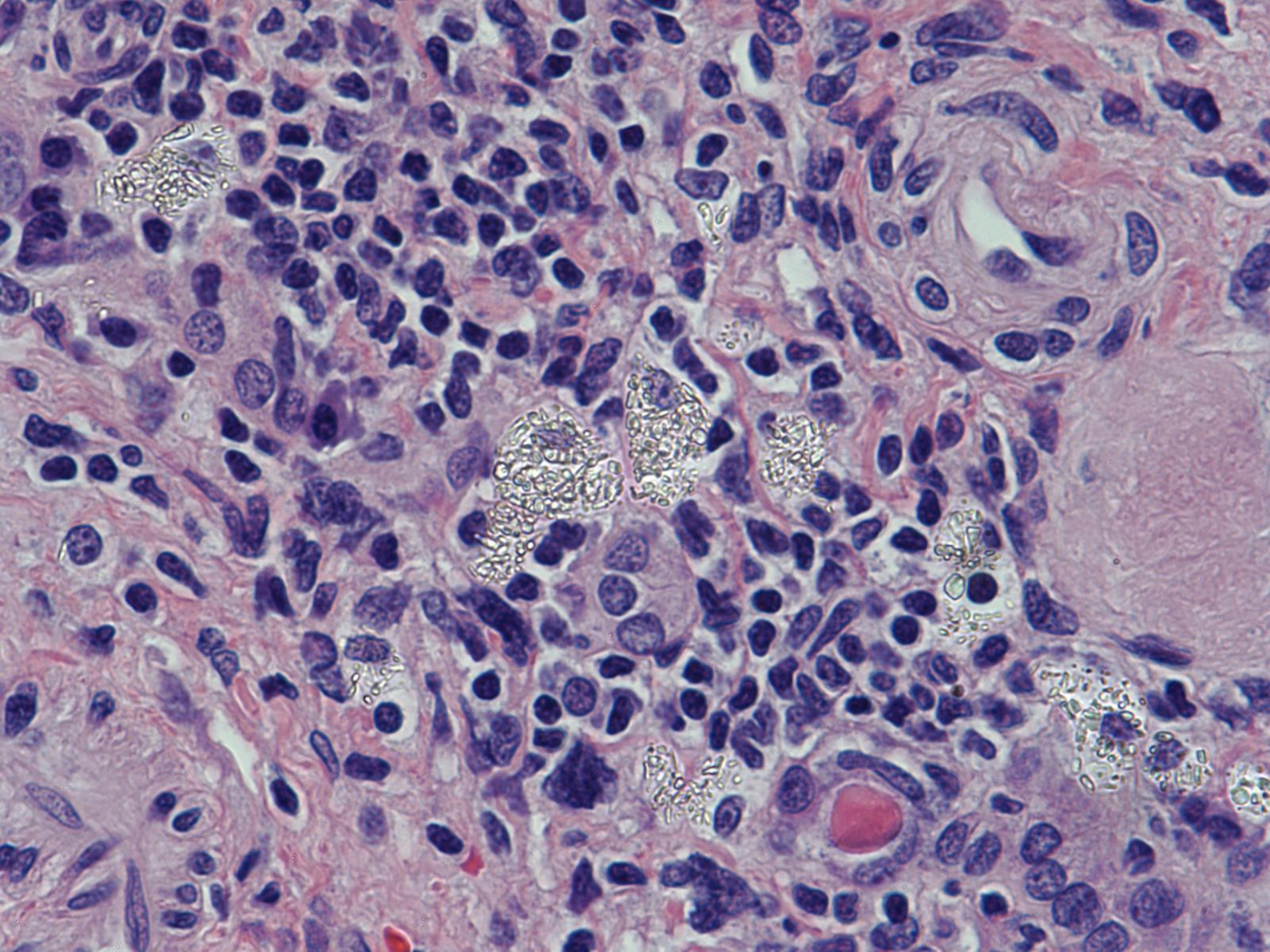














# SB 5880

29-year-old man with hand mass. Excision submitted.

Adam Gomez/Richard Kempson/Florette Hazard;  
Stanford











