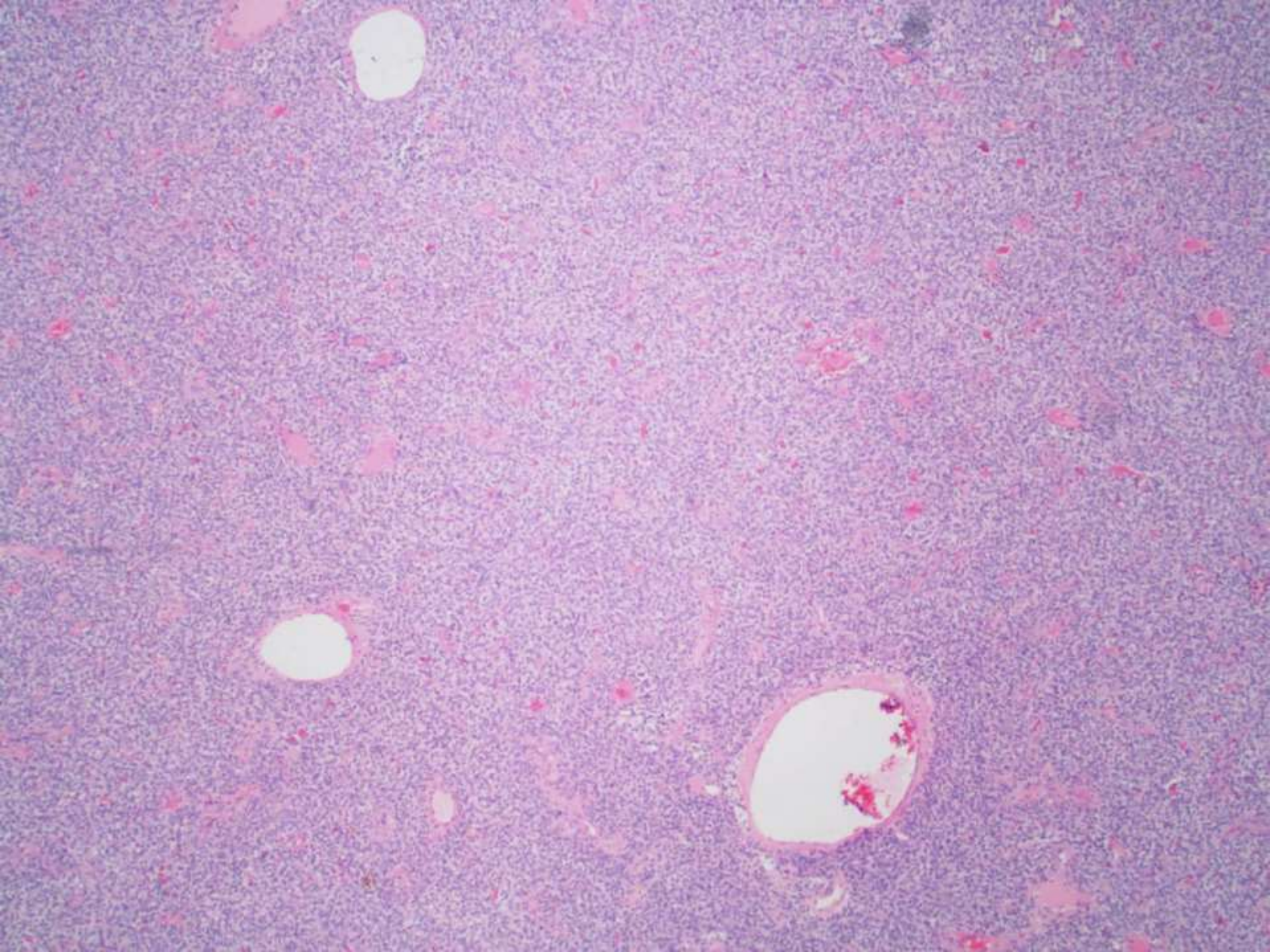


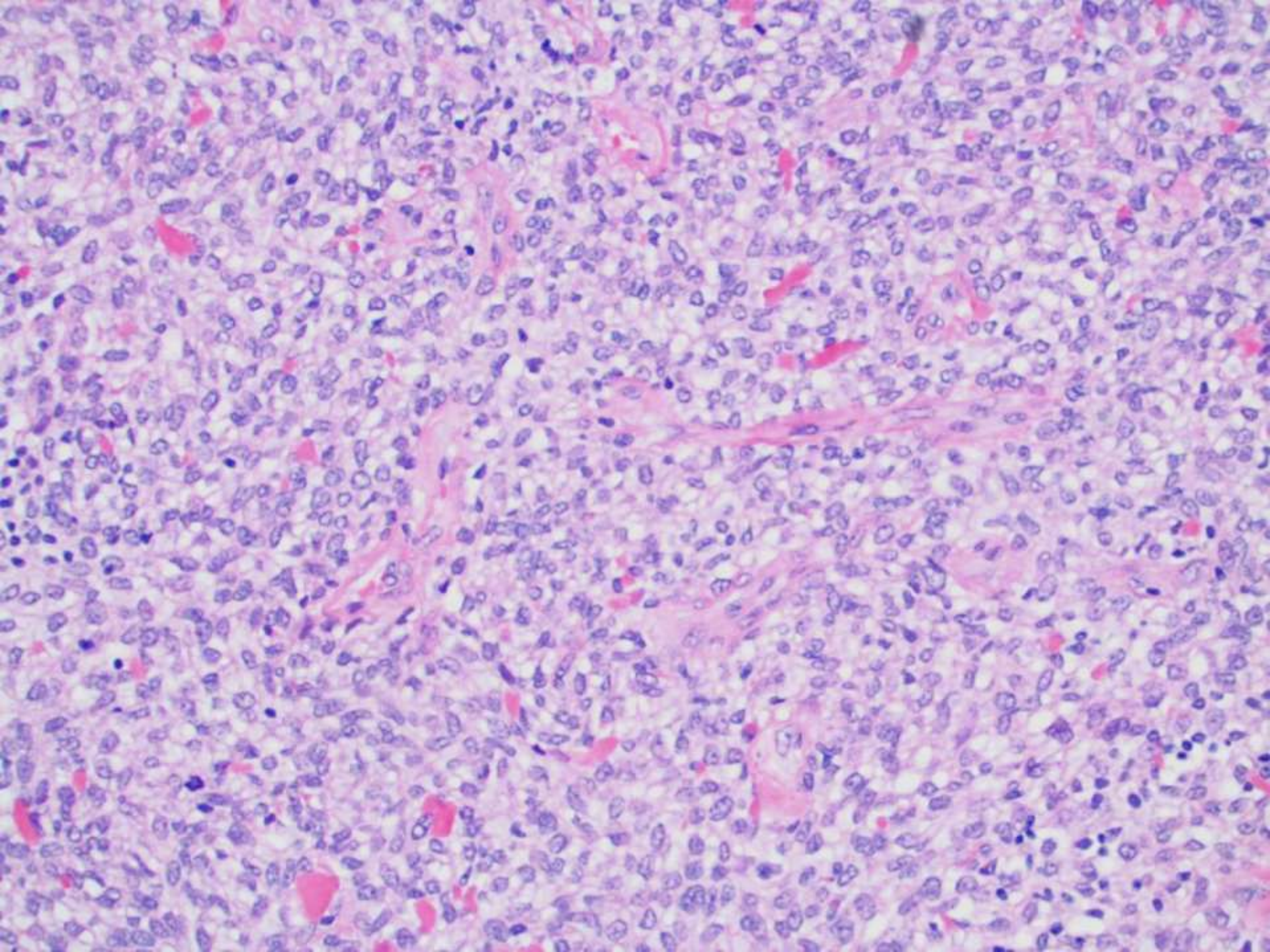
South Bay Pathology Society

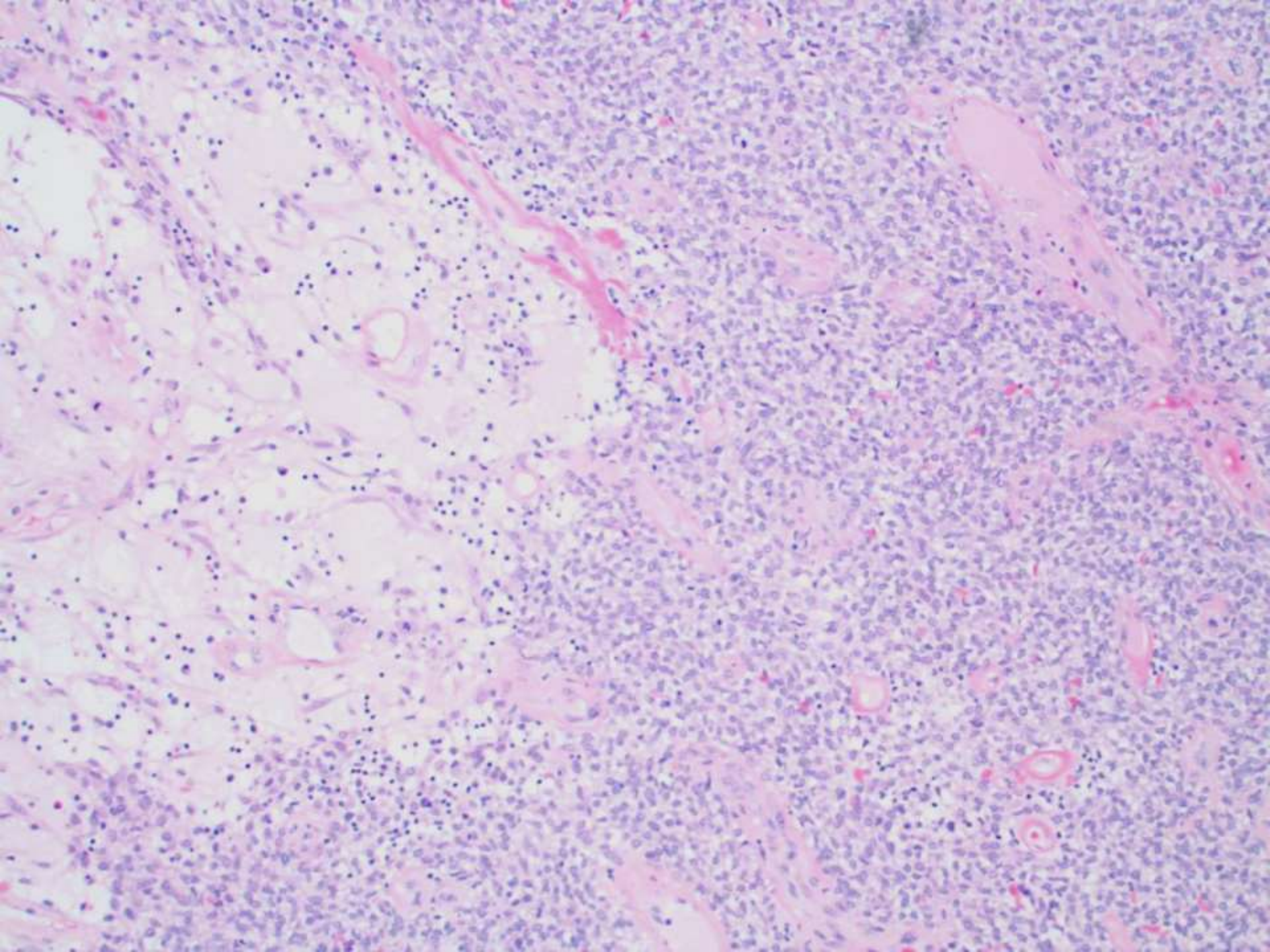
September 2014

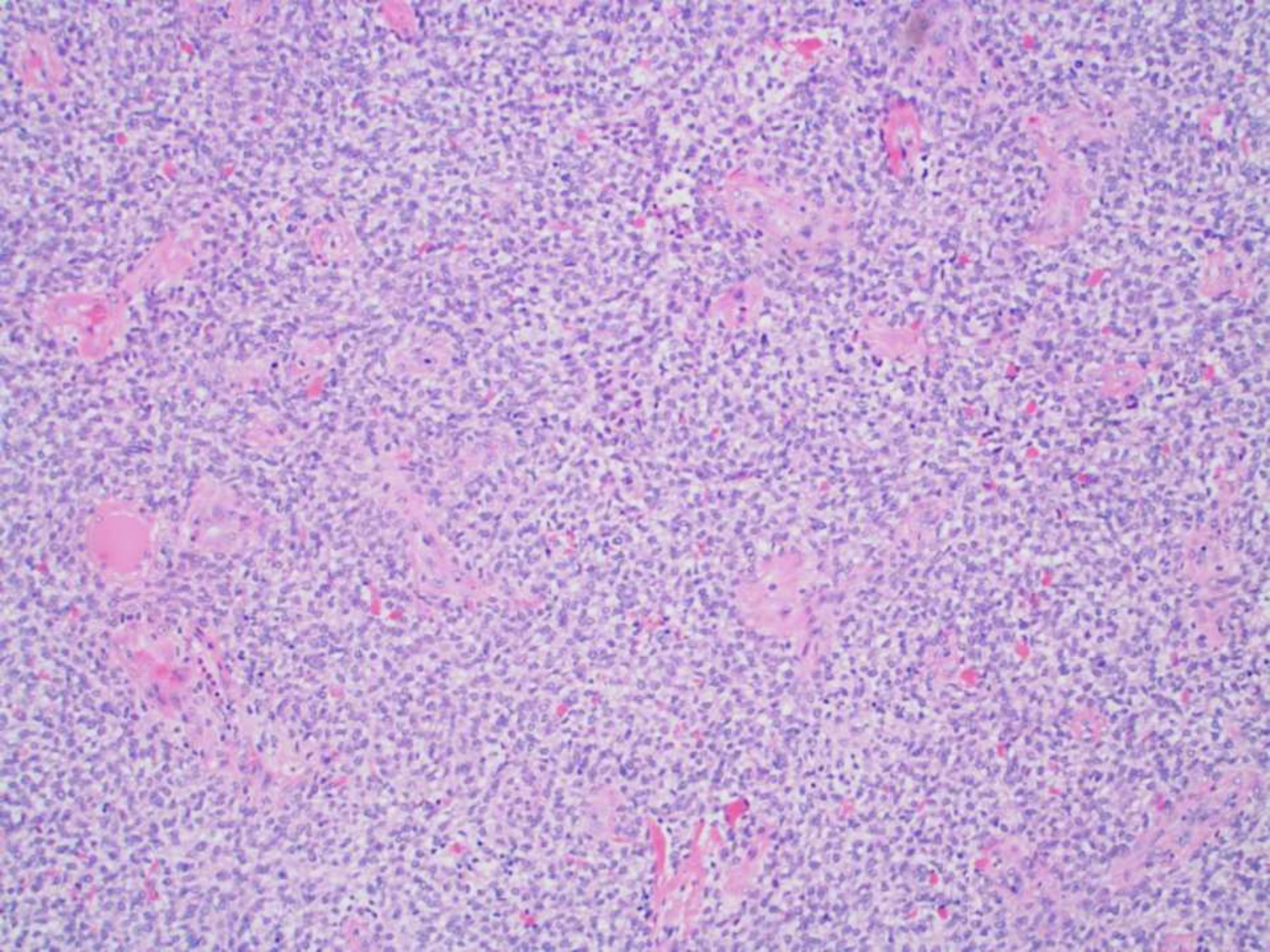
SB 5861

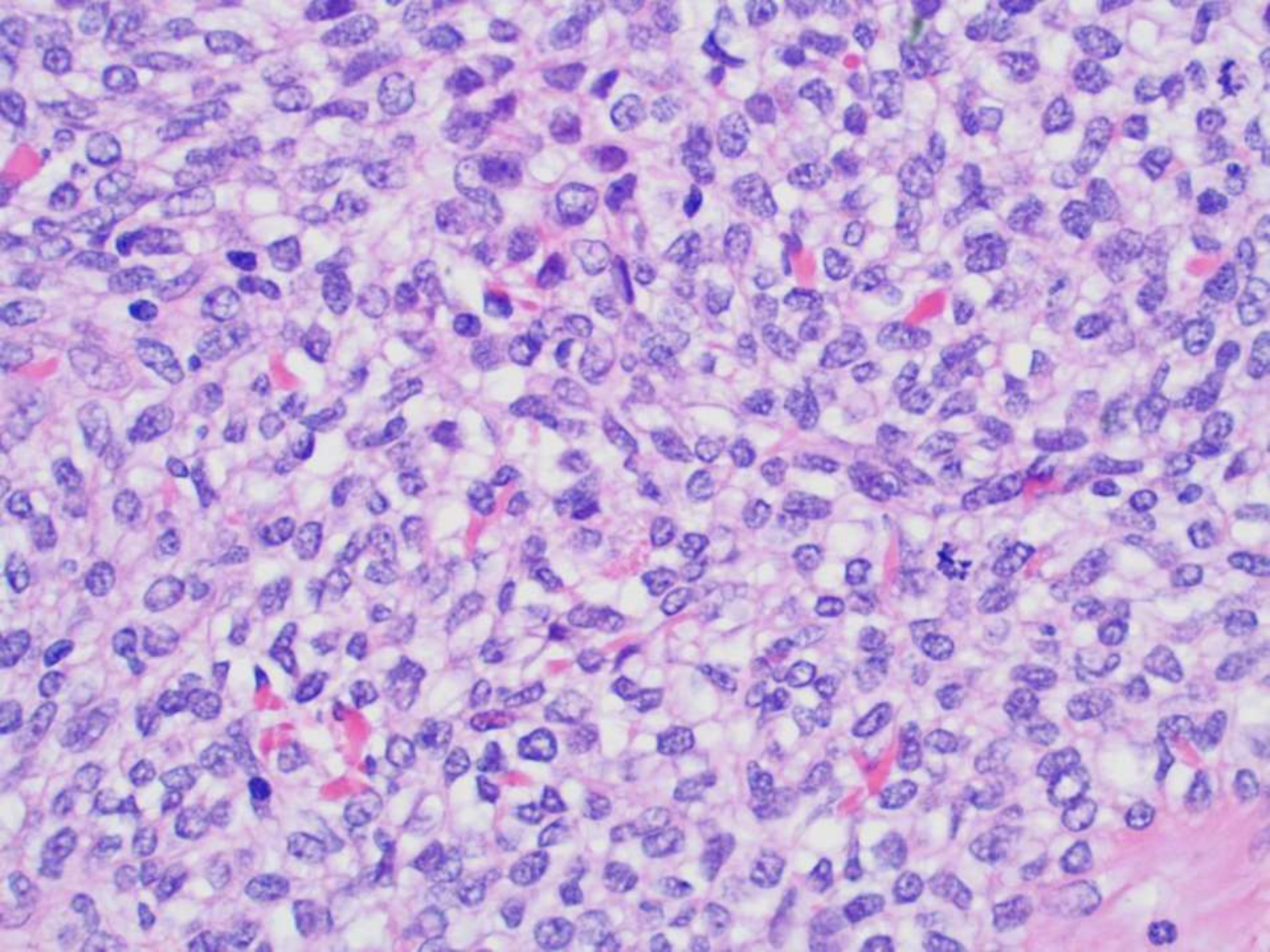
- 53-year-old woman with diffuse pelvic and intra-abdominal masses. Four years earlier she underwent resection of a pelvic mass diagnosed as ovarian granulosa cell tumor. Decades ago she underwent hysterectomy for benign indications. The current masses are tan, solid, and rubbery.

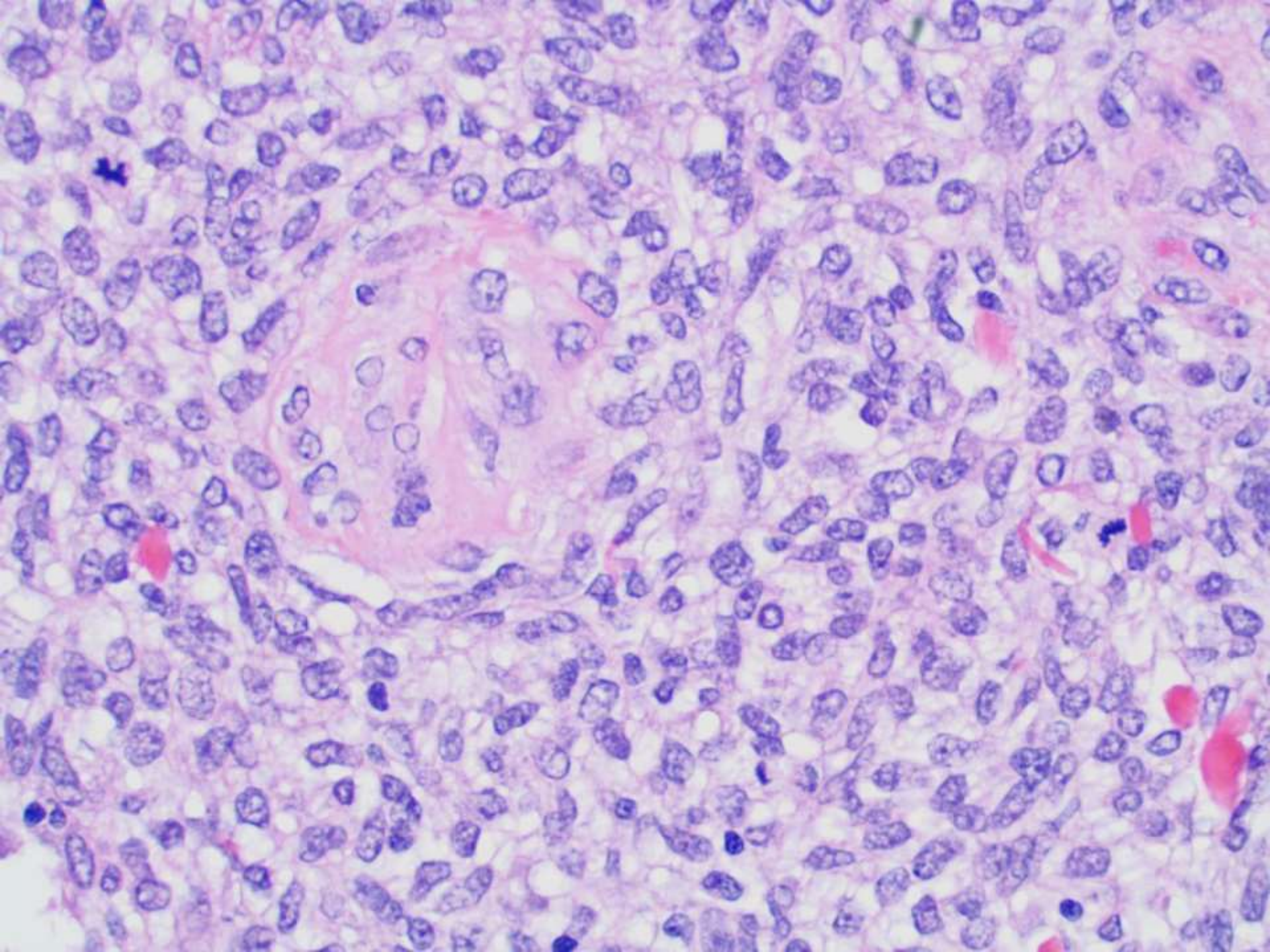






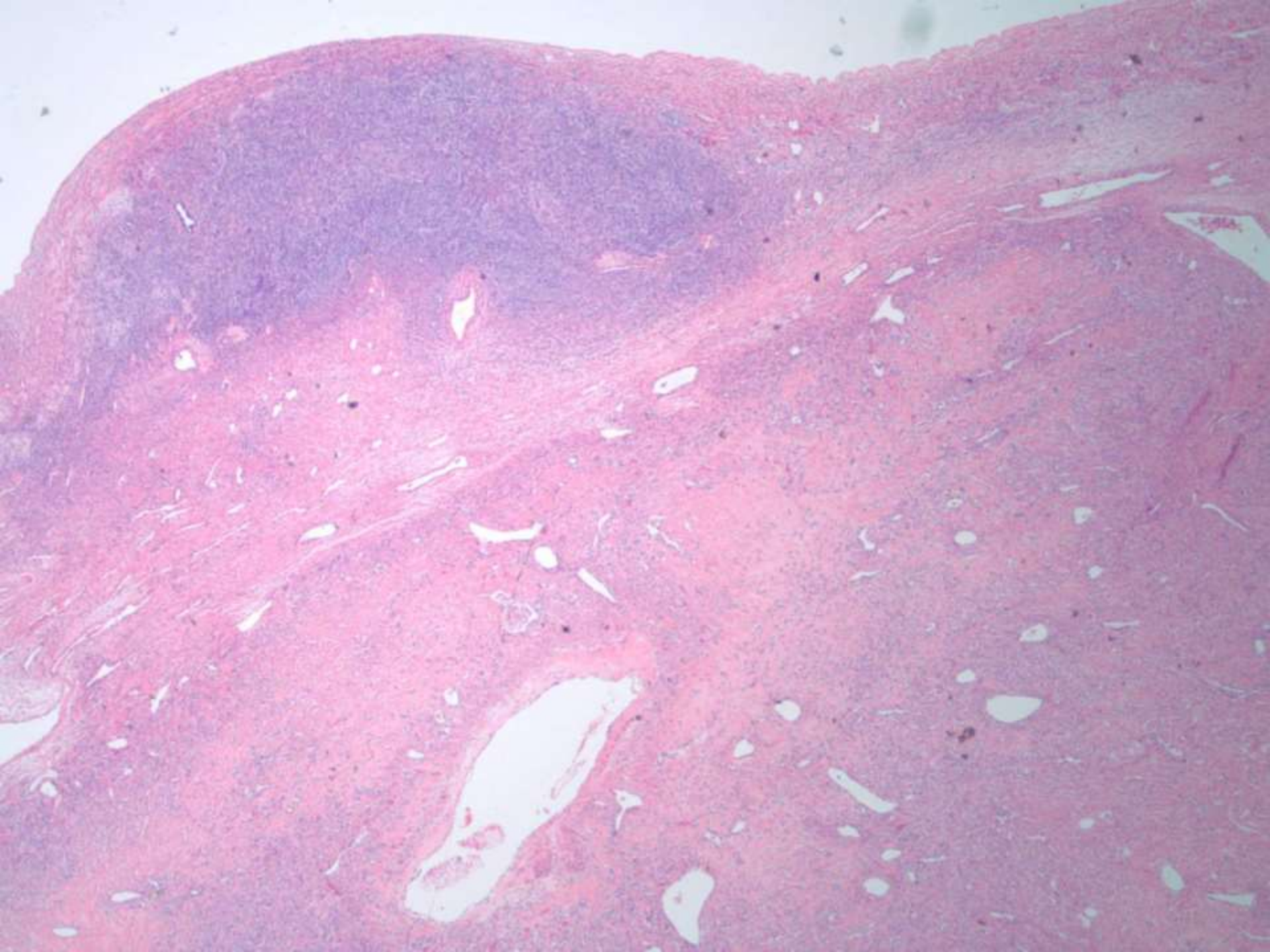


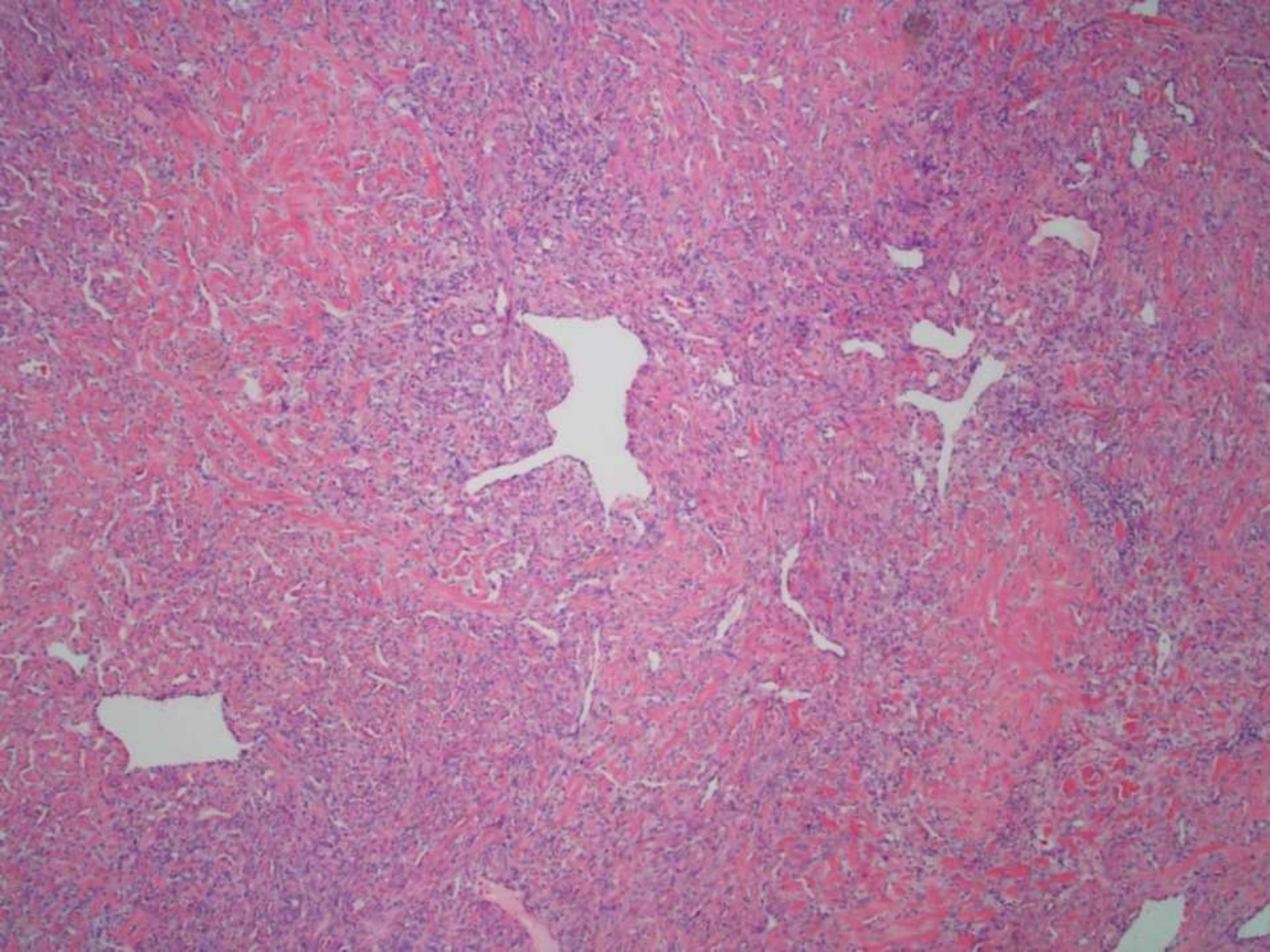


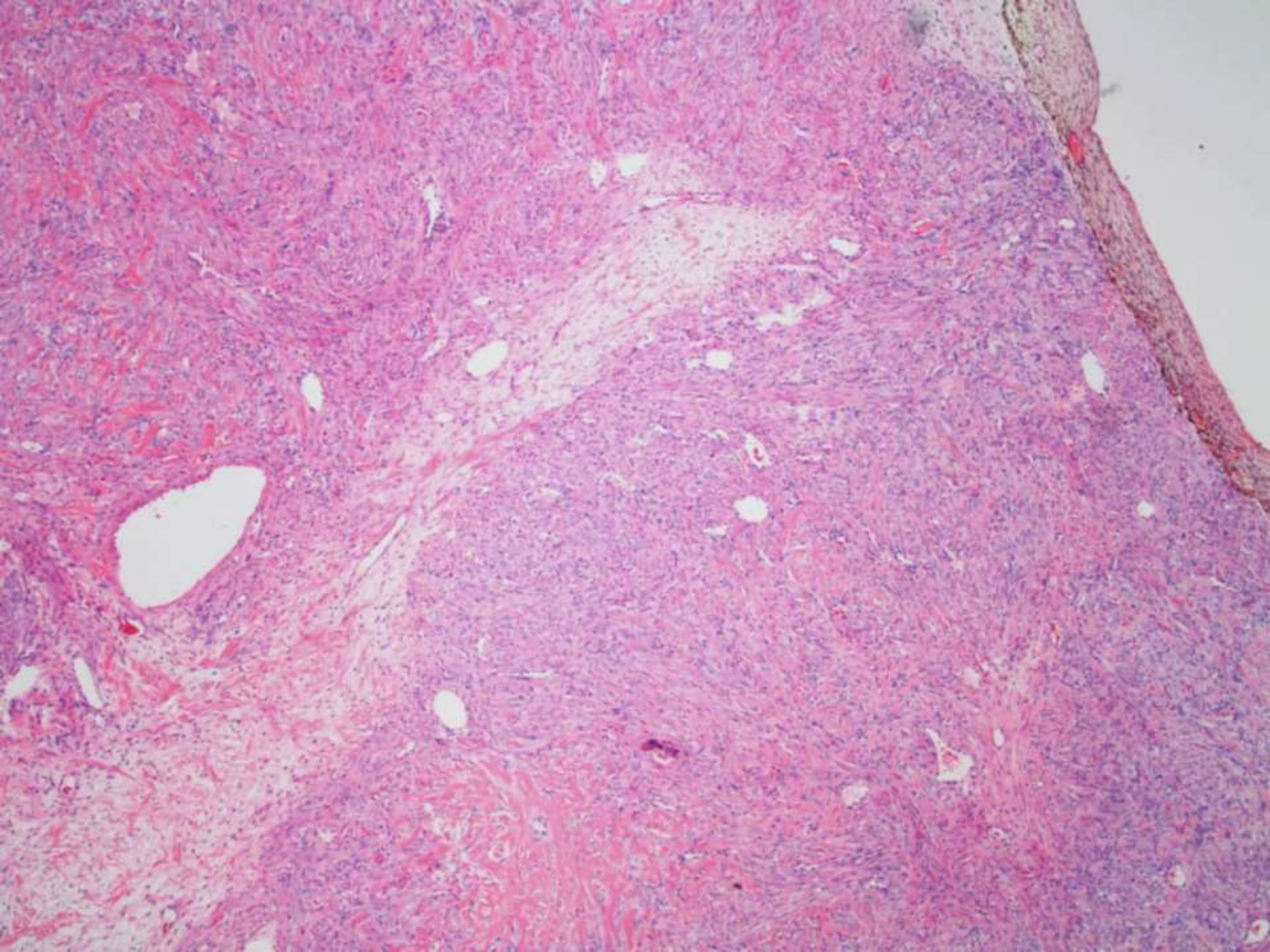


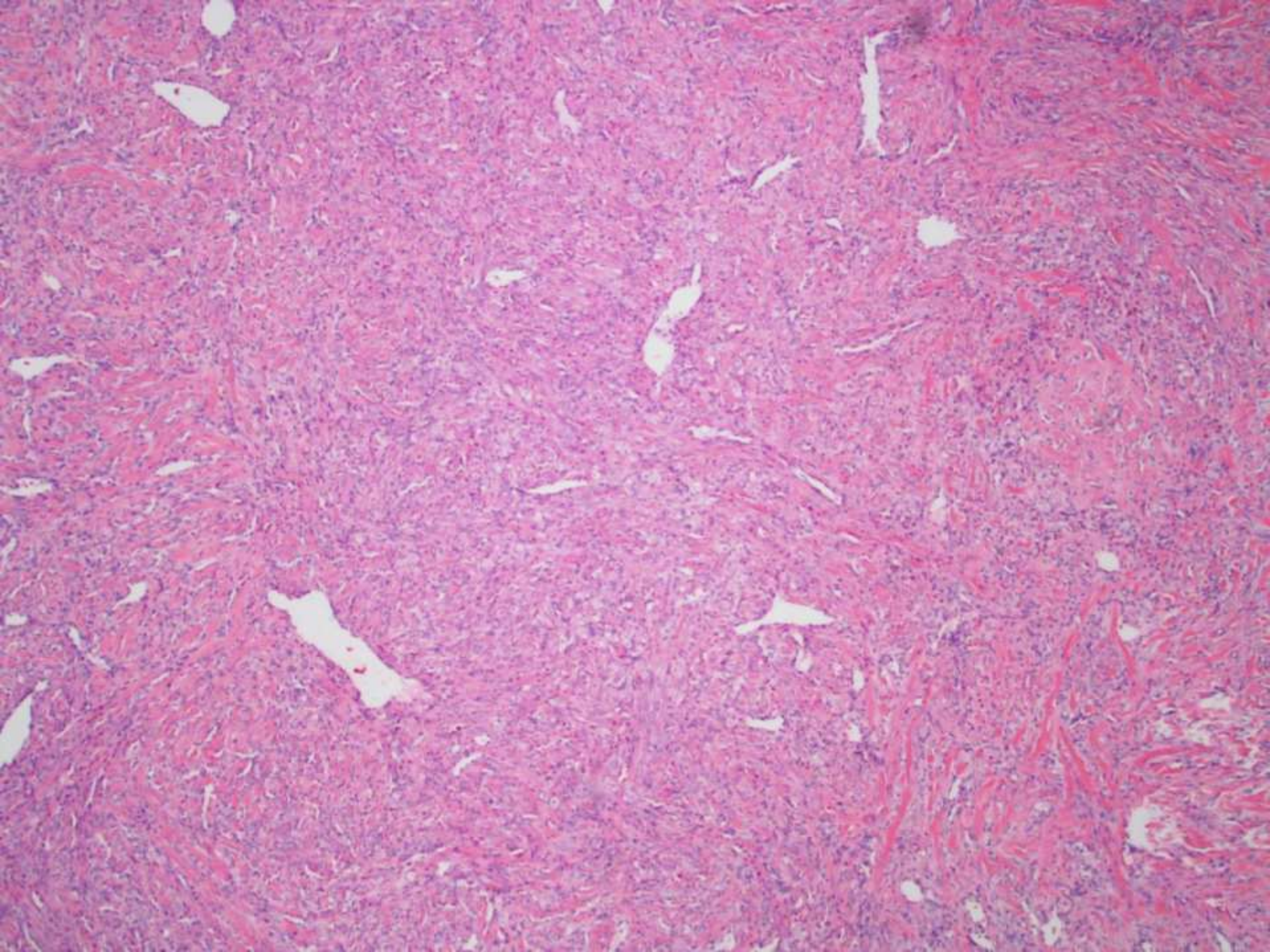
SB 5862

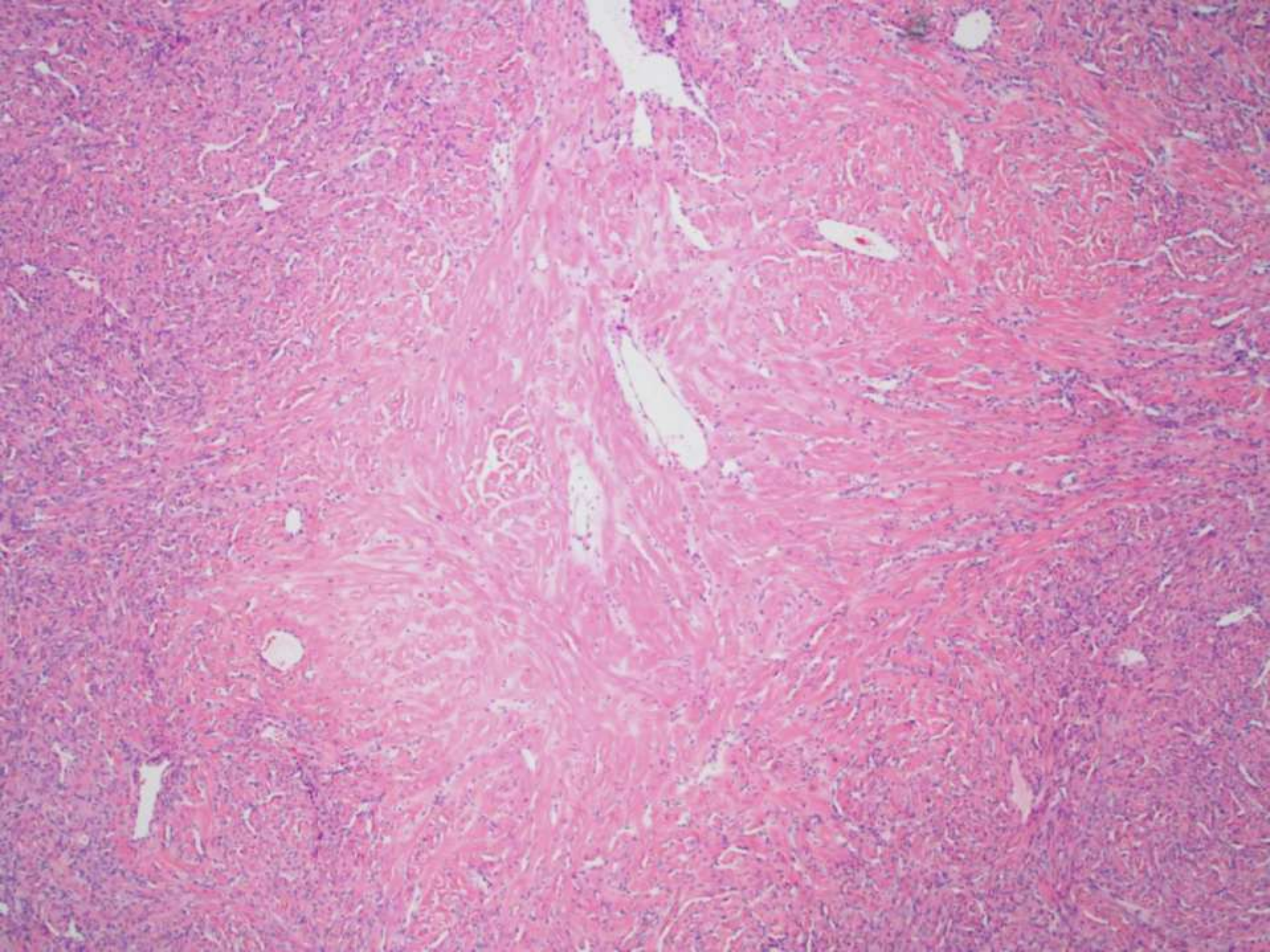
- 56-year-old woman with 2cm yellow-orange, solid rubbery ovarian mass found during hysterectomy for leiomyomas.

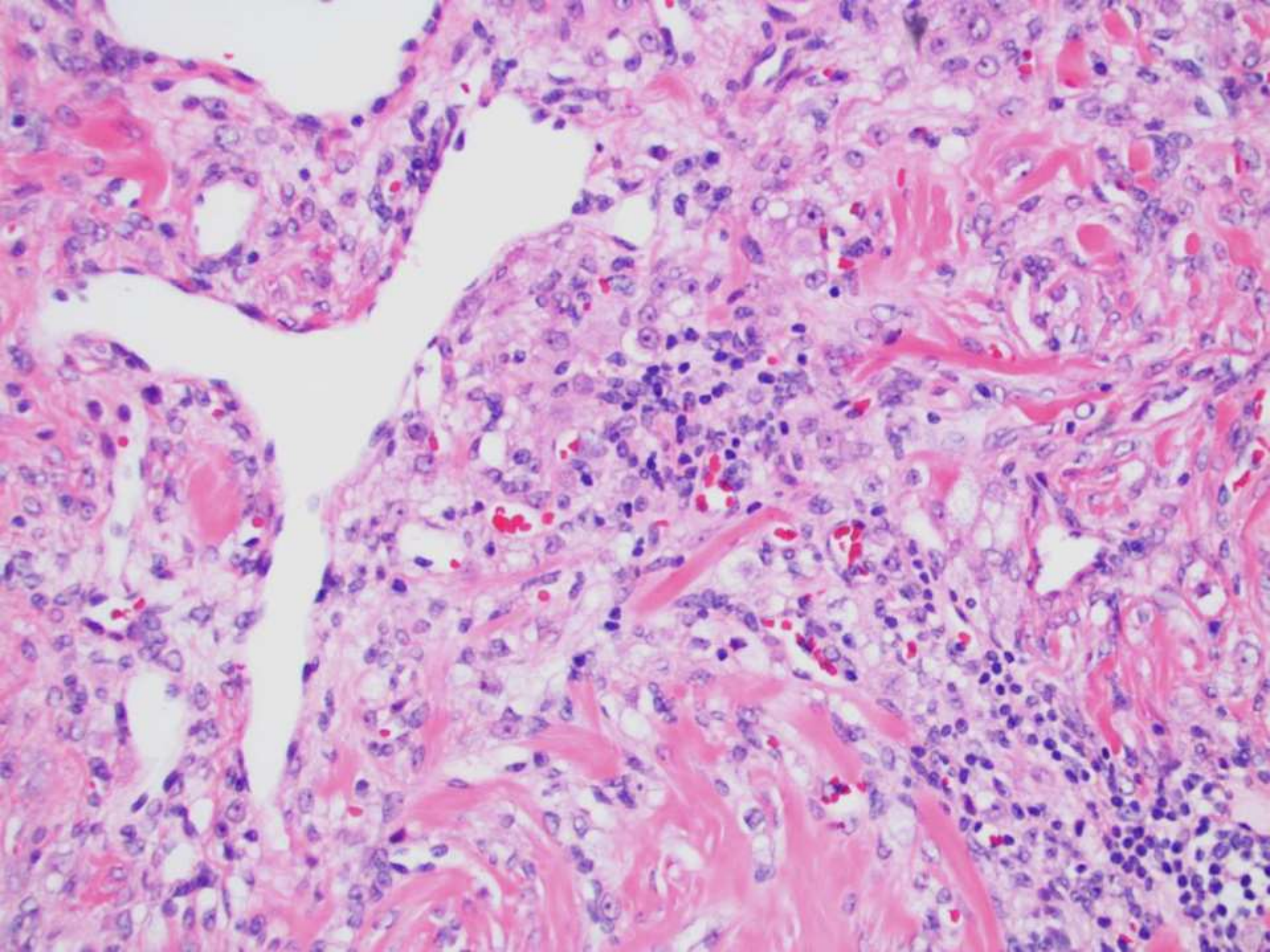


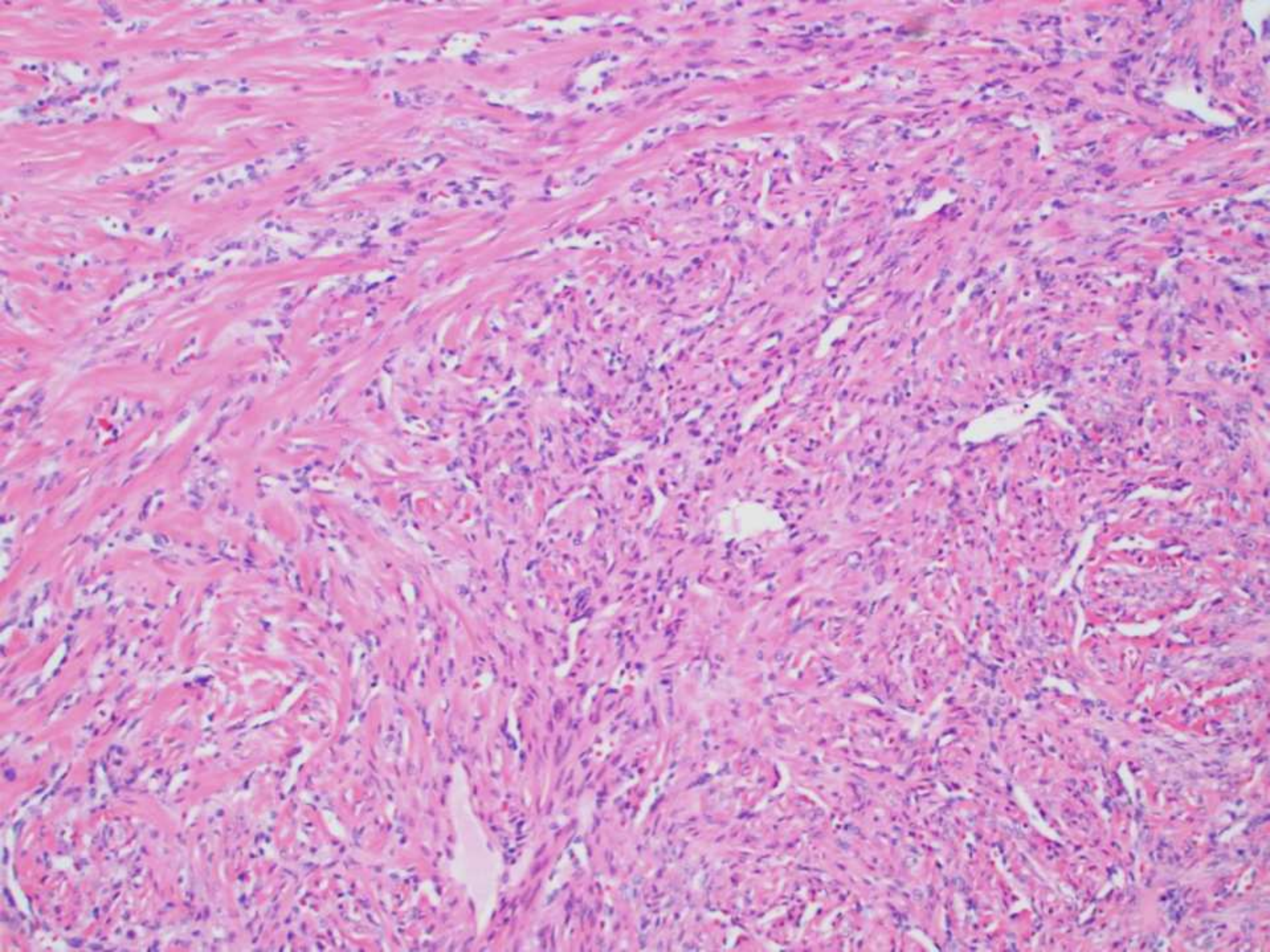


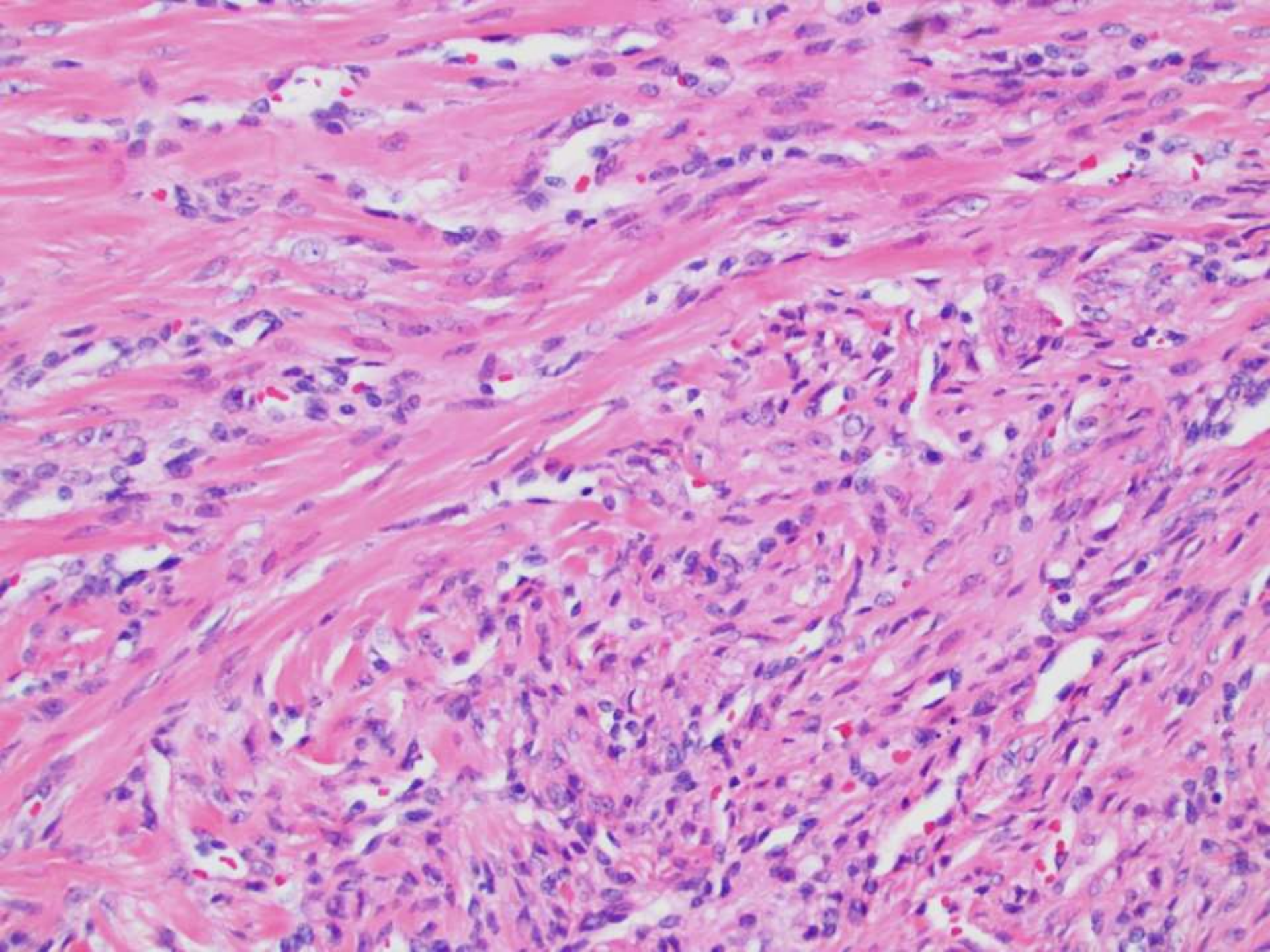






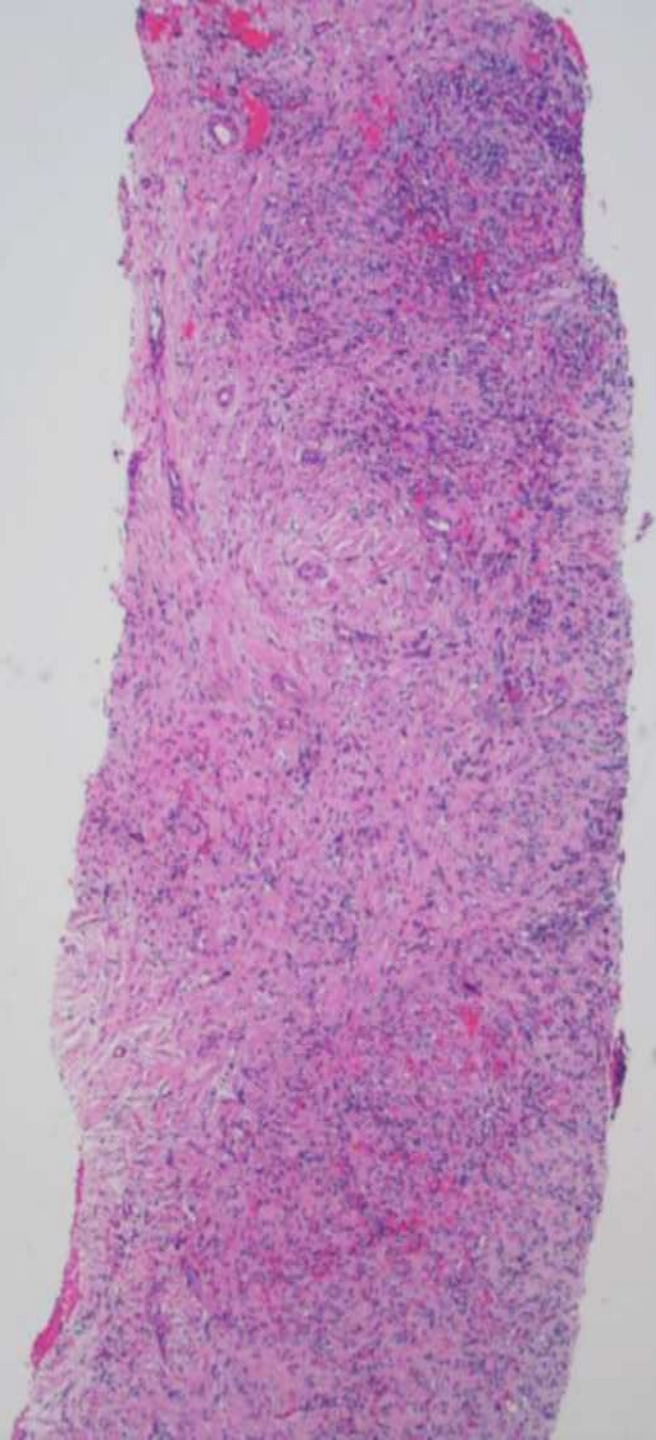
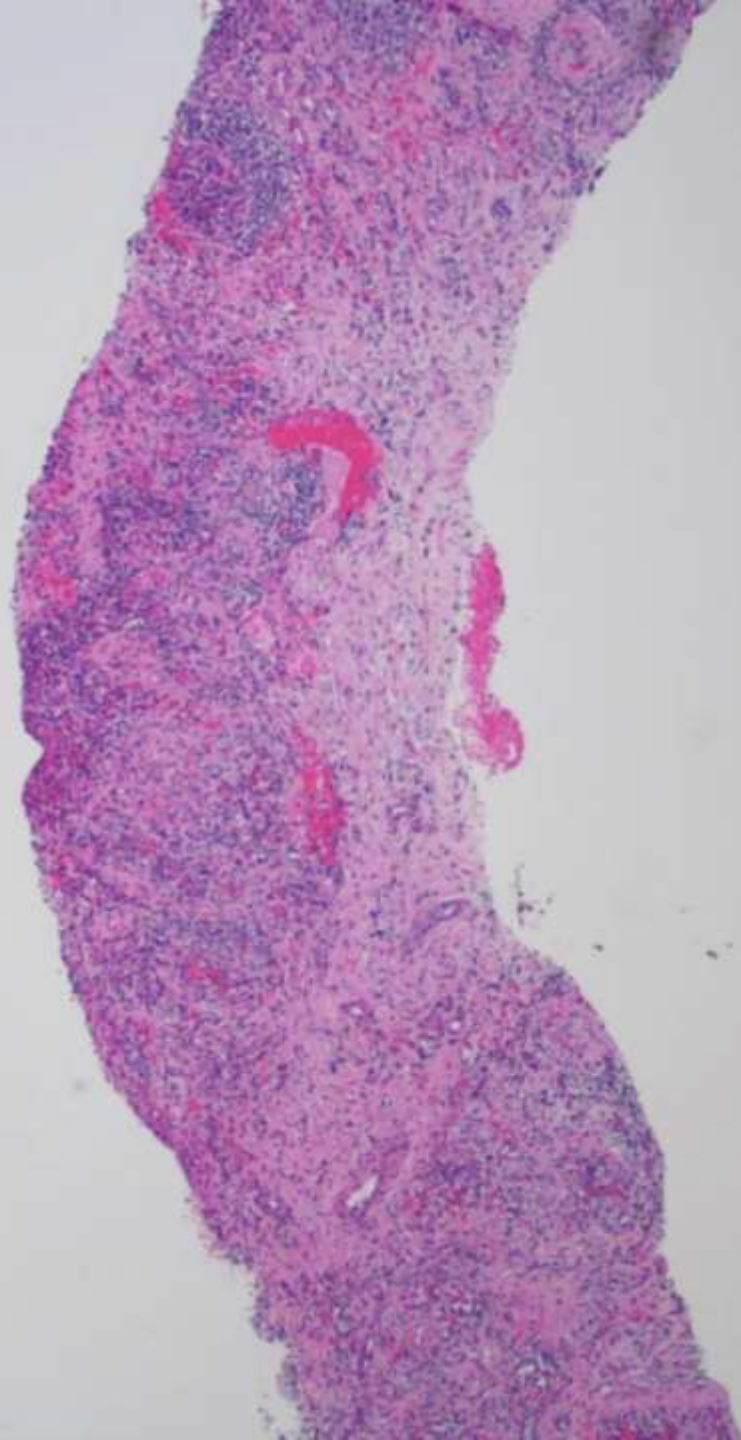


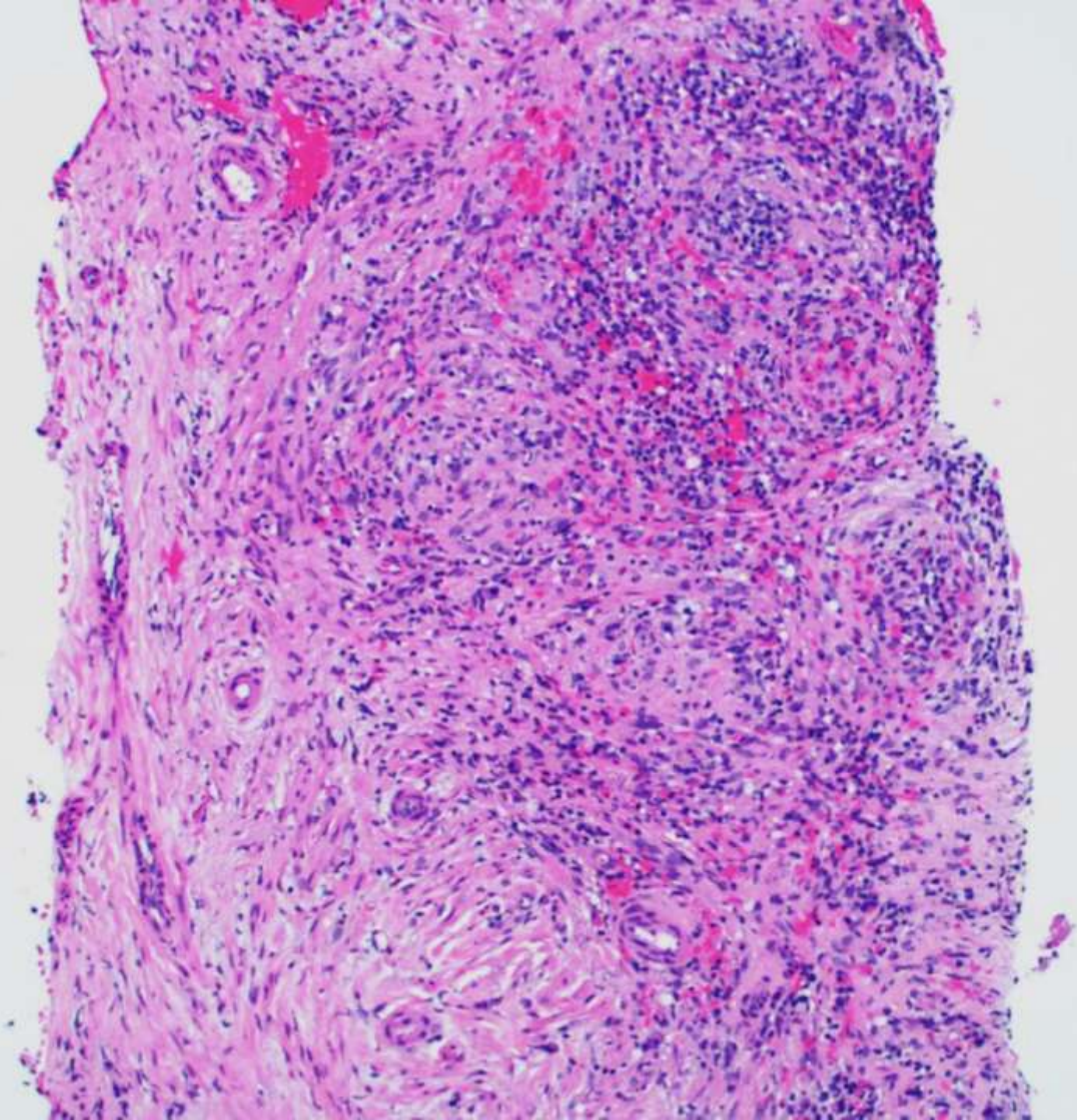


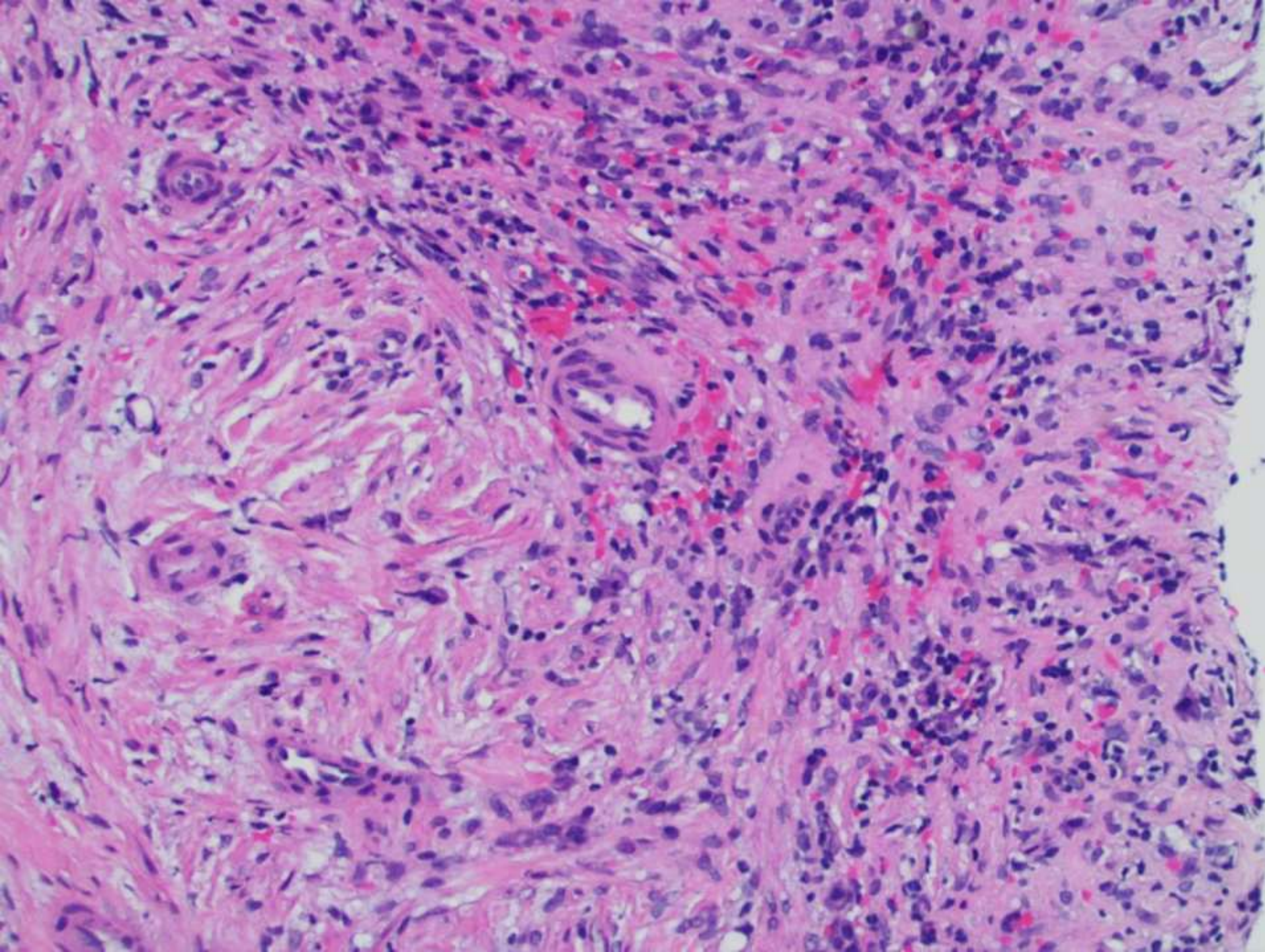


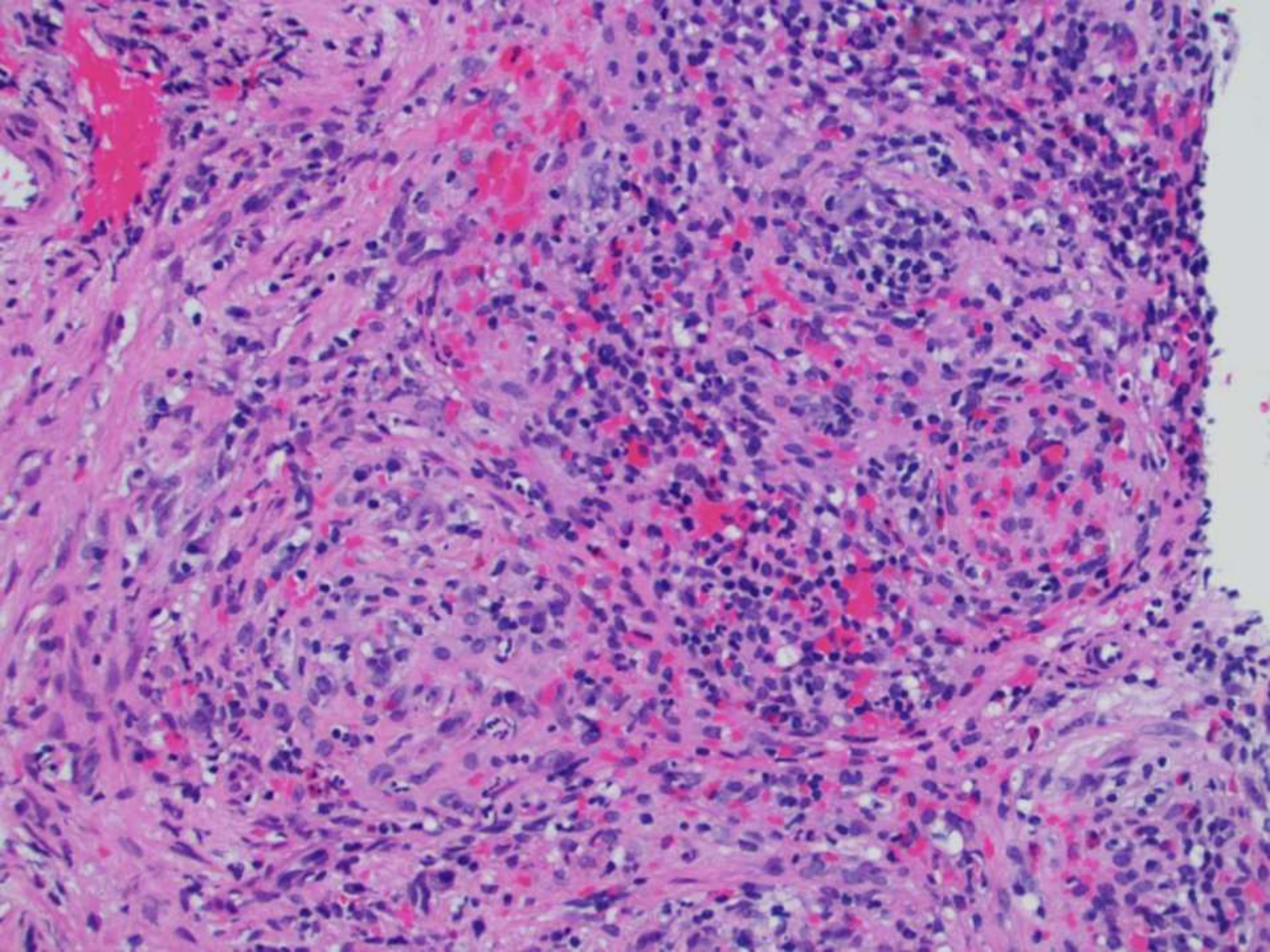
SB 5863

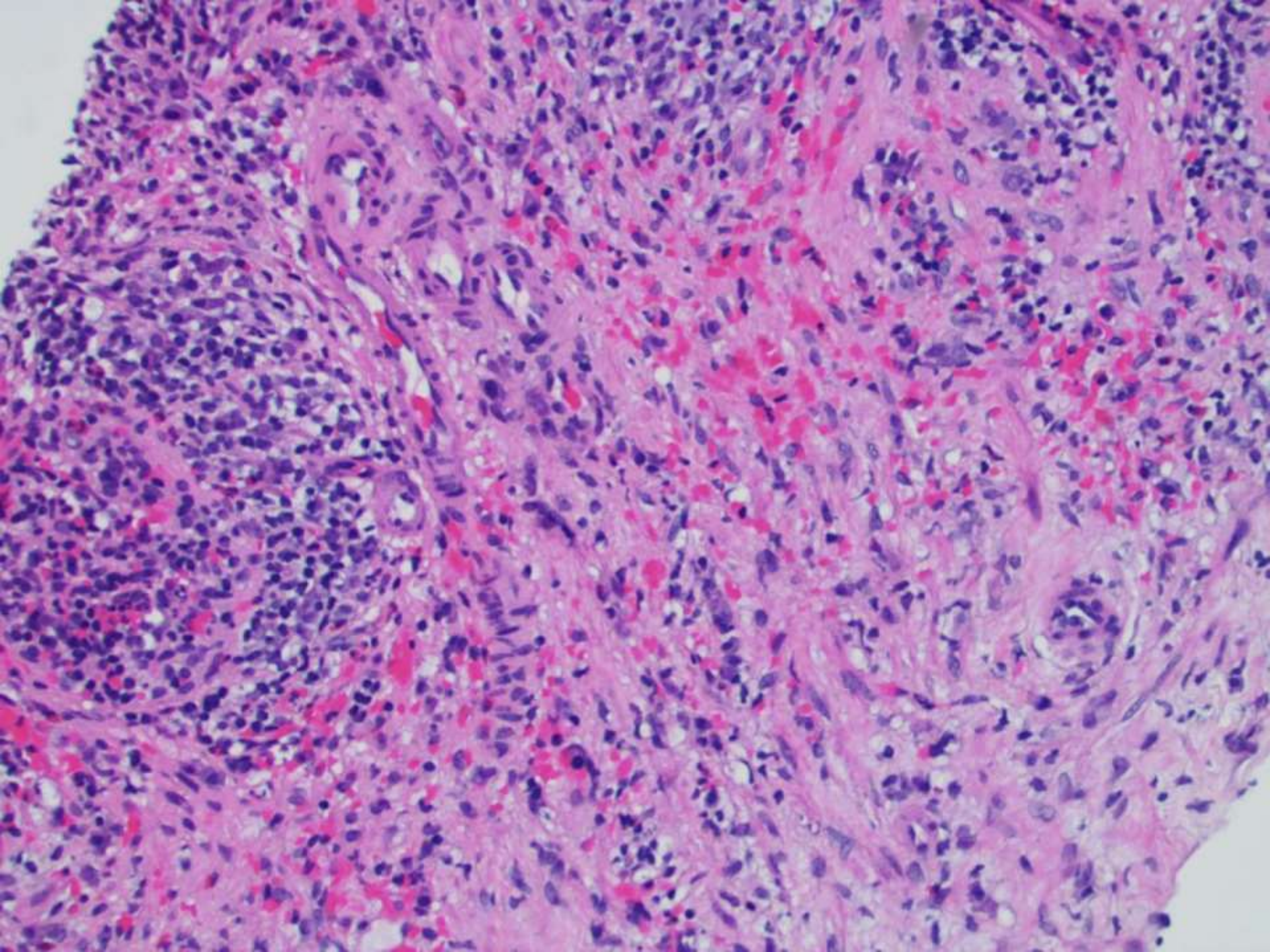
- 50-year-old woman with recent weight loss and abdominal pain, found to have splenic mass on CT.

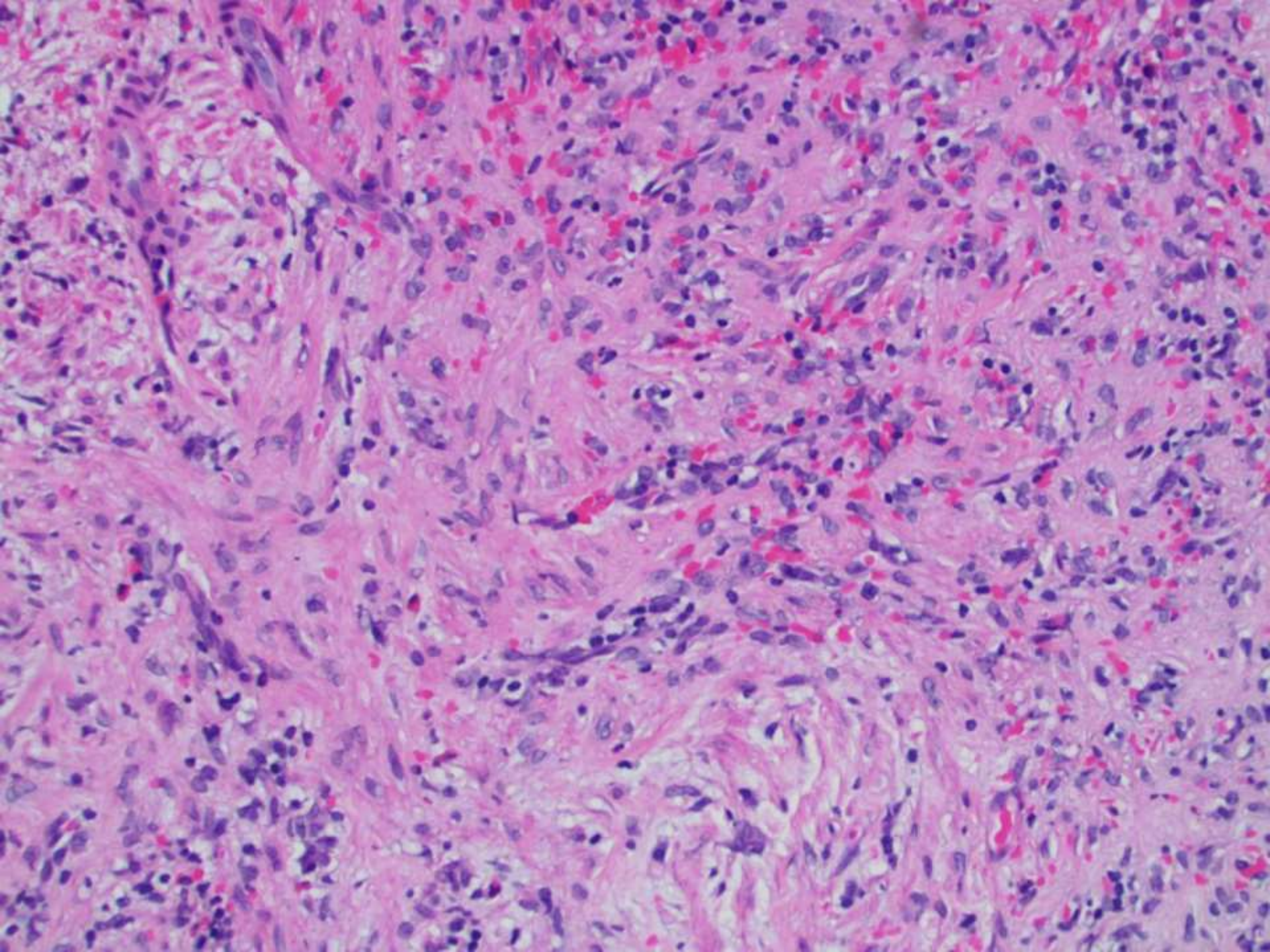






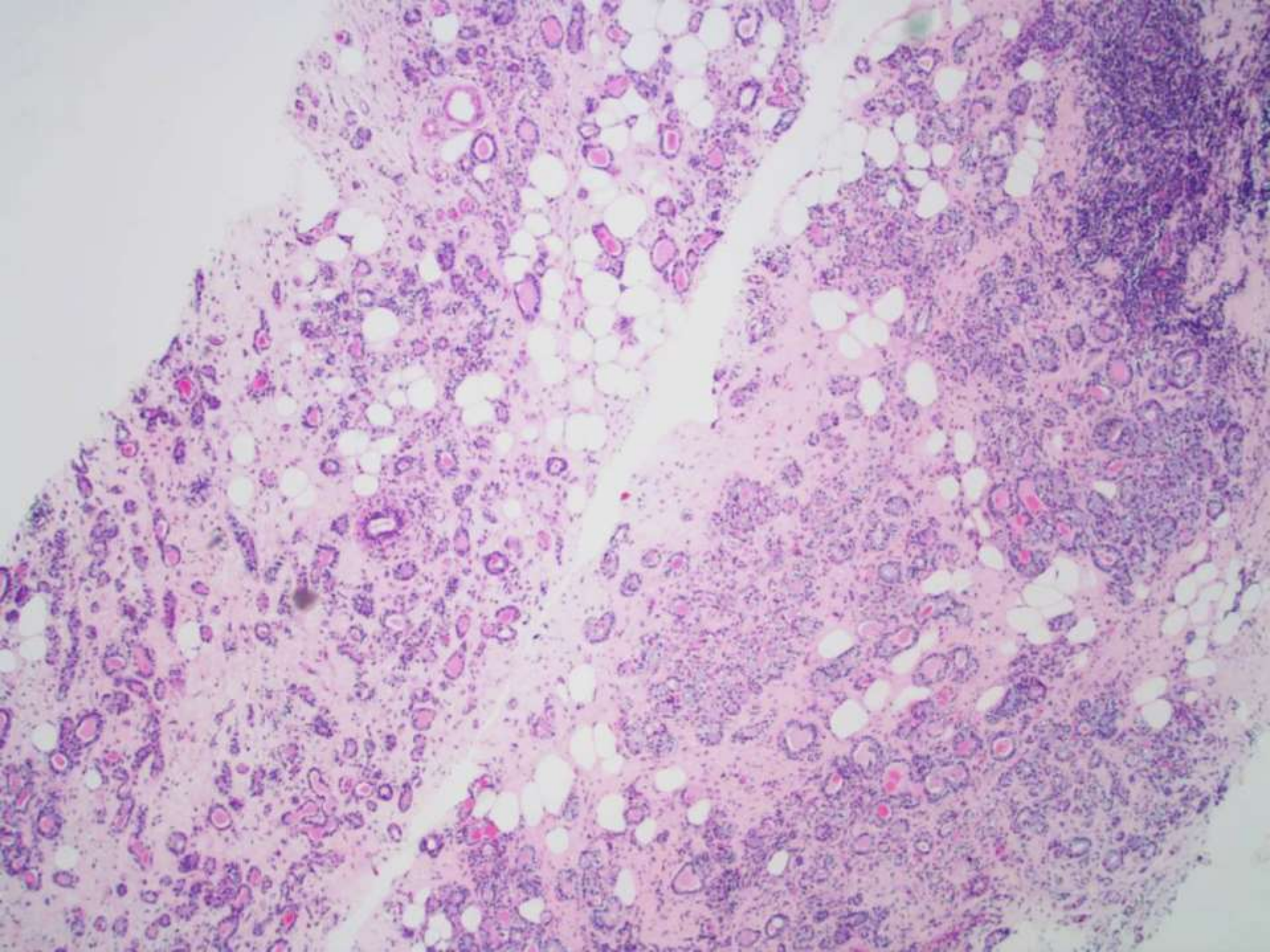


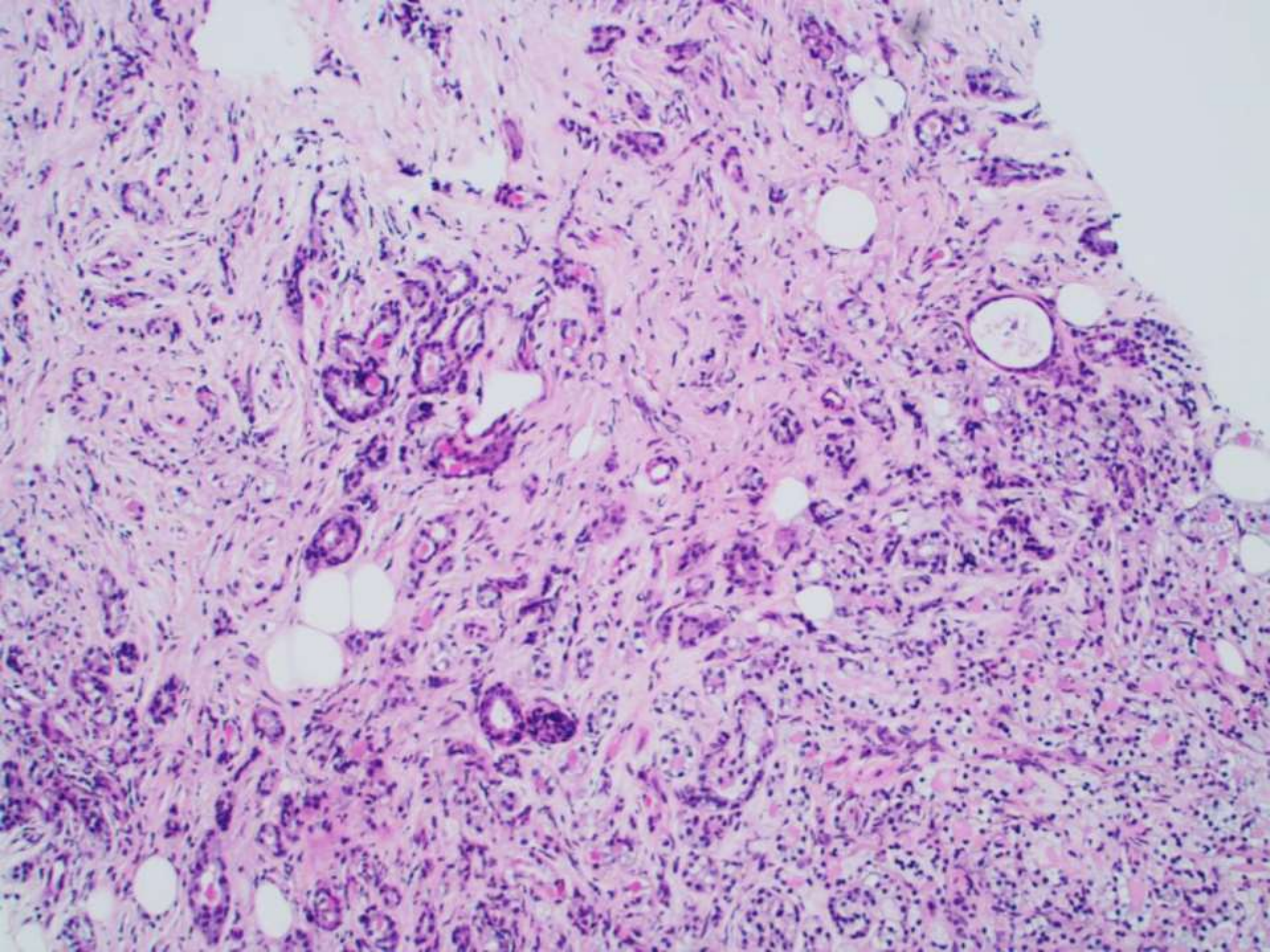


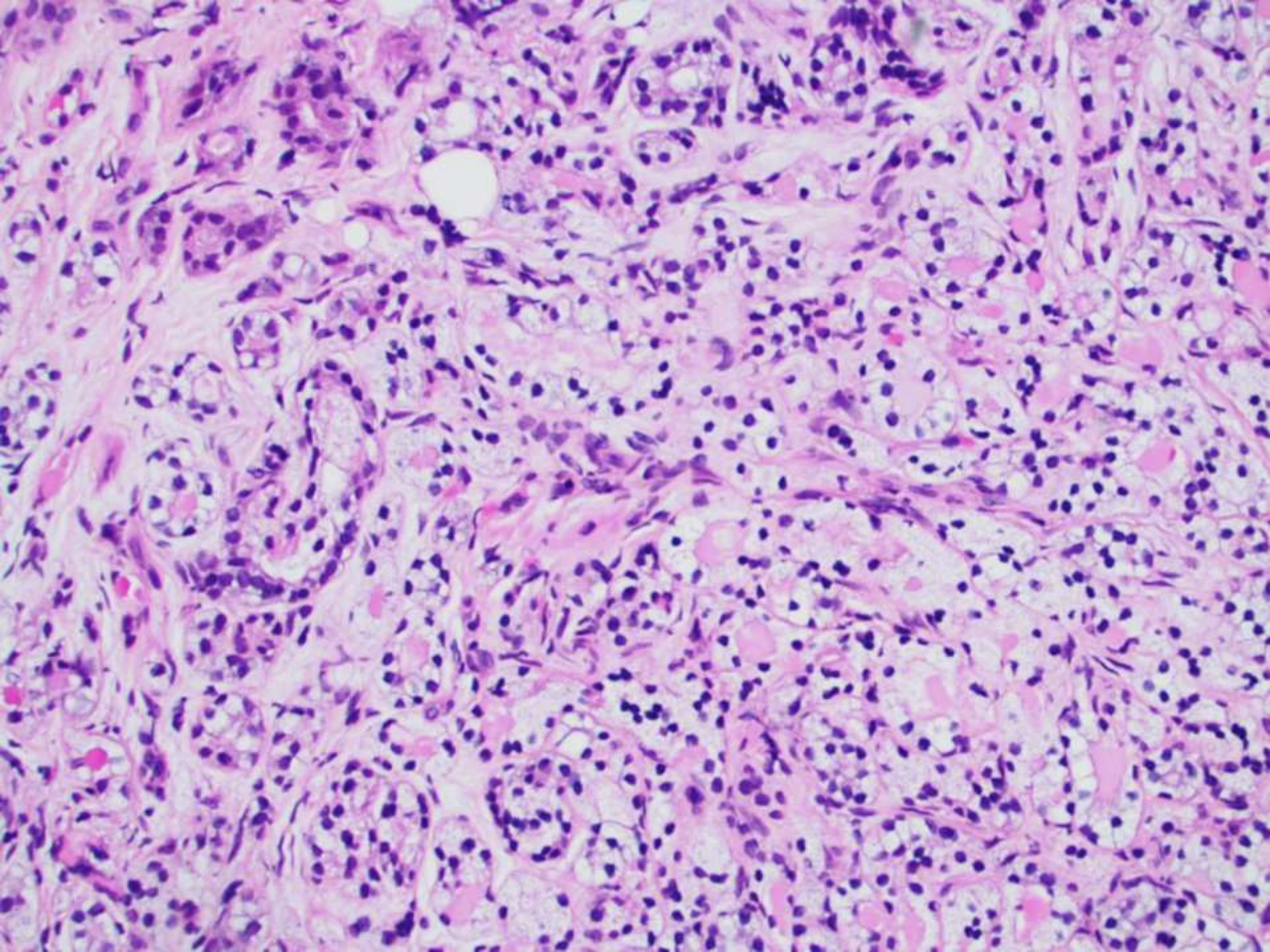


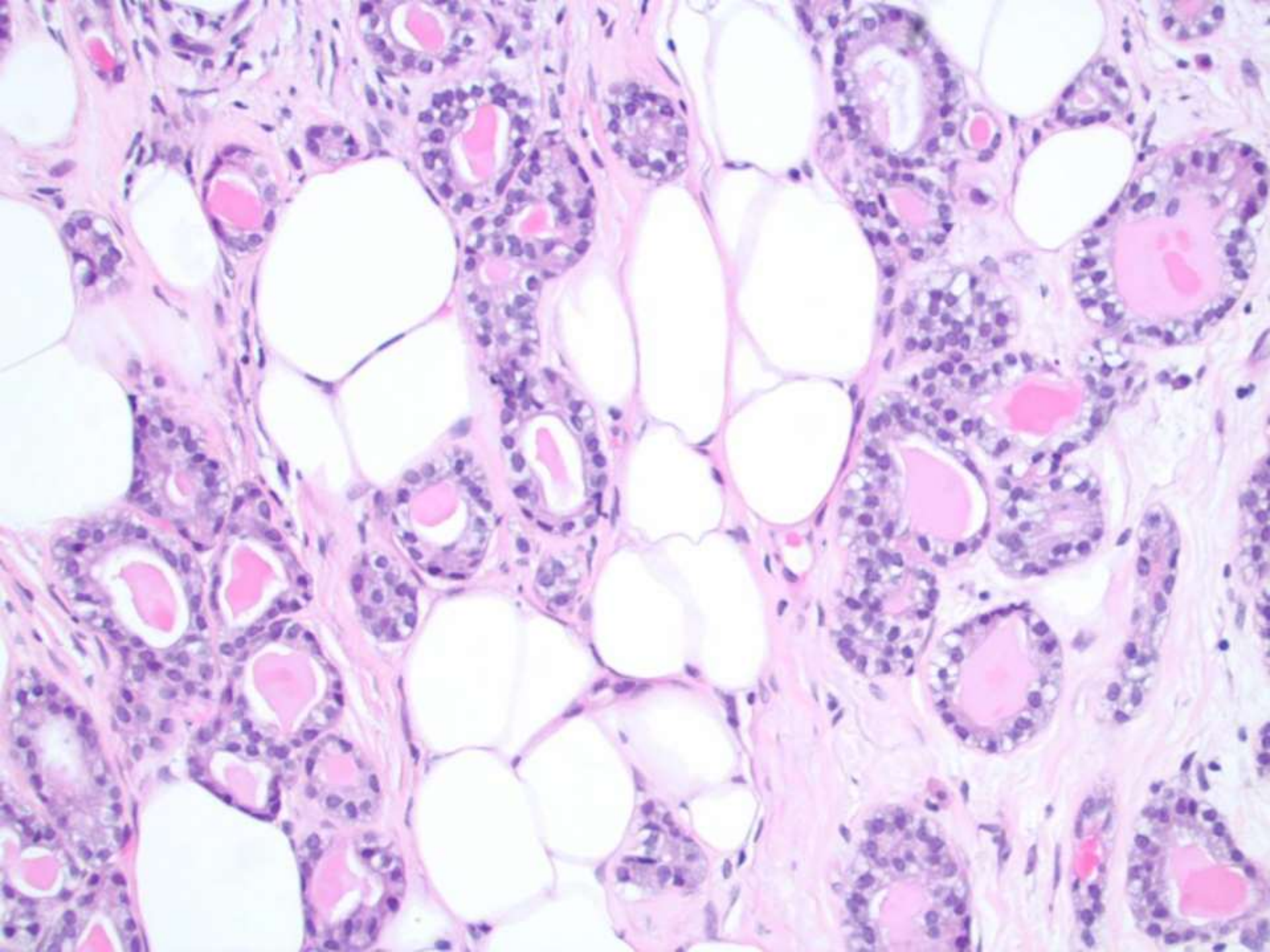
SB 5864

- 84-year-old woman with breast biopsy of palpable 2.5x1.7cm hypoechoic area on ultrasound.



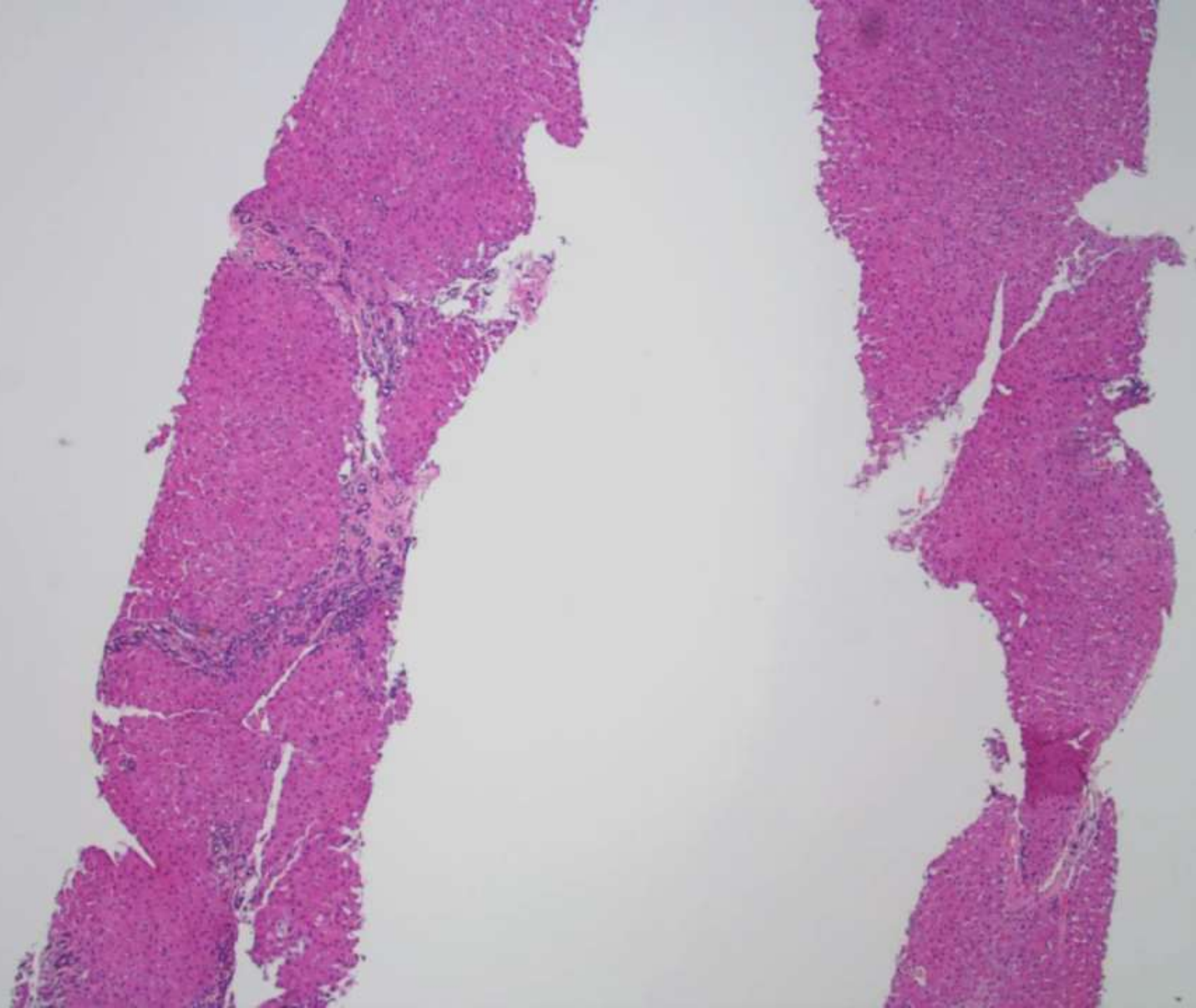


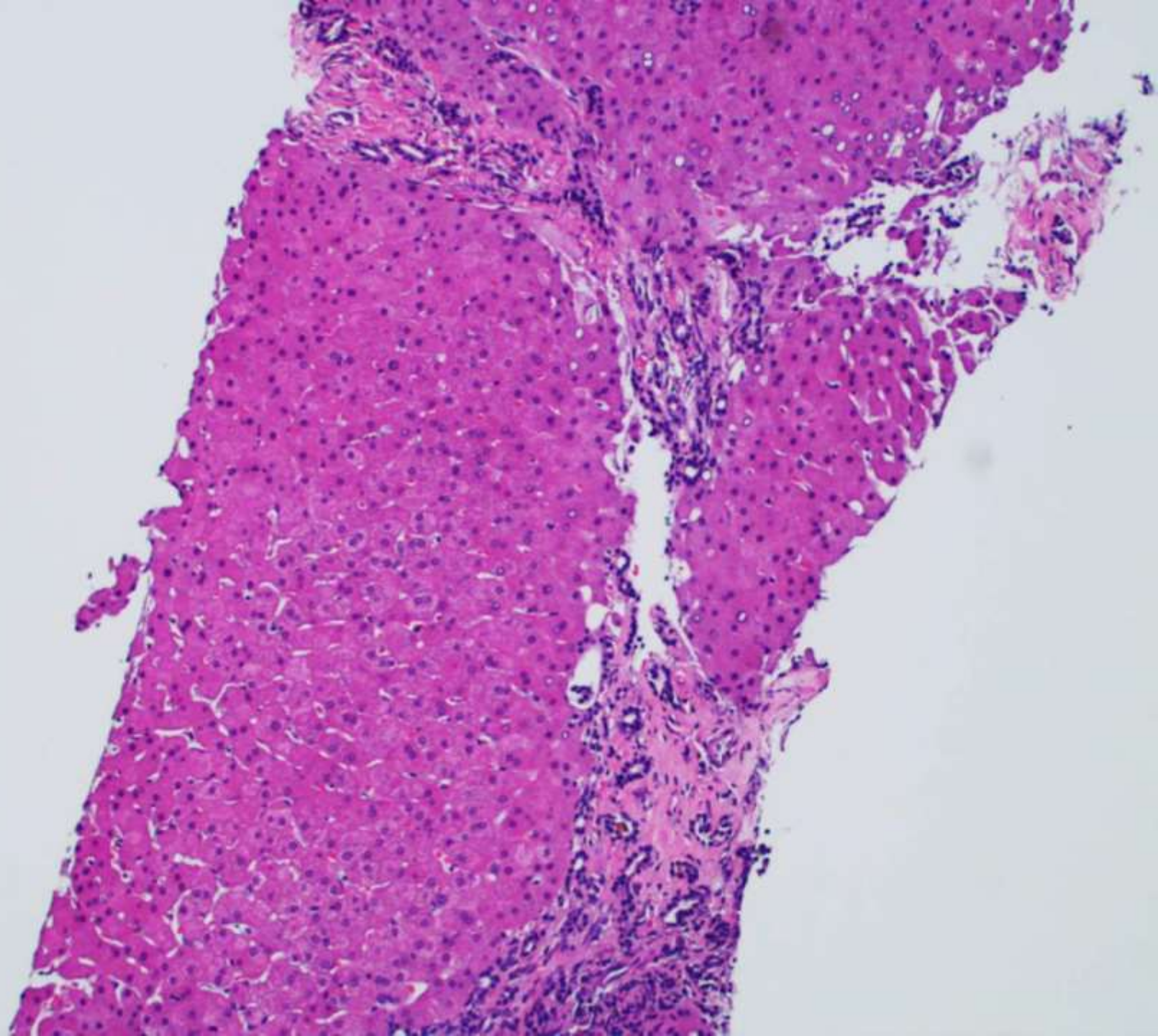


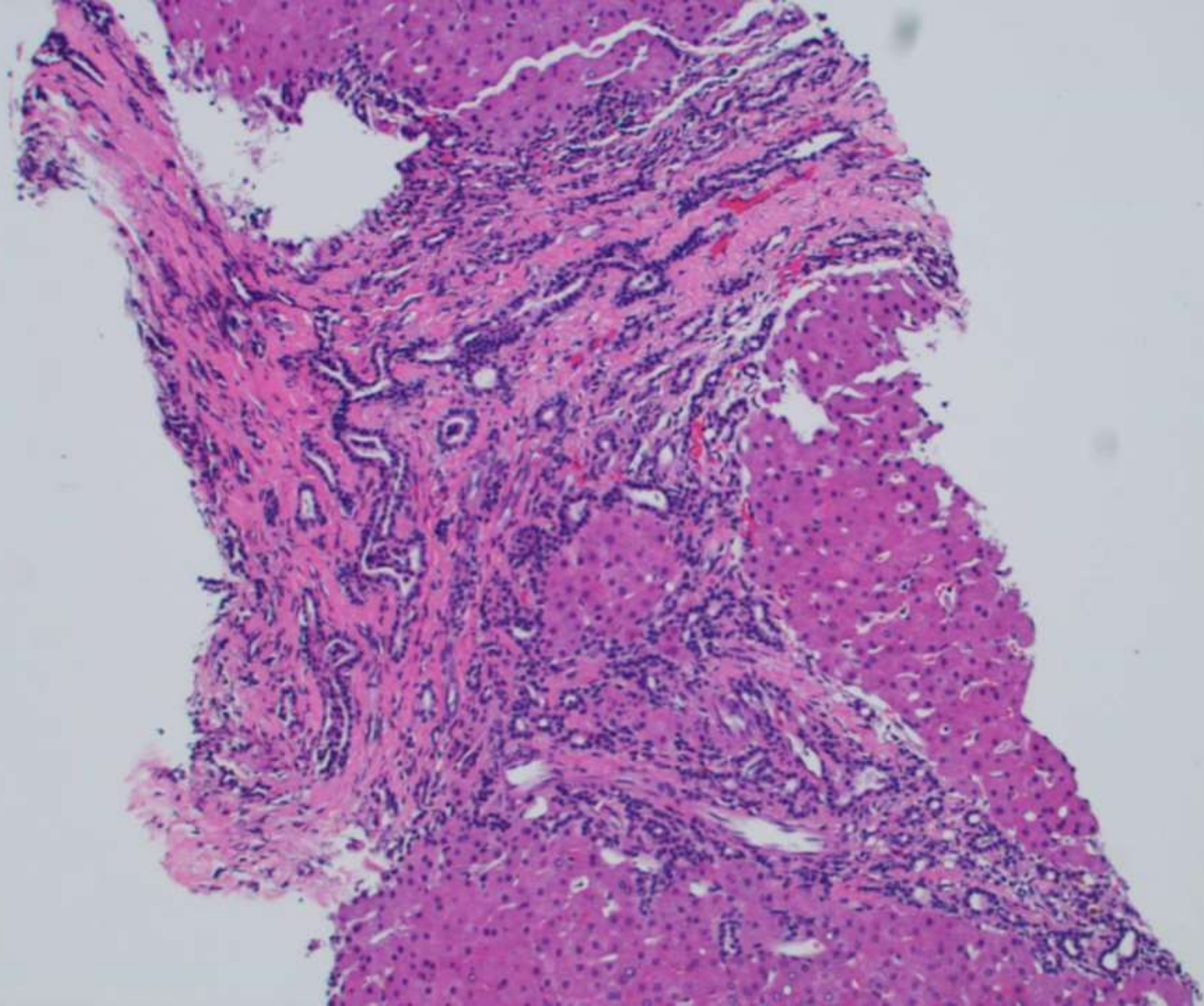


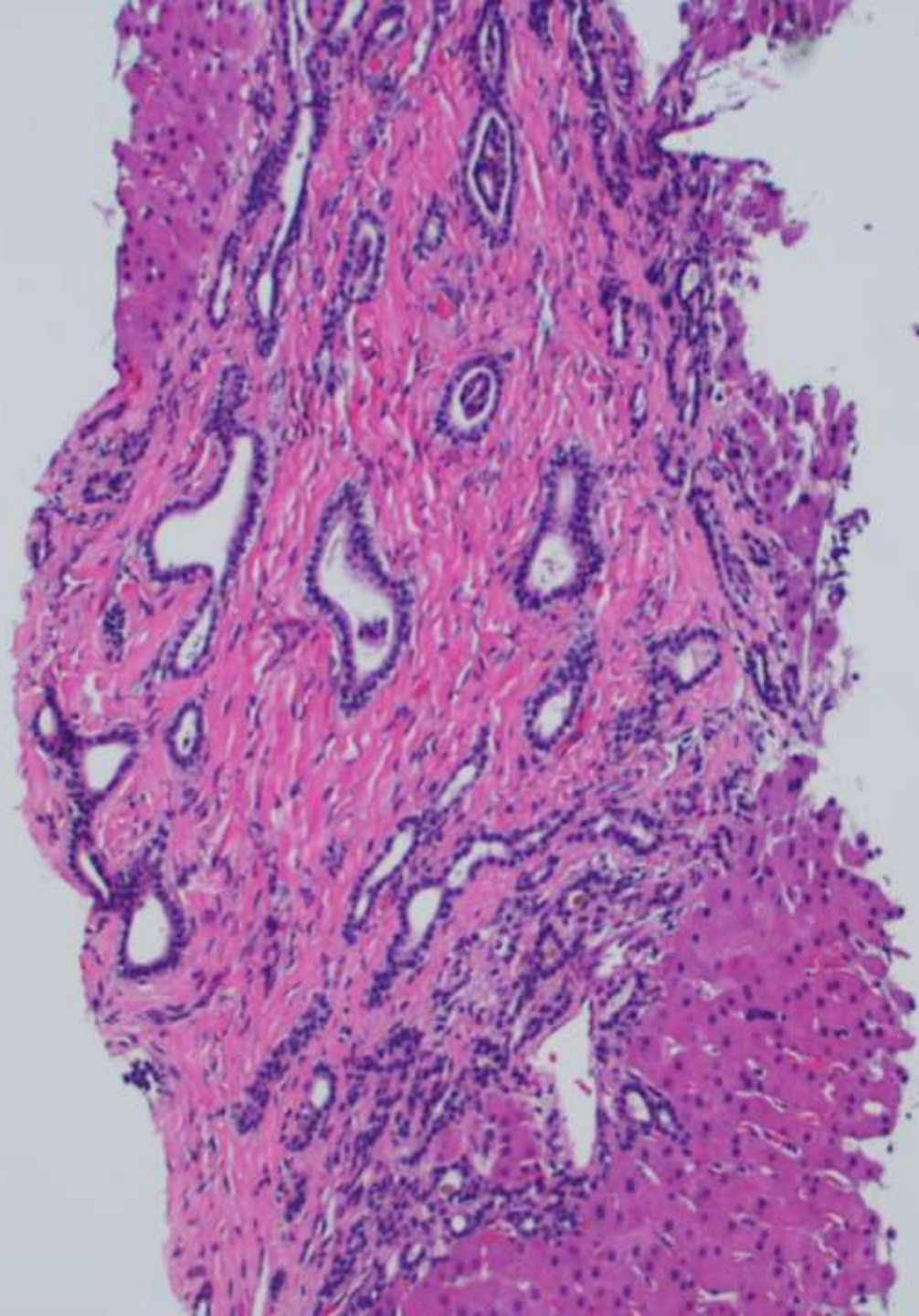
SB 5865

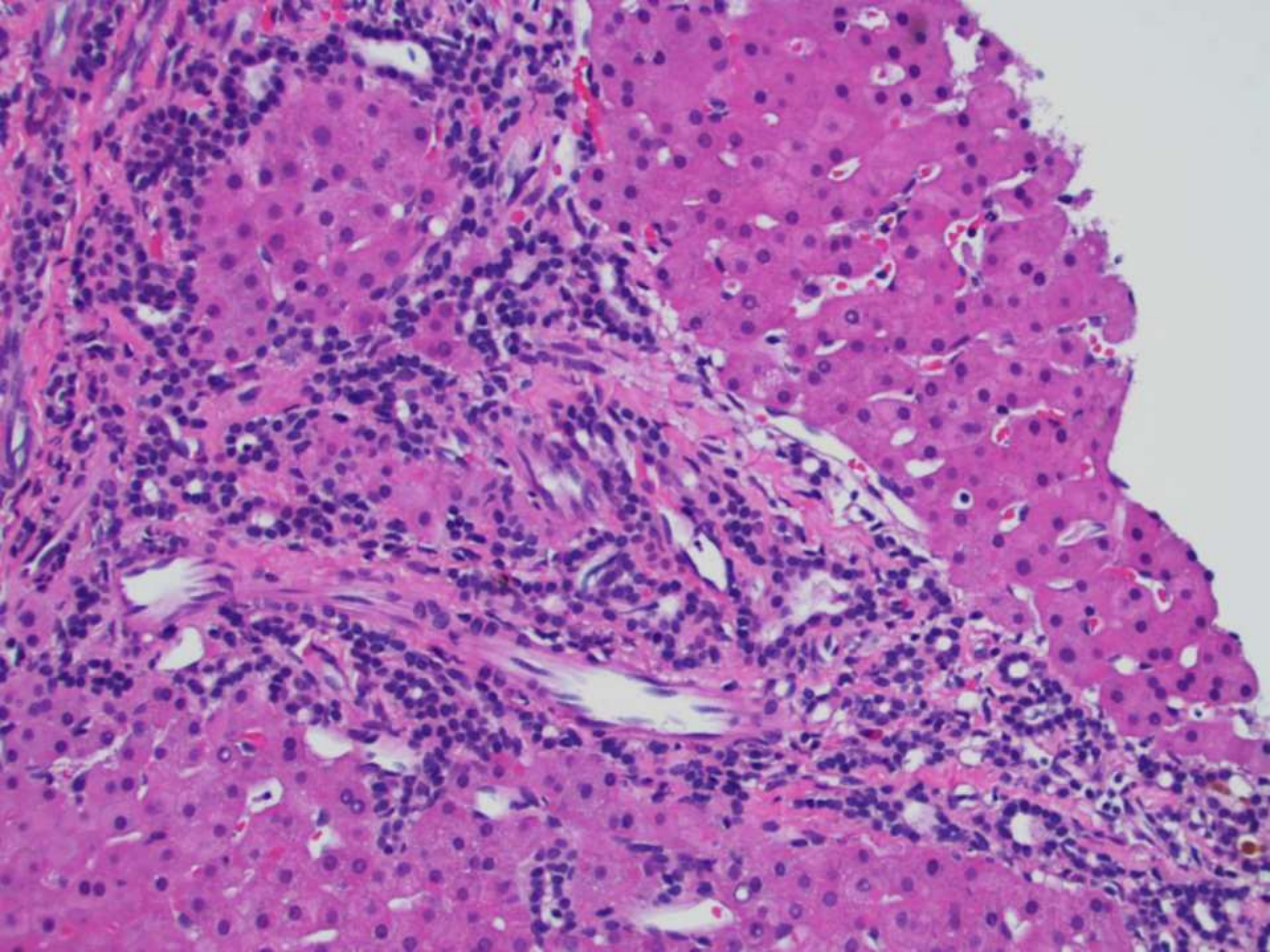
- 18-year-old woman with portal hypertension. Probable cirrhosis of unclear etiology. Negative viral serology. Liver biopsy performed.





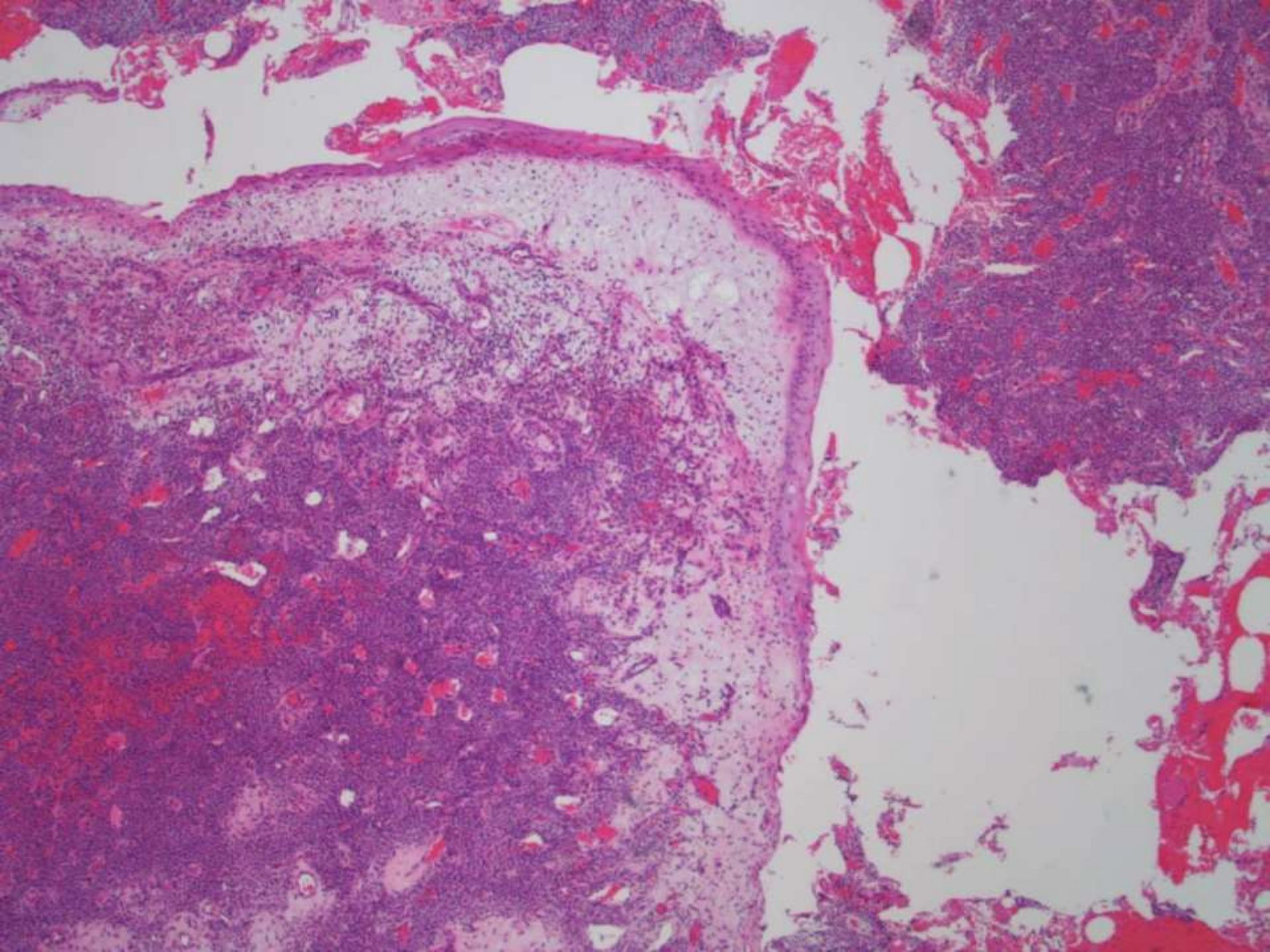


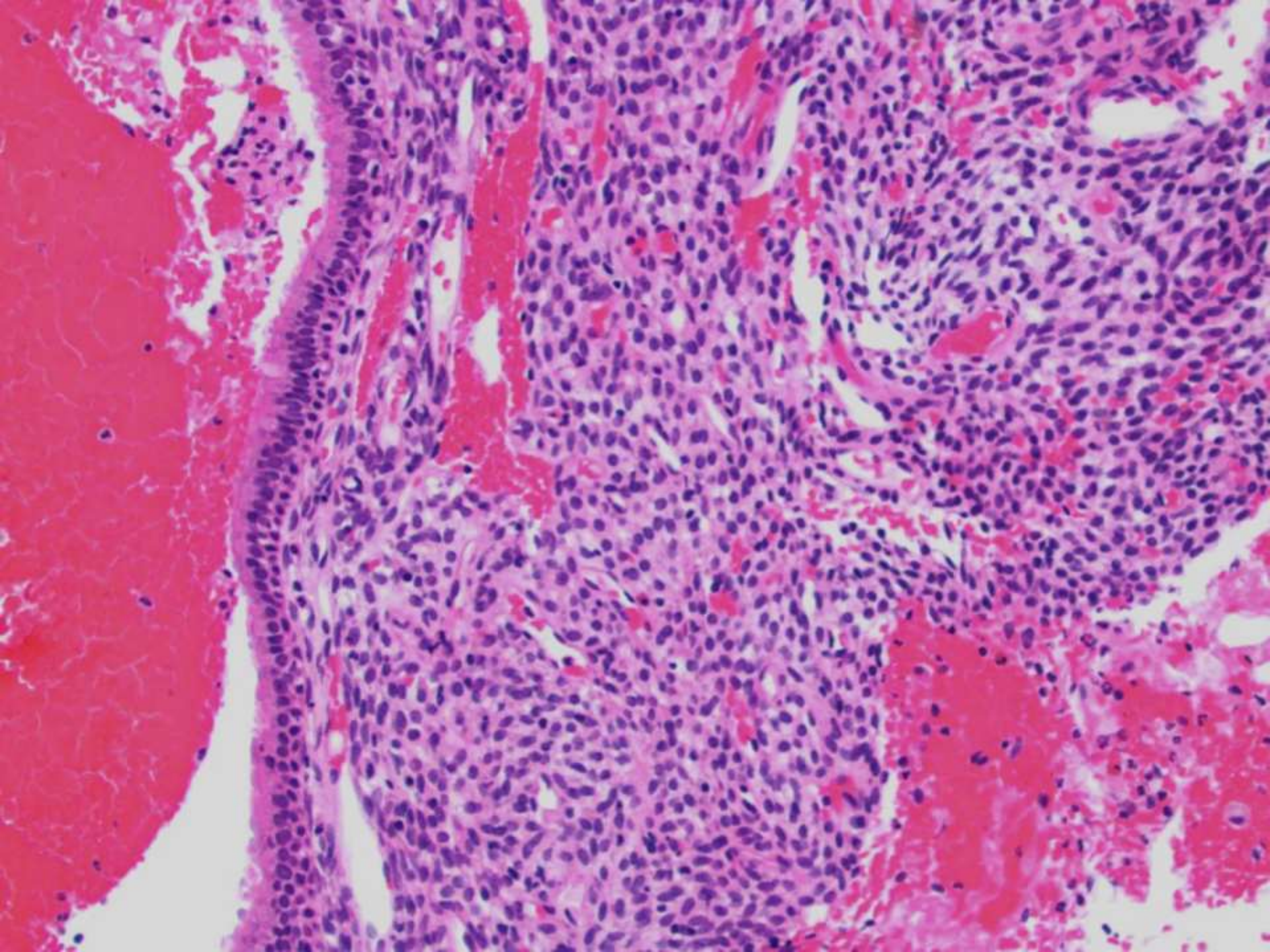


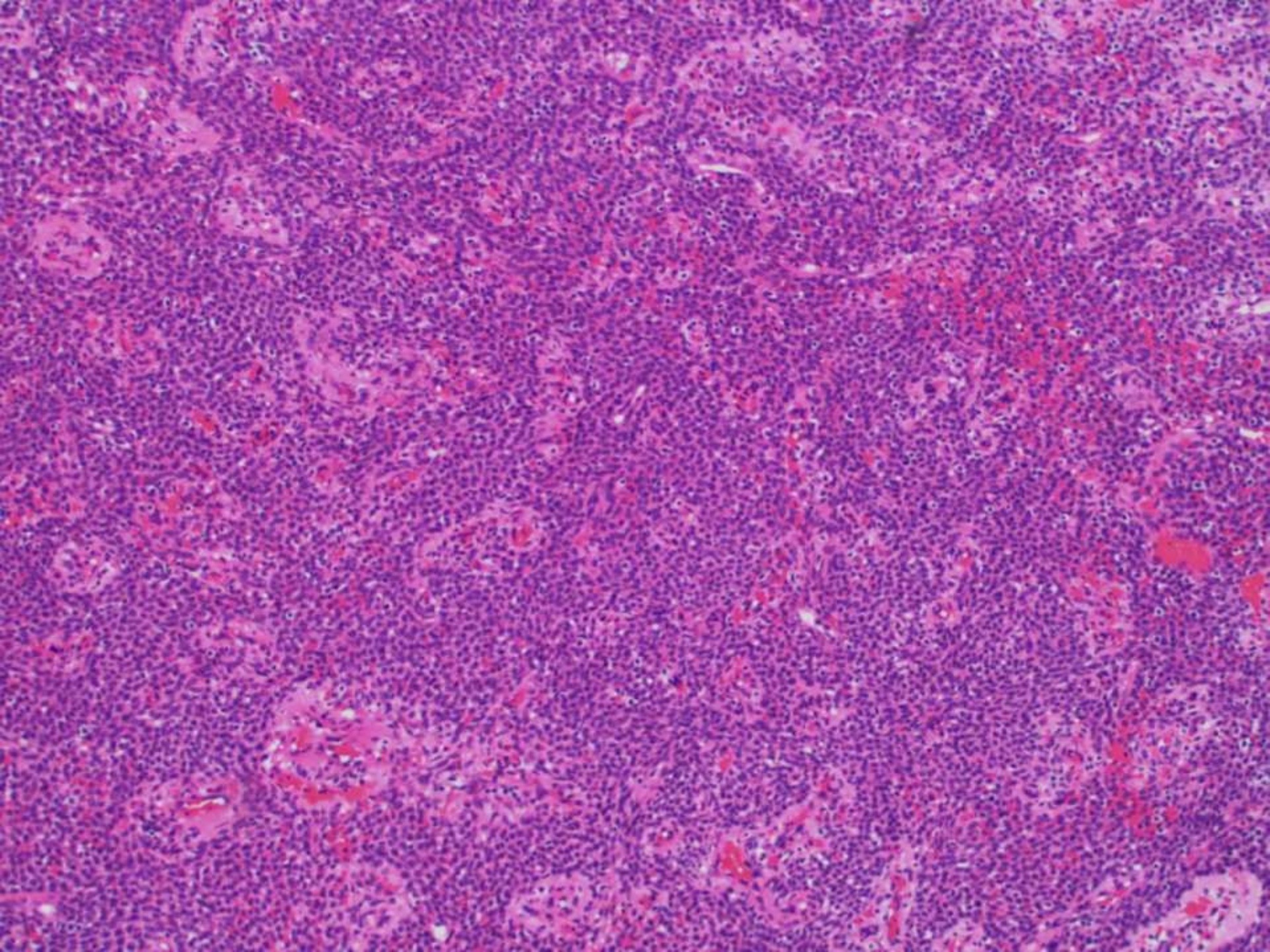


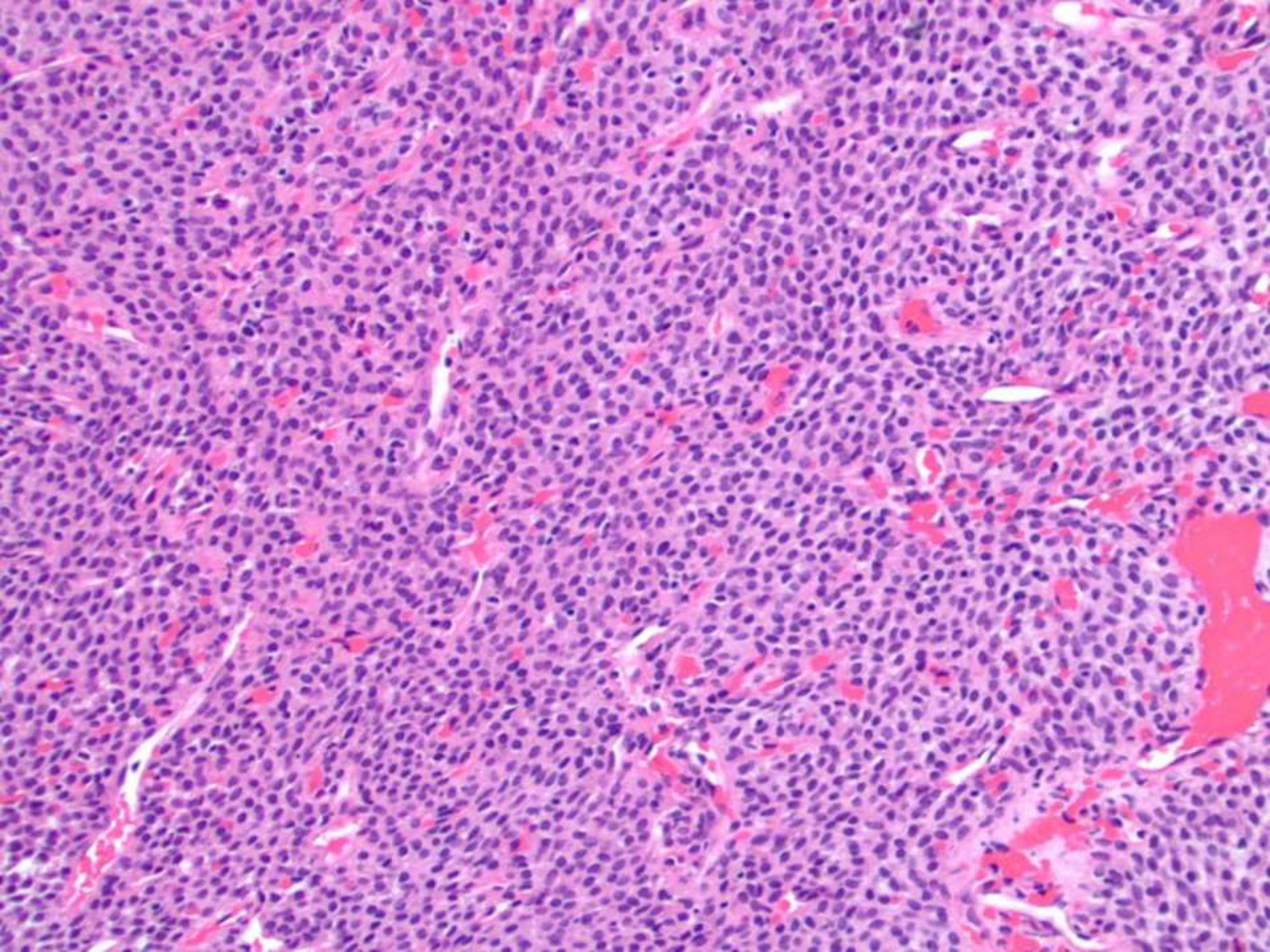
SB 5866

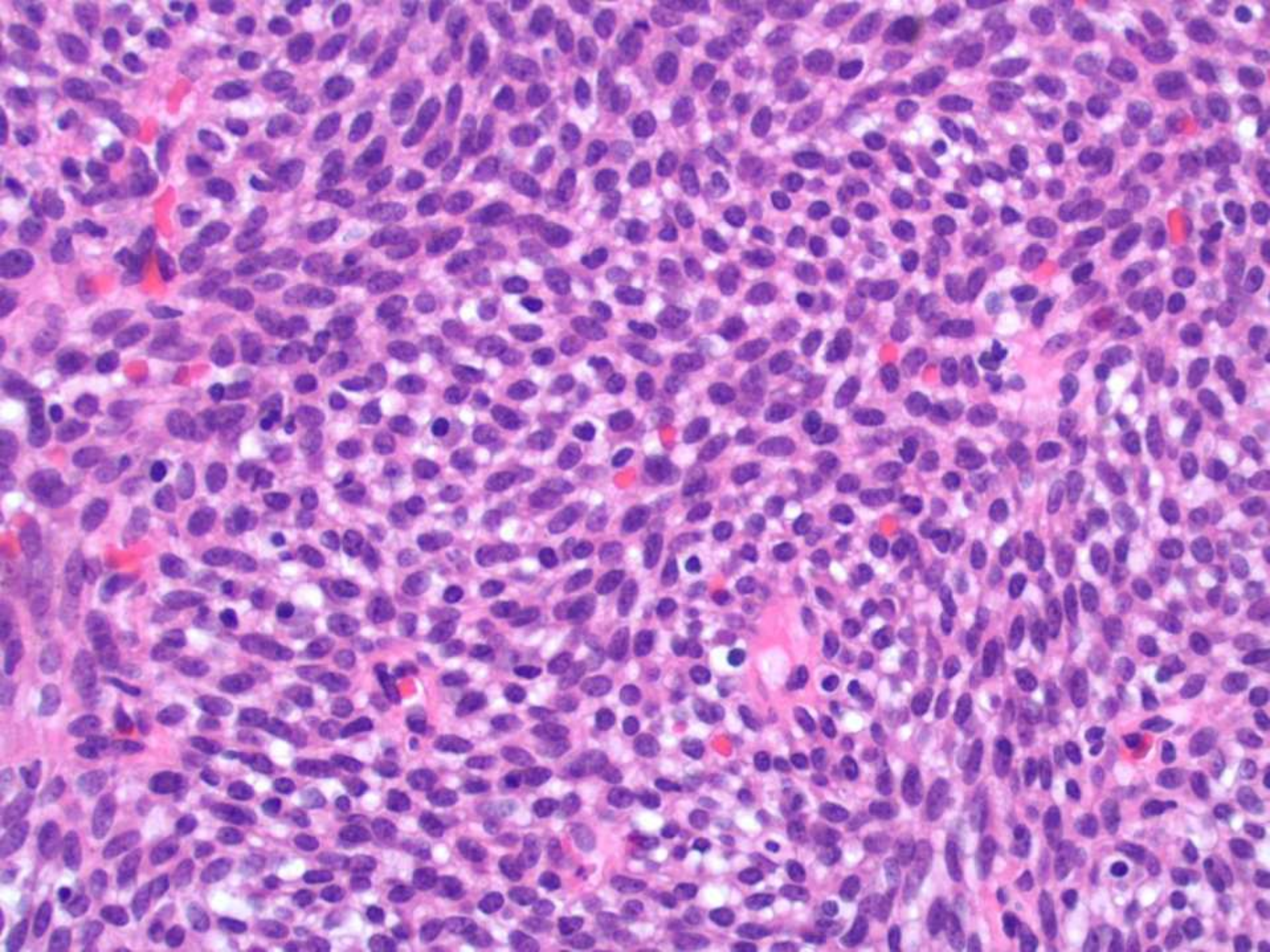
- 64-year-old man with deviated nasal septum and recurrent nasal polyposis. Sinus contents submitted.





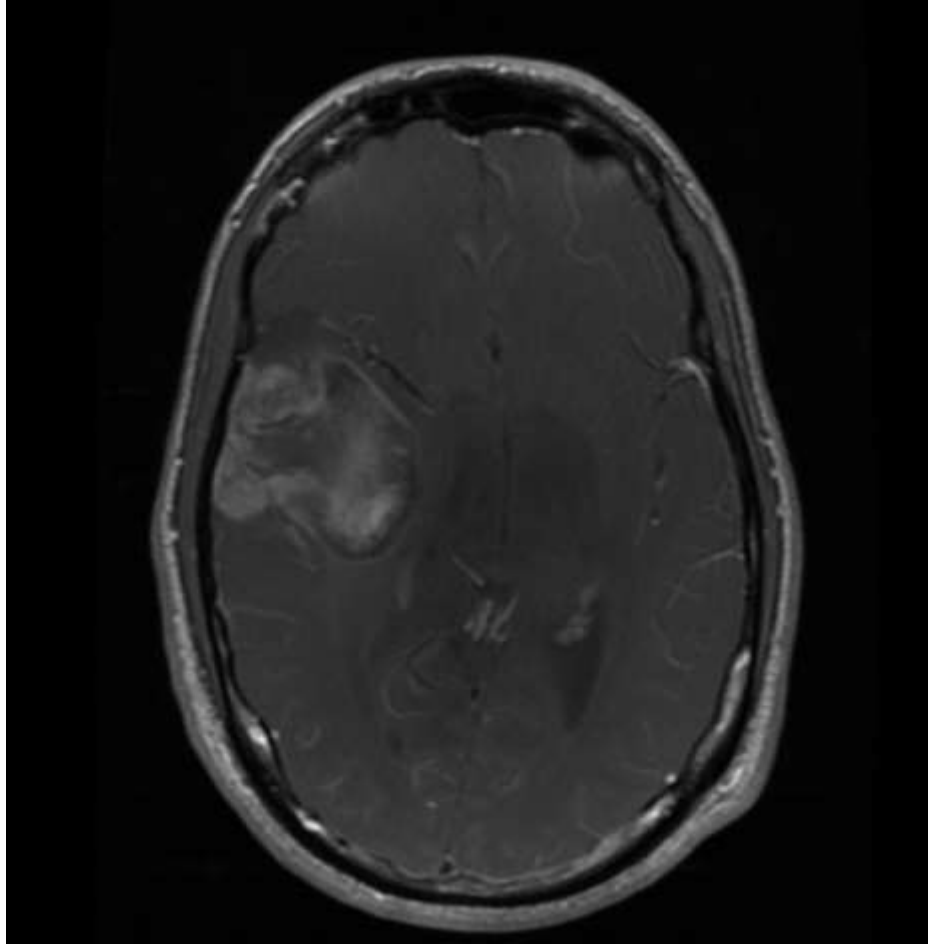


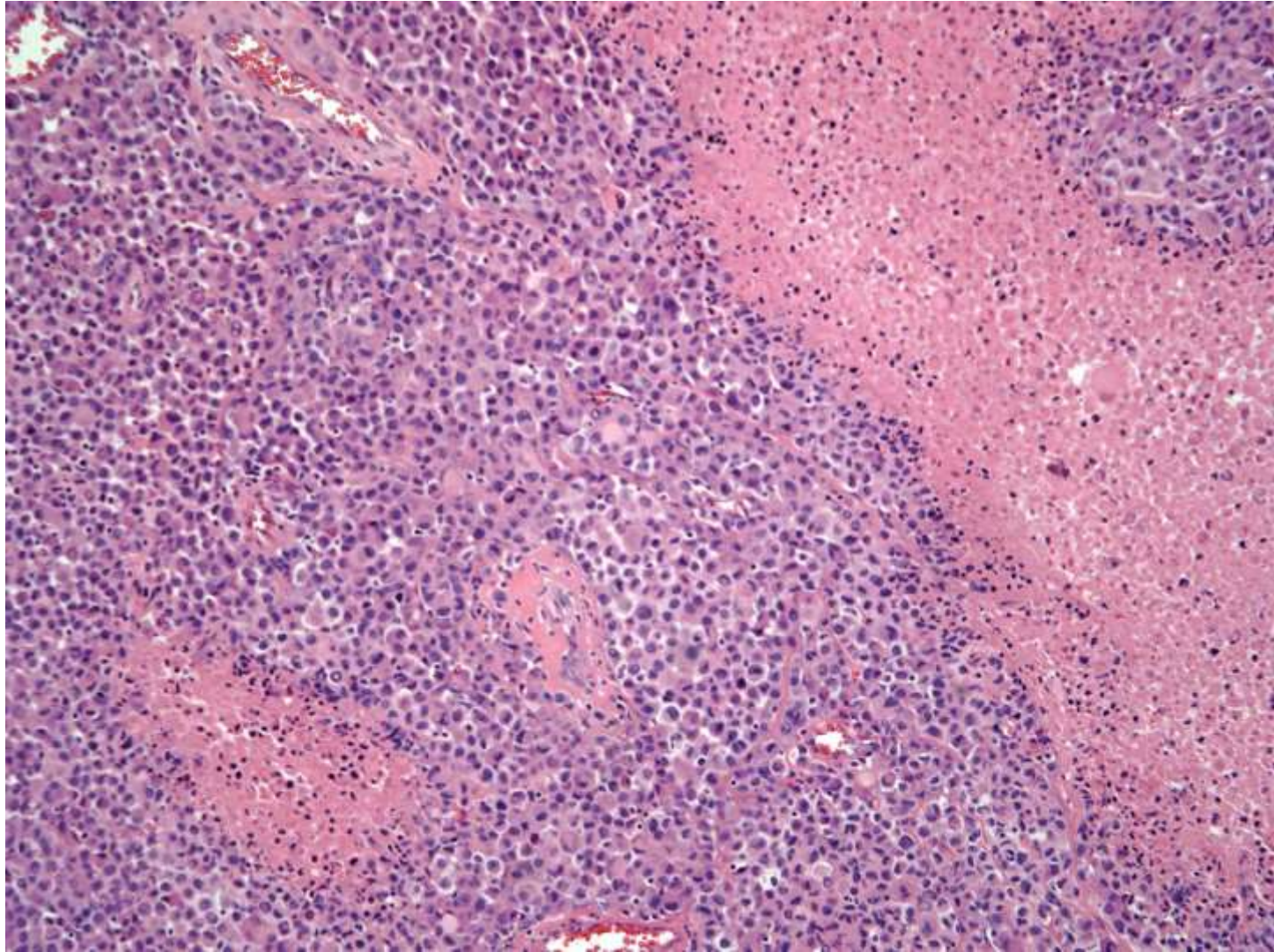


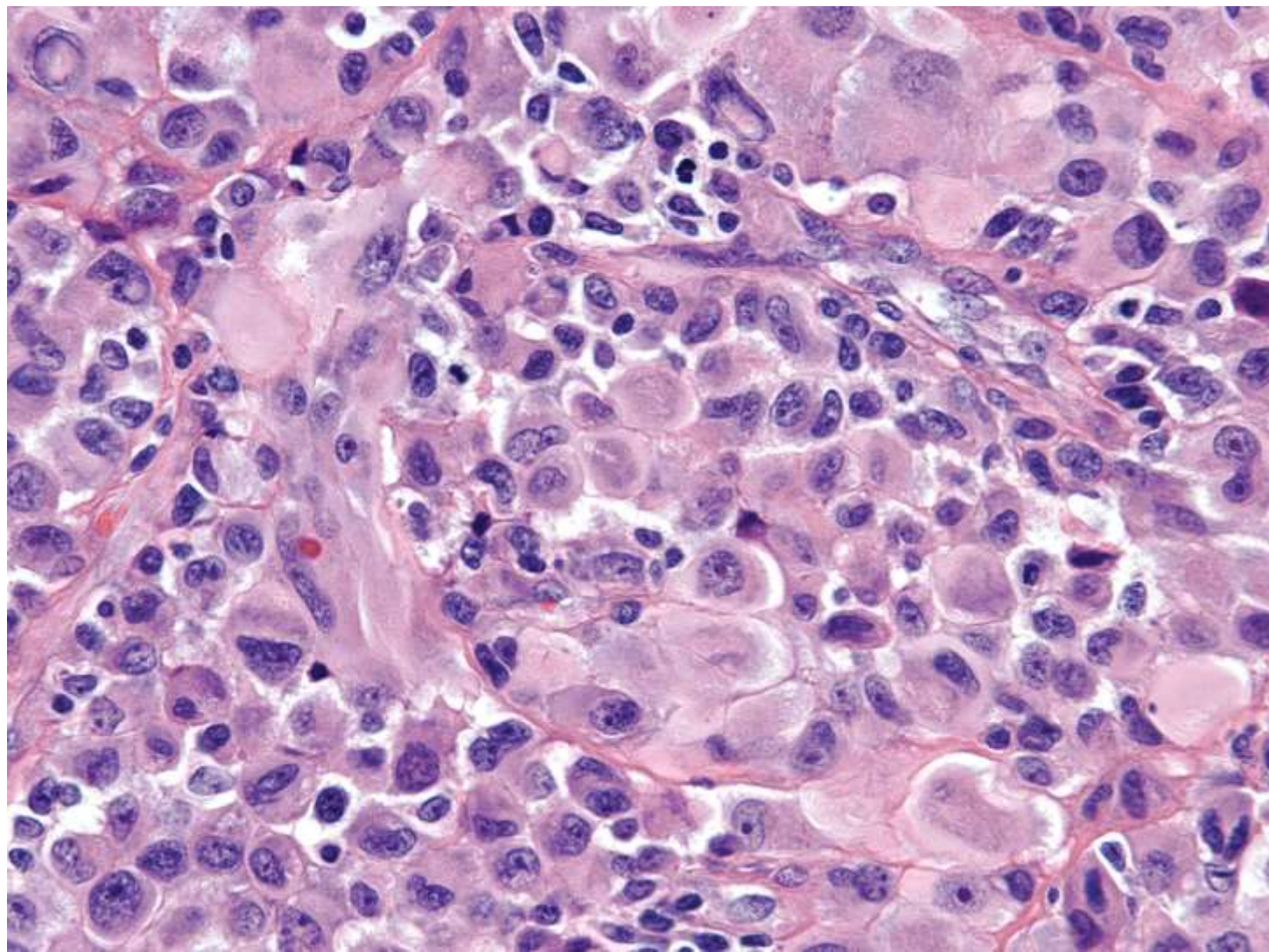


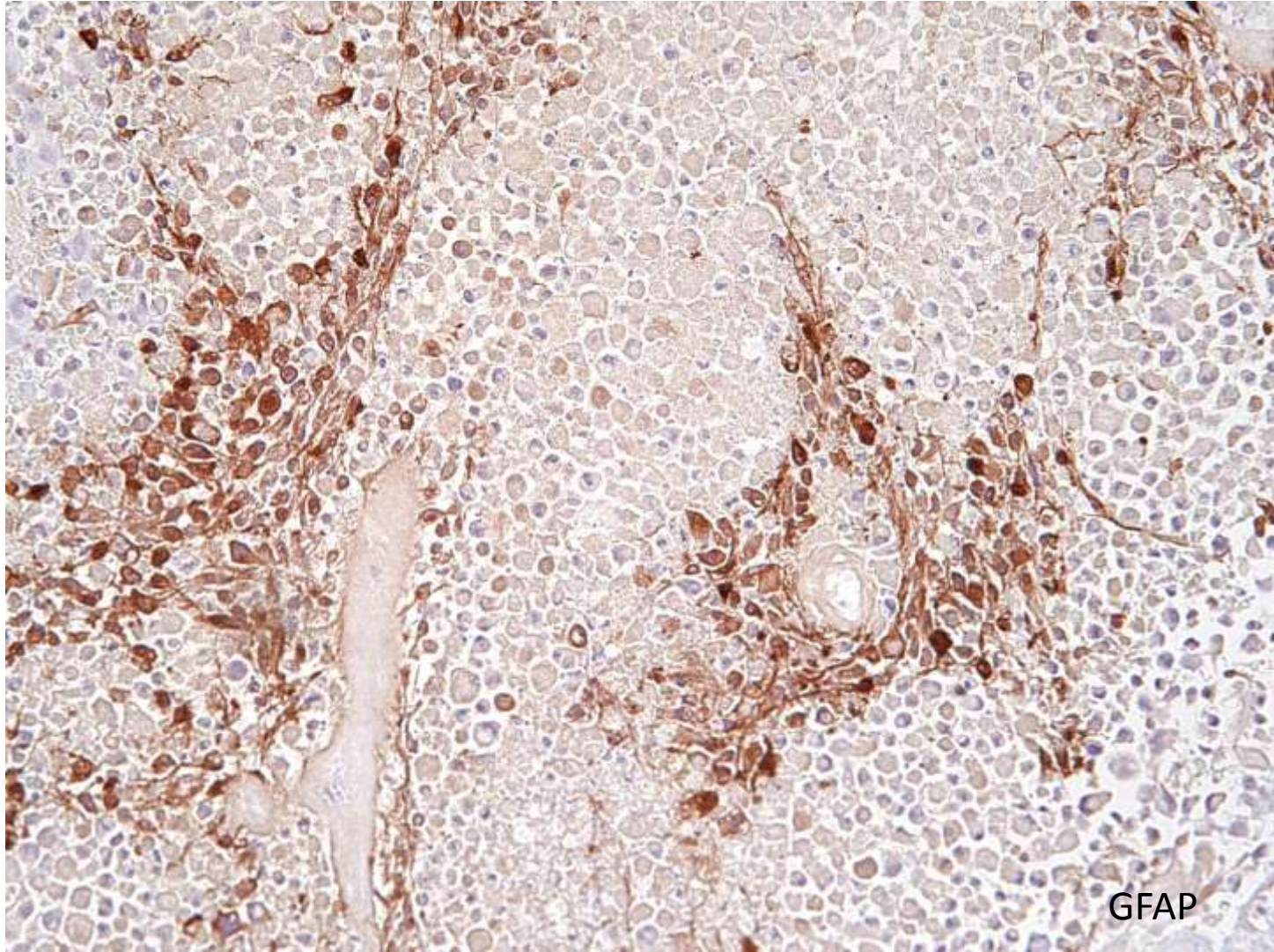
SB 5867

- 26-year-old man with bipolar disorder developed nausea and vomiting with altered mental status. A right temporal lobe tumor was found.

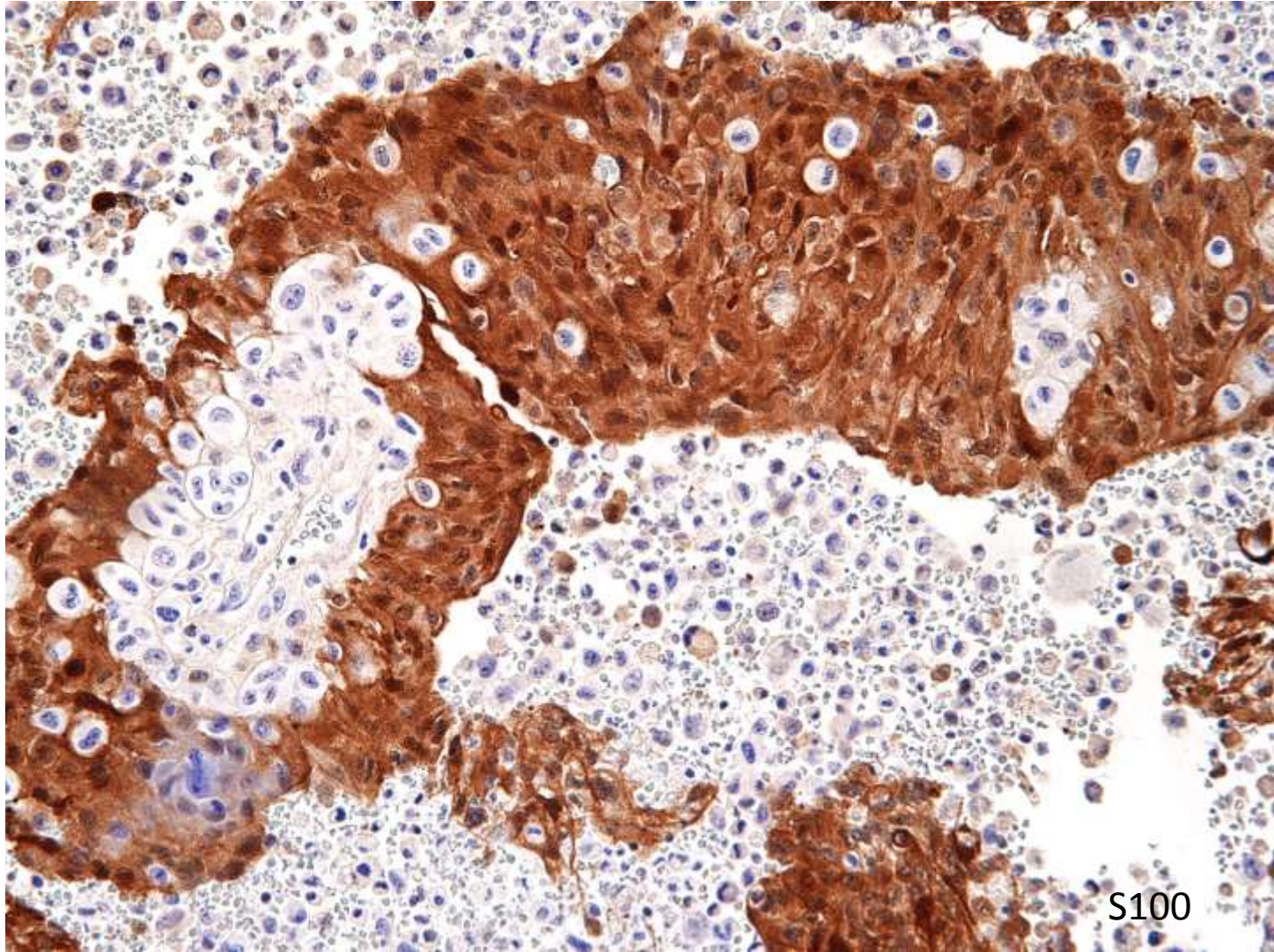




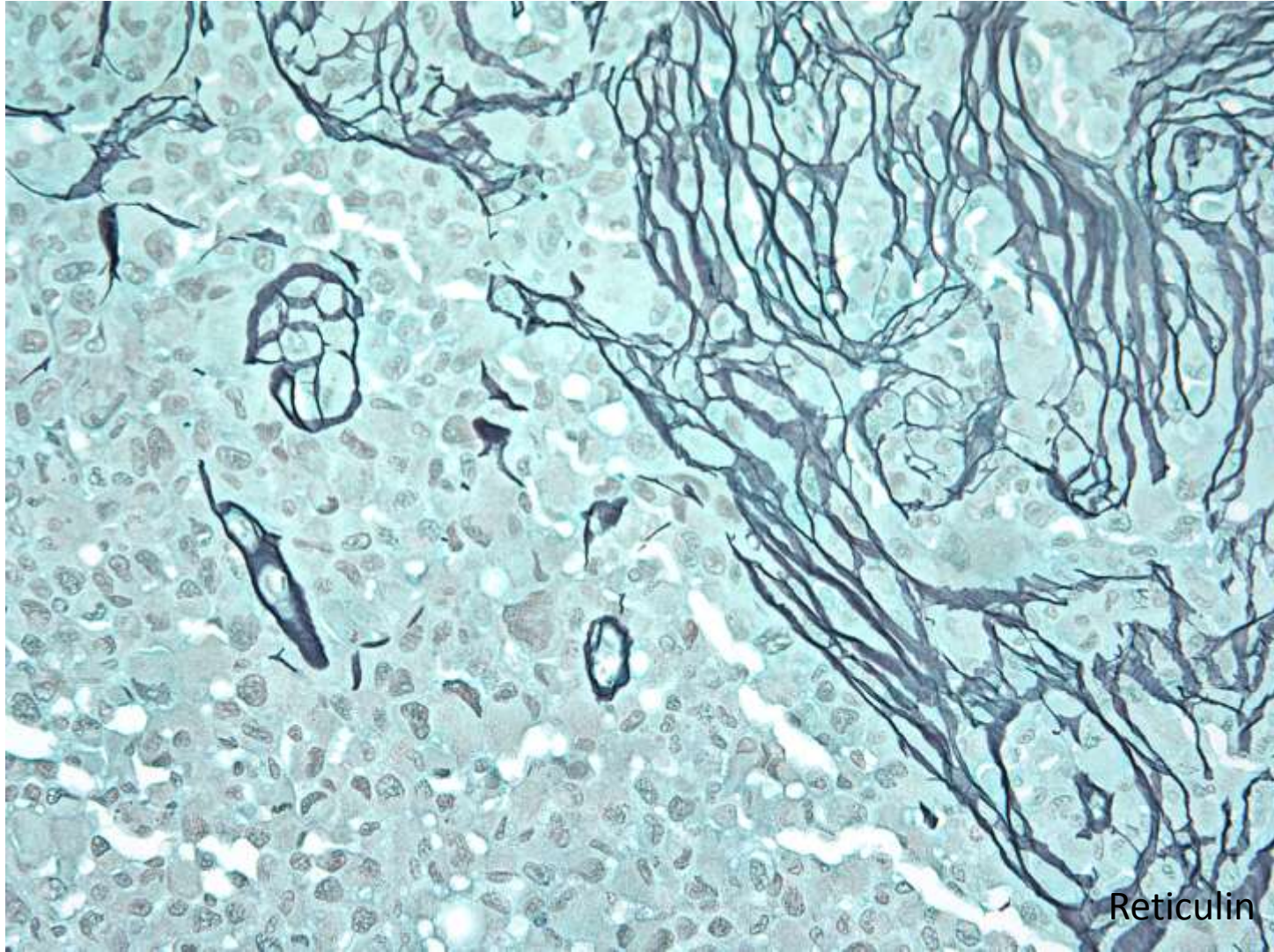




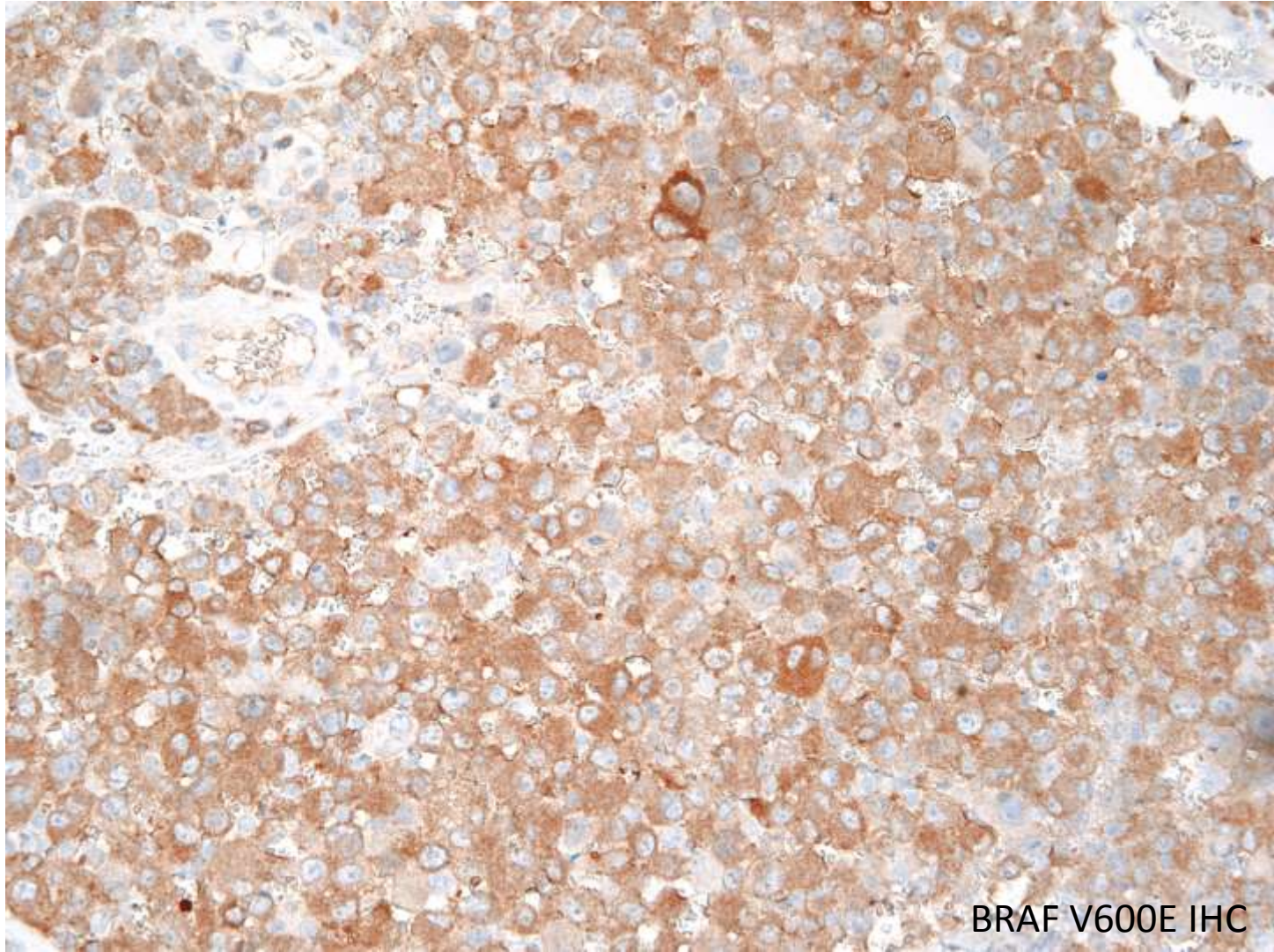
GFAP



S100

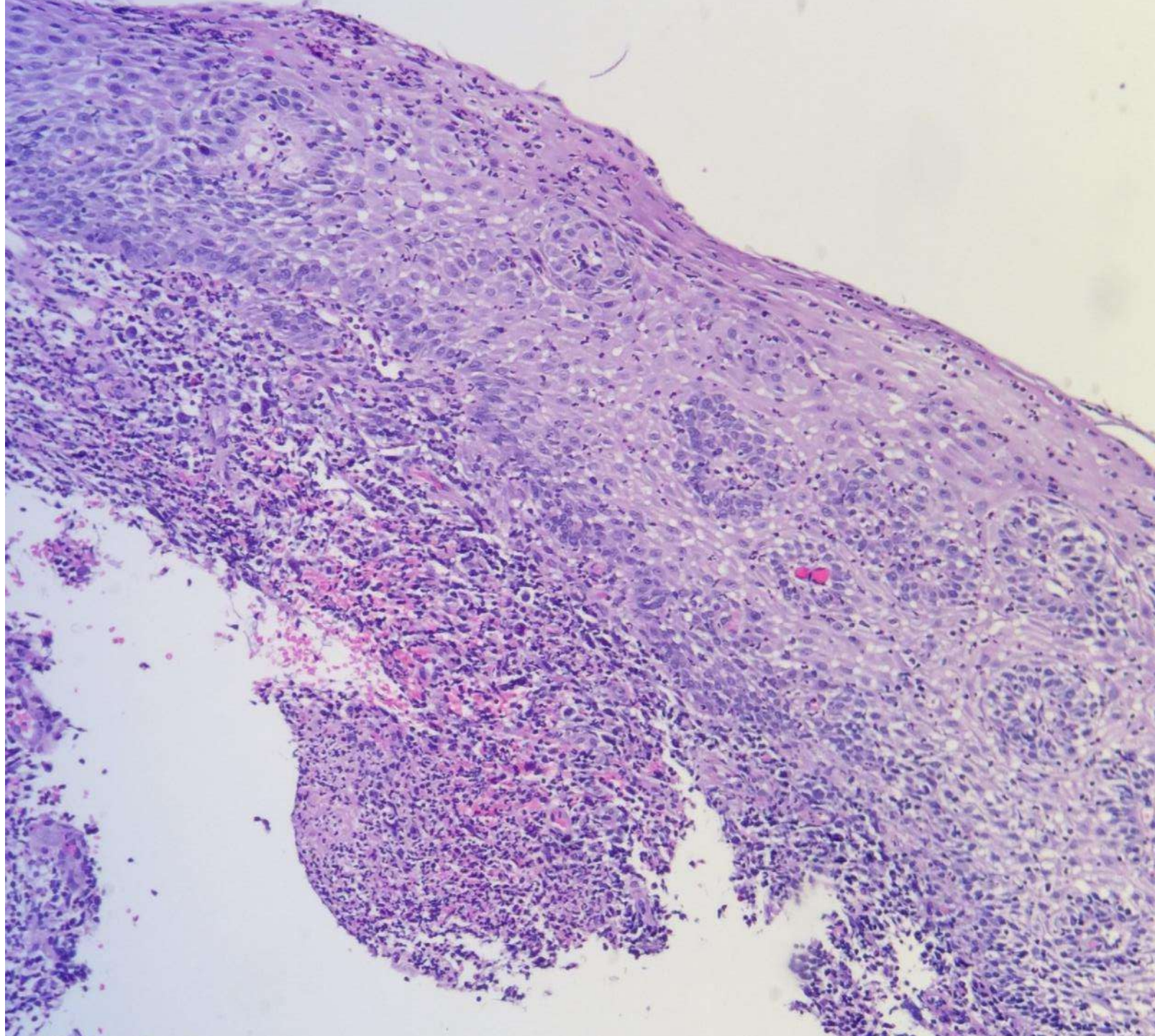


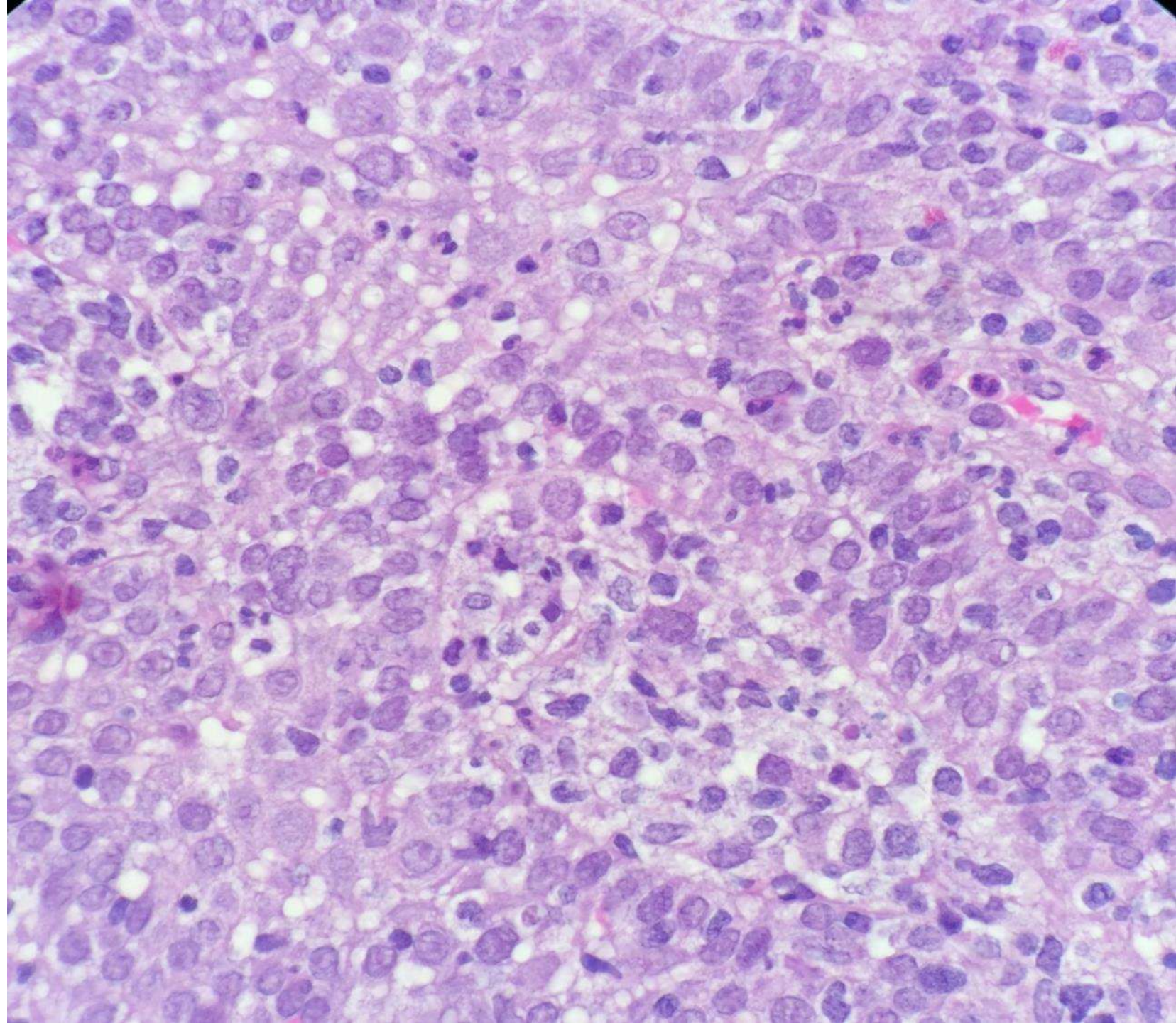
Reticulin

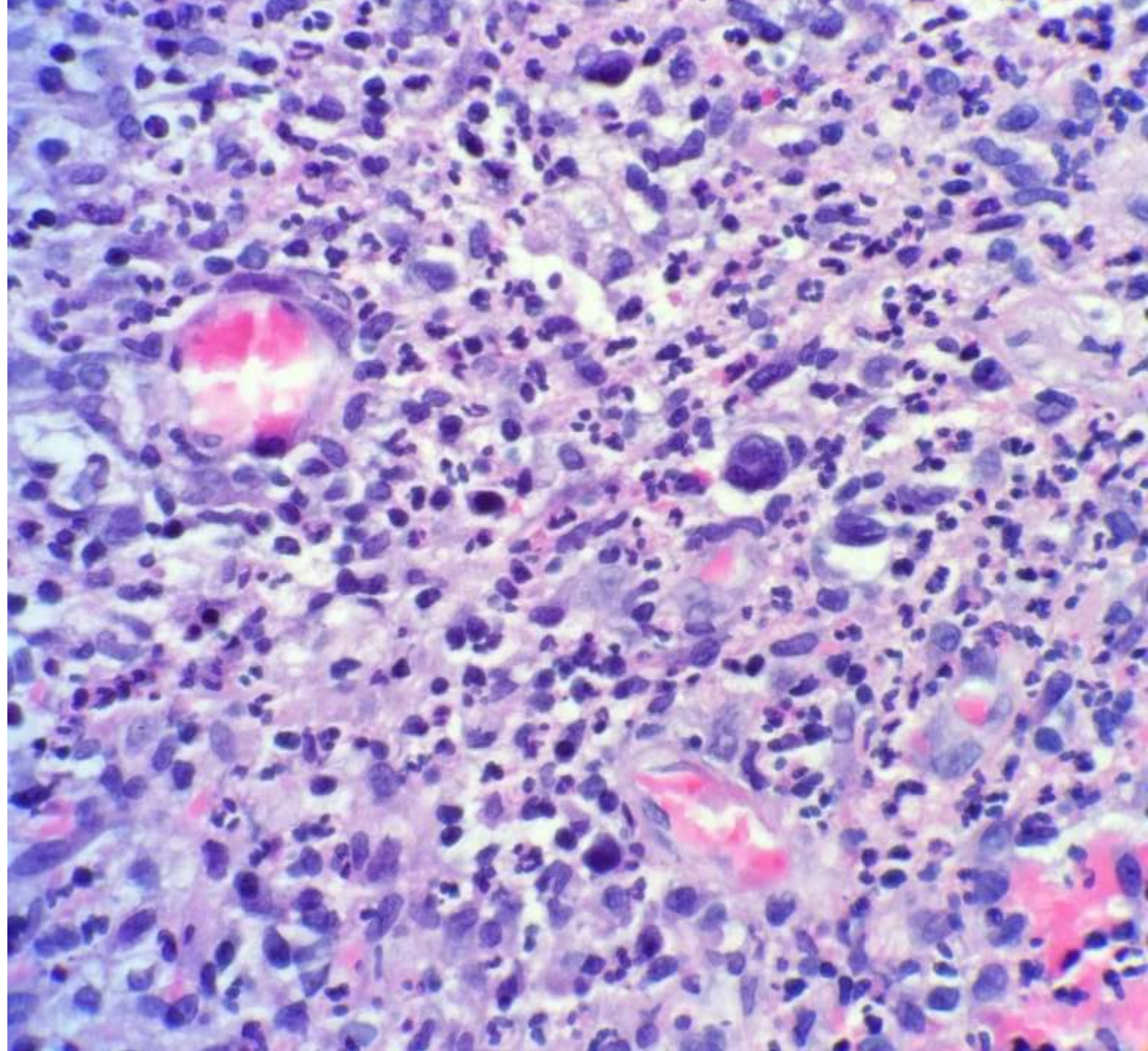


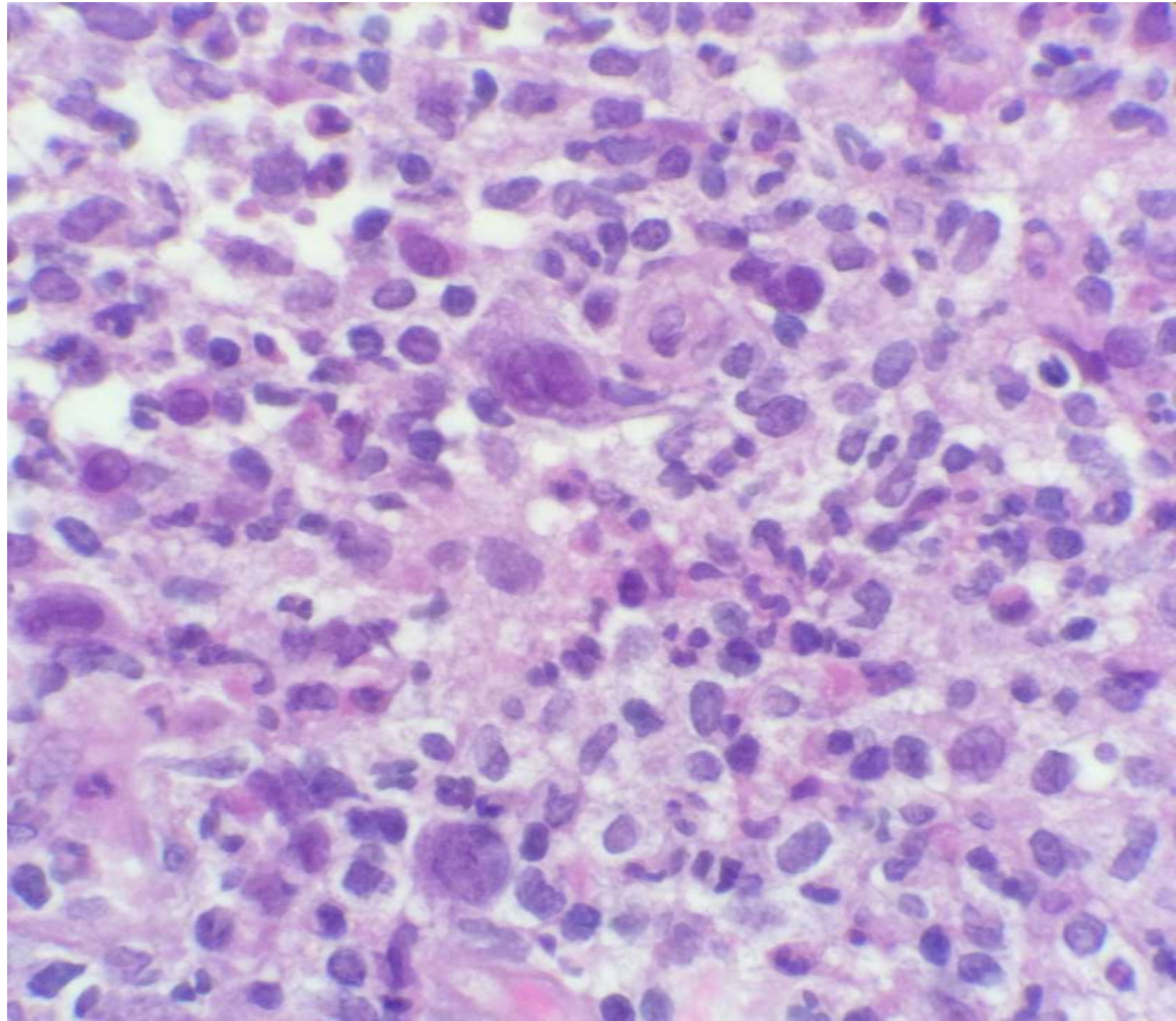
SB 5868

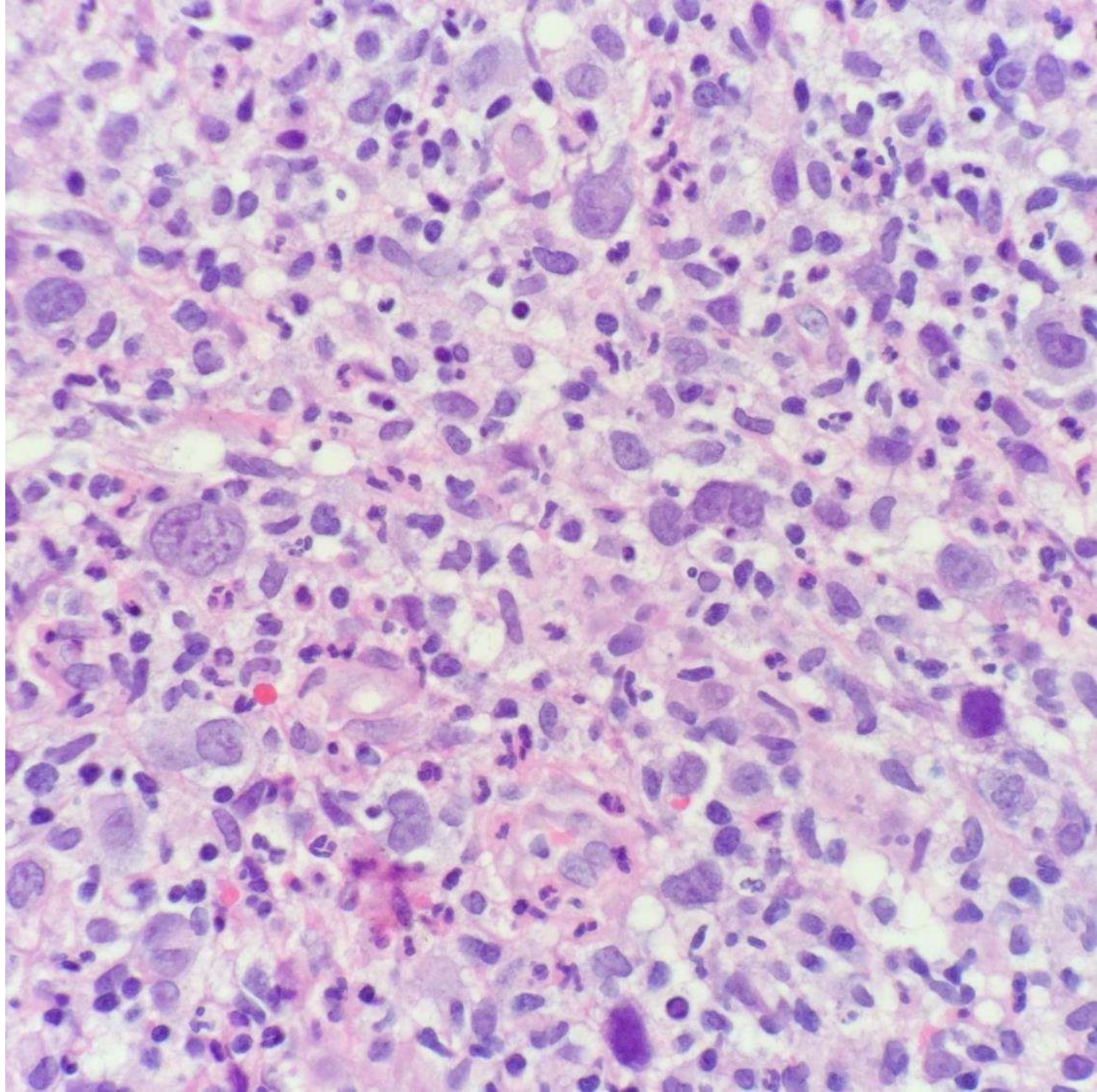
- 65-year-old woman with an esophageal stricture.



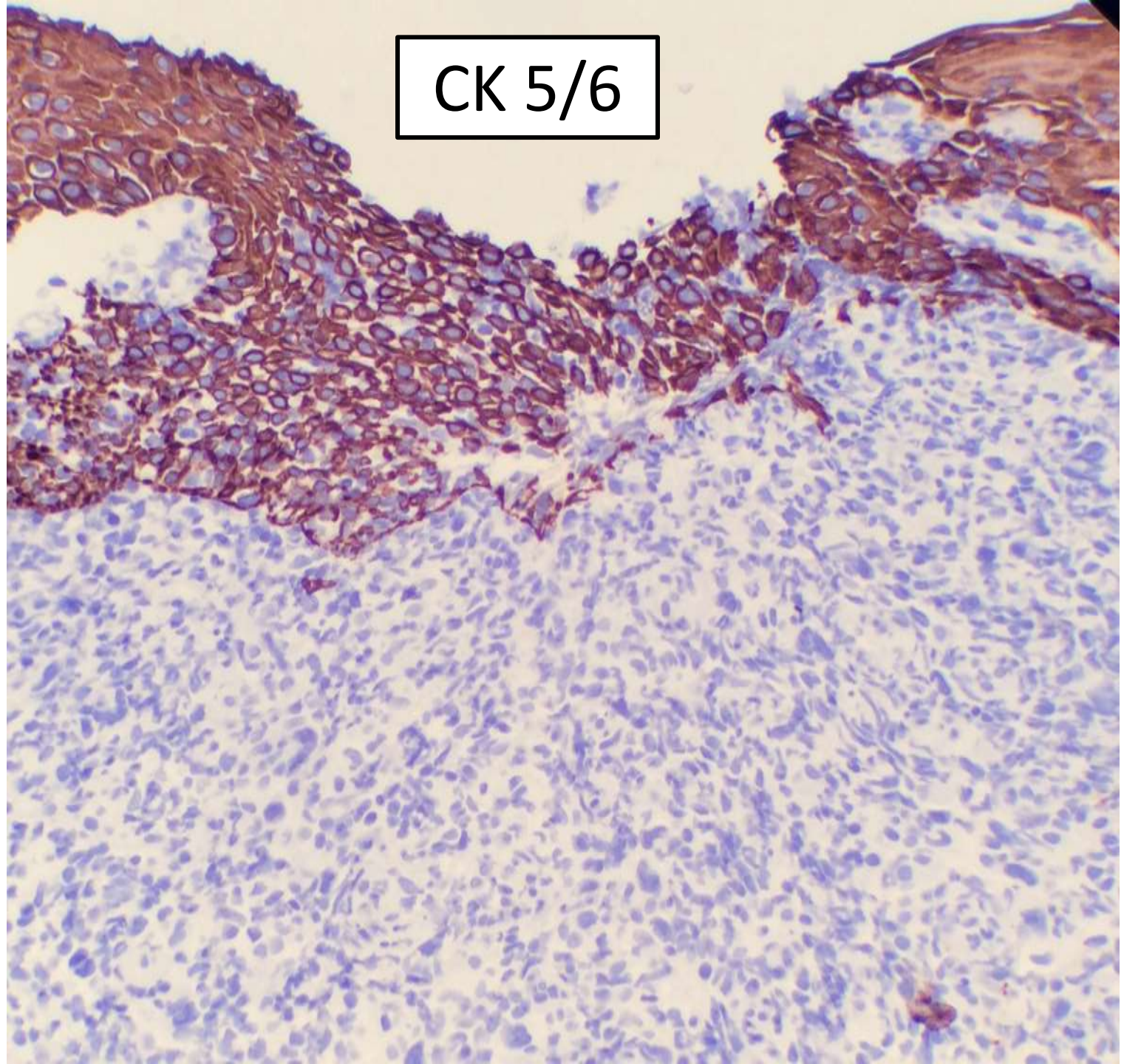






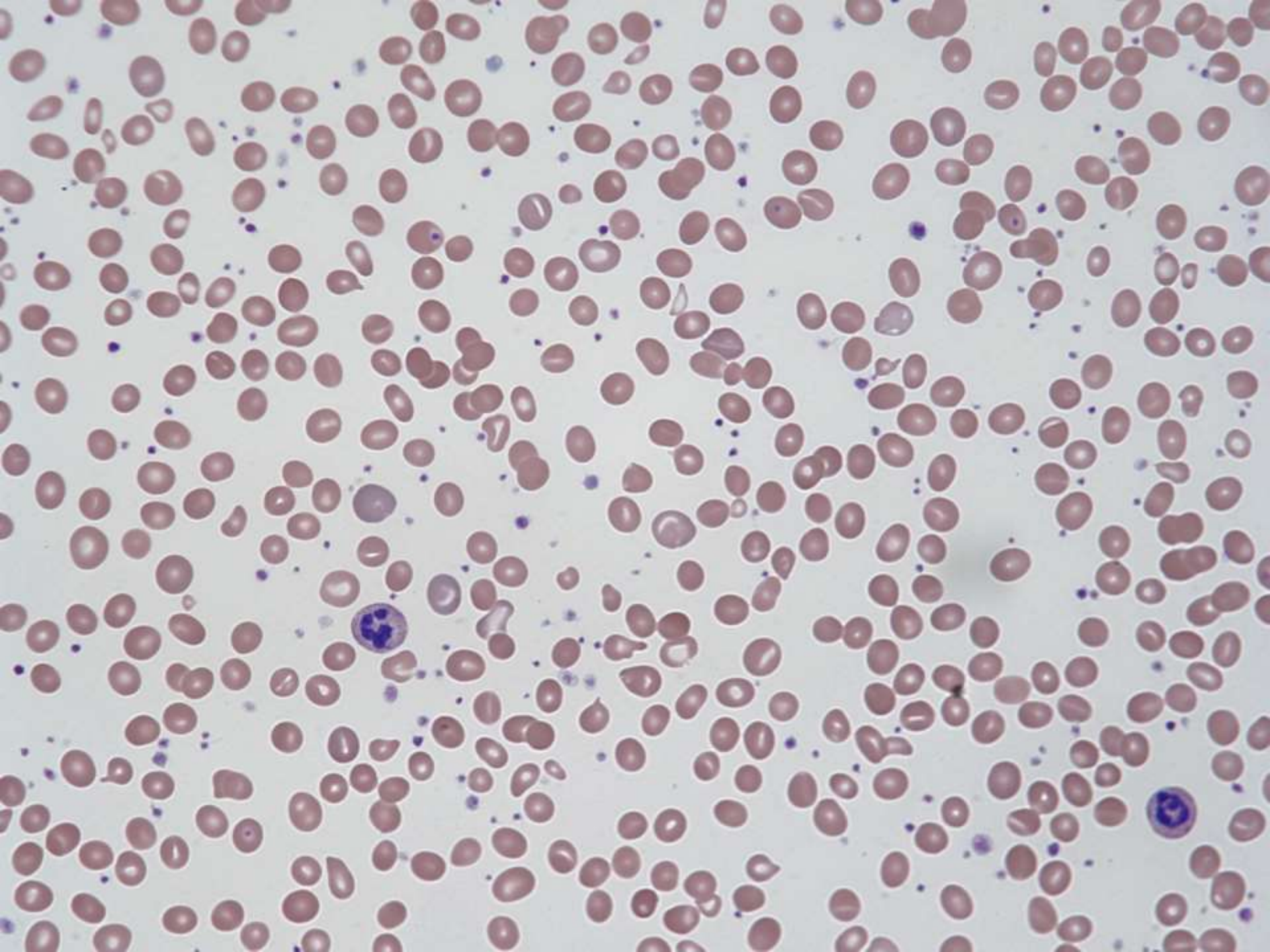


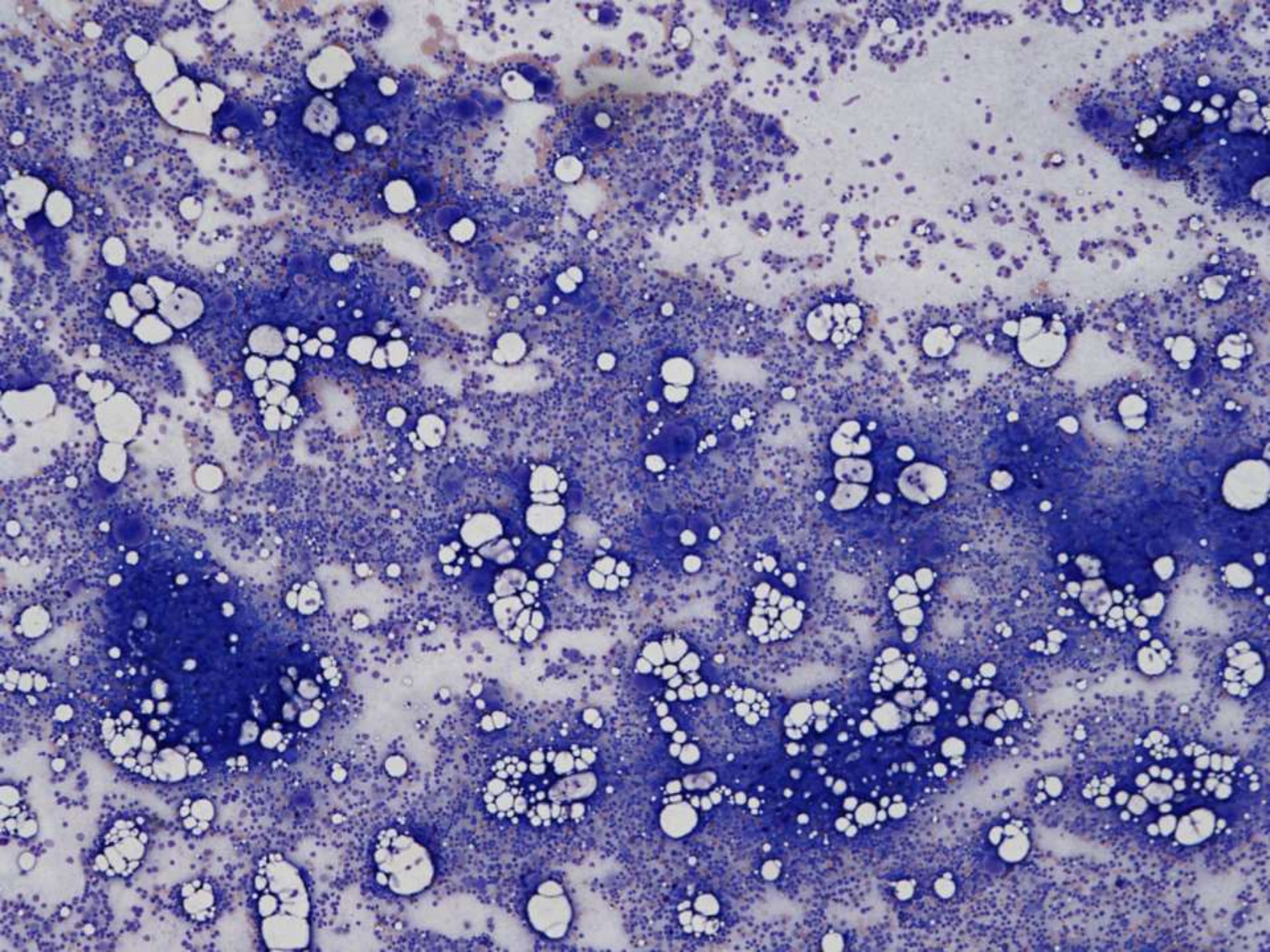
CK 5/6

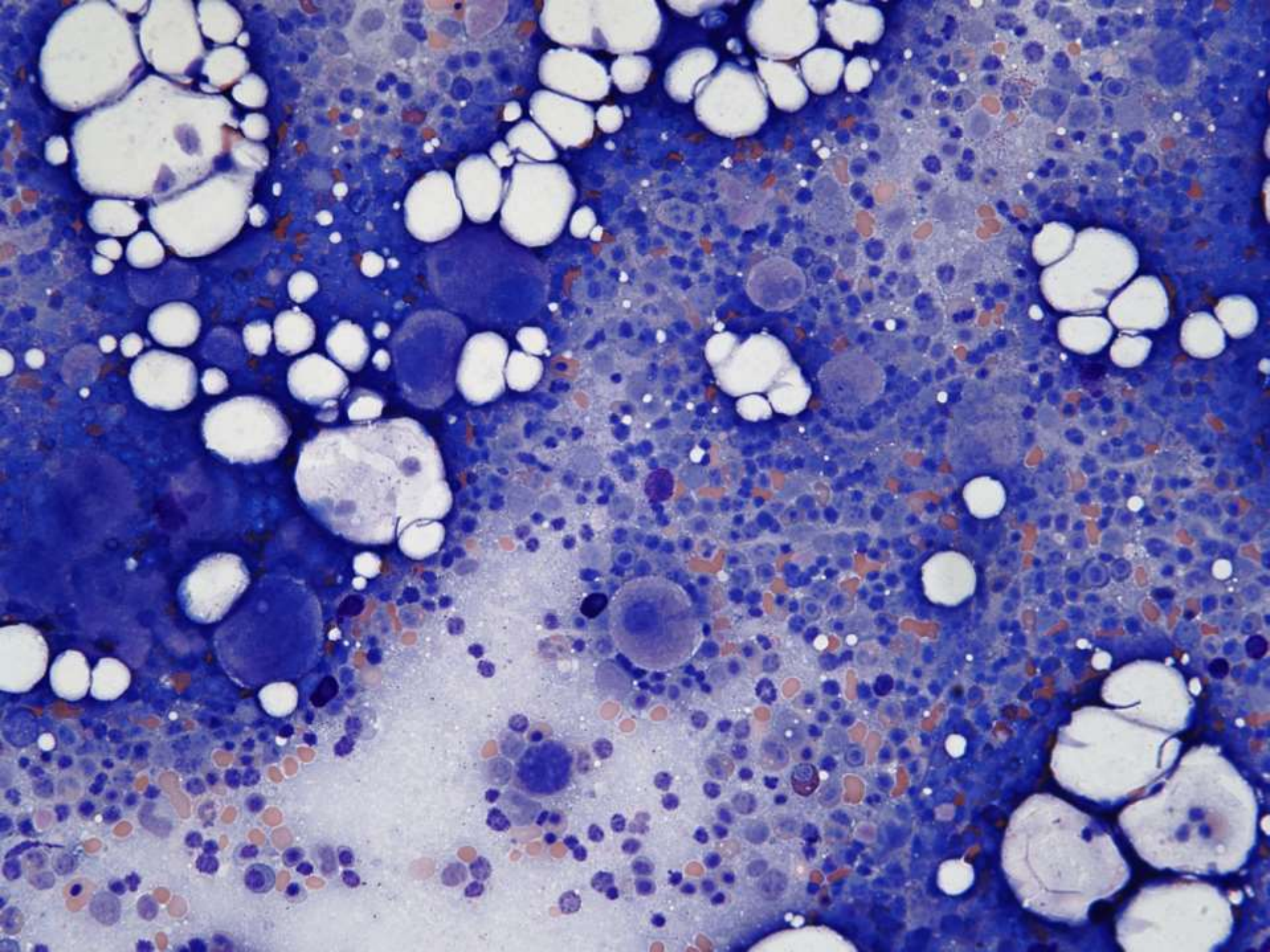


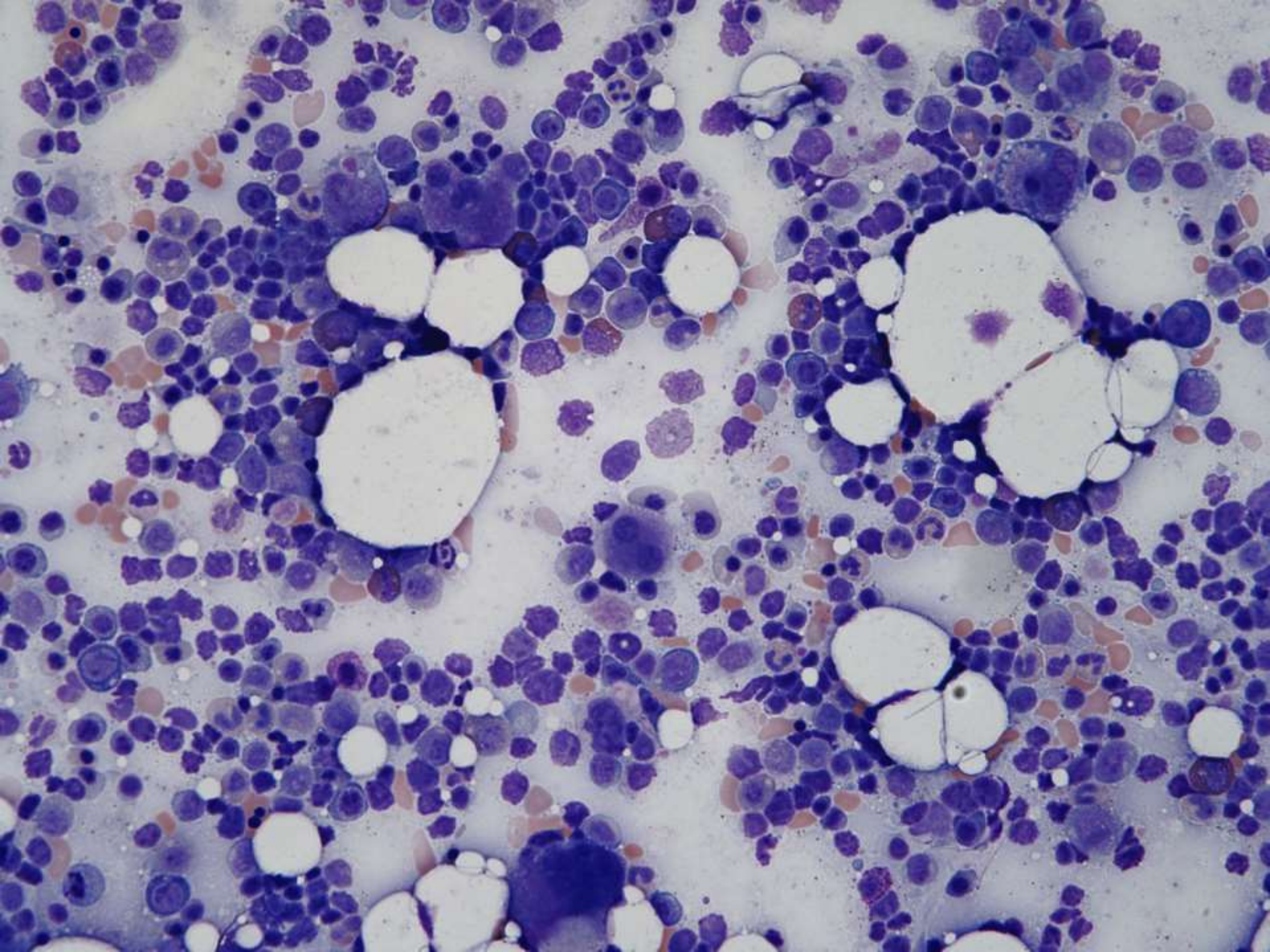
SB 5869

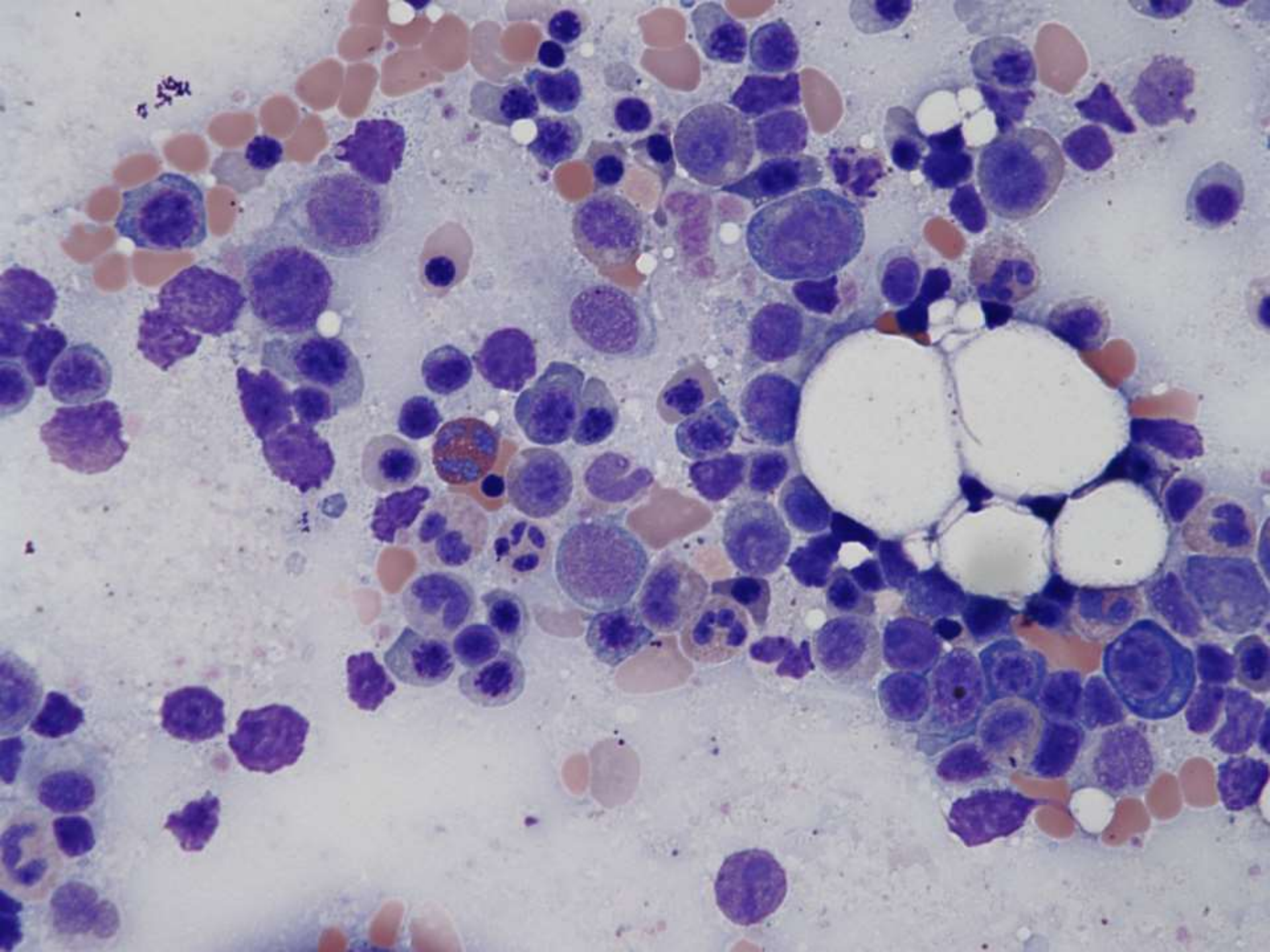
- 67-year-old man with several year history of anemia. Peripheral blood smear and bone marrow biopsy submitted.
- CBC data: WBC: $4.2 \times 10^9/L$ RBC: $1.82 \times 10^9/L$ Hgb 8.1 g/dl MCV 127 fL RDW 18.1% Plt: $677 \times 10^9/L$

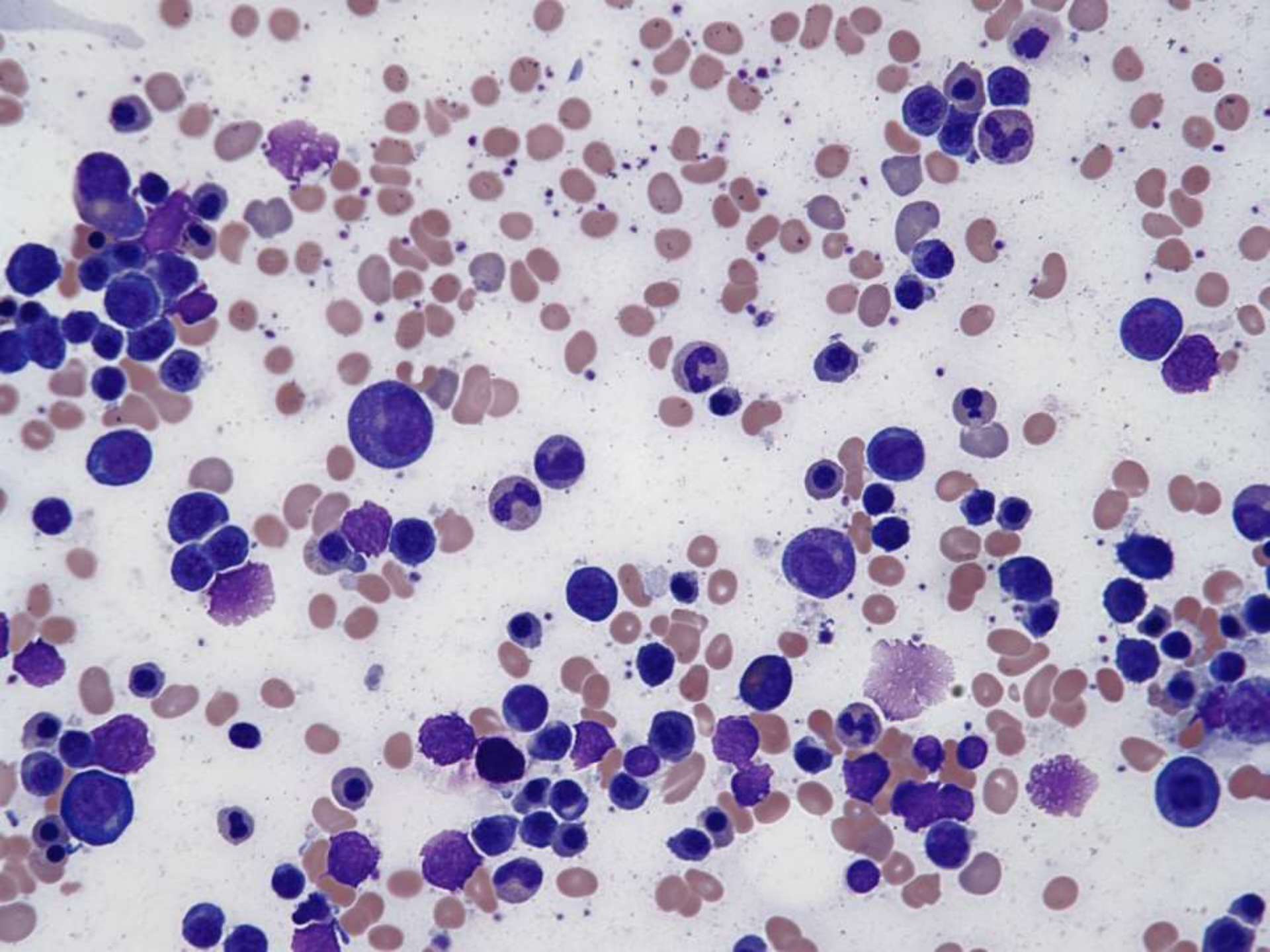


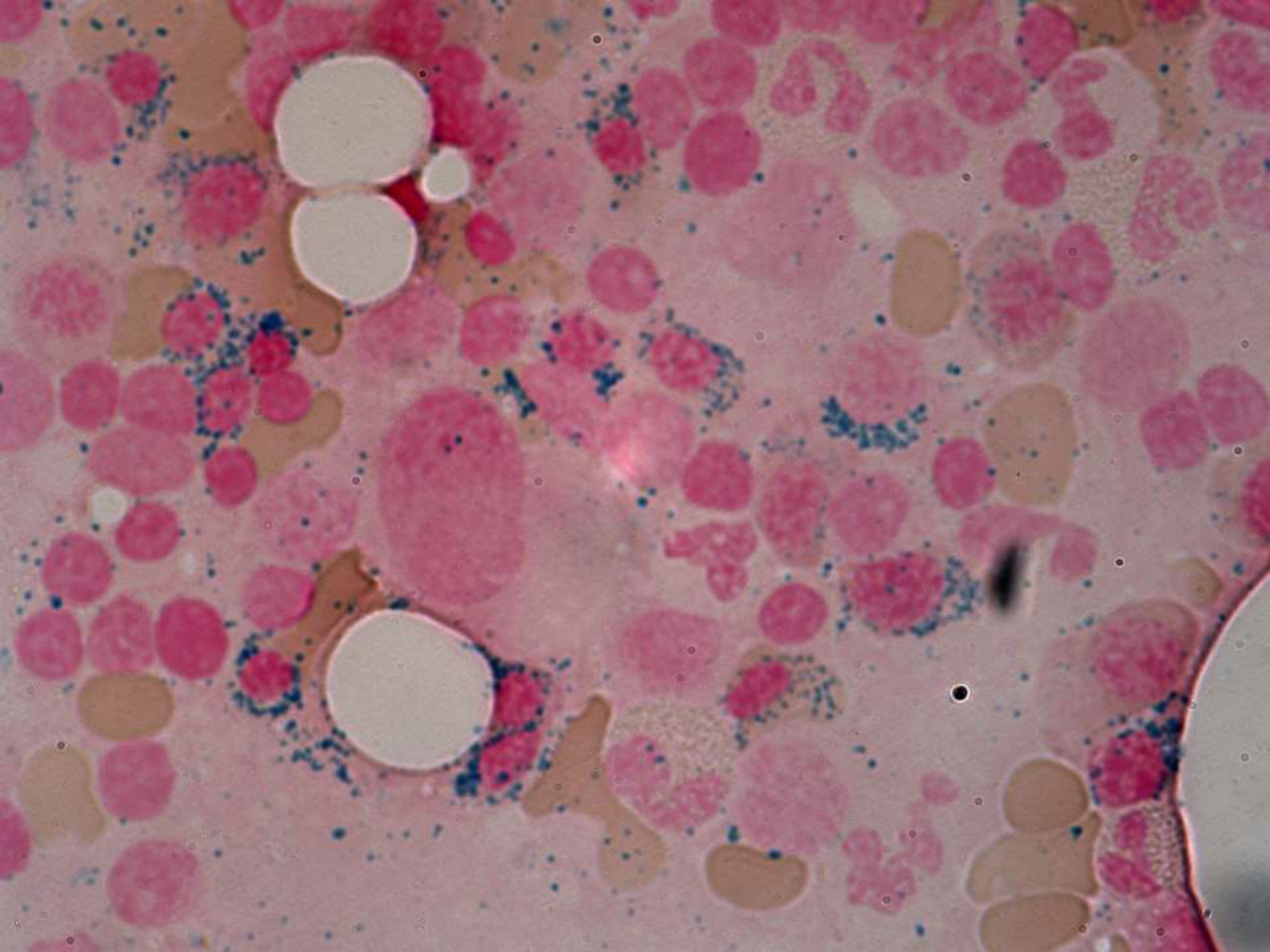






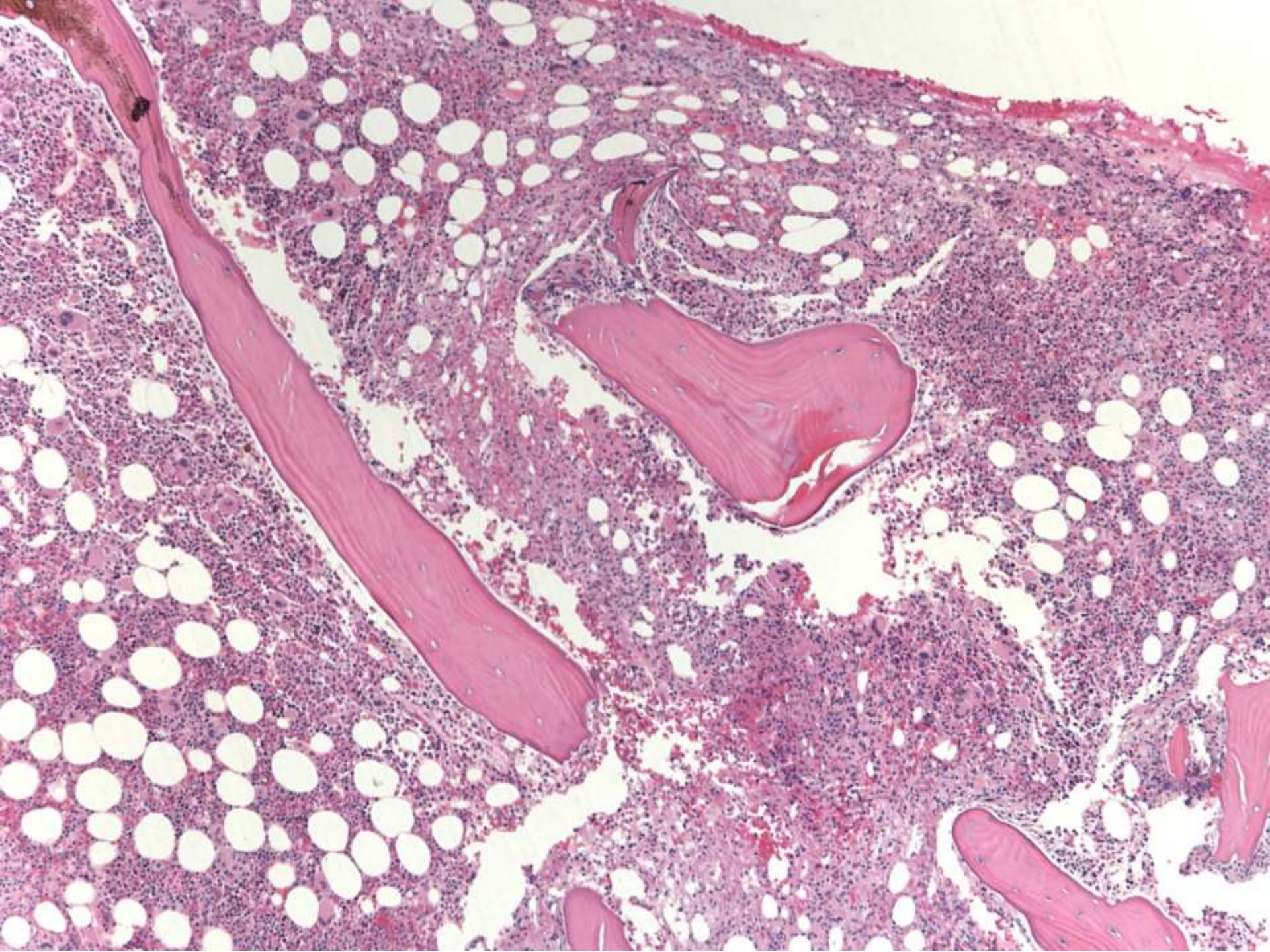


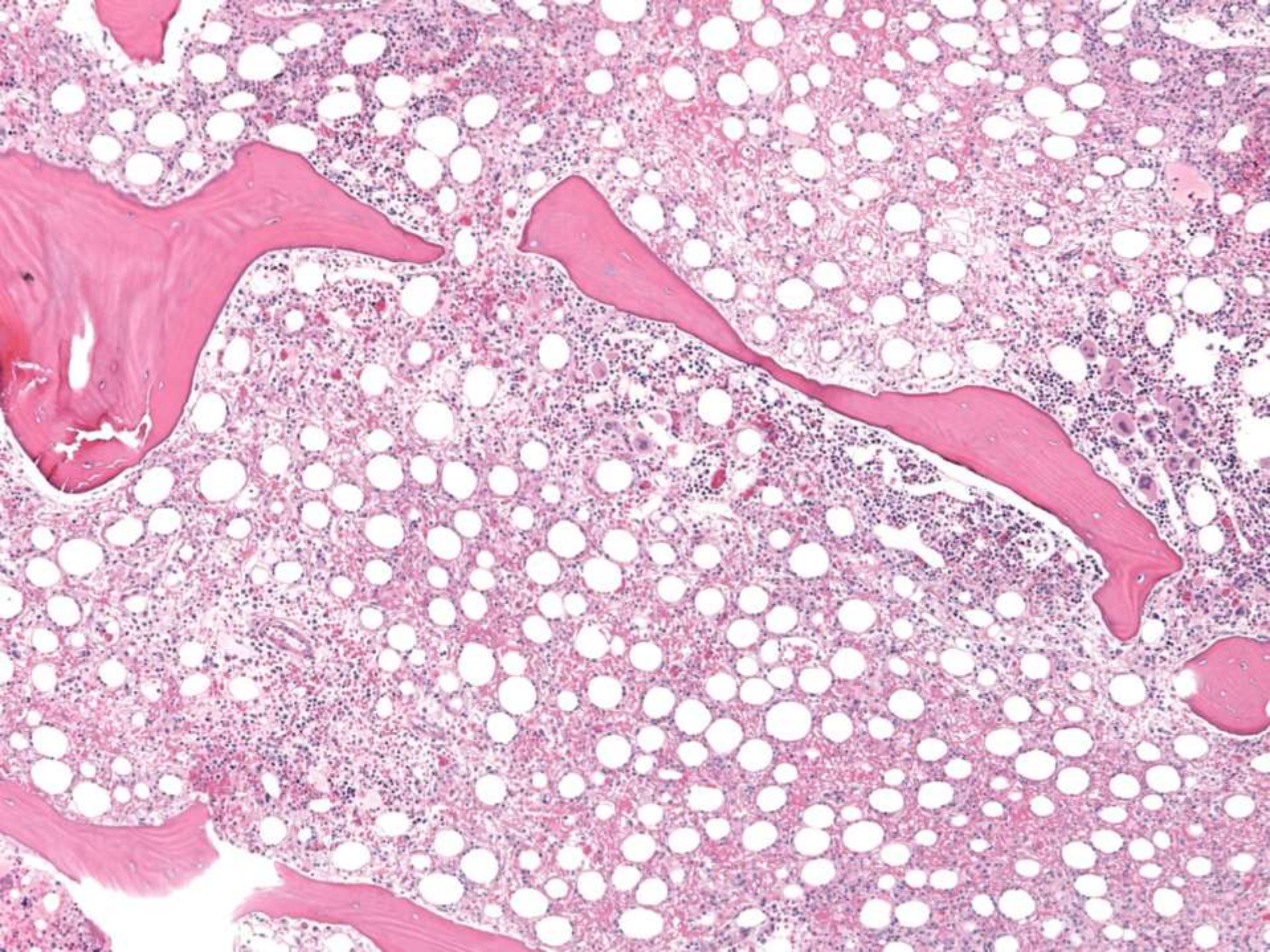


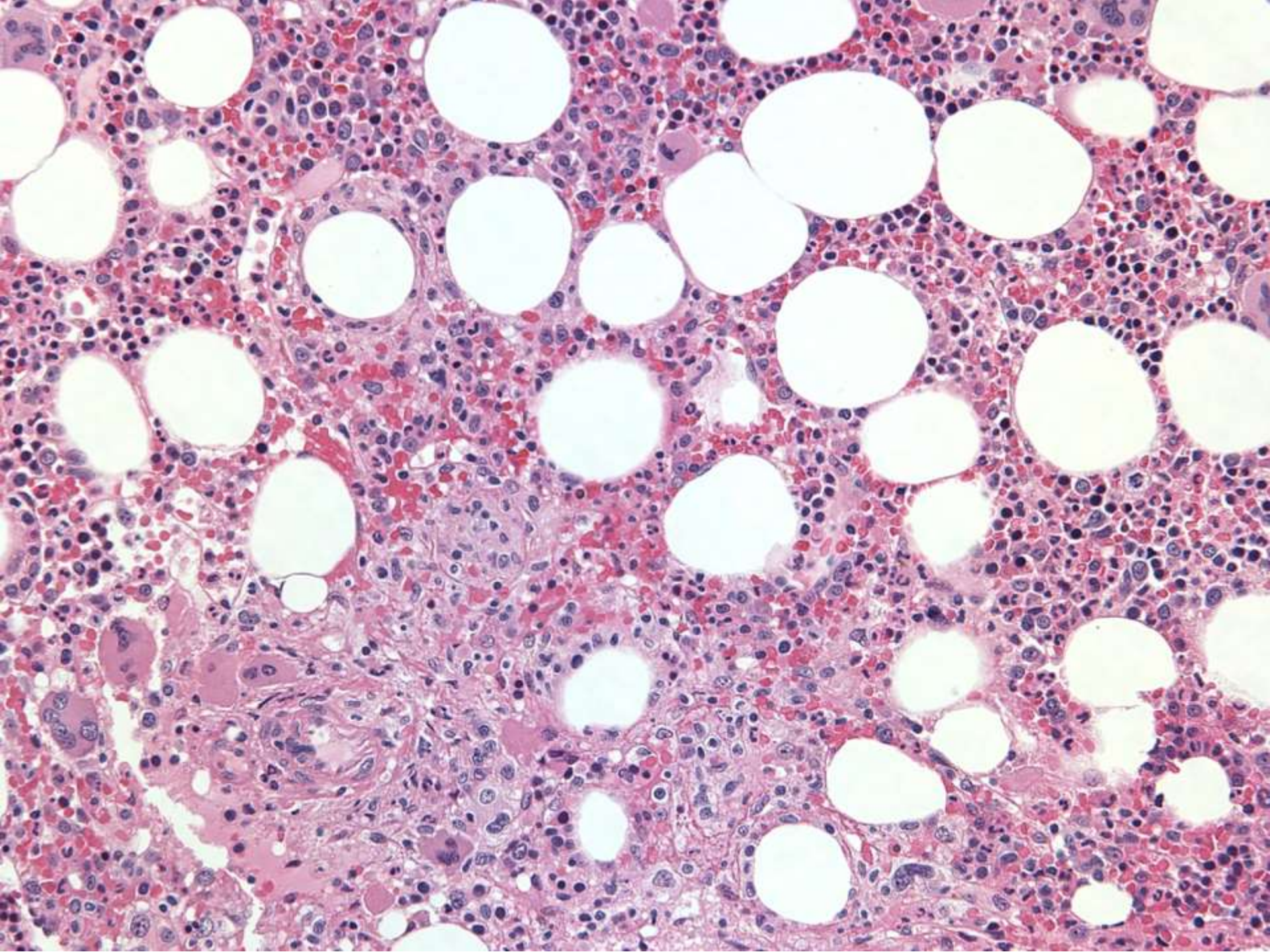


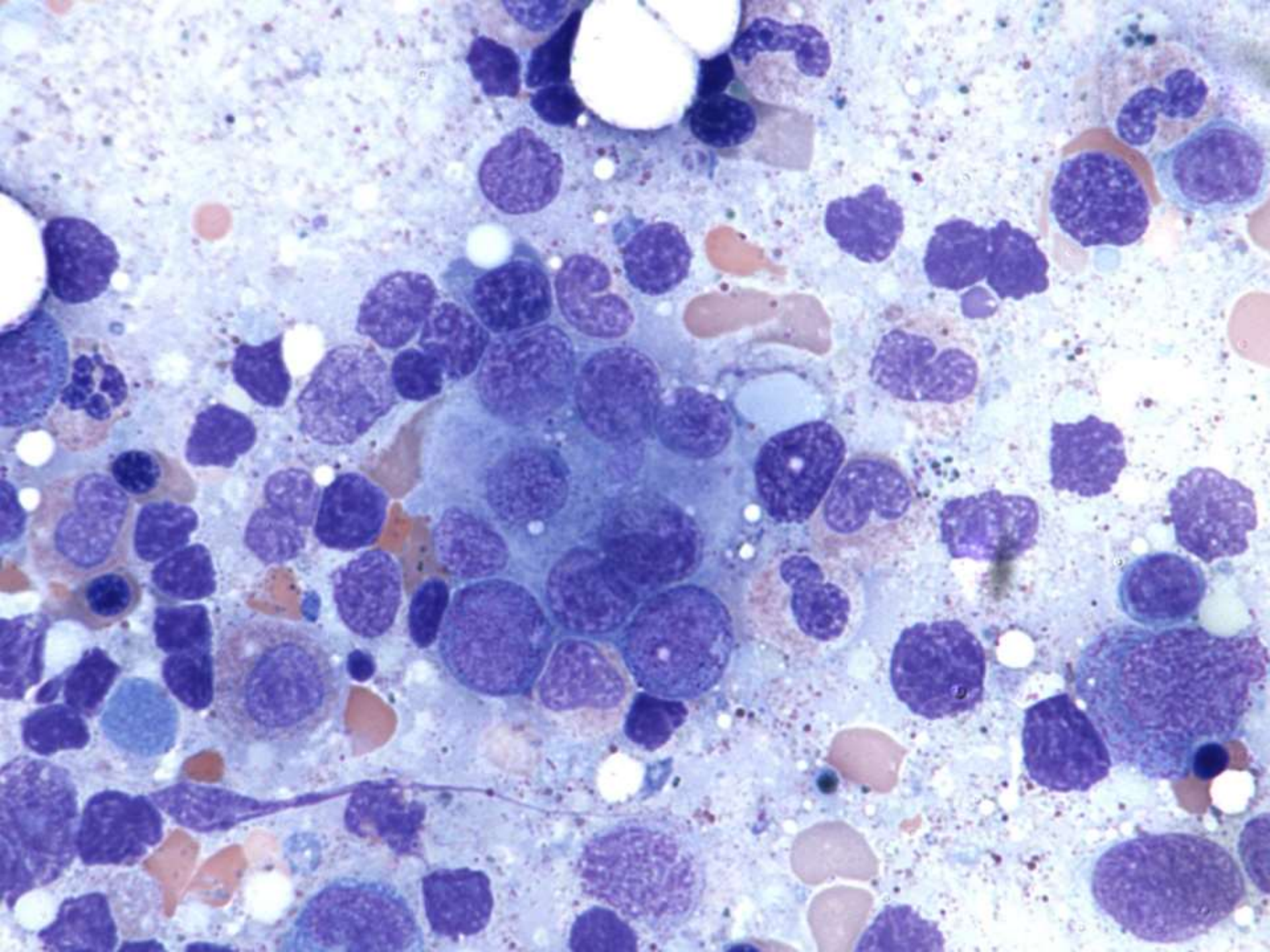
SB 5870

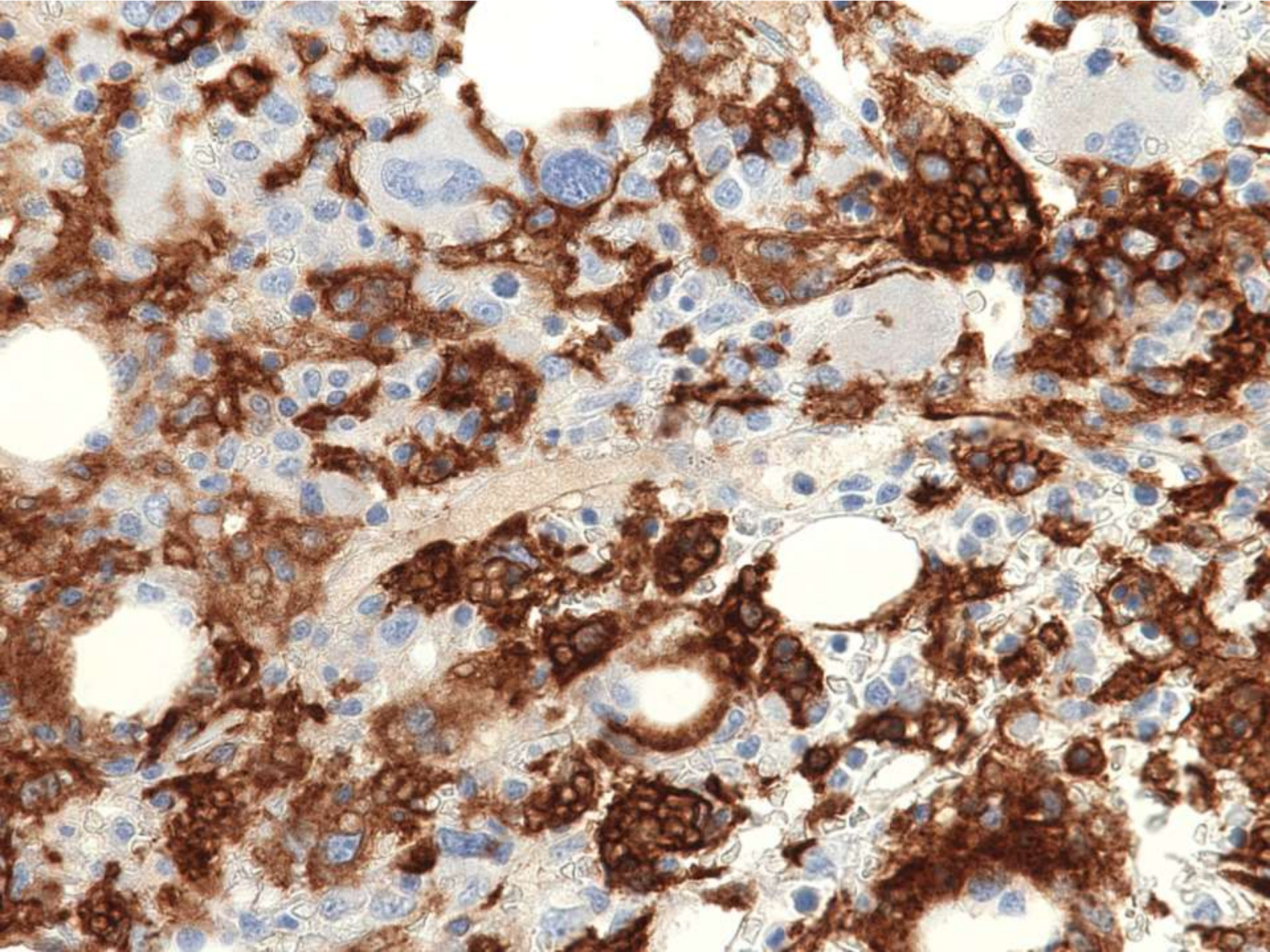
- 39-year-old woman status post 6 cycles of R-CHOP and cardiomyopathy with persistent low grade fevers, hepatomegaly of unclear cause. Patient on caspofungin for presumed fungemia. Bone marrow biopsy performed.











See you Monday!

Remember,
we need cases