

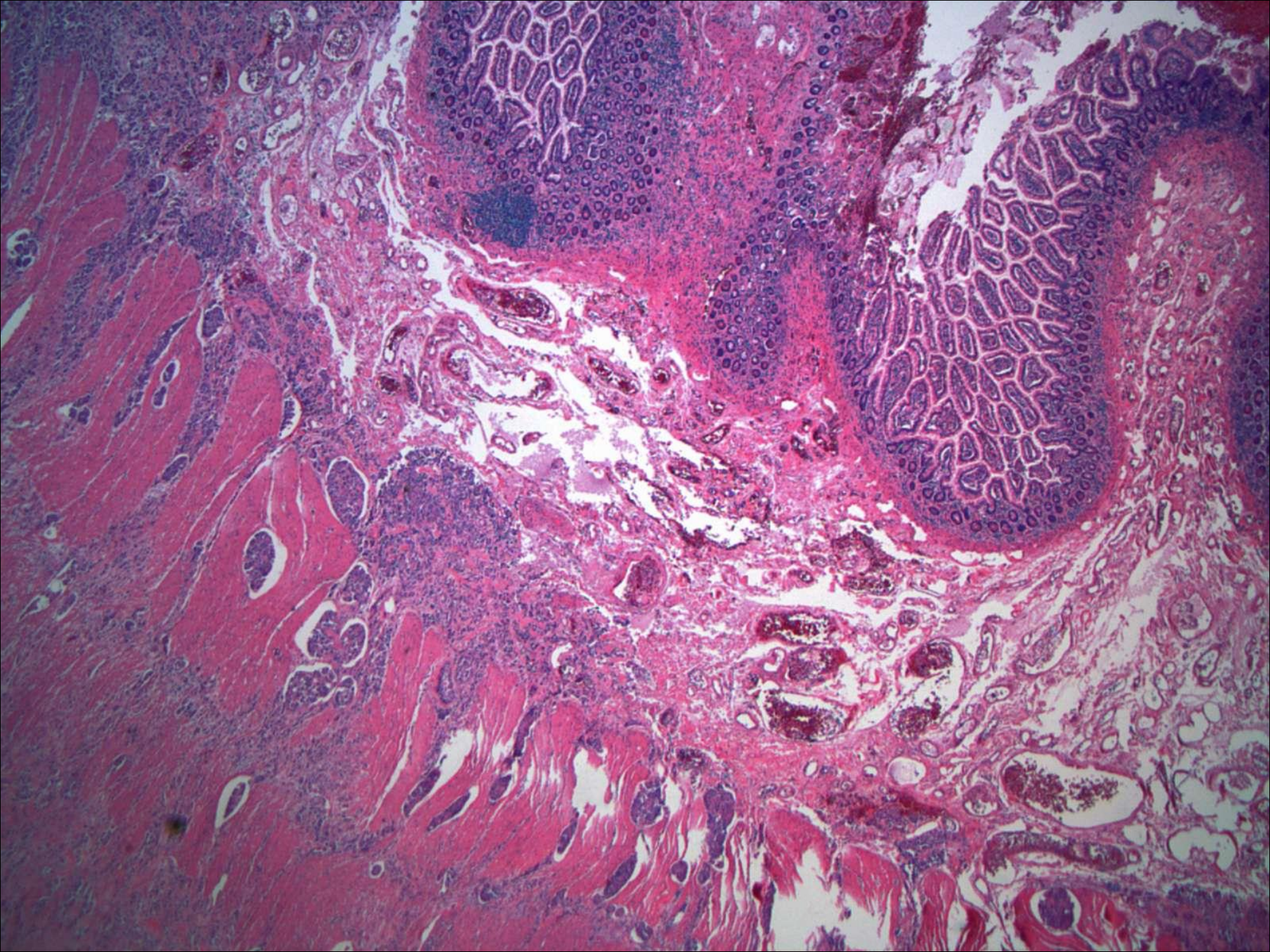
South Bay Pathology Society

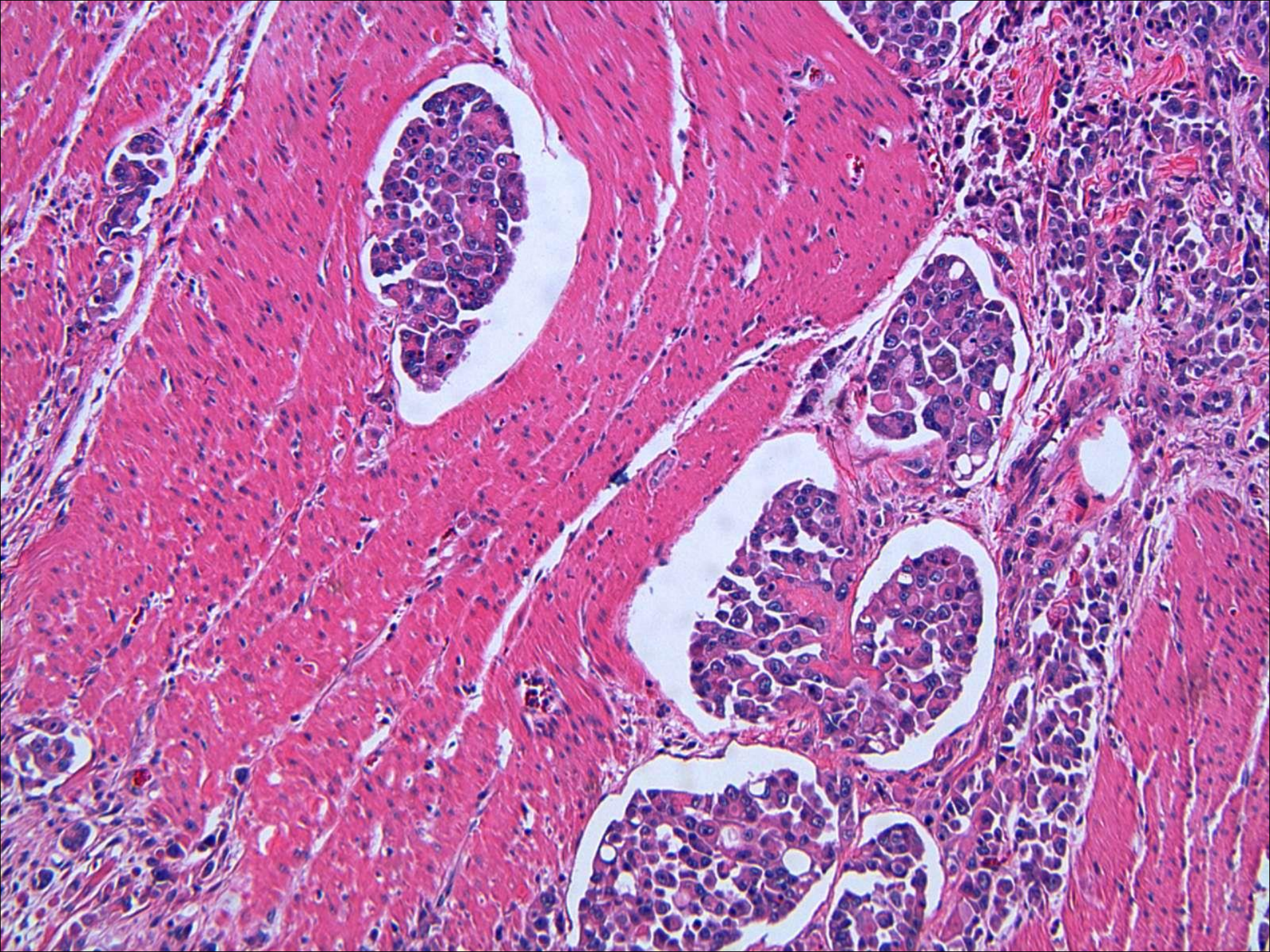
July 7, 2014

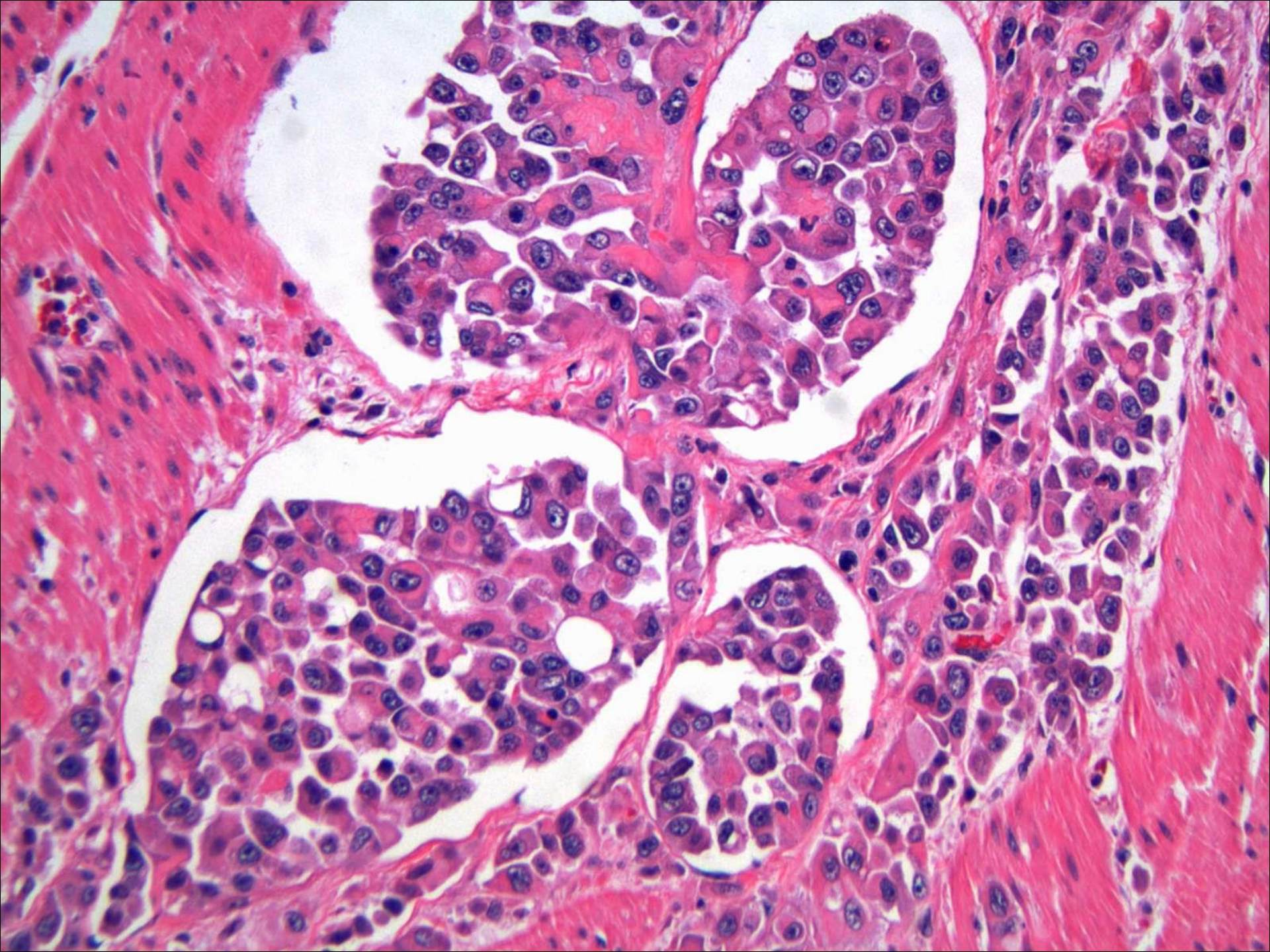
SB 5841

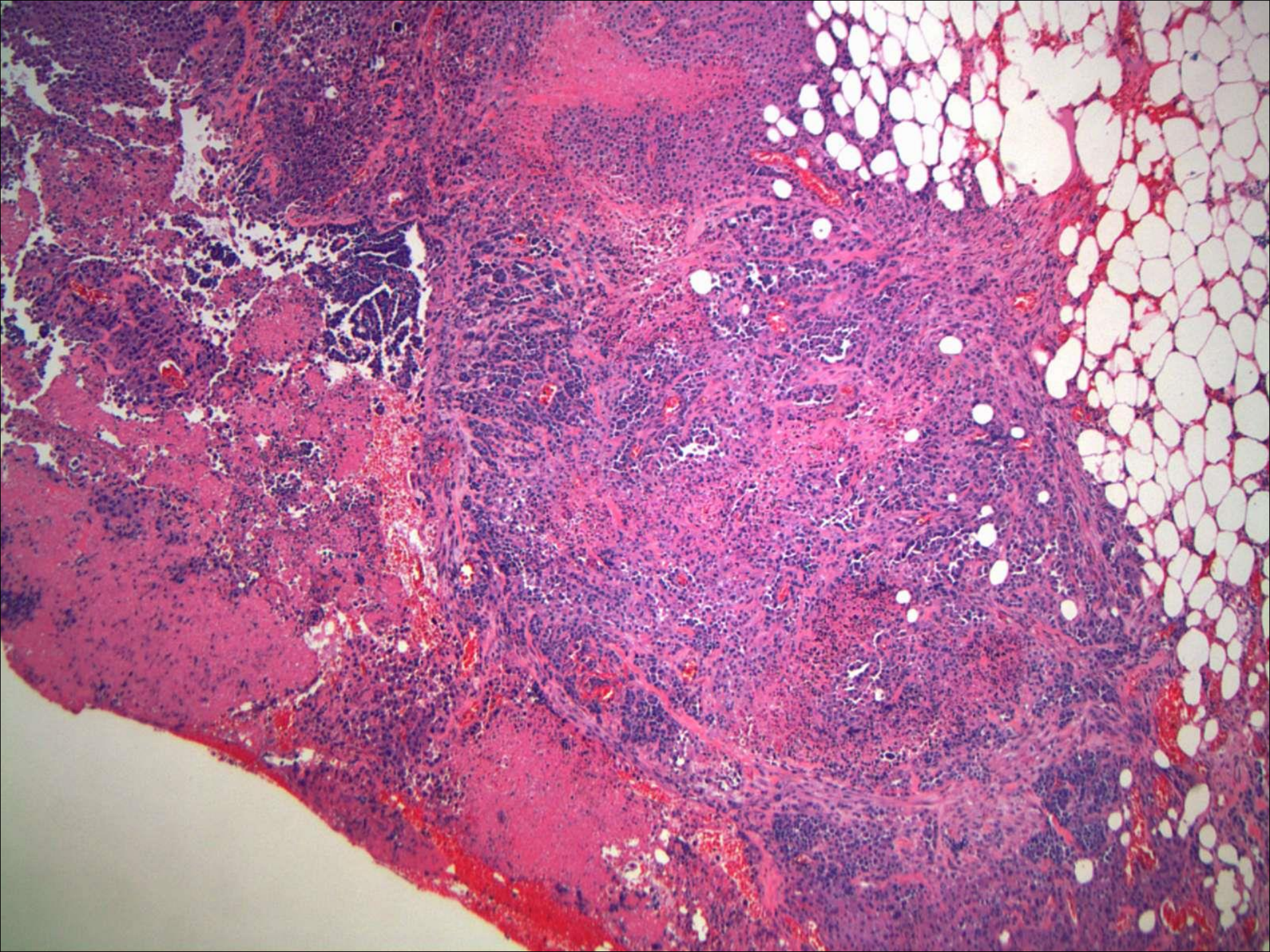
Mahendra Ranchod; Good Samaritan Hospital

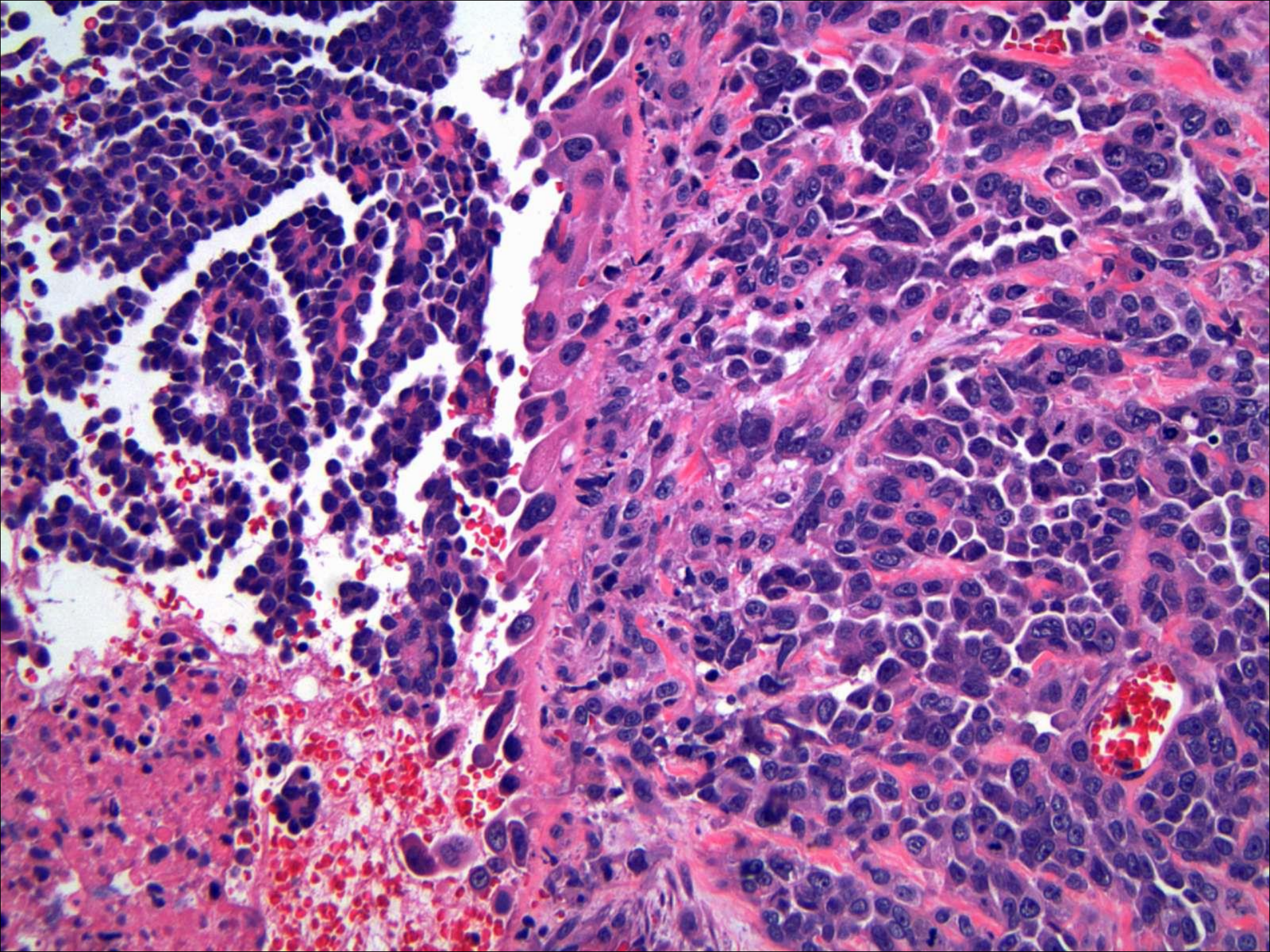
74-year-old woman with 3 month history of abdominal pain and weight loss. Presented with intestinal obstruction.







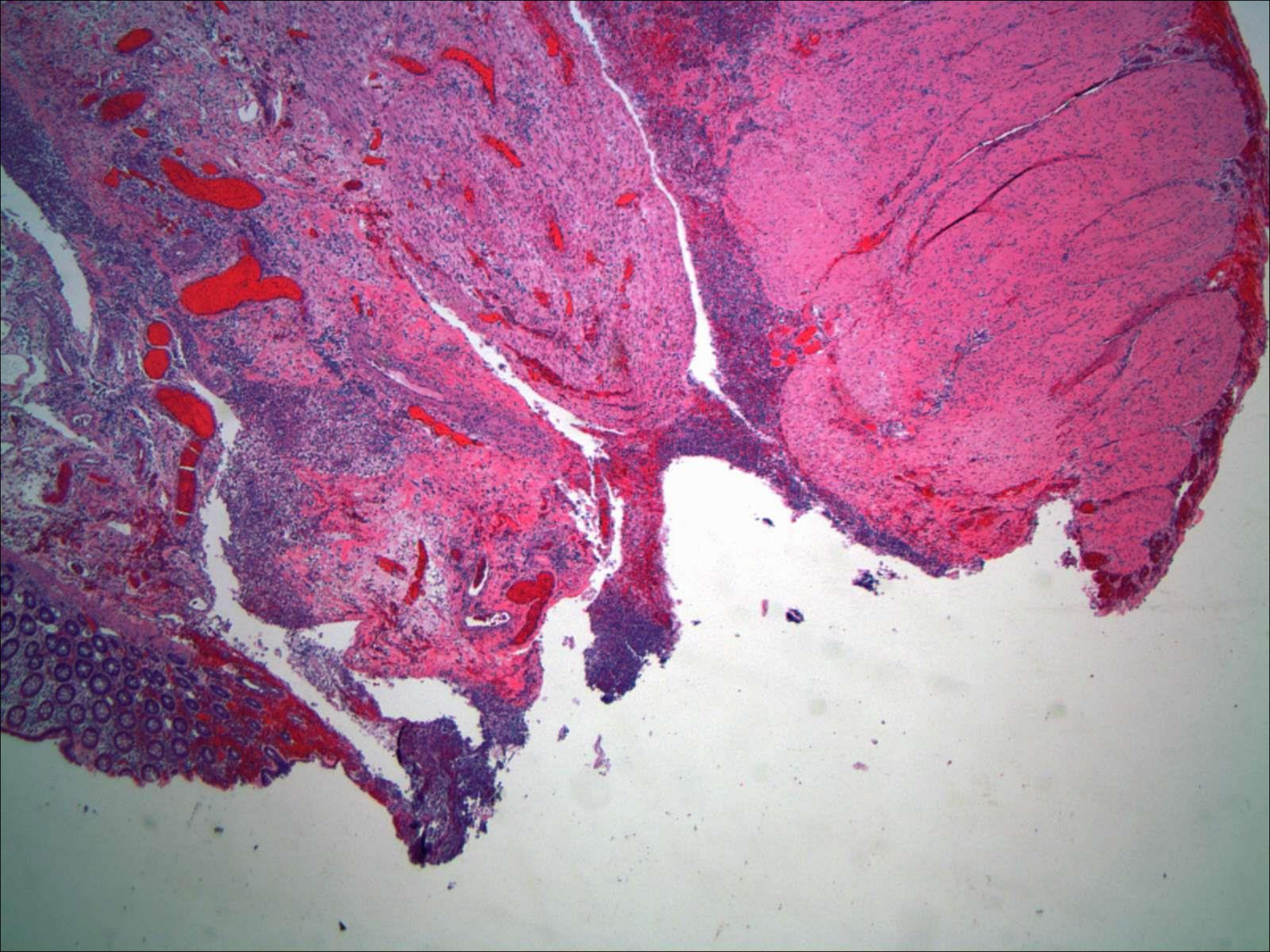


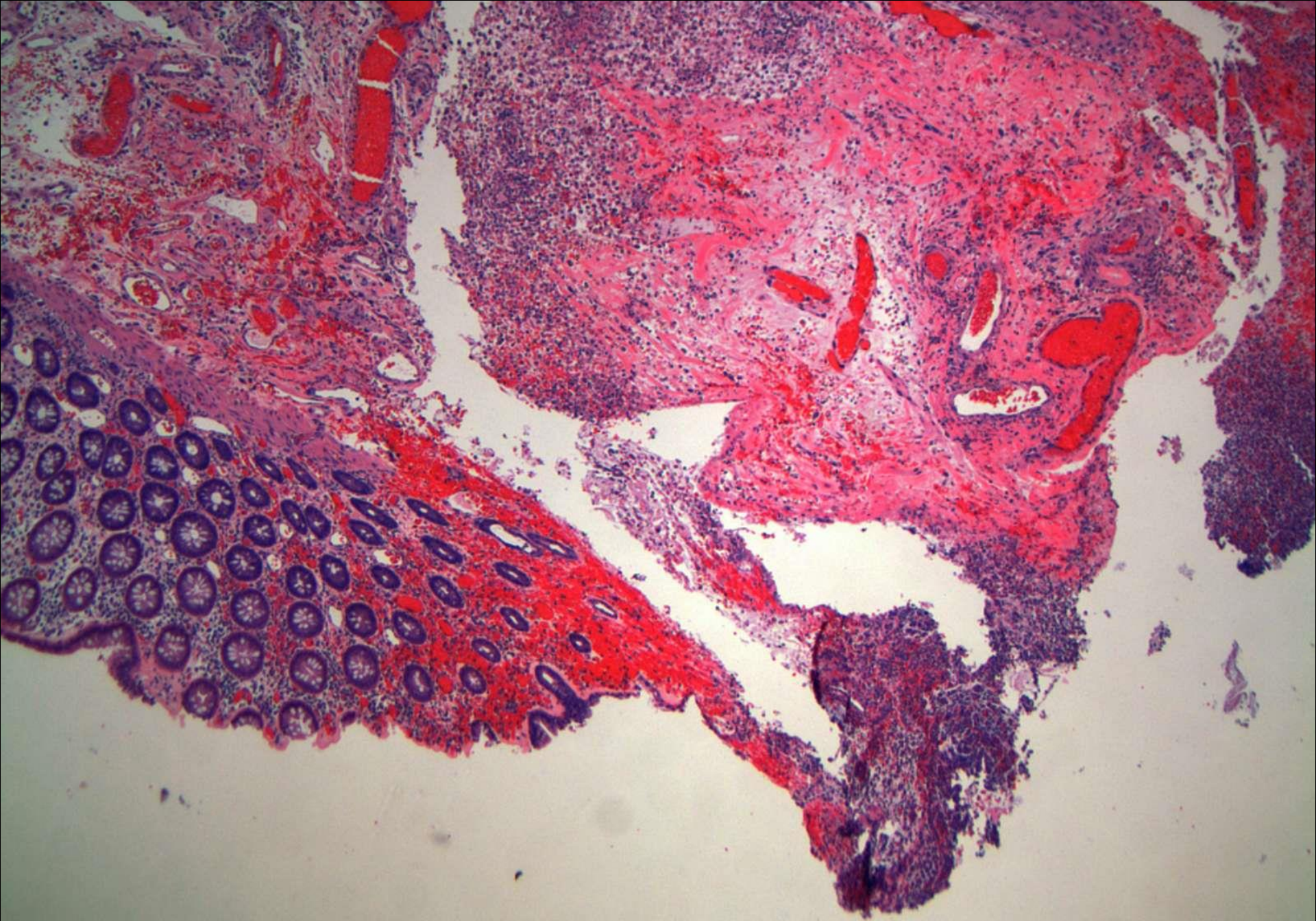


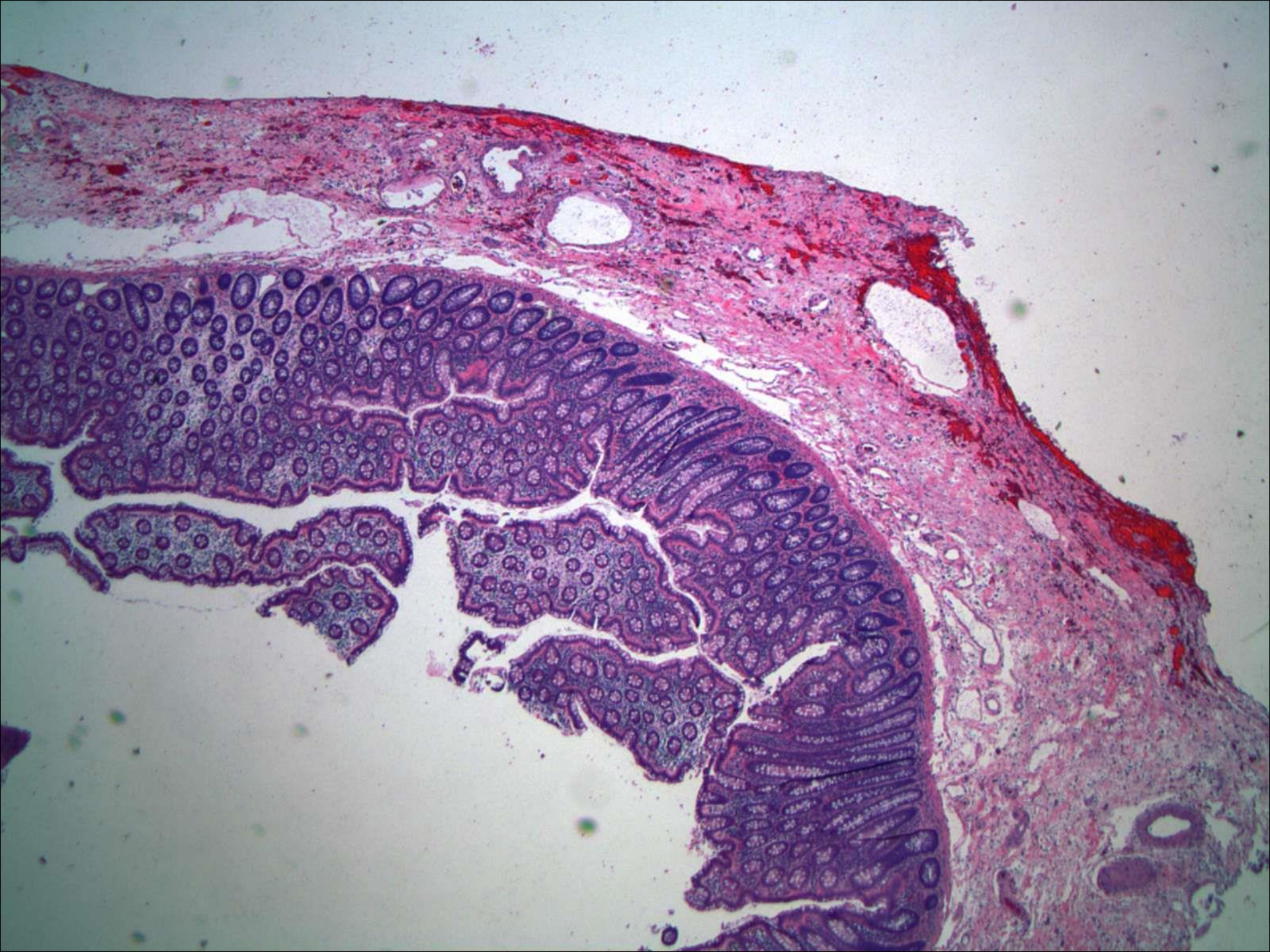
SB 5842

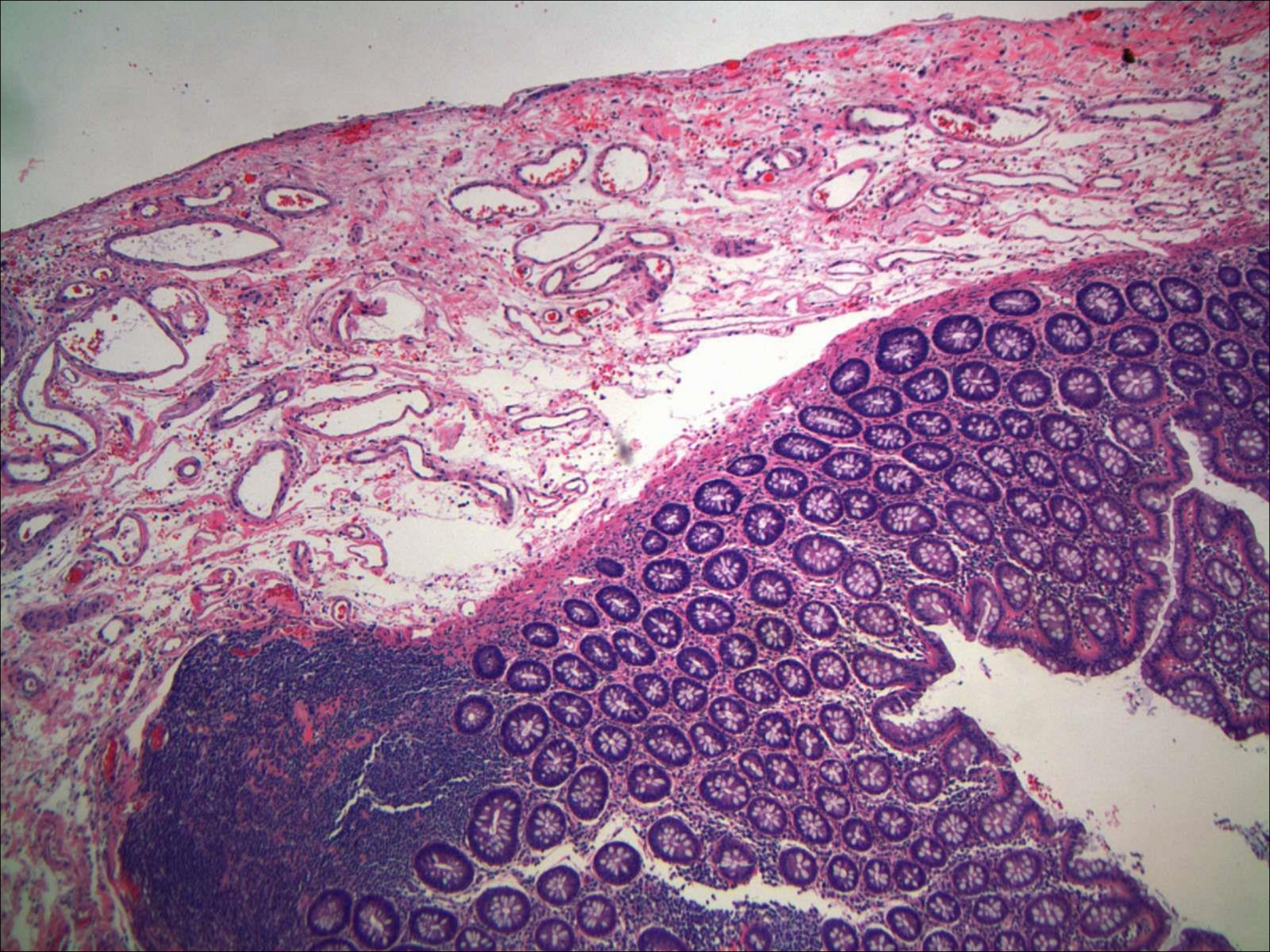
Mahendra Ranchod; Good Samaritan Hospital

88-year-old man with perforation
of sigmoid colon.





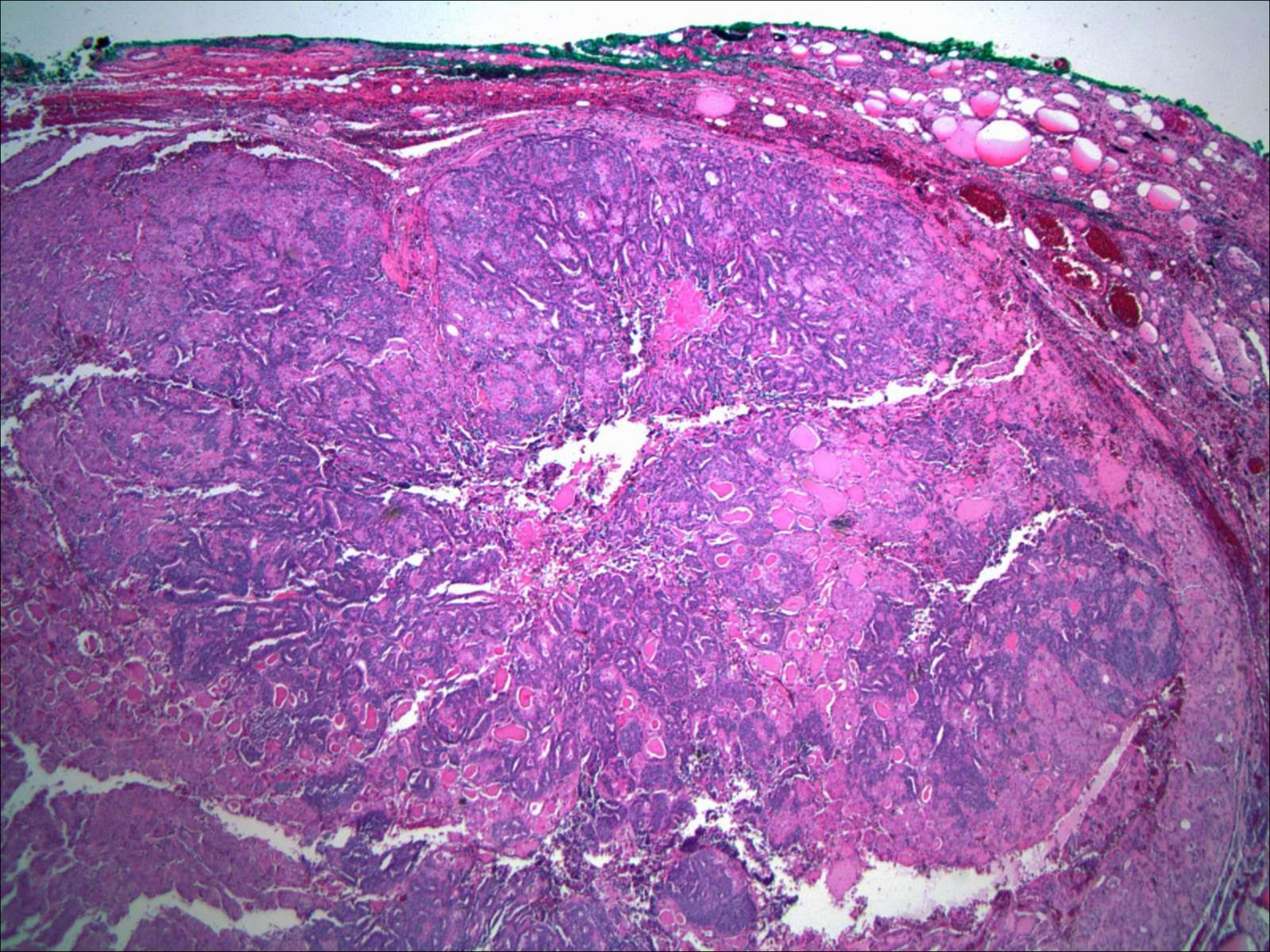


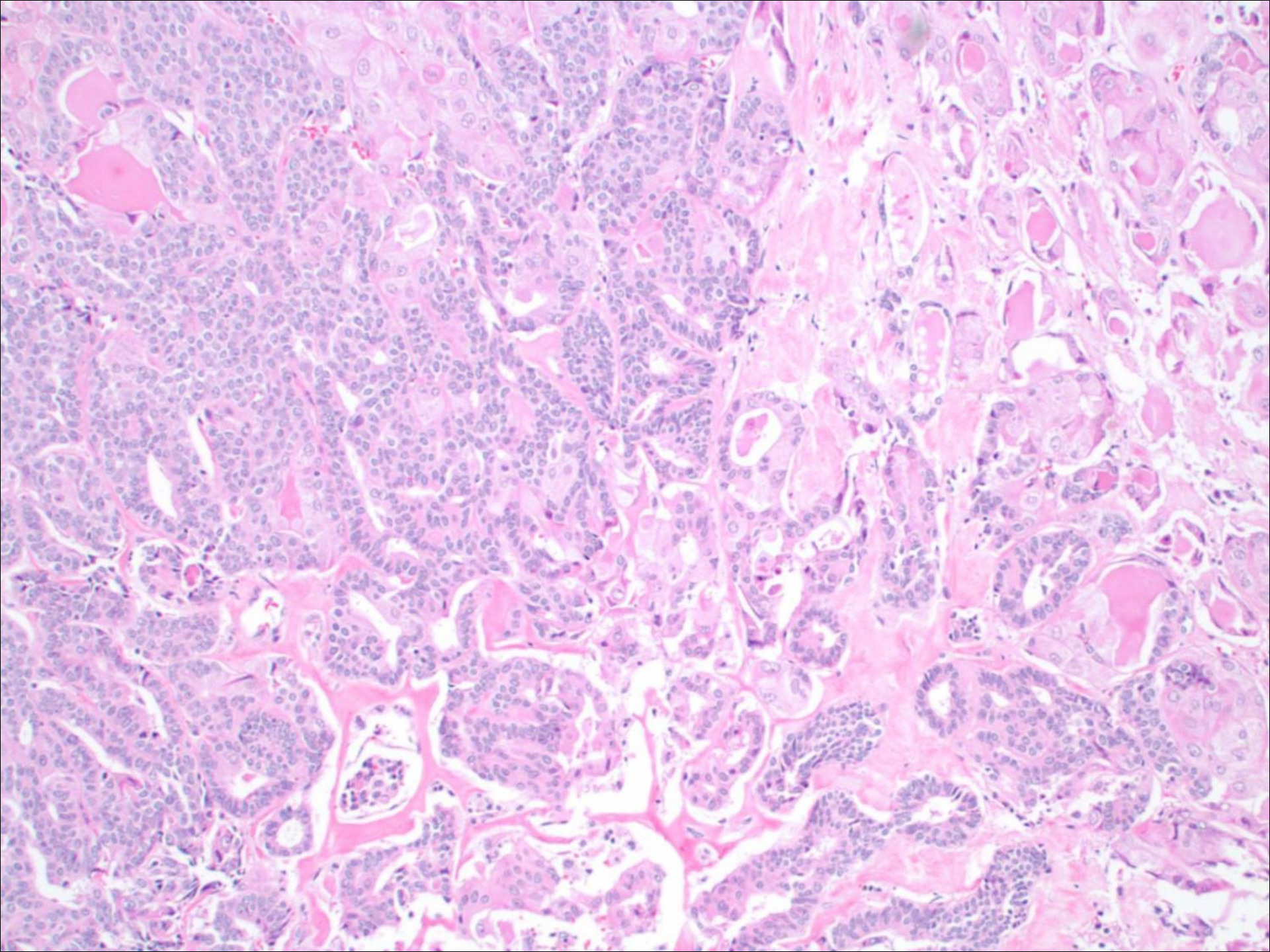


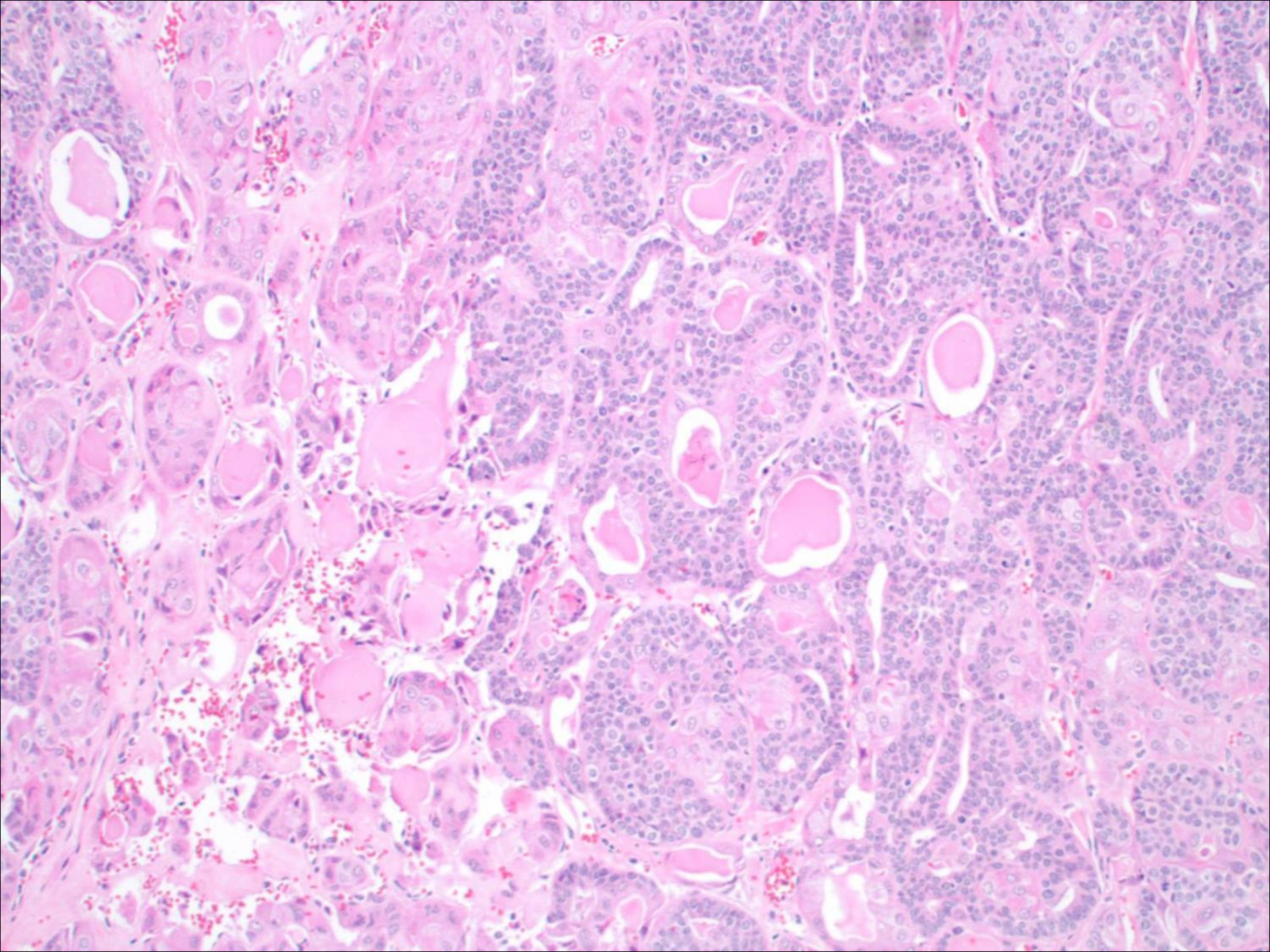
SB 5843

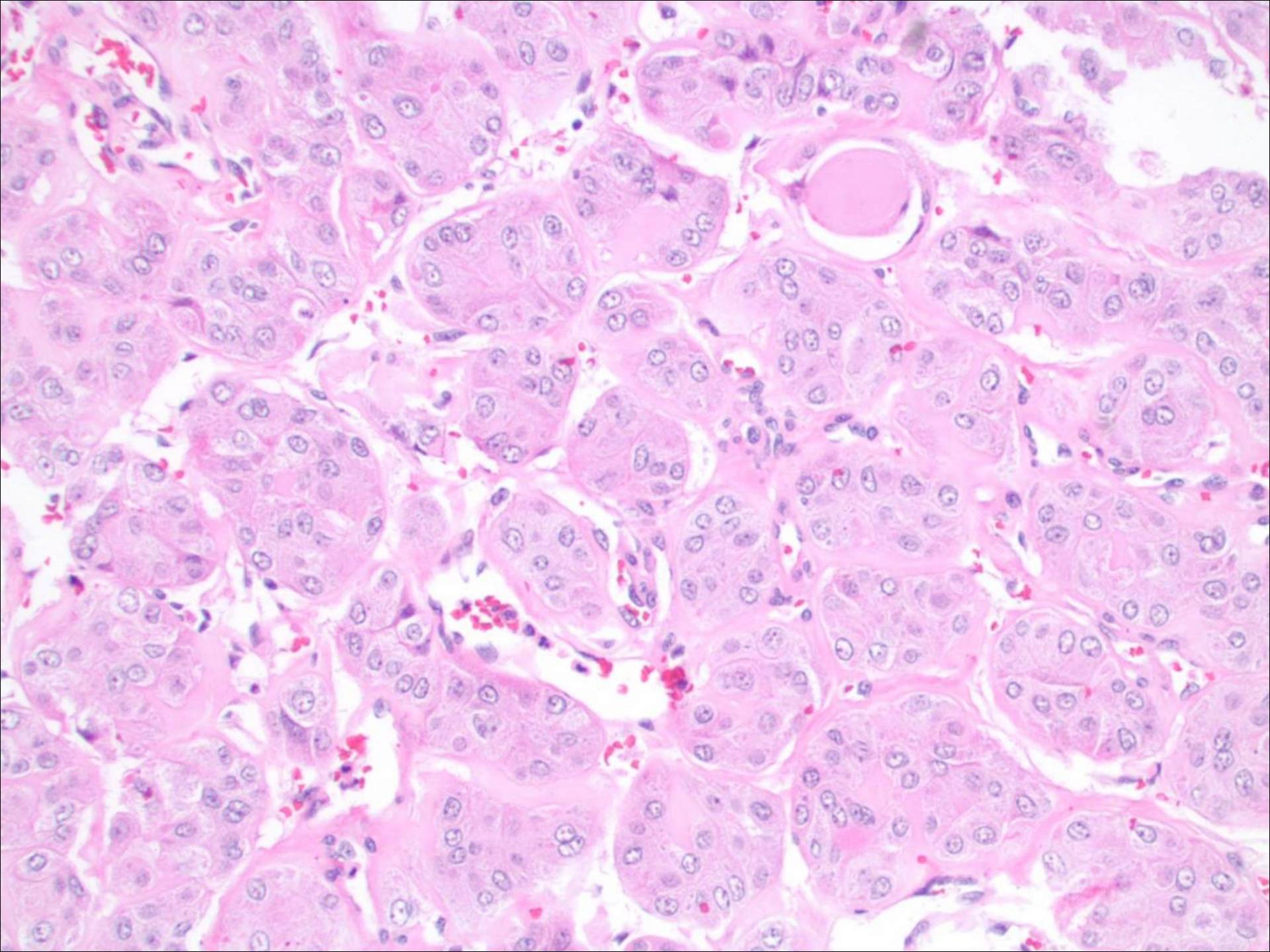
Will Rogers; El Camino Hospital

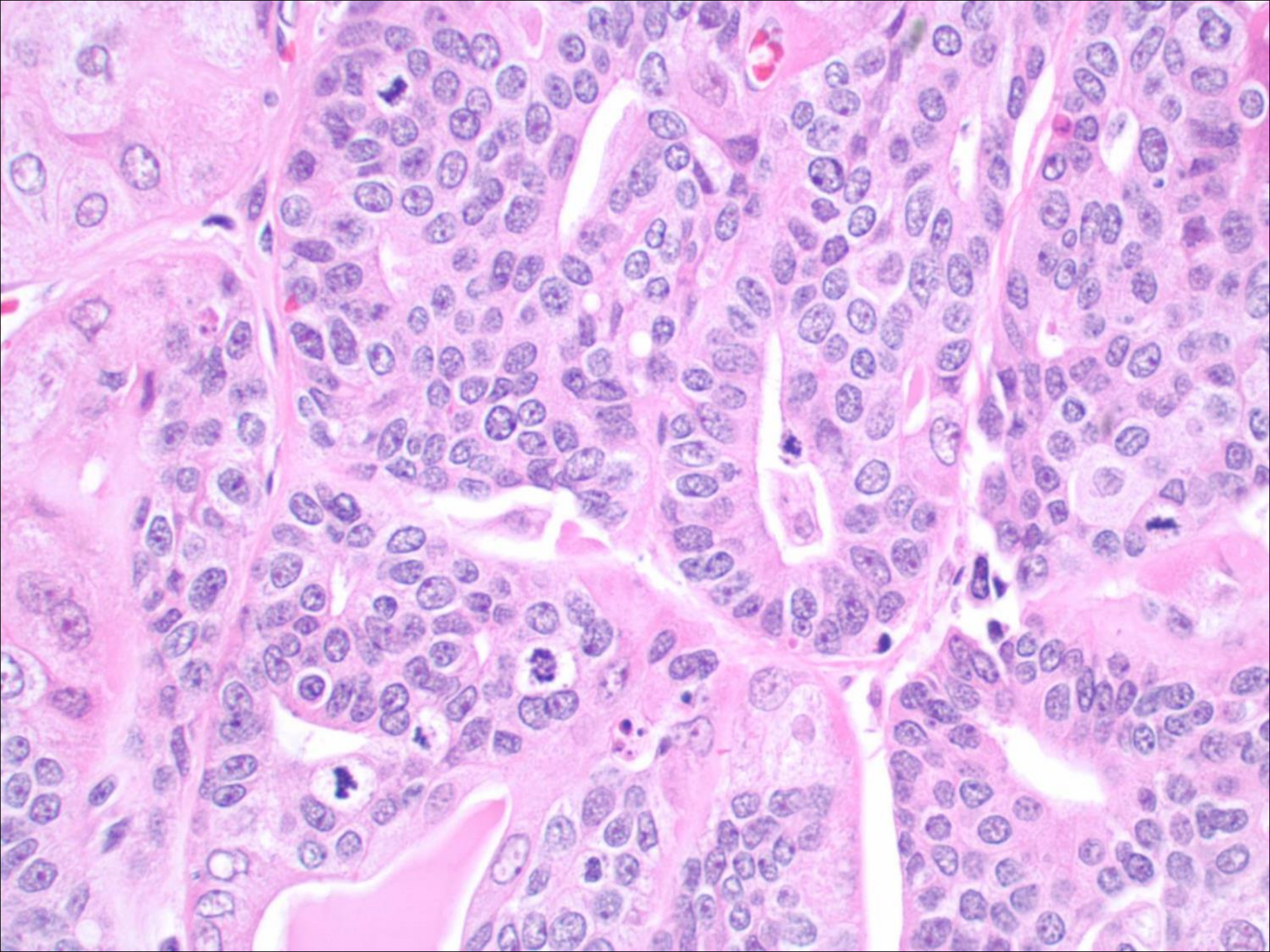
39-year-old female presenting for total thyroidectomy for outside diagnosis of papillary thyroid carcinoma.







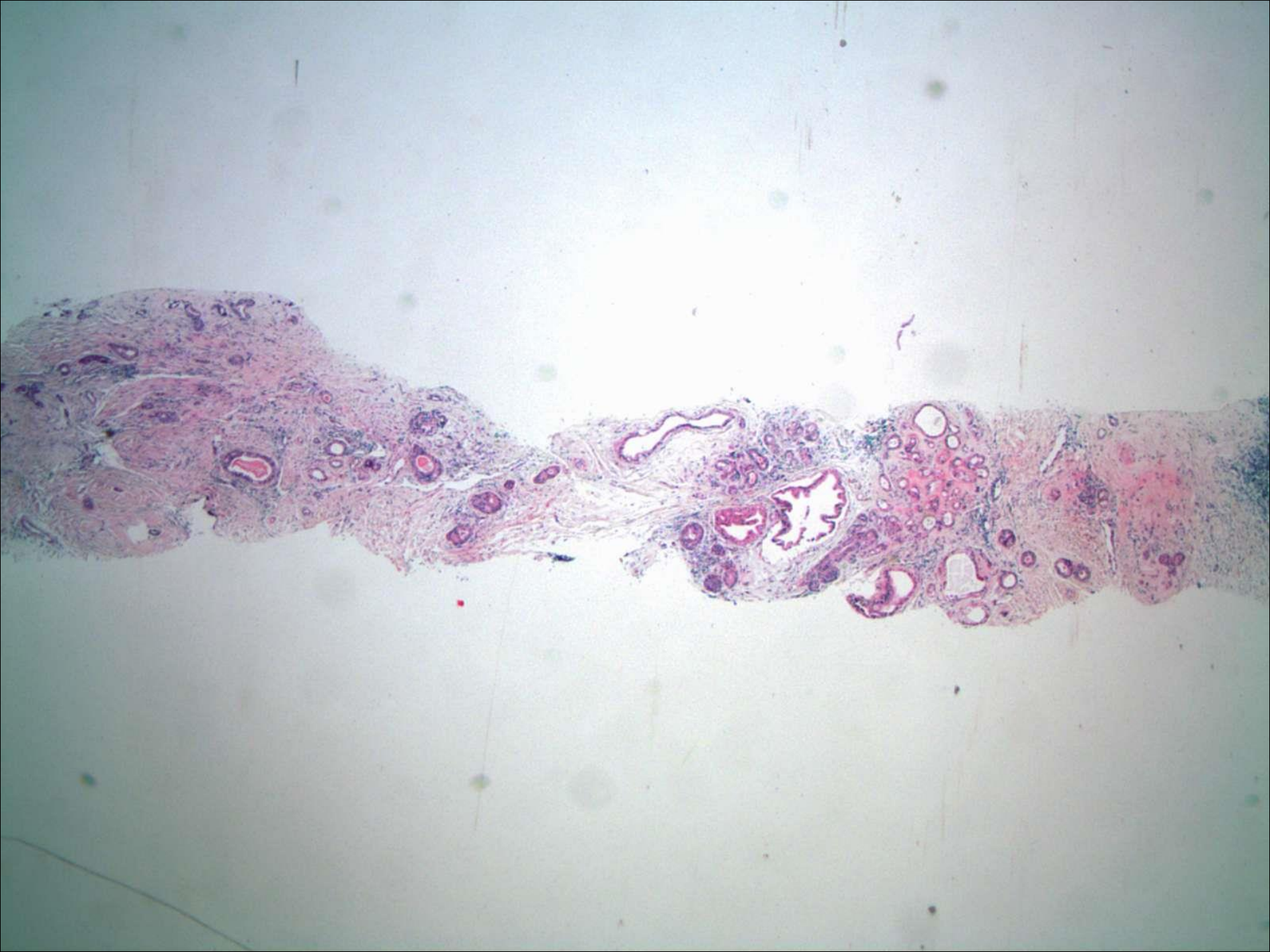


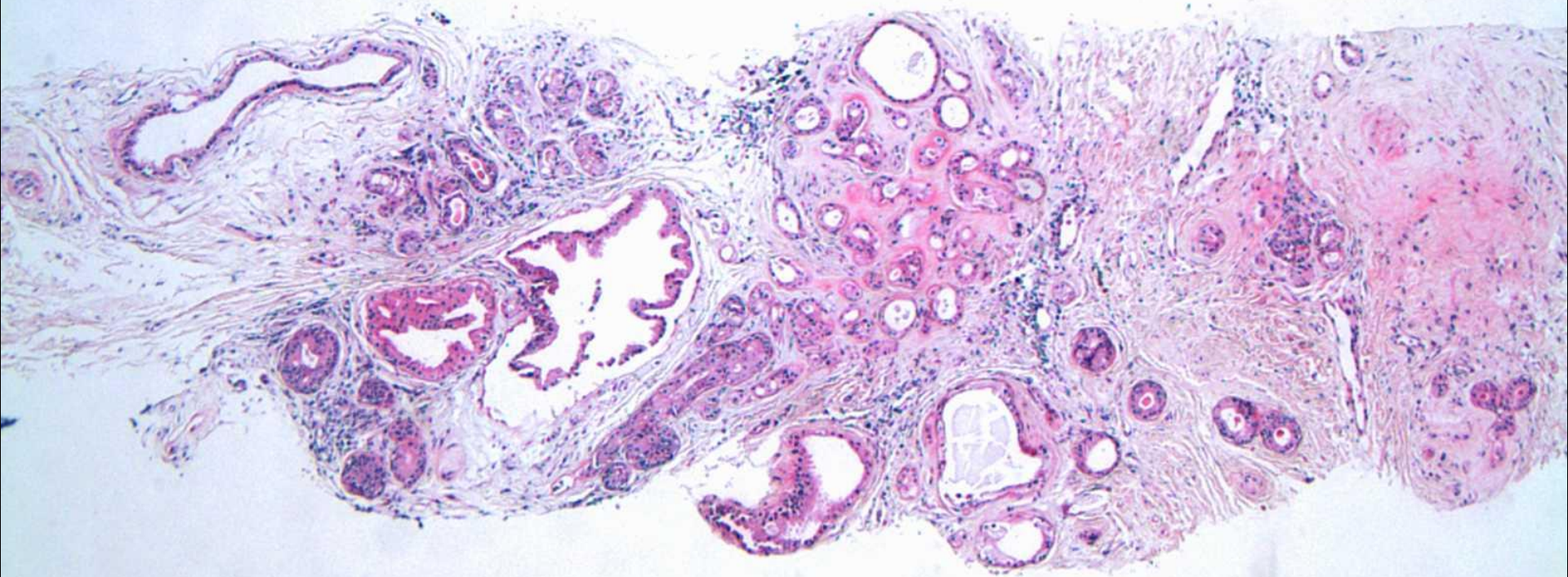


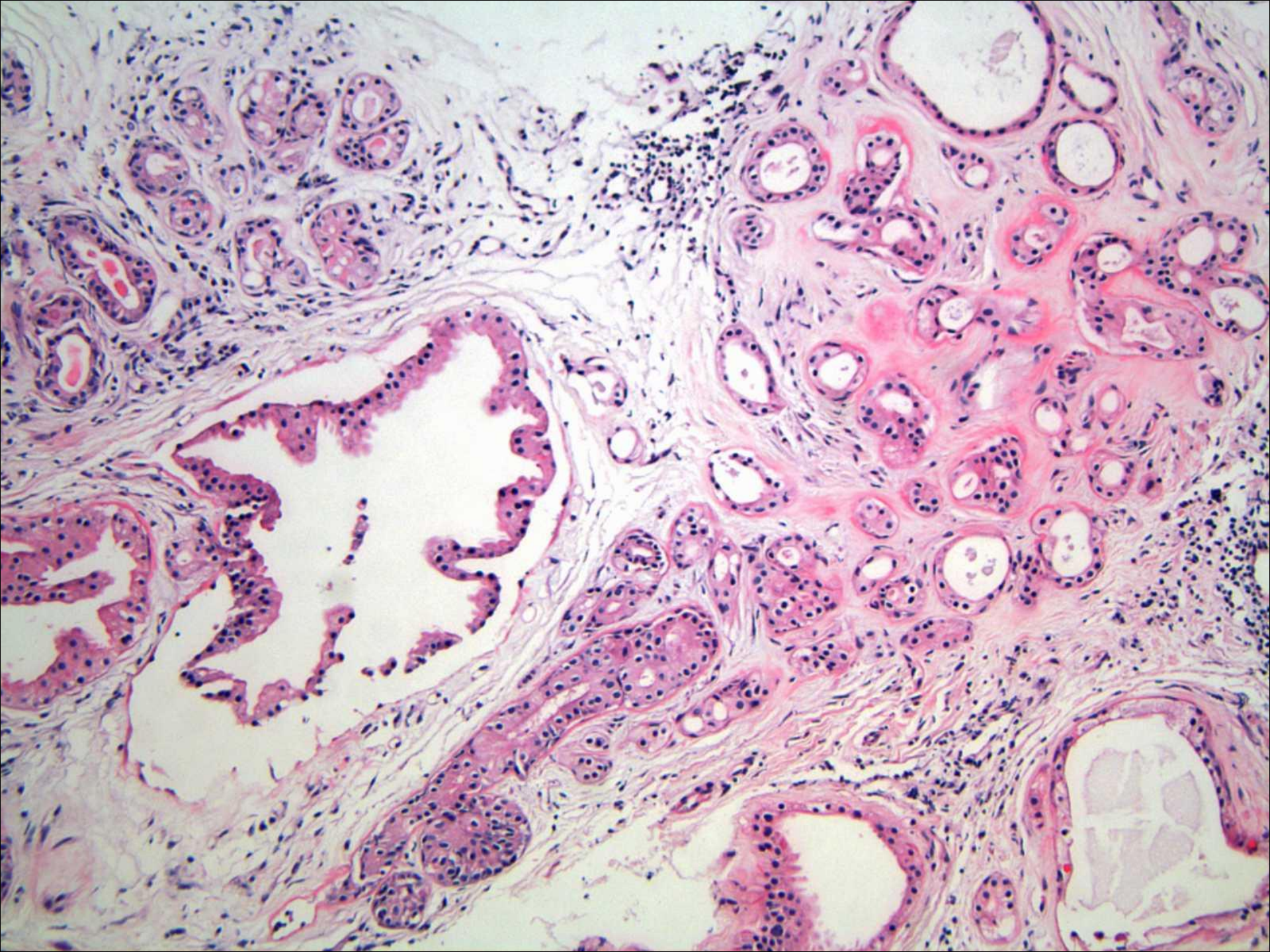
SB 5844

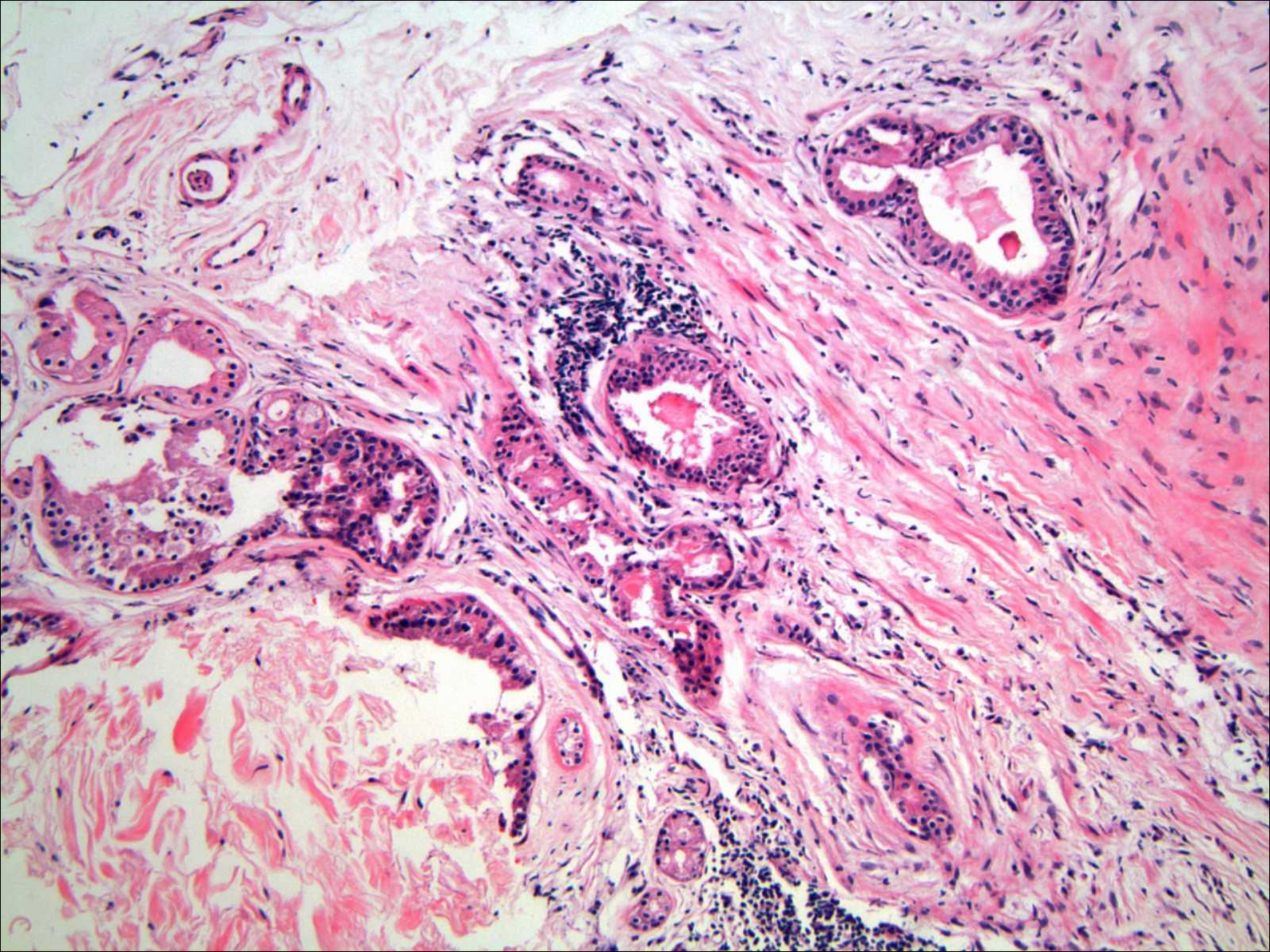
Balaram Puligandla; Kaiser Oakland Medical Center

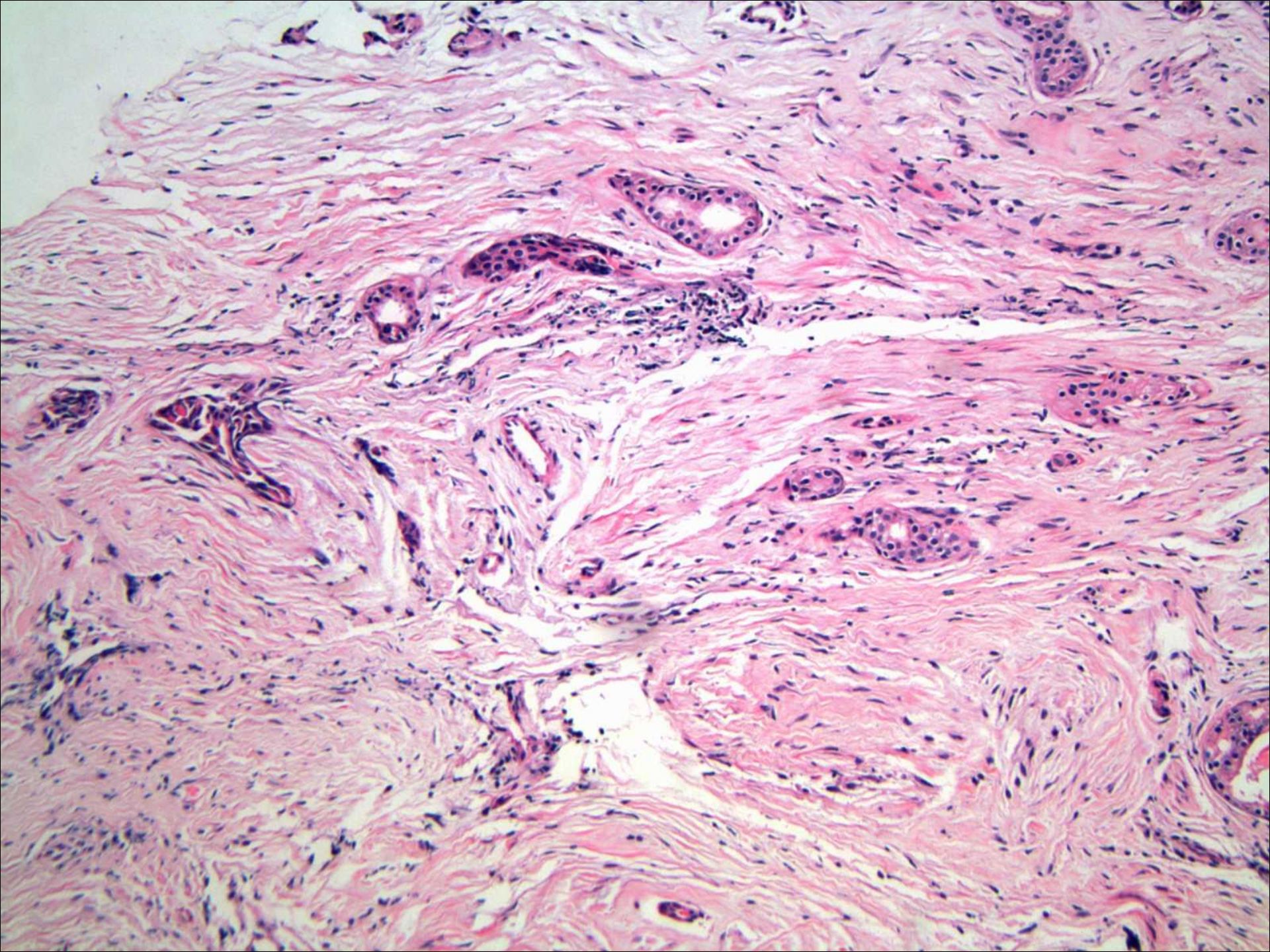
74-year-old woman with a left
neck mass.







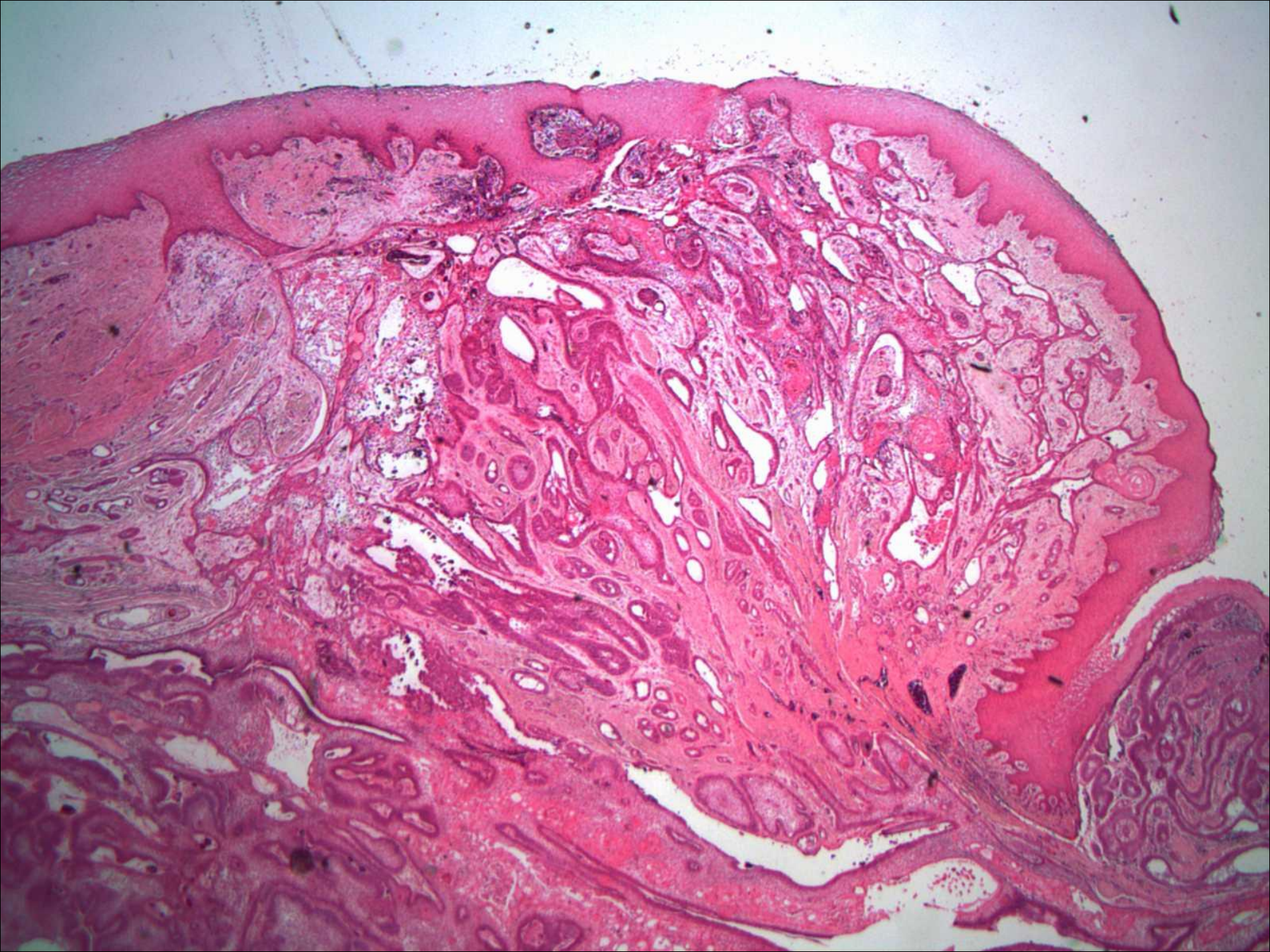


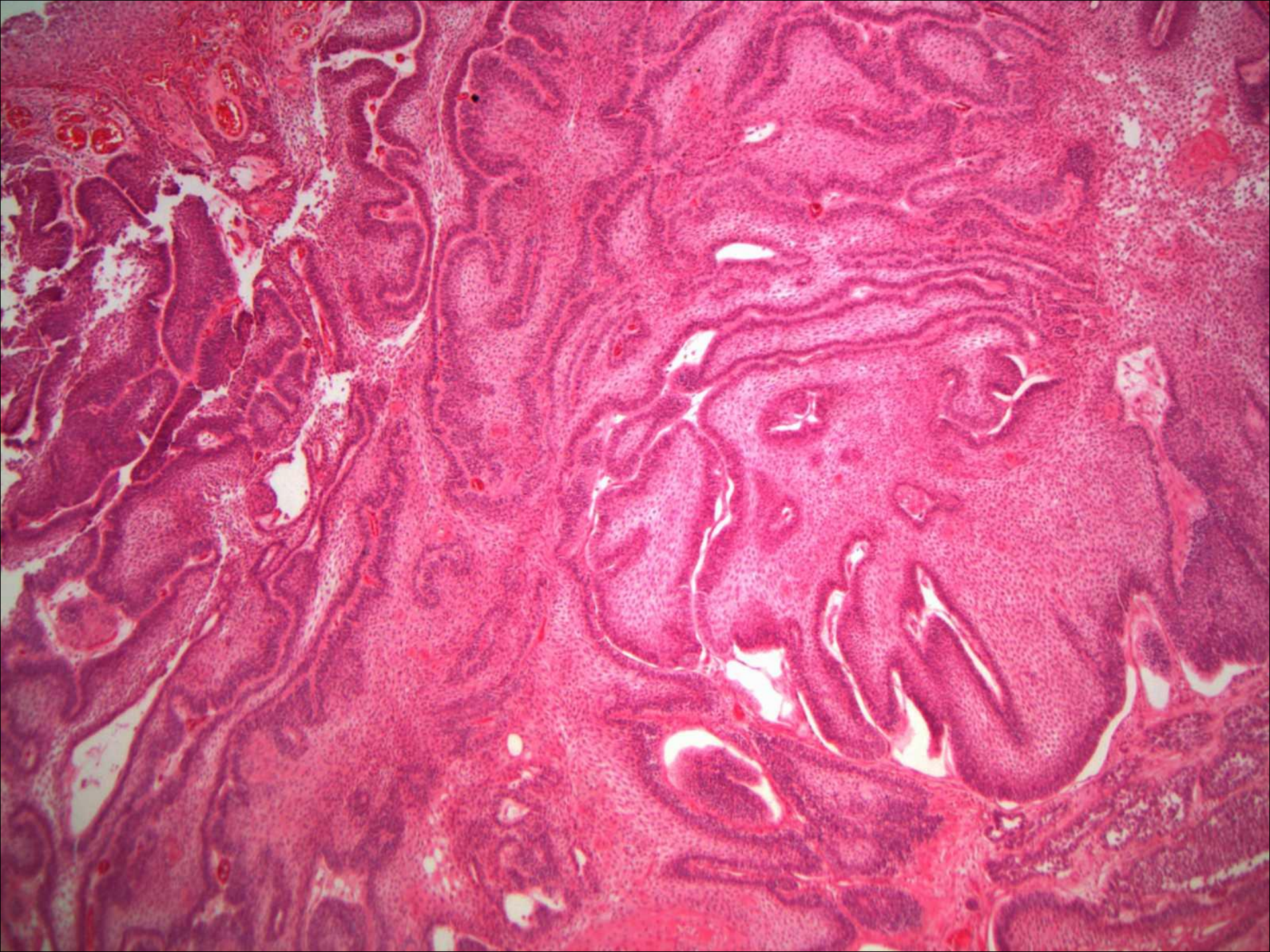


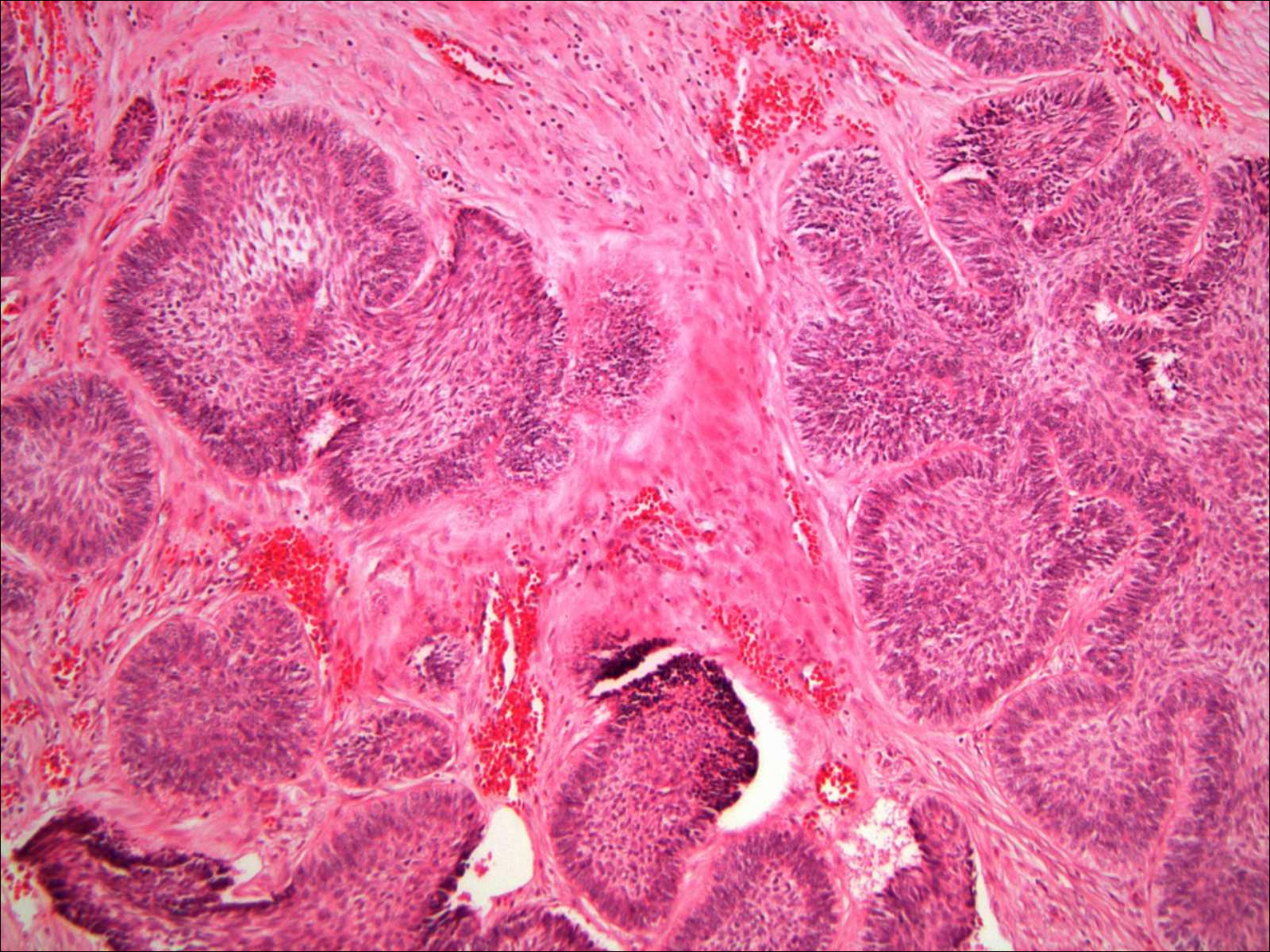
SB 5845

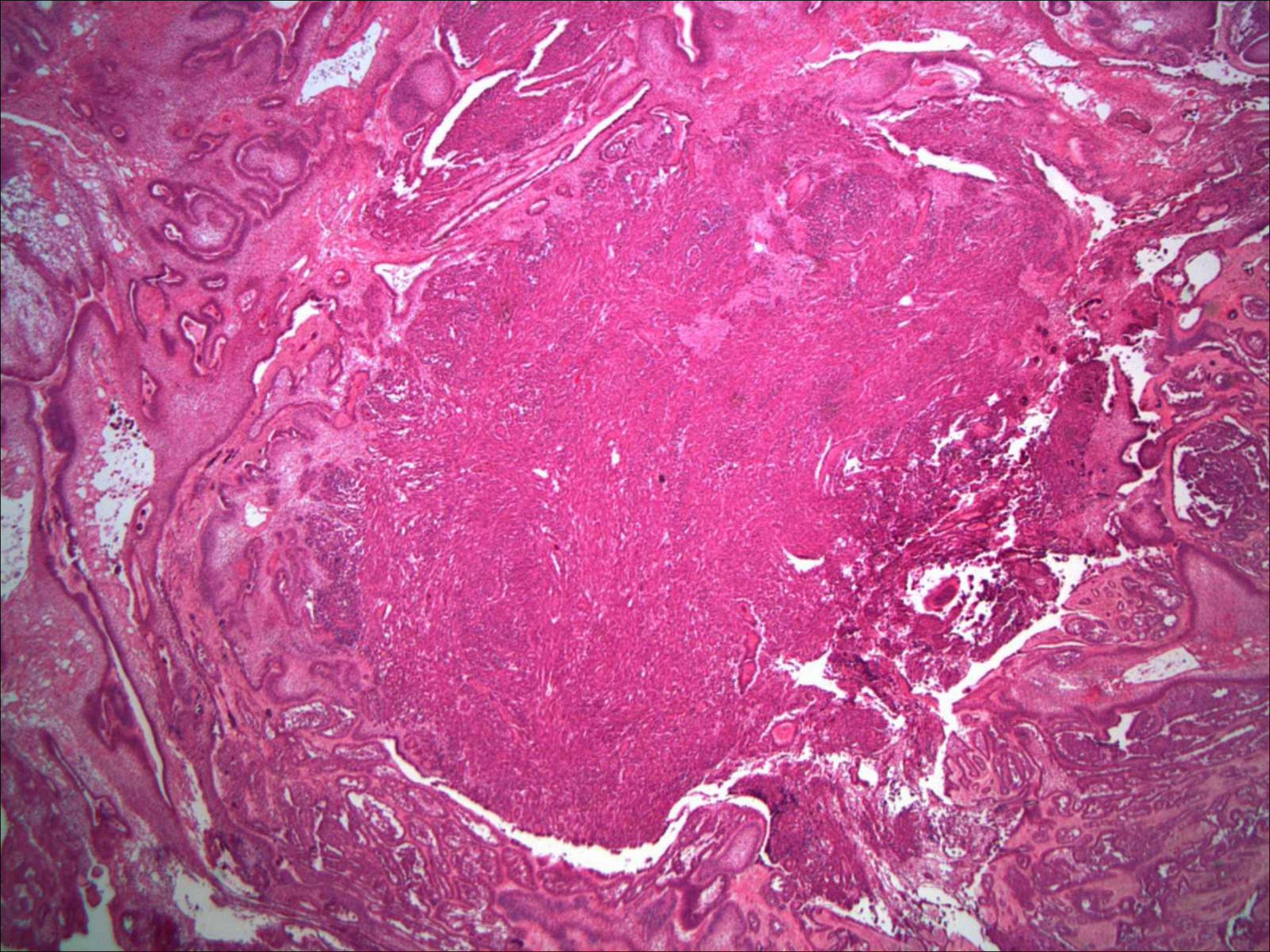
Balaram Puligandla; Kaiser Oakland Medical Center

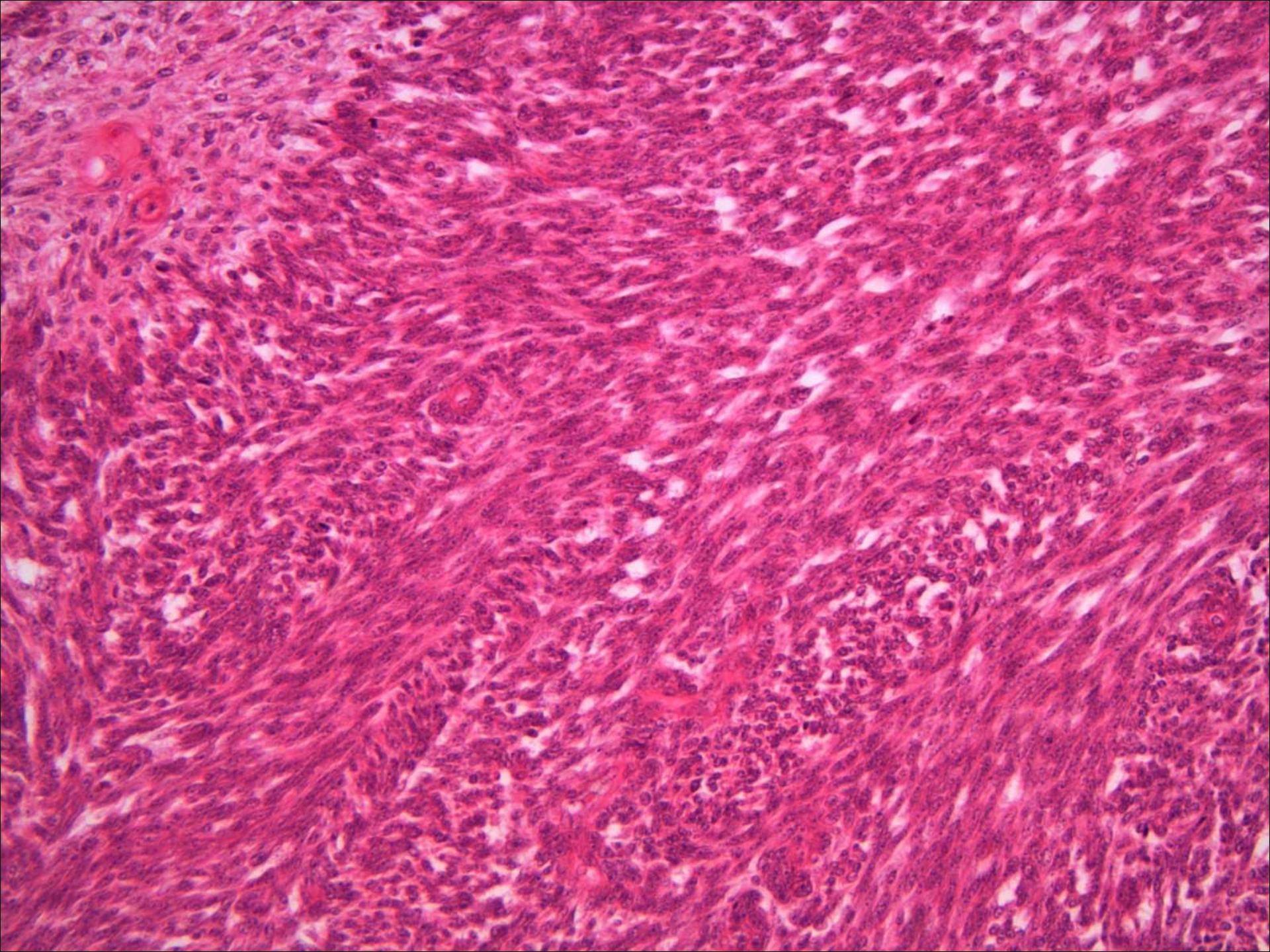
60-year-old man with right
mandible lesion.







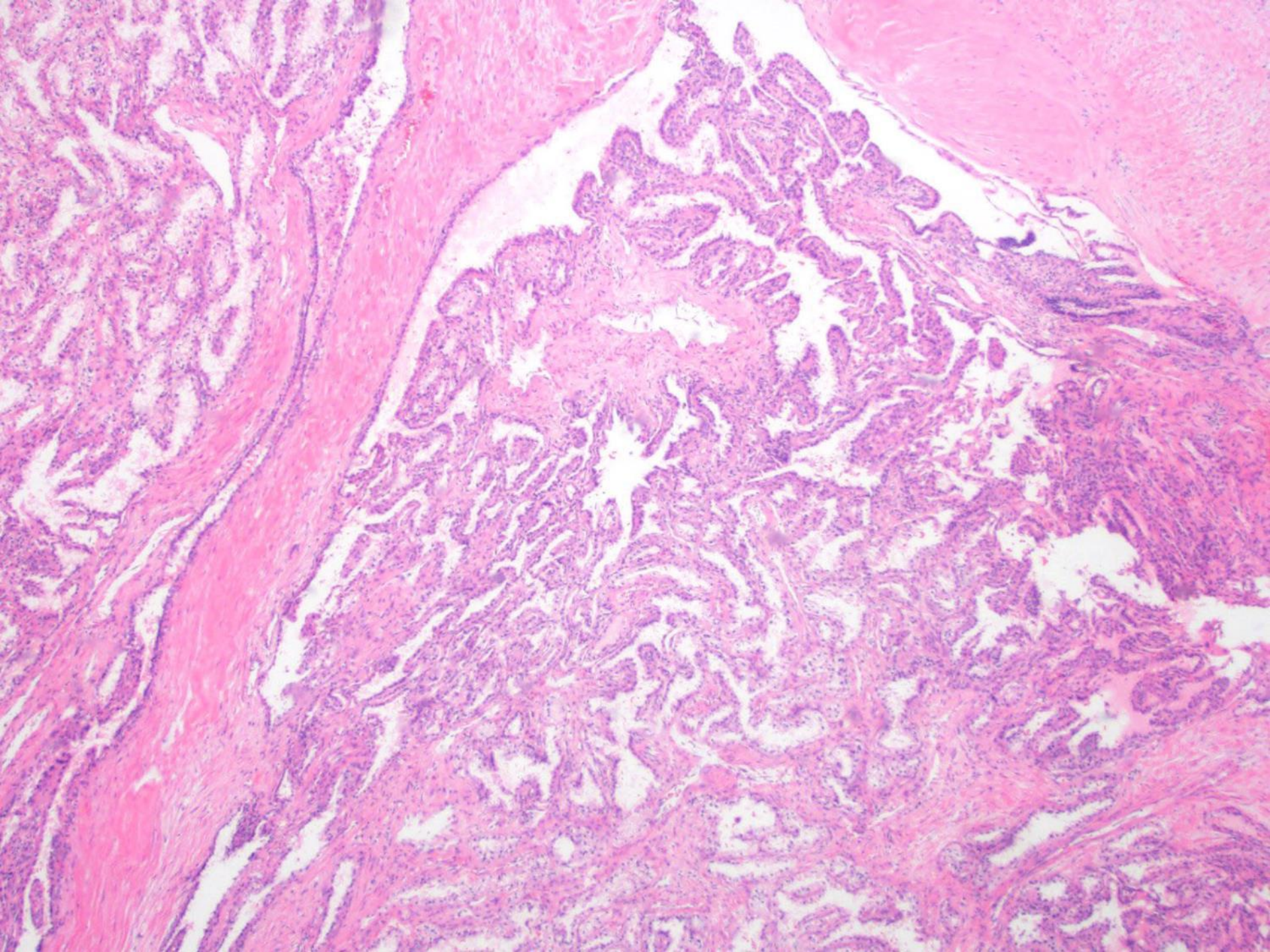


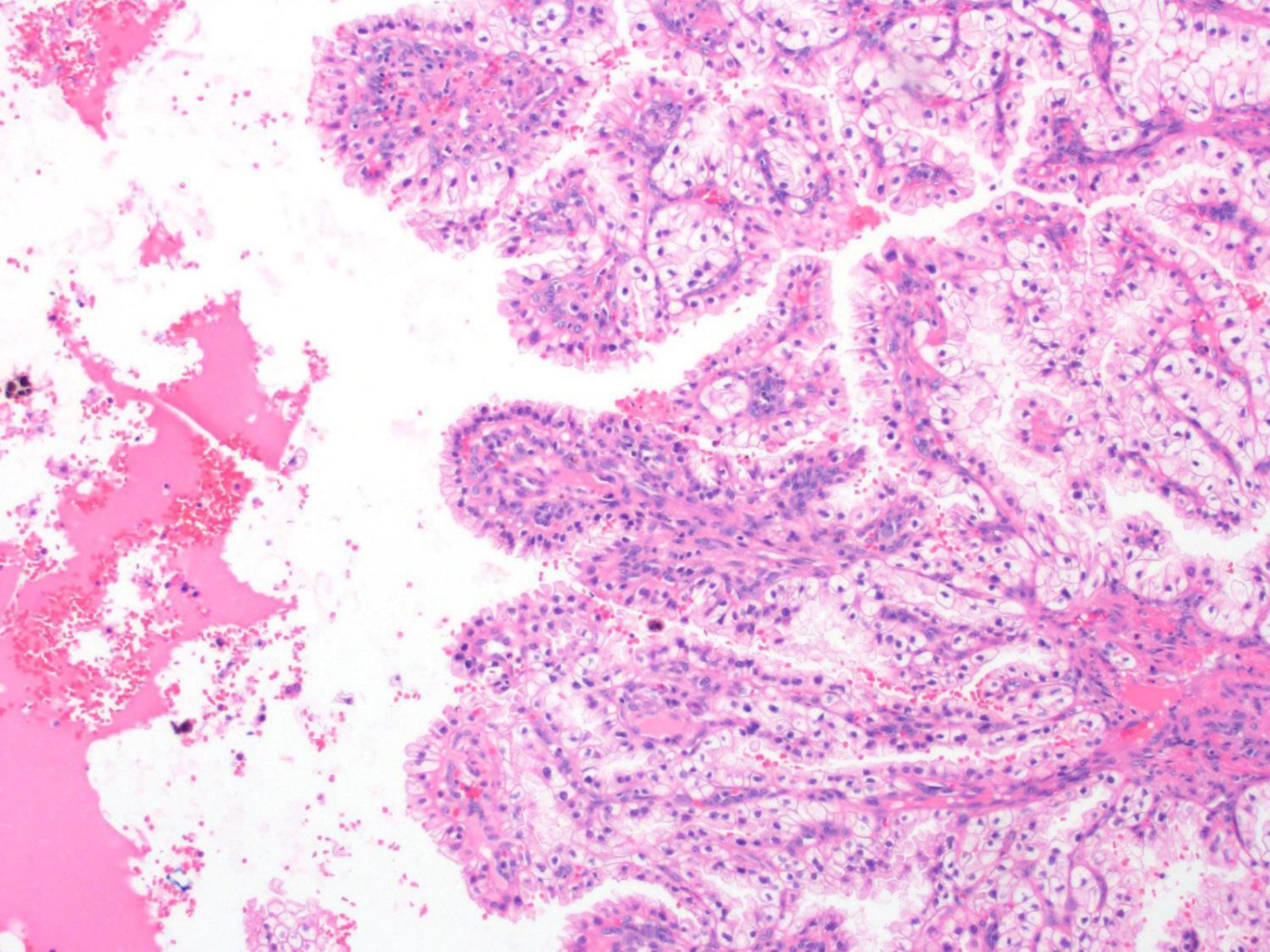


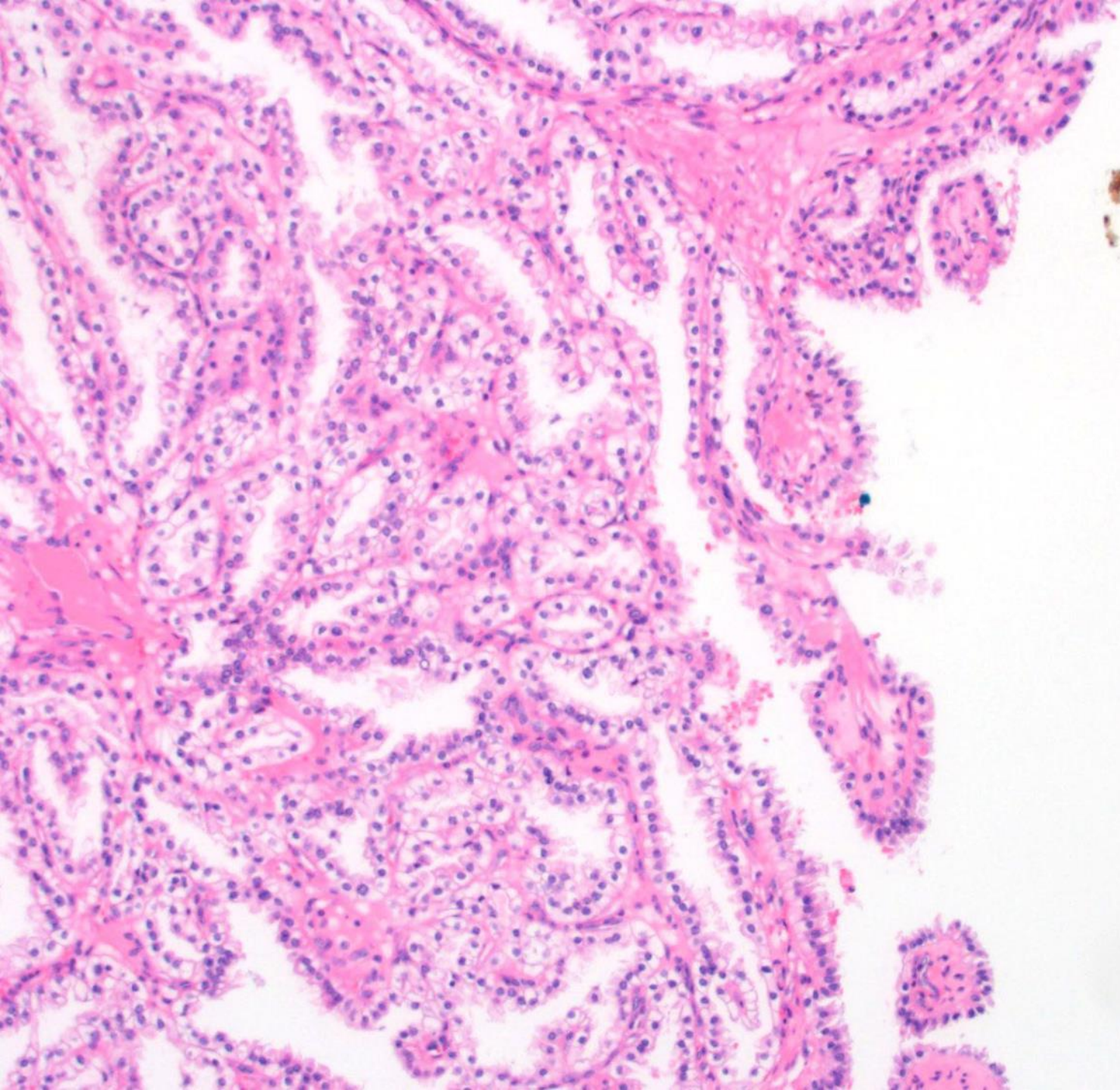
SB 5846

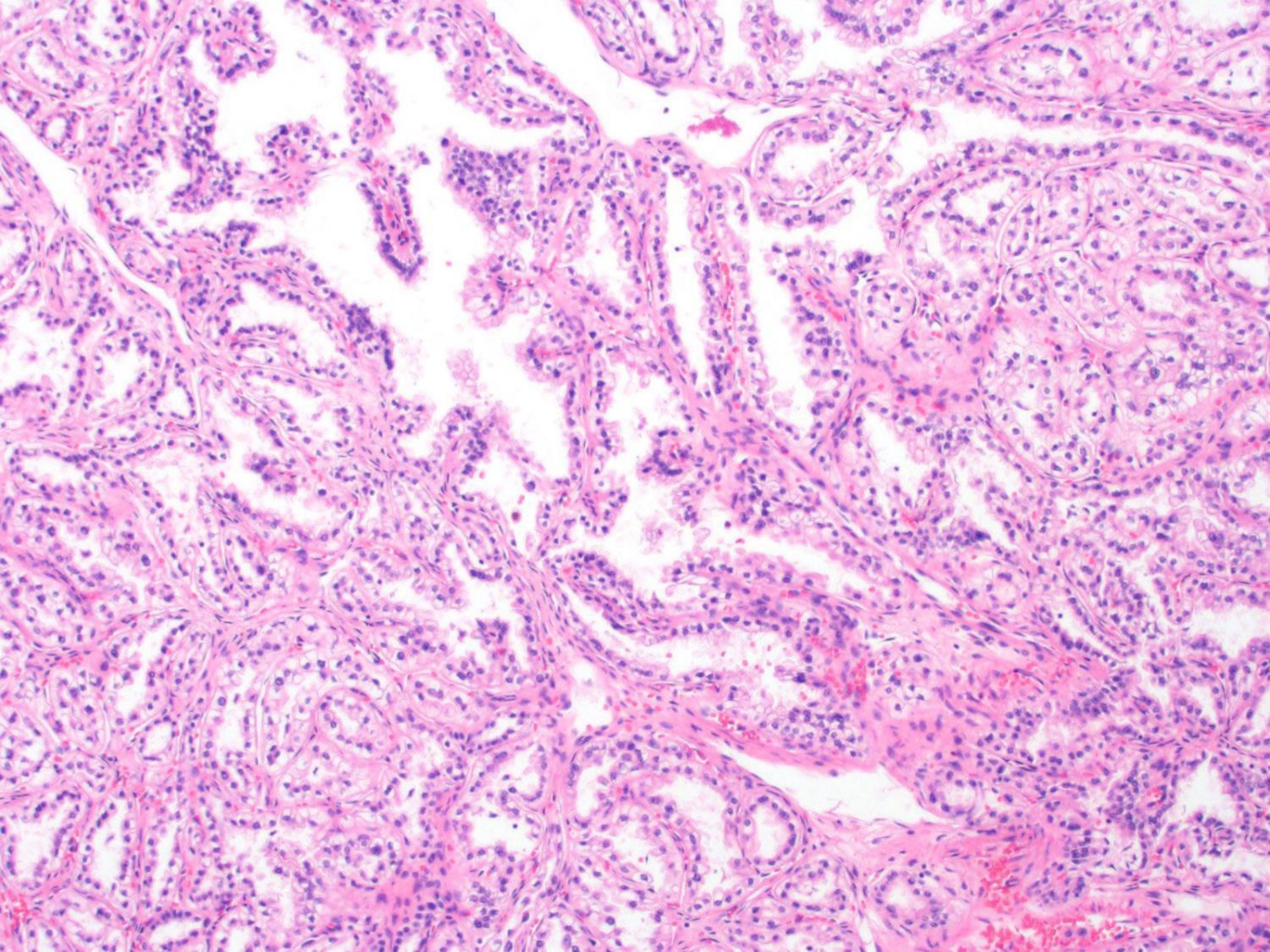
Jeong Han; Kaiser Oakland Medical Center

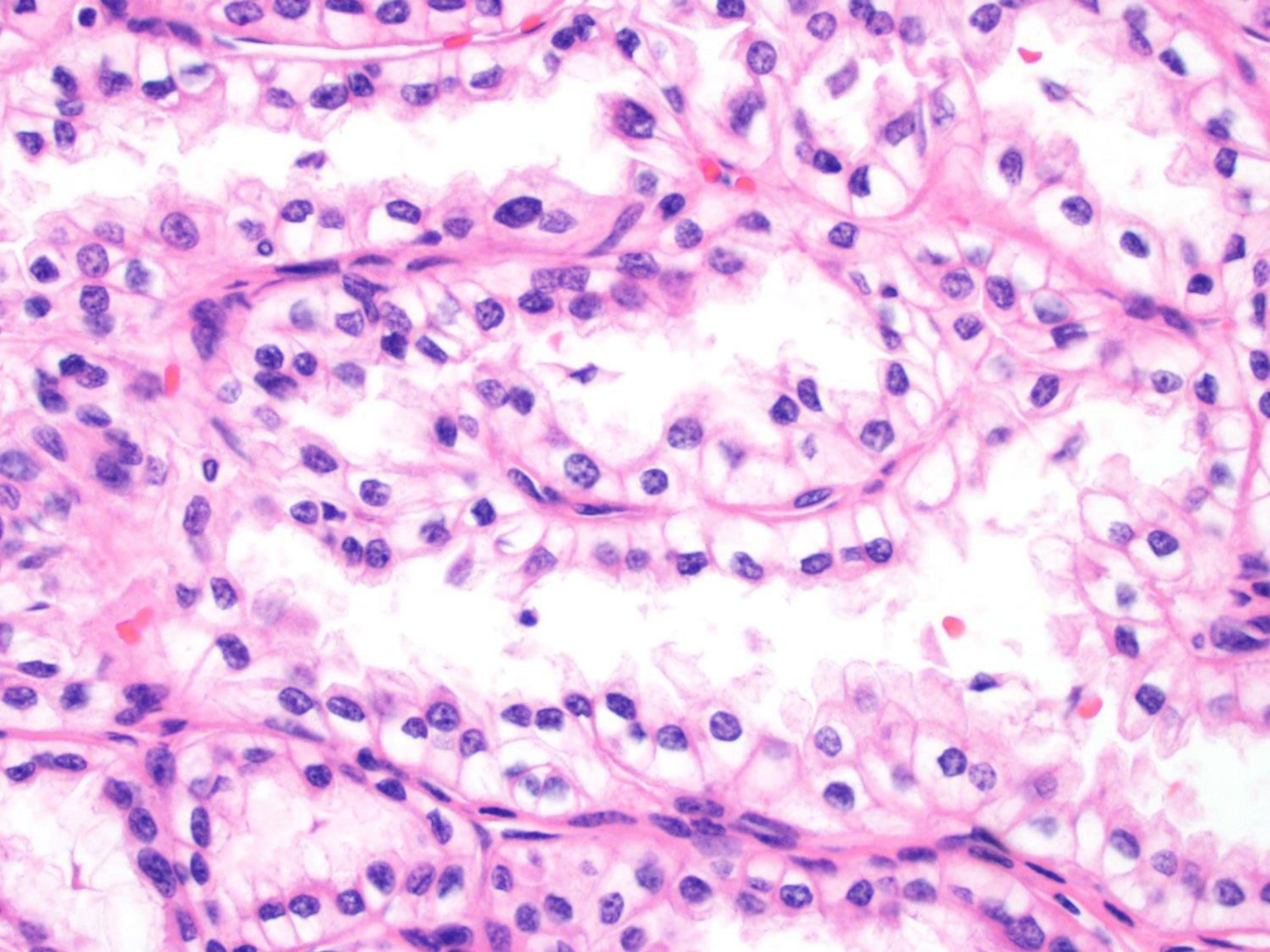
59-year-old female with history of clear cell RCC in 2006 s/p left nephrectomy, now presents with multiple right kidney masses.







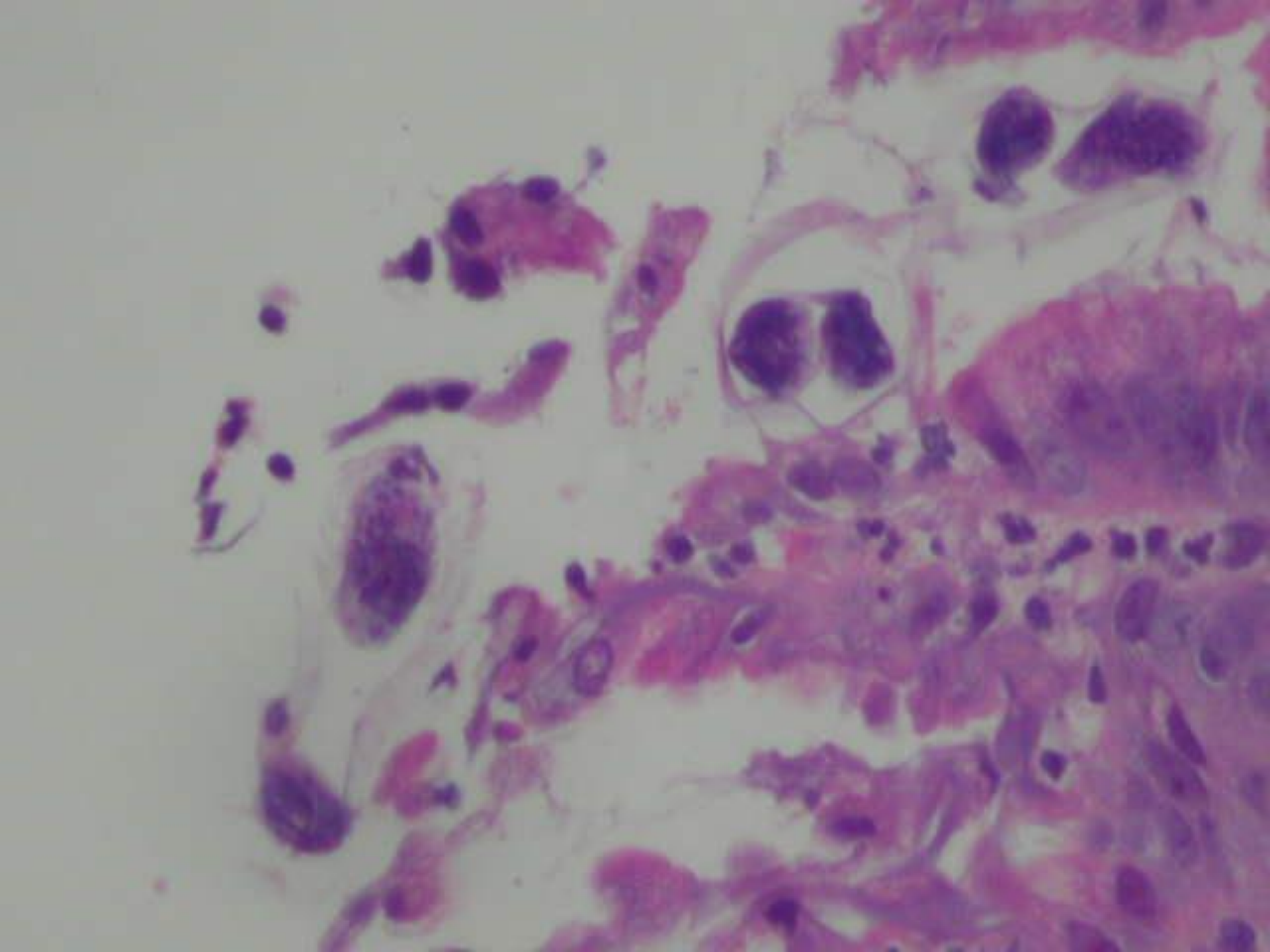


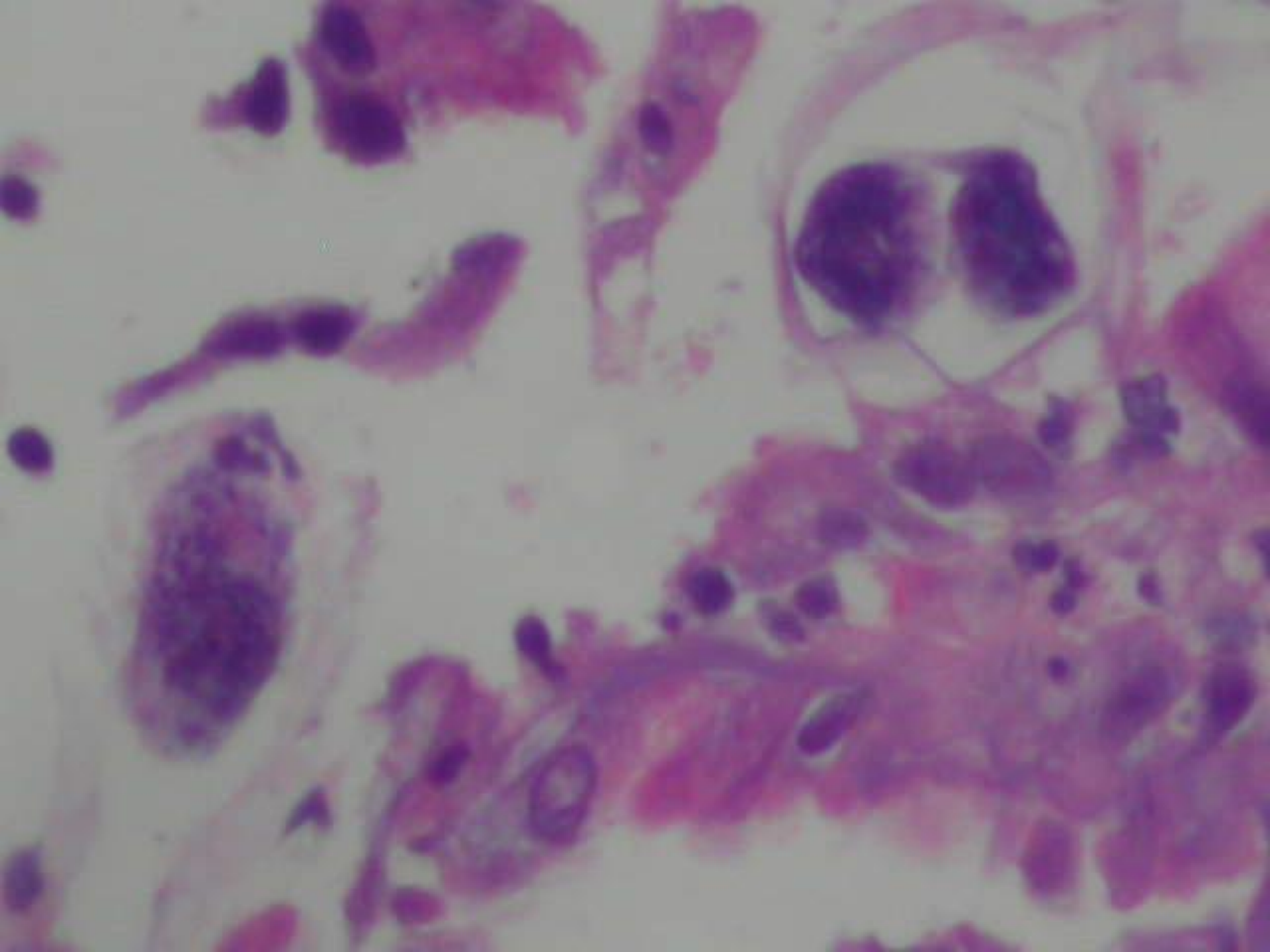


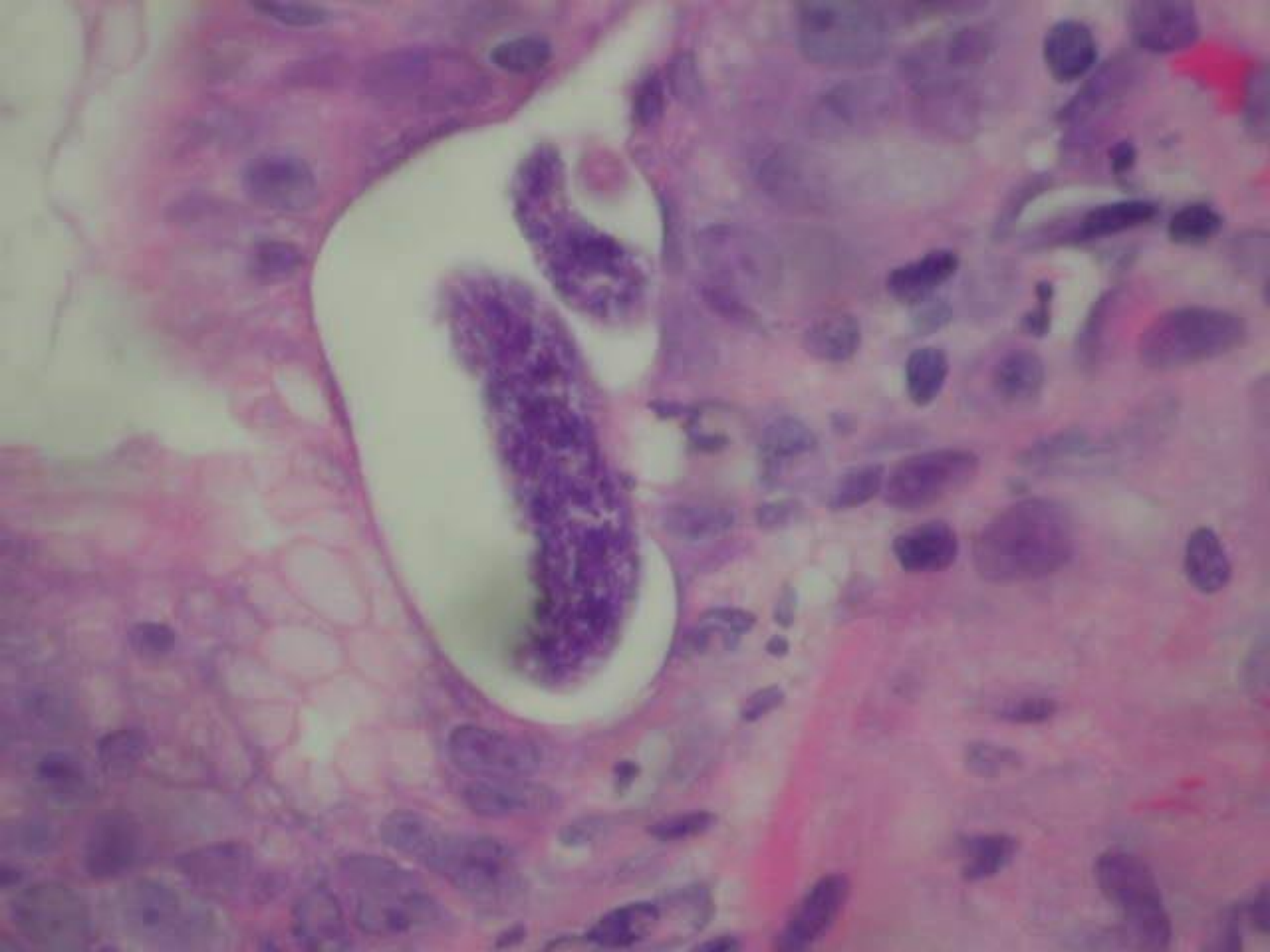SB 5847

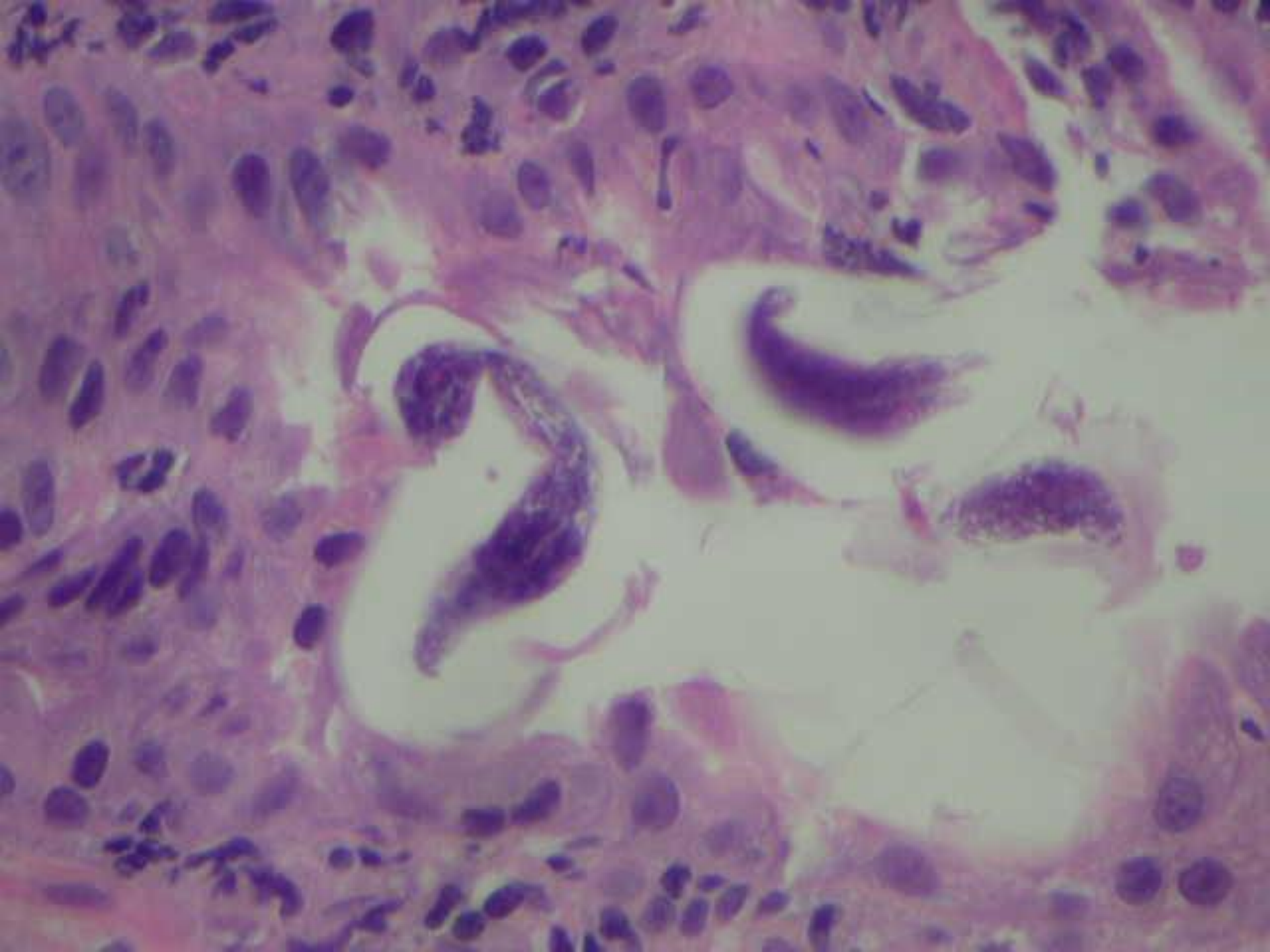Justin Cuff / Keith Duncan; Mills Peninsula

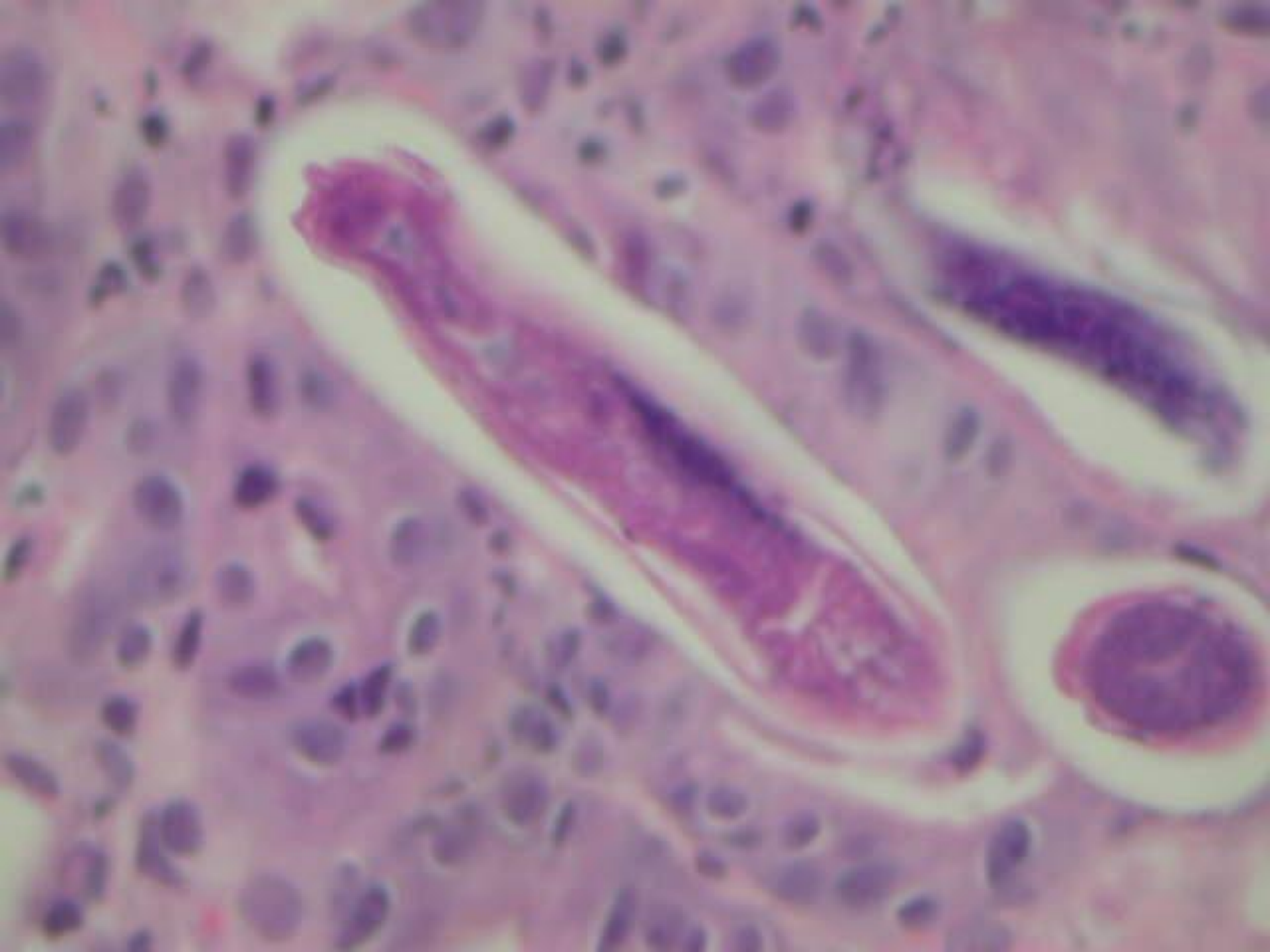32-year-old Hispanic male with small bowel obstruction and abdominal pain.
Immunosuppressed, treated for presumed sarcoid cardiomyopathy.

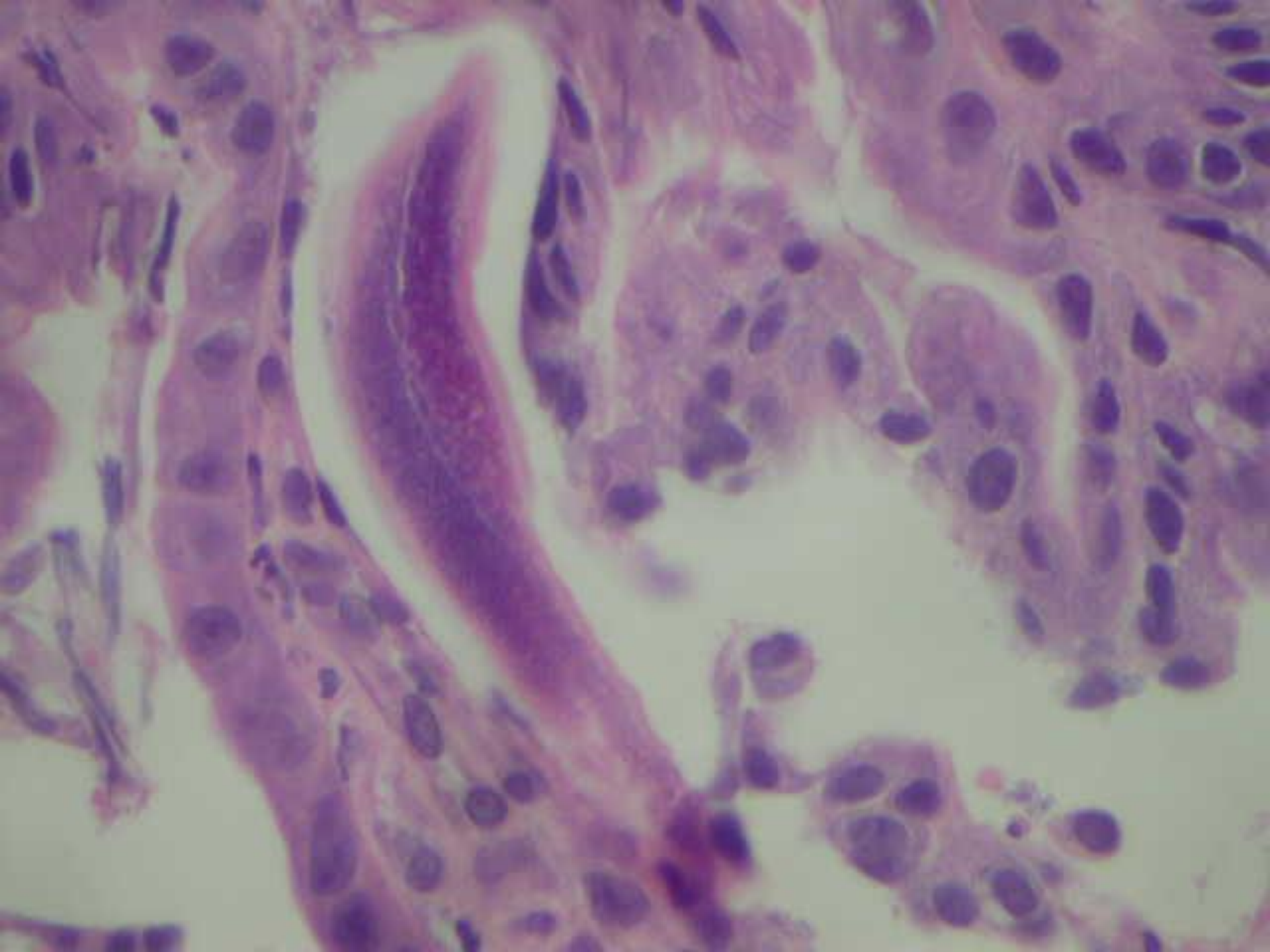

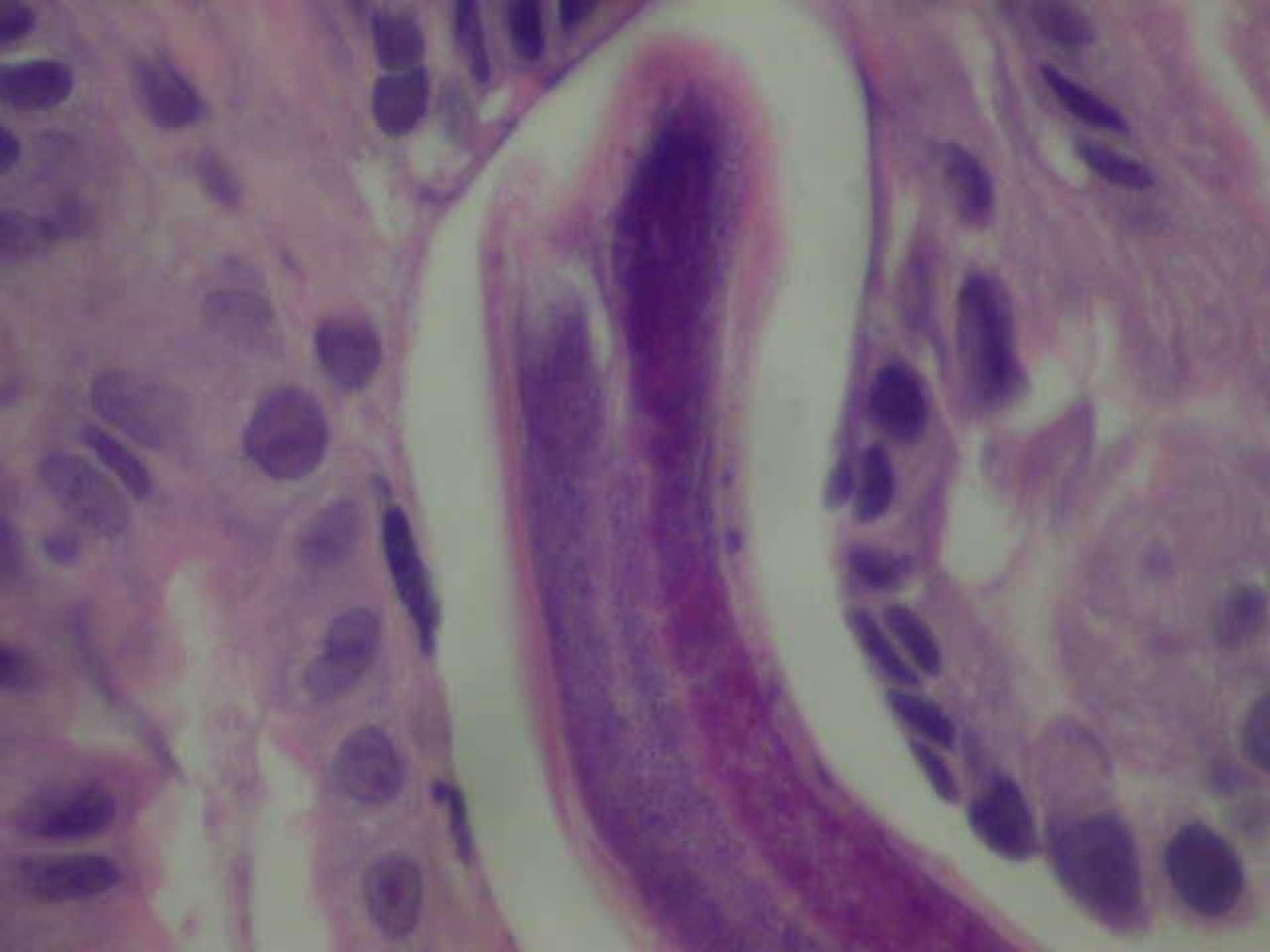








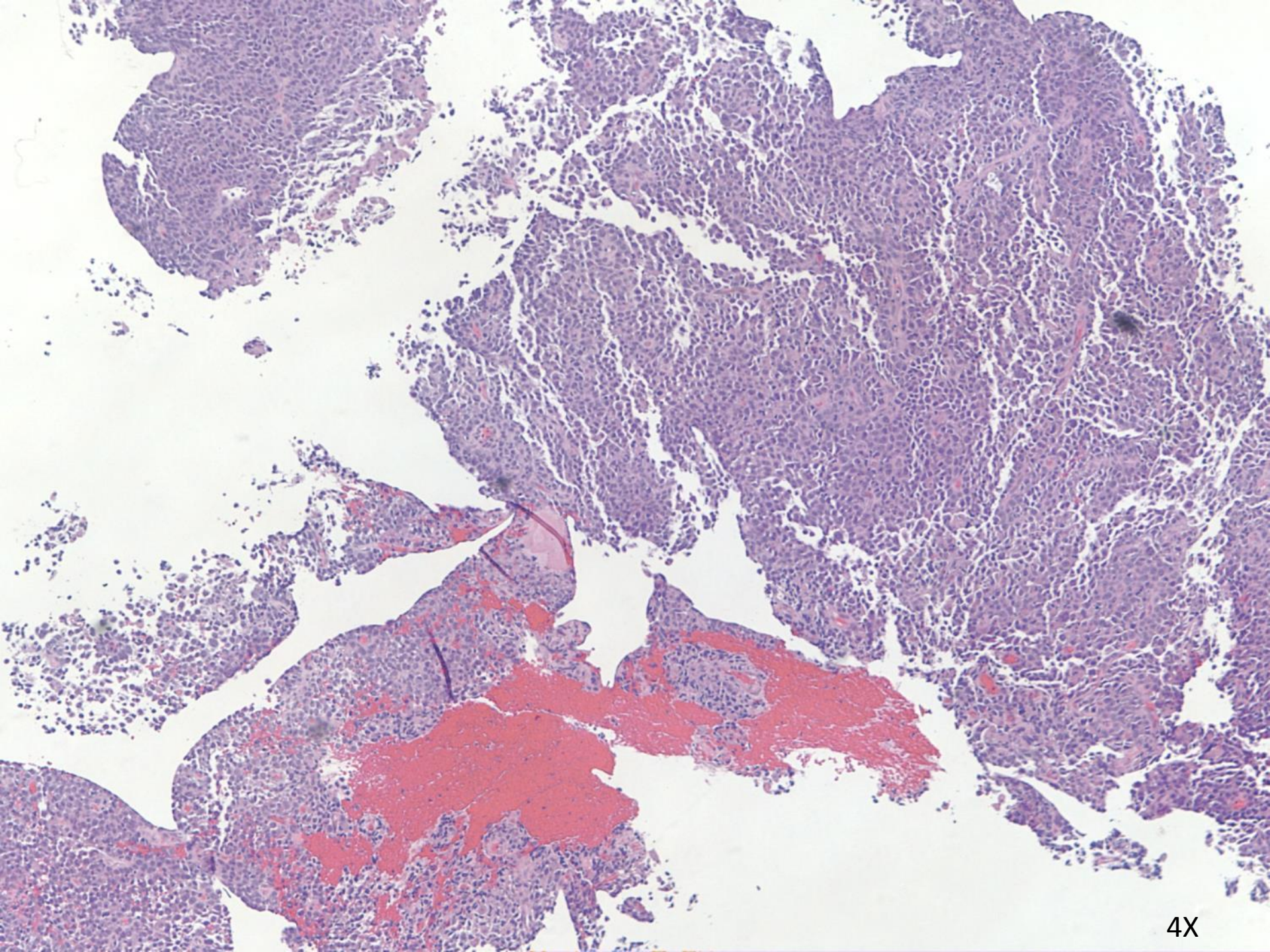




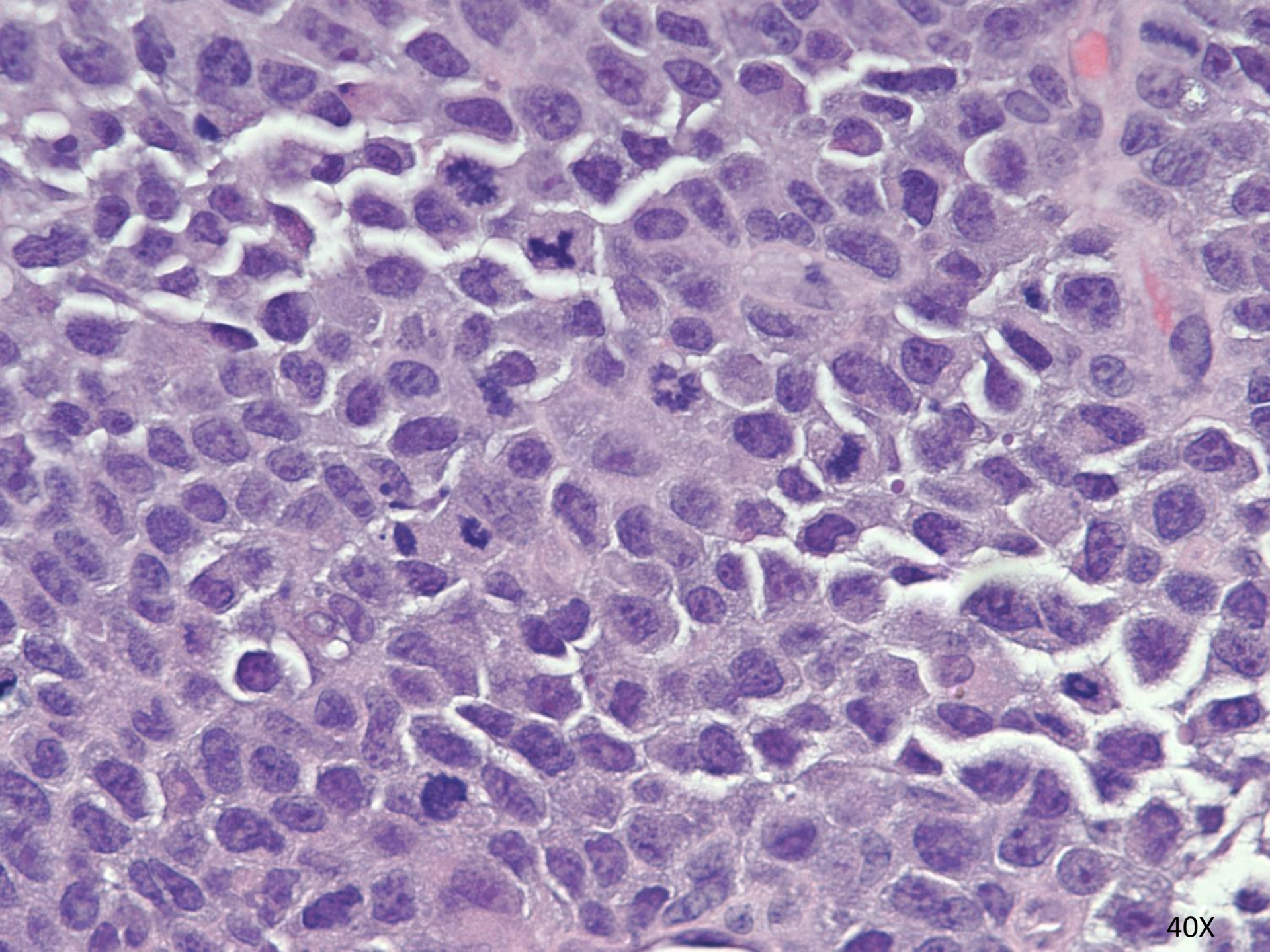
SB 5848

Lauren Edelman / Christina Kong; Stanford

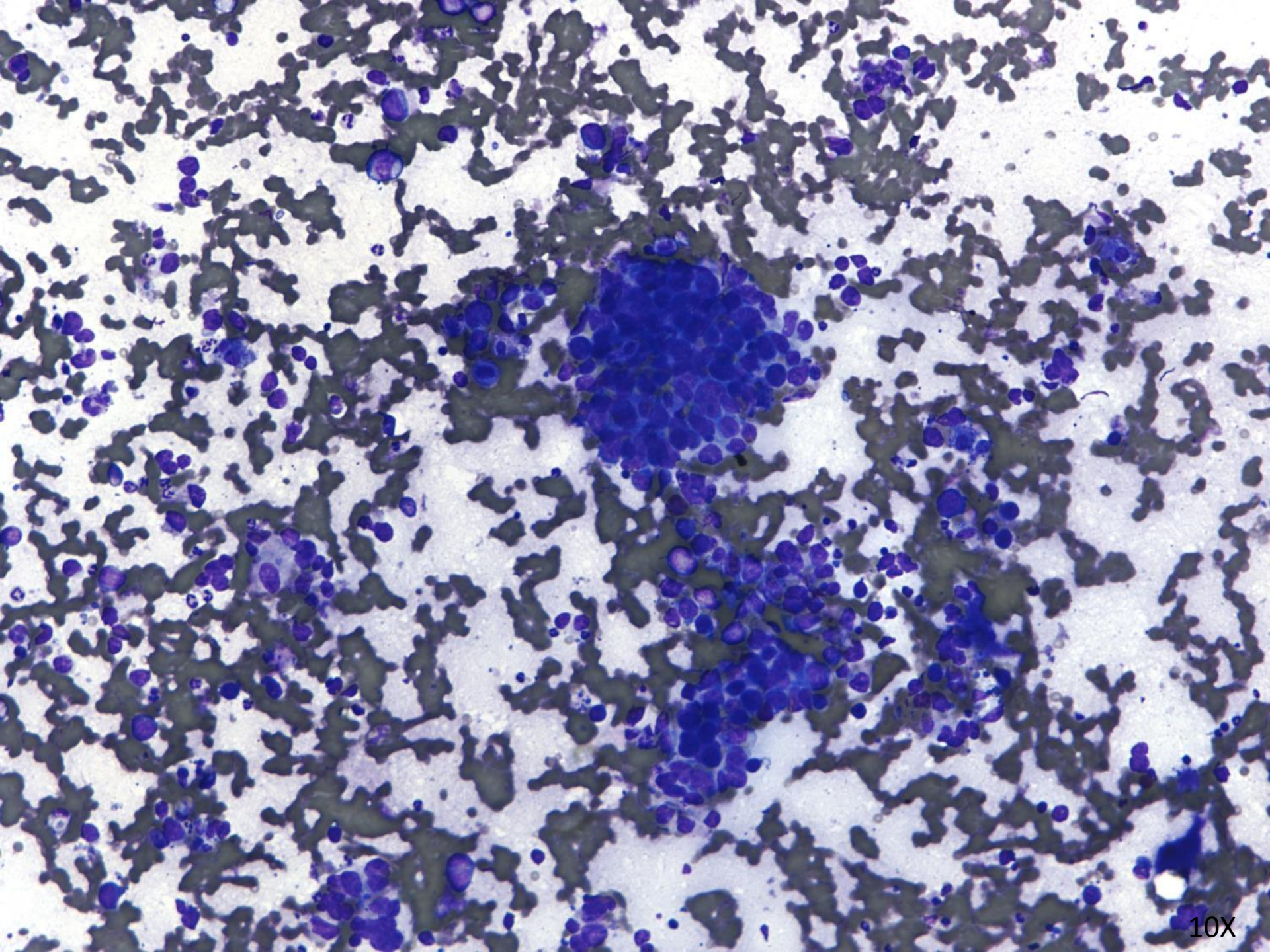
57-year-old female with history of endometrial carcinoma. Axillary lymph node biopsied. Per requisition, rule out metastatic endometrial carcinoma vs breast primary.

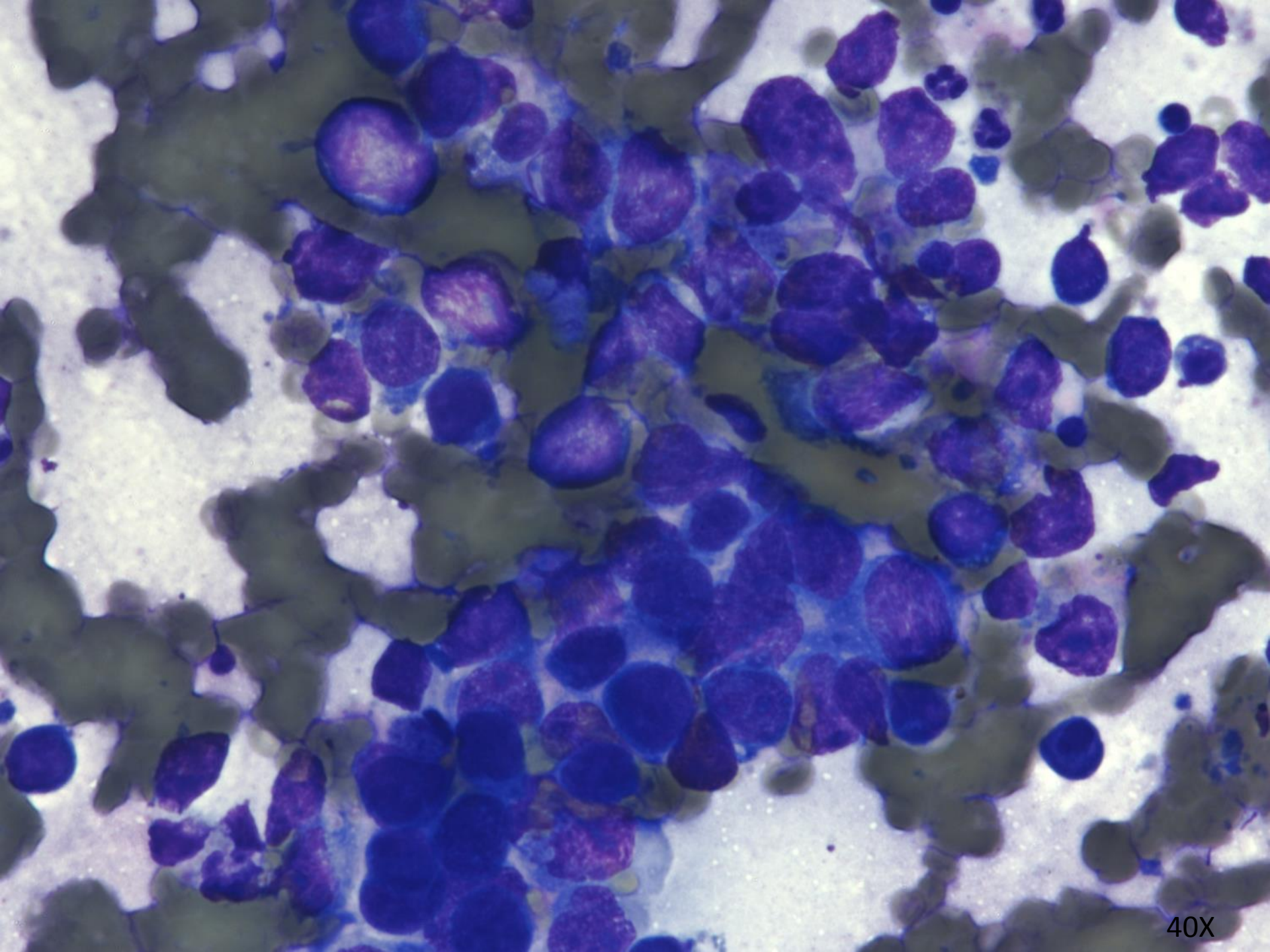


4X

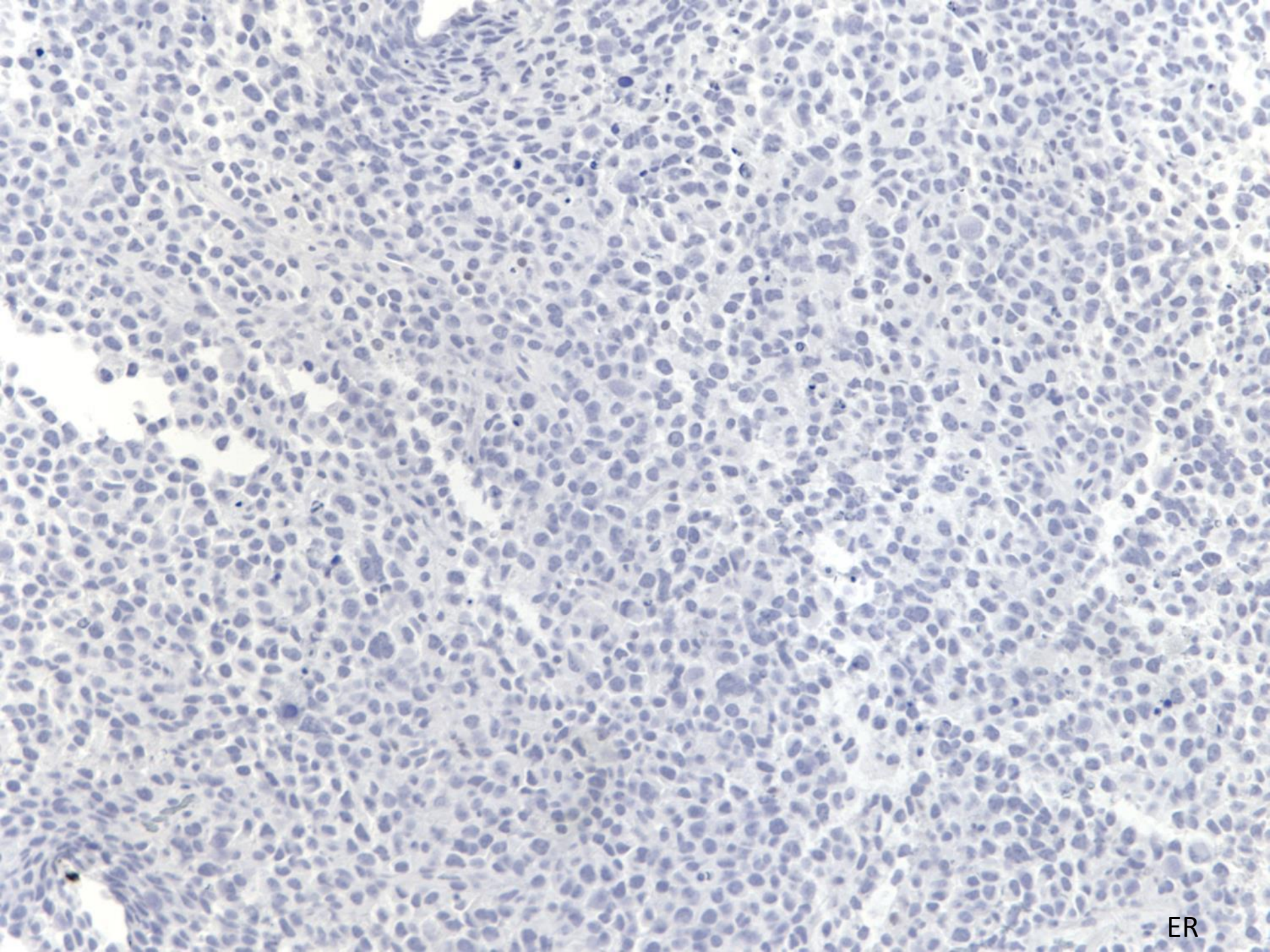


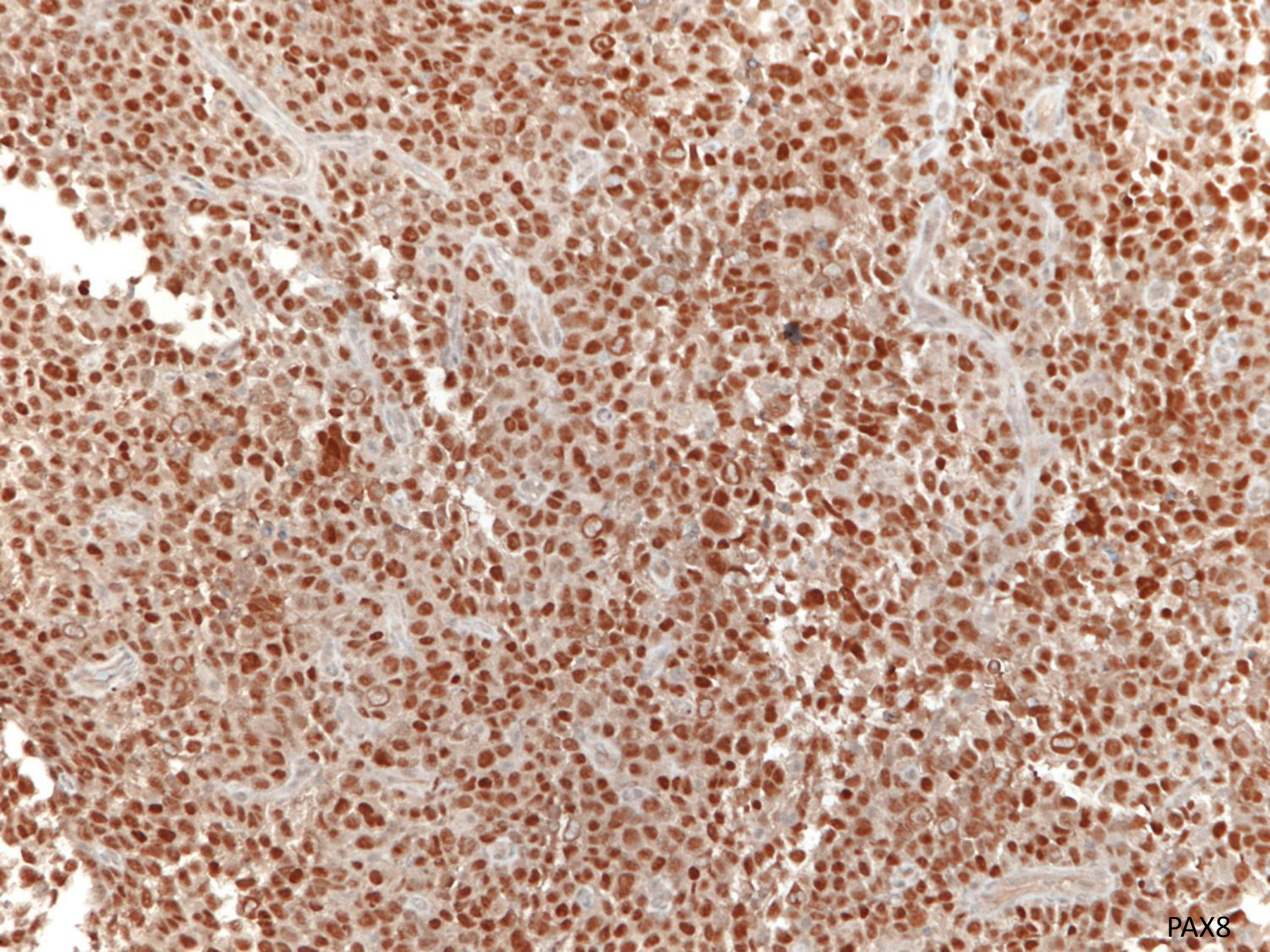
40X





40X



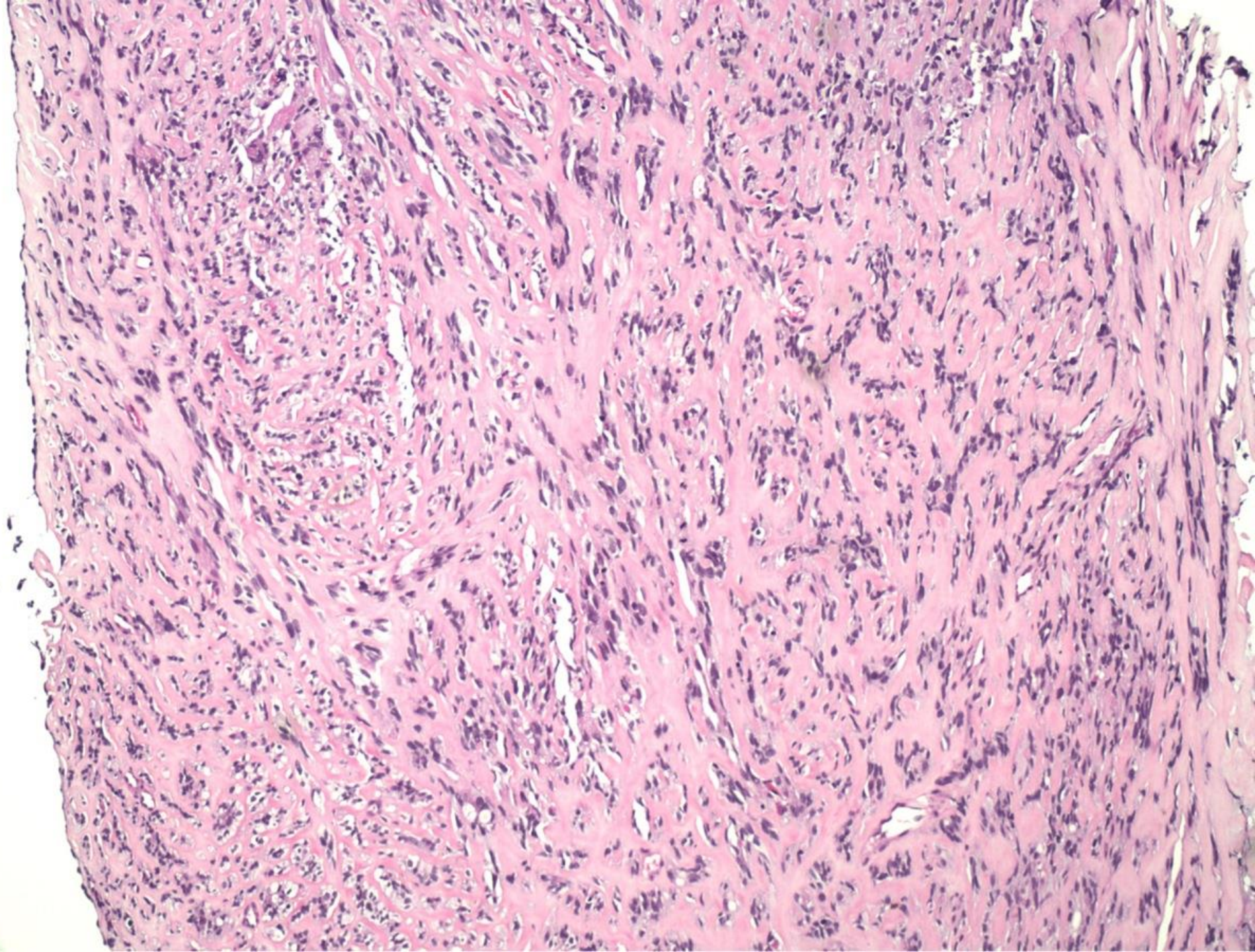


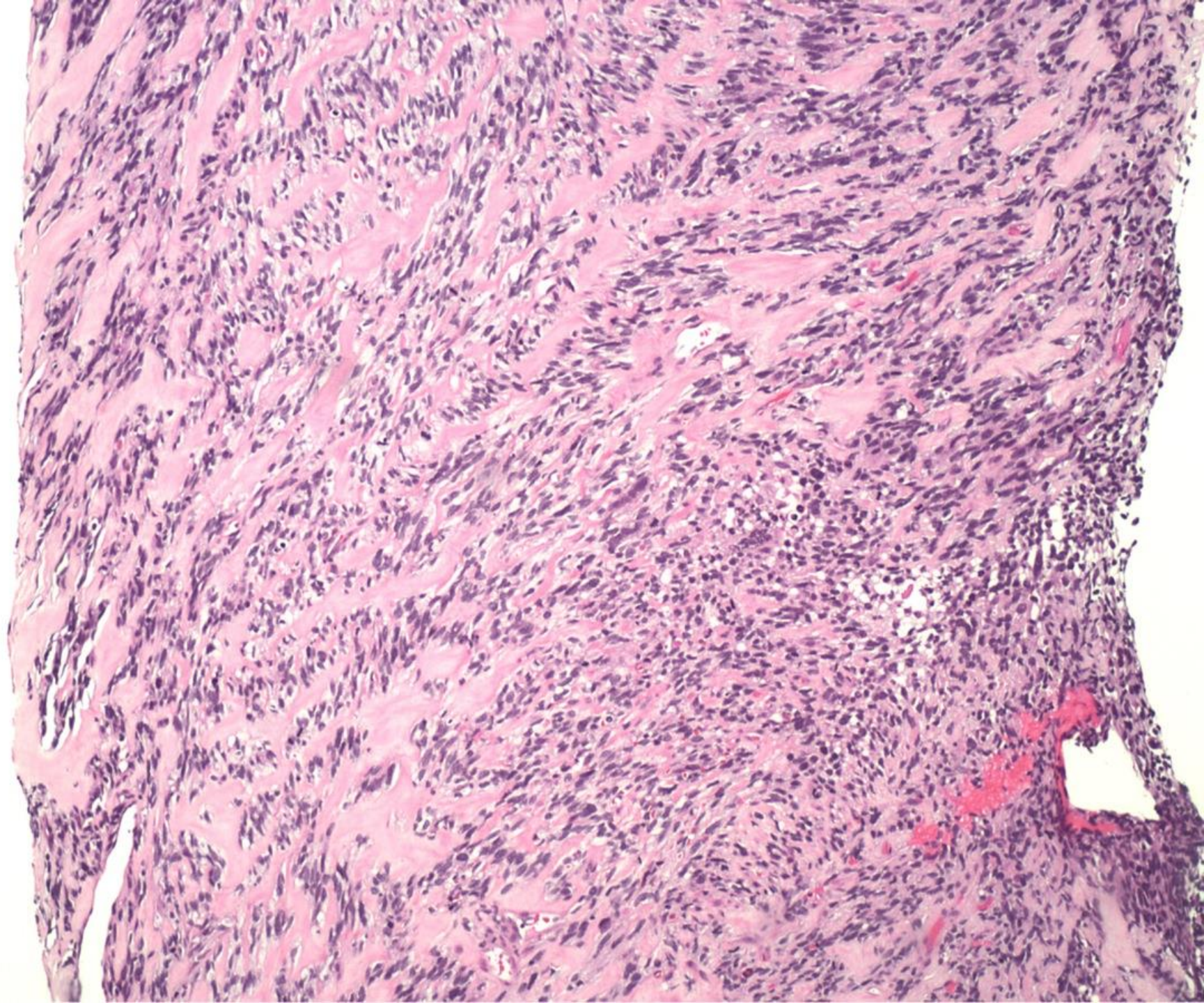
PAX8

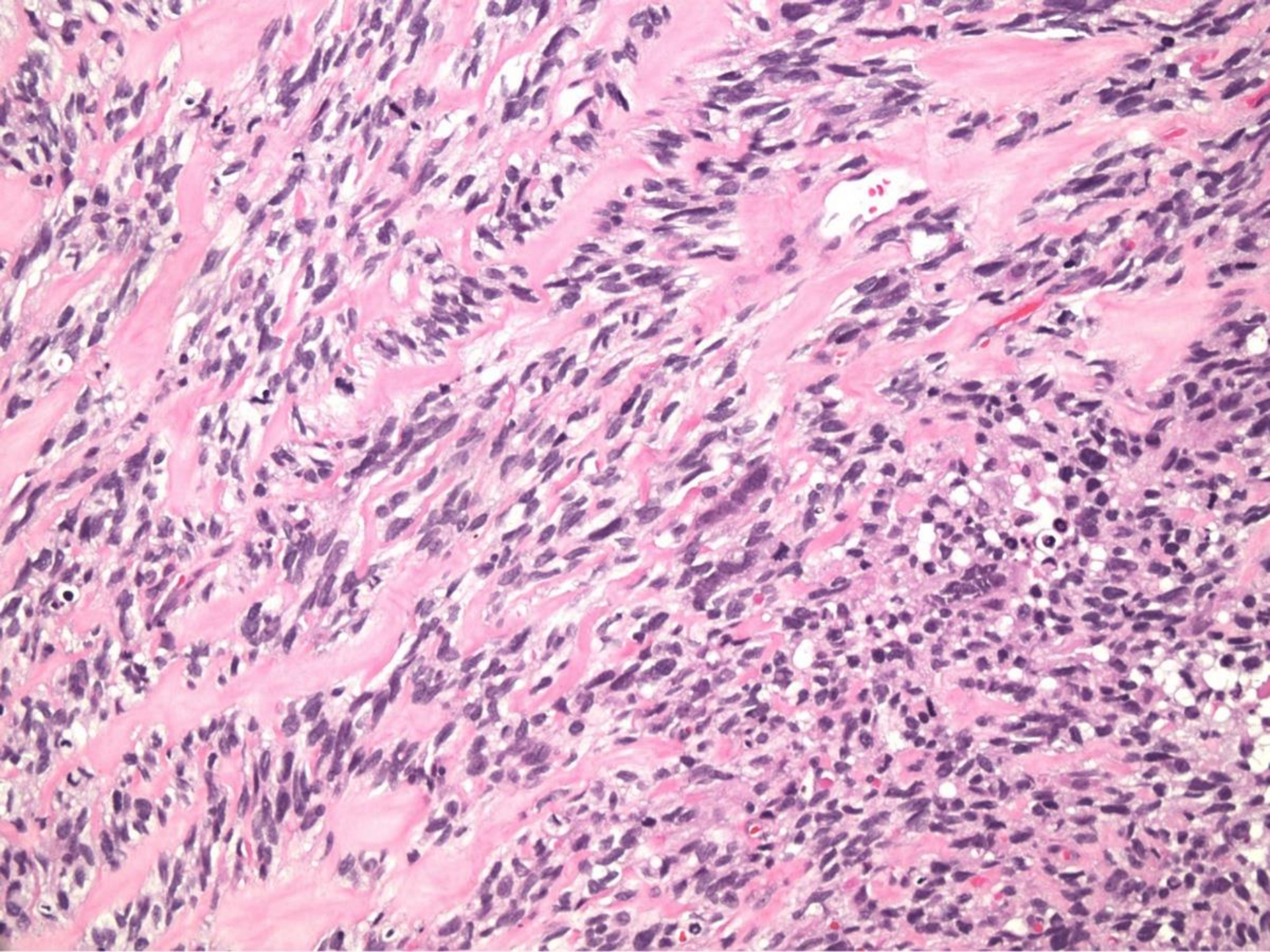
SB 5849

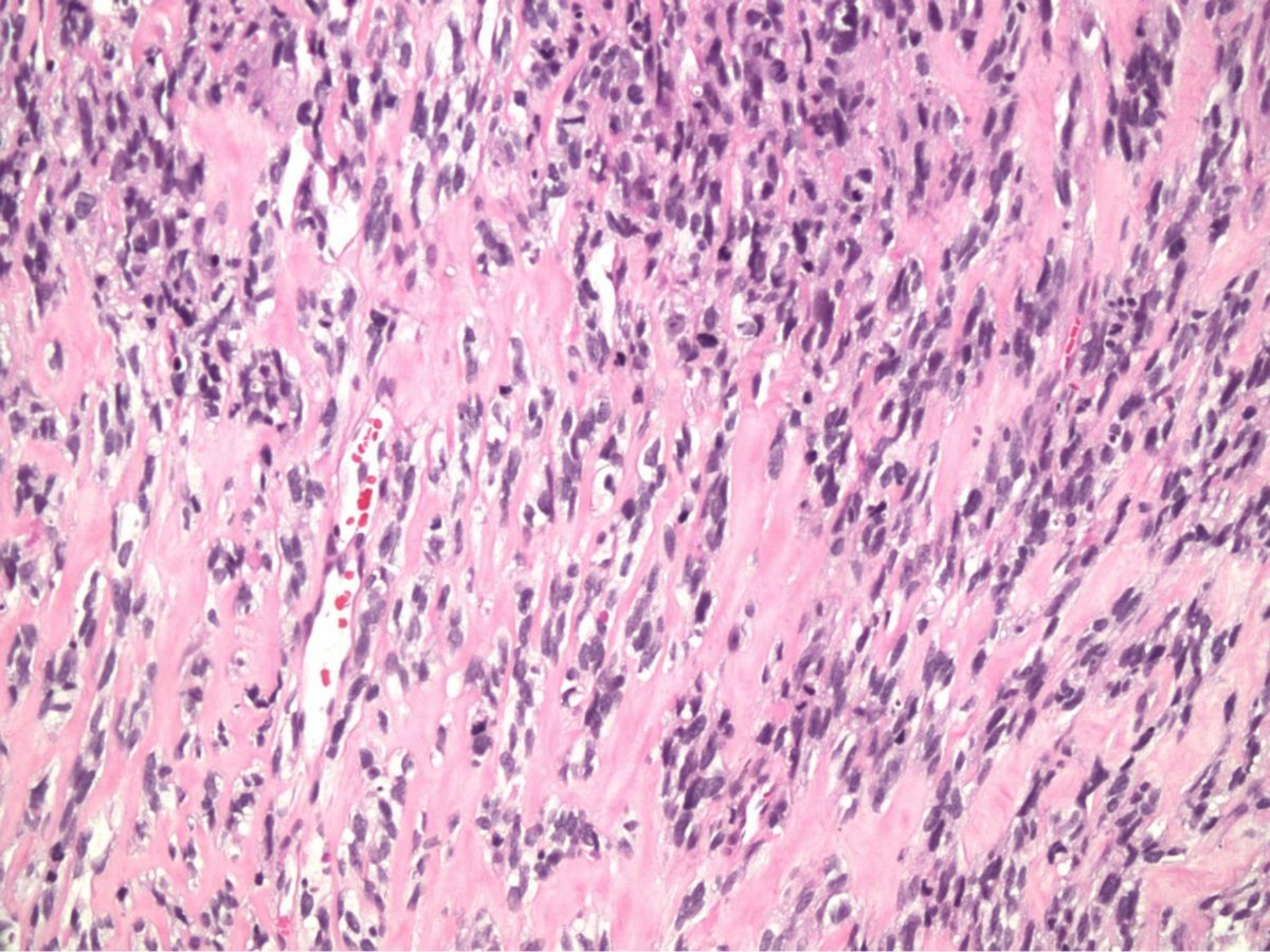
Sebastian Fernandez-Pol; Stanford

25-year-old man with chest wall
mass.









SB 5850

Sebastian Fernandez-Pol / Dean Fong; Stanford

82-year-old female with anemia.
Found to have mass in jejunum.

