

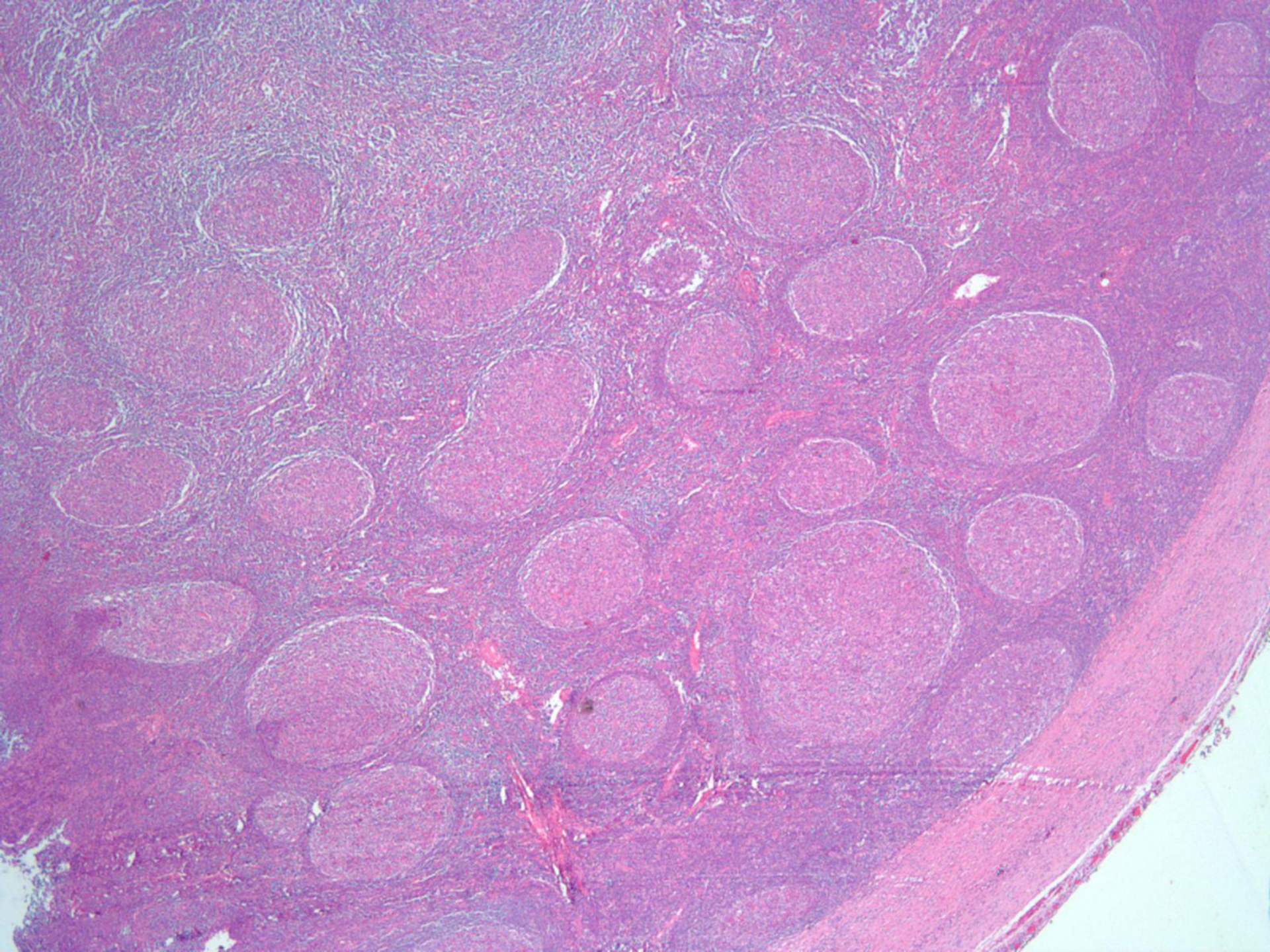
JUNE 2014 SBPS meeting

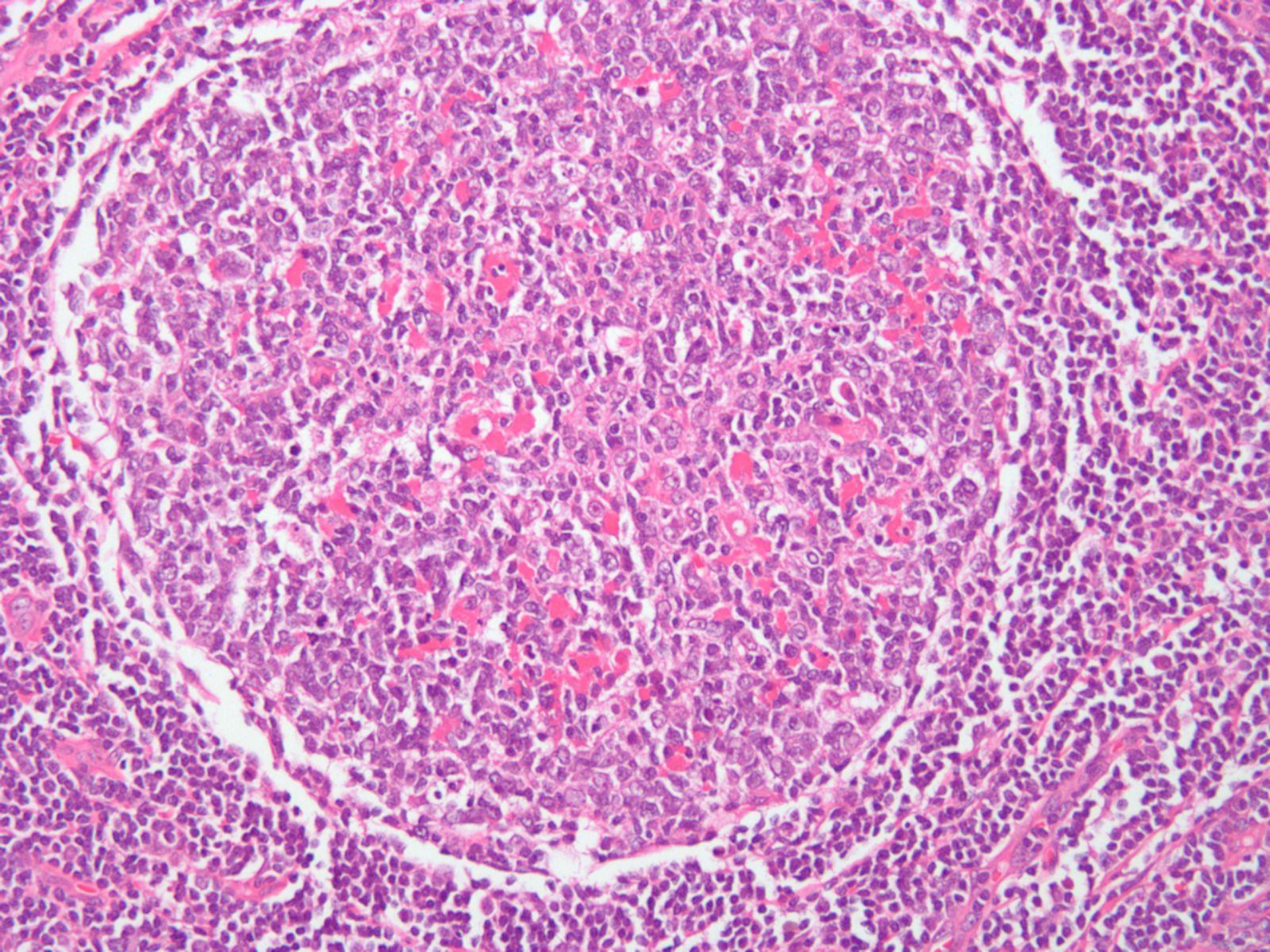
Disclosures

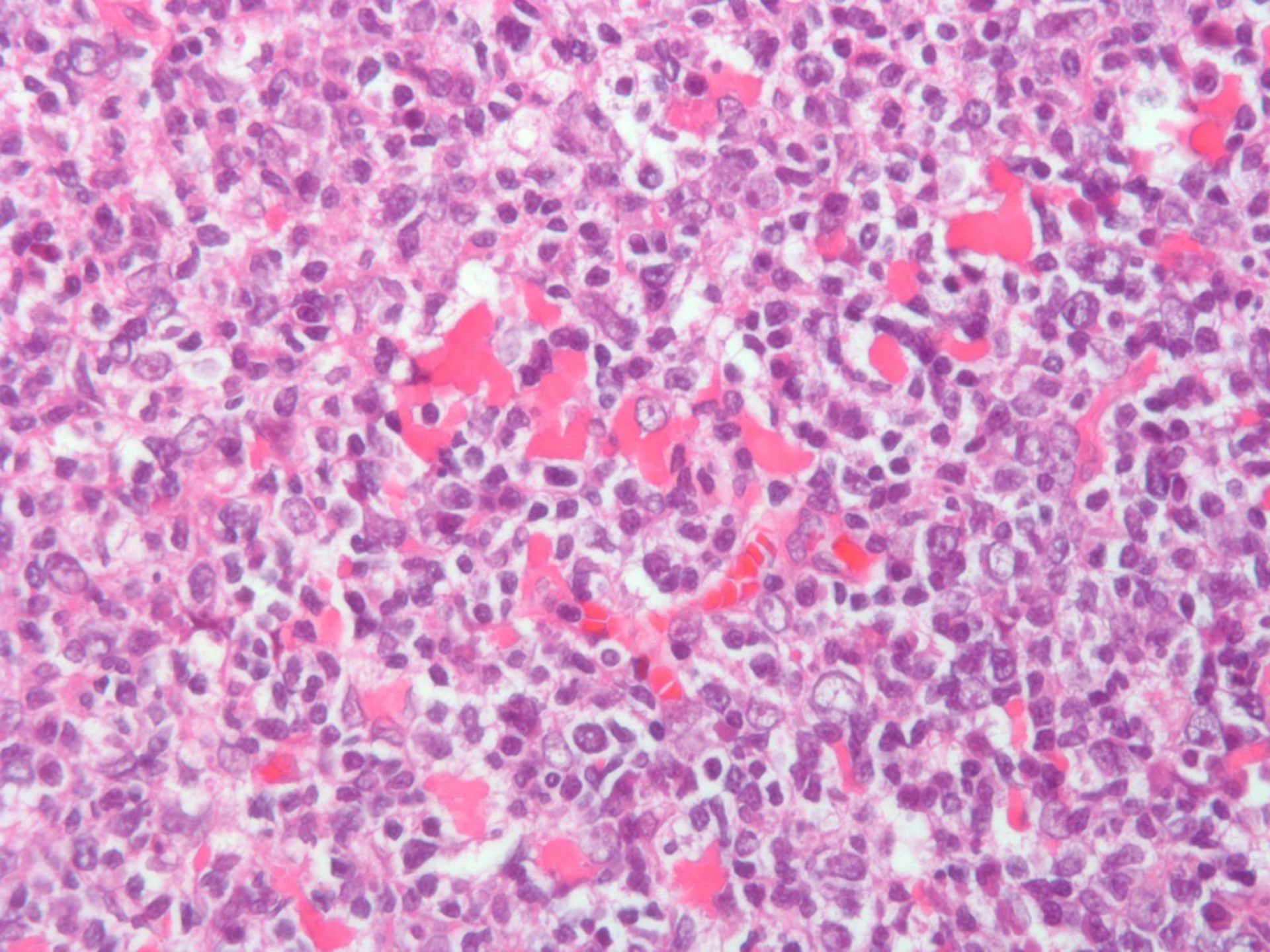
All presenters and planning committee members listed have disclosed that they have no financial relationships with commercial or industry organizations. The Education Committee has reviewed the disclosure information for the planner(s), and/or committee/faculty for this program and they do not have relationships that present a conflict of interest.

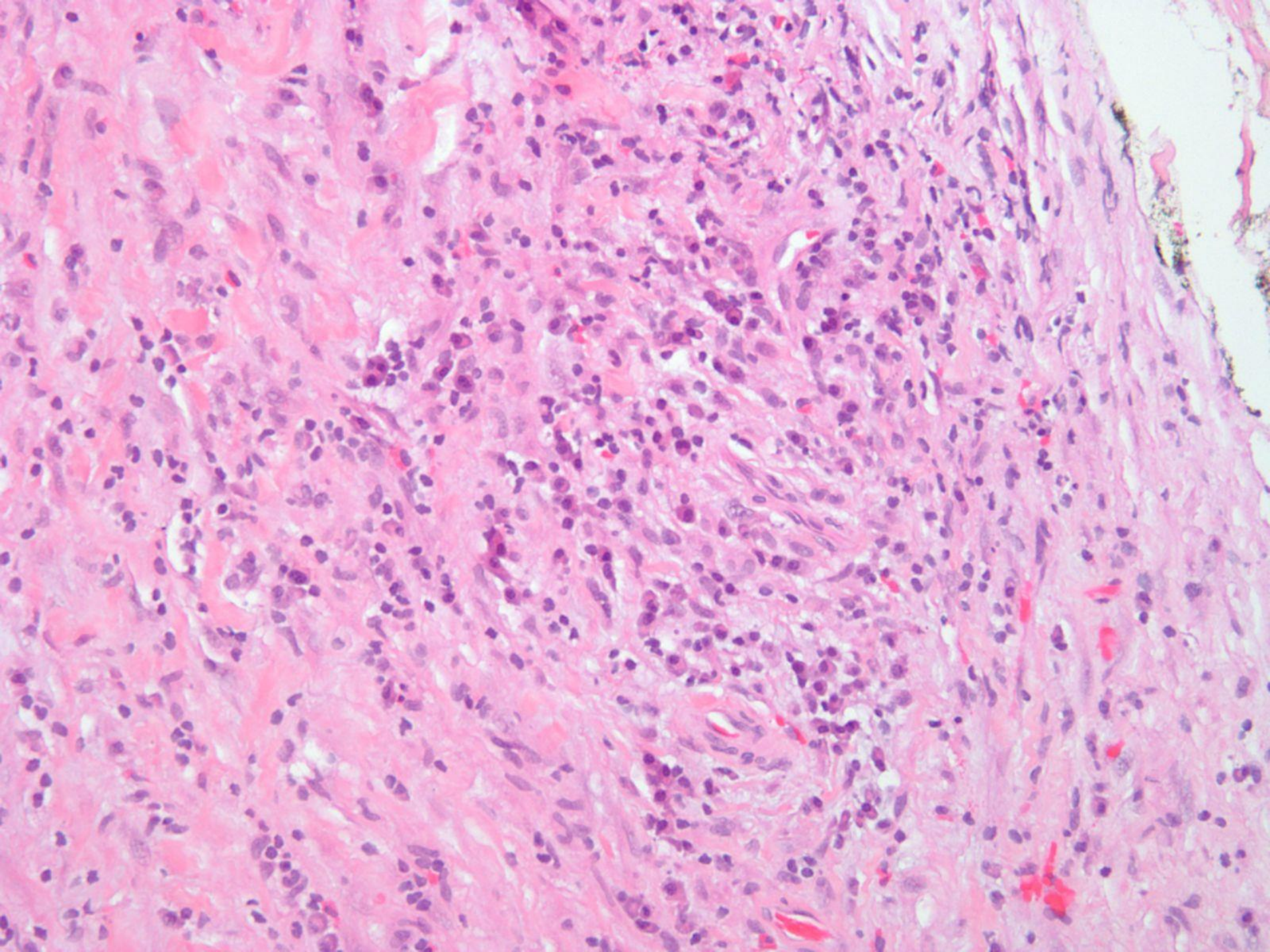
SB 5831

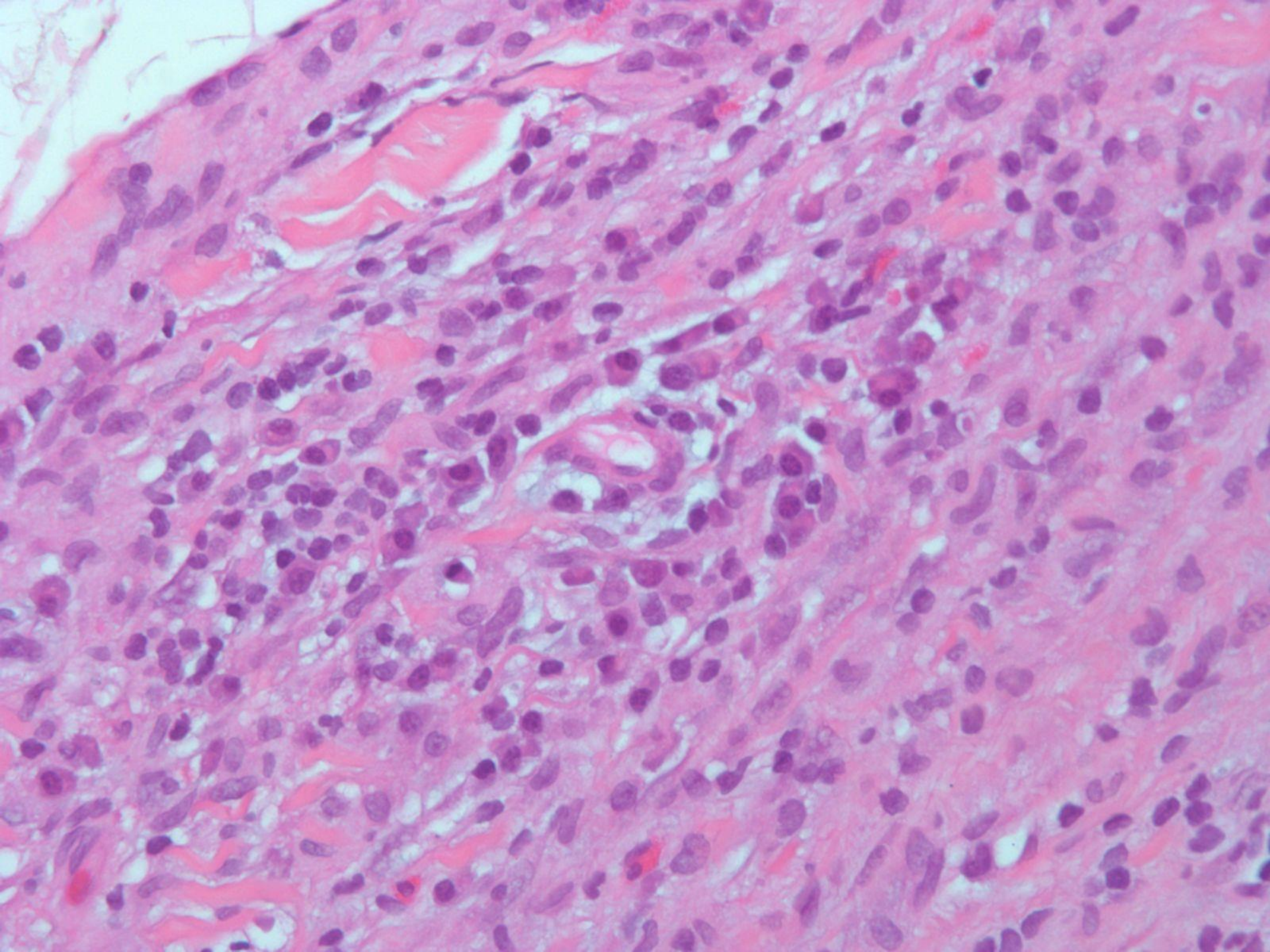
30-year-old male with left cervical
lymph node excision.





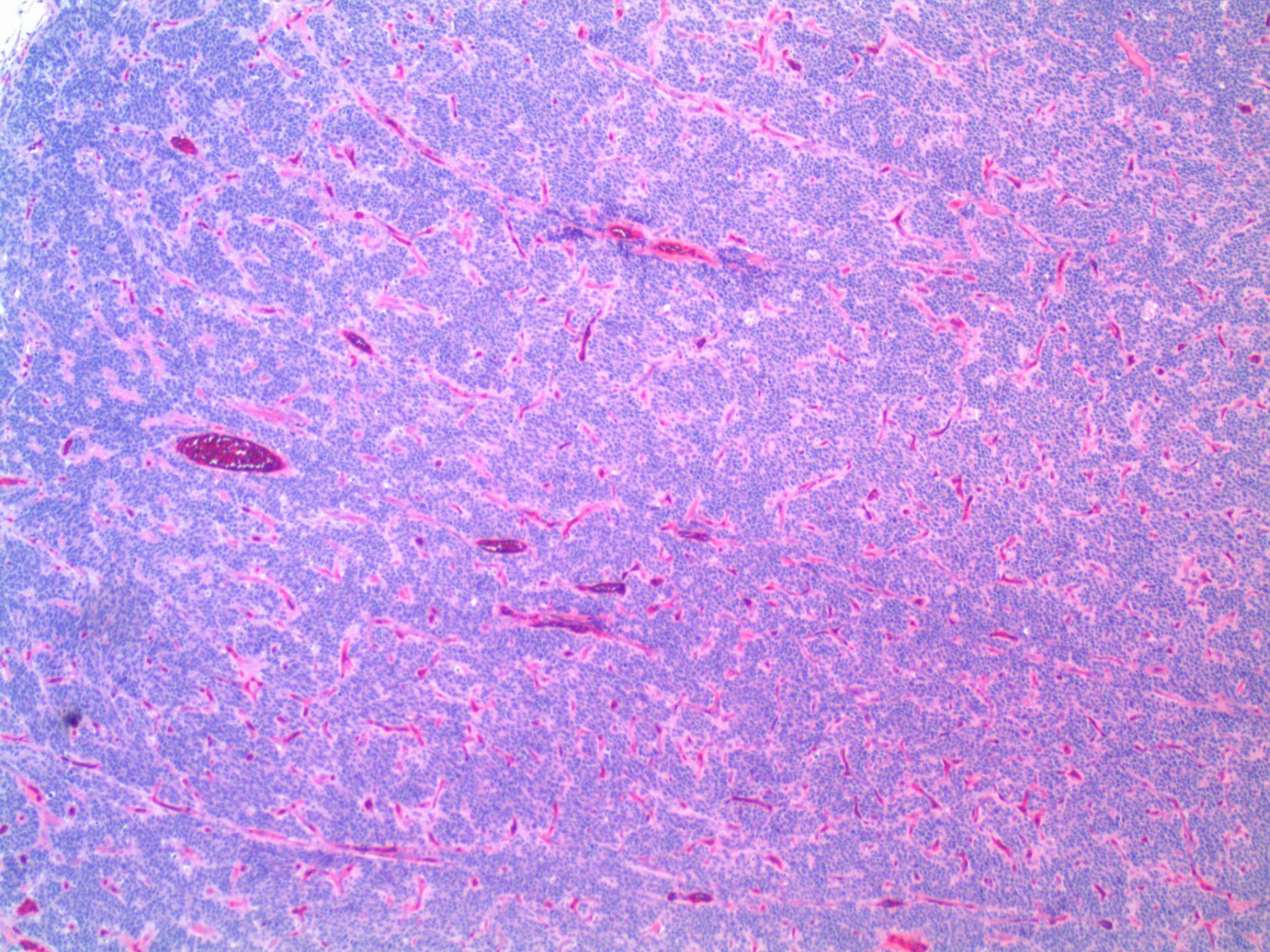


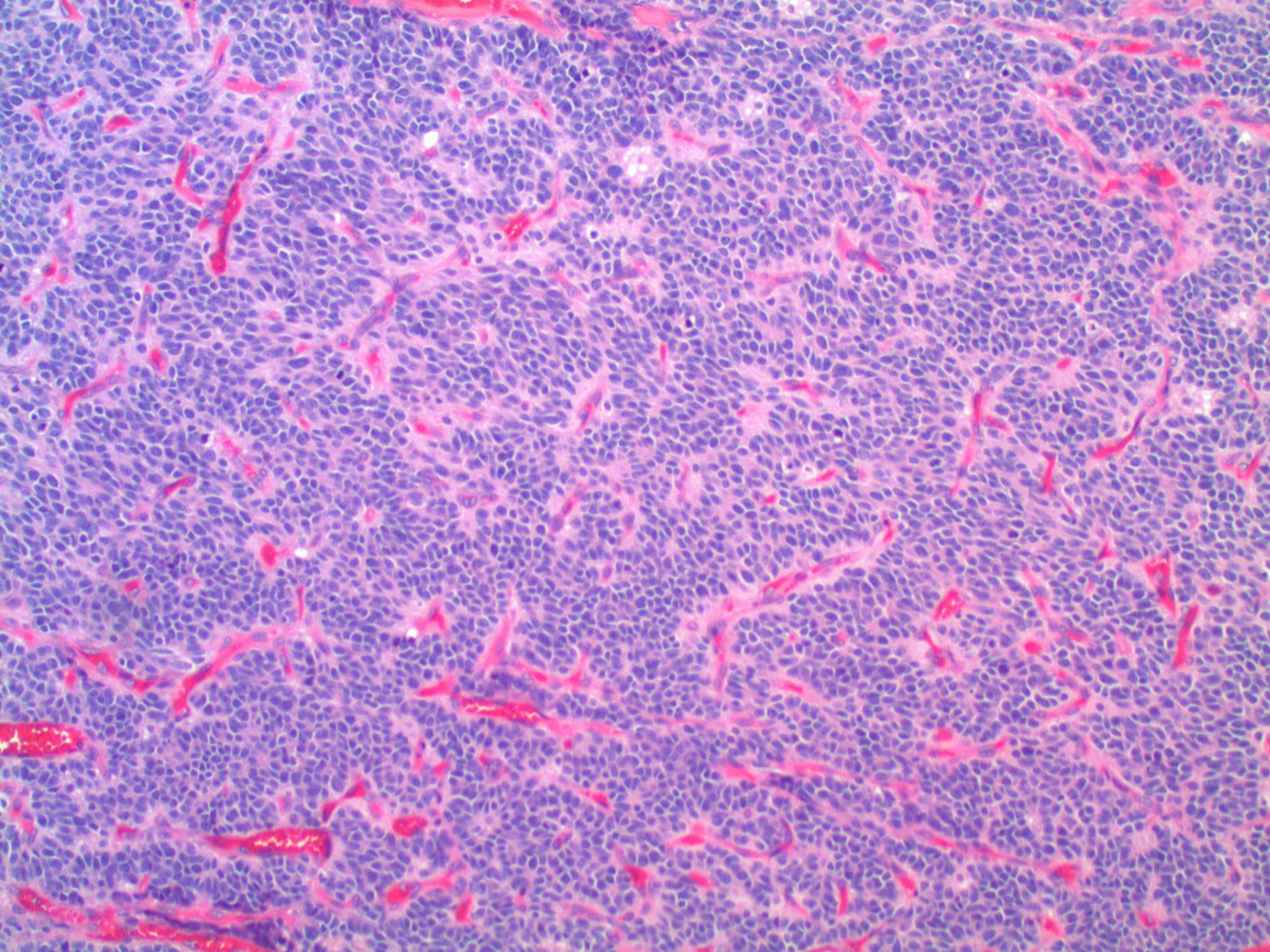


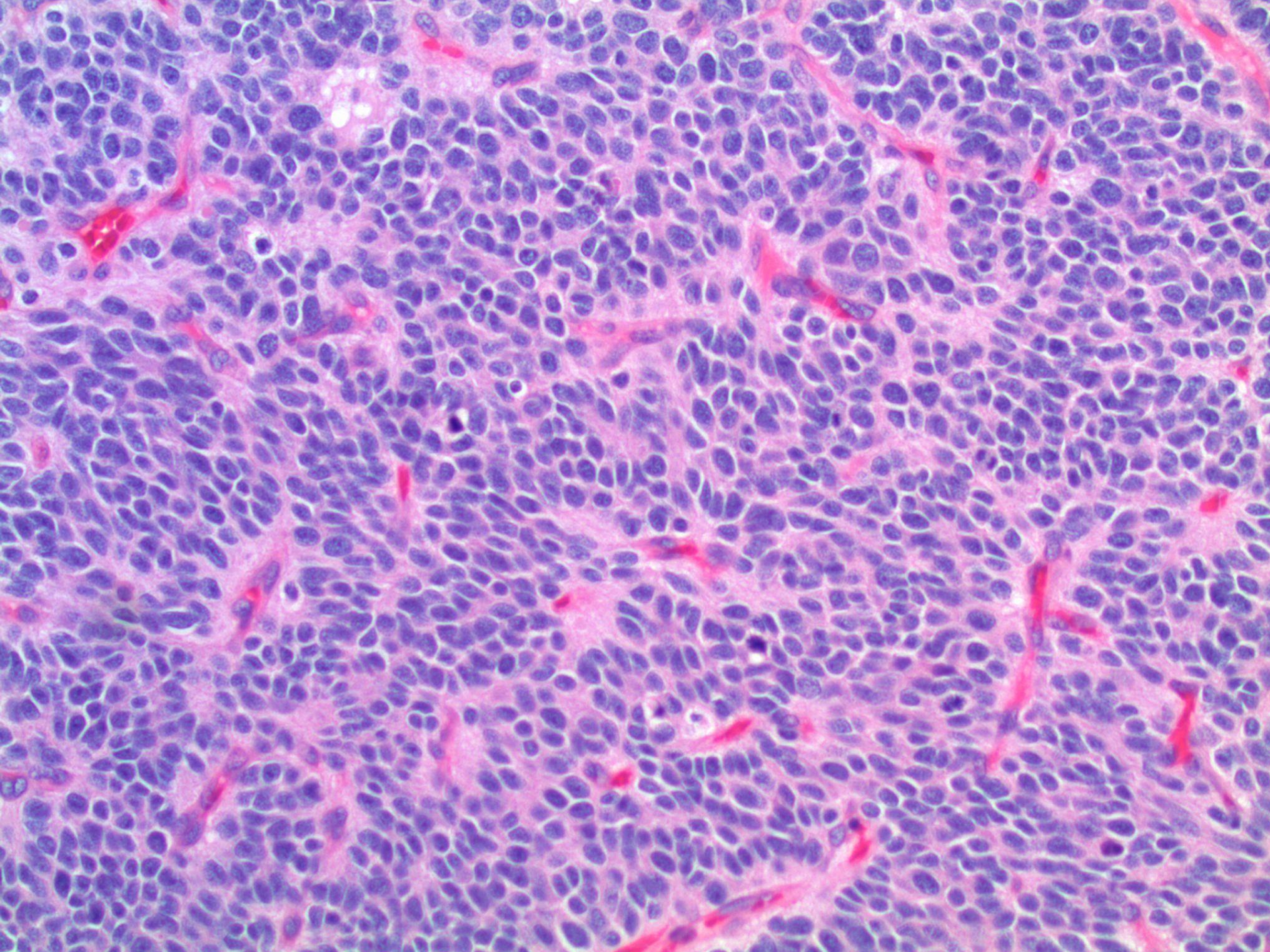


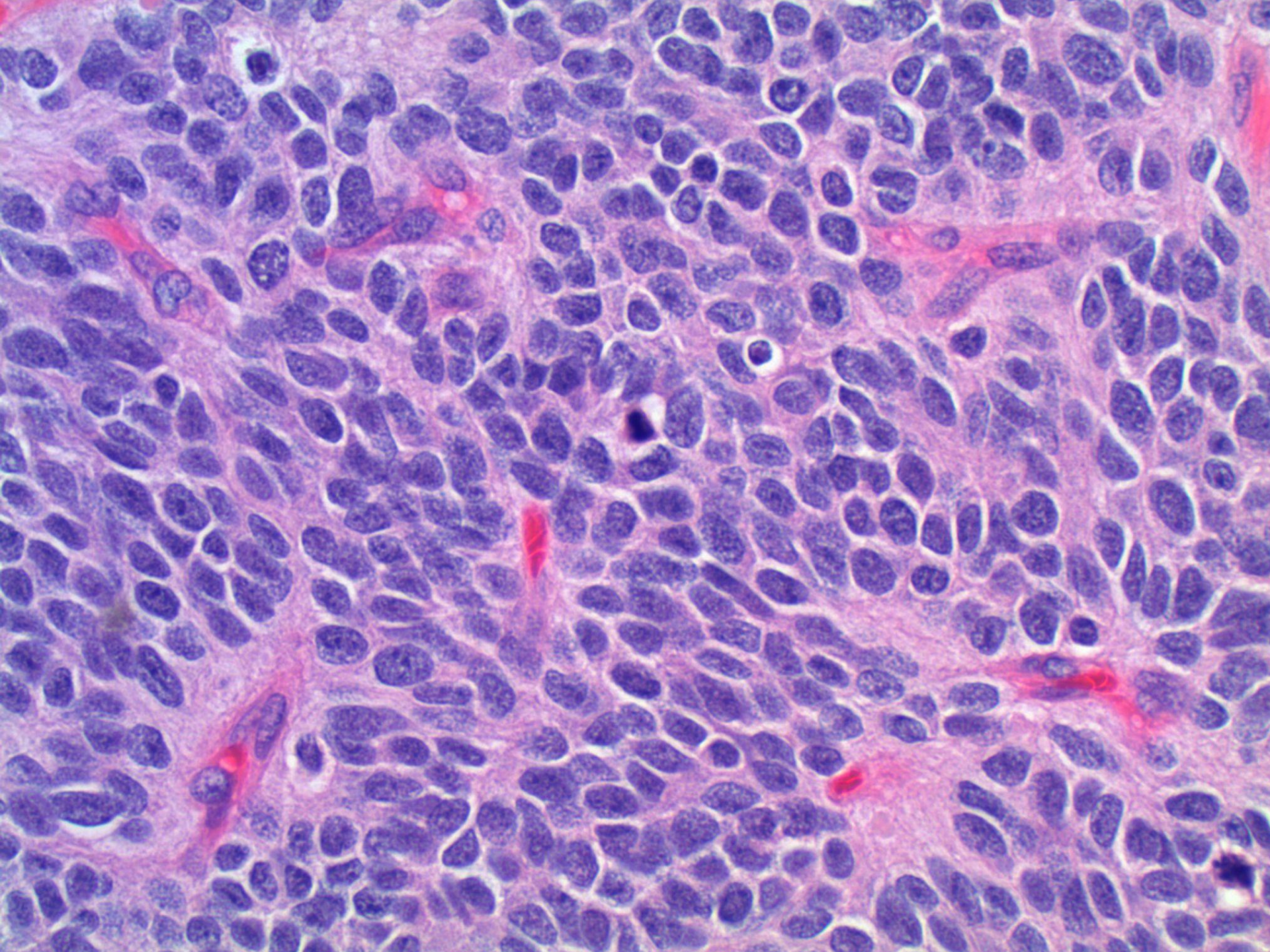
SB 5832

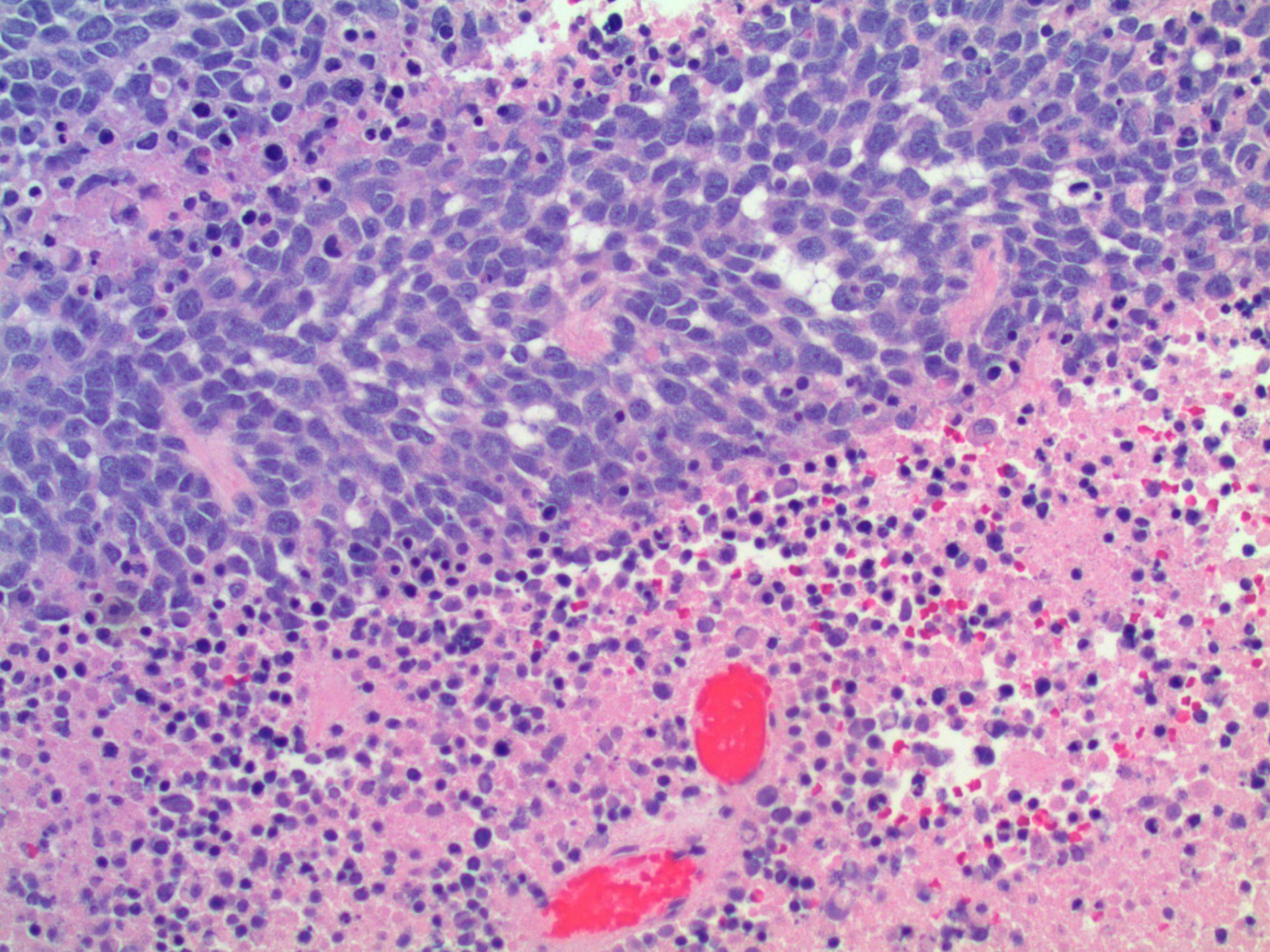
2-year-old boy with recent onset of epileptic staring and drooling episodes. Large partially cystic/solid heterogenously contrast-enhancing calcified left frontoparietal mass identified, reportedly “shelled out” by neurosurgery.





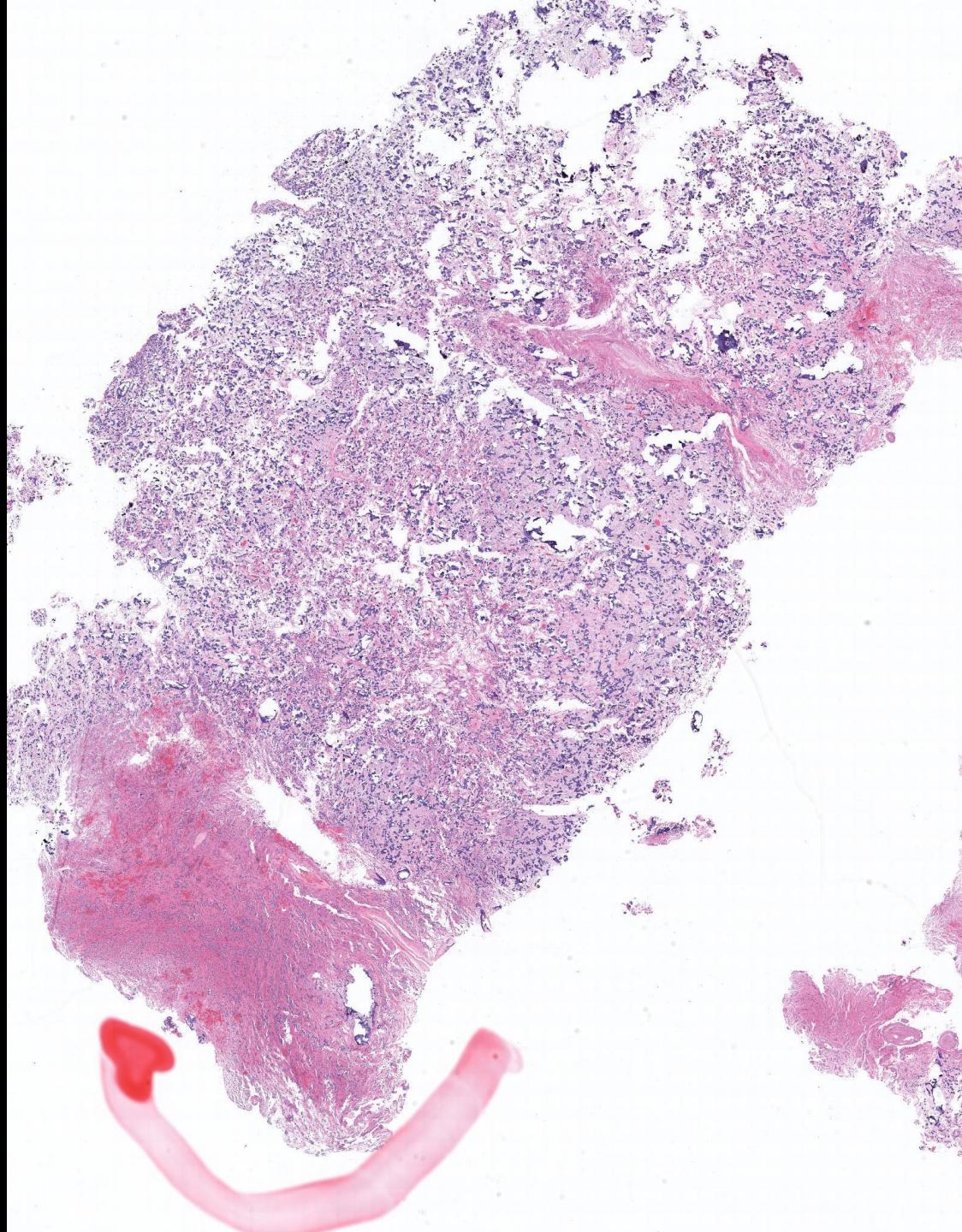


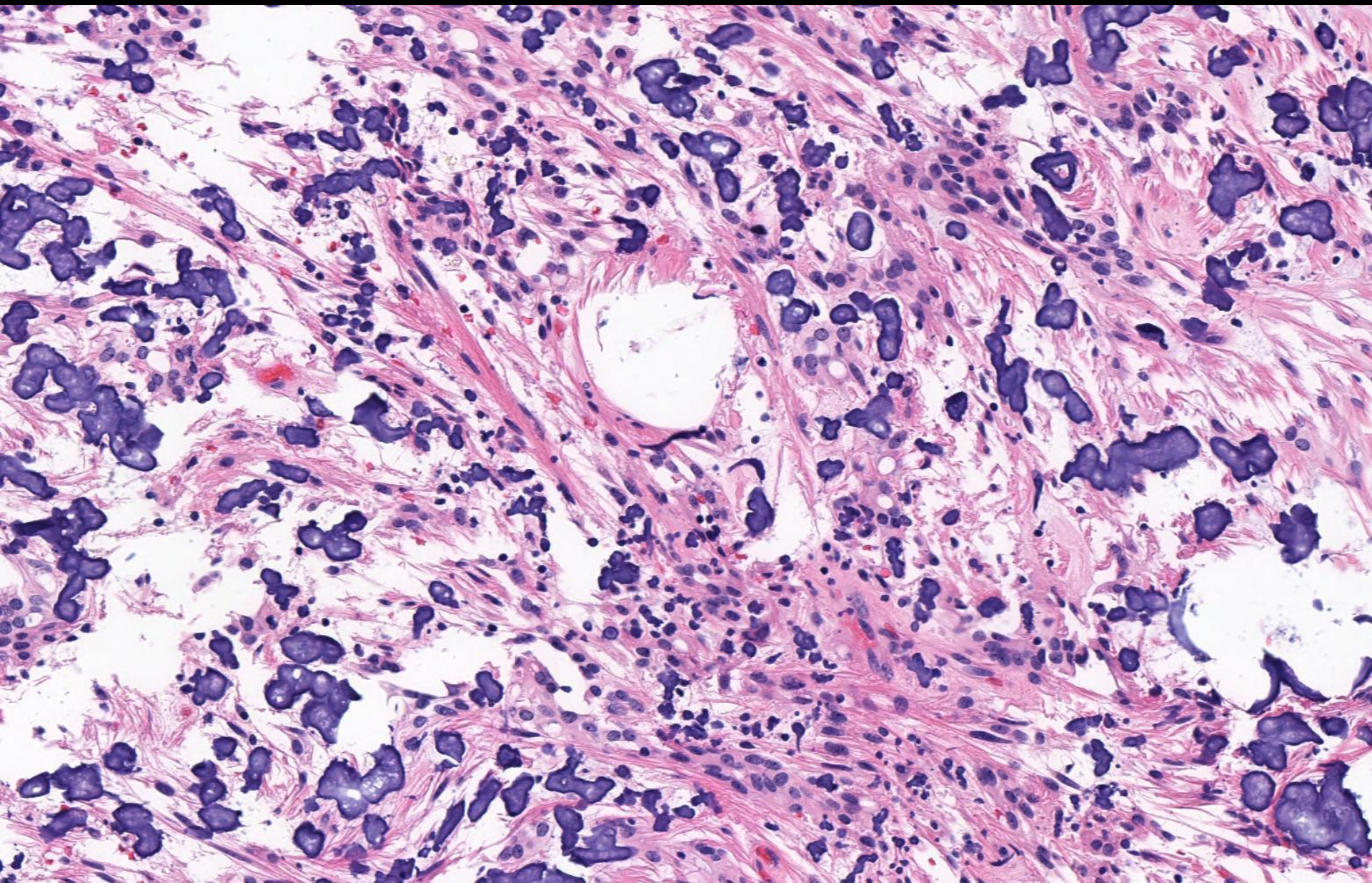


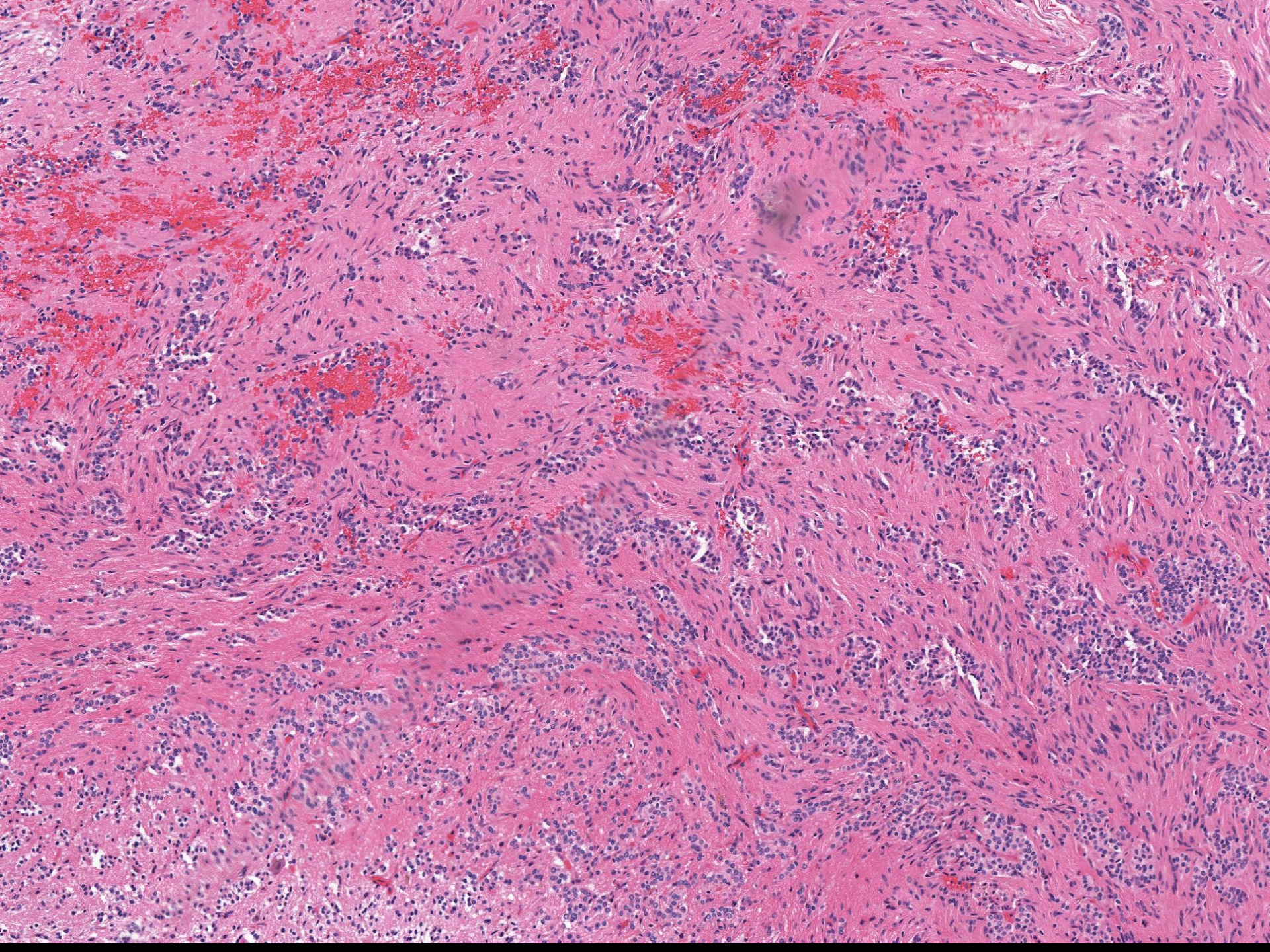


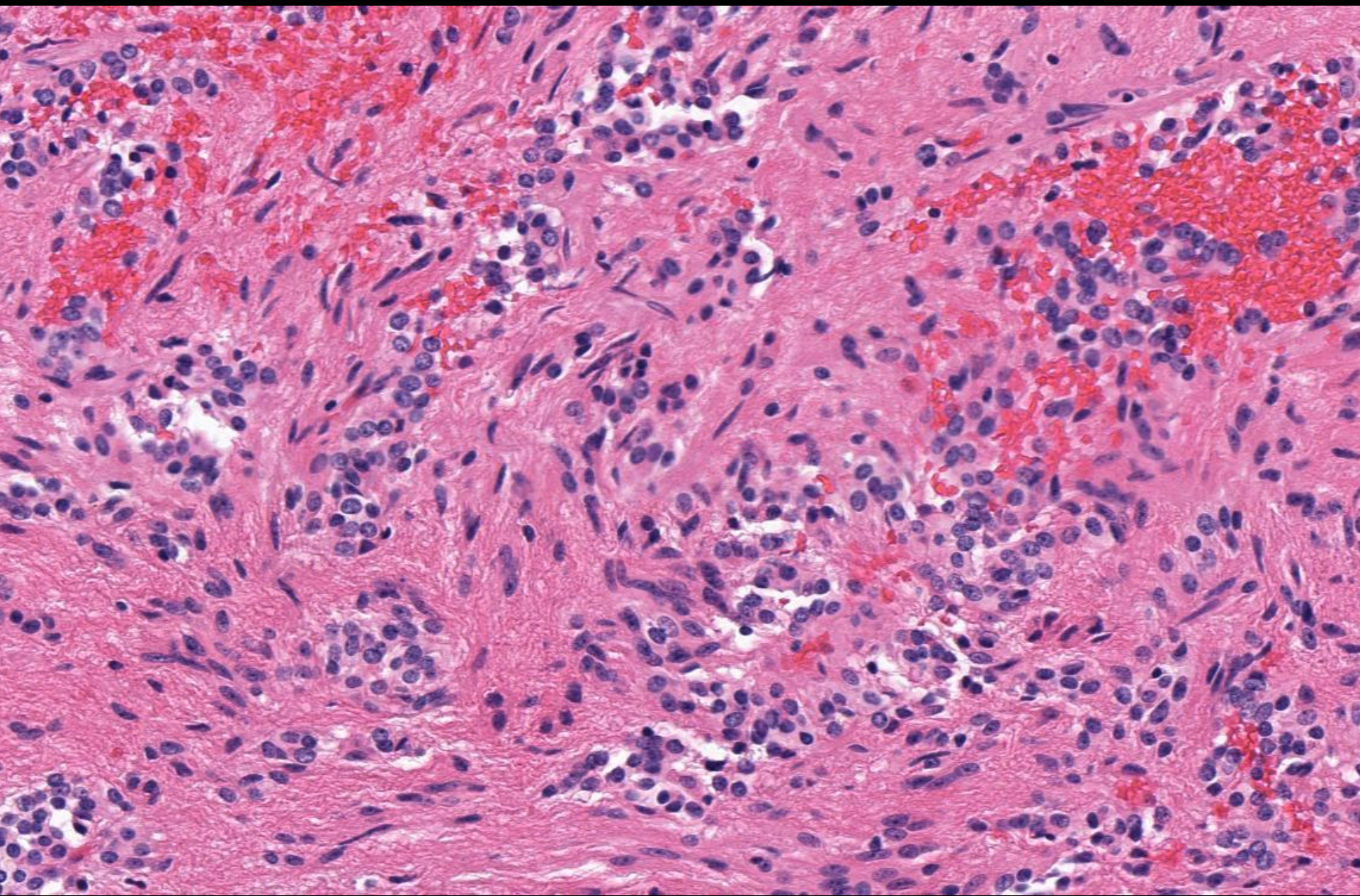
SB 5833

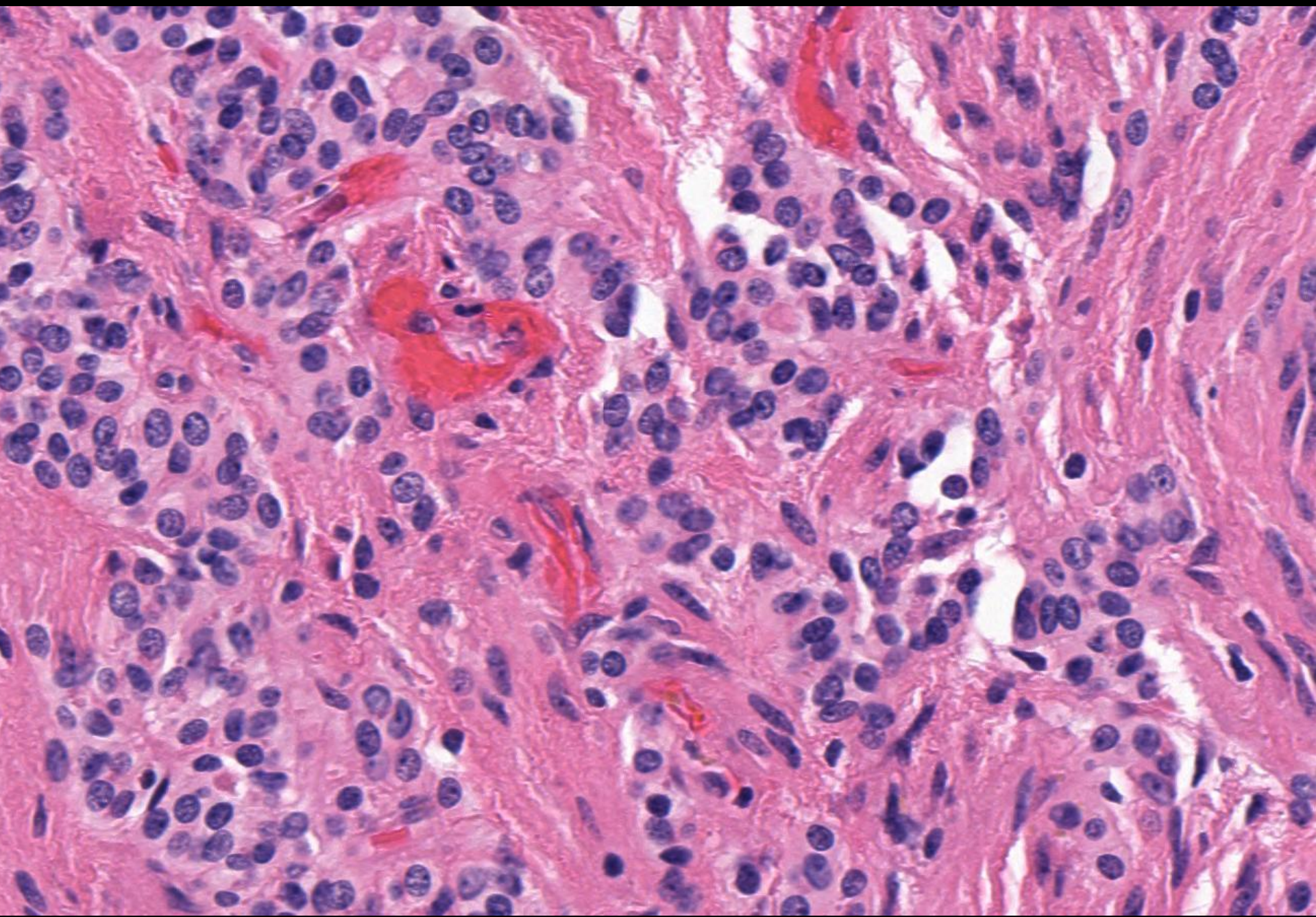
67-year-old man with 37 year history of epilepsy. Densely calcified lesion near the right hippocampus resection. “Rule out cavernous malformation.”





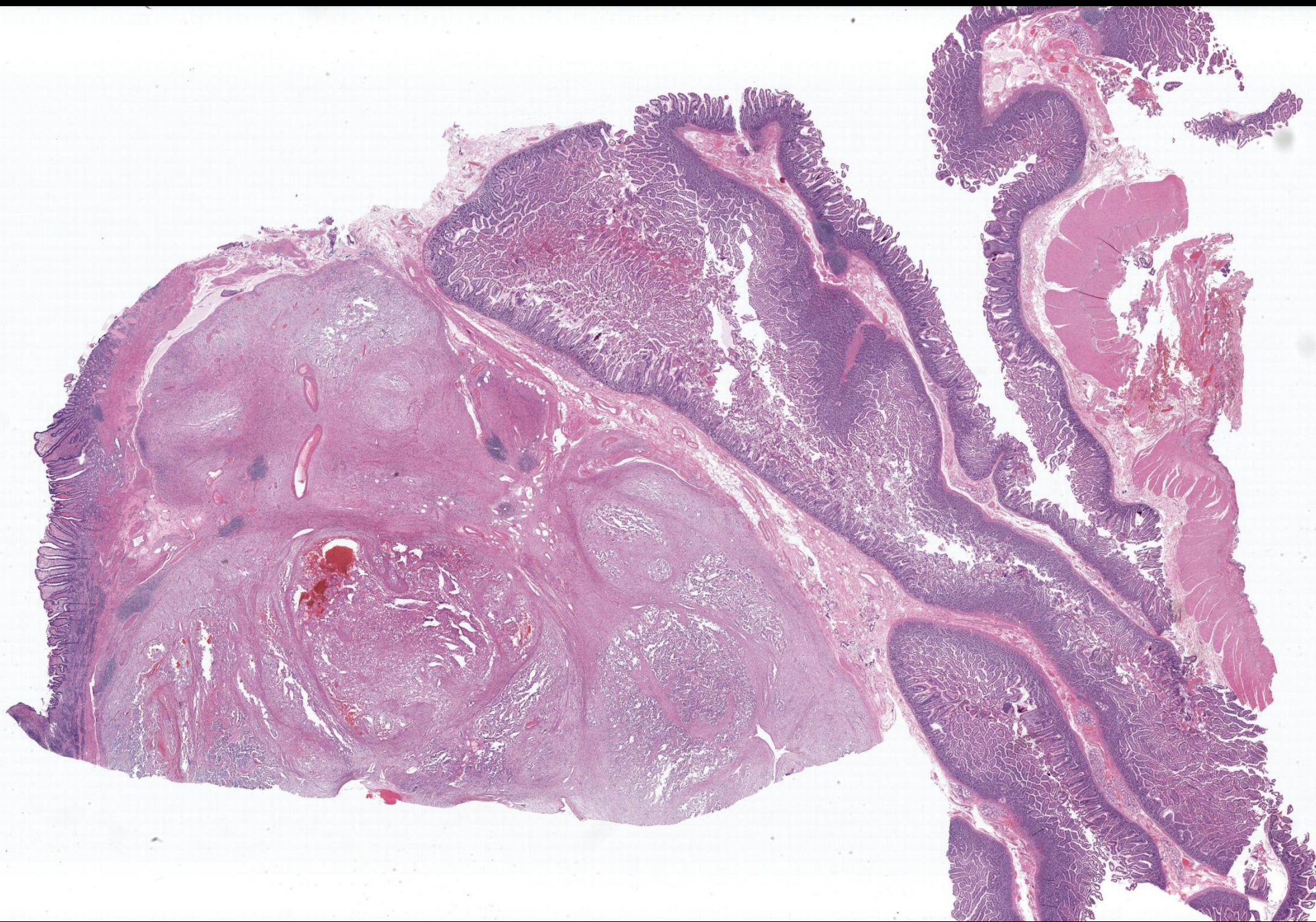


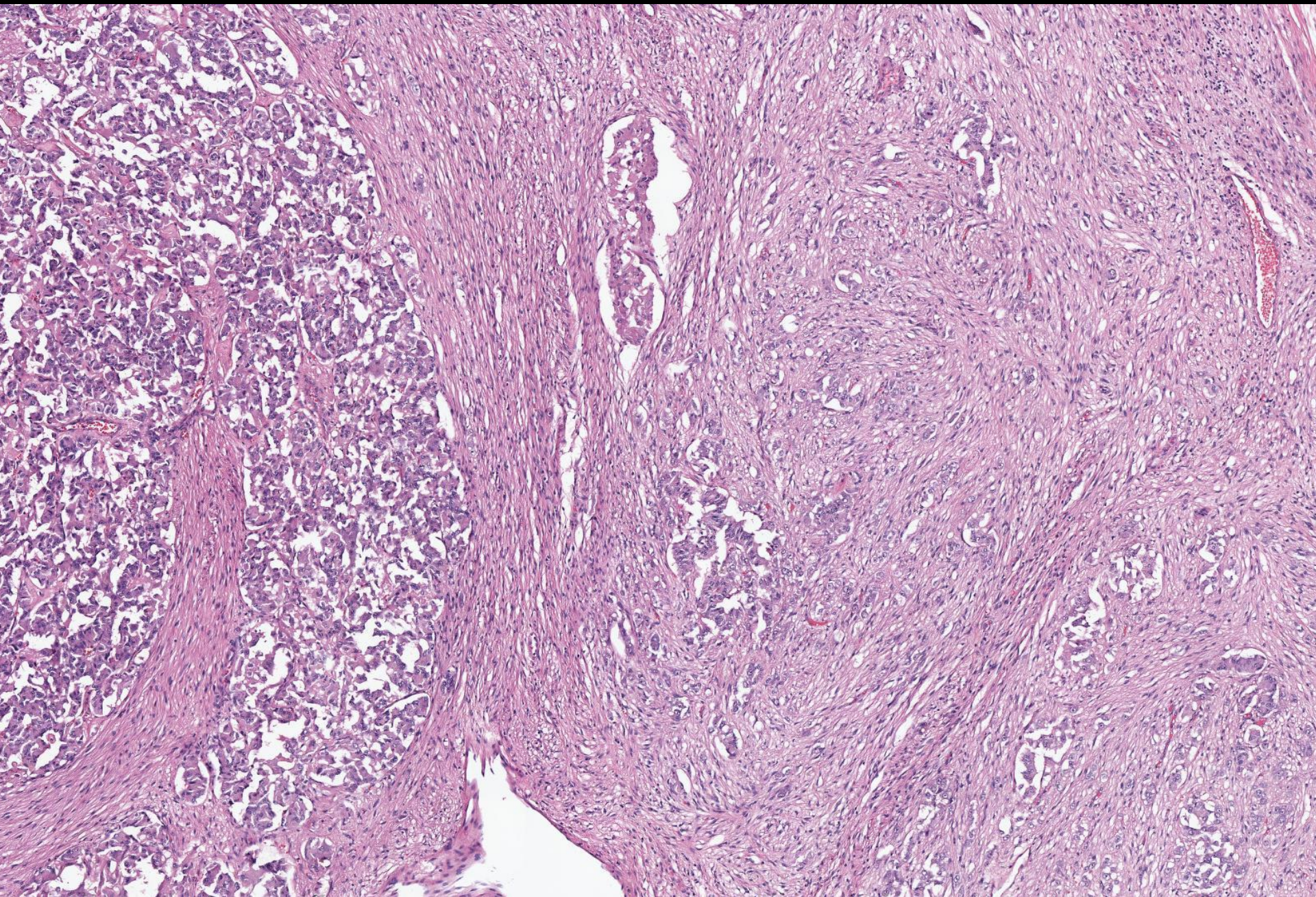


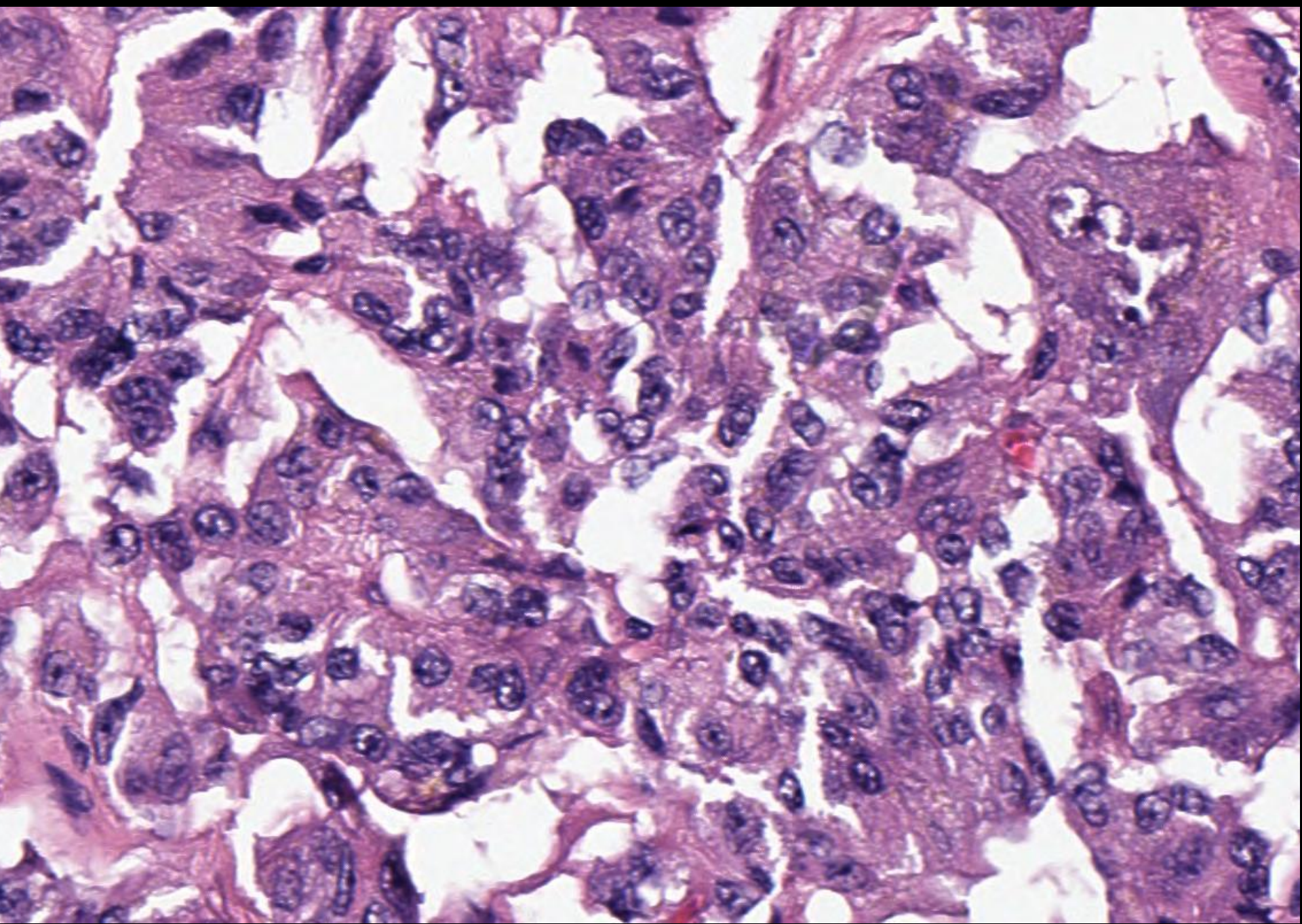


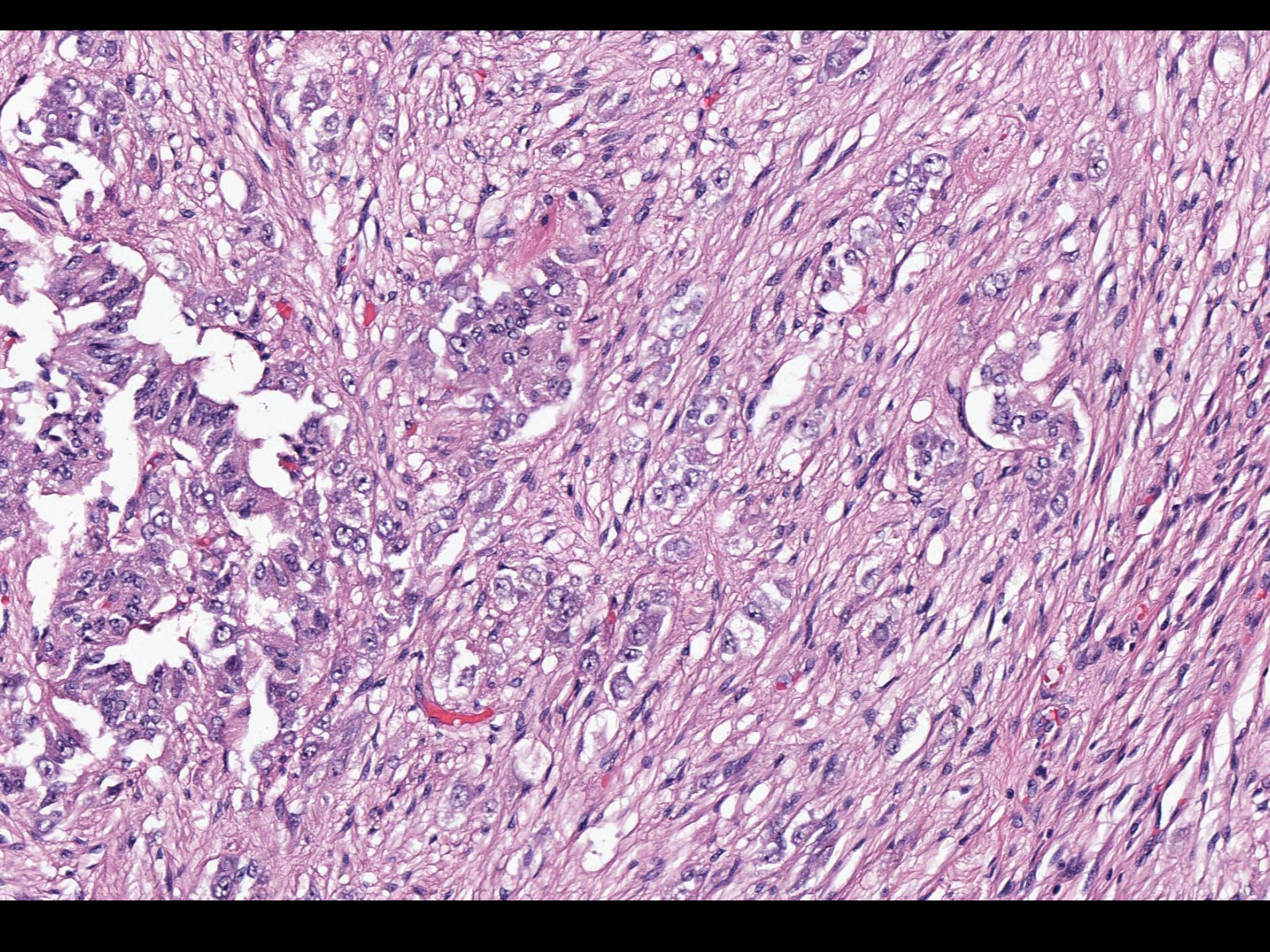
SB 5834

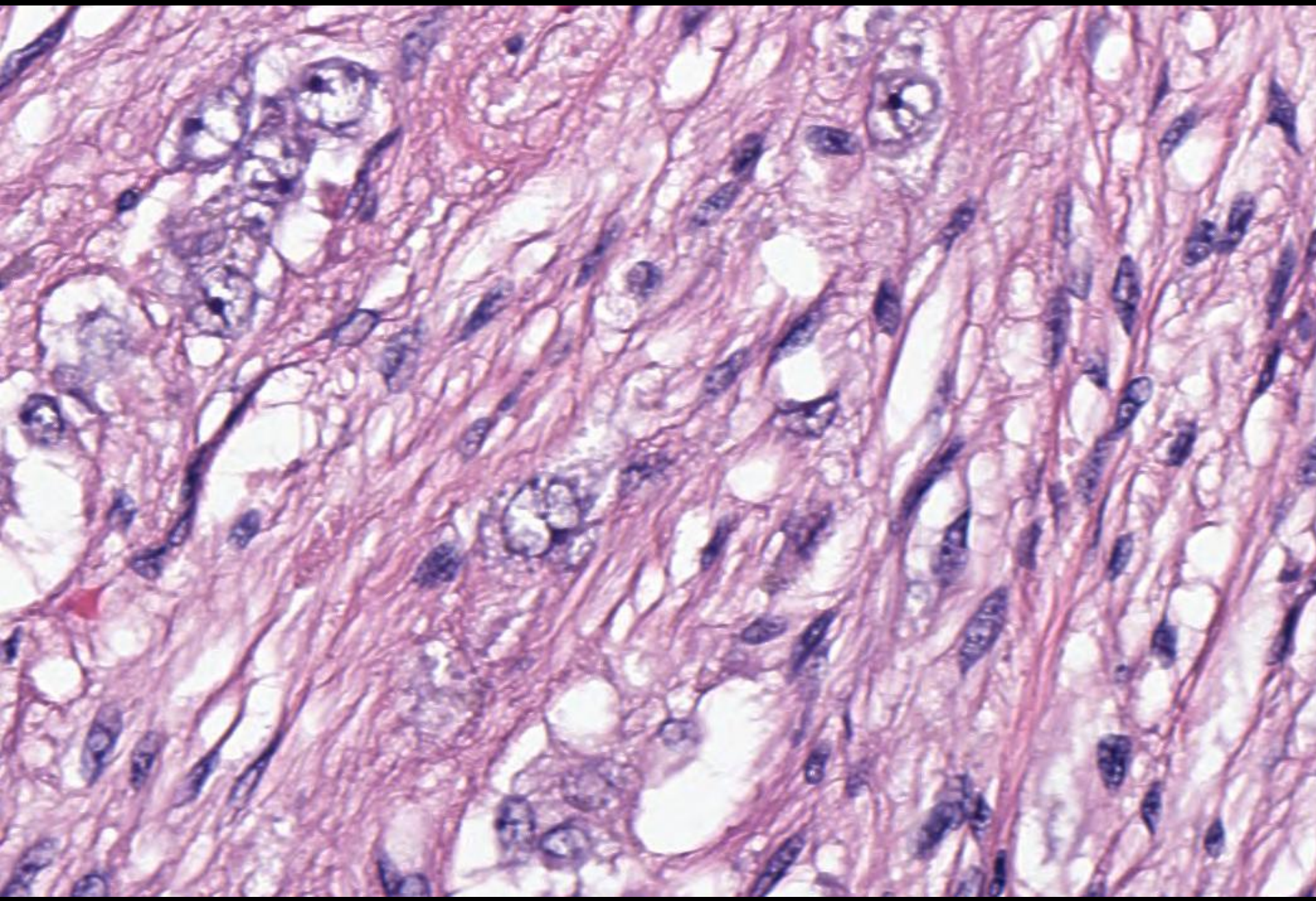
Adult male with duodenal mass.





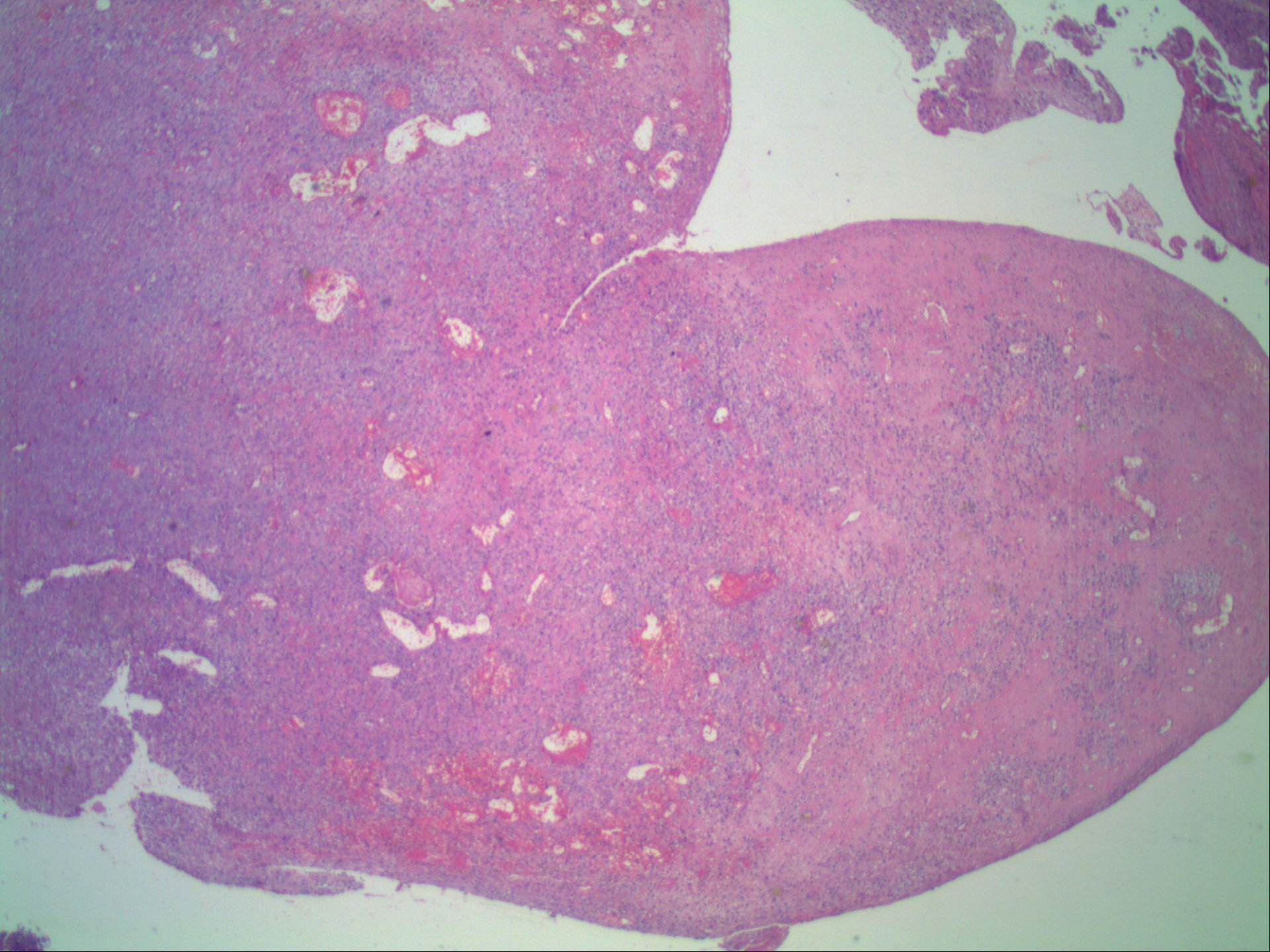


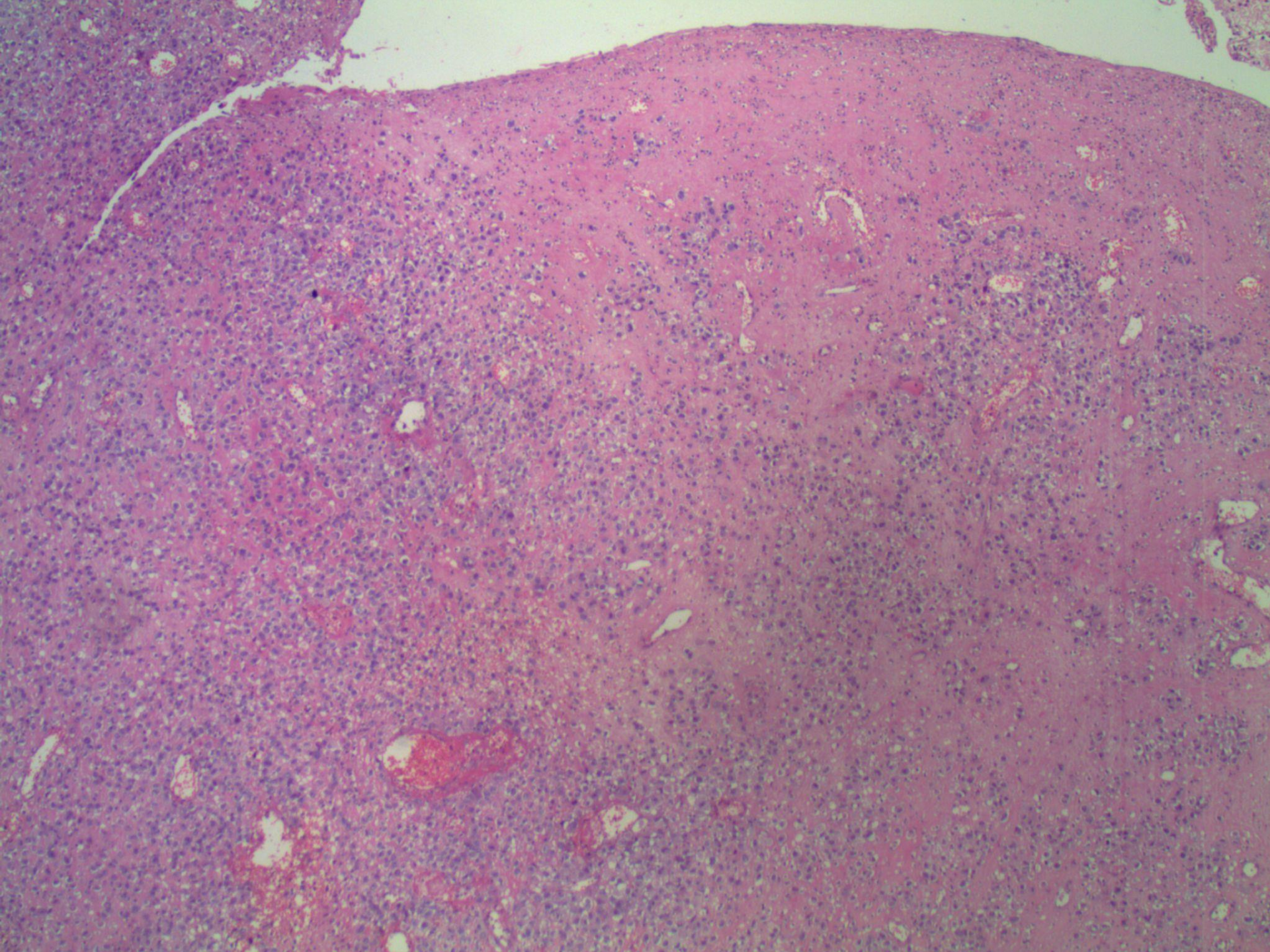


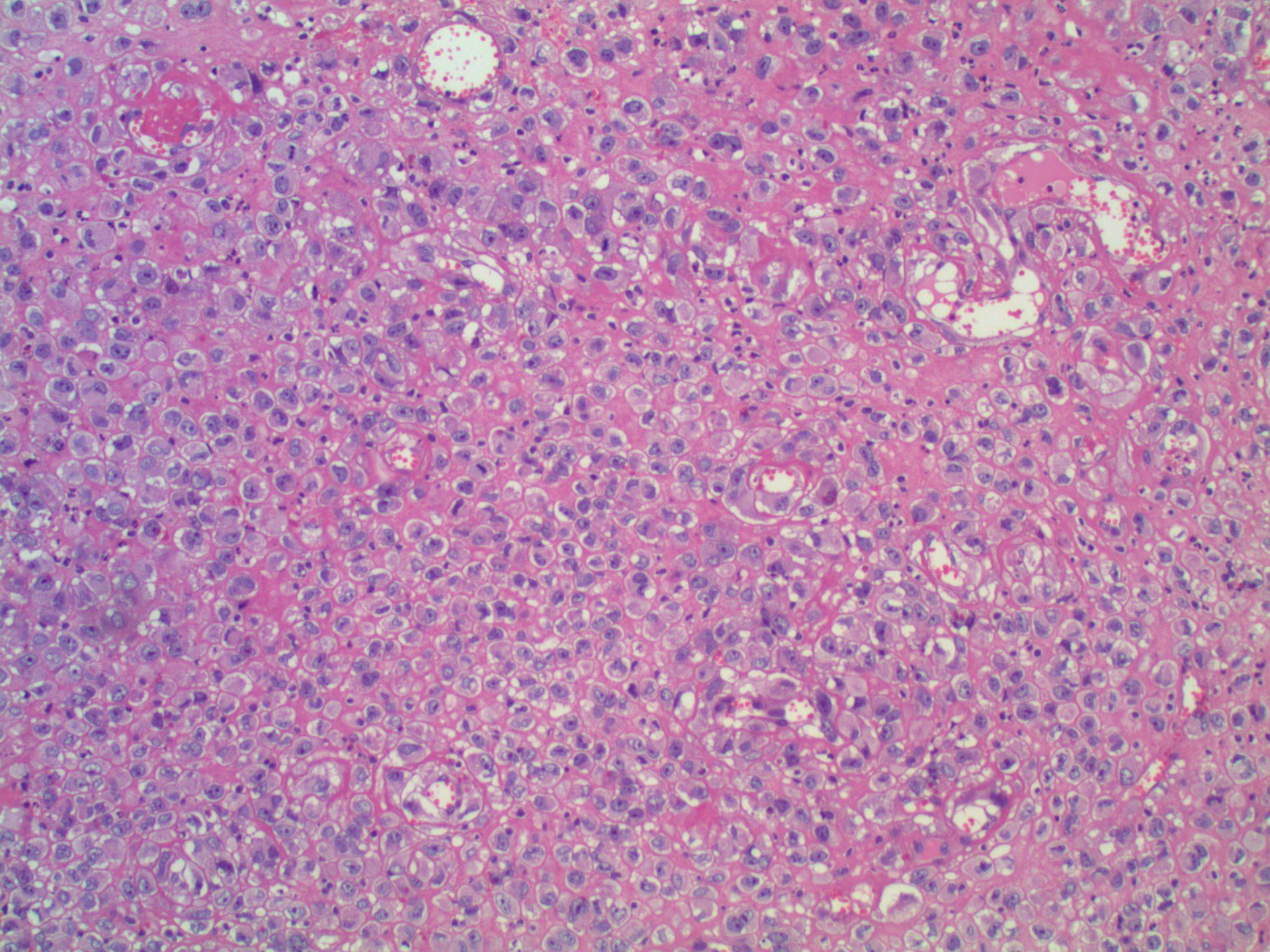


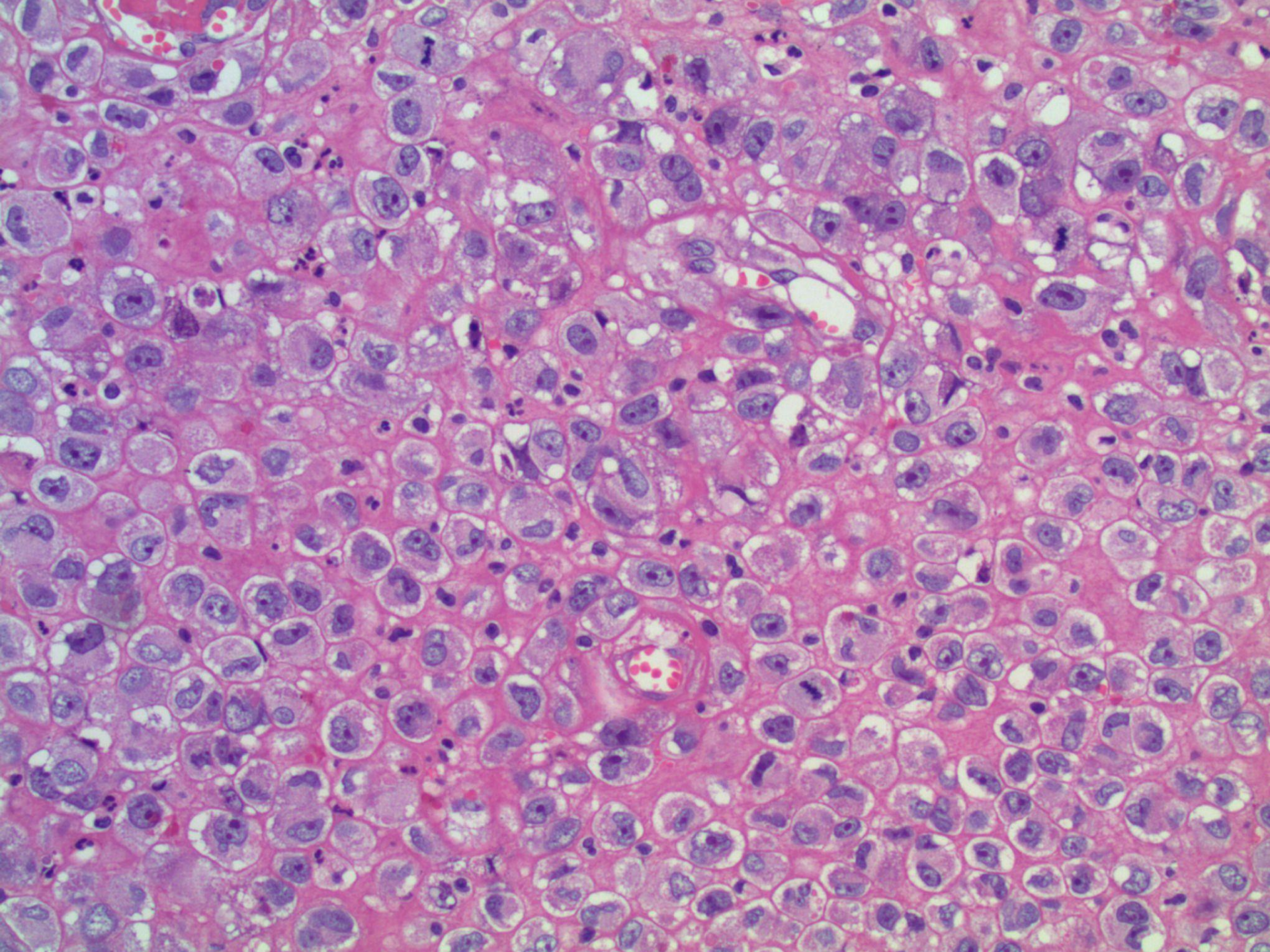
SB 5835

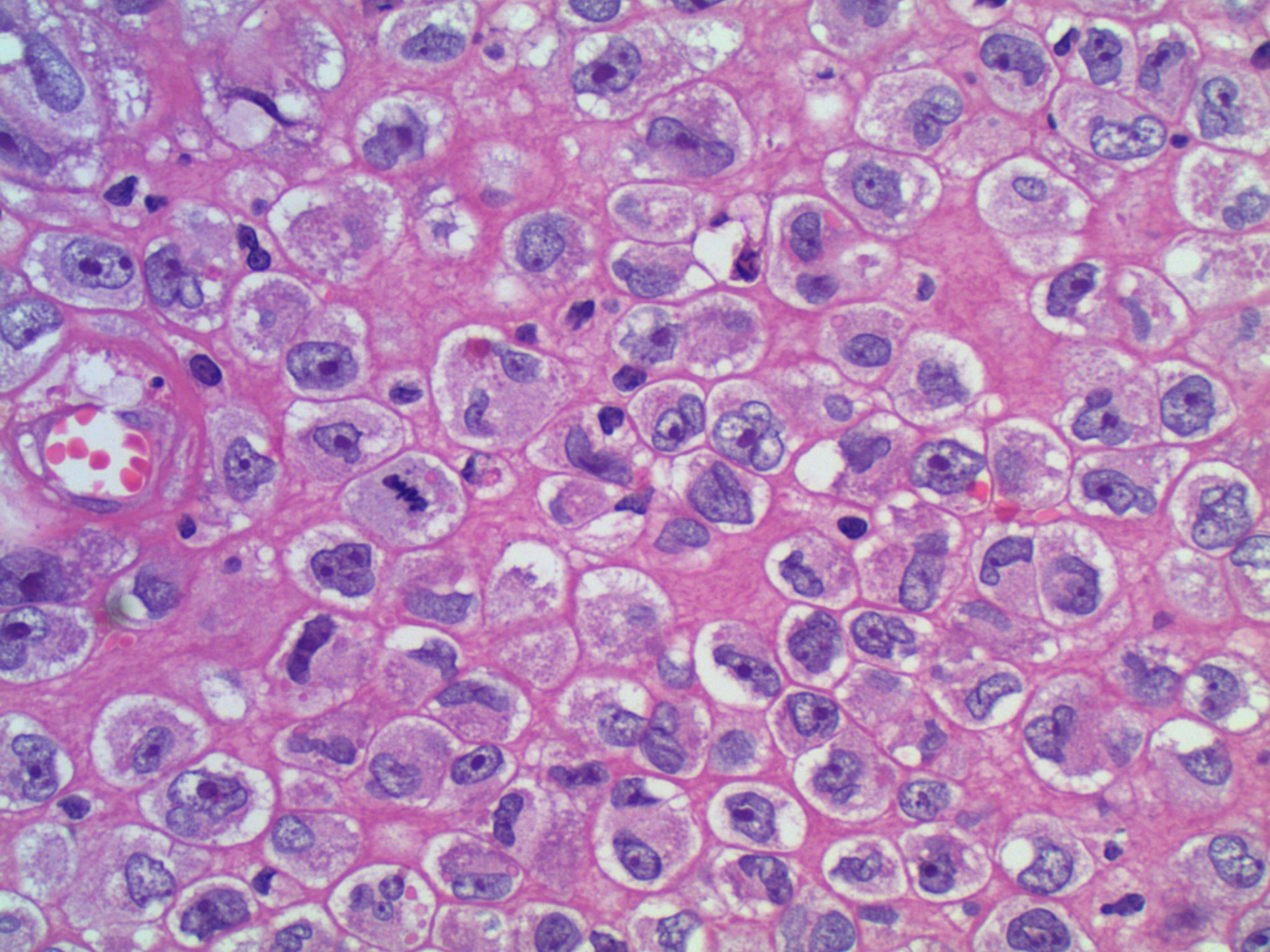
55-year-old male had asymptomatic thyroid swelling extending to mediastinum for 15 years, which on excision revealed “papillary carcinoma, diffuse follicular variant”. He had post-operative radio-iodine therapy but 2 months following surgery developed breathlessness and stridor due to an intratracheal fleshy mass which was biopsied.

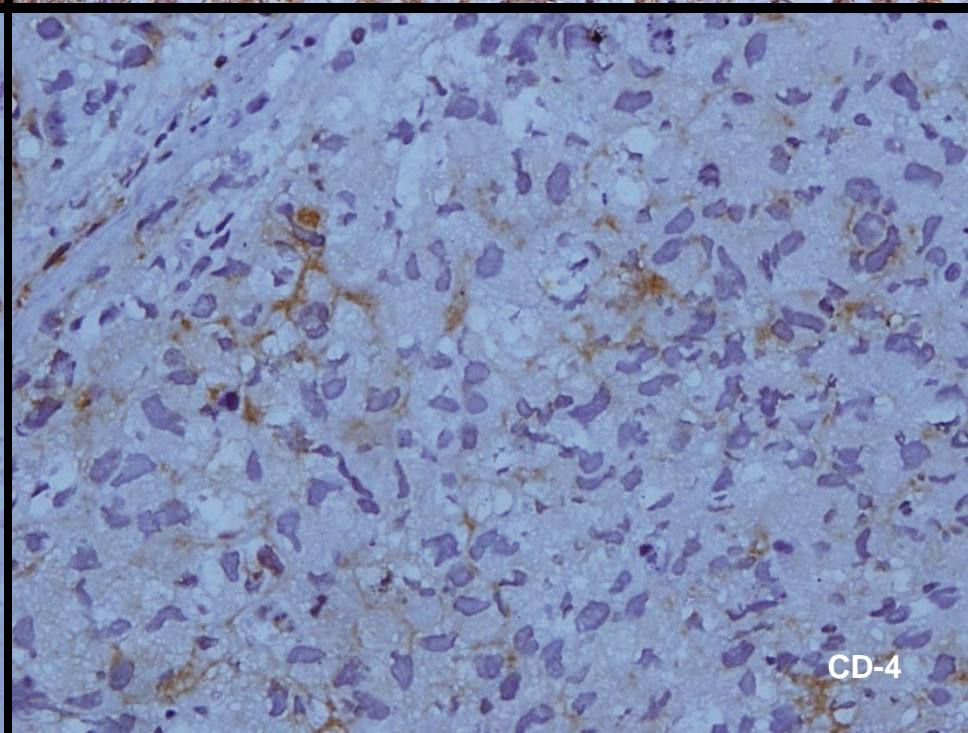
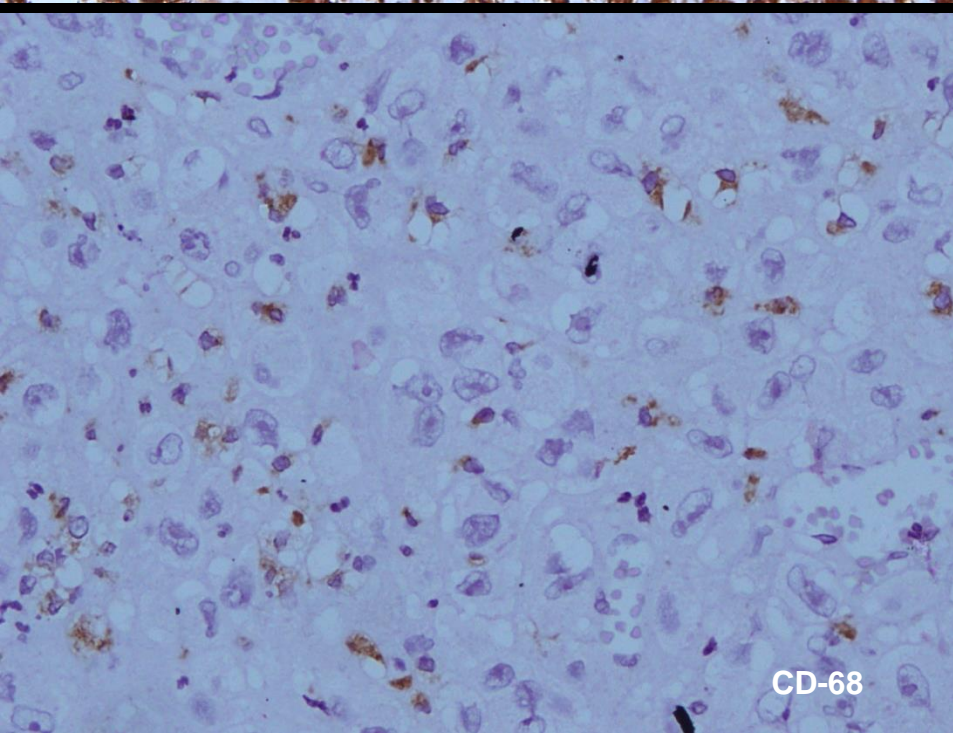
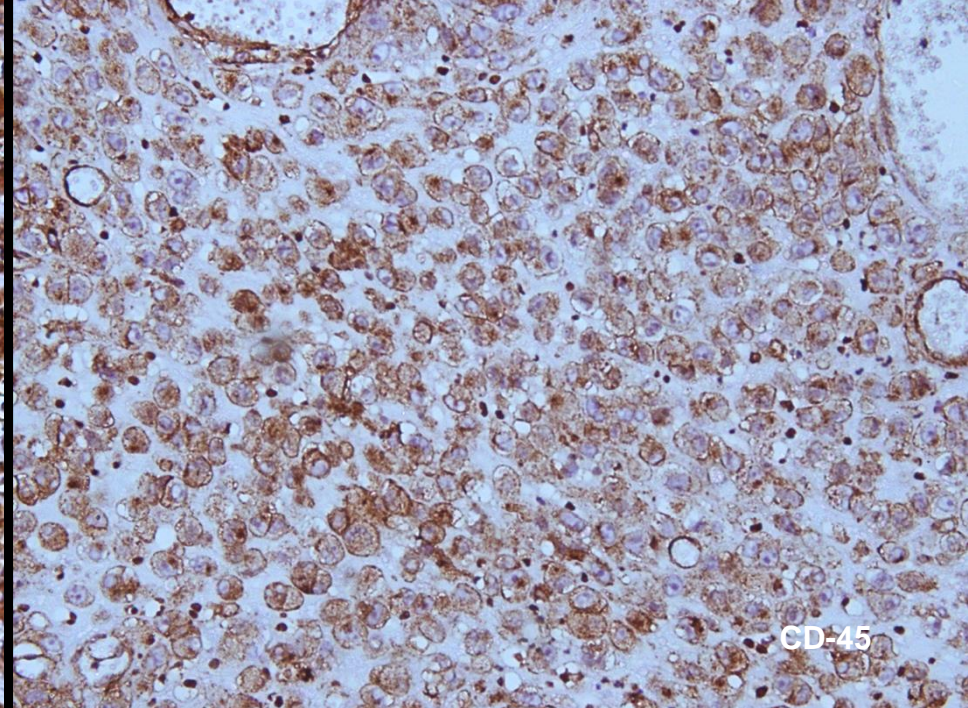
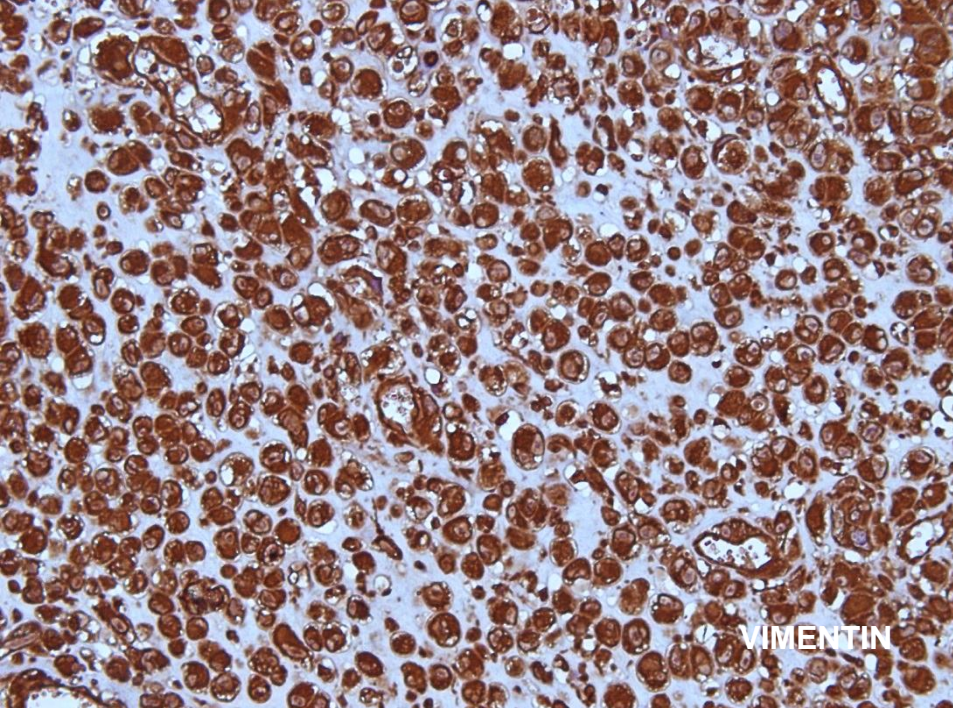






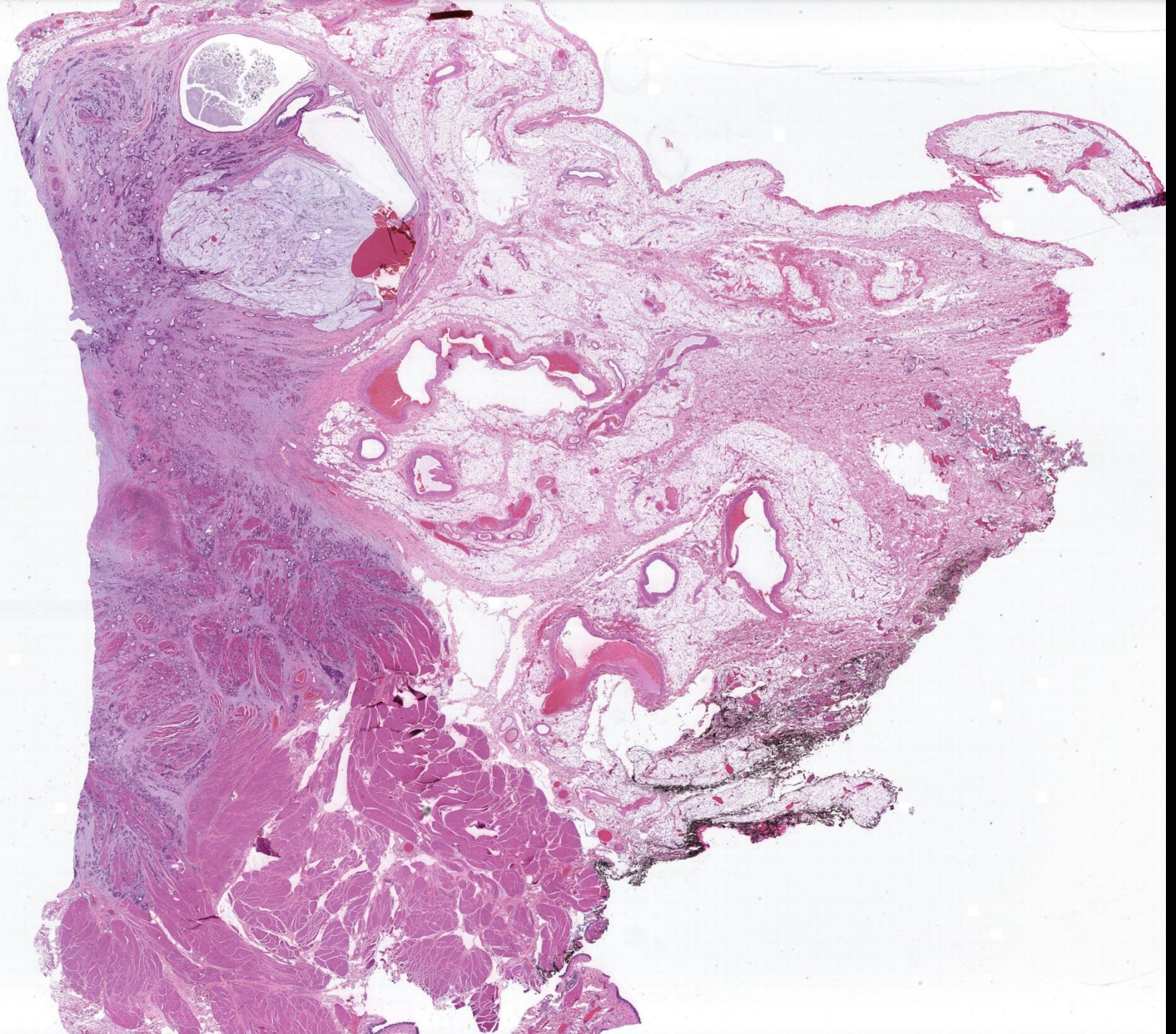


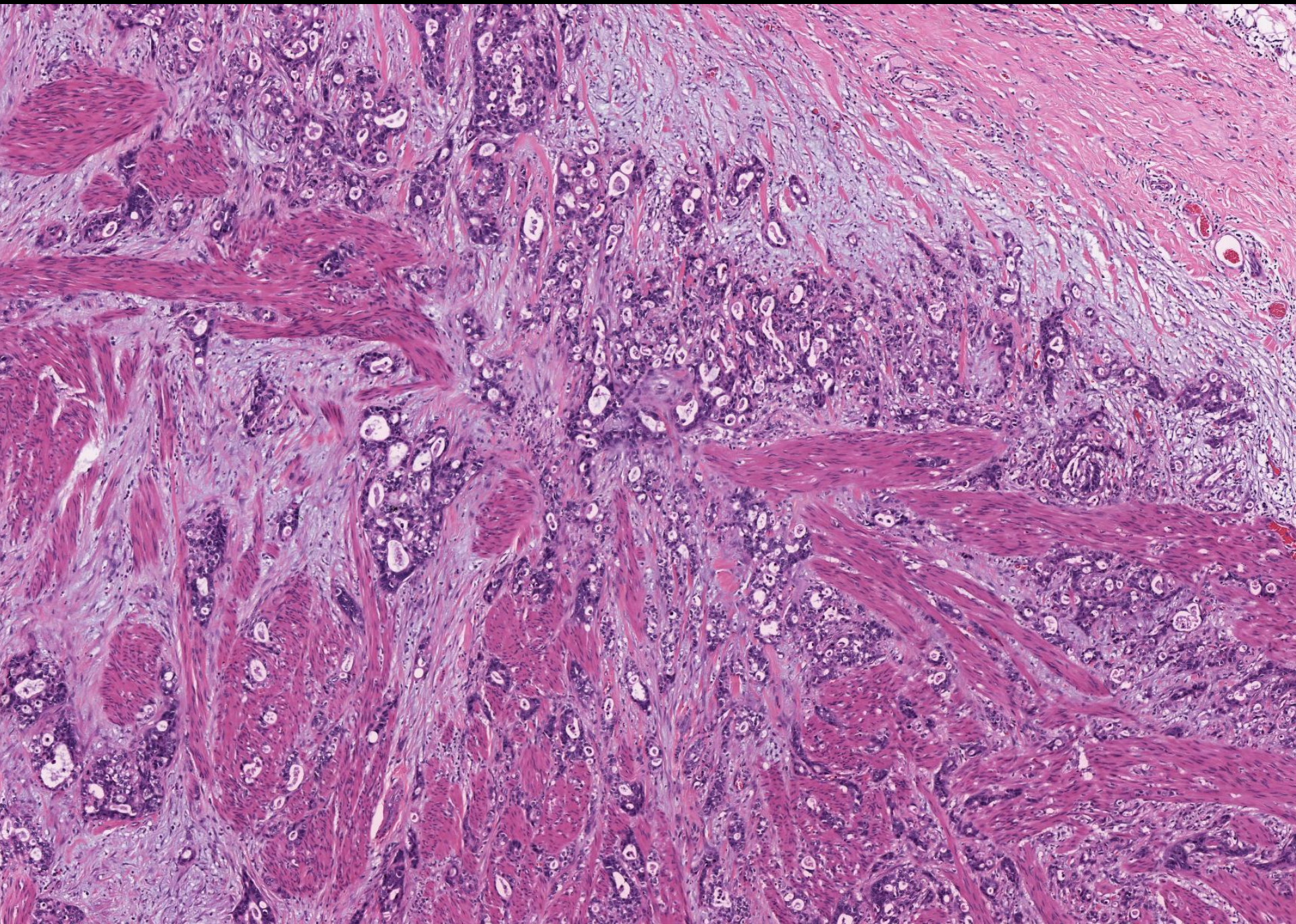


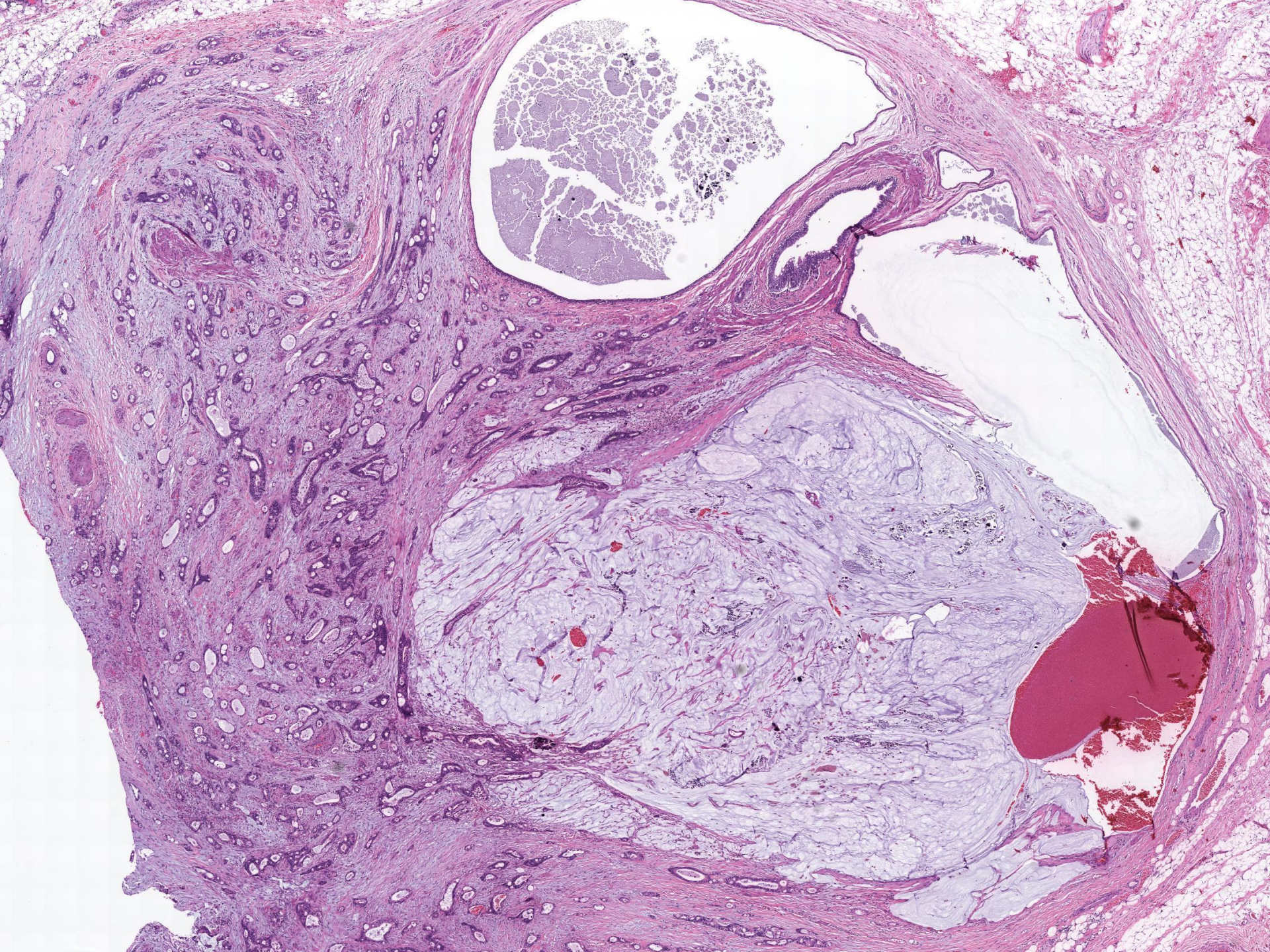


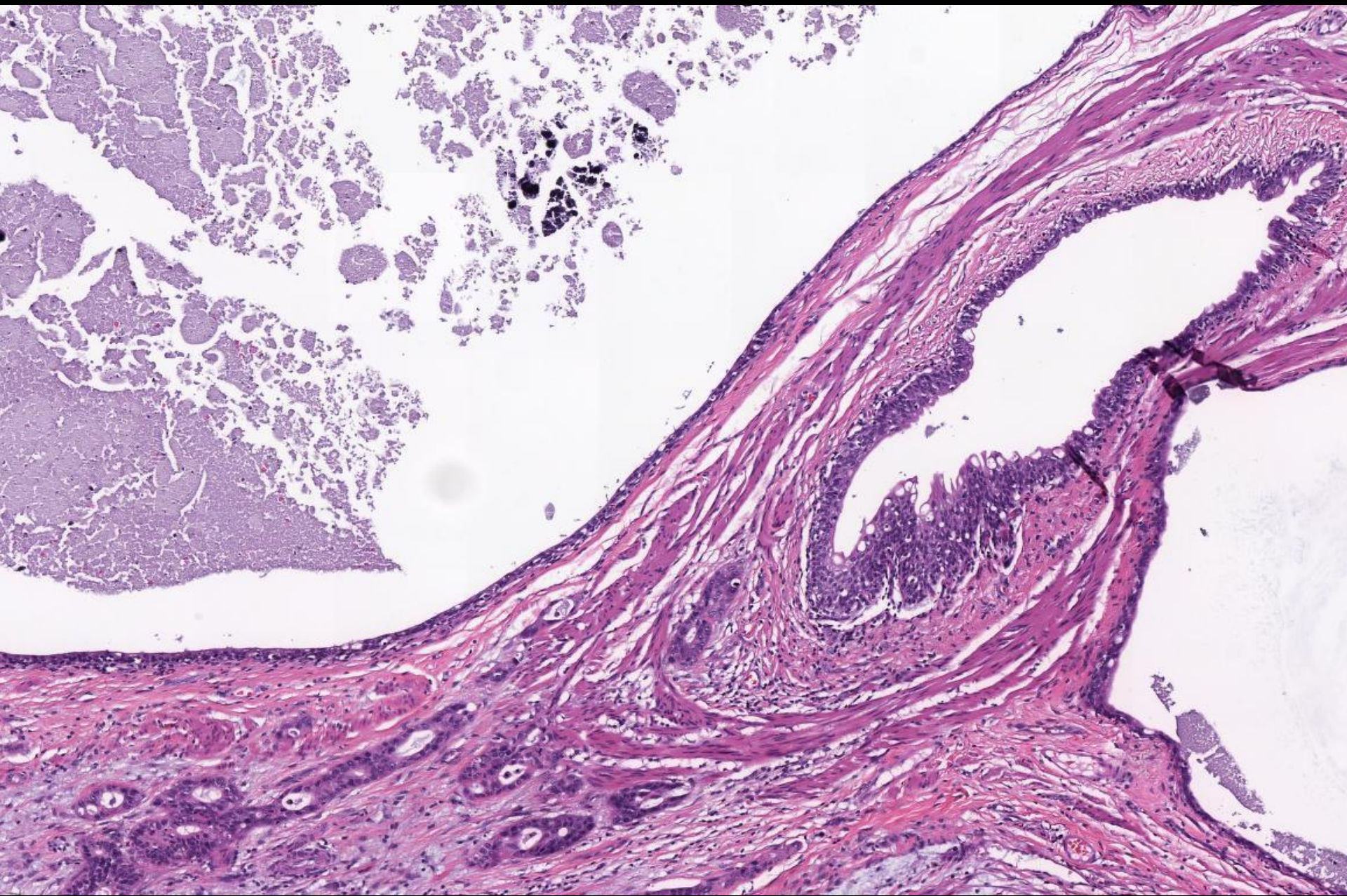
SB 5836

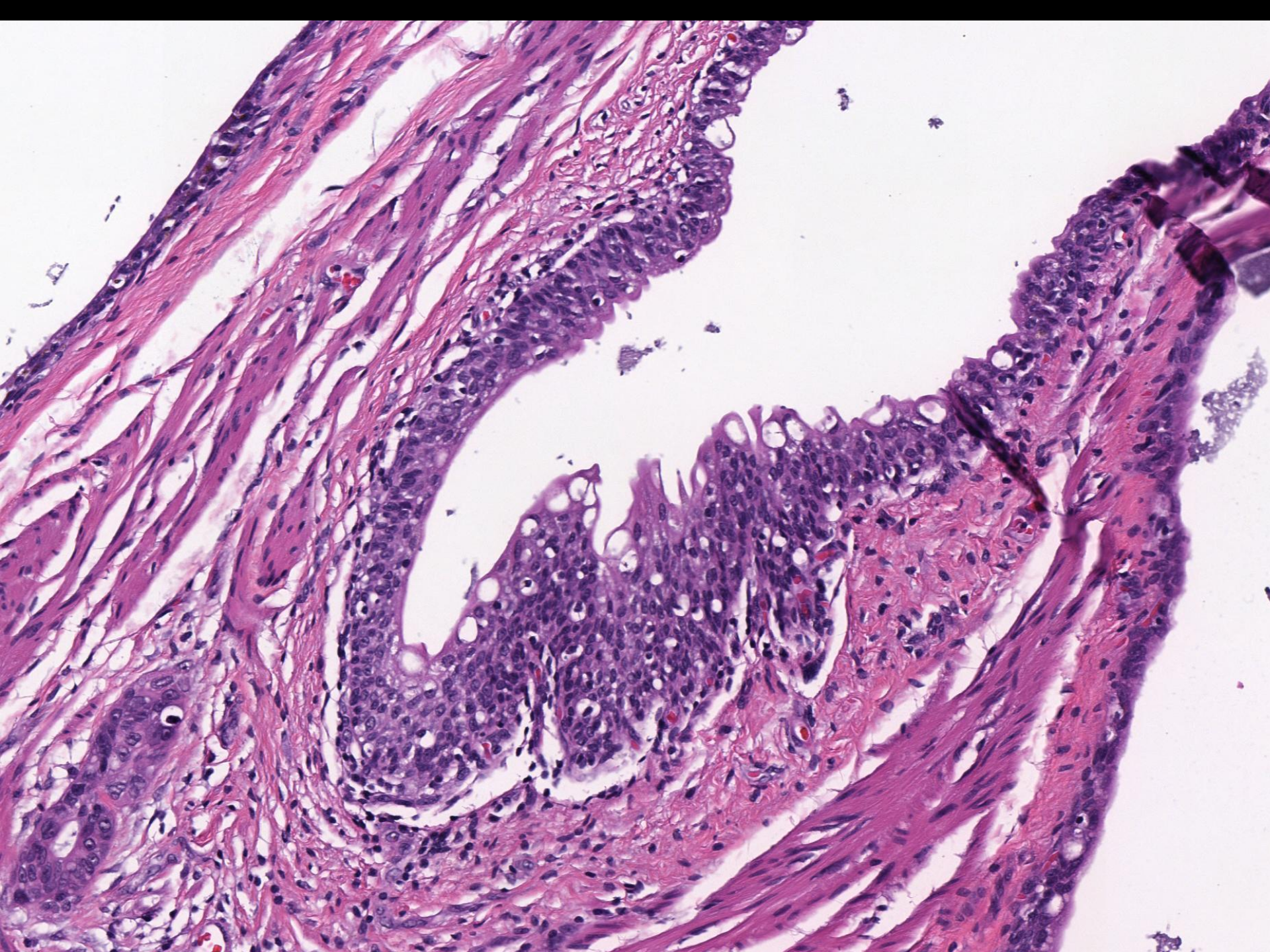
51-year-old male presenting for radical cystectomy for prior outside biopsy diagnosis of “adenocarcinoma consistent with colon primary.”





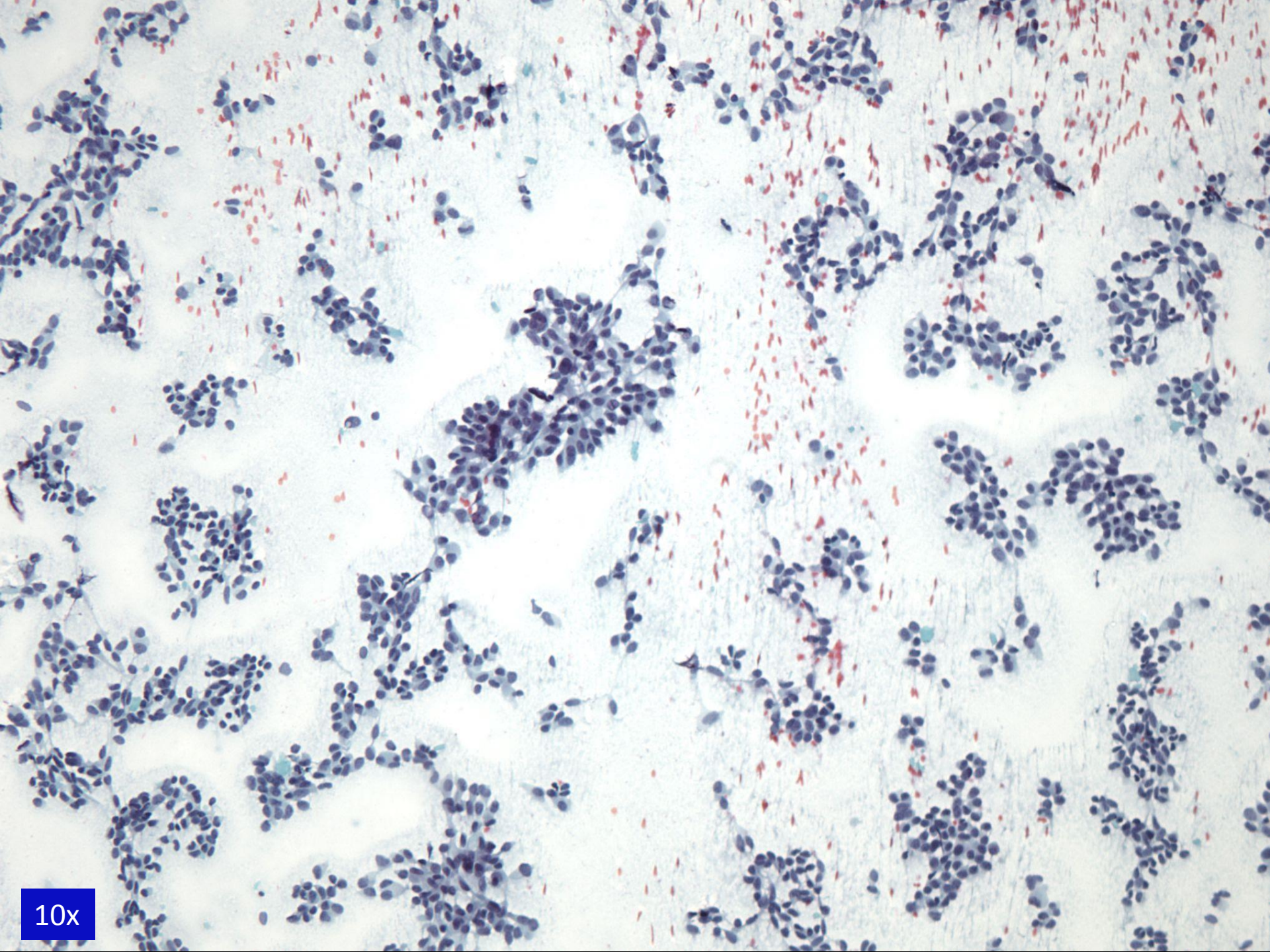




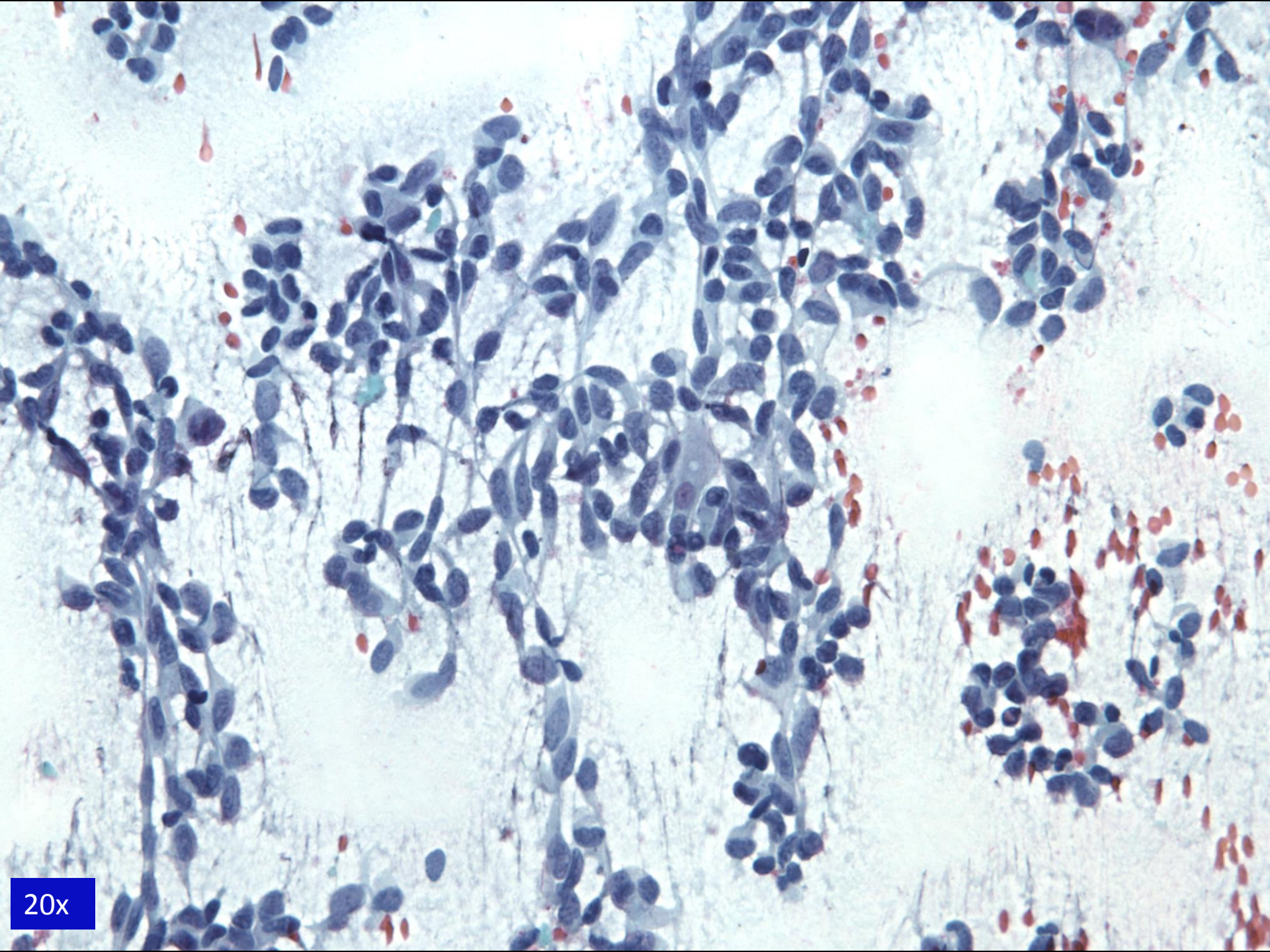


SB 5837

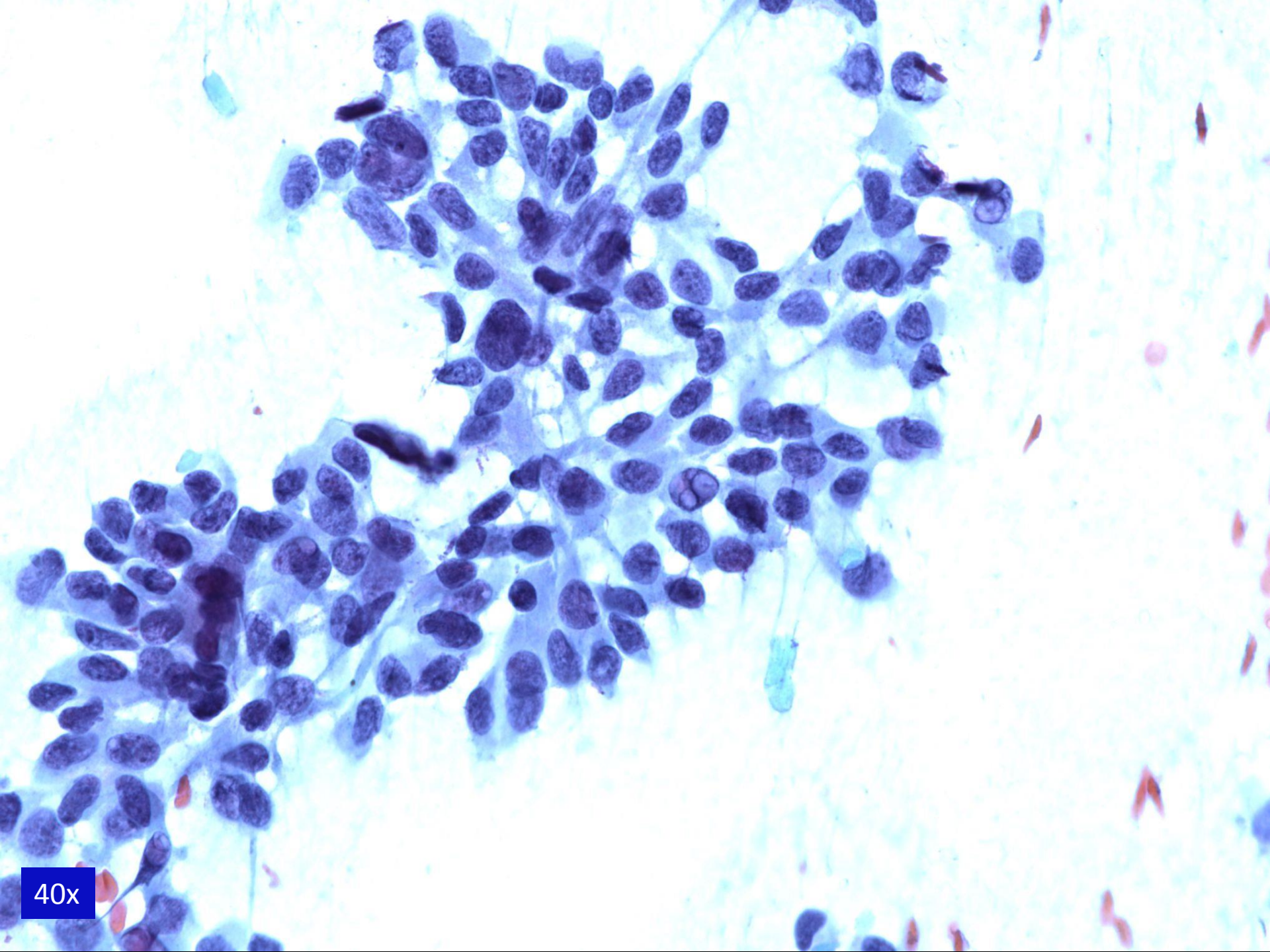
73-year-old female with a history of invasive ductal carcinoma (diagnosed April 2013) presents with fullness of the neck and found to have a retrotracheal mass on CT.



10x



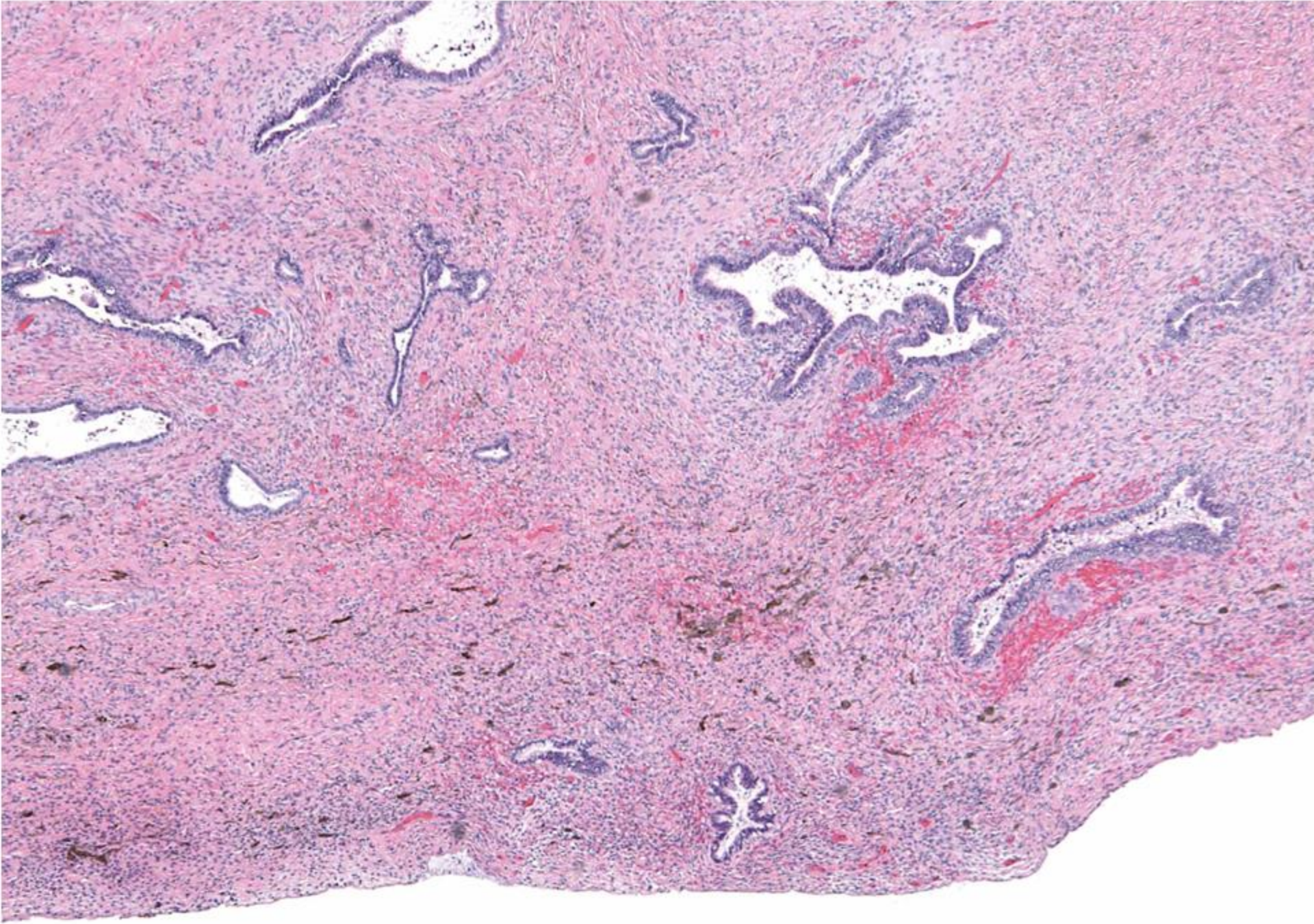
20x

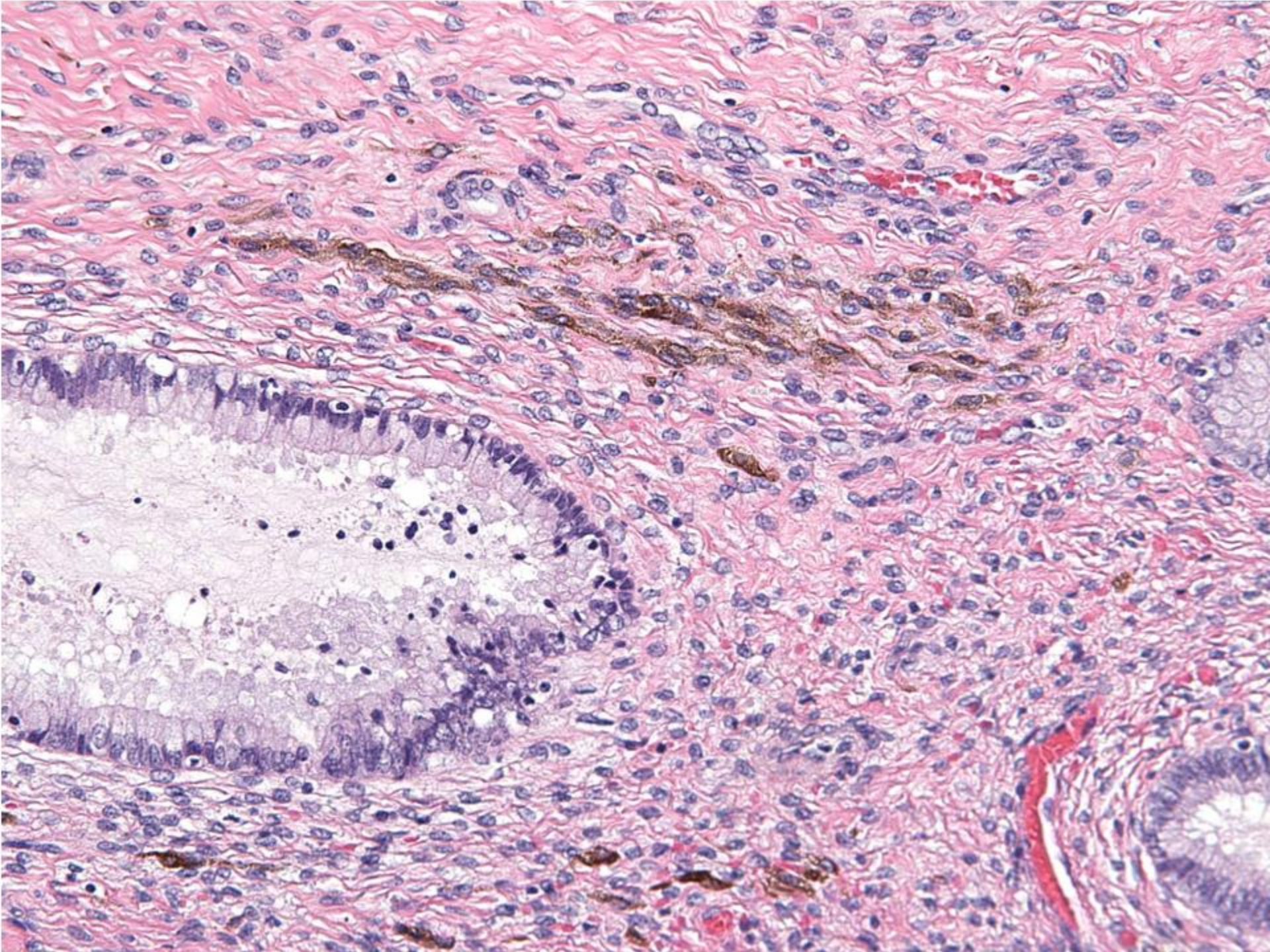


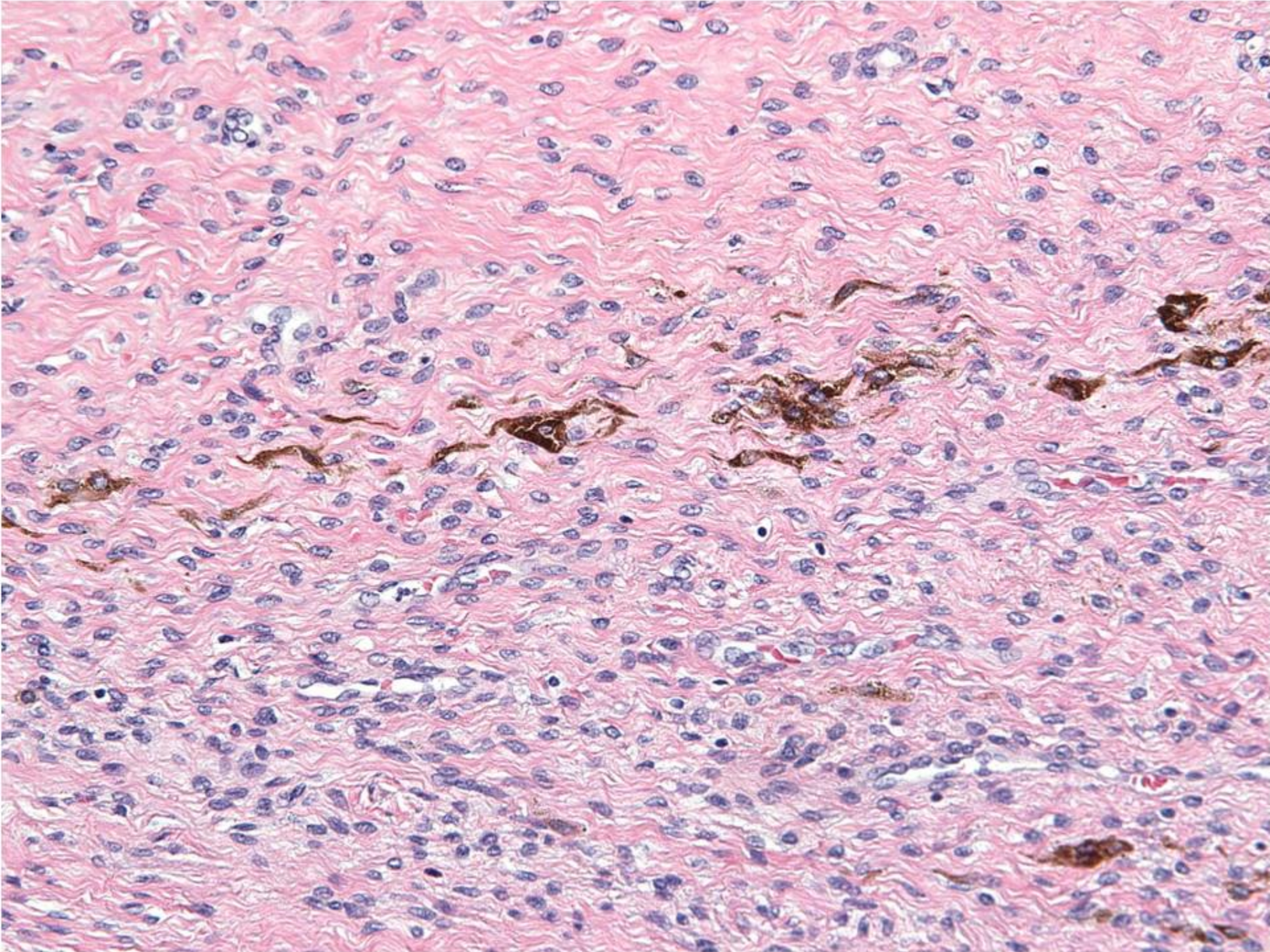
40x

SB 5838

**39-year-old female status post
hysterectomy for leiomyomata.
Section of cervix submitted.**

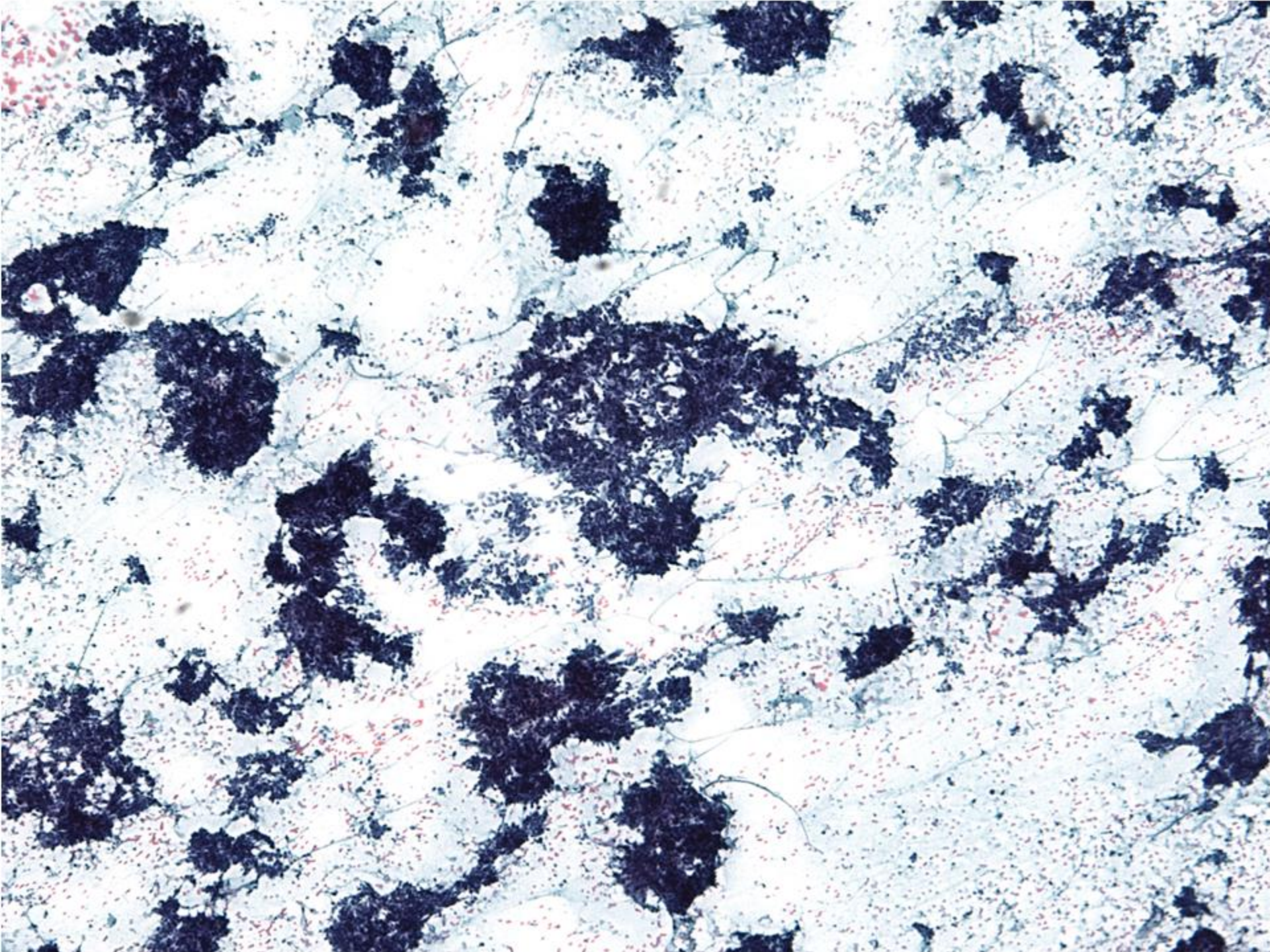


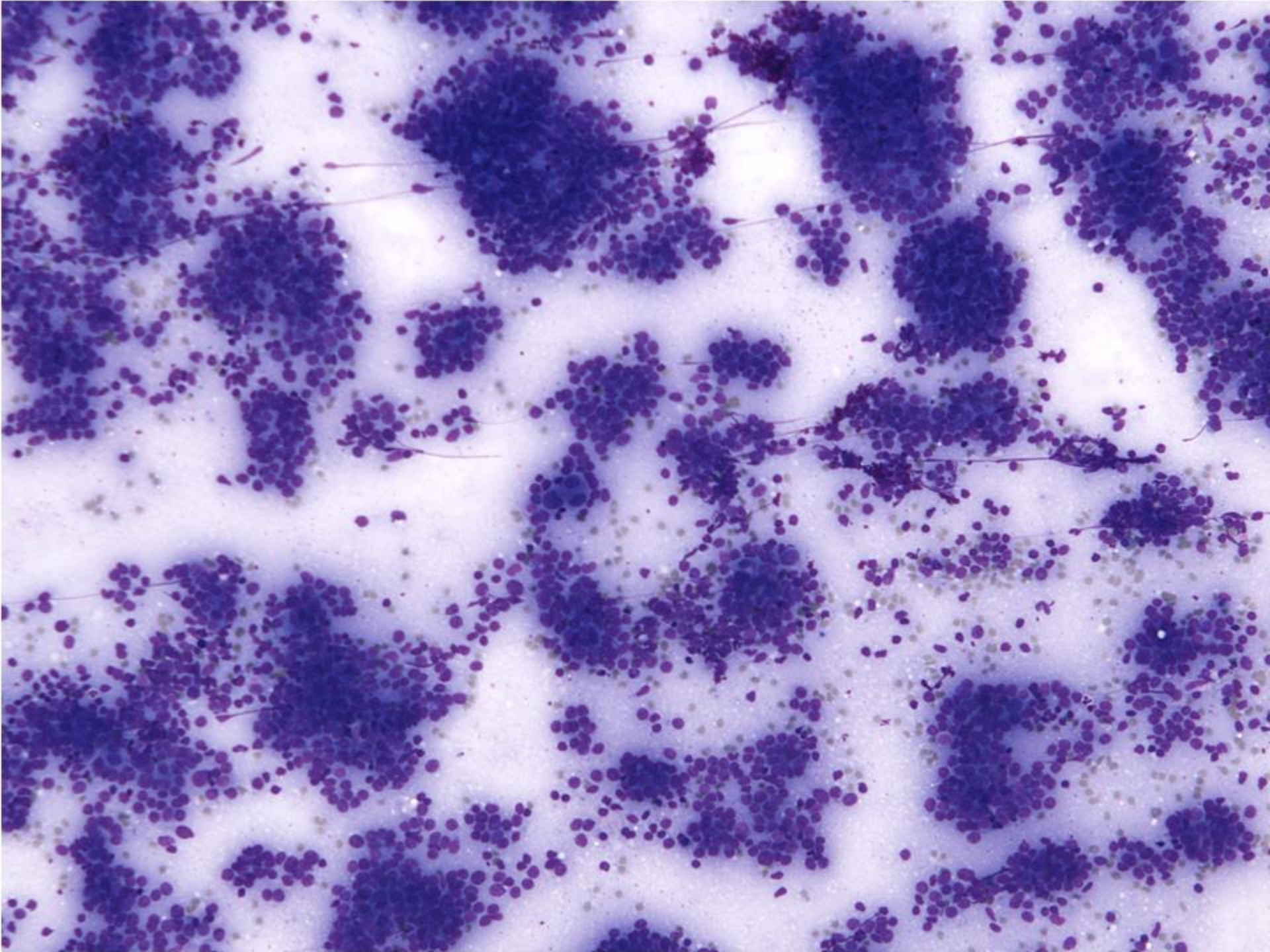


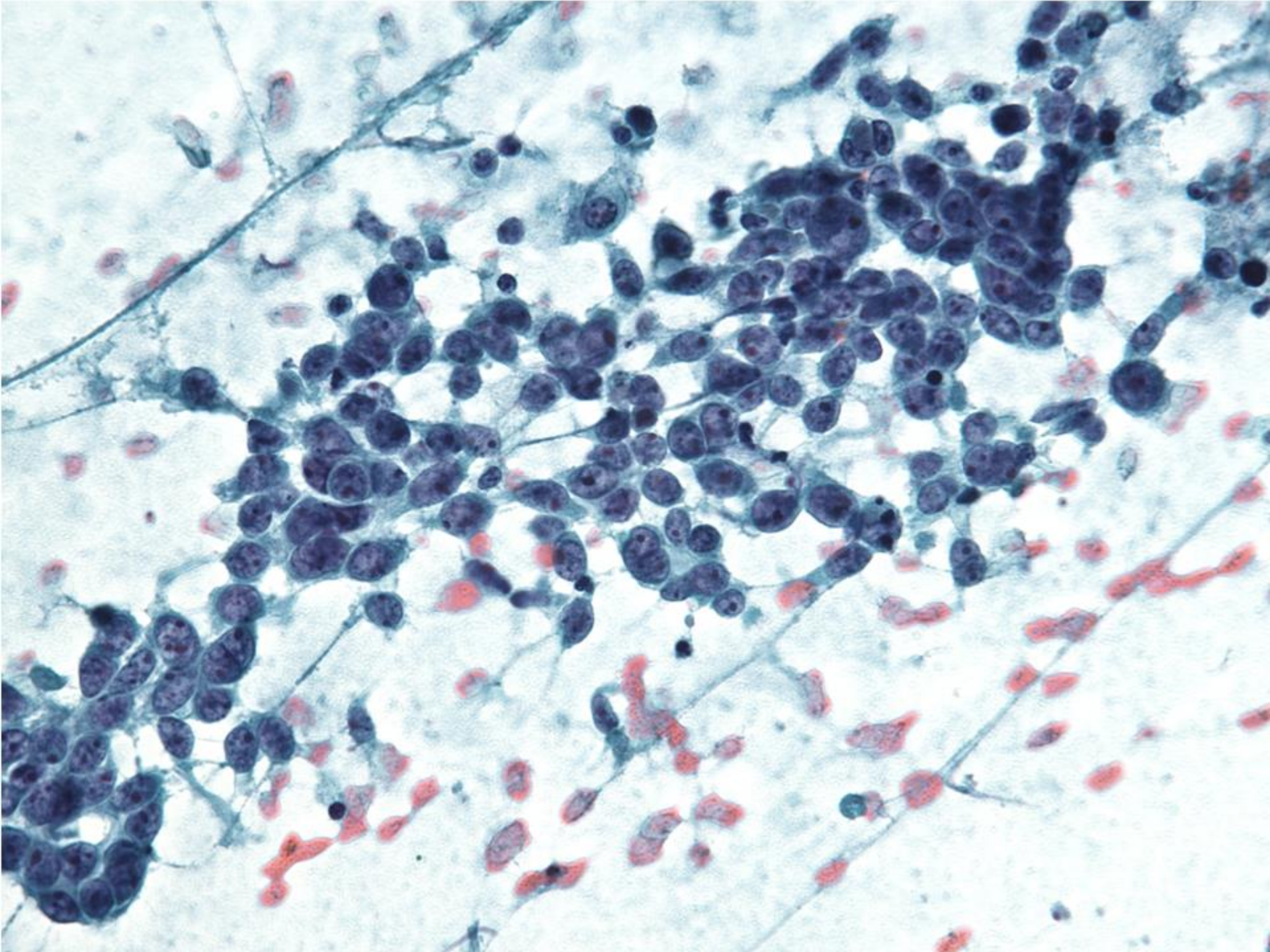


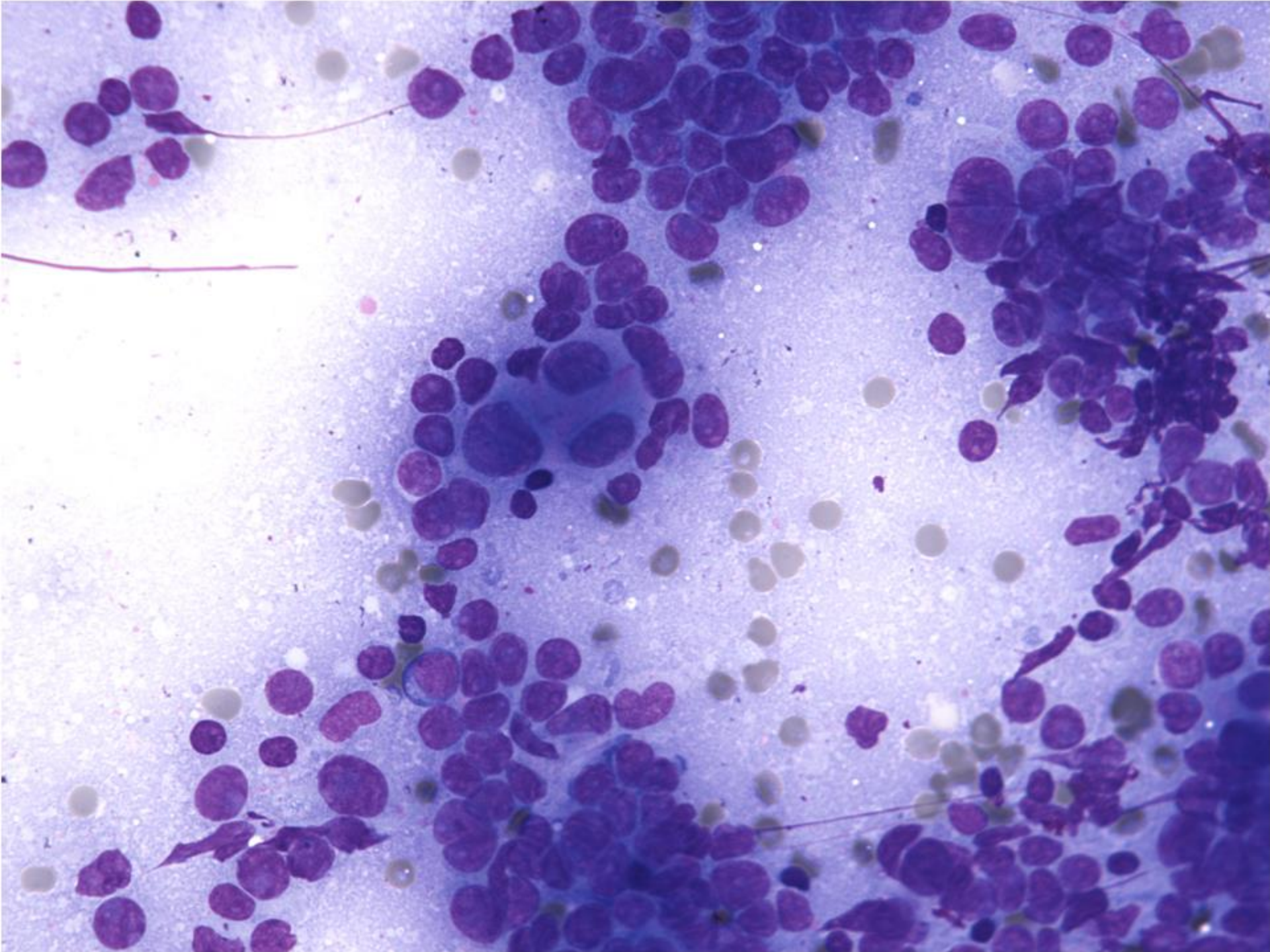
SB 5839

60-year-old female with a 4.5cm right thyroid nodule and a 3cm right level IV cervical lymph node. FNA of both sites showed similar features.









SB 5840

32-year-old female with a palpable left supraclavicular lymph node and a history of a left ovarian mass status post oophorectomy 4 years ago.

