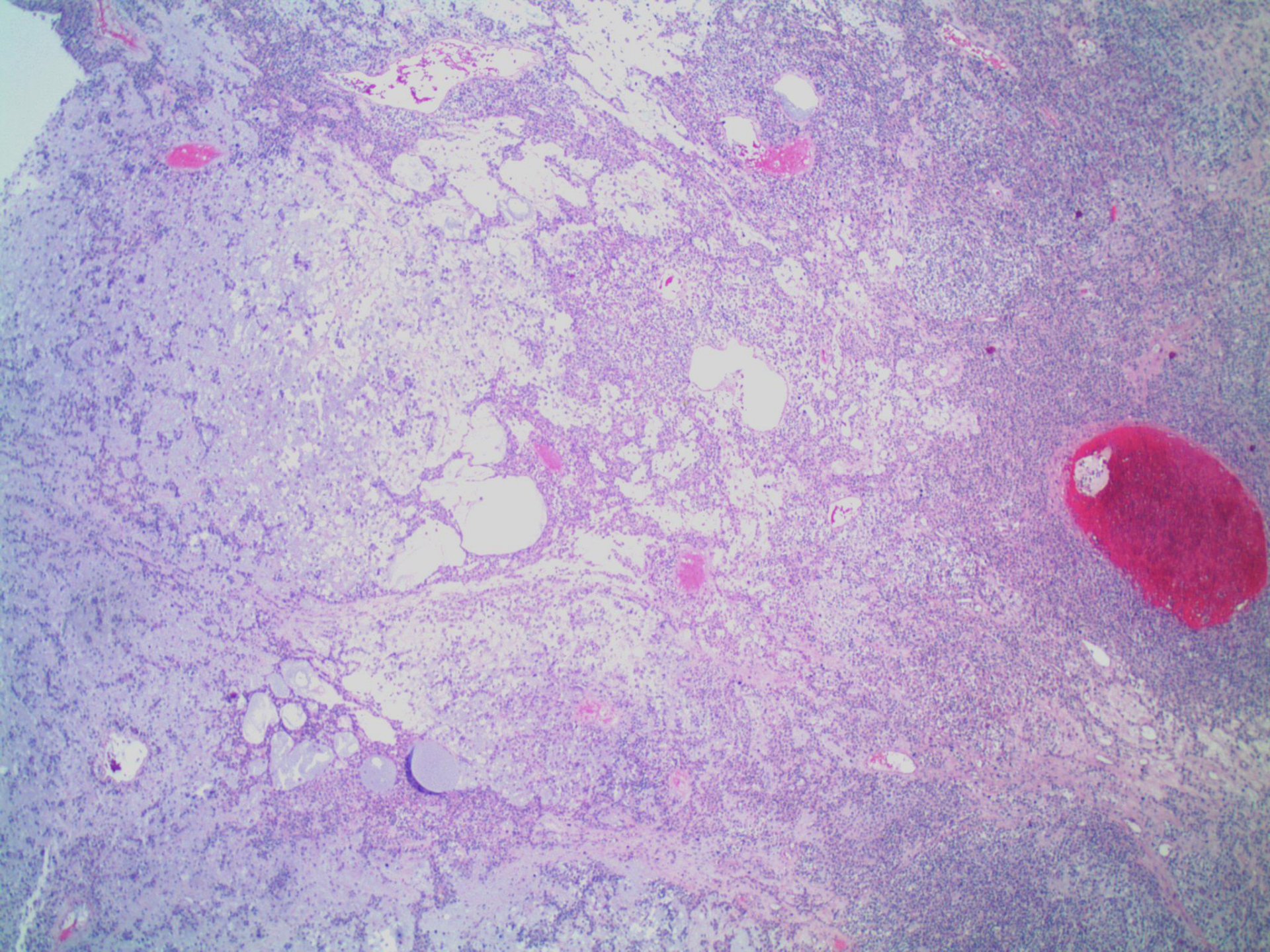
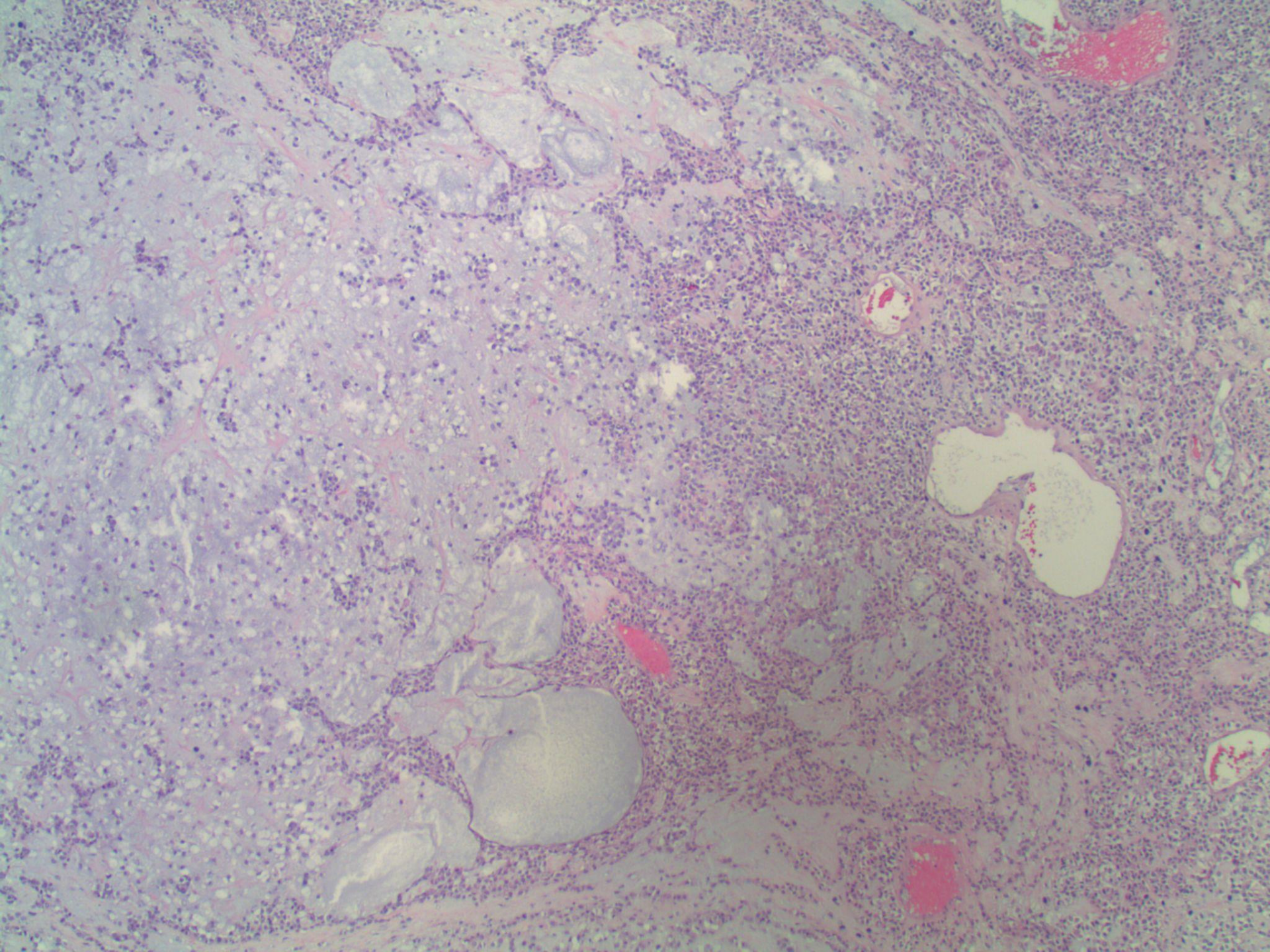
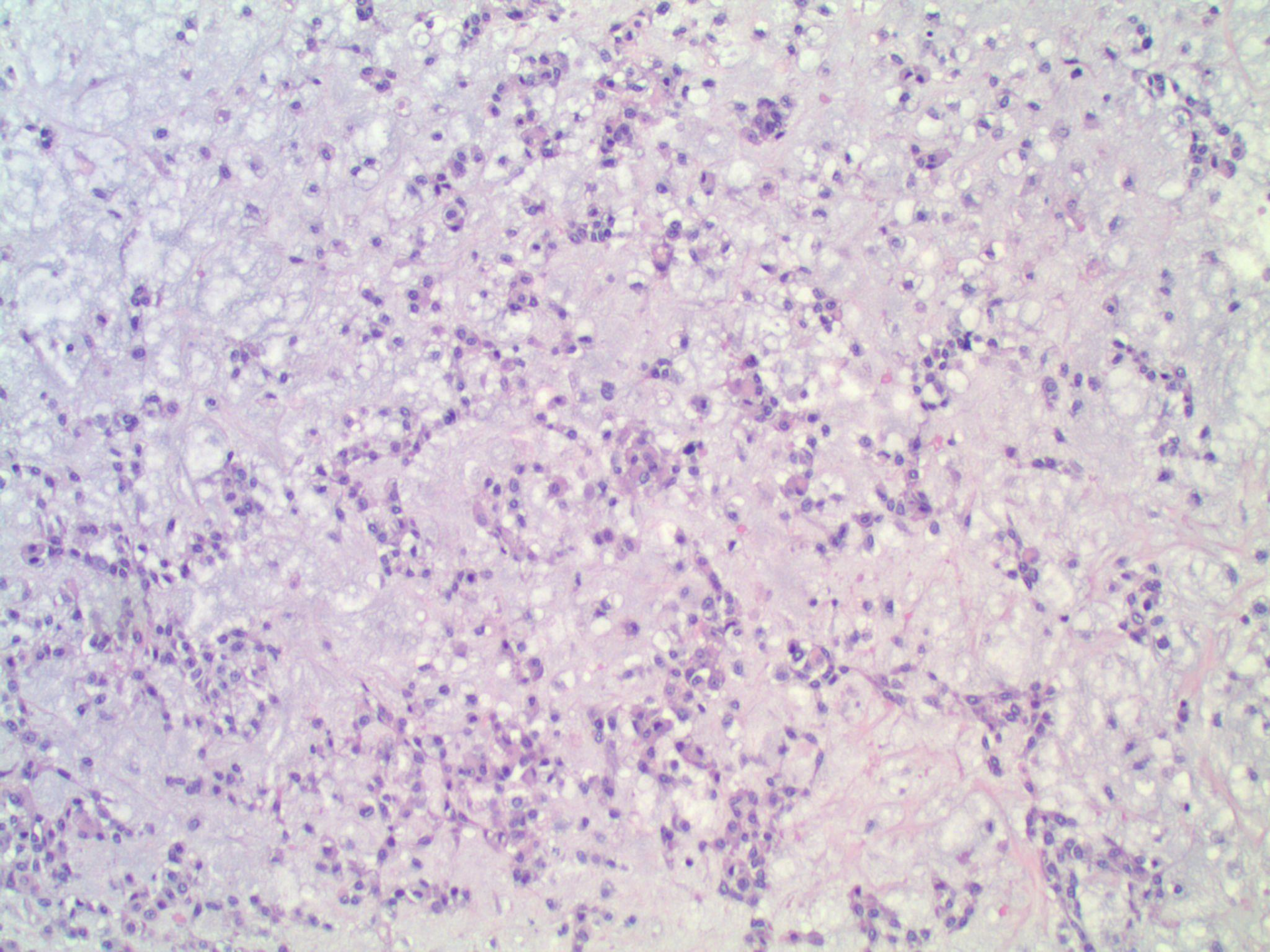


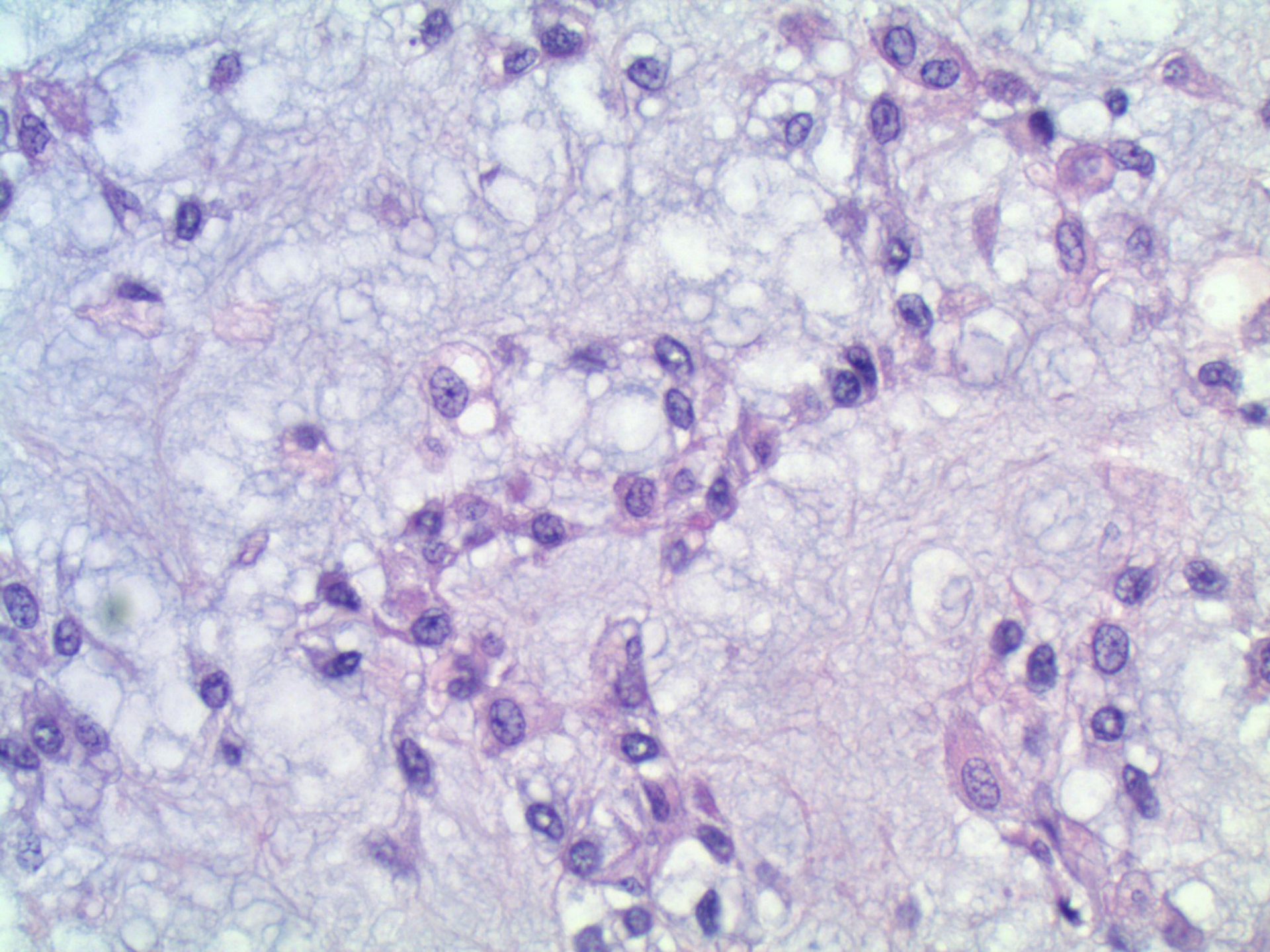
SB 5801

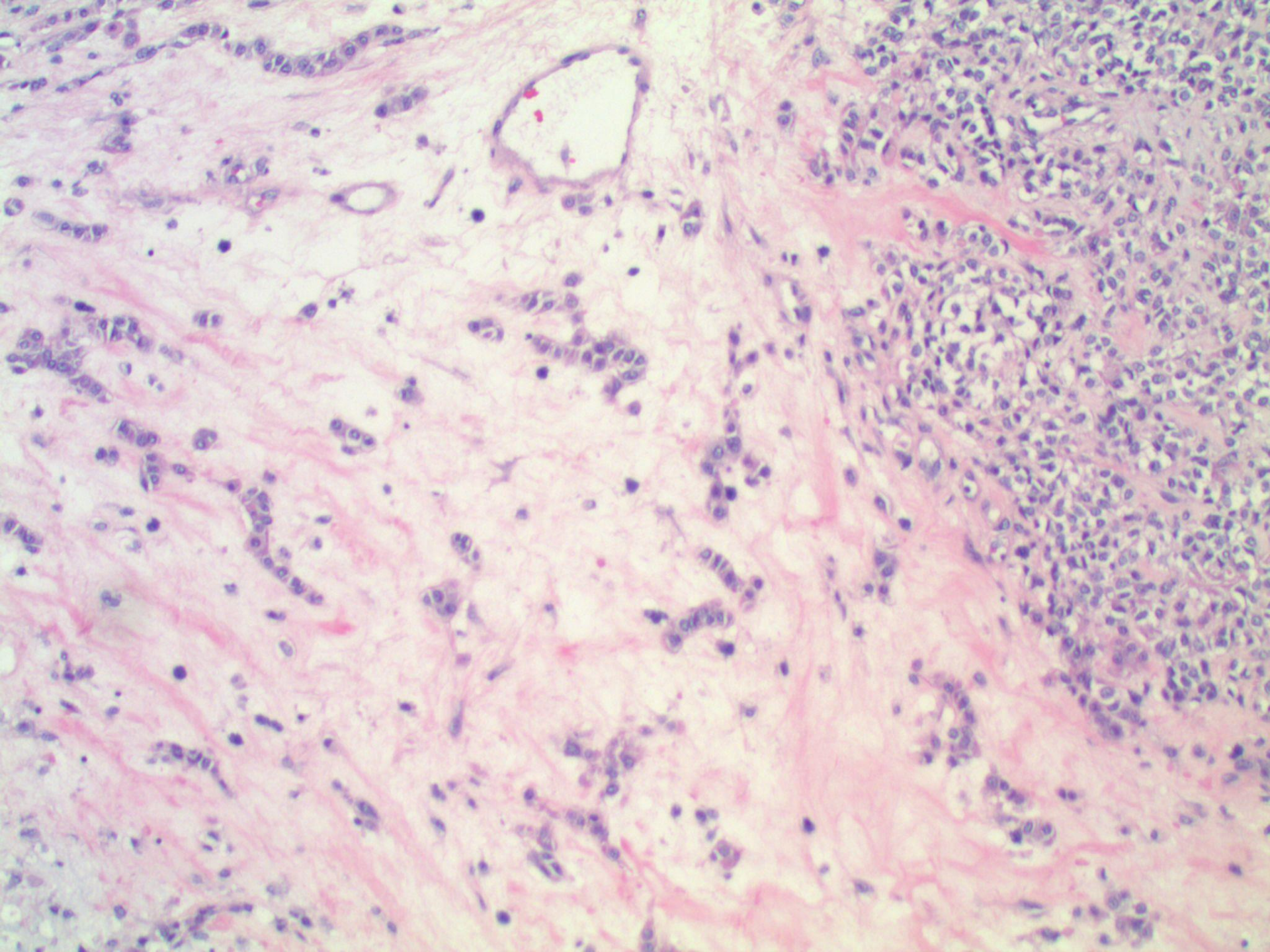
88-year-old male with right
thigh mass.

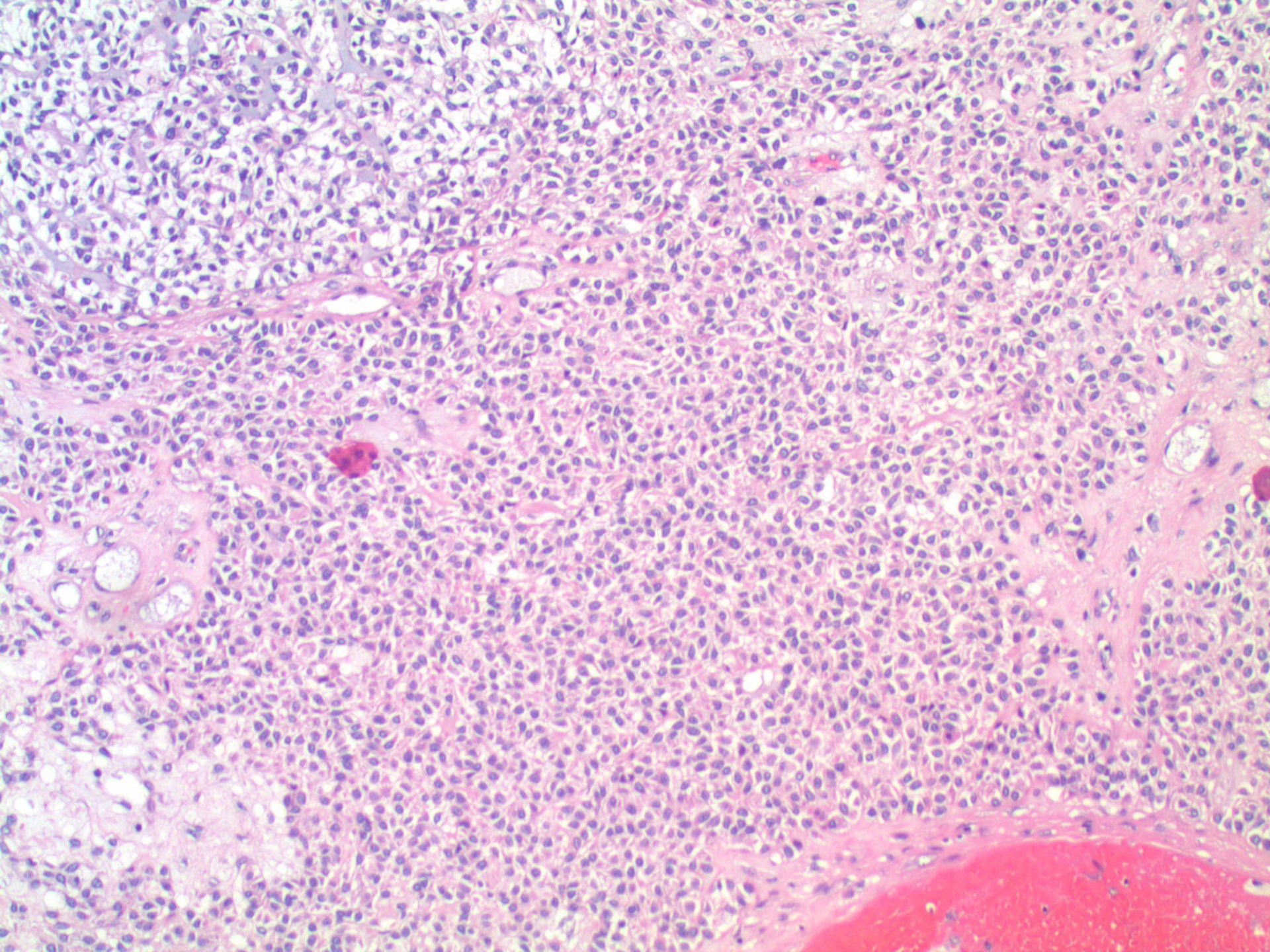


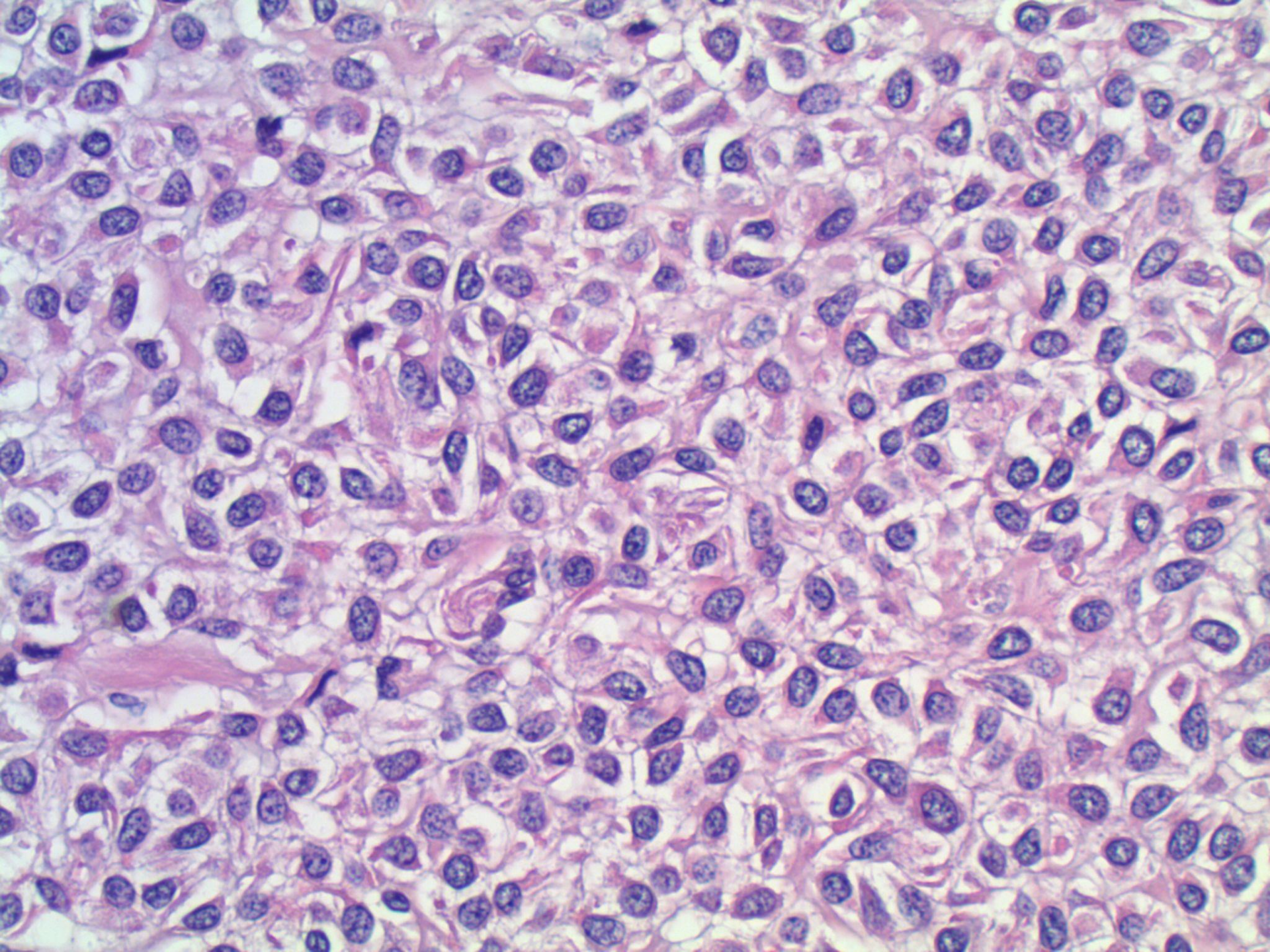






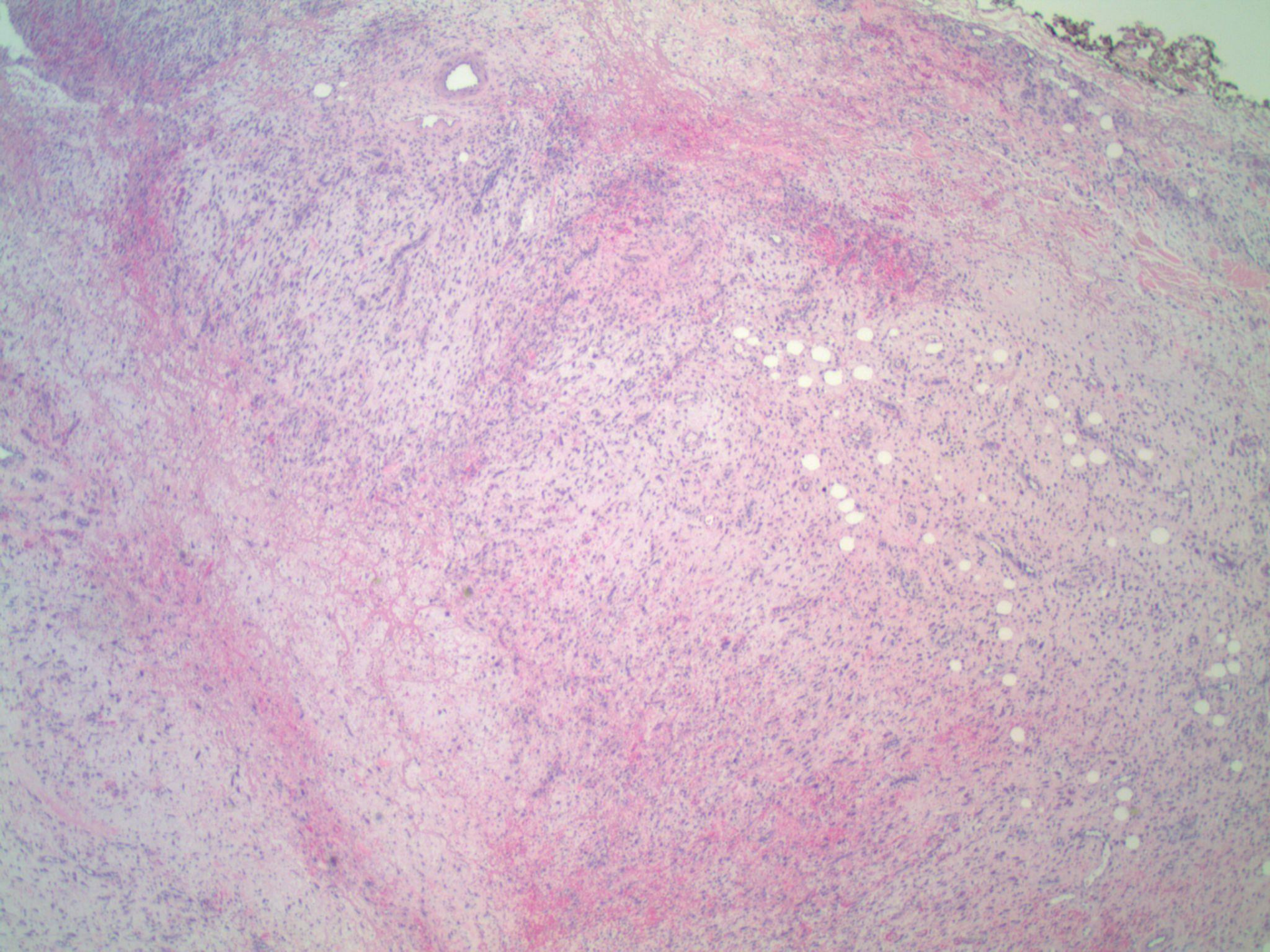


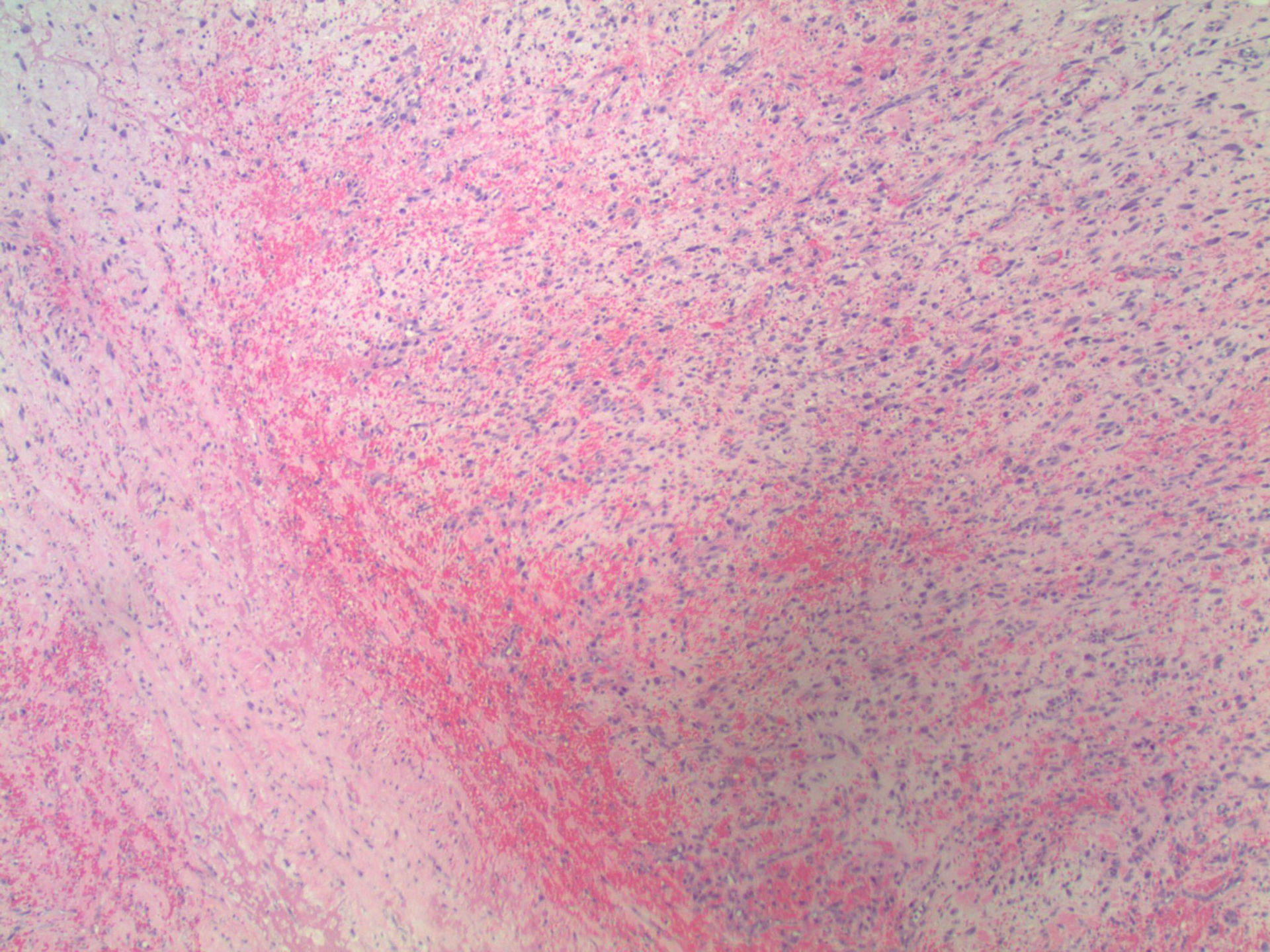


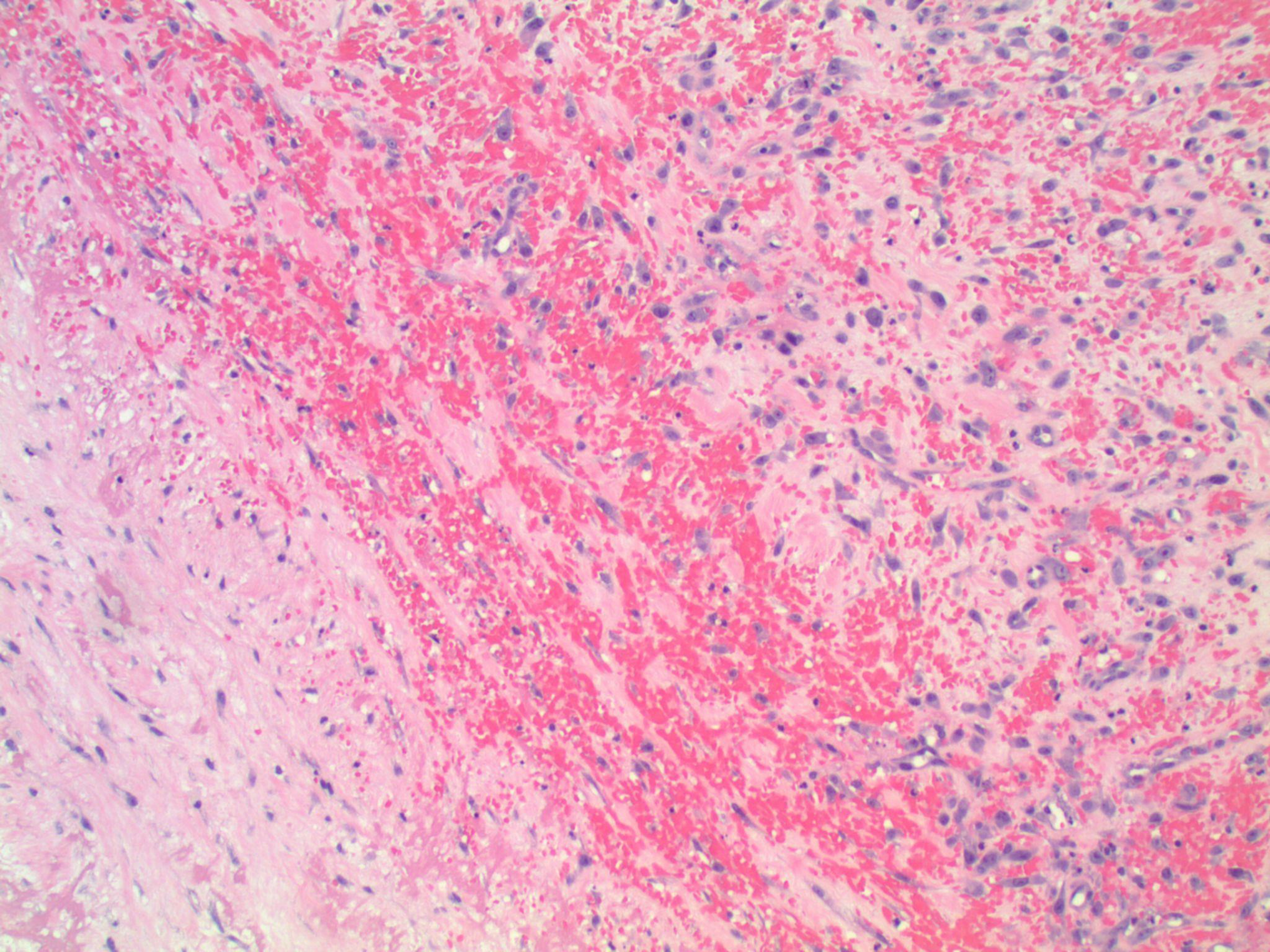


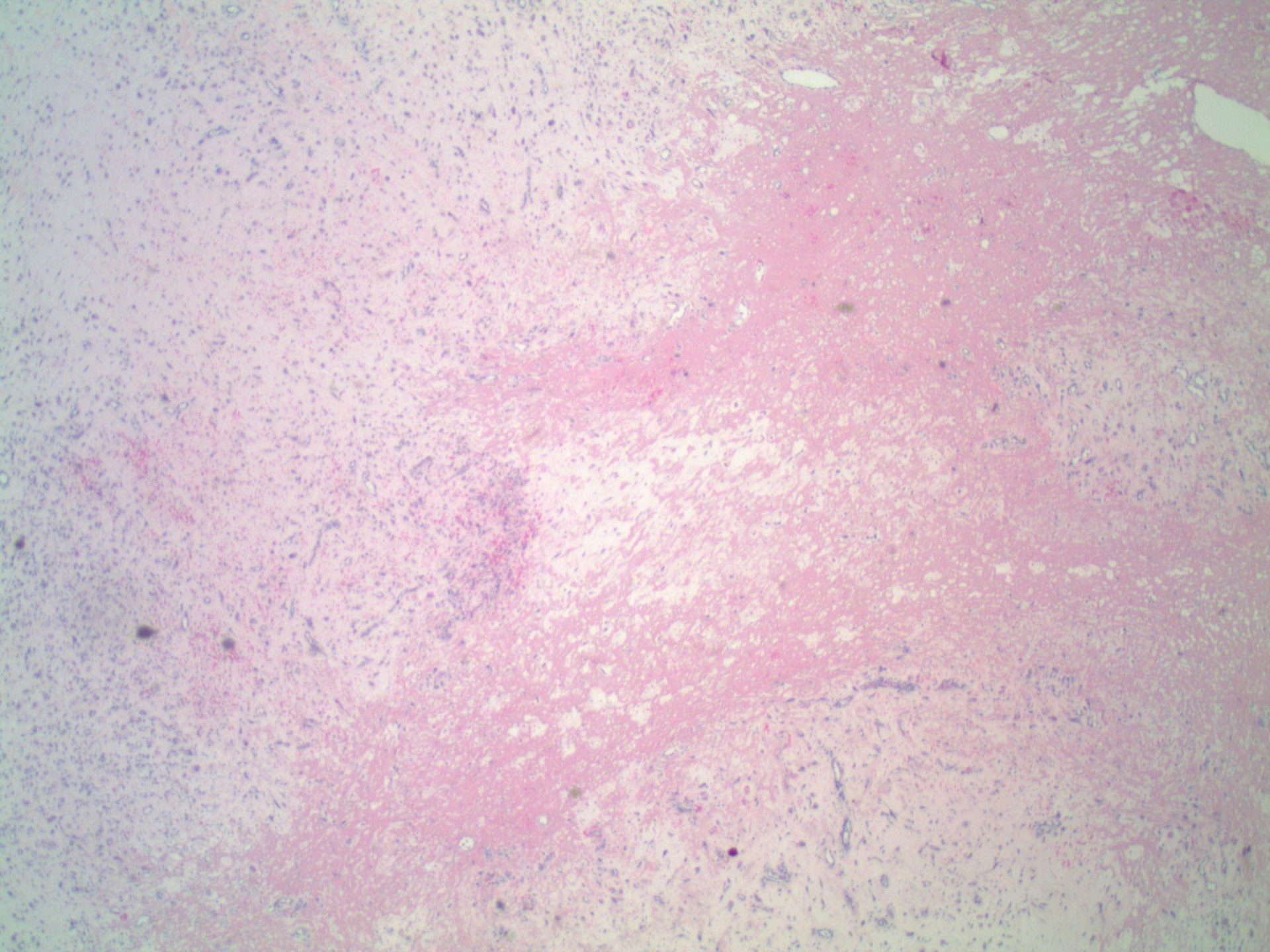
SB 5802

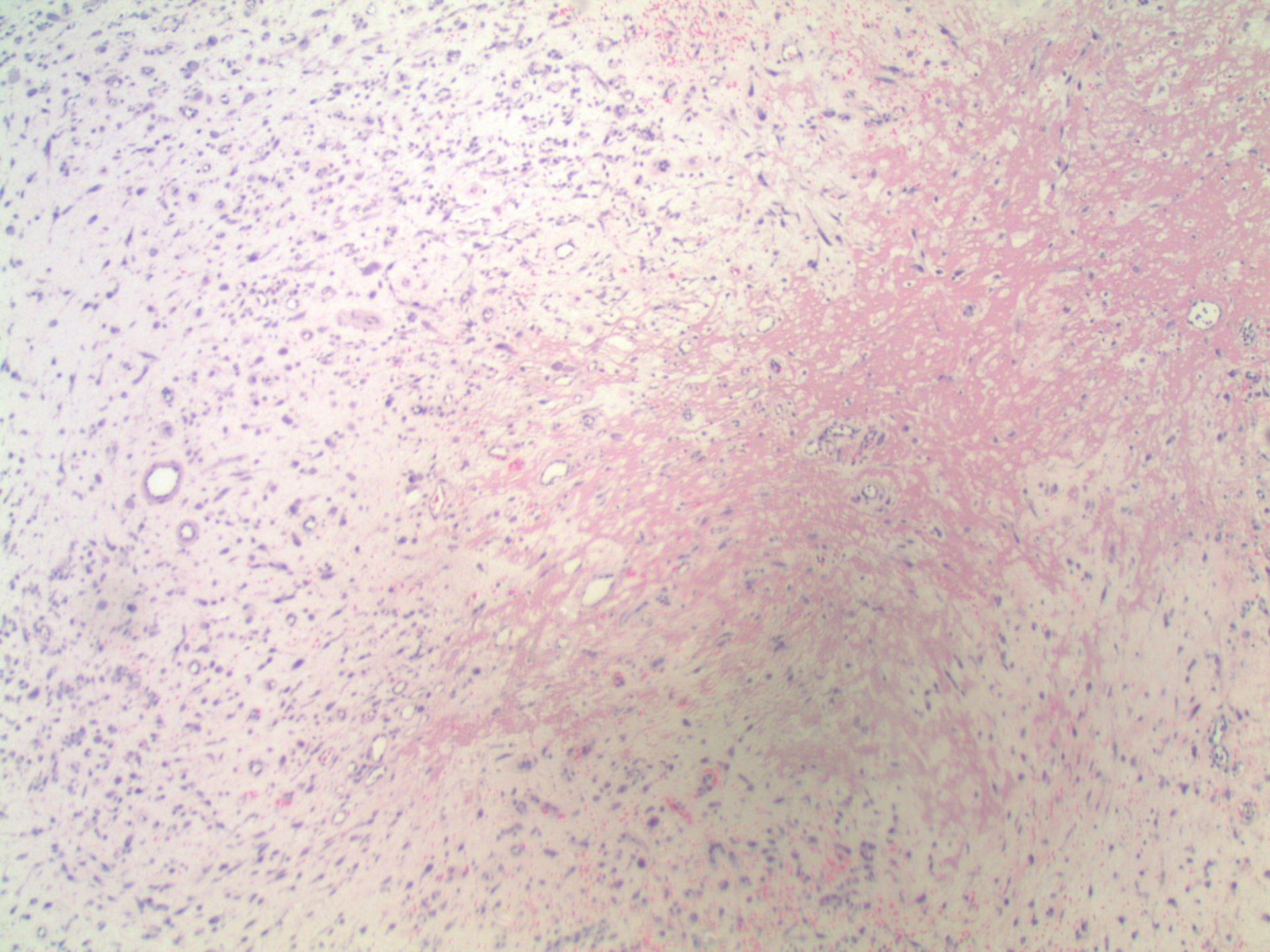
85-year-old male with right
shoulder mass.

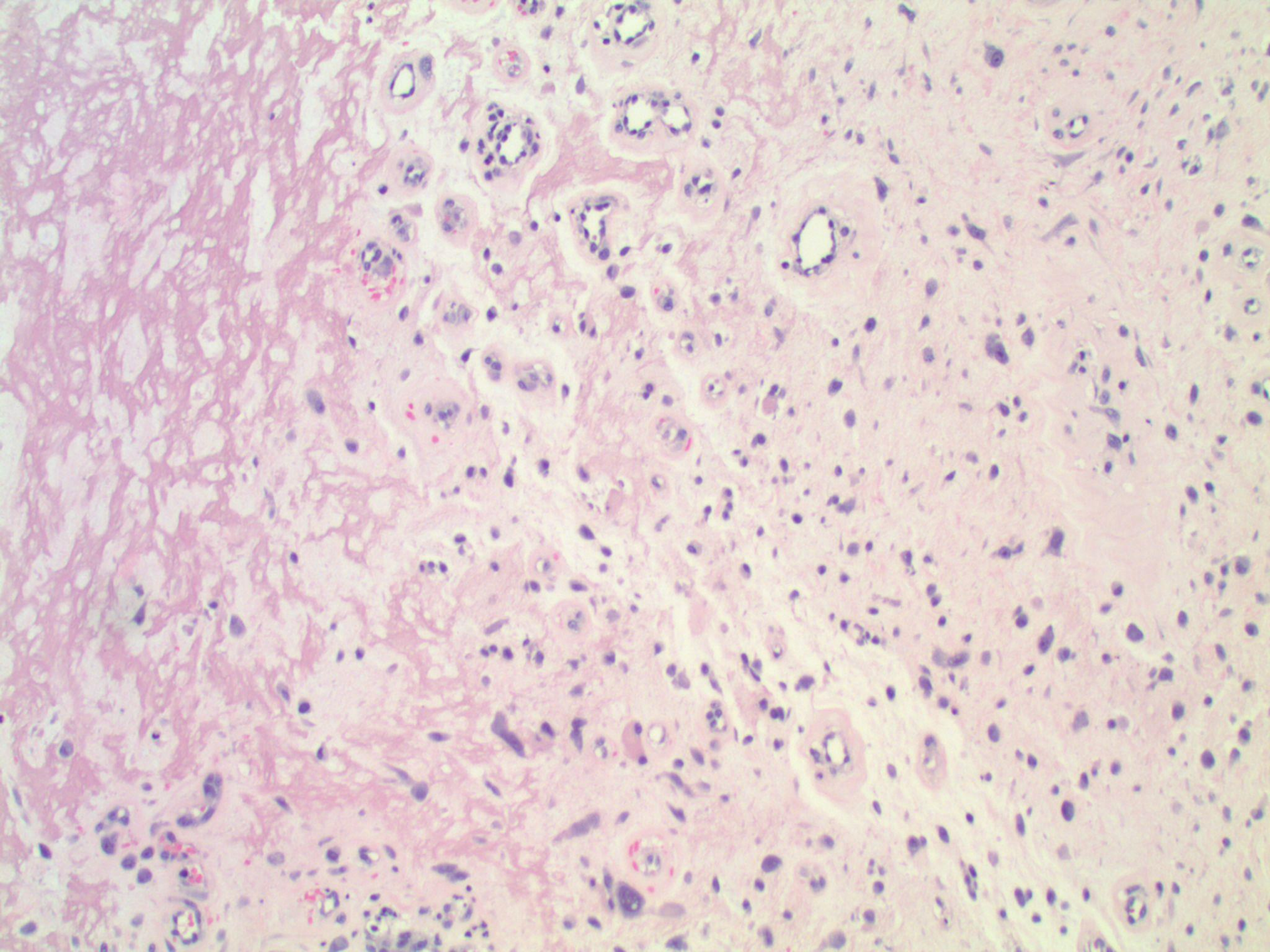


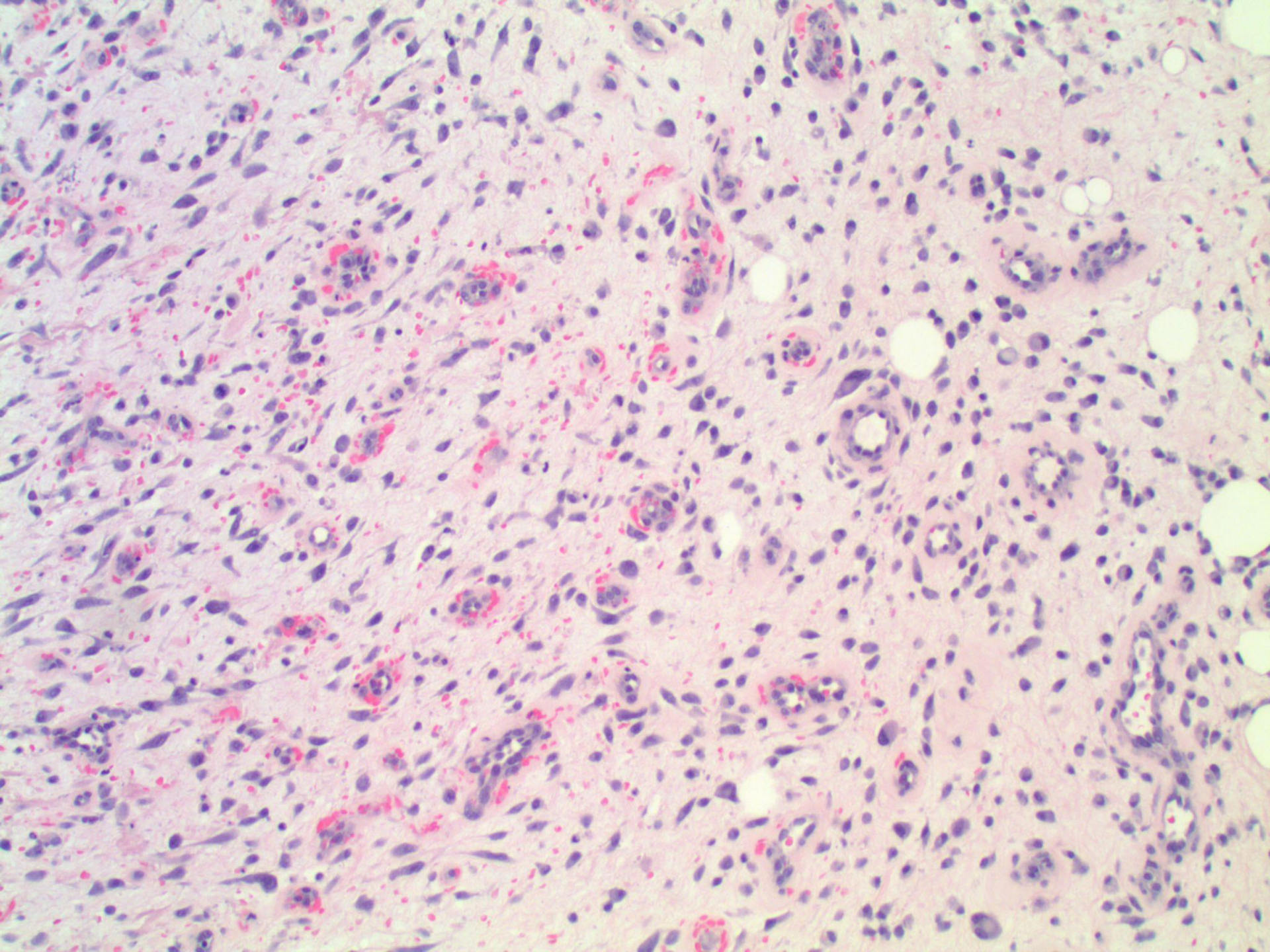


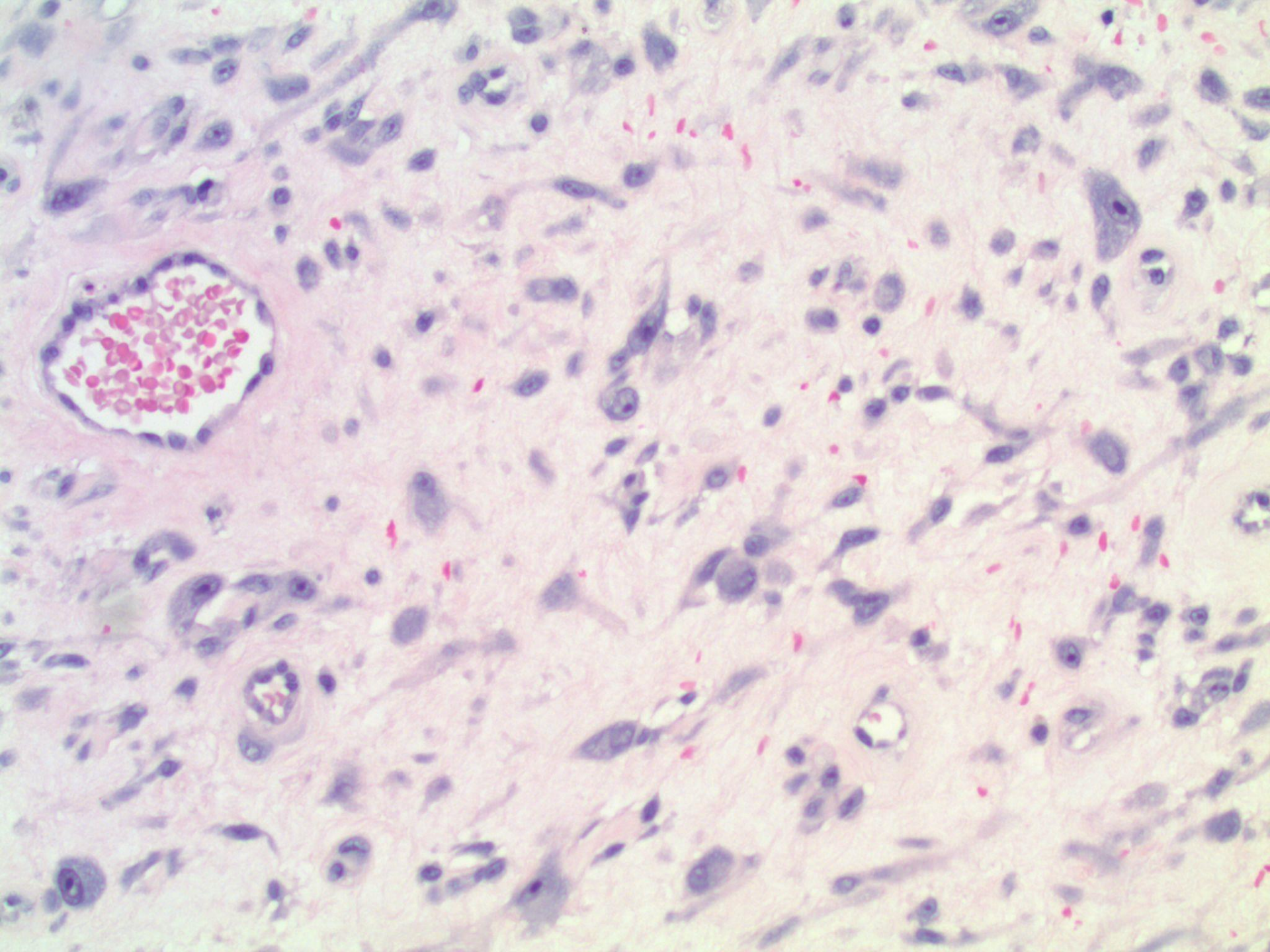


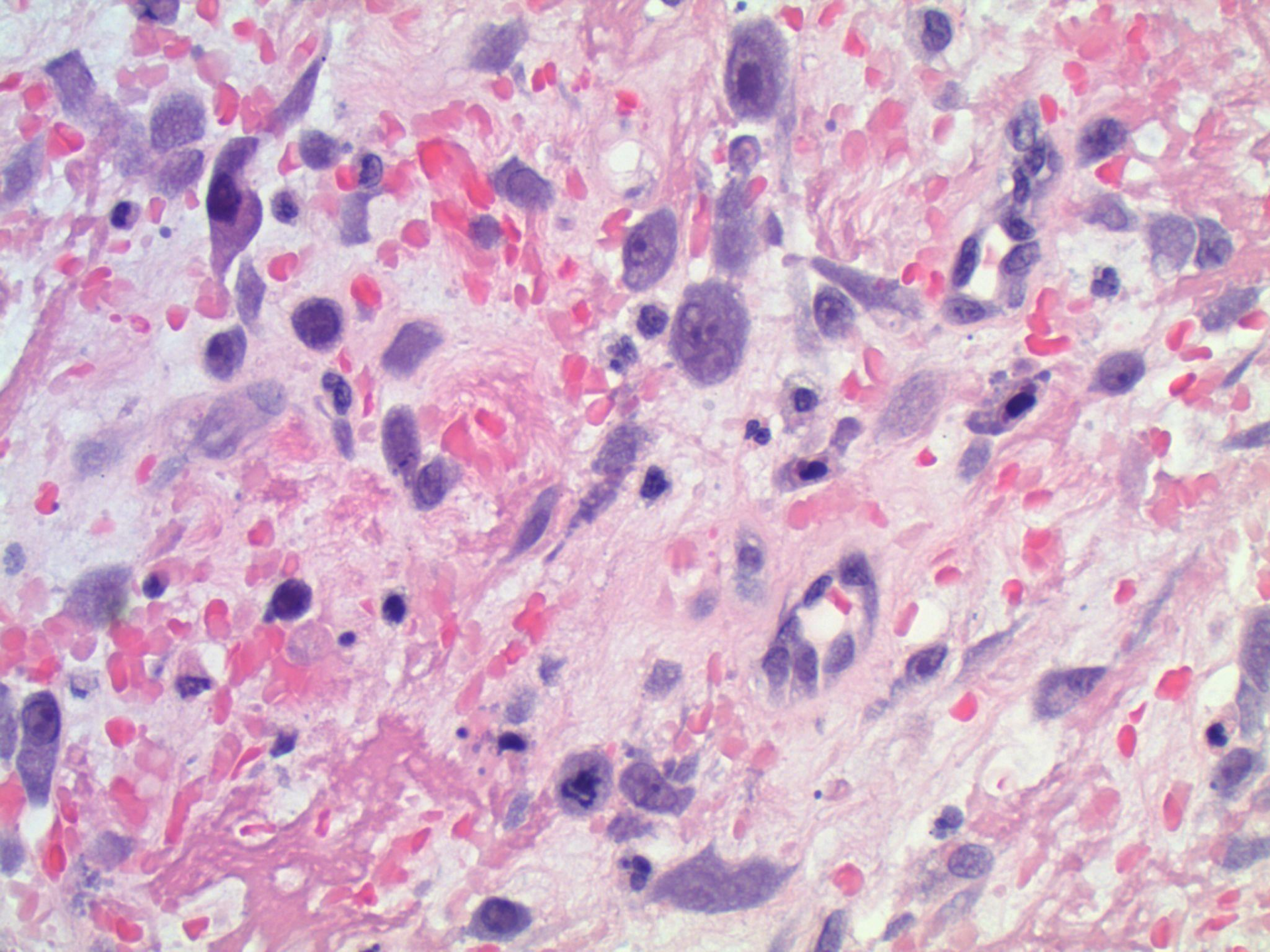






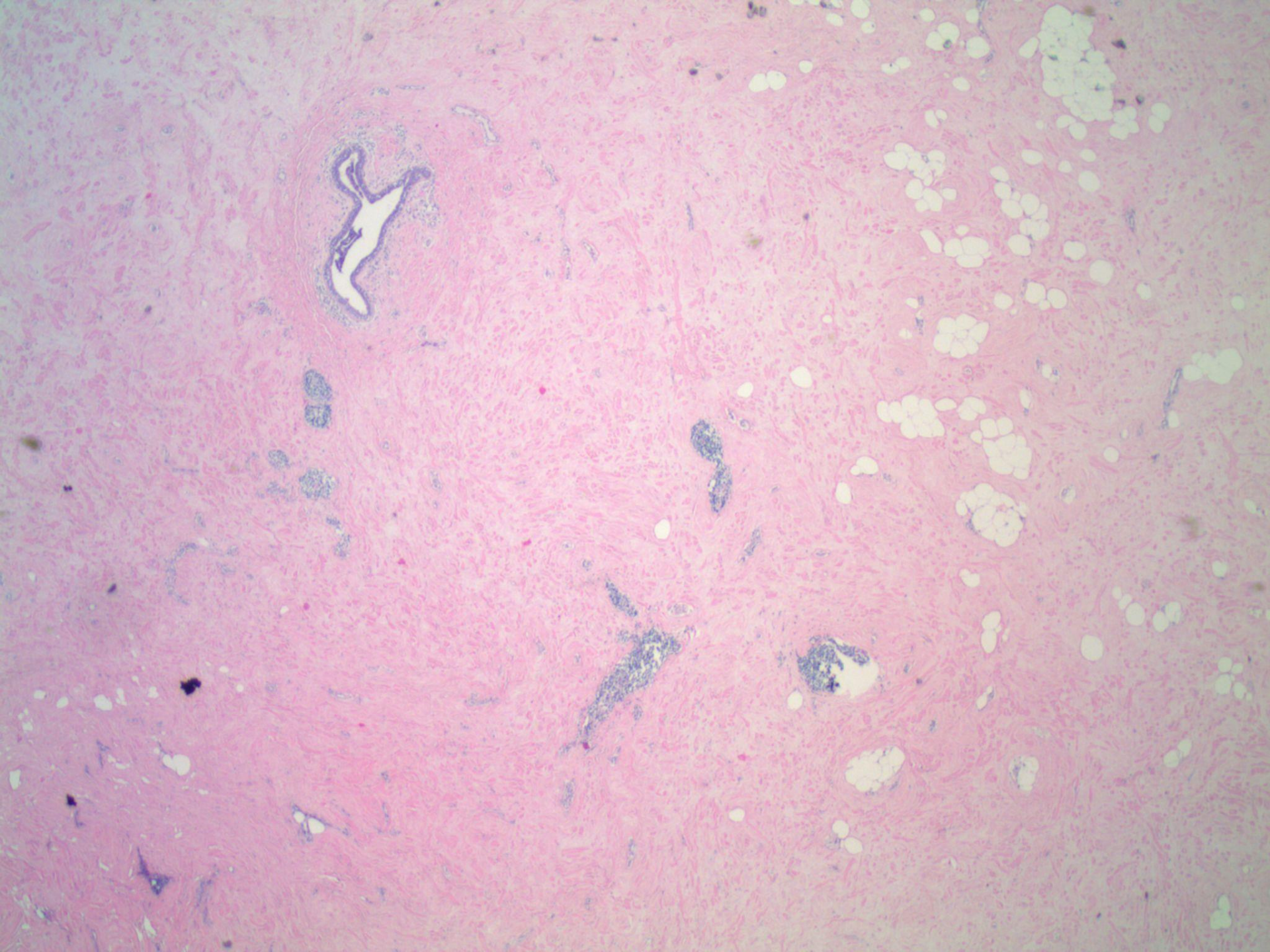


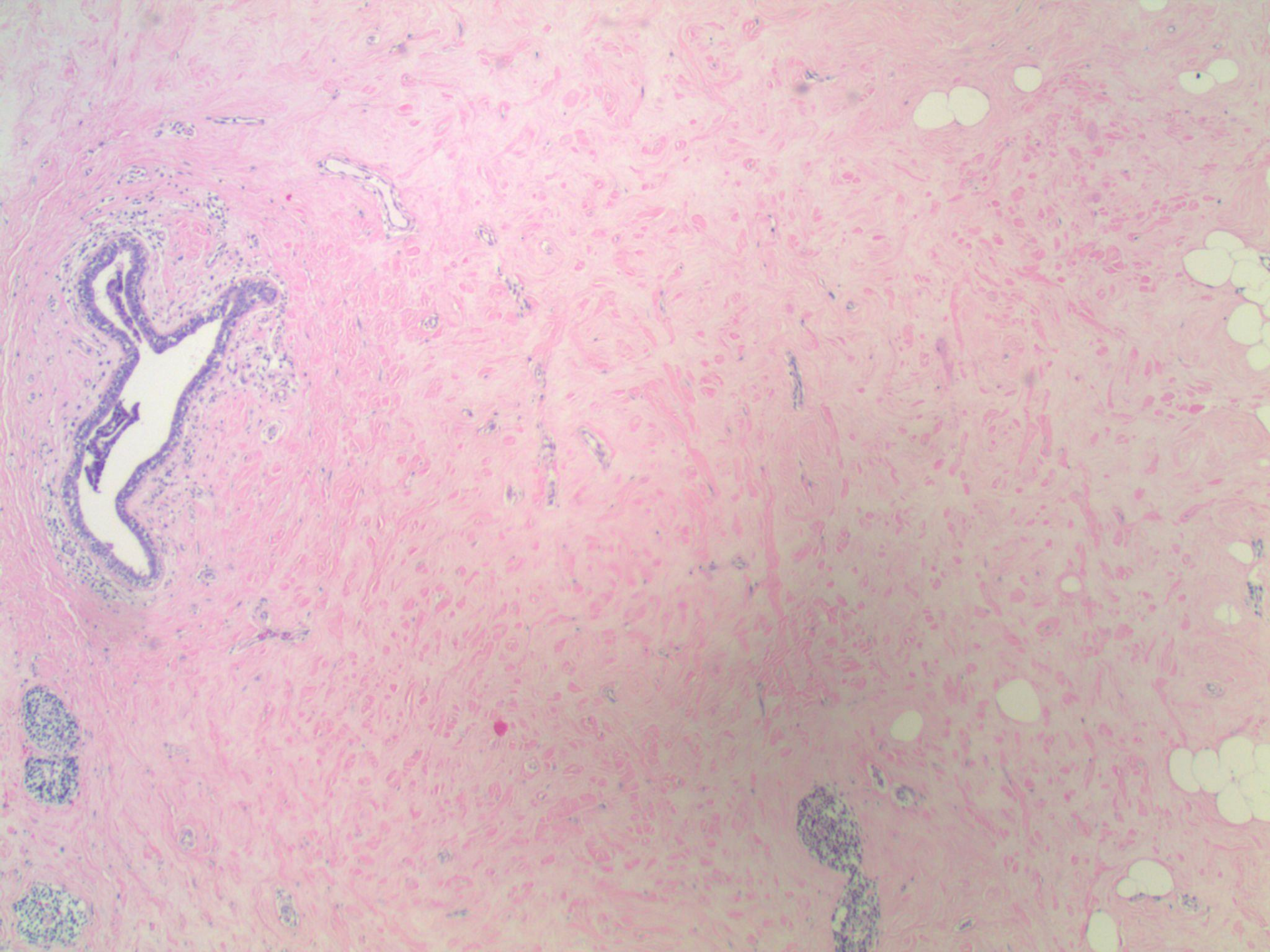


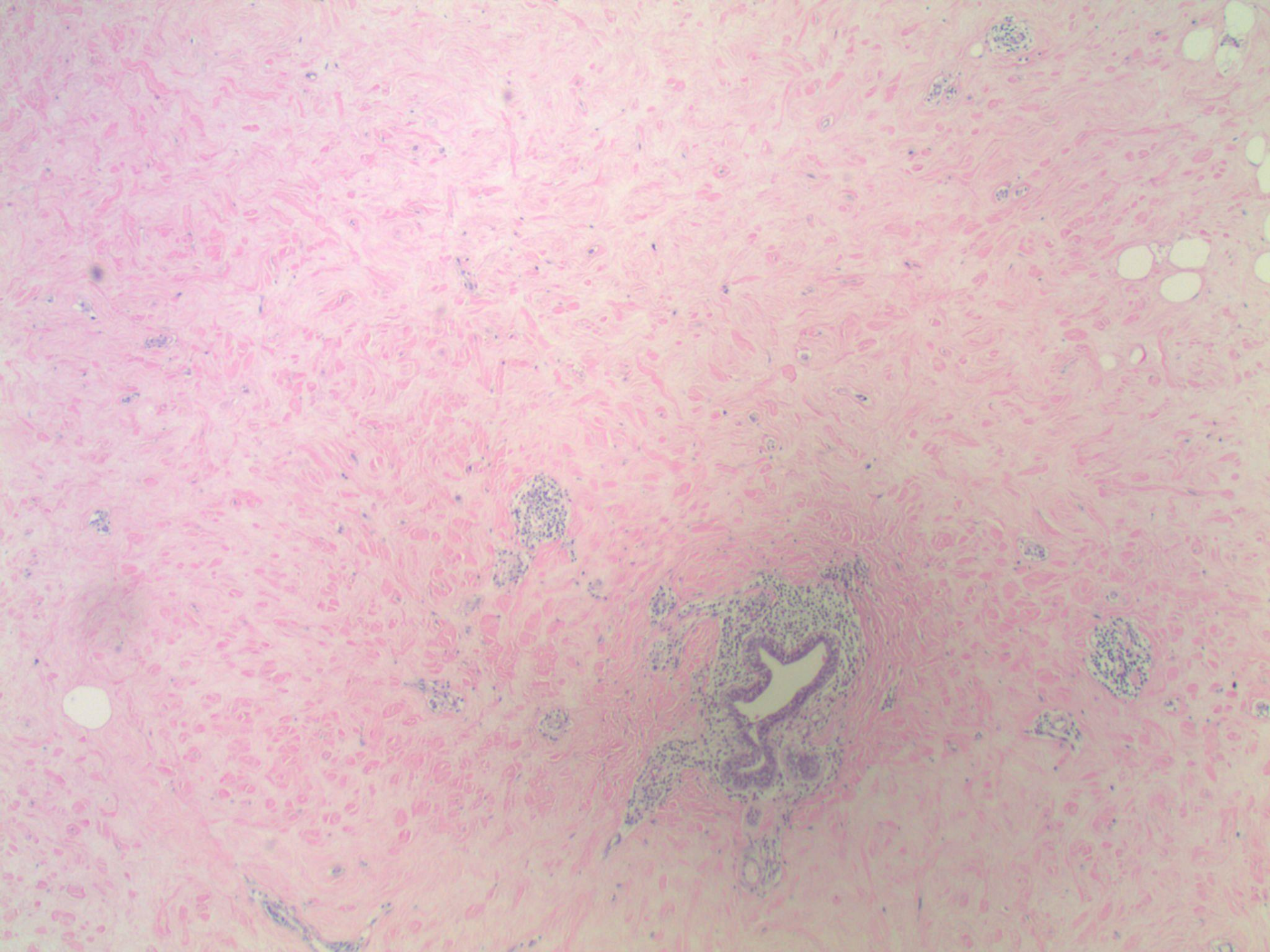


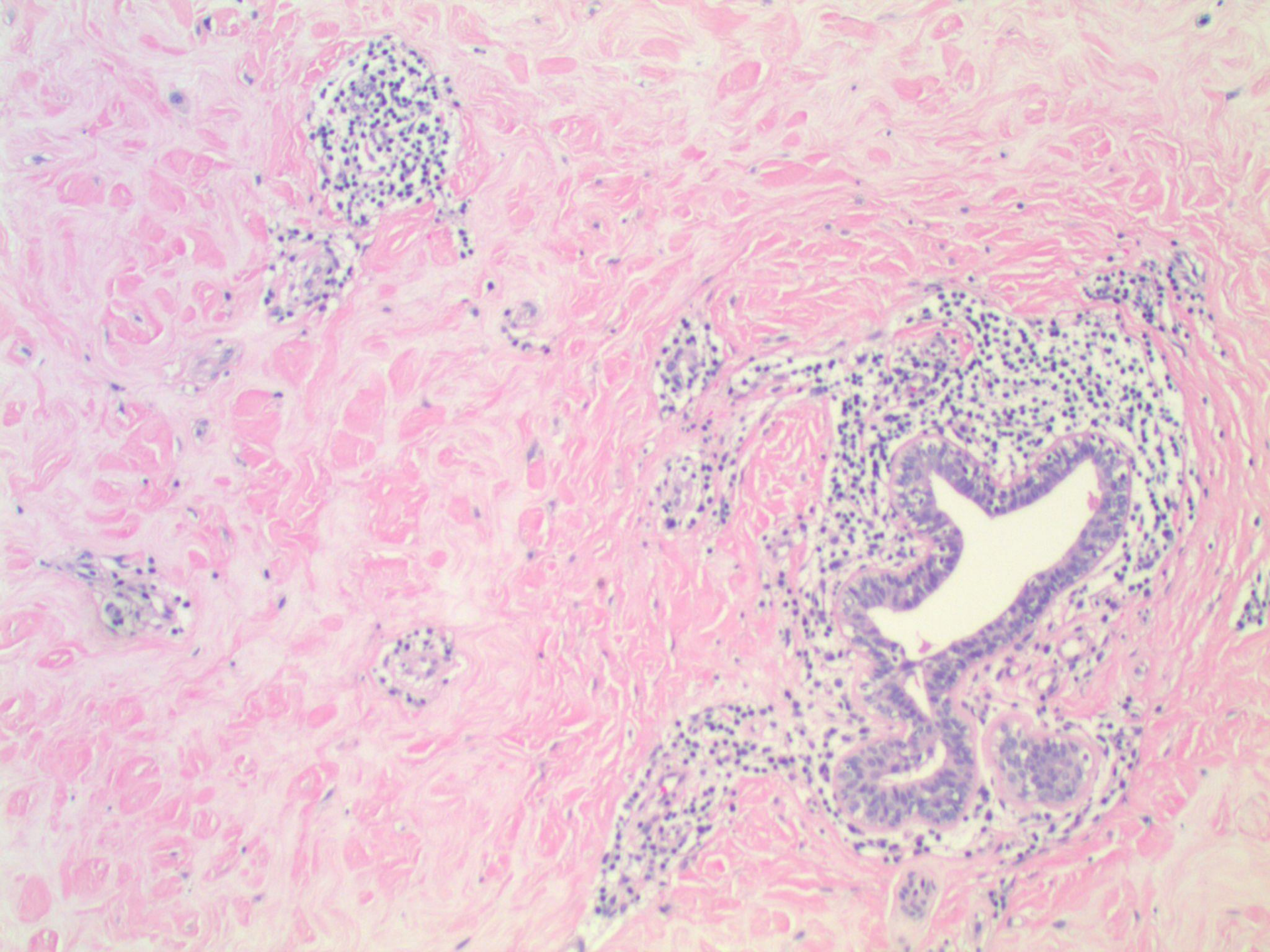
SB 5803

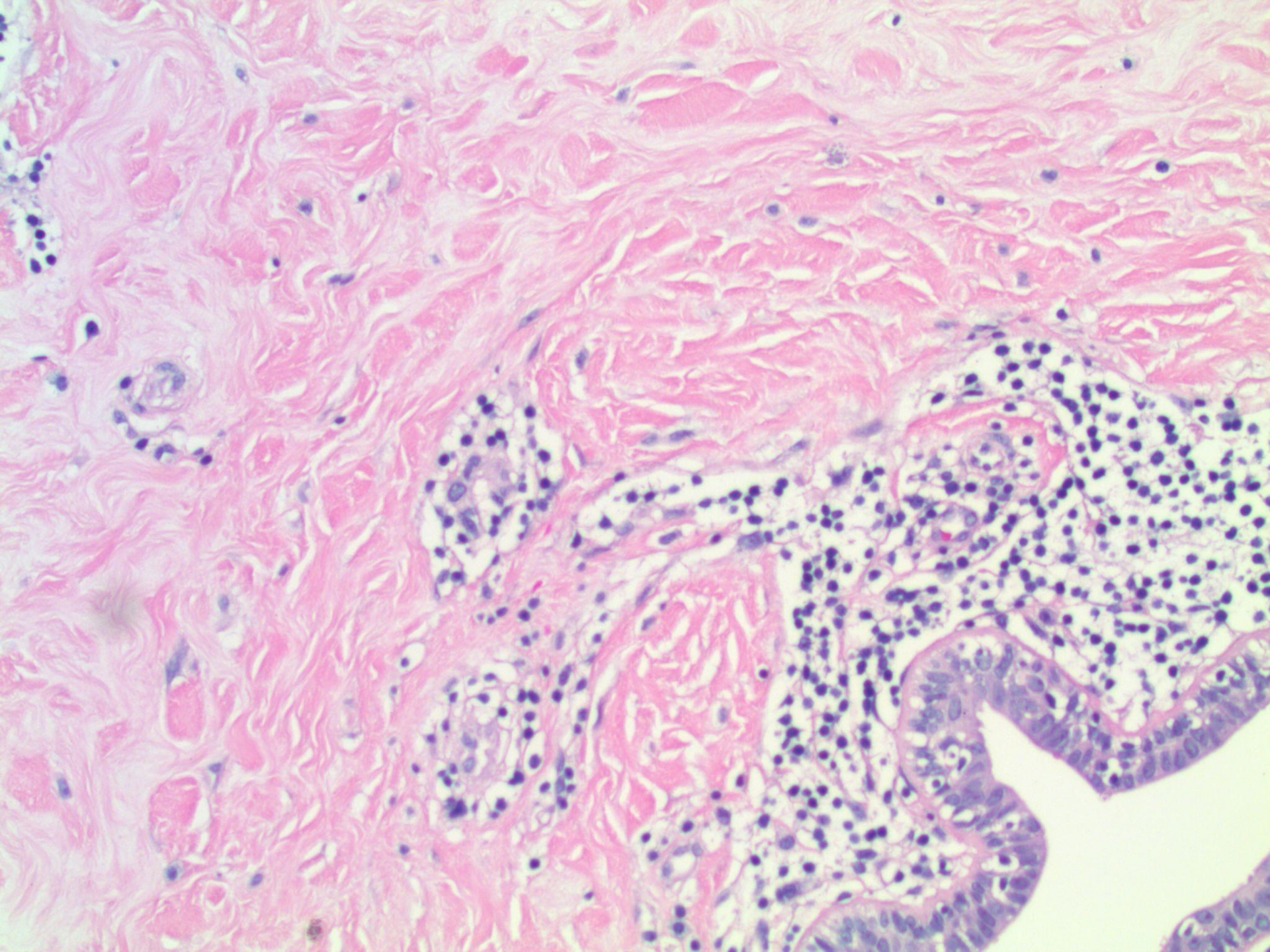
51-year-old female with breast mass. Lumpectomy performed.





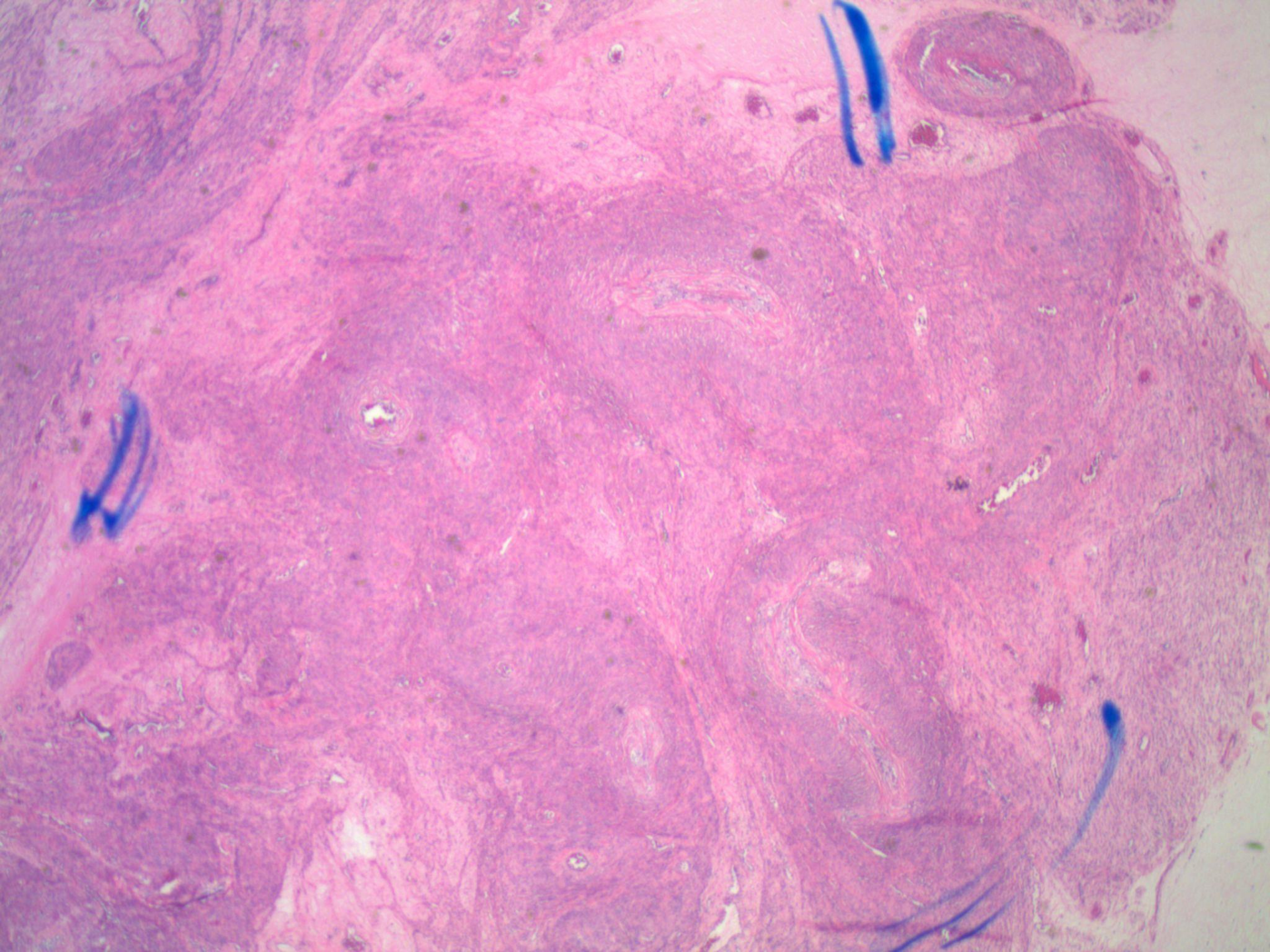


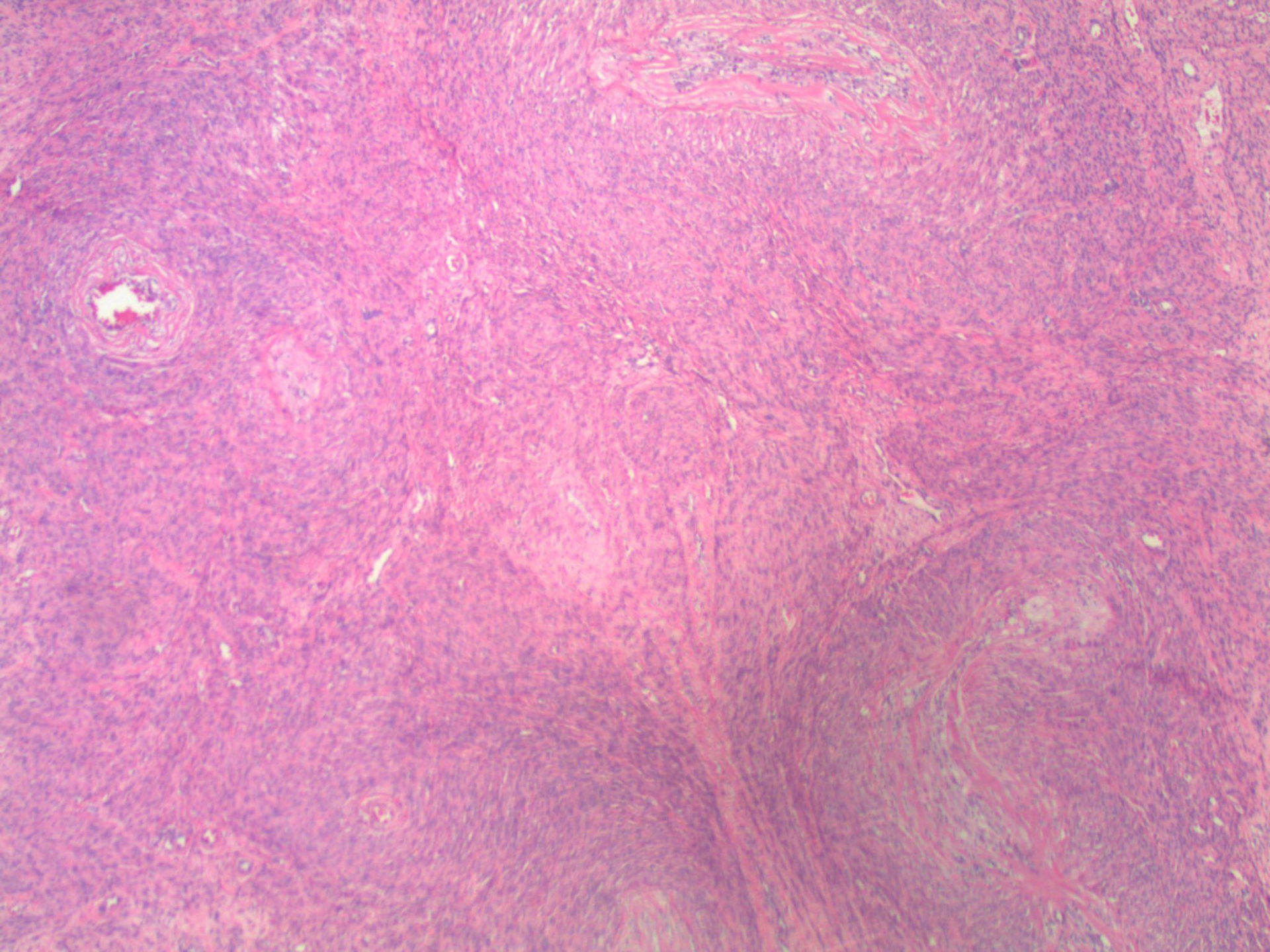


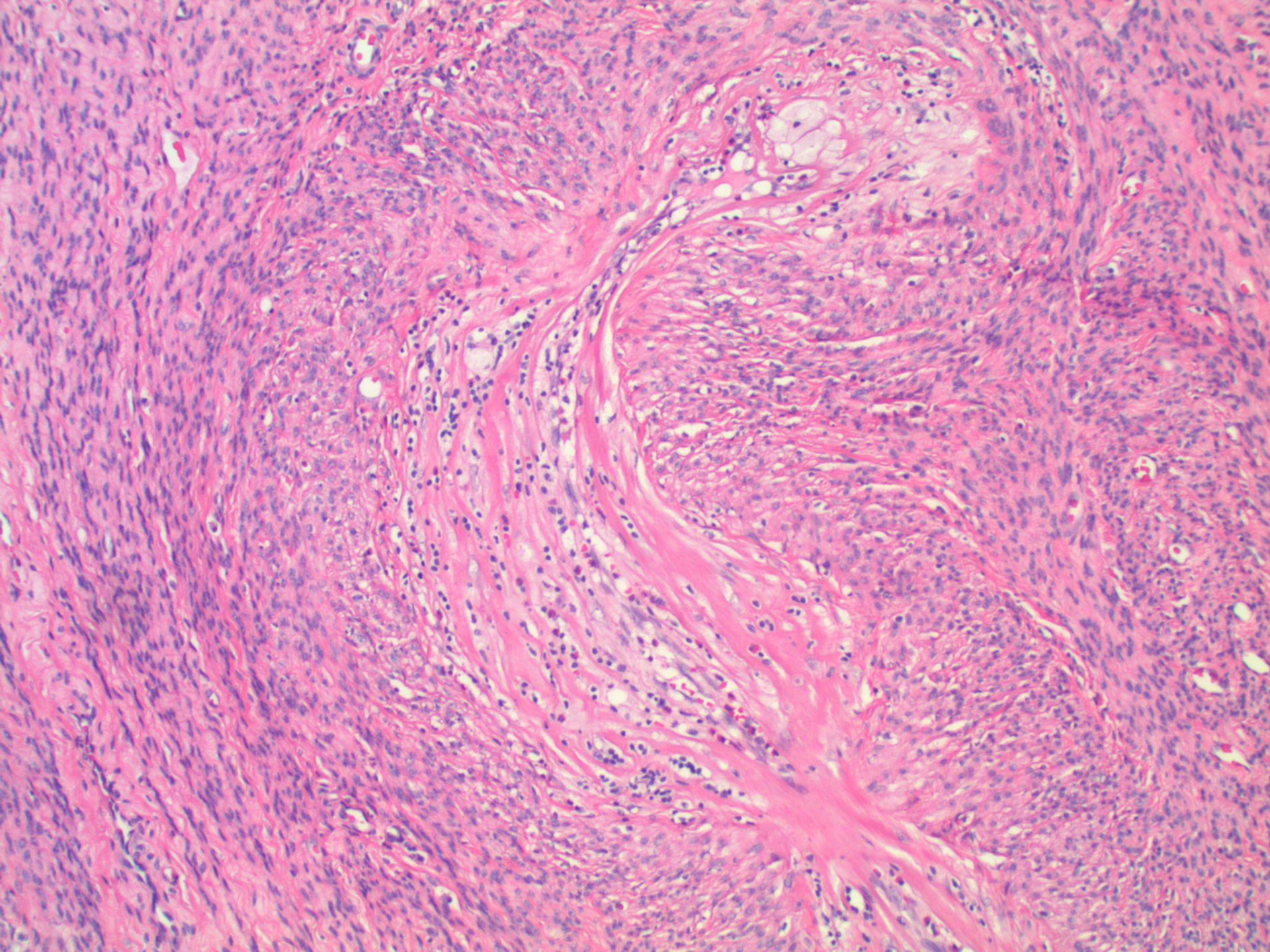


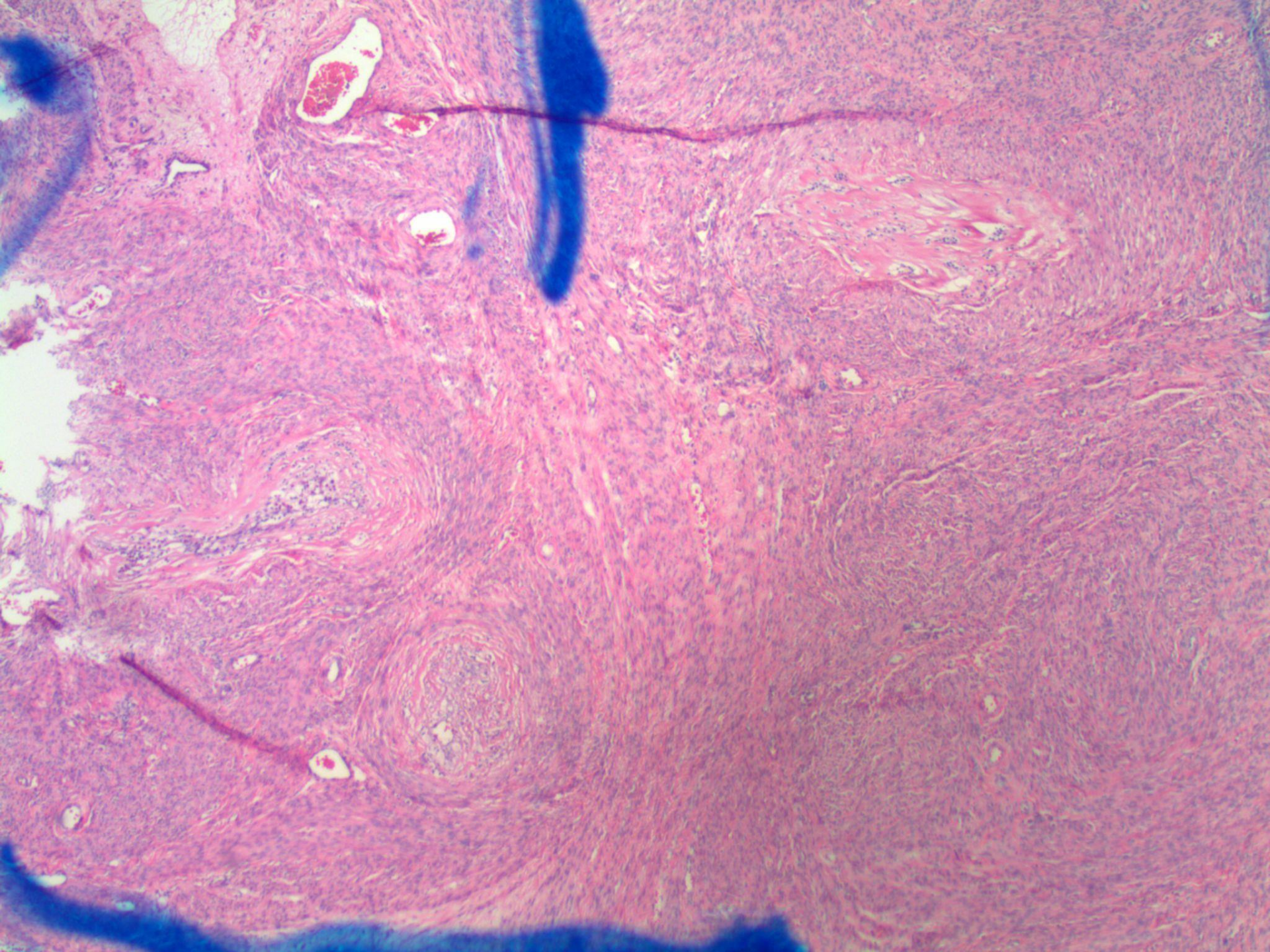
SB 5804

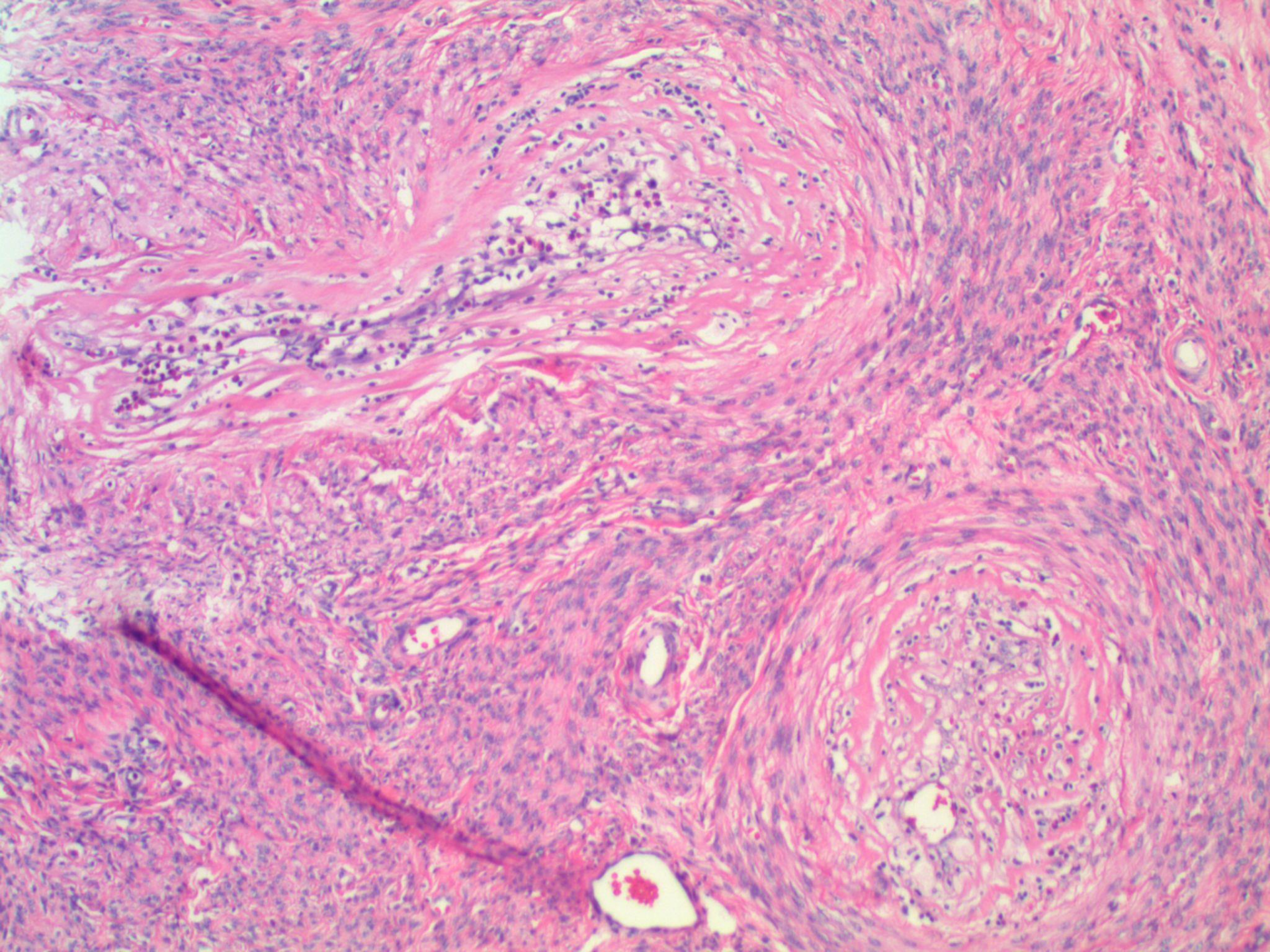
49-year-old female with fibroid uterus. Hysterectomy performed.

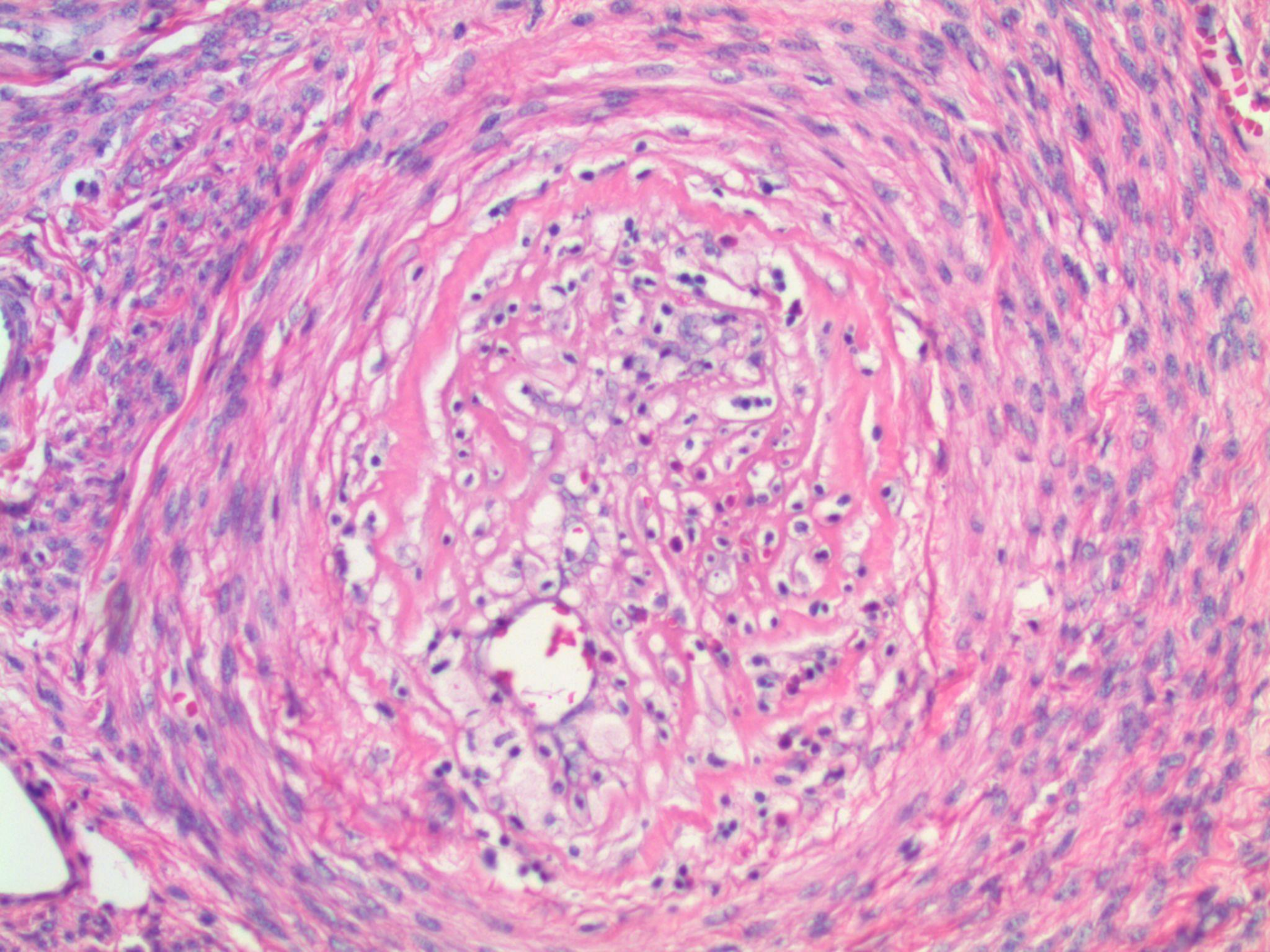


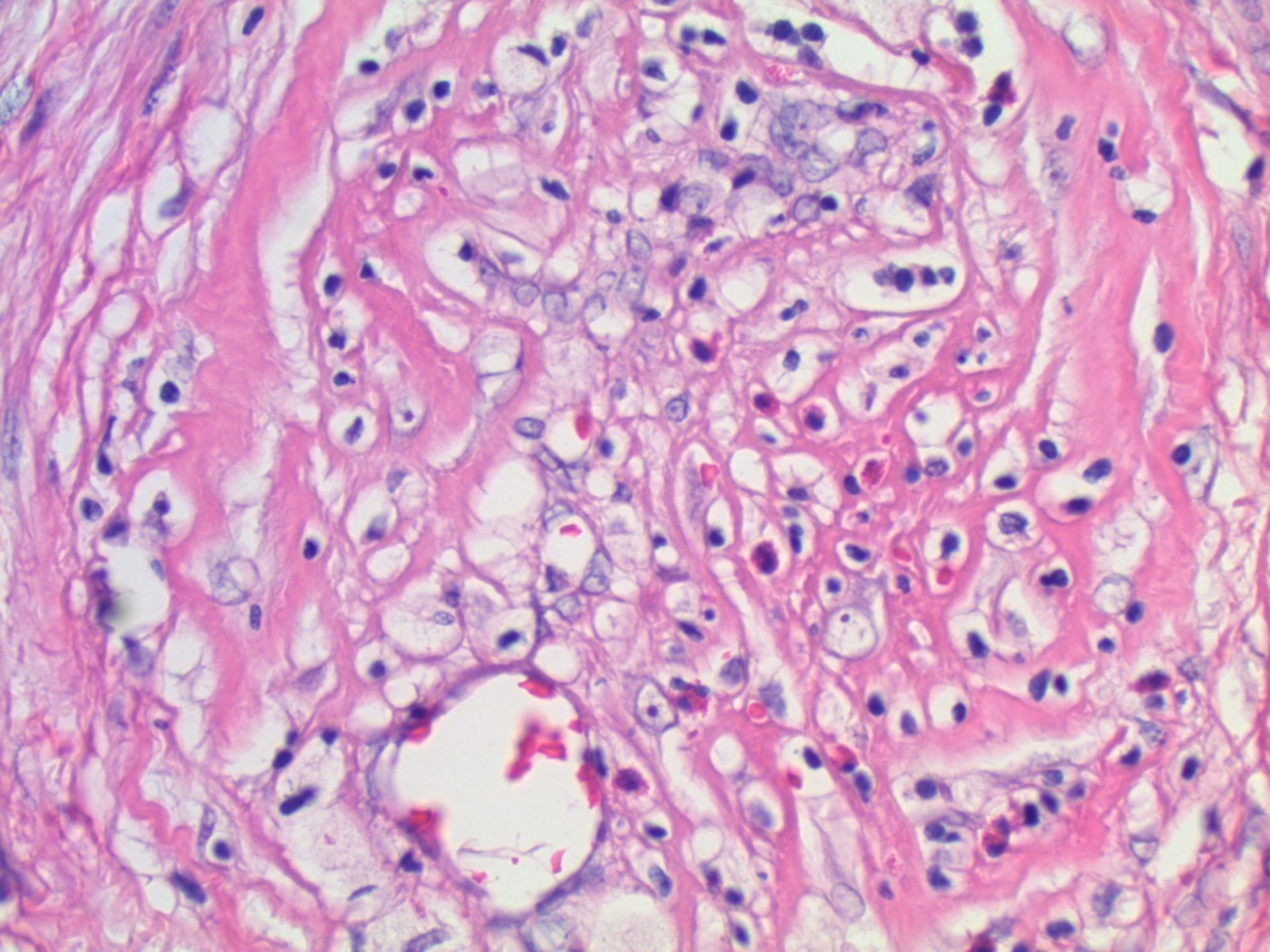






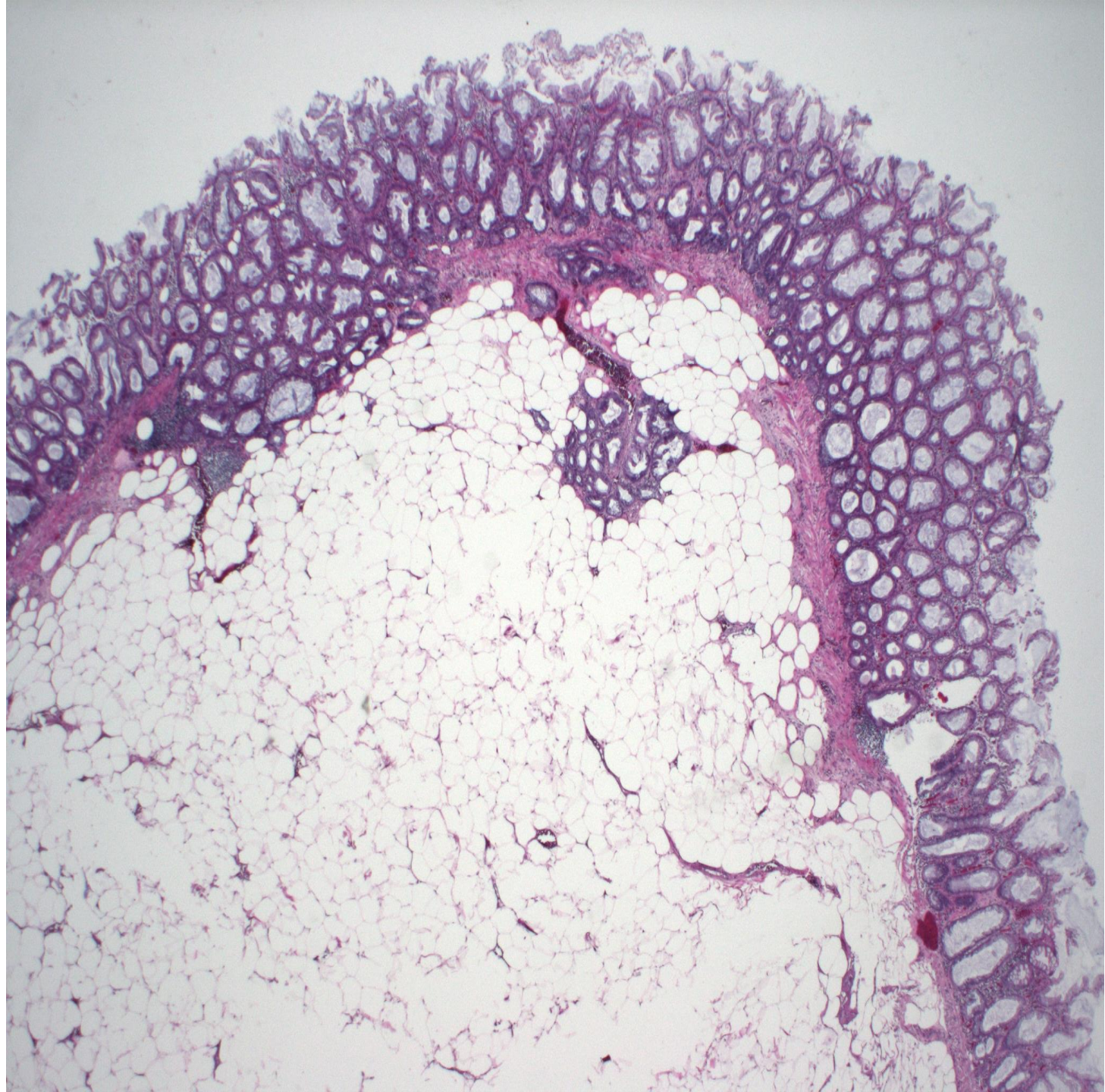


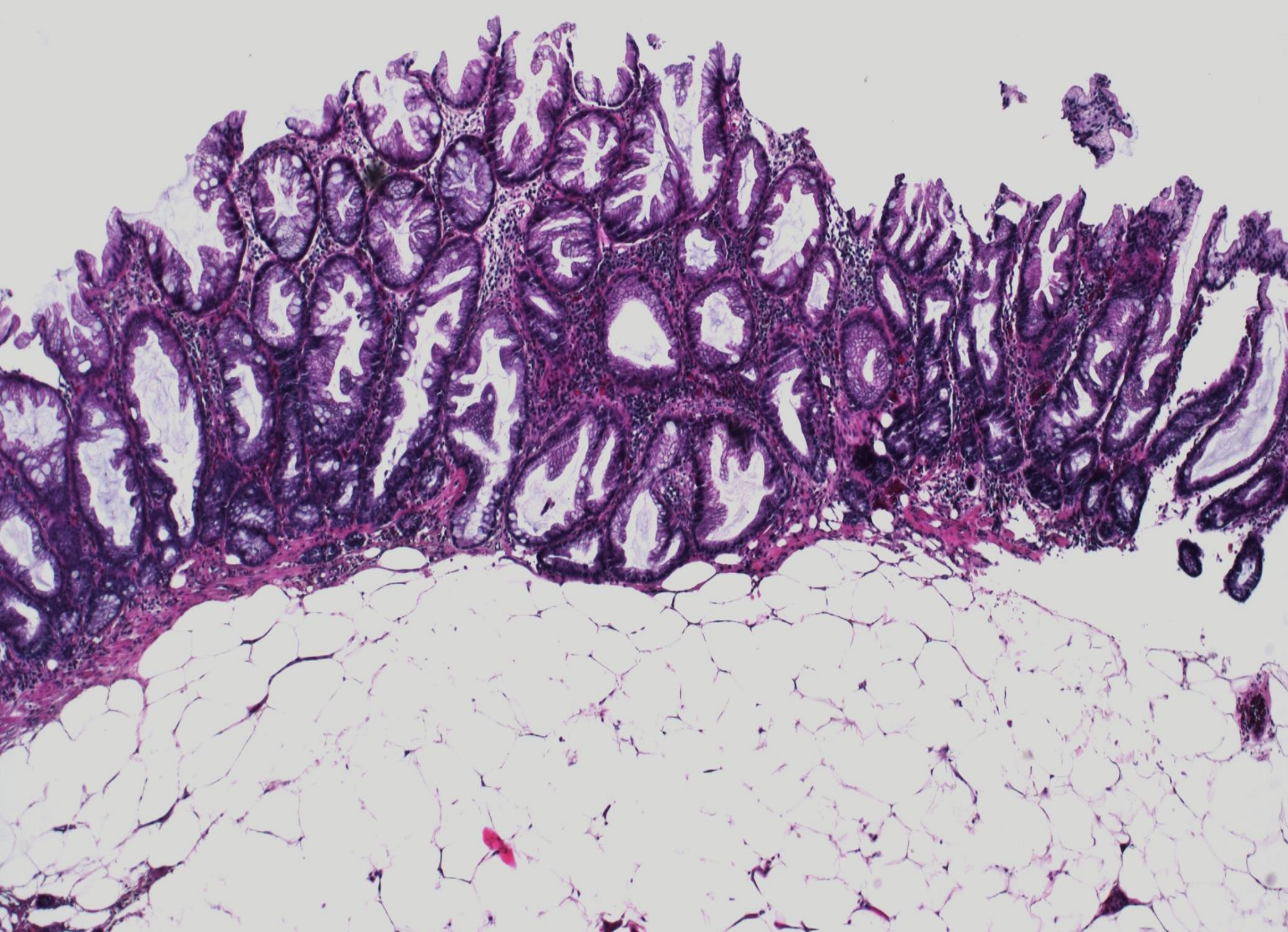


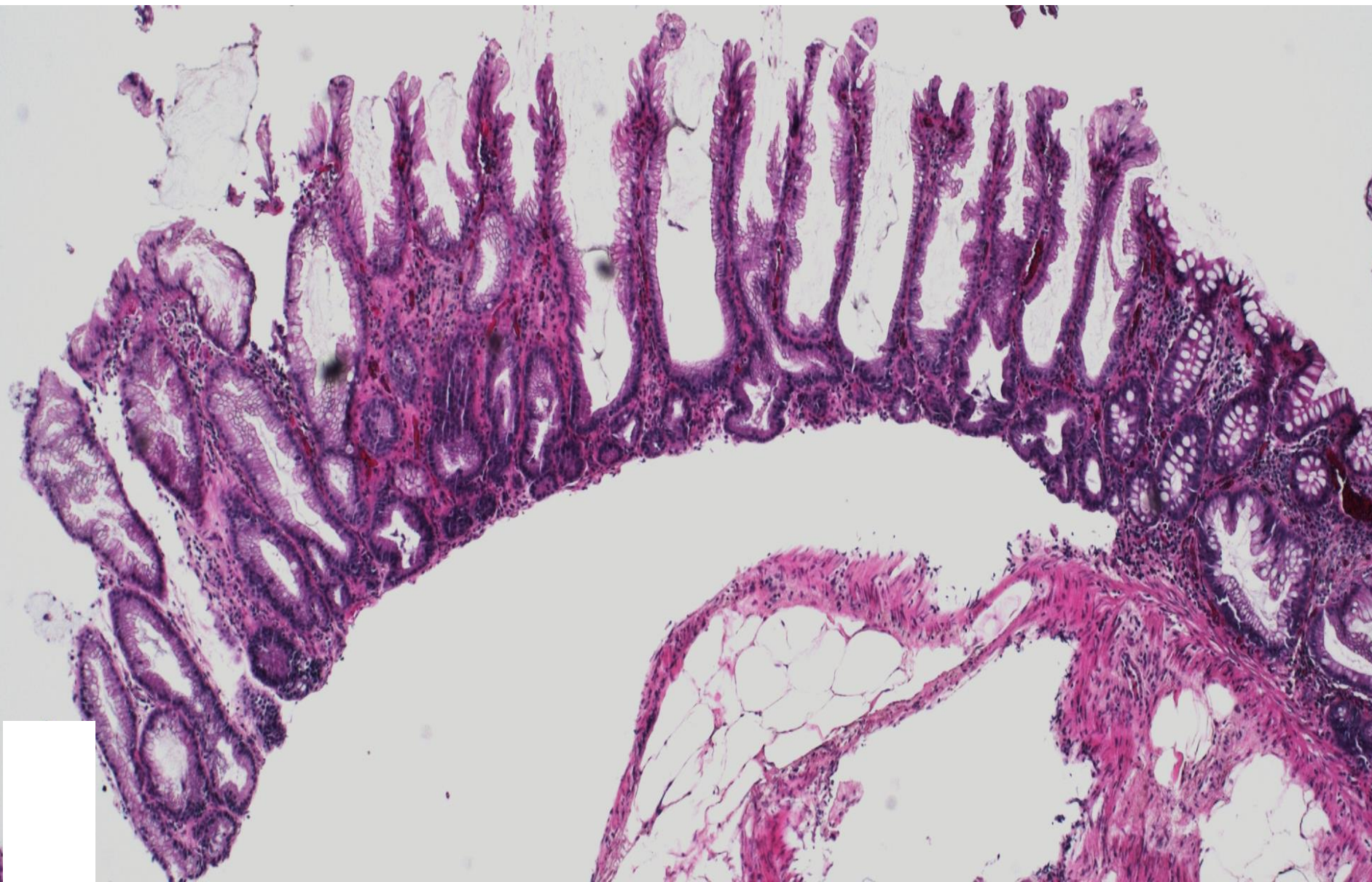


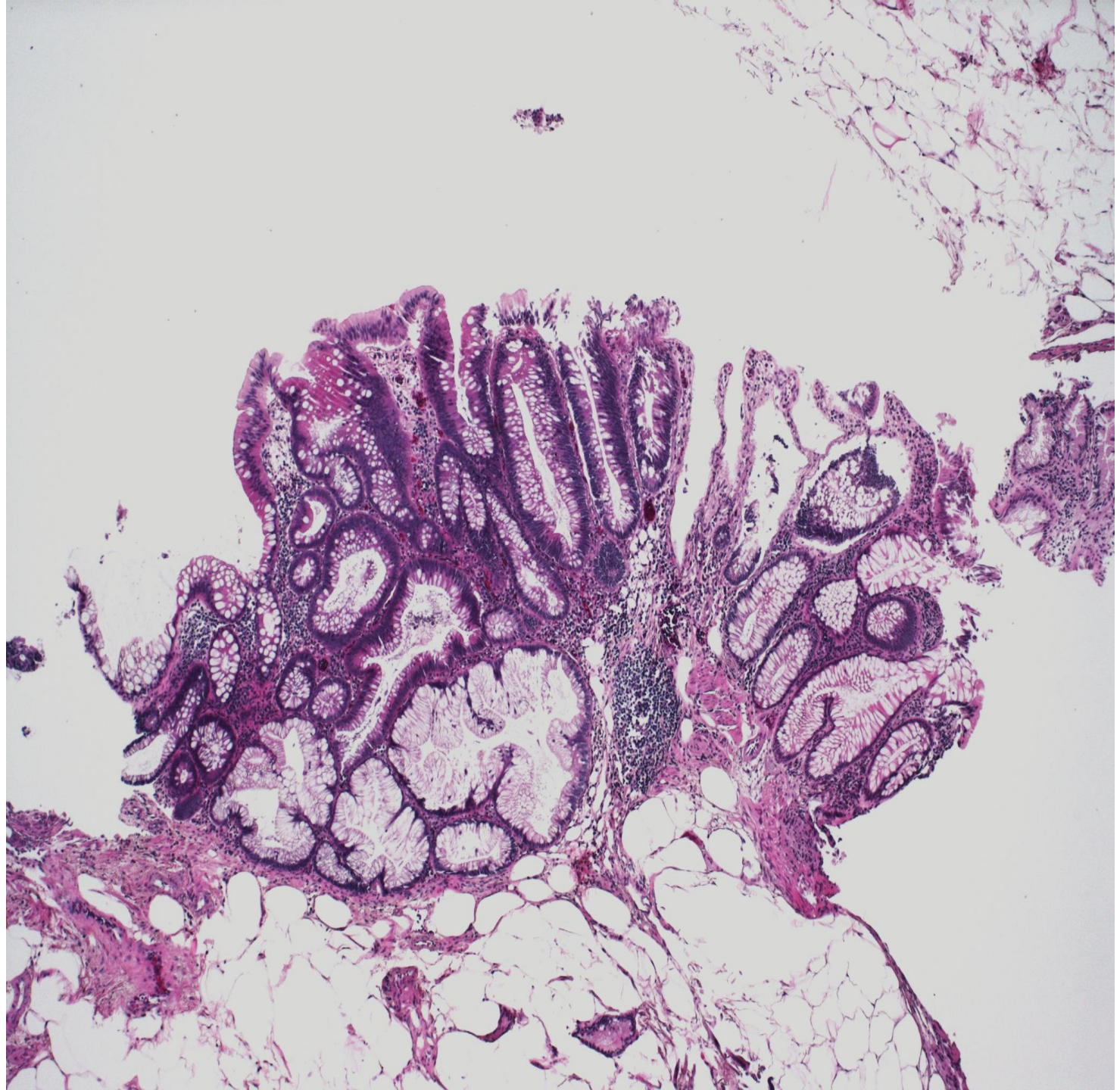
SB 5805

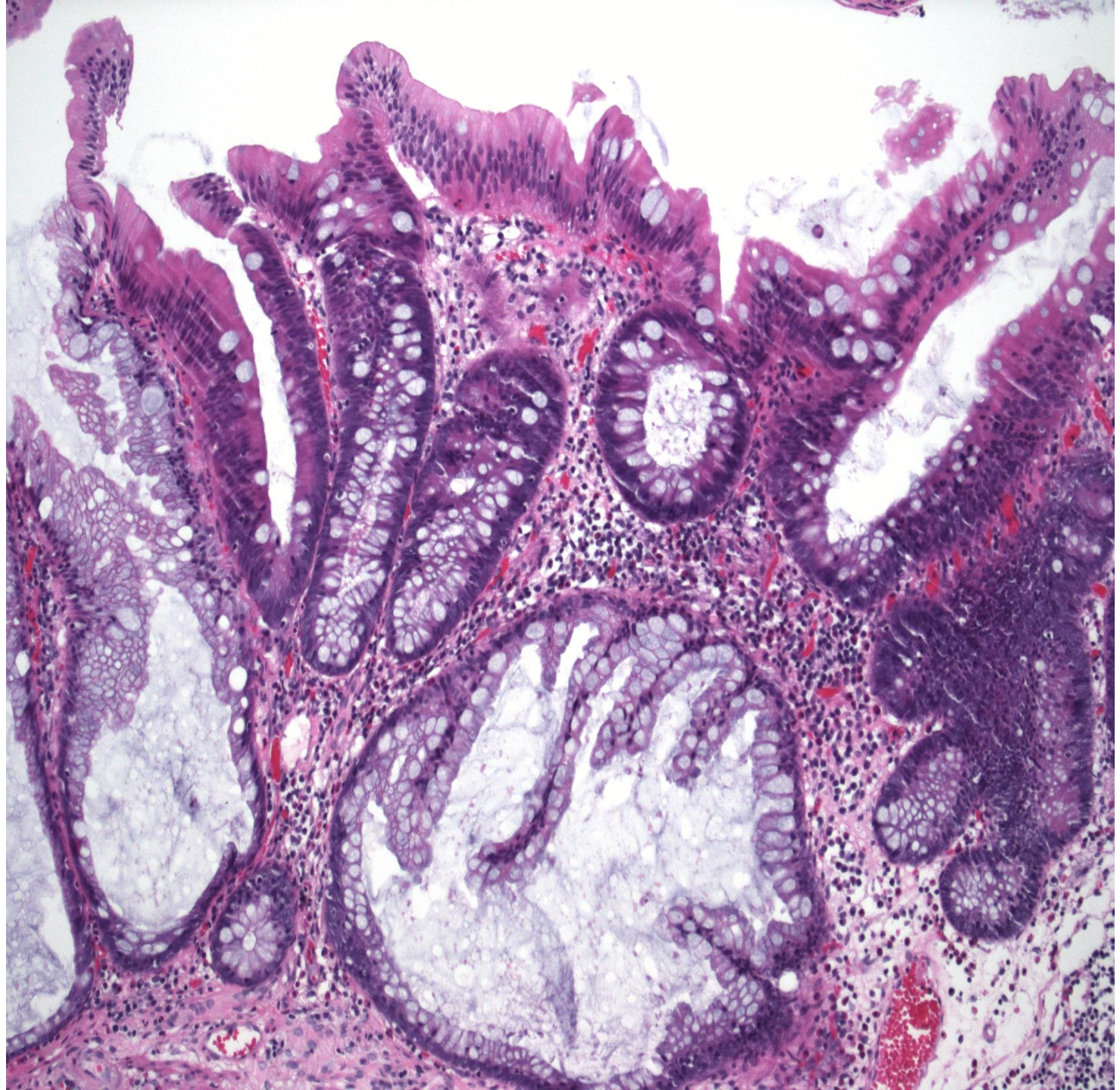
70-year-old male with 3cm polyp
at the hepatic flexure.

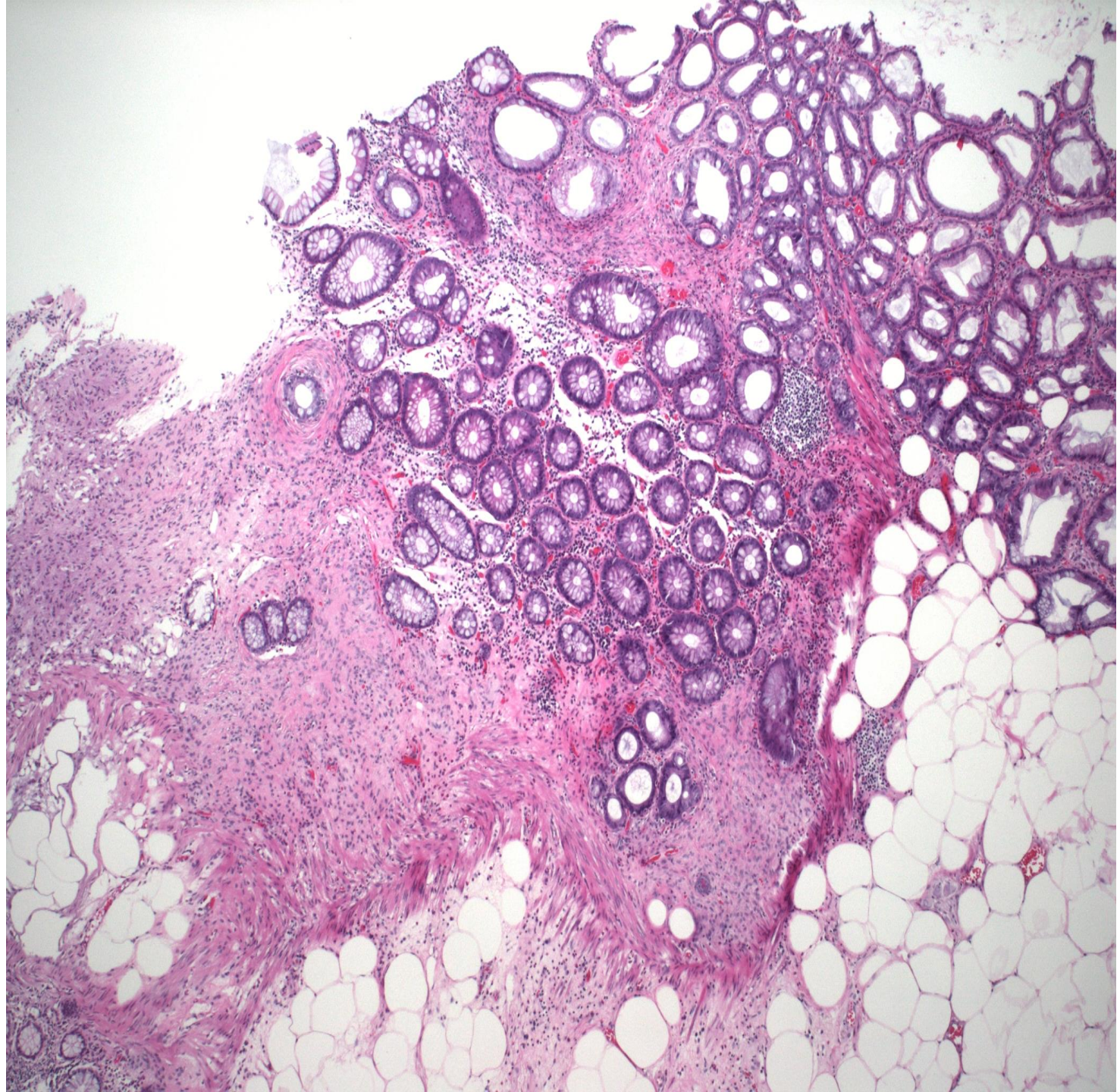


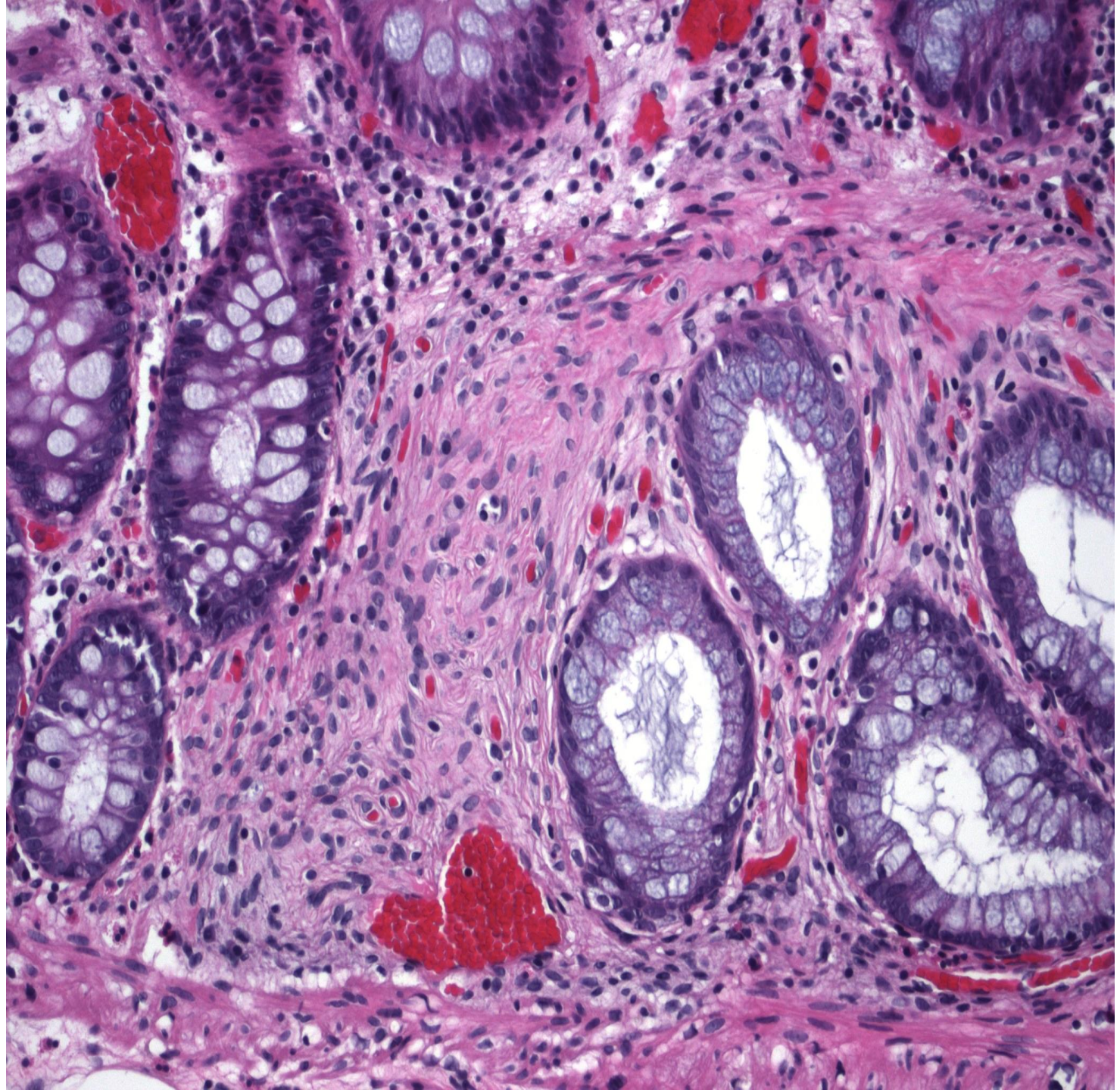






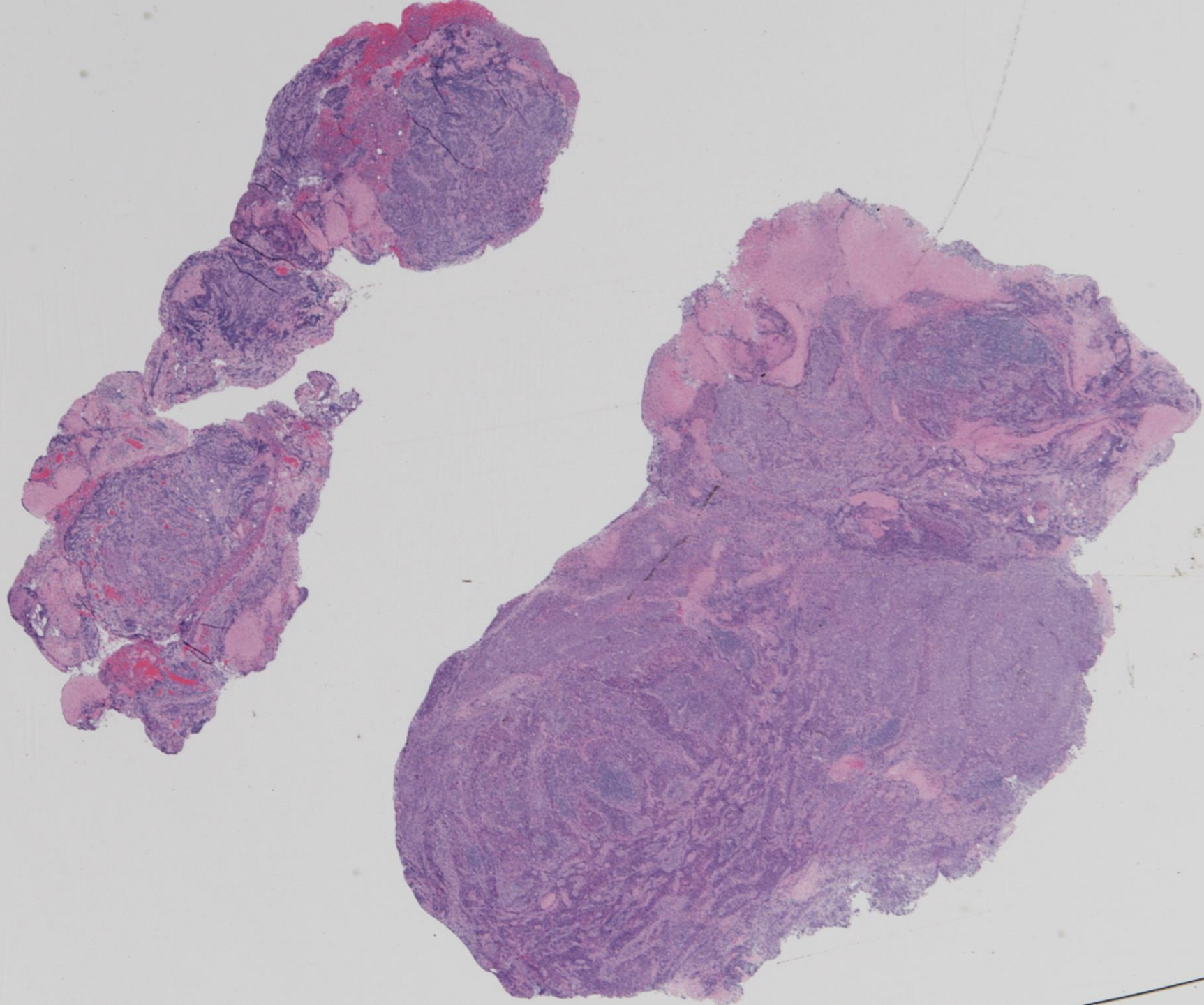


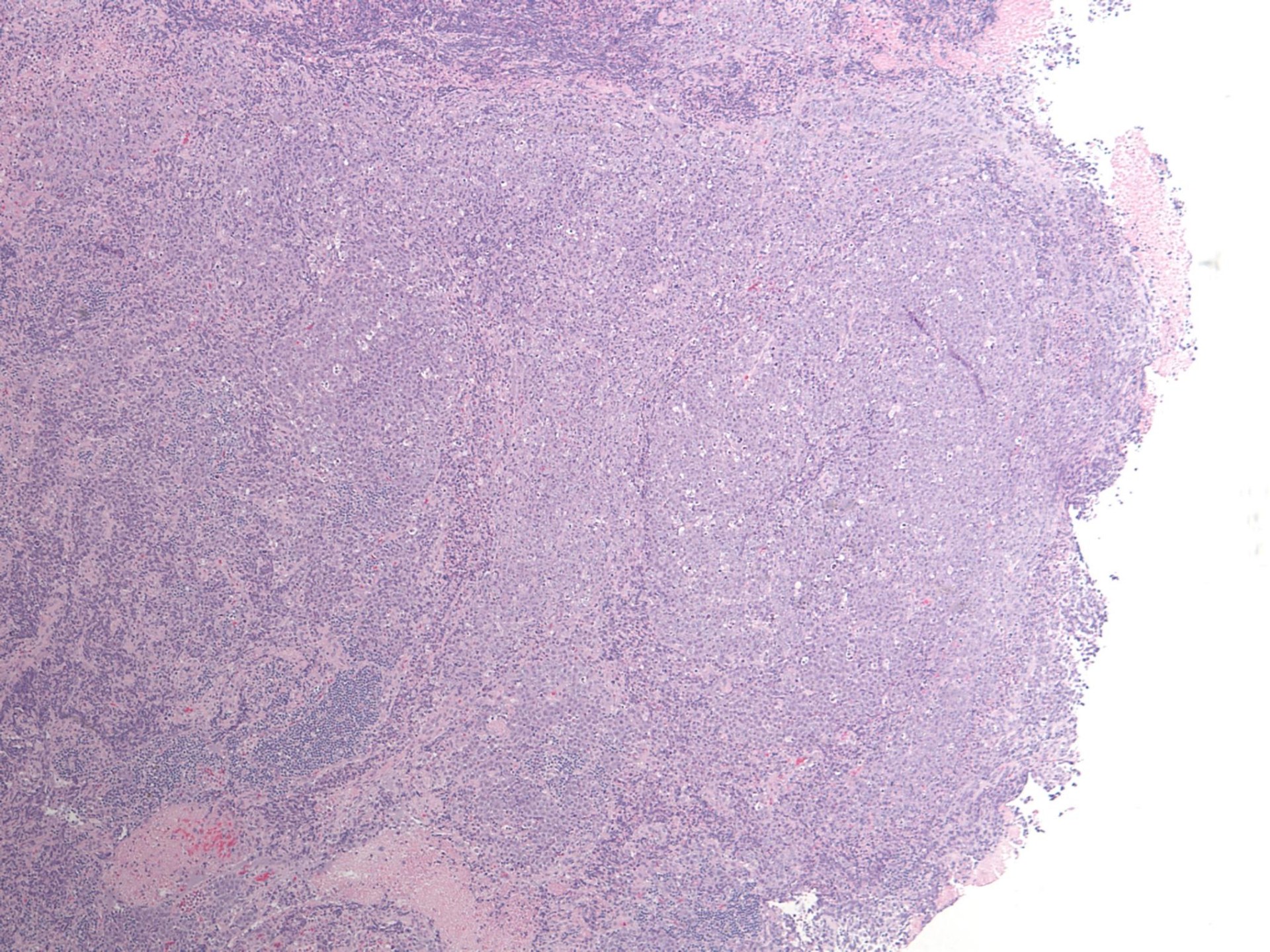


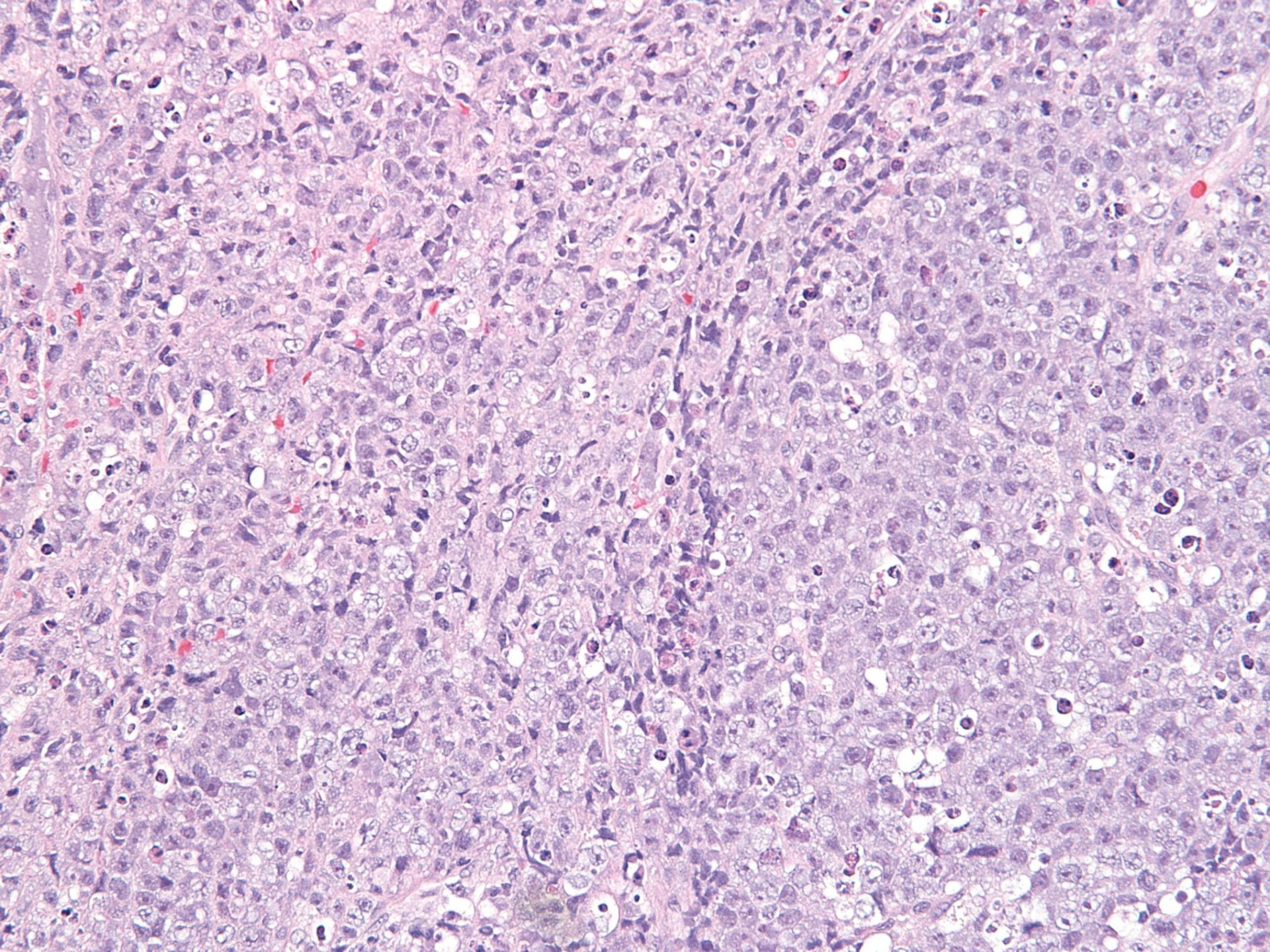


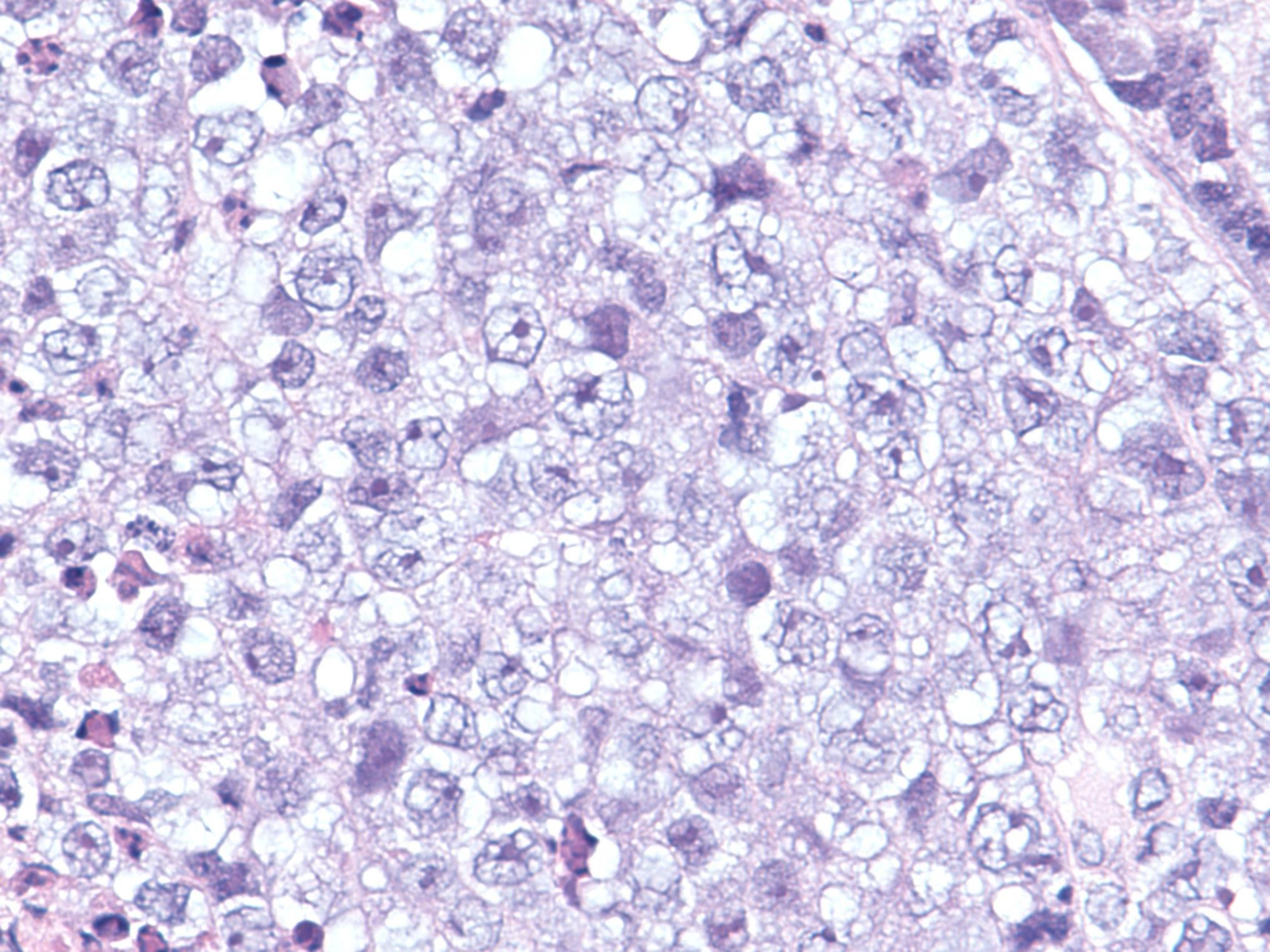
SB 5806

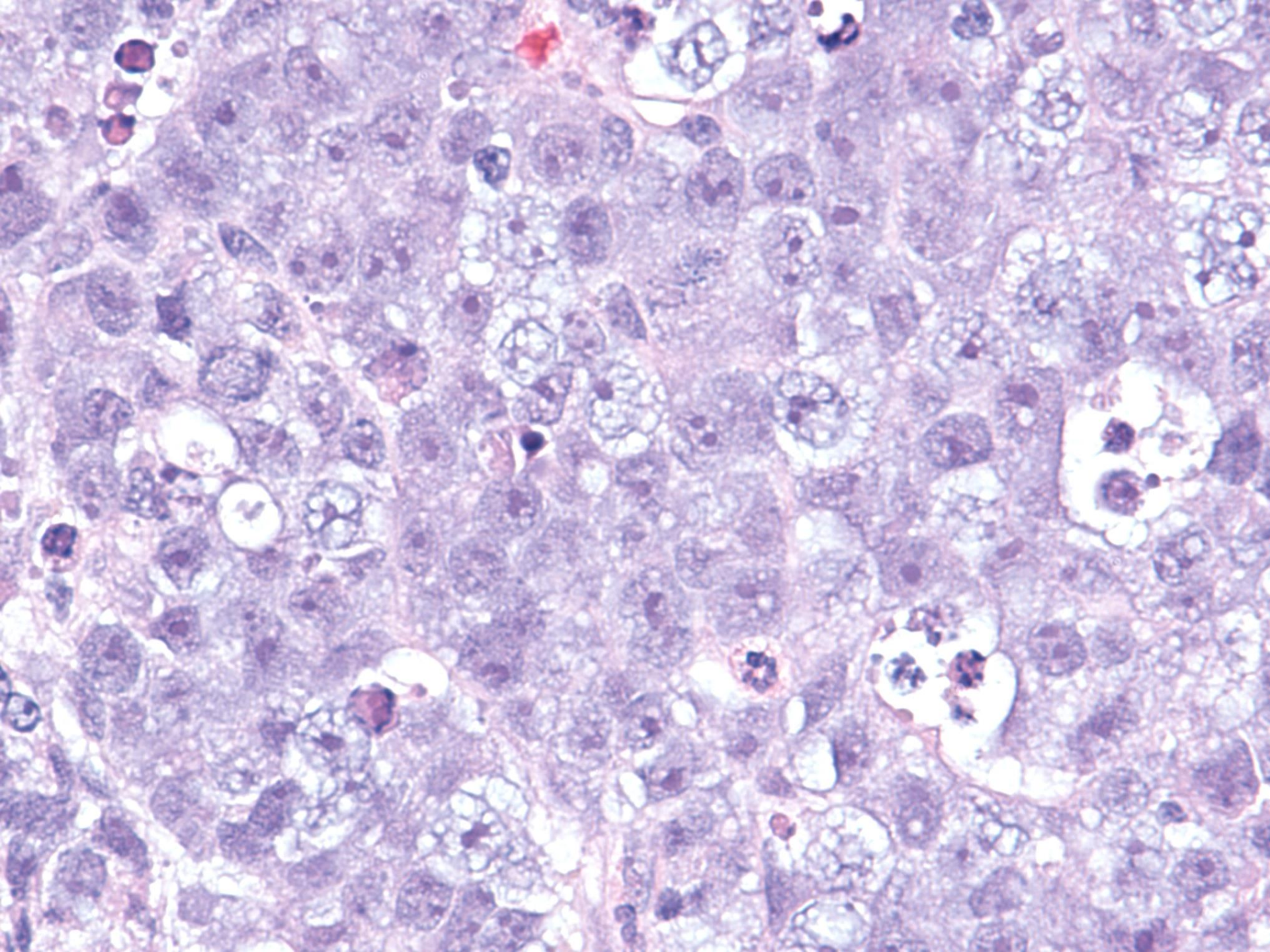
38-year-old female with a left hilar mass, status post biopsy of mediastinal lymph nodes.





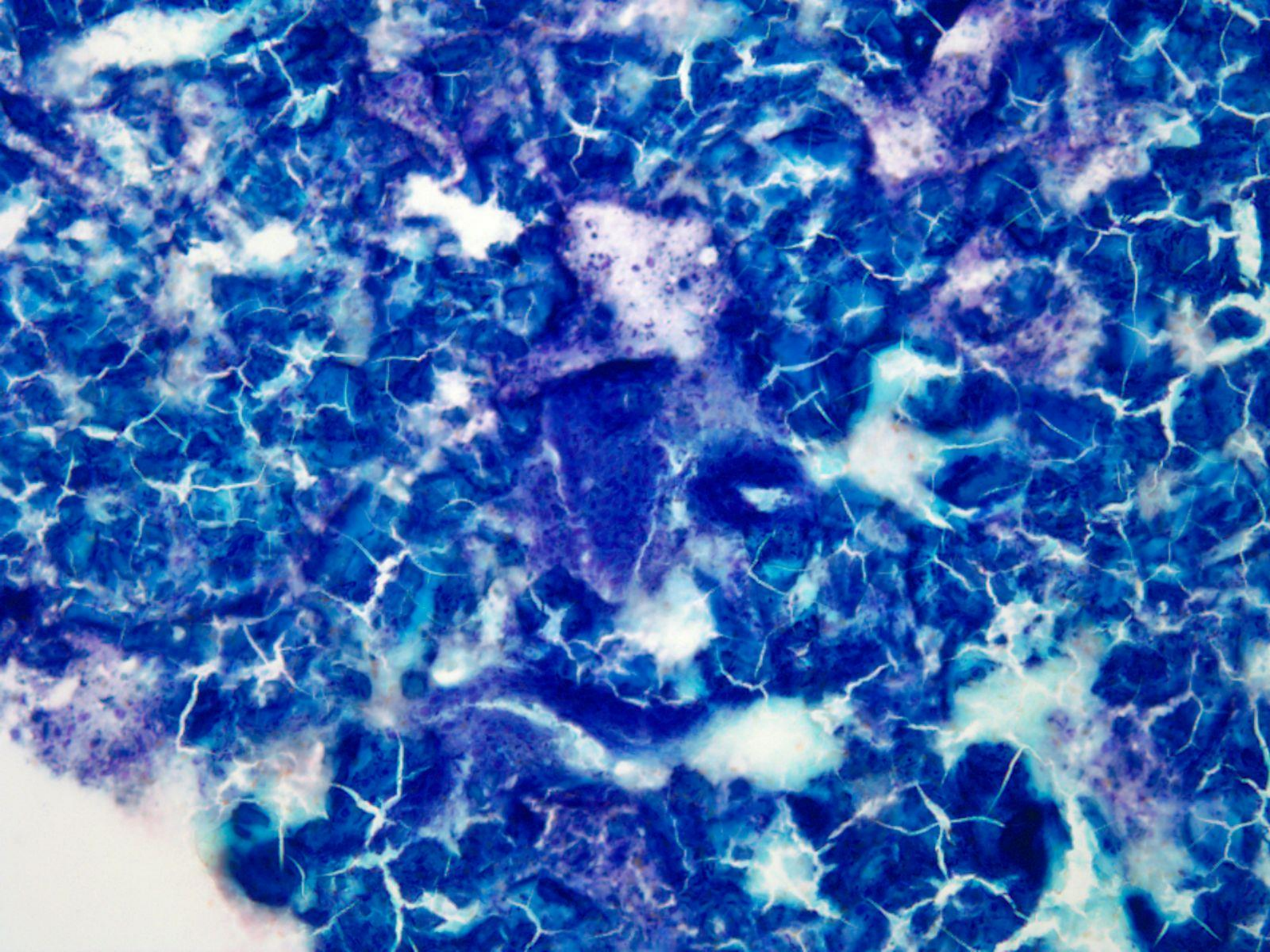


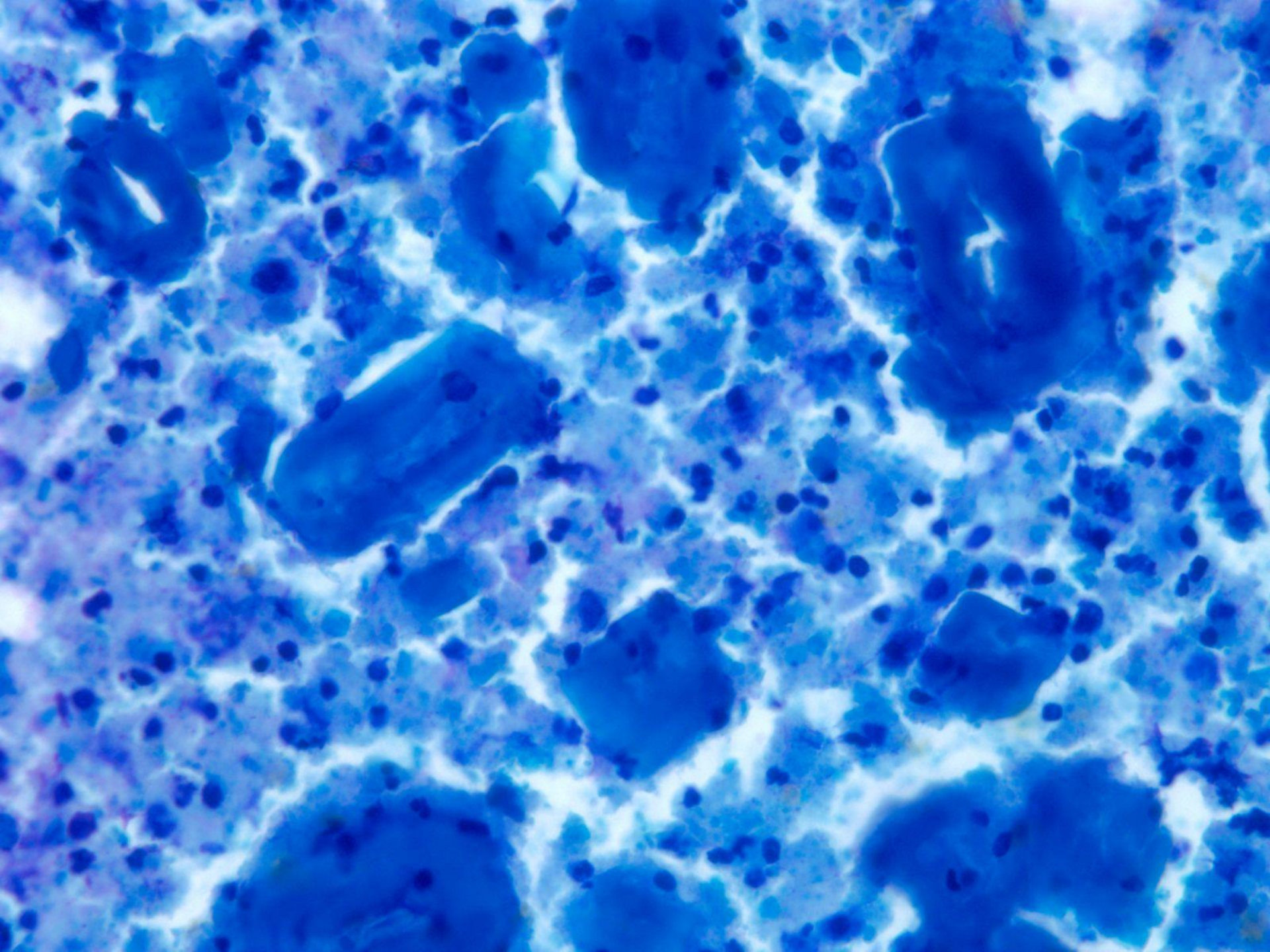


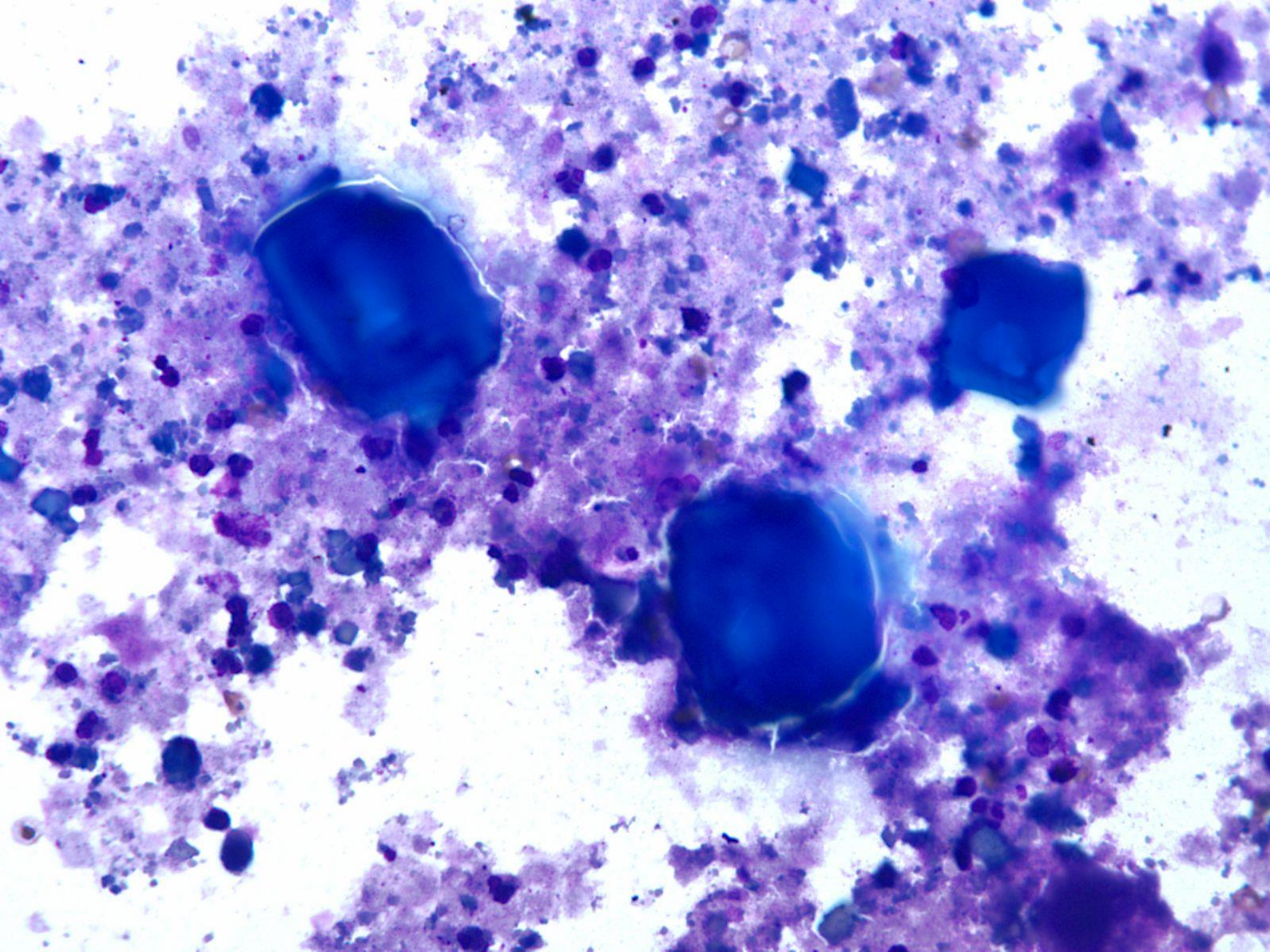


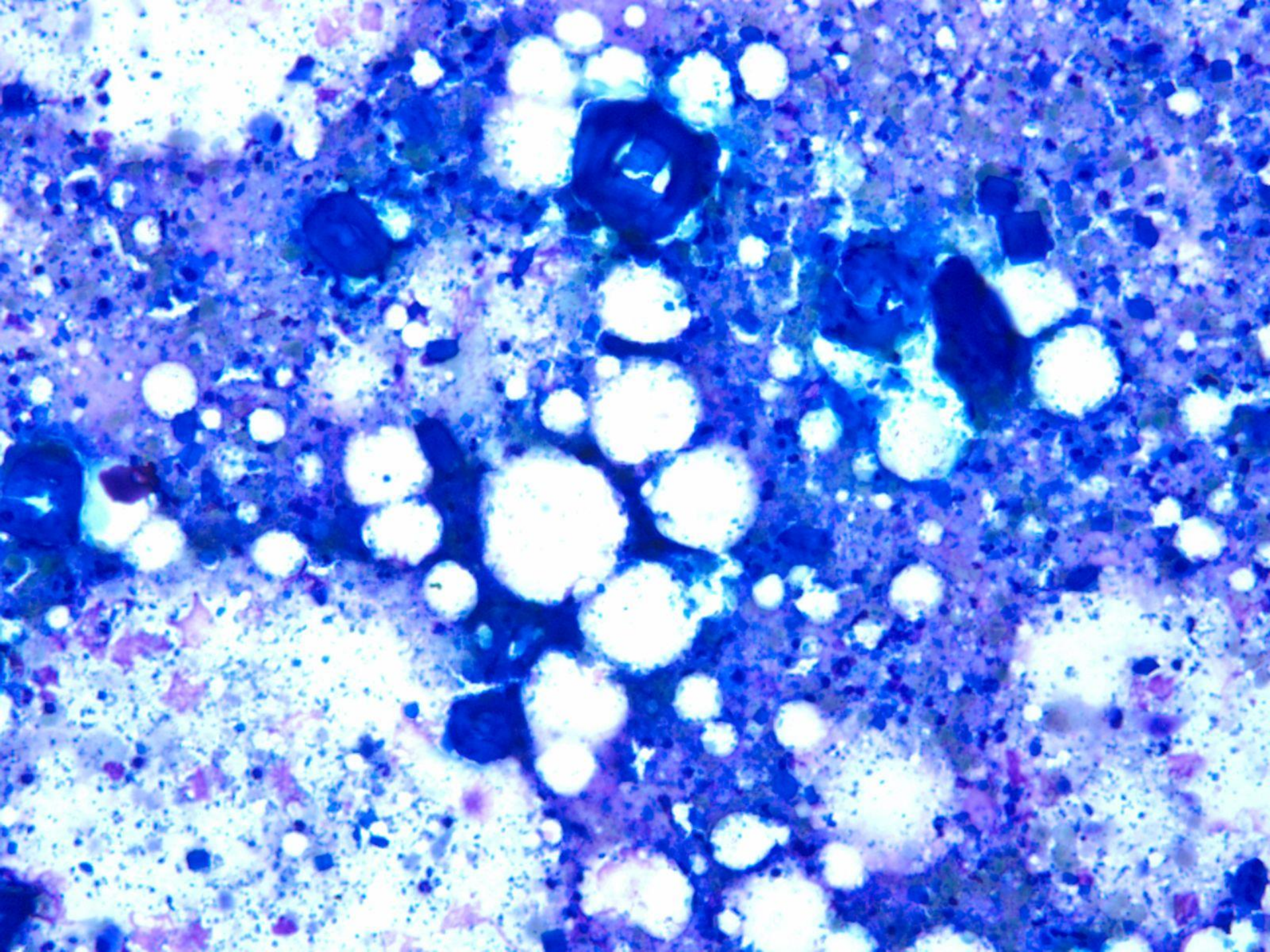
SB 5807

61-year-old female with right
parotid mass. FNA performed.



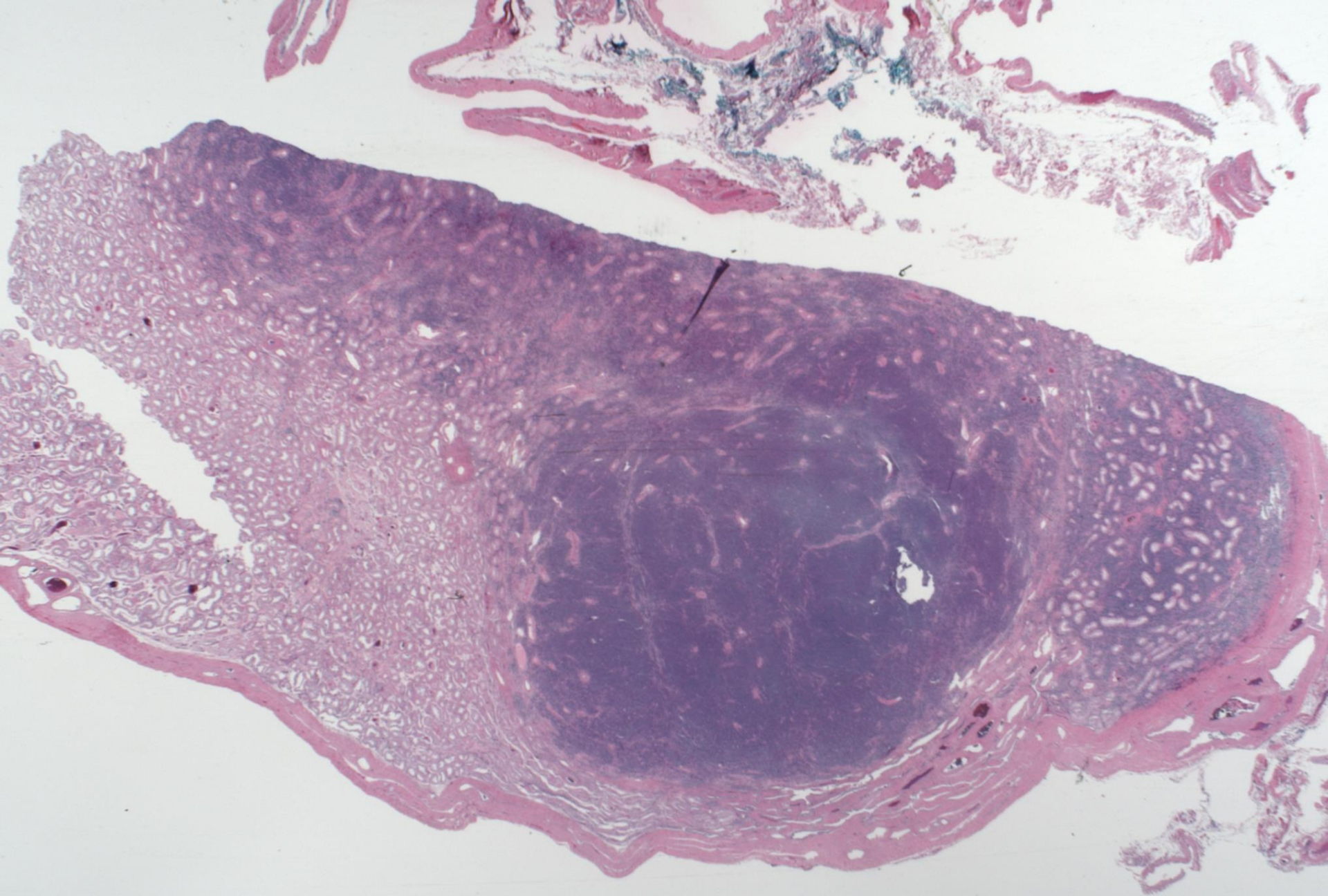


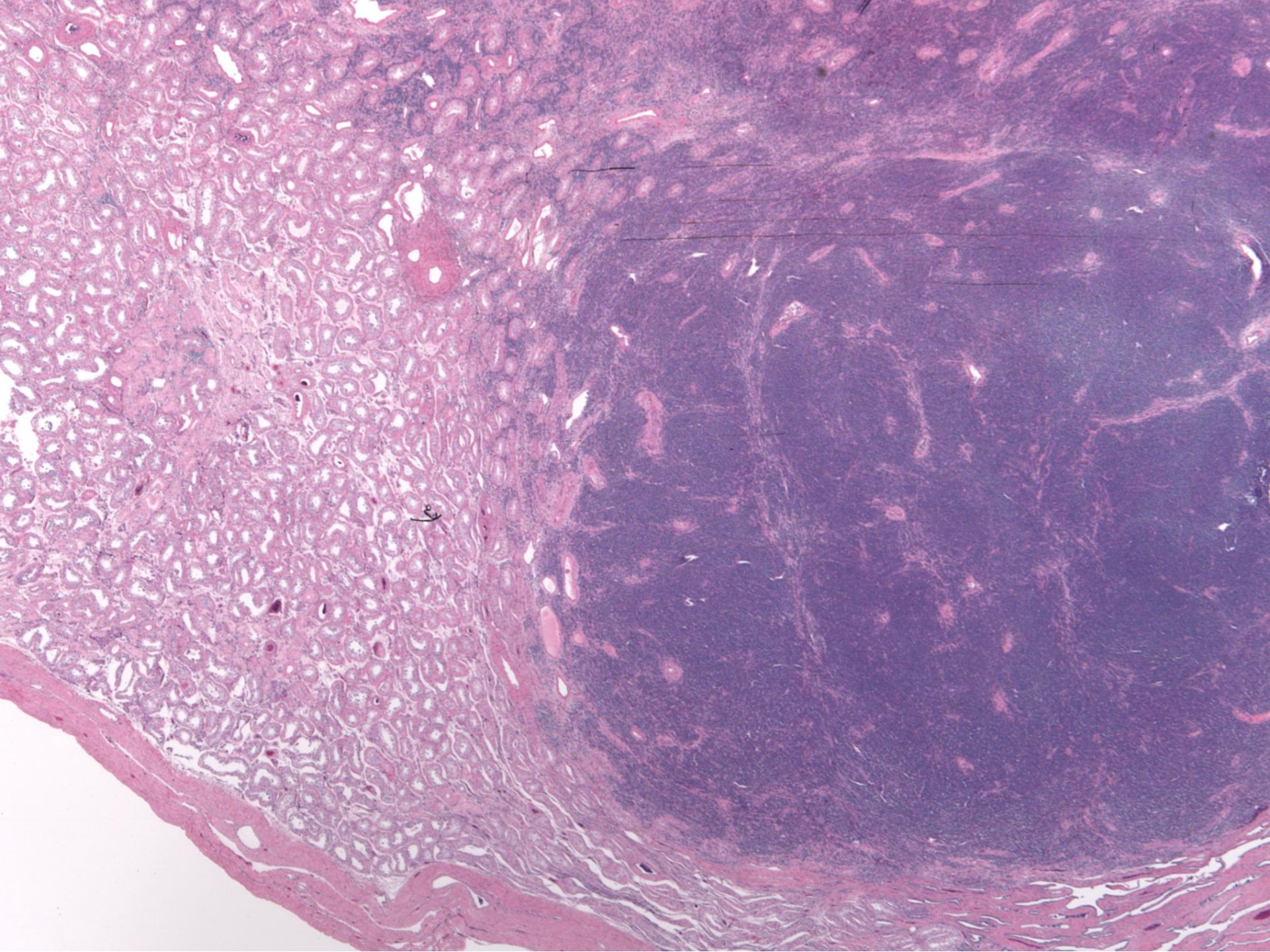


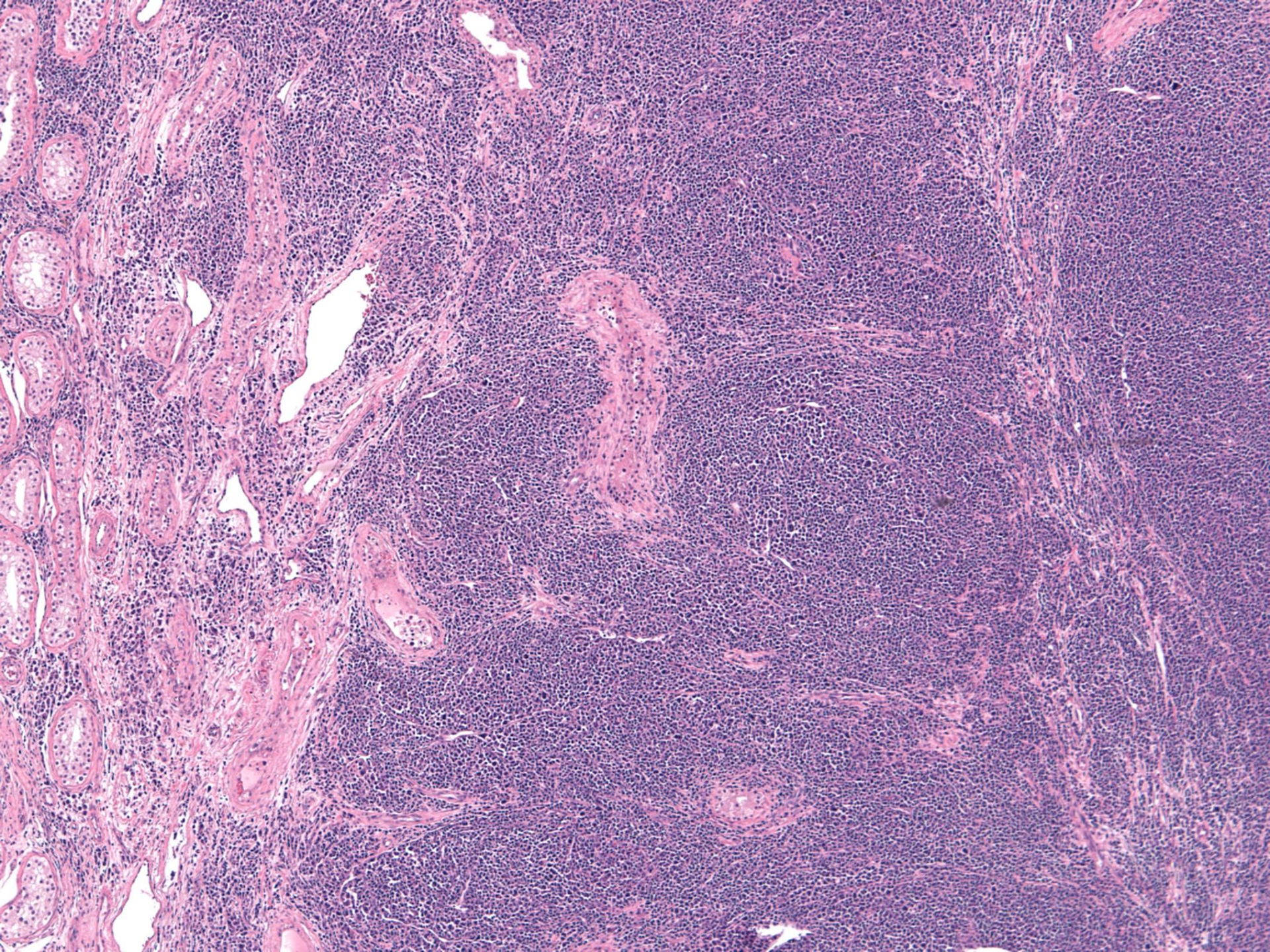


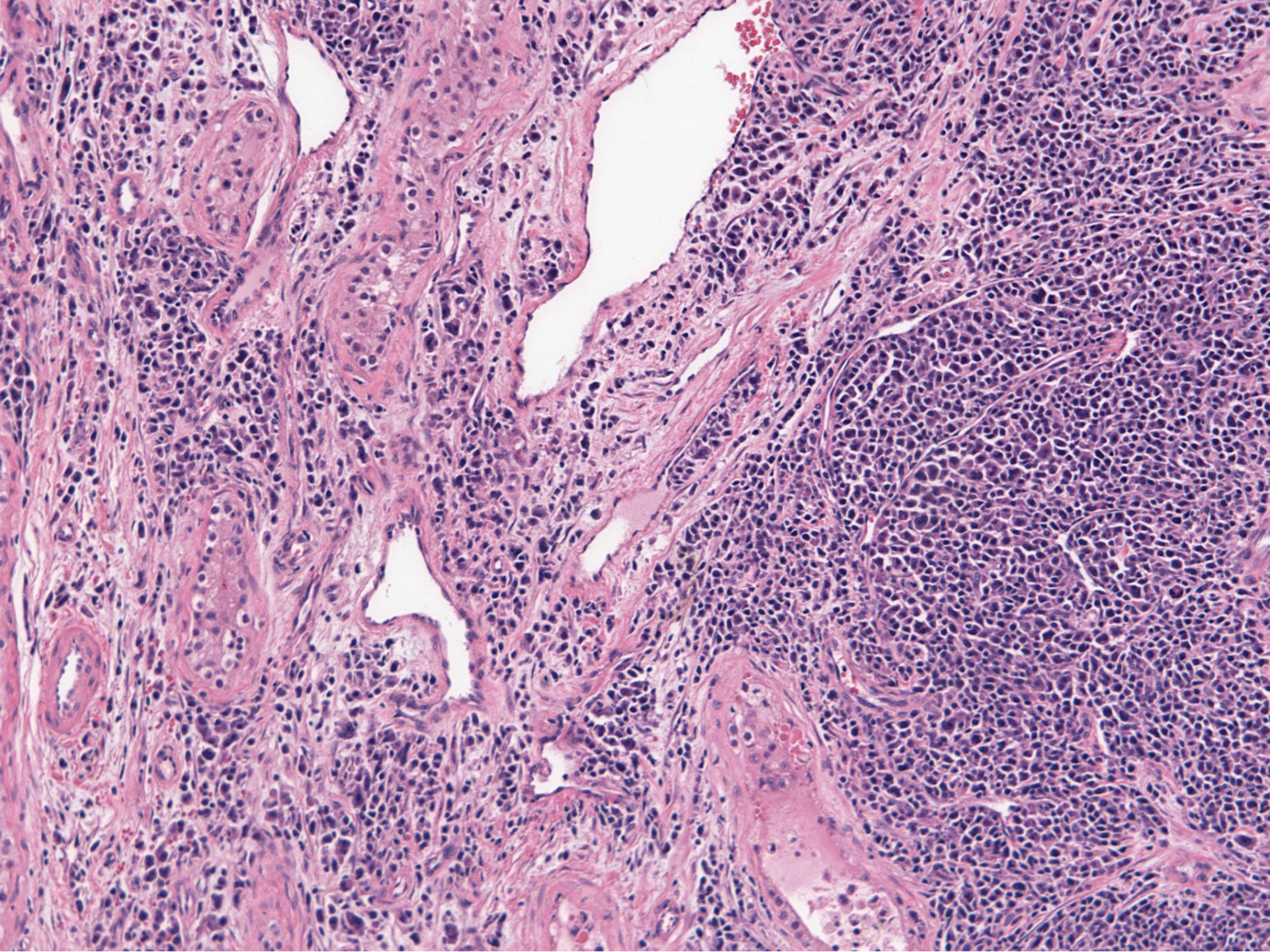
SB 5808

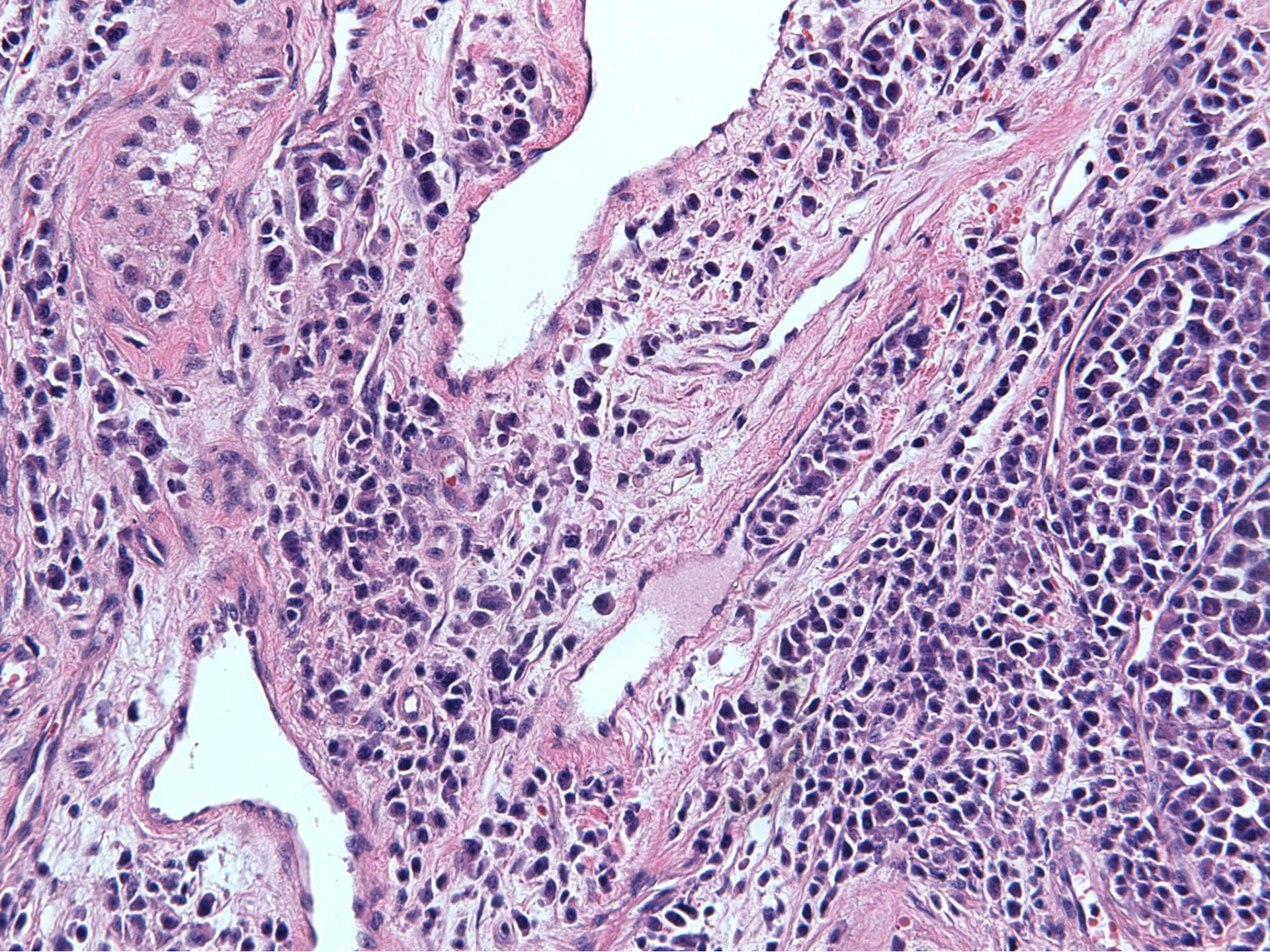
52-year-old man with a history of MGUS, now with worsening back pain and left testicular mass.

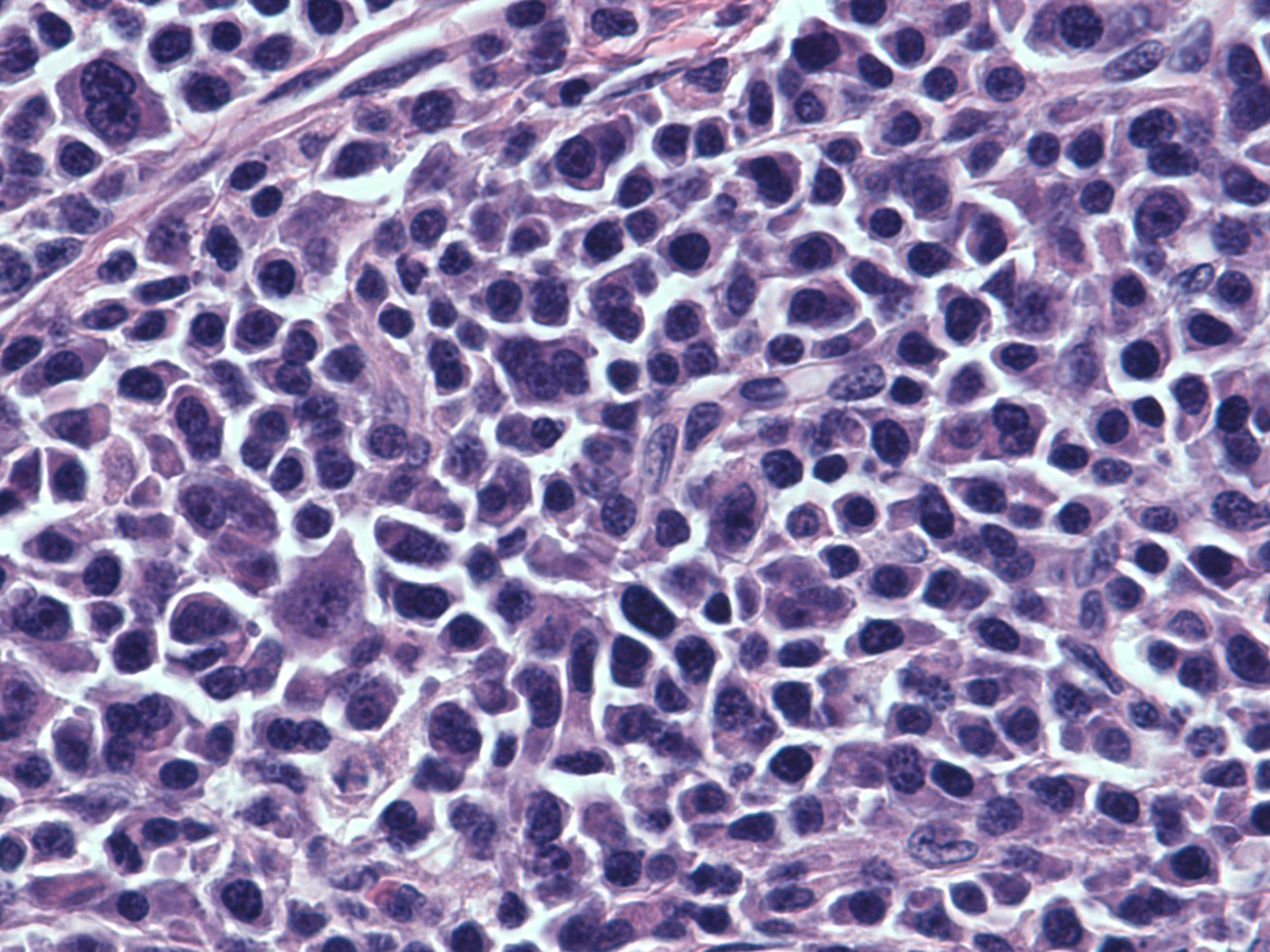






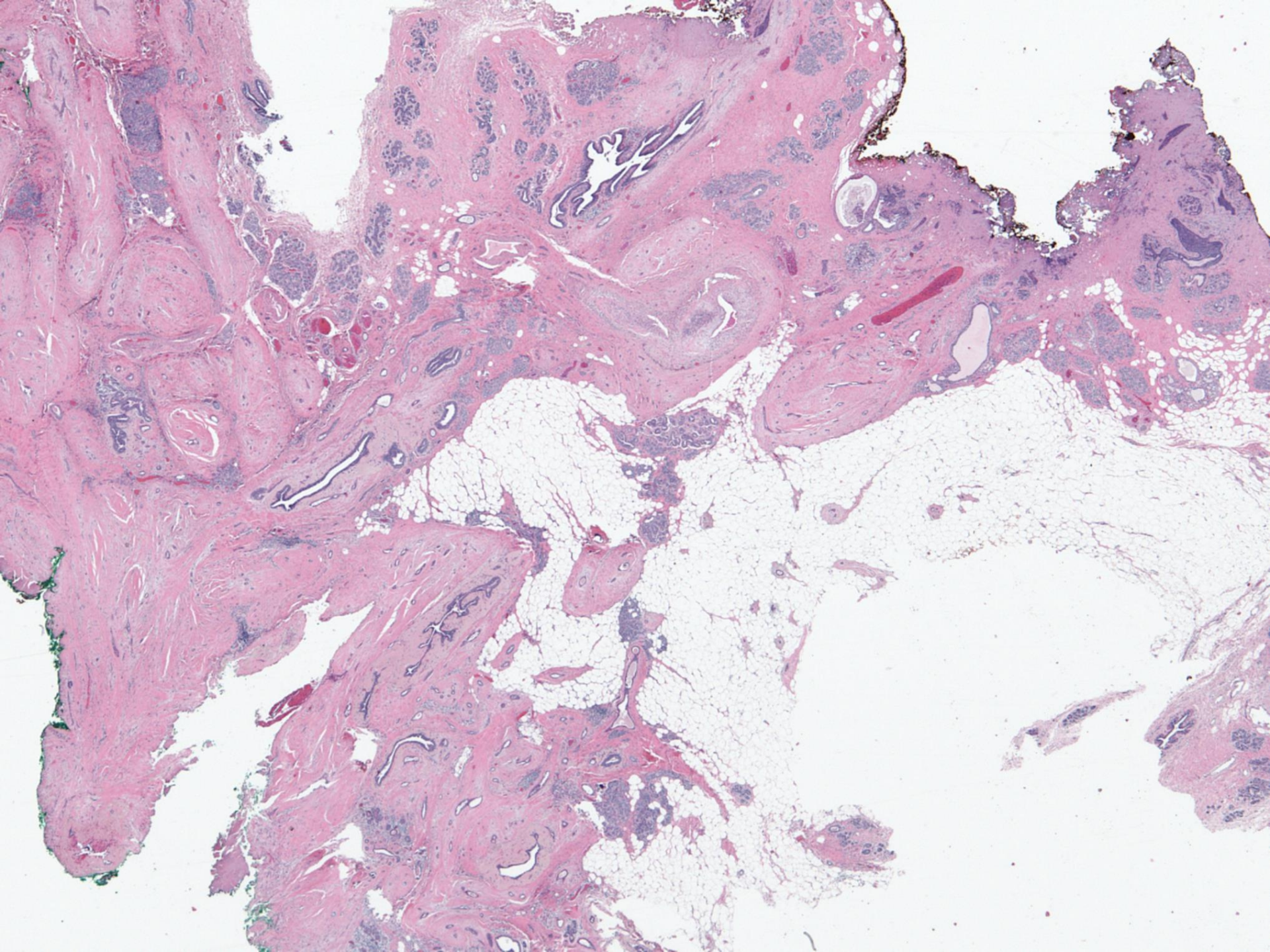


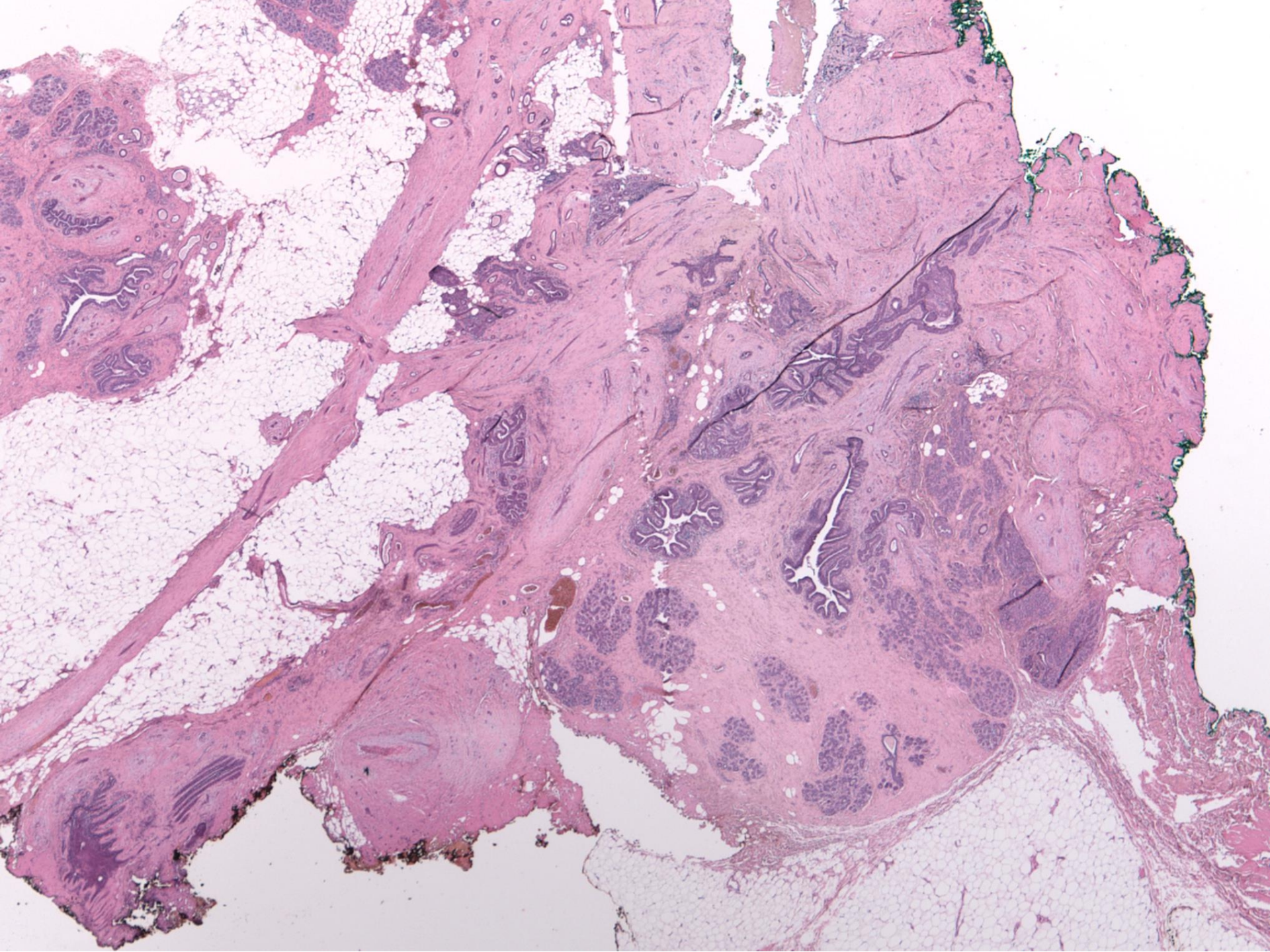


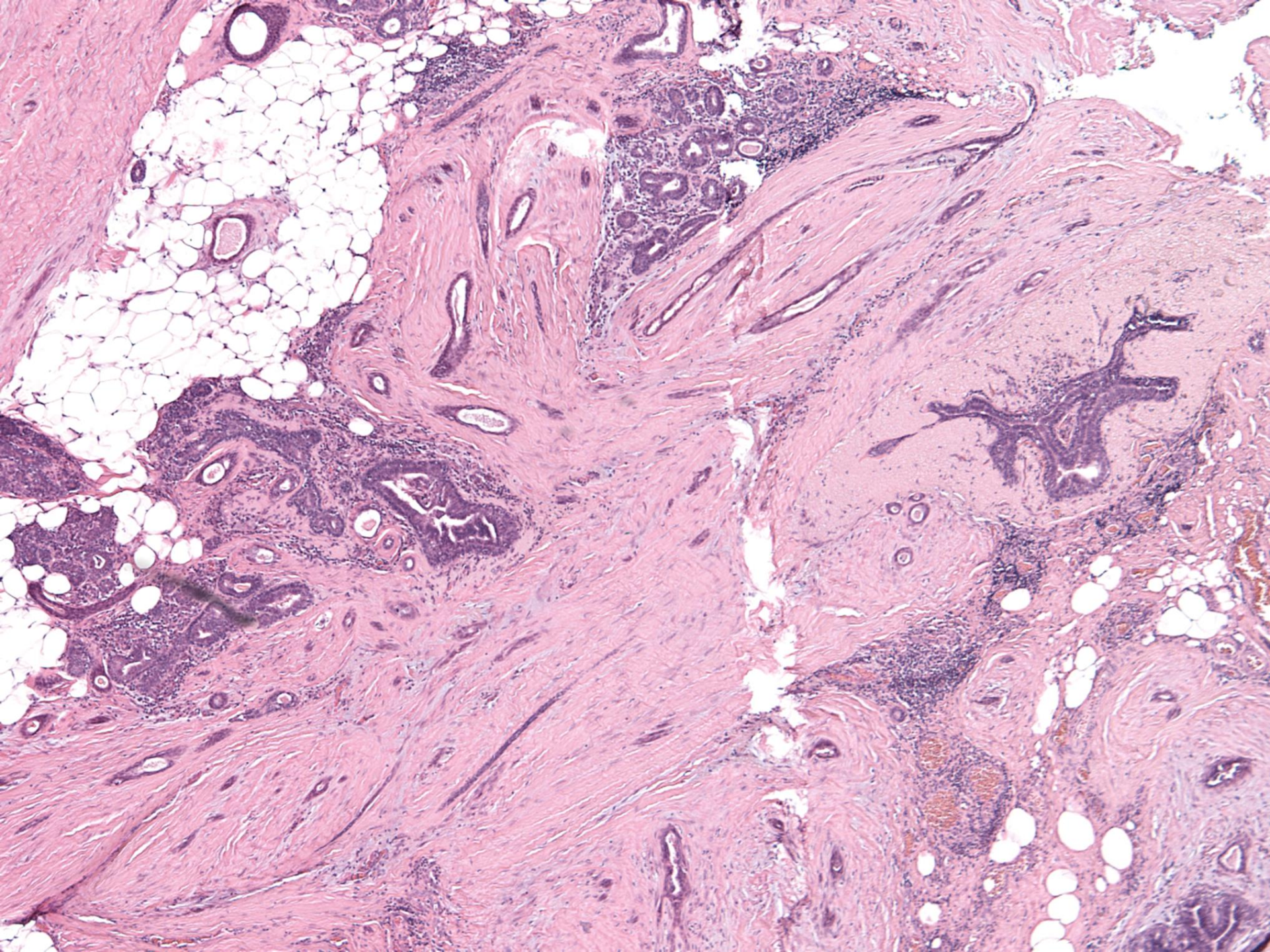


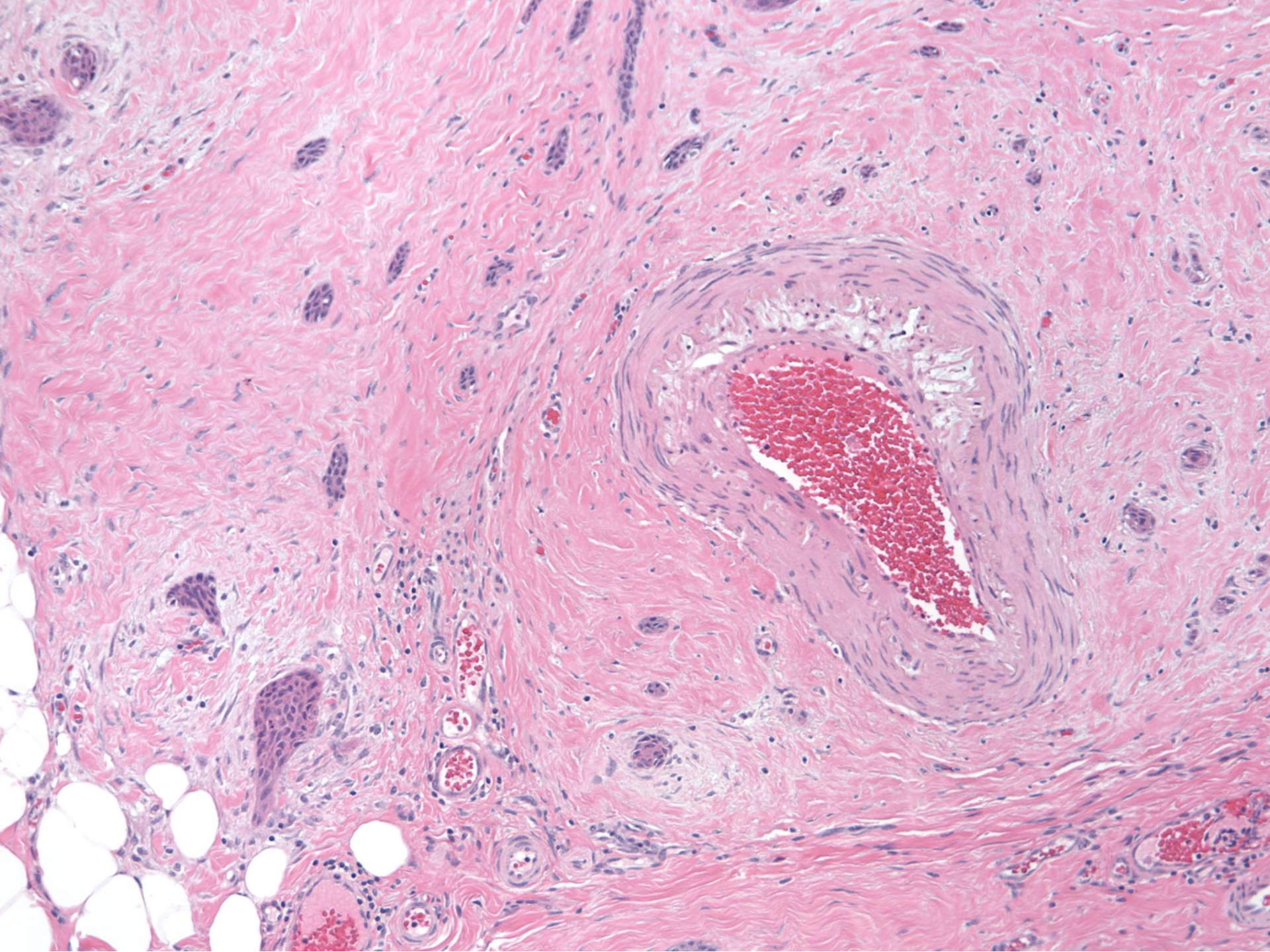
SB 5809

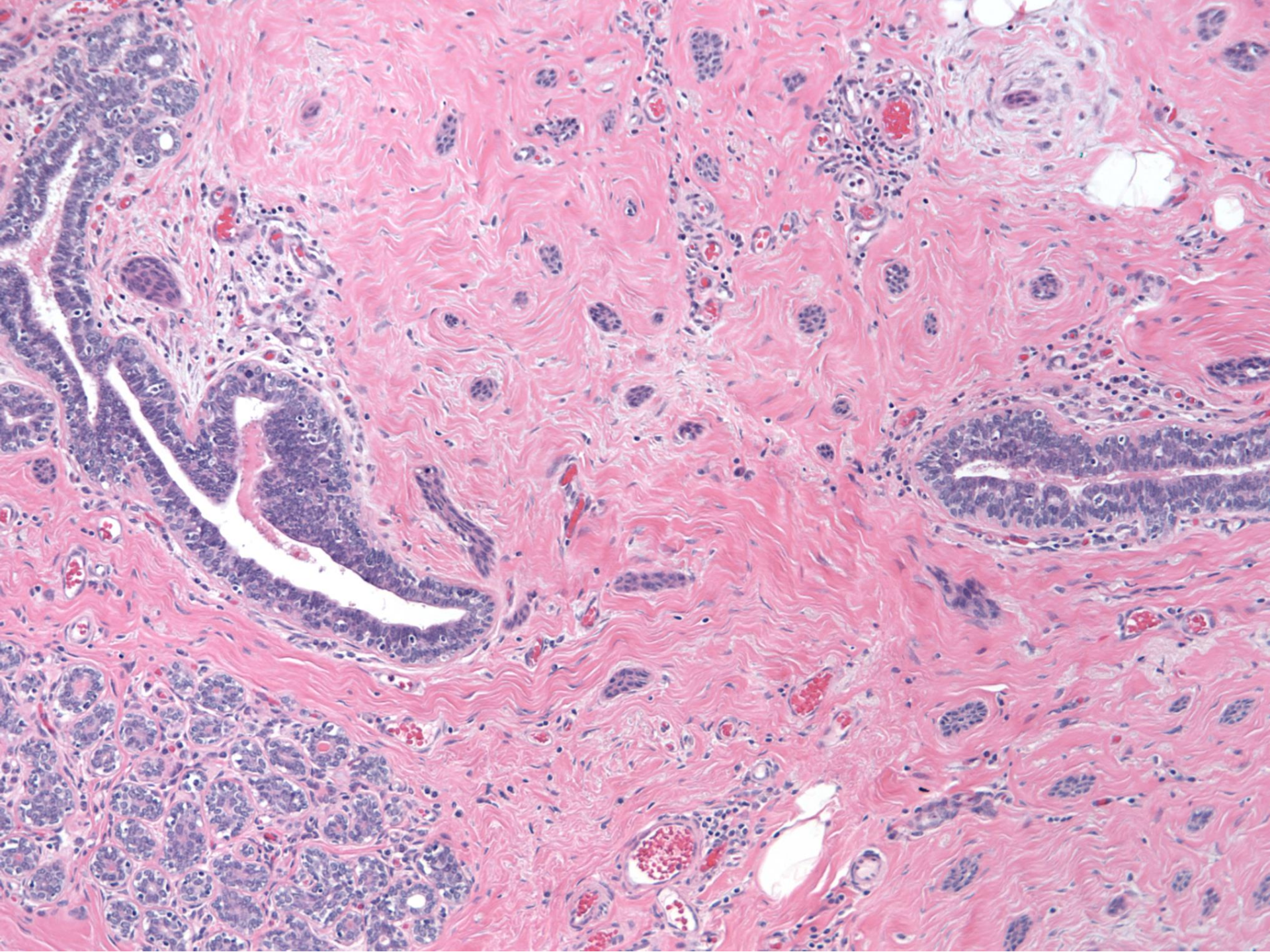
39-year-old female with left breast
retroareolar mass excision.

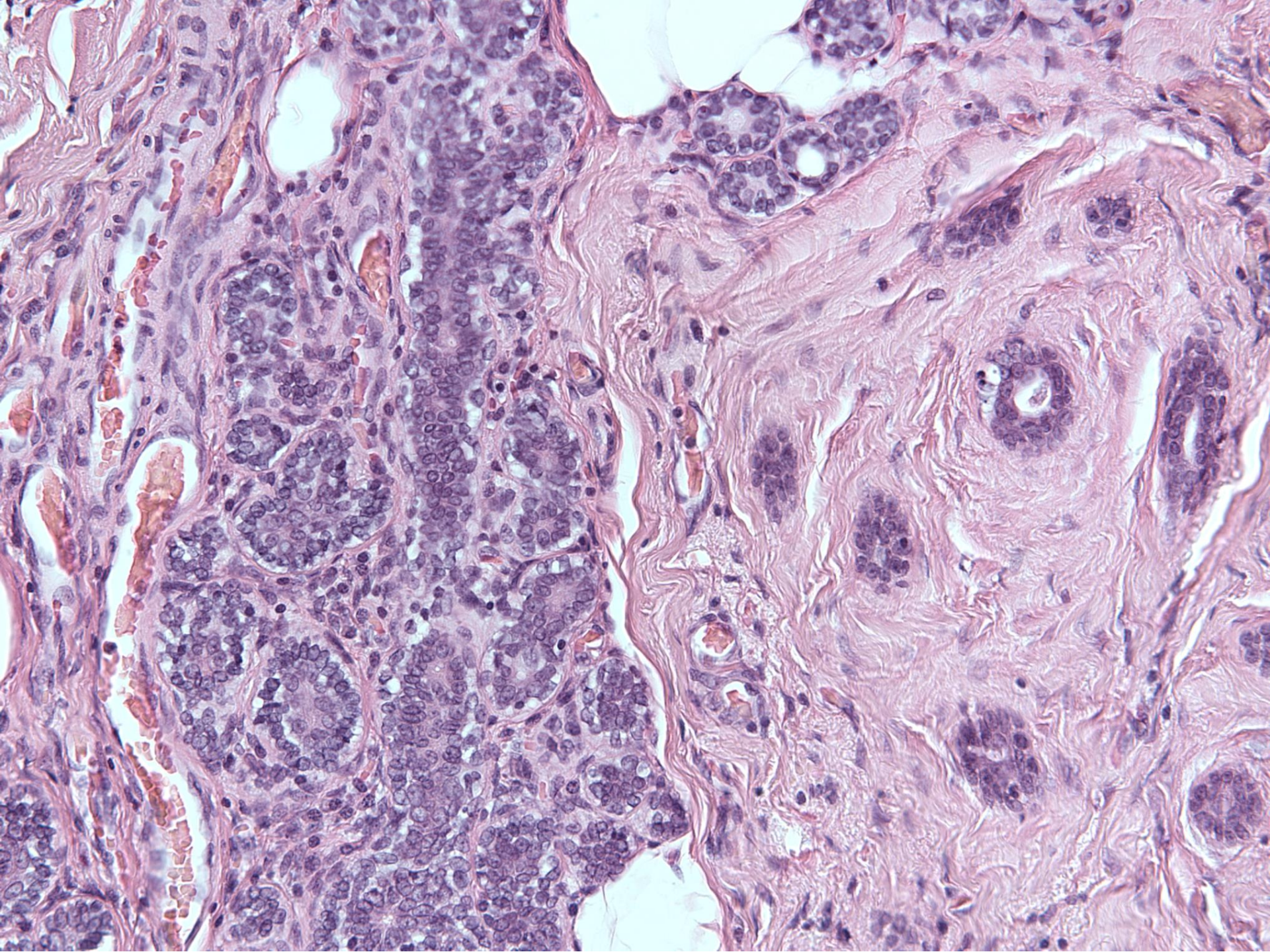


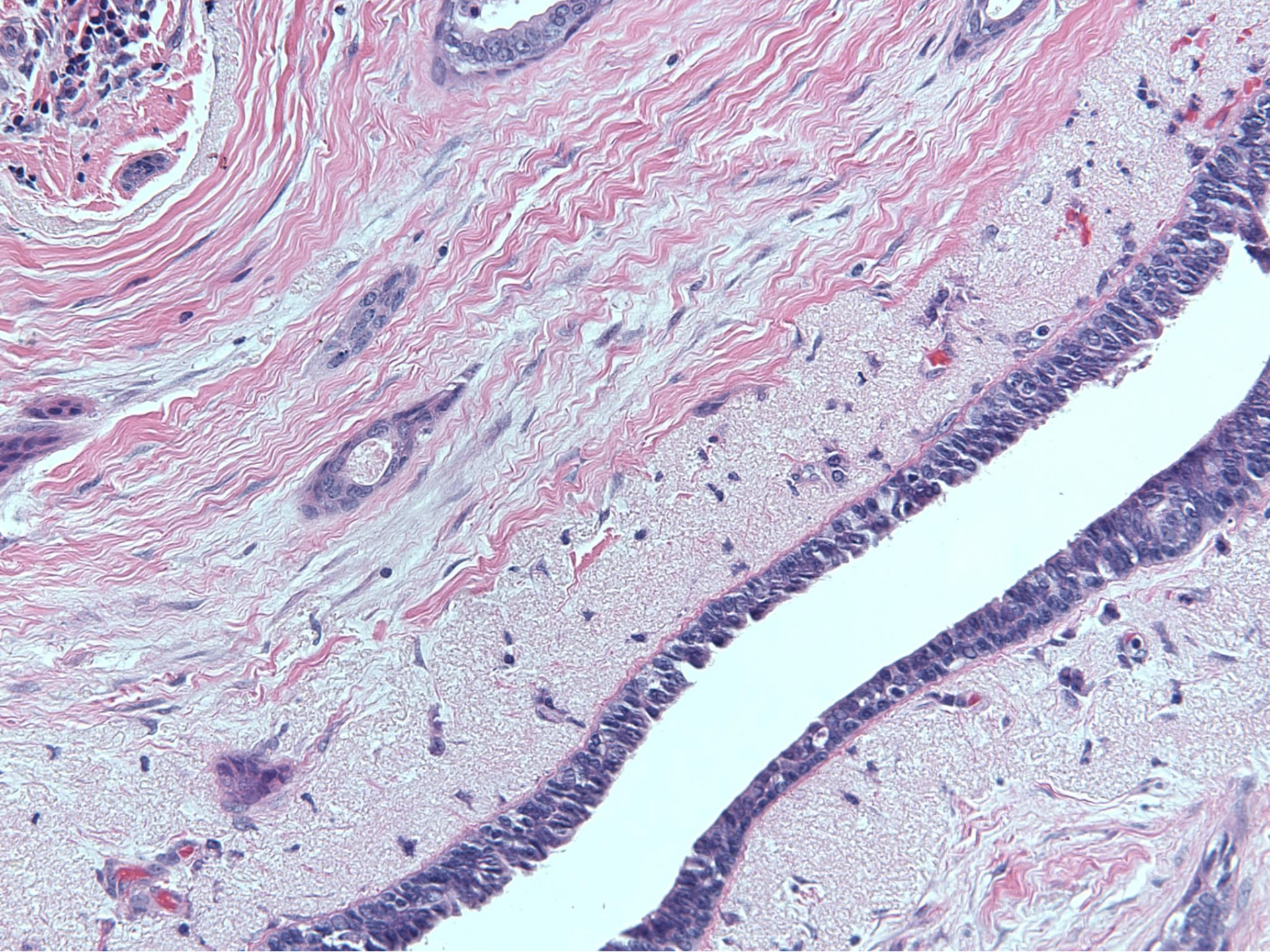


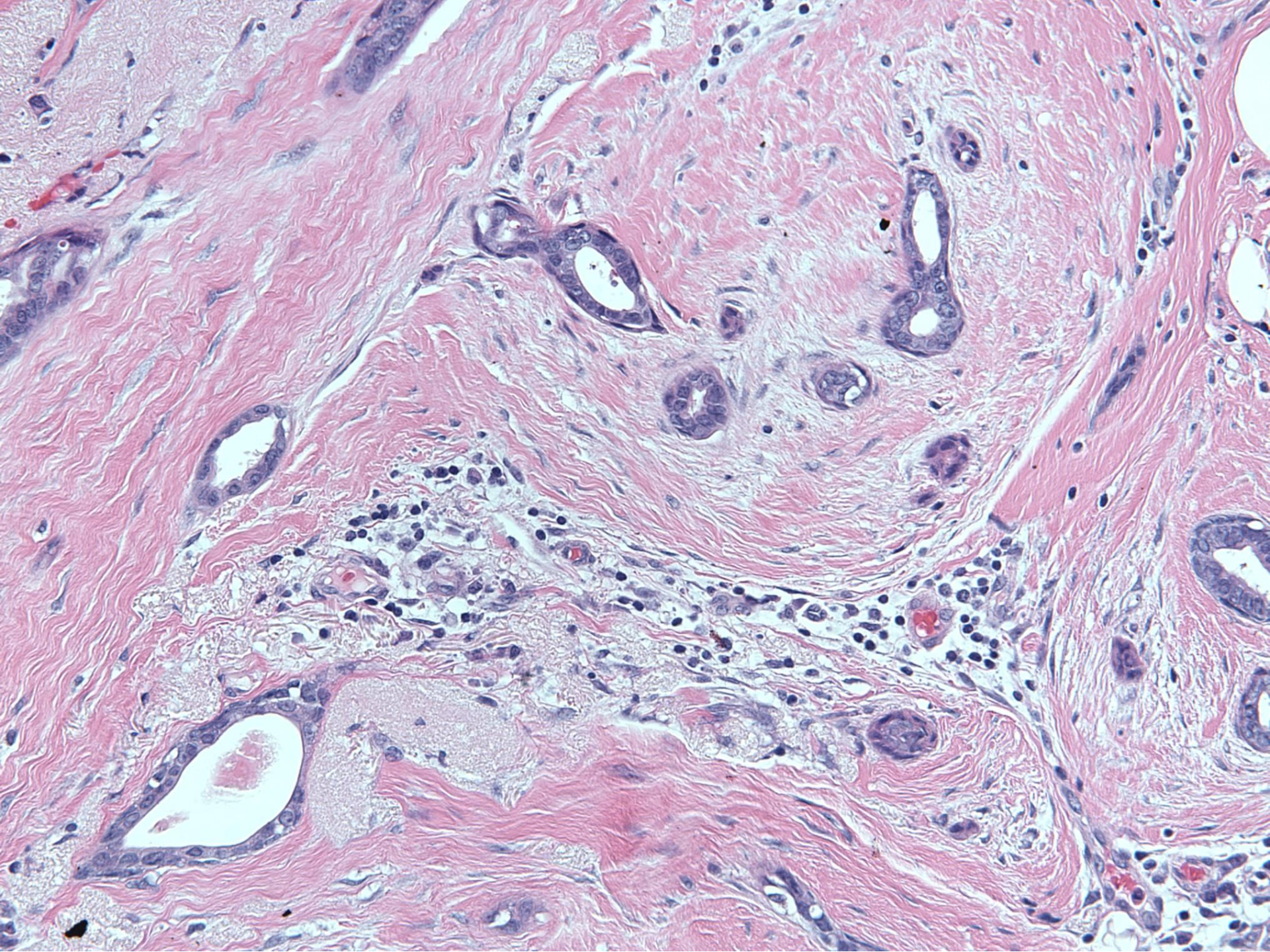


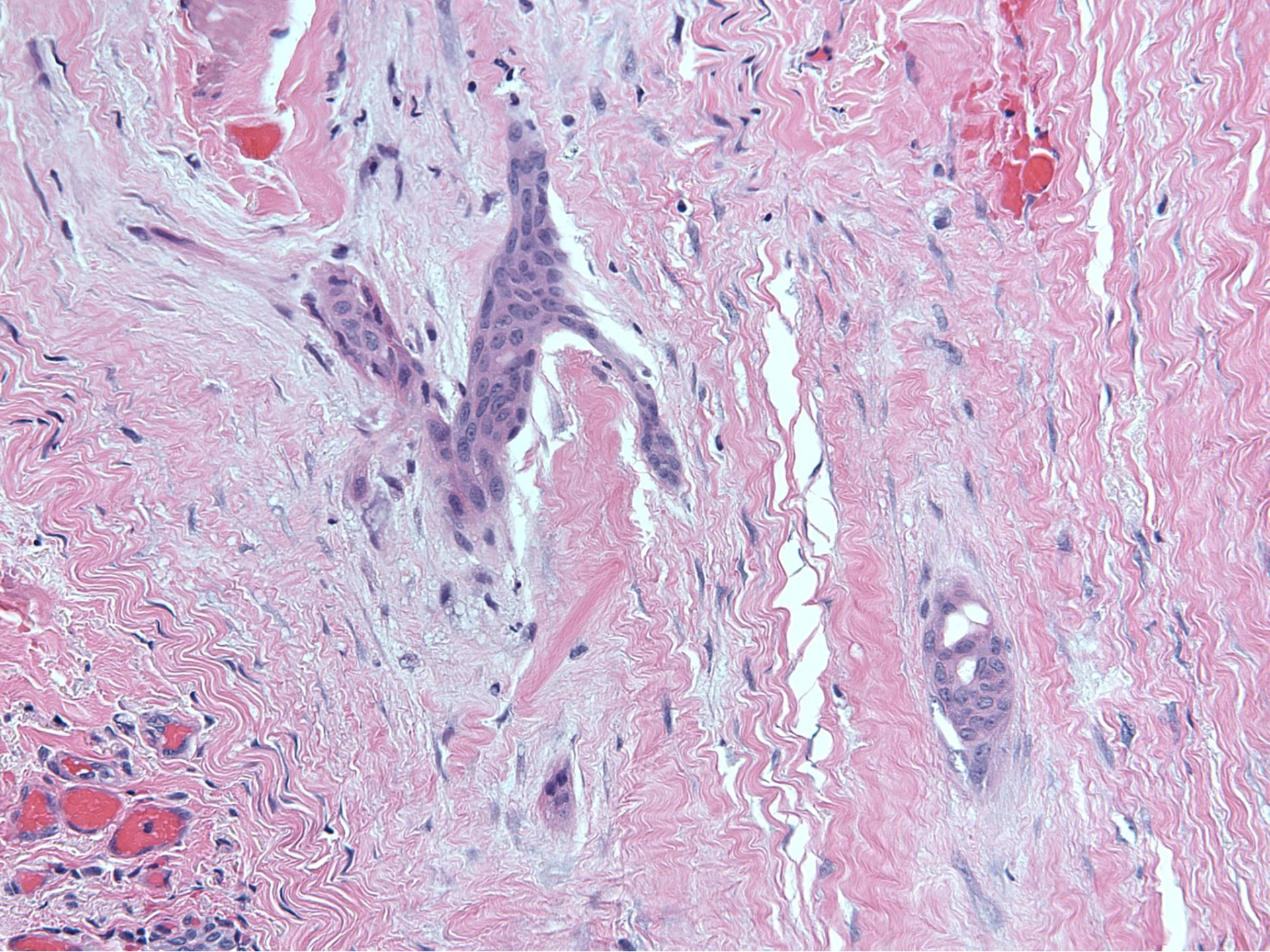












SB 5810

43-year-old female with history of
cosmetic surgery, now with lip
excision.

