

## **NOV 2020 DIAGNOSIS LIST**

20-1101: amyloid (type TBD) [kidney; non-neoplastic]

20-1102: adrenal cortical adenoma with necrotizing vasculitis [adrenal gland/endocrine pathology]

20-1103: diffuse large B-cell lymphoma [heart; hematopathology]

20-1104: oncocytic papillary cystadenoma with mucinous differentiation [salivary gland/H&N pathology]

20-1105: papillary meningioma [brain/neuropathology]

20-1106: stromogenic prostatic cancer [prostate/GU pathology]

20-1107: prostatic cancer 3+3 with IDC vs 3+4 [prostate/GU pathology]

# Disclosures

## November 2, 2020

The following planners and presenters had disclosures:

Ankur Sangoi: Google-consultant

South Bay Pathology Society has determined that these relationships are not relevant to the clinical cases being presented. The presentation slides have been reviewed for potential bias and found to contain none.

The following planners and faculty had no financial relationships with commercial interests to disclose:

**Presenters:**

Emily Ryan, MD

Greg Rumore, MD

Hannes Vogel, MD

Angus Toland, MD

Dean Fong, MD

**Activity Planners/Moderator:**

Kristin Jensen, MD

Megan Troxell, MD

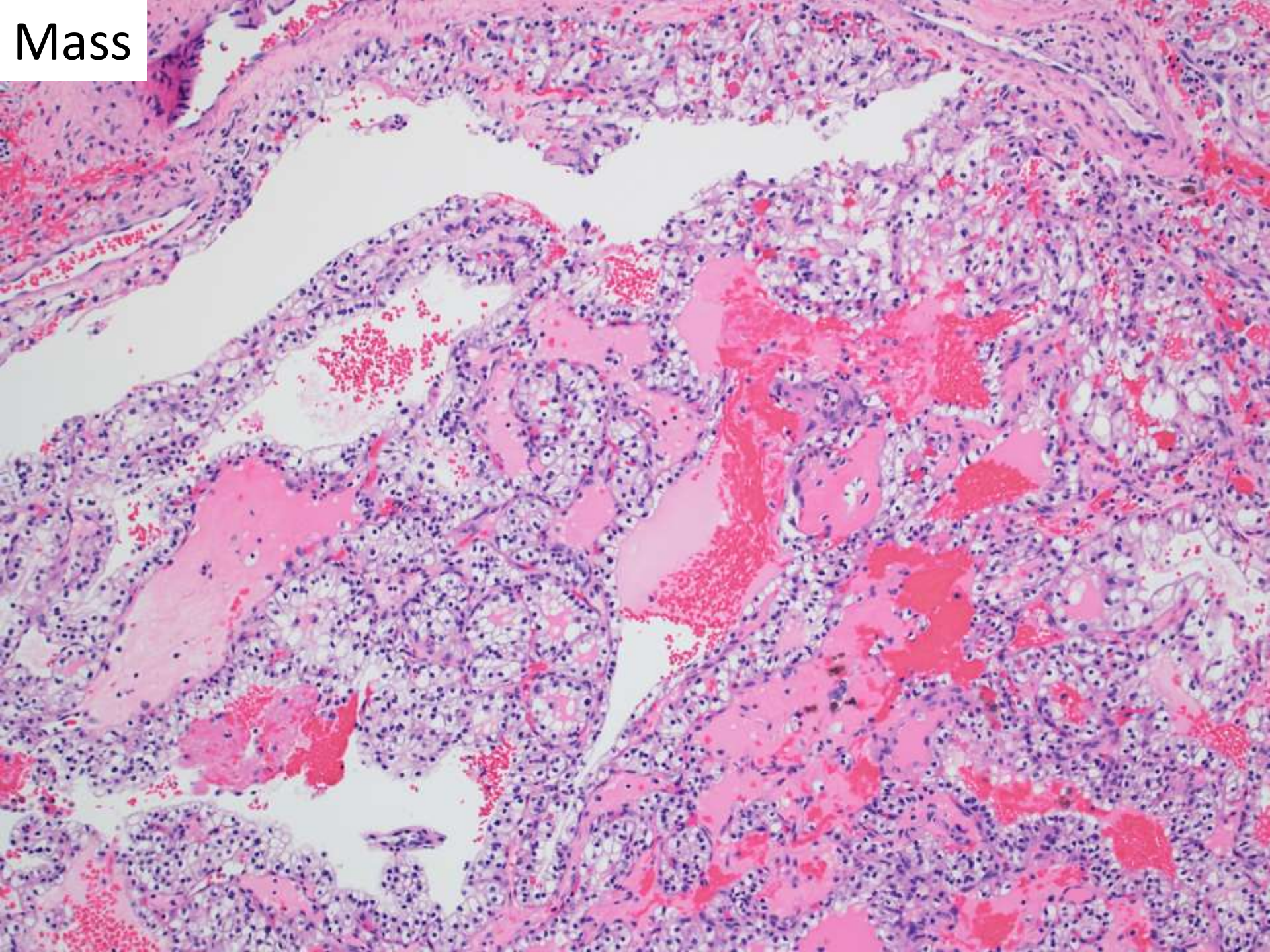
# 20-1101

Megan Troxell; Stanford

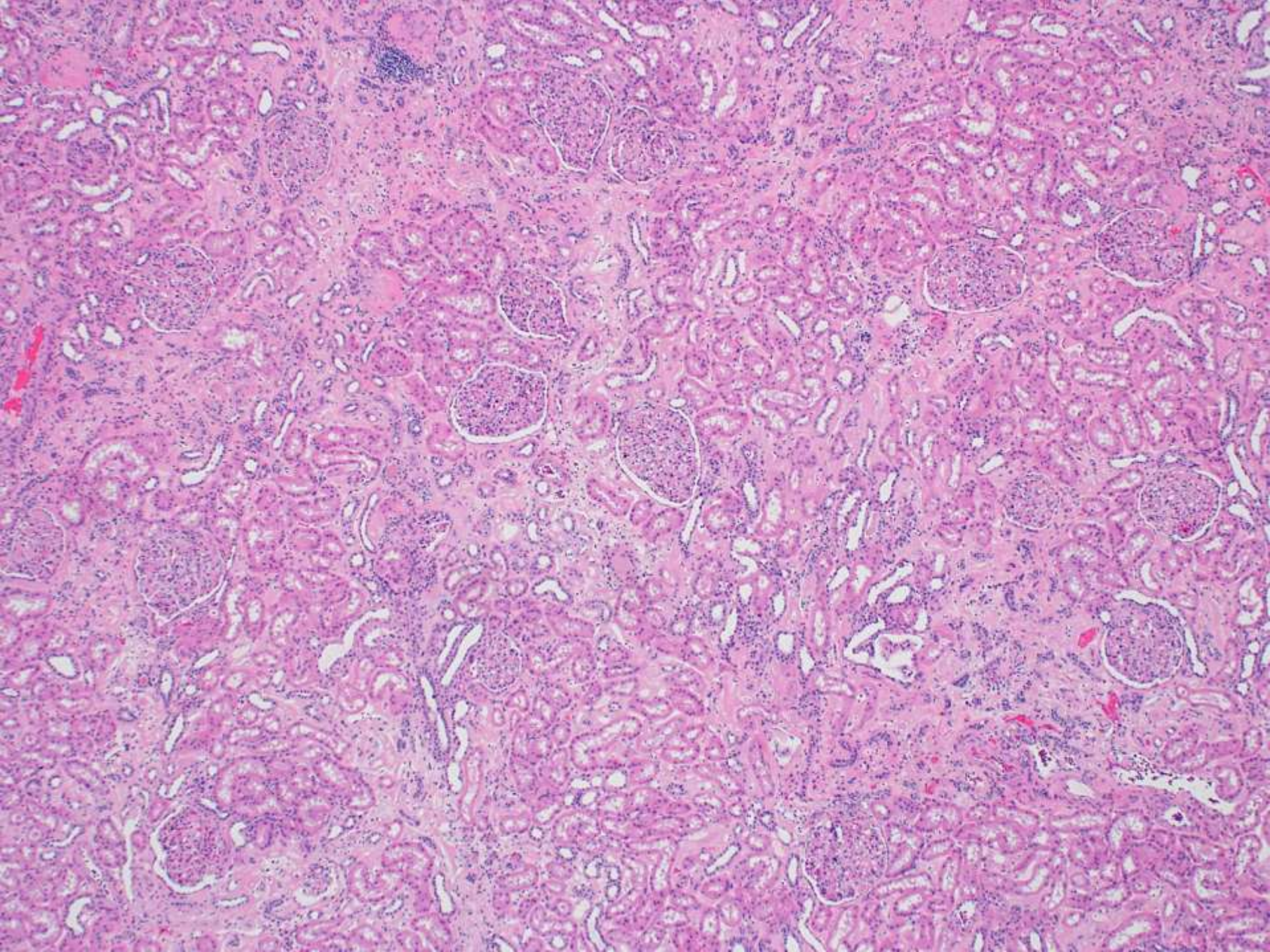
72-year-old with 3-4cm kidney mass, incidentally discovered on imaging. Partial nephrectomy.



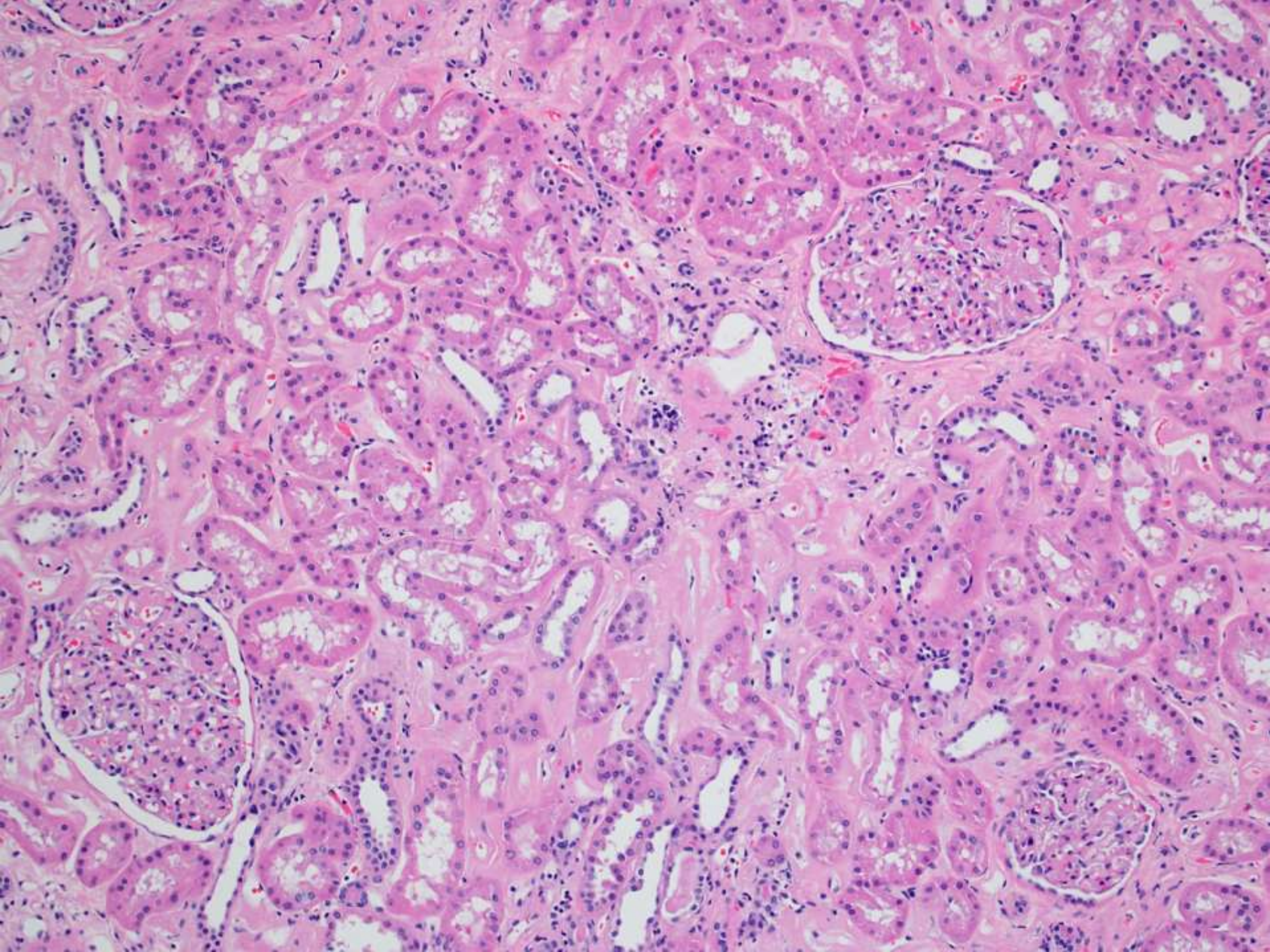
Mass



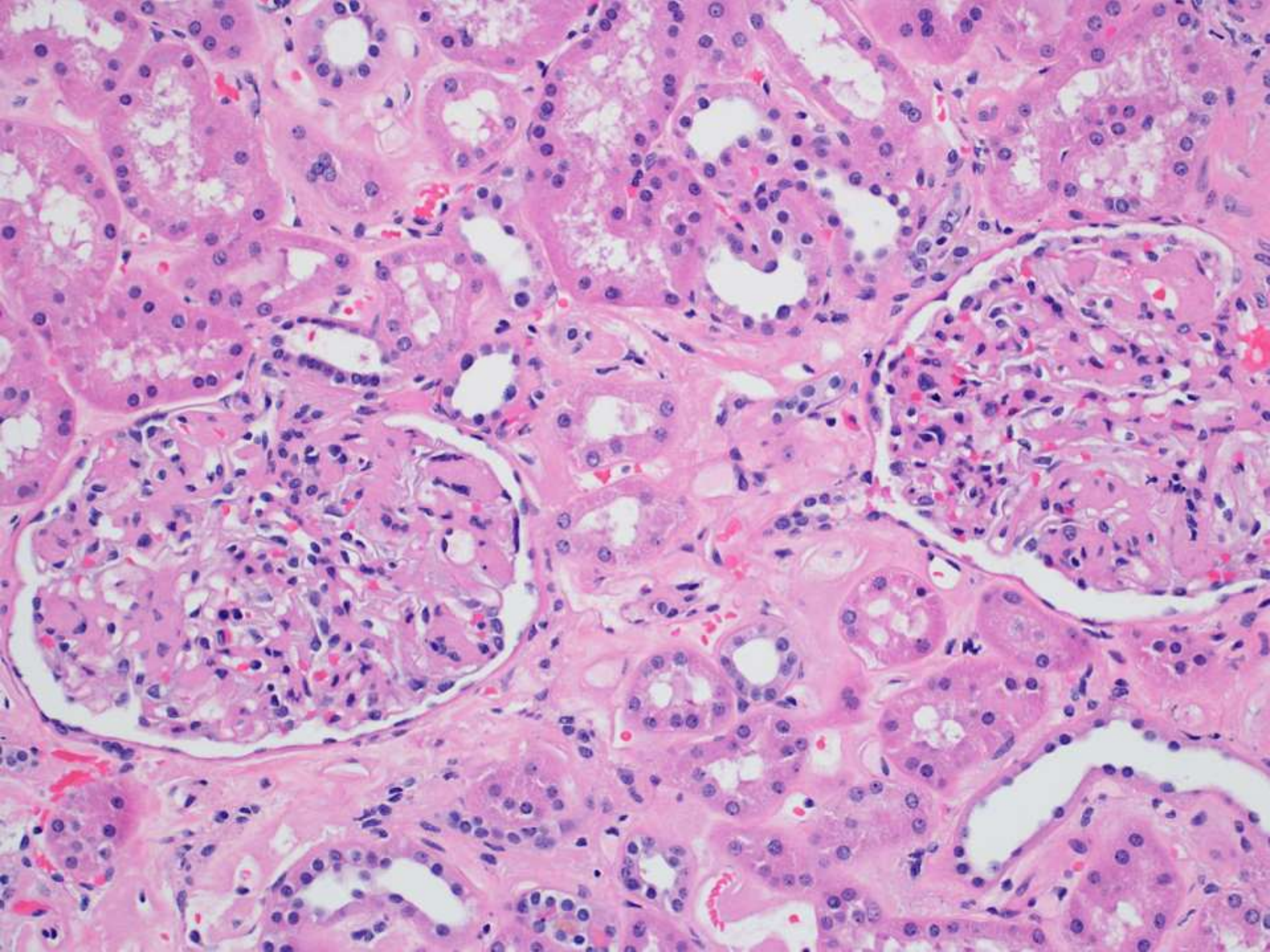




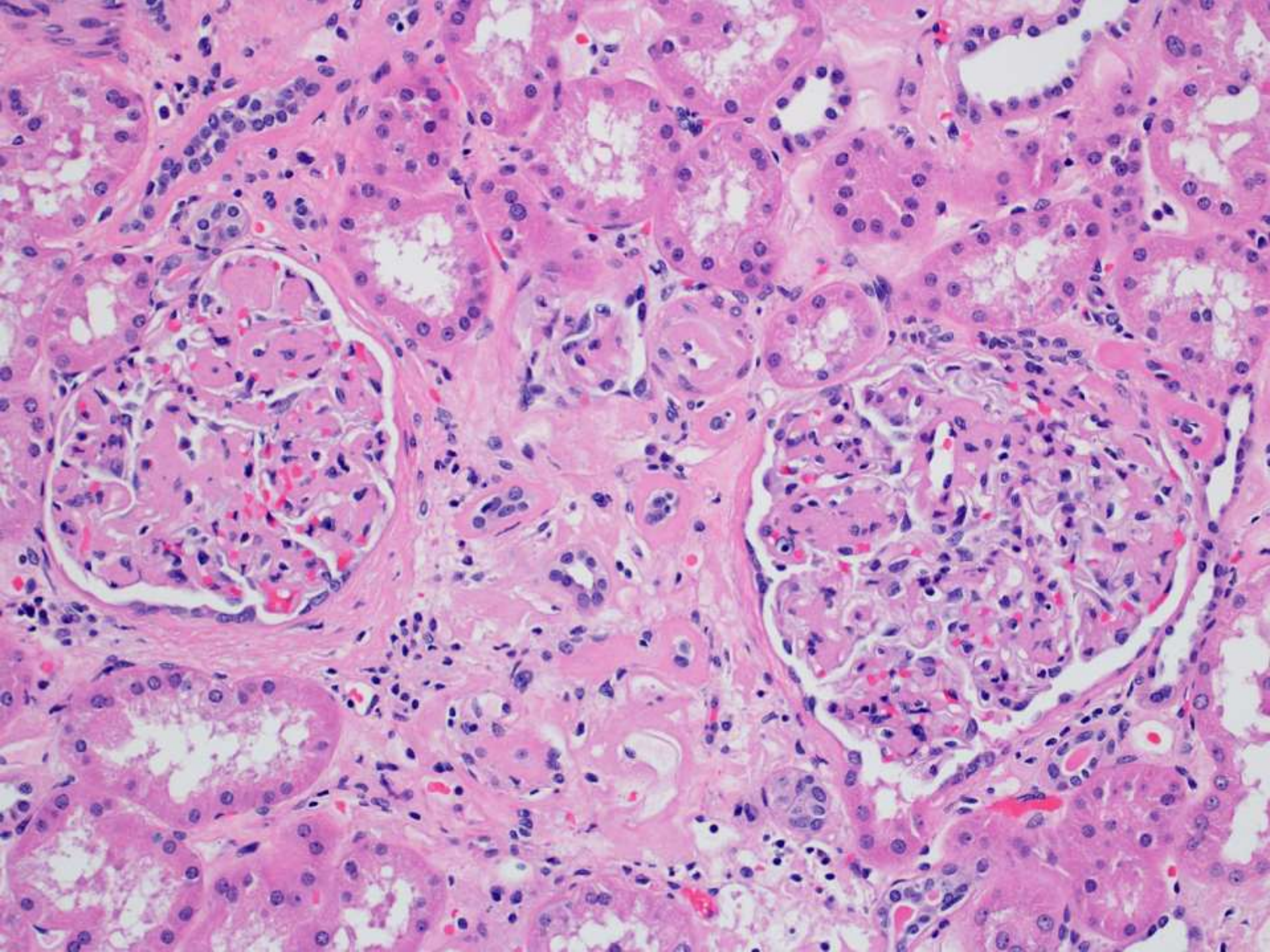




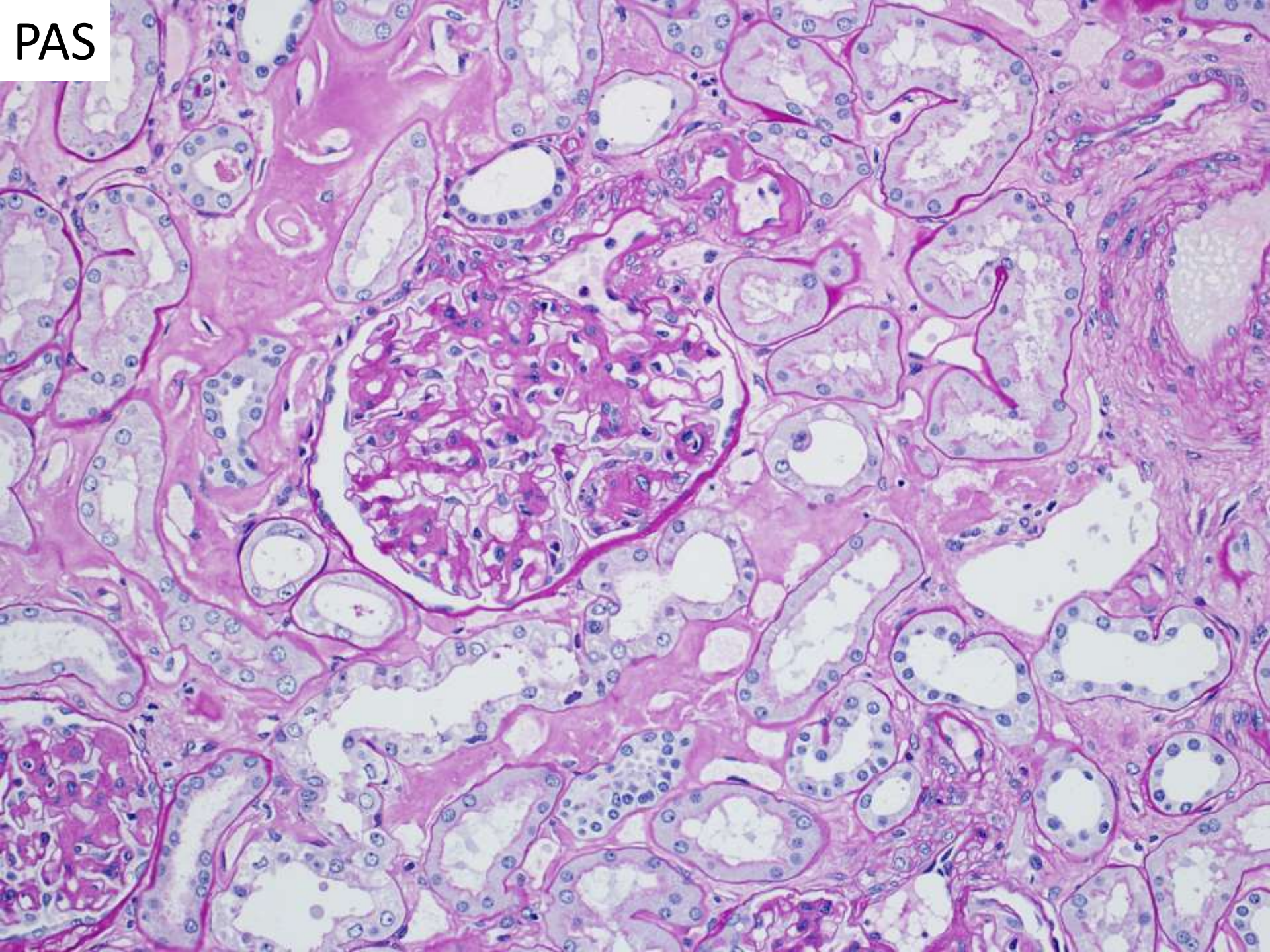






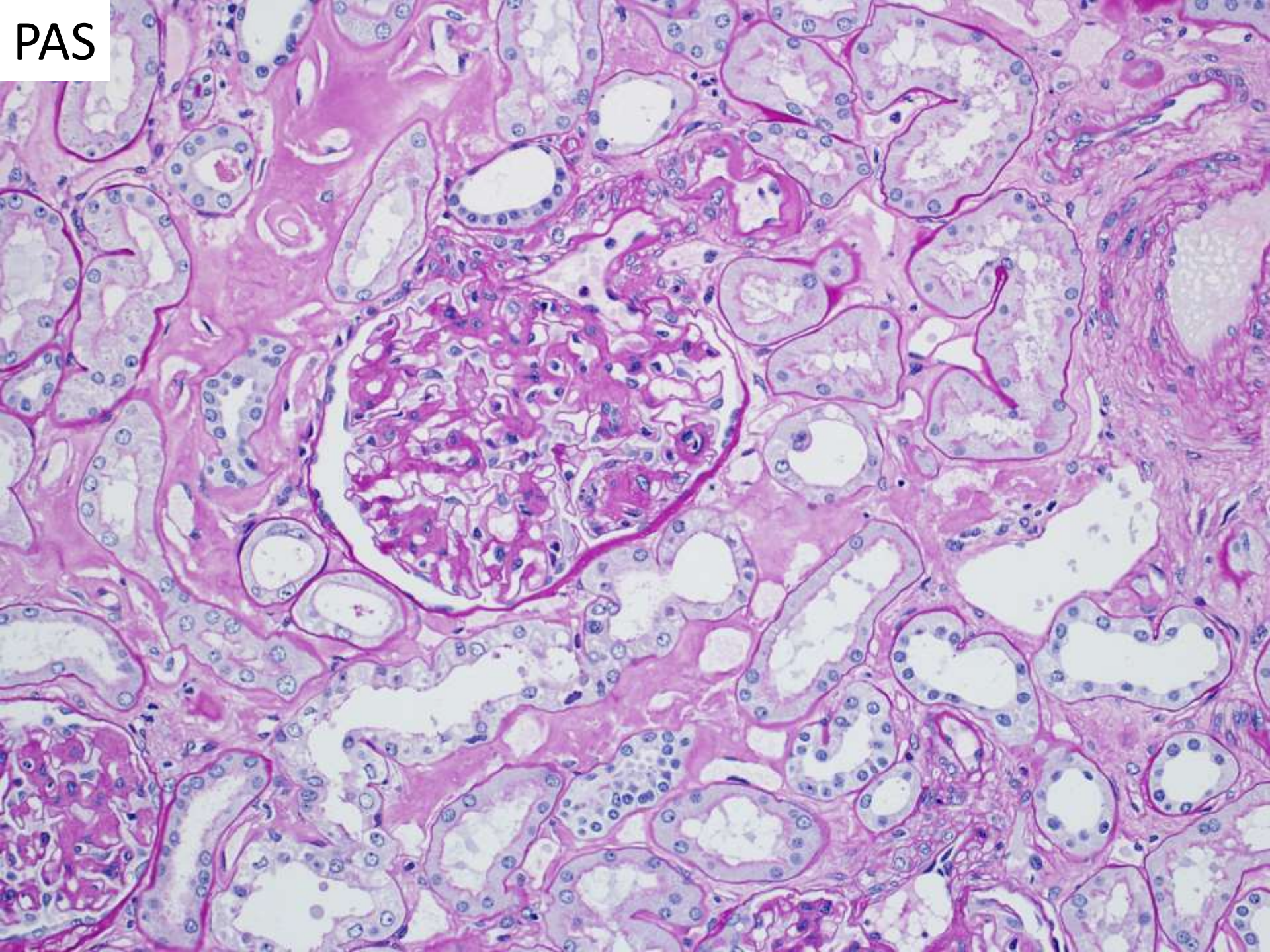






PAS

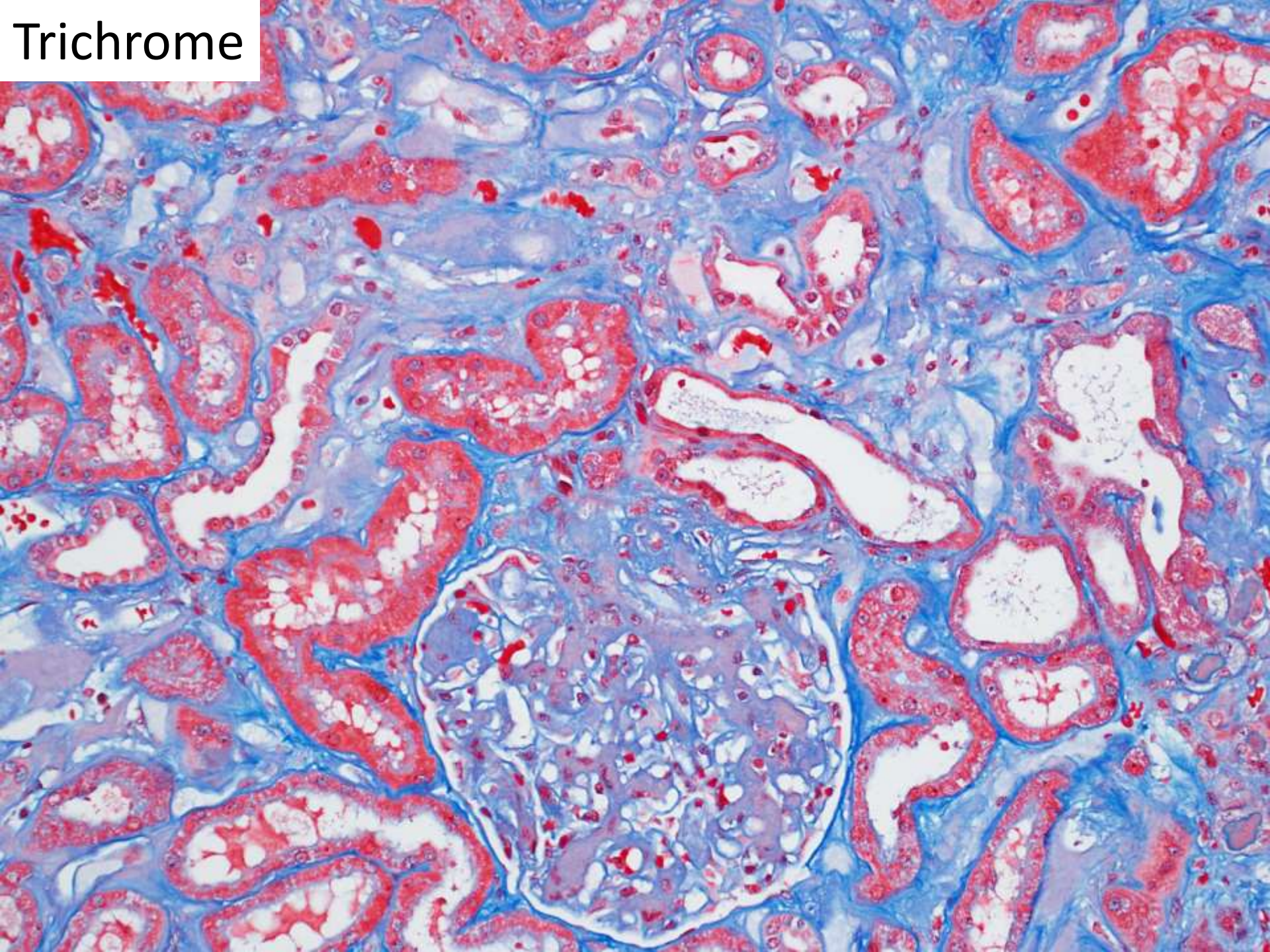




PAS

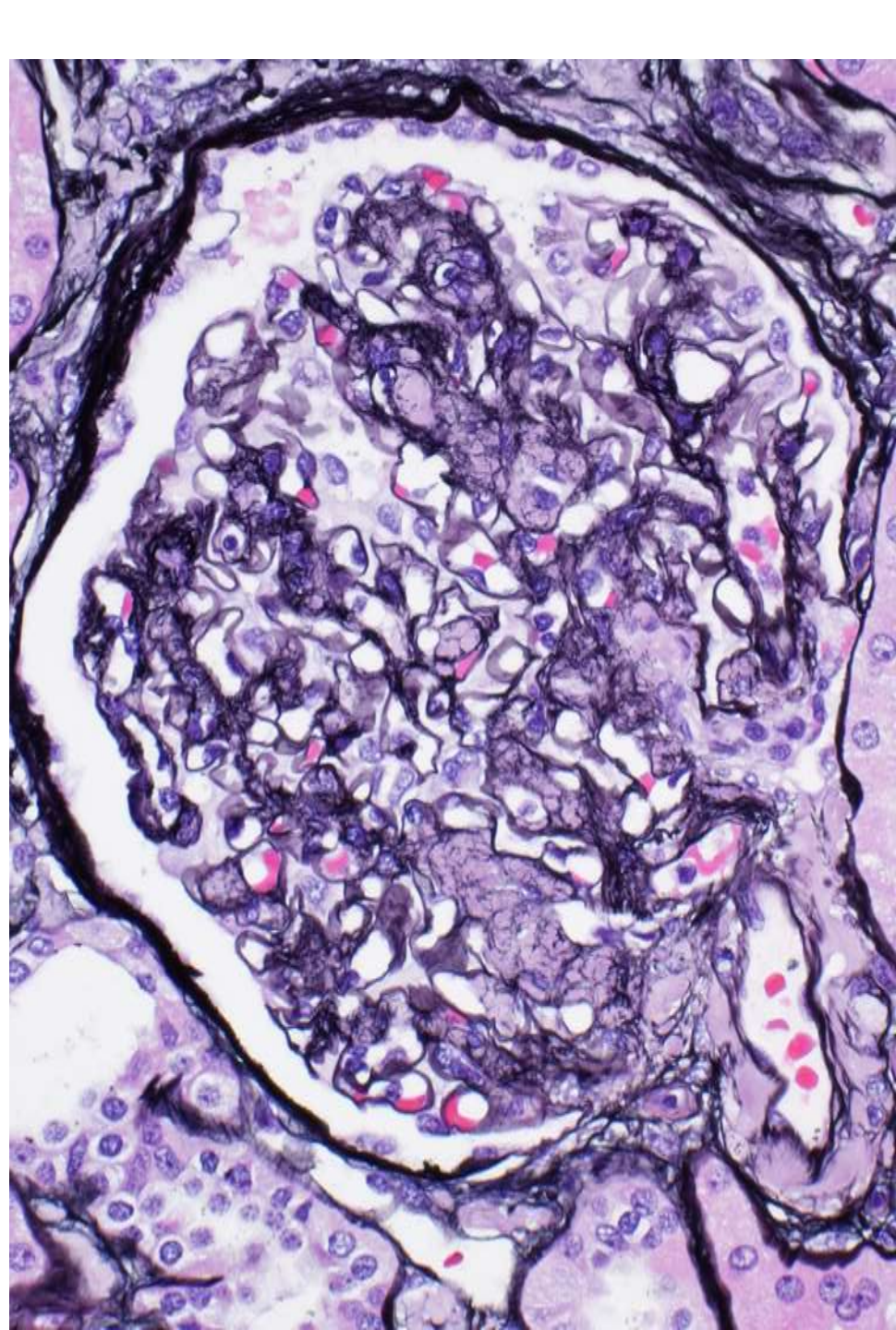
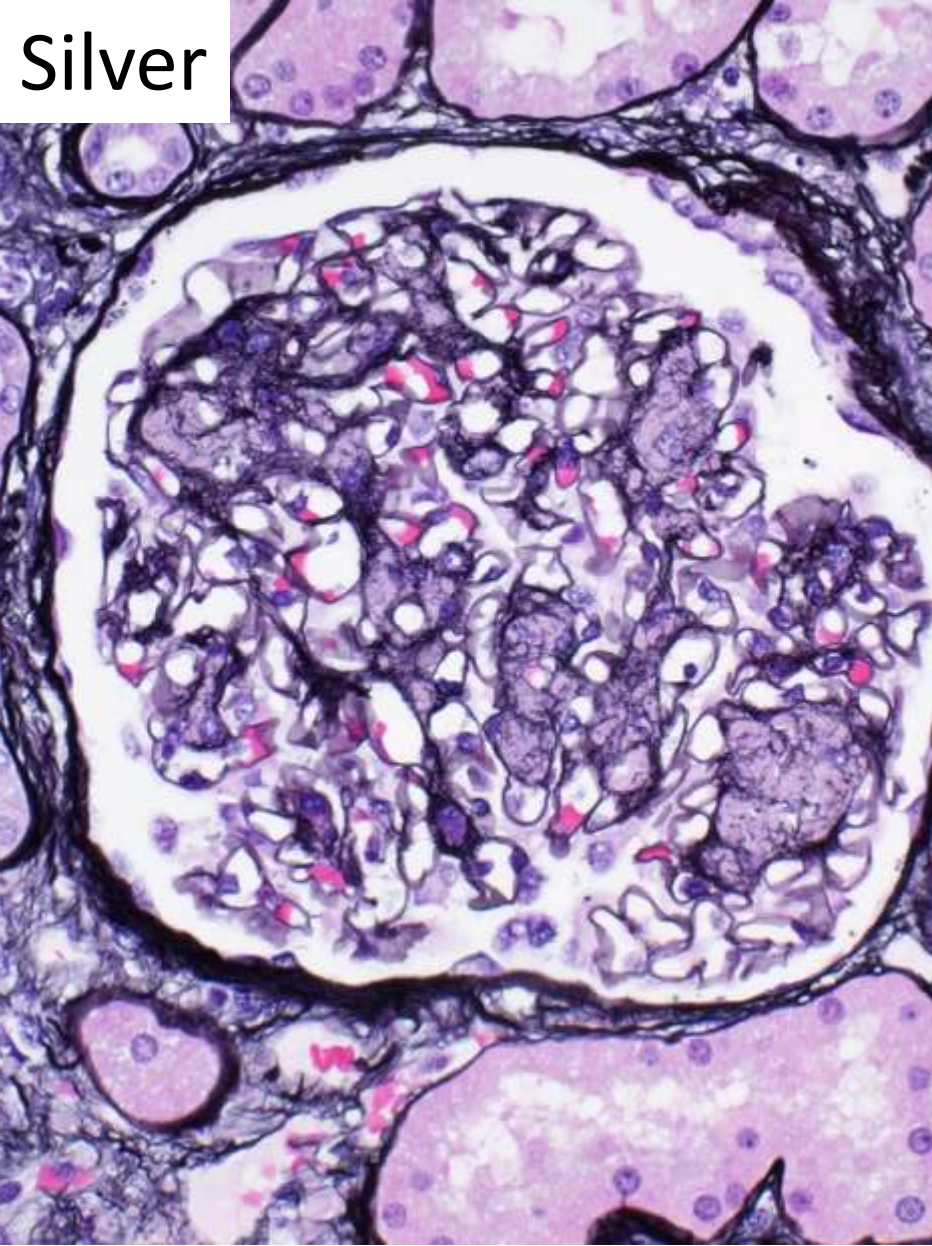


Trichrome



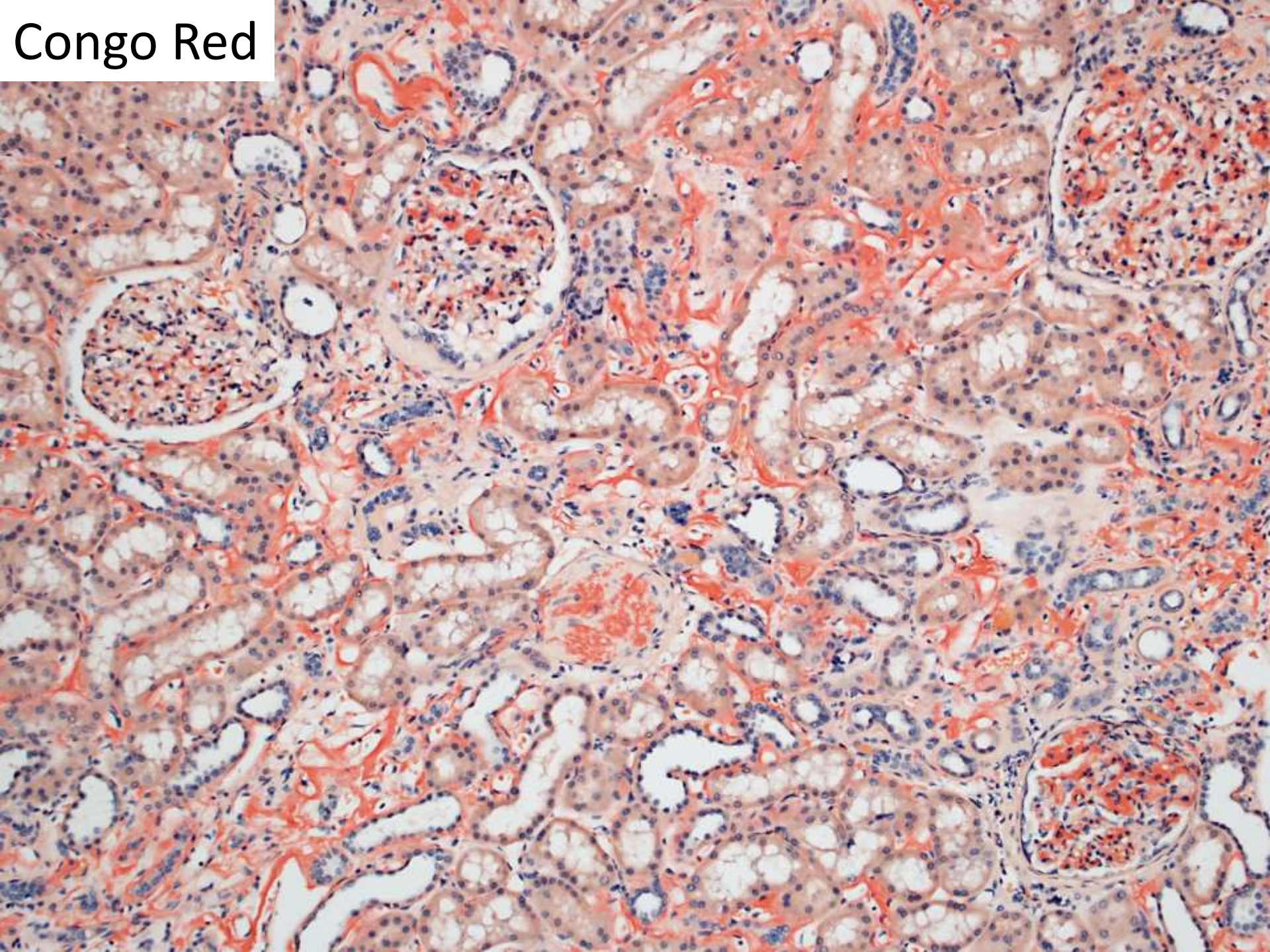


Silver



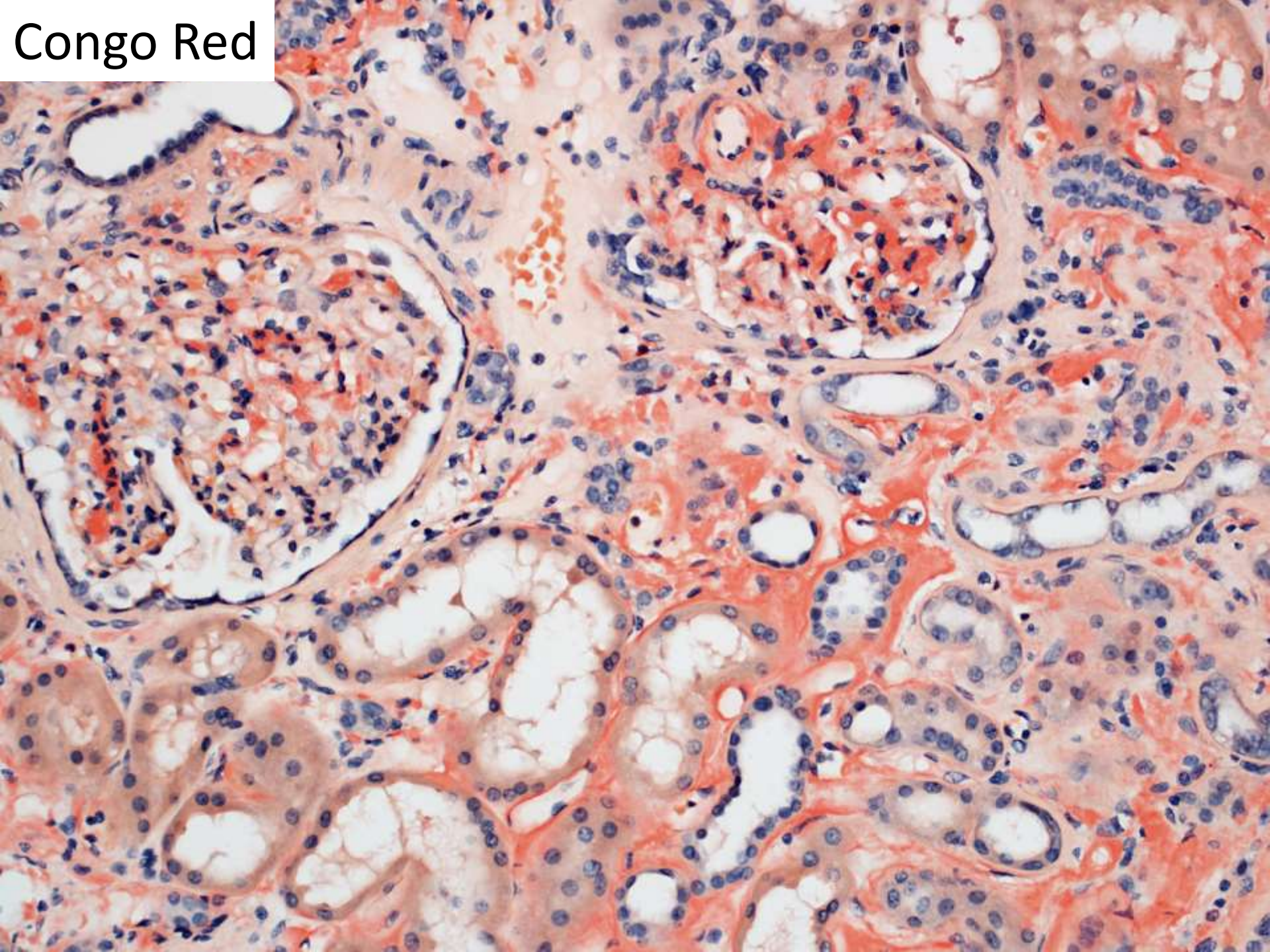


Congo Red





Congo Red



# Diagnosis

Non-neoplastic kidney with

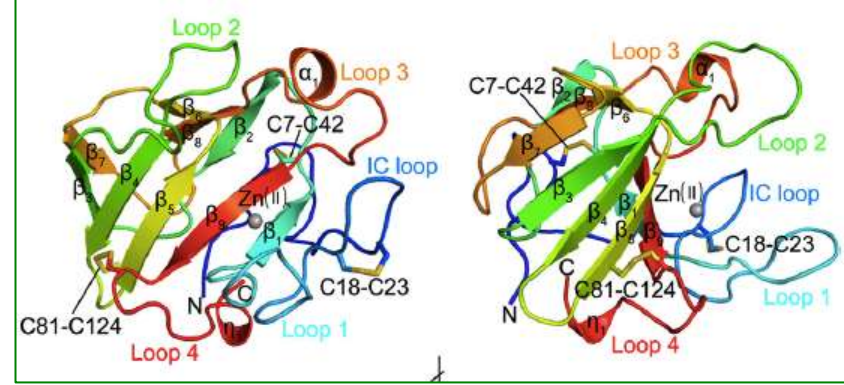
- ALCT2 amyloid, involving interstitium > glomeruli > vessels
- Diabetic nephropathy

Amyloid type	Mayo all % (n=474)	Mayo Referral % (n=127)	Nephropath % (n=414)	Stanford % (n=93)
Light chain (AL)	81	41	83	46
Ig heavy chain or H&L	4.8	10		1
<b>ALECT2</b>	<b>2.7</b>	<b>20</b>	<b>10</b>	<b>19</b>
Serum amyloid A (AA)	7	12	5	17
Fibrinogen A-alpha (Afib)	1.3	5.5	1	1
Apolipoprotein (AApoAI-IV)	0.6	3	1	1
Gelsolin (AGel)		2		
Beta-2 microglobulin		1		
Transthyretin (ATTR)		1		
Indeterminate	2.3	4	1	No MS-10% MS indet-5%

Sethi. KI. 2012;82:226–34. Said. cJASN. 2013; 8: 1515–23. Larsen KI. 2014;86:378–82;  
Nasr SH, Clin J Am Soc Nephrol. 2015;10(11):2084-93



# ALECT2



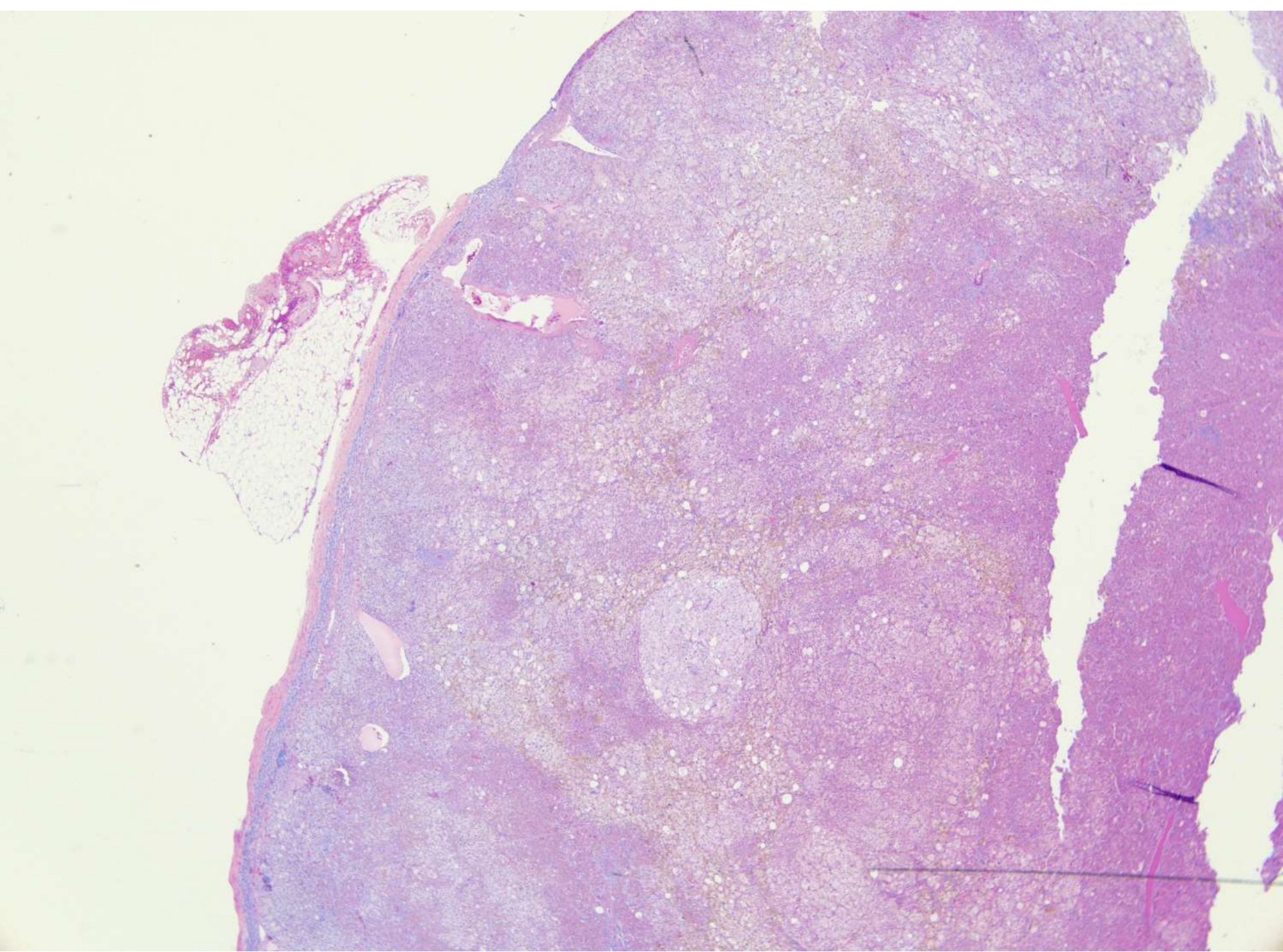
Zheng. JBC. 2016;  
291:17133–42

- LEukocyte cell-derived ChemoTaxin 2
  - Neutrophil chemotactic protein, “hepatokine”
  - Zinc M23 peptidase family
- Propensity for renal interstitium
  - Also glomerular, vascular, +/- proteinuria
  - Medulla relatively spared
  - Other organs: liver, bone marrow, spleen, adrenal, lung
    - Rare in myocardium, brain, fat pad → Implications for survival and biopsy dx
- No specific therapy at present
  - Overall survival better than AL, AA
  - Renal survival still poor (20-30+% ESRD)
- ALECT2 associated with homozygosity for SNP: Isol → Val aa40
  - Hispanic, Middle Eastern, Indian, rare in European Caucasians

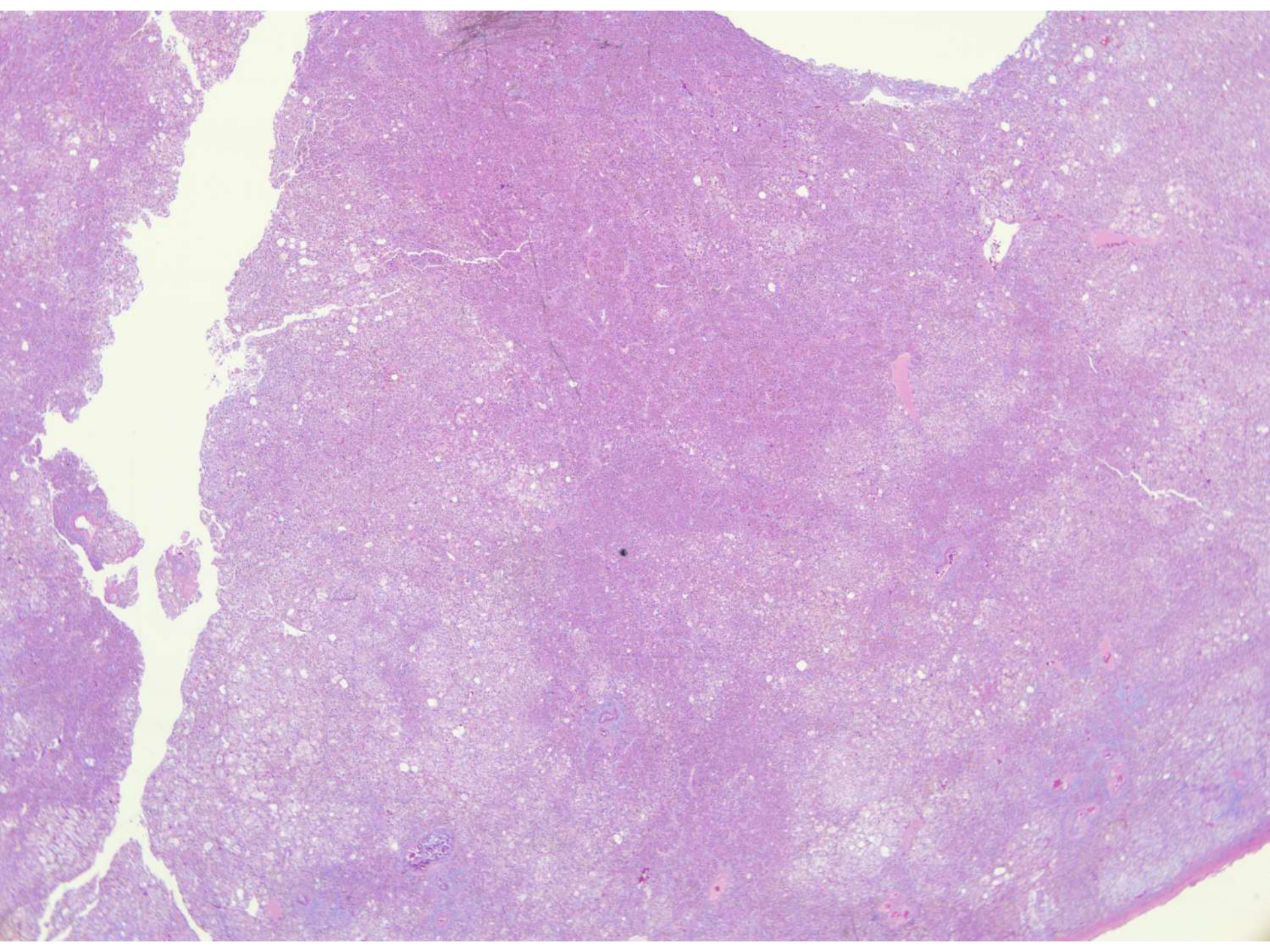
# 20-1102

Emily Ryan/Megan Troxell; Stanford

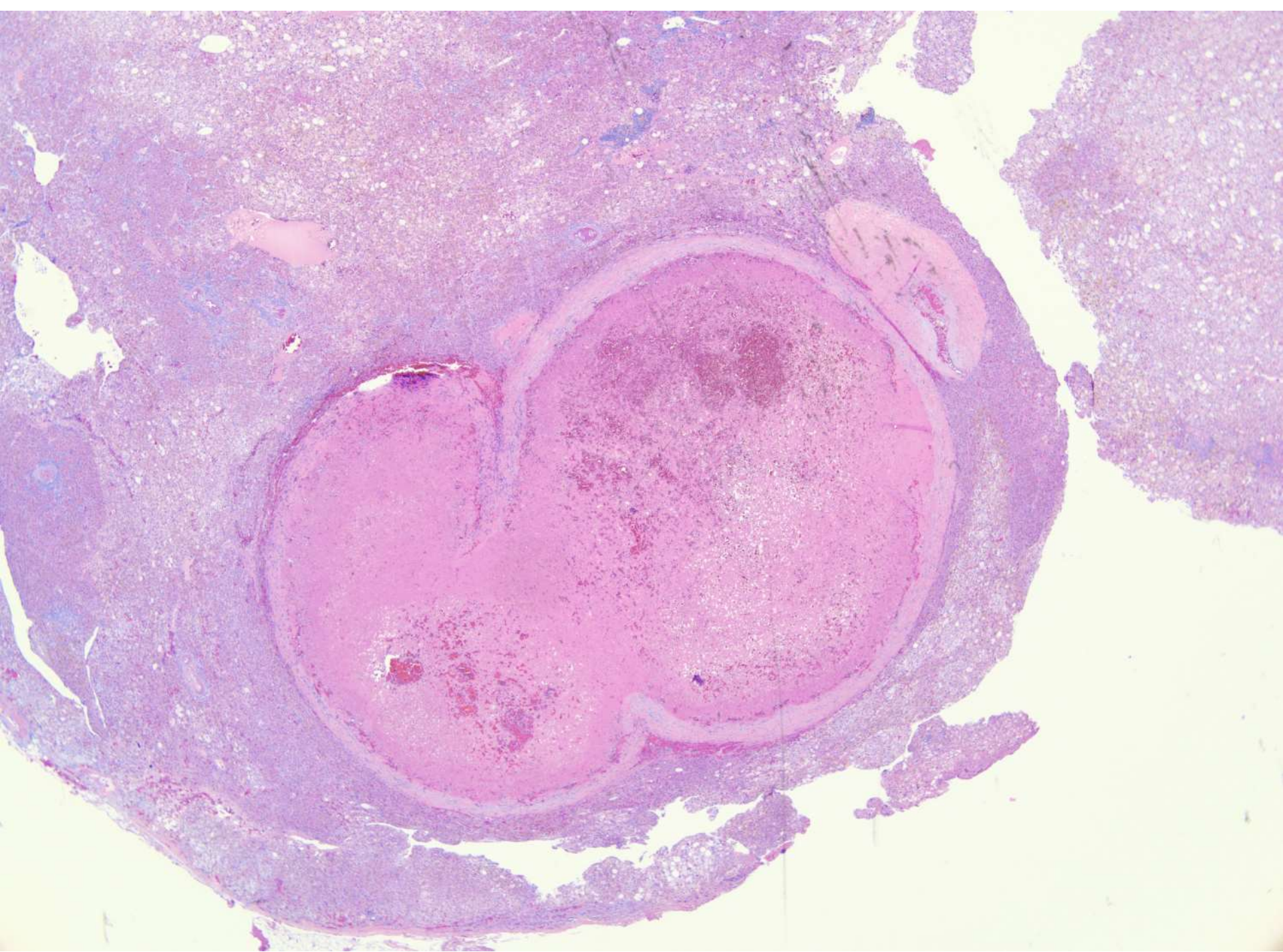
72-year-old F with adrenal mass



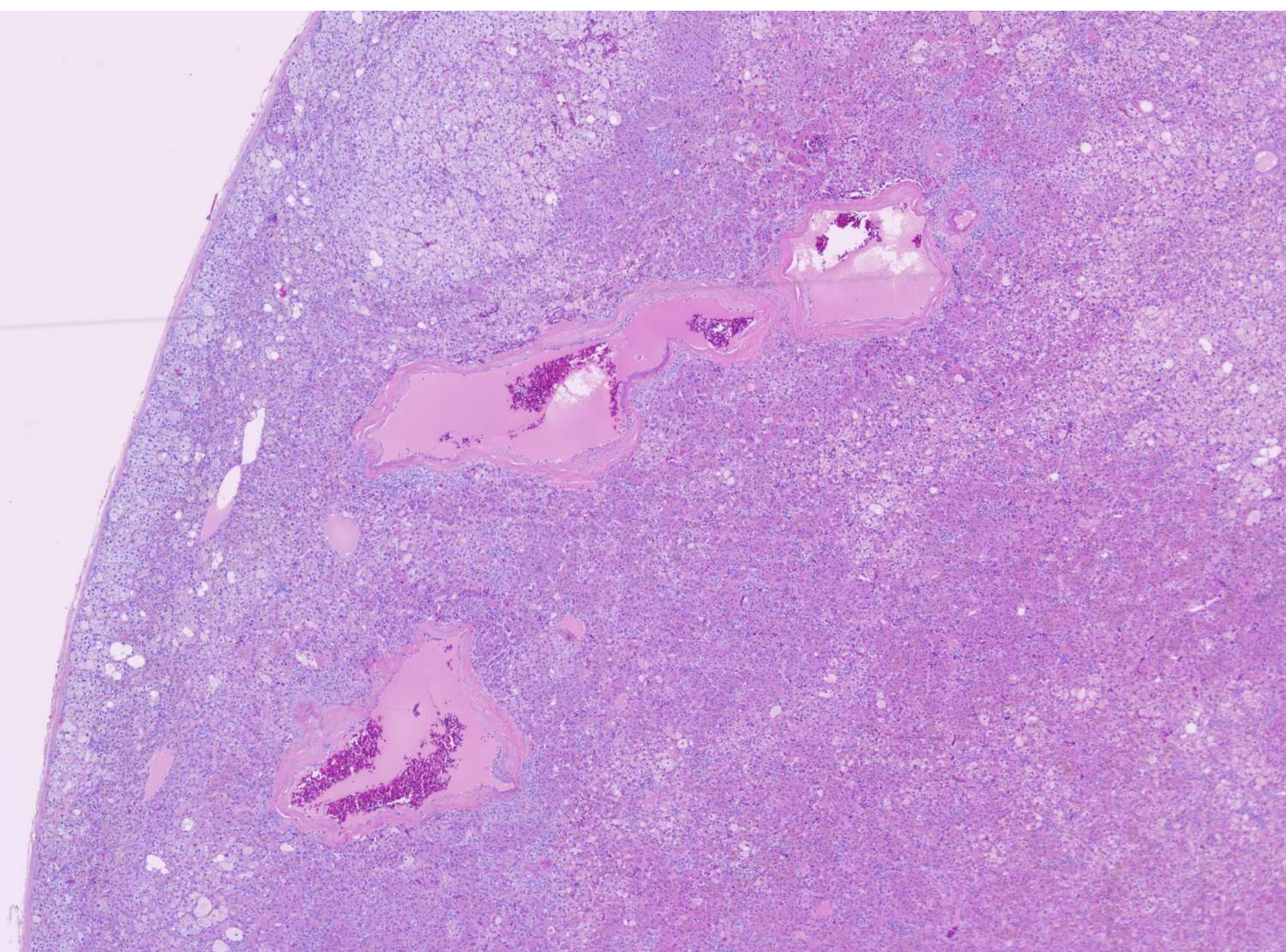




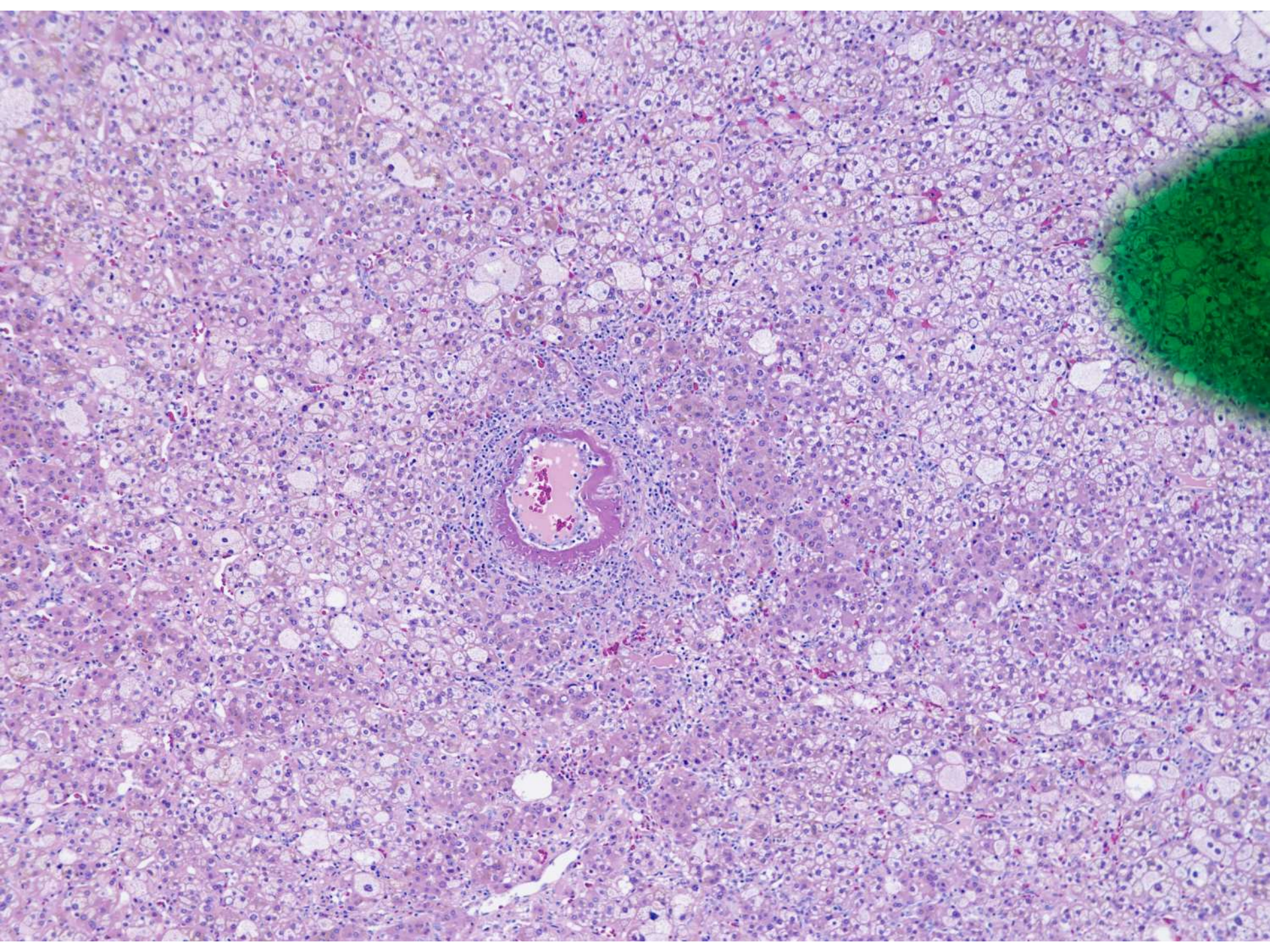




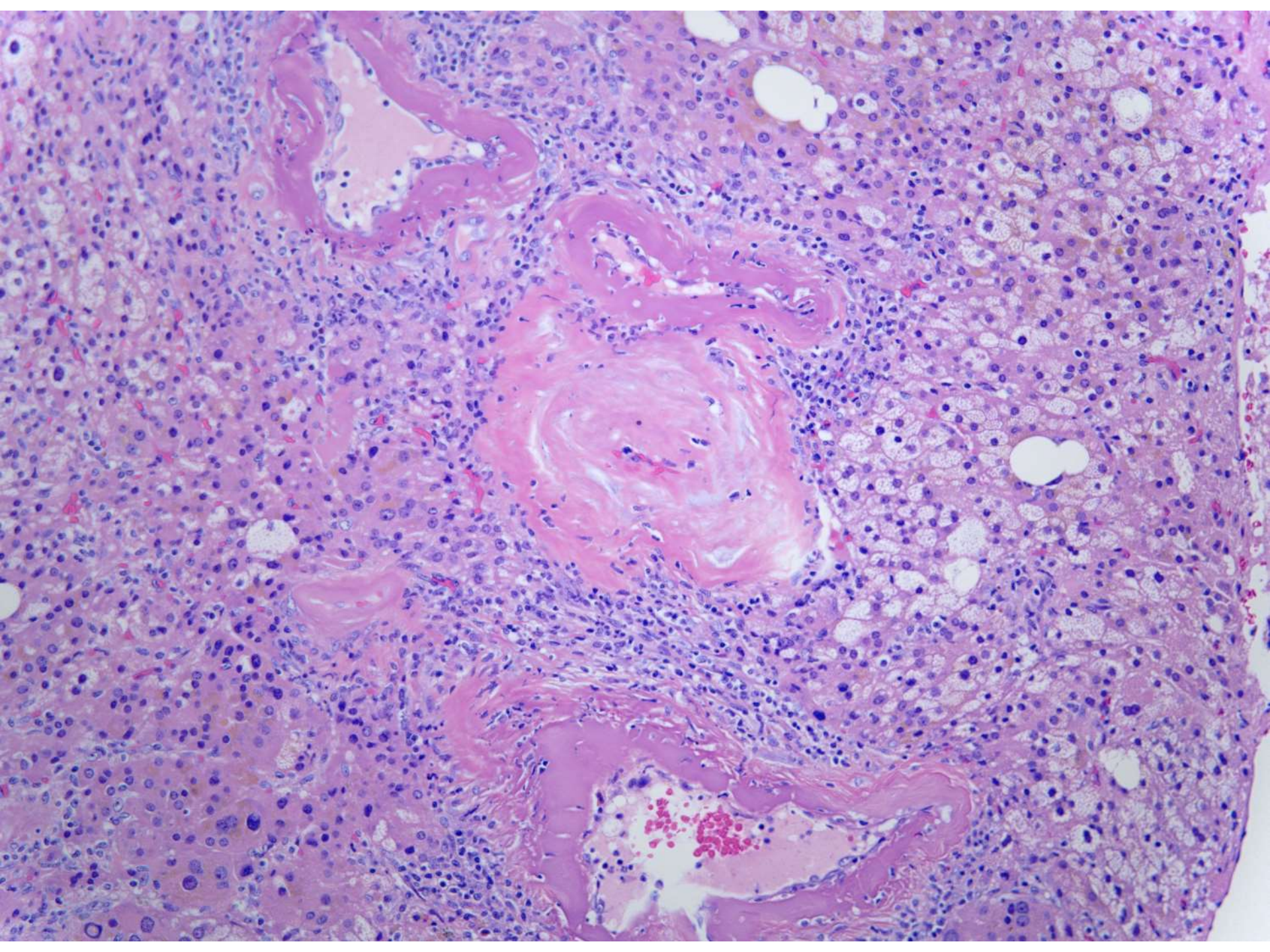




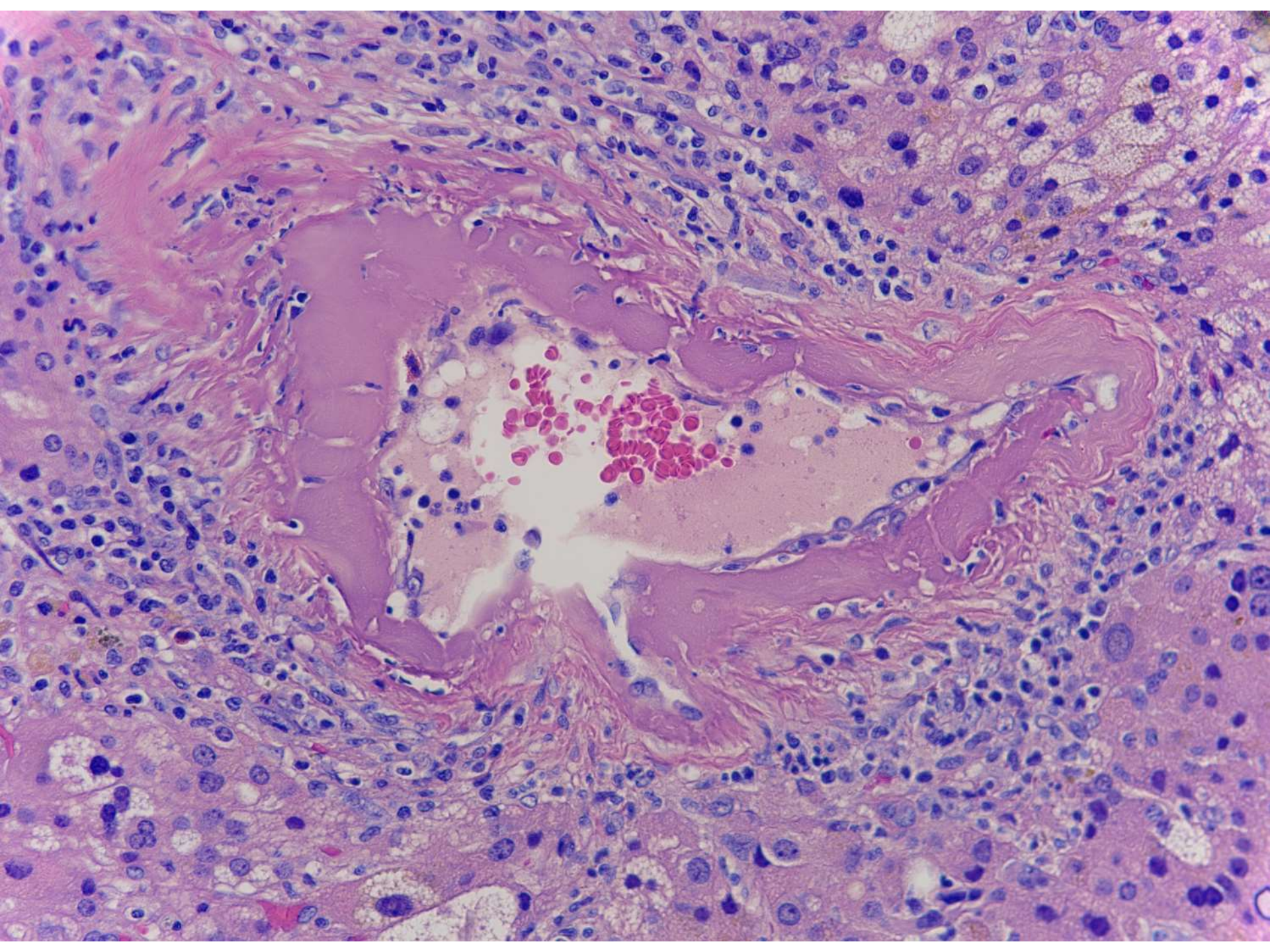














## 1994 Chapel Hill Conference

**Goal:** Define nomenclature of the most common forms of vasculitis and to construct a specific definition for each

**Definitions proposed:** Characteristics required to justify the diagnosis

- No specification of what observations or criteria required to make the diagnosis
- Definition versus diagnostic criteria versus classification criteria

Example: Definition requires histopathologic descriptions, in practice diagnosis may not be required (a cavitory lesion in the lung by imaging may be sufficient to diagnose necrotizing granulomatous pulmonary inflammation)

So... another consensus conference in 2012, to improve the existing nomenclature by modifying names and definitions and adding categories that had been omitted in 1994

## Arthritis & Rheumatism

An Official Journal of the American College of Rheumatology  
[www.arthritisrheum.org](http://www.arthritisrheum.org) and [wileyonlinelibrary.com](http://wileyonlinelibrary.com)

### SPECIAL ARTICLE

#### 2012 Revised International Chapel Hill Consensus Conference Nomenclature of Vasculitides

J. C. Jennette,<sup>1</sup> R. J. Falk,<sup>1</sup> P. A. Bacon,<sup>2</sup> N. Basu,<sup>3</sup> M. C. Cid,<sup>4</sup> F. Ferrario,<sup>5</sup> L. F. Flores-Suarez,<sup>6</sup> W. L. Gross,<sup>7</sup> L. Guillevin,<sup>8</sup> E. C. Hagen,<sup>9</sup> G. S. Hoffman,<sup>10</sup> D. R. Jayne,<sup>11</sup> C. G. M. Kallenberg,<sup>12</sup> P. Lamprecht,<sup>13</sup> C. A. Langford,<sup>10</sup> R. A. Luqmani,<sup>14</sup> A. D. Mahr,<sup>15</sup> E. L. Matteson,<sup>16</sup> P. A. Merkel,<sup>17</sup> S. Ozen,<sup>18</sup> C. D. Pusey,<sup>19</sup> N. Rasmussen,<sup>20</sup> A. J. Rees,<sup>21</sup> D. G. I. Scott,<sup>22</sup> U. Specks,<sup>16</sup> J. H. Stone,<sup>23</sup> K. Takahashi,<sup>24</sup> and R. A. Watts<sup>25</sup>



**Table 1.** Explanation of terminology

Term	
Diagnosis	The name
Definition	Disease p patient the dia
Classification criteria	Observati patient categor
Diagnostic criteria	Observati confide of the disease

\* The classification criteria and diagnostic criteria and diagnostic of a disease (e.g., histologic confirmation of acute myocardial infarction). ANCA syndrome.



## Example 2

### Polyarteritis nodosa

Necrotizing arteritis of medium or small arteries without glomerulonephritis or vasculitis in arterioles, capillaries, or venules, and not associated with ANCA  
Medium artery necrotizing arteritis seen on biopsy, negative ANCA, no MCLNS, and no evidence of glomerulonephritis

Medium artery aneurysm seen on imaging or necrotizing arteritis seen on biopsy, negative ANCA, no MCLNS, and no evidence of glomerulonephritis

from any validated study. Note that logic process that is a defining feature c criterion for an actionable diagnosis MCLNS=mucocutaneous lymph node



## **Required in all cases:**

Vasculitis: Inflammation of blood vessel walls, at some point

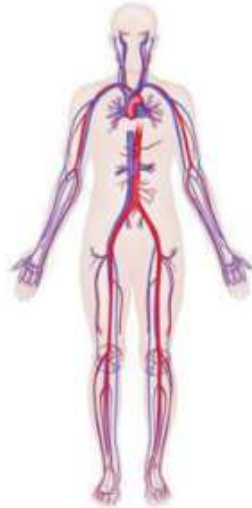
## **Features that vary among different forms of vasculitis:**

- Etiology
- Pathogenesis
- Type of vessel affected
- Type of inflammation
- Favored organ distribution
- Clinical manifestations
- Genetic predispositions
- Distinctive demographic characteristics

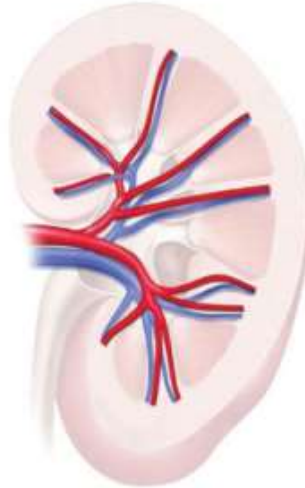
Classifying by etiology would be great...not always known, so the CHCC nomenclature subdivides vasculitides based on combinations of features



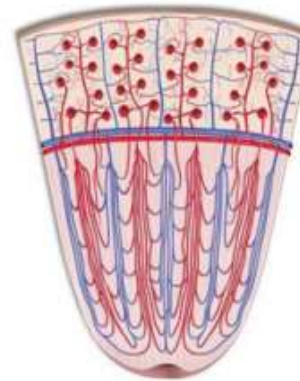
**A Large Vessels**



**B Medium Vessels**

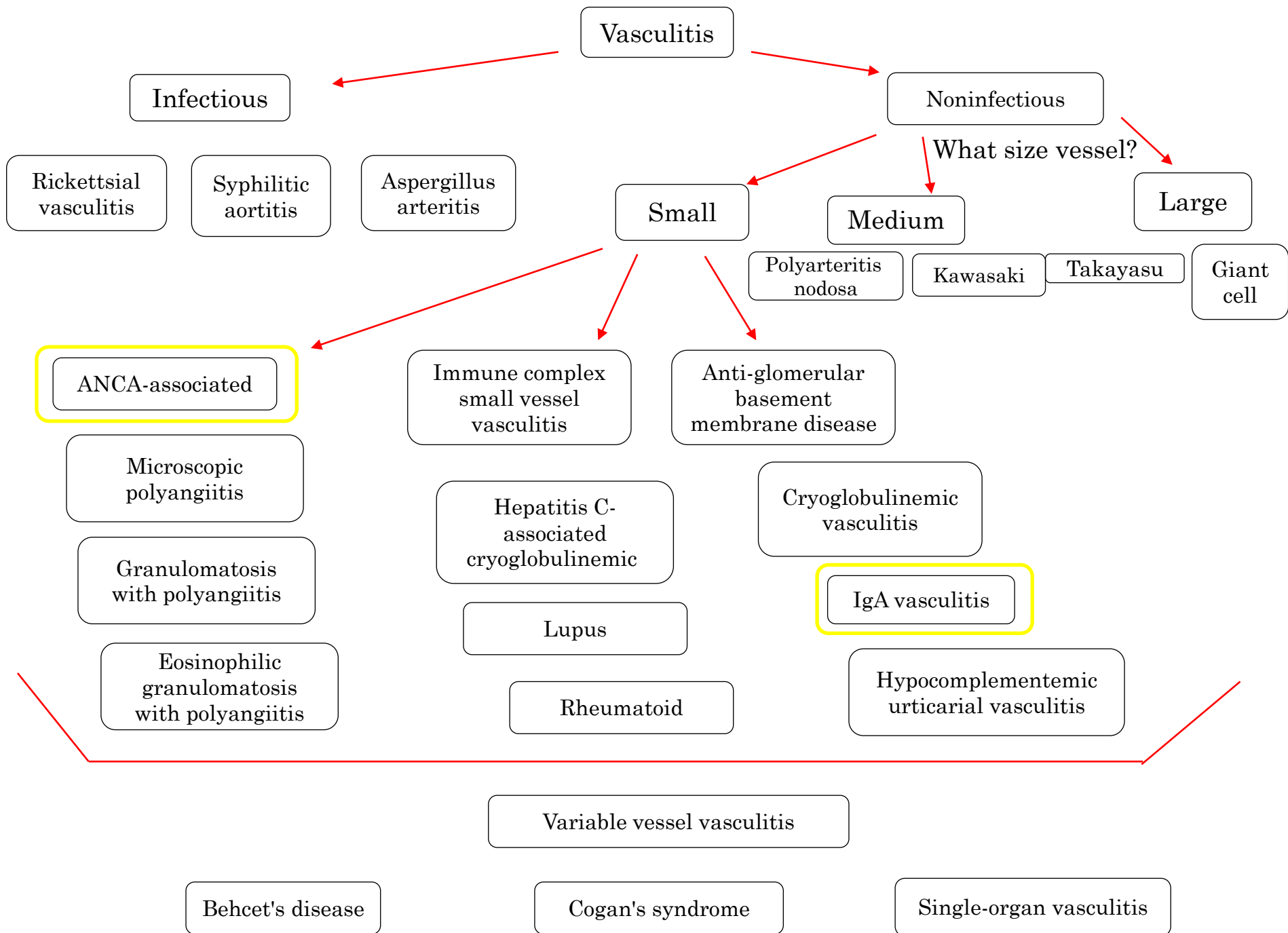


**C Small Vessels**

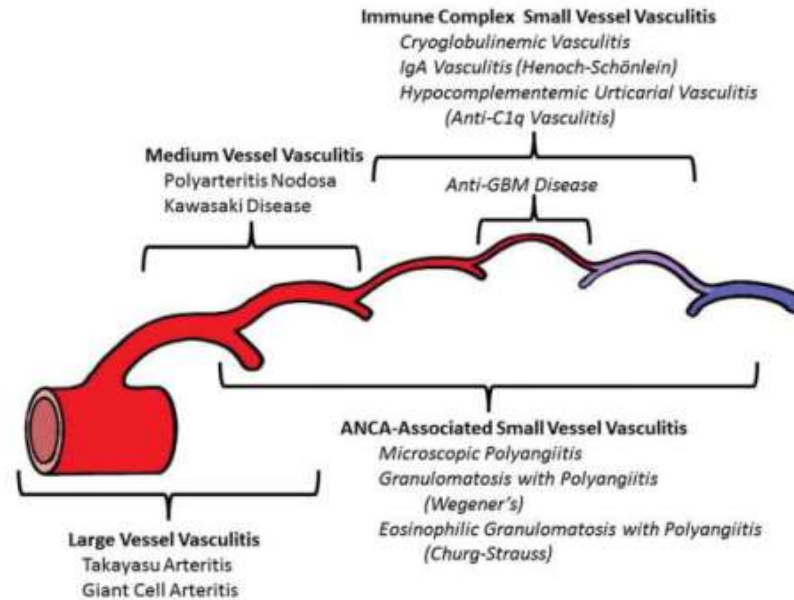


**Figure 1.** Types of vessels that are defined as large vessels (A), medium vessels (B), and small vessels (C) in the Chapel Hill Consensus Conference nomenclature system. The kidney is used to exemplify medium and small vessels. Large vessels are the aorta and its major branches and the analogous veins. Medium vessels are the main visceral arteries and veins and their initial branches. Small vessels are intraparenchymal arteries, arterioles, capillaries, venules, and veins.



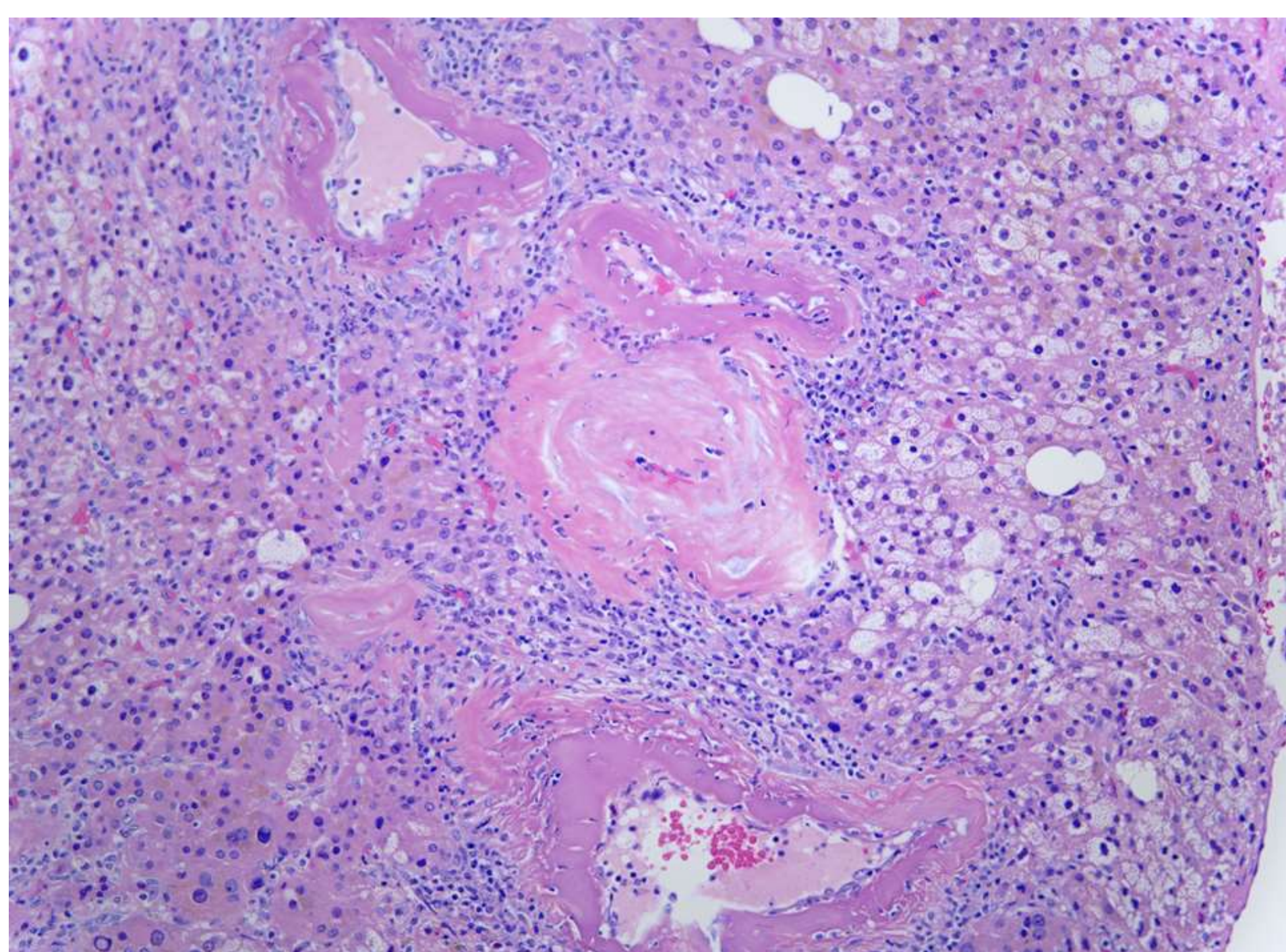






**Figure 2.** Distribution of vessel involvement by large vessel vasculitis, medium vessel vasculitis, and small vessel vasculitis. Note that there is substantial overlap with respect to arterial involvement, and an important concept is that all 3 major categories of vasculitis can affect any size artery. Large vessel vasculitis affects large arteries more often than other vasculitides. Medium vessel vasculitis predominantly affects medium arteries. Small vessel vasculitis predominantly affects small vessels, but medium arteries and veins may be affected, although immune complex small vessel vasculitis rarely affects arteries. Not shown is variable vessel vasculitis, which can affect any type of vessel, from aorta to veins. The diagram depicts (from left to right) aorta, large artery, medium artery, small artery/arteriole, capillary, venule, and vein. Anti-GBM = anti-glomerular basement membrane; ANCA = antineutrophil cytoplasmic antibody.







**DIAGNOSIS (MICROSCOPIC):**

**A. ADRENAL, RIGHT, ADRENALECTOMY**

- ADRENAL CORTICAL ADENOMA WITH NECROTIZING ARTERITIS (SEE COMMENT)**



## Single-organ vasculitis

- Arteries or veins of any size in a single organ
- No features that indicate that it is a limited expression of a systemic vasculitis
- Distribution may be unifocal or multifocal (diffuse) within an organ or organ system

“Some patients originally diagnosed as having SOV will develop additional disease manifestations that warrant reclassifying the vasculitis as one of the systemic vasculitides (e.g., cutaneous arteritis later becoming systemic PAN). Clinical, laboratory, and pathologic features are useful in distinguishing SOV from an isolated expression of systemic vasculitis. Concluding that an isolated vasculitis is a limited expression of a systemic vasculitis does not imply that the vasculitis will or will not subsequently evolve into systemic disease.” (Jennette et al)

### Single-organ vasculitis of the cervix accompanying human papillomavirus infection

MURAT GÖZÜKÜÇÜK<sup>1,\*</sup>, ASLI YARCI GÜRSOY<sup>2</sup>, DUYGU KANKAYA<sup>3</sup>, CEM ATABEKOĞLU<sup>4</sup>

<sup>1</sup>Department of Obstetrics and Gynecology, Kocaeli Training and Research Hospital, Kocaeli, Turkey

<sup>2</sup>Department of Obstetrics and Gynecology, Ufuk University Medical Faculty, Ankara, Turkey

<sup>3</sup>Department of Pathology, Ankara University Medical Faculty, Ankara, Turkey

<sup>4</sup>Department of Obstetrics and Gynecology, Ankara University Medical Faculty, Ankara, Turkey

\*Corresponding author: Murat Gözükcük, MD, Department of Obstetrics and Gynecology, Kocaeli Training and Research Hospital, Kocaeli, Turkey; Phone: +90 352 238 2349; Fax: +90 352 329 7213; E-mail: muratgokuzkucuk@gmail.com

## Original Article

### Comparison between classical polyarteritis nodosa and single organ vasculitis of medium-sized vessels: a retrospective study of 25 patients and review of the literature

N. Kint<sup>1</sup>, P. De Haes<sup>2</sup>, D. Blockmans<sup>1</sup>

<sup>1</sup>Department of General Internal Medicine, University Hospital Gasthuisberg, Leuven, Belgium, <sup>2</sup>Department of Dermatology, University Hospital Gasthuisberg, Leuven, Belgium



# References

Bielsa, I. 2015. “Update of Systemic Vasculitides Nomenclature. International Chapel Hill Consensus Conference, 2012.” *Actas Dermo-Sifiliográficas (English Edition)* 106 (8): 605–8.

Kint, N., P. De Haes, and D. Blockmans. 2016. “Comparison between Classical Polyarteritis Nodosa and Single Organ Vasculitis of Medium-Sized Vessels: A Retrospective Study of 25 Patients and Review of the Literature.” *Acta Clinica Belgica* 71 (1): 26–31.

Jennette, J. C., R. J. Falk, P. A. Bacon, N. Basu, M. C. Cid, F. Ferrario, L. F. Flores-Suarez, et al. 2013. “2012 Revised International Chapel Hill Consensus Conference Nomenclature of Vasculitides.” *Arthritis and Rheumatism* 65 (1): 1–11.

Mahr, Alfred, and Mathilde de Menthon. 2015. “Classification and Classification Criteria for Vasculitis: Achievements, Limitations and Prospects.” *Current Opinion in Rheumatology* 27 (1): 1–9.

Hernández-Rodríguez, José, Eamonn S. Molloy, and Gary S. Hoffman. 2008. “Single-Organ Vasculitis.” *Current Opinion in Rheumatology* 20 (1): 40–46.

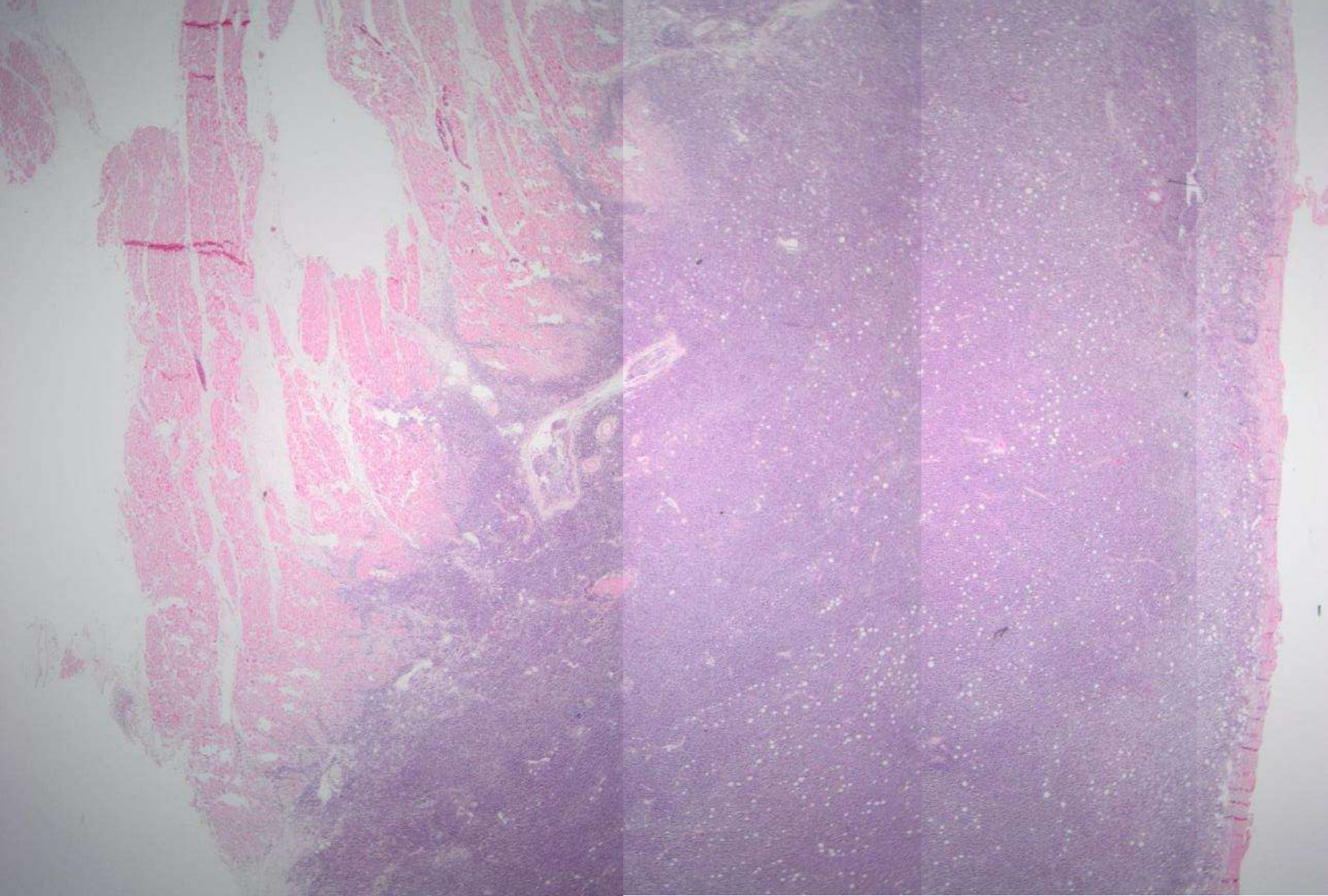


# 20-1103

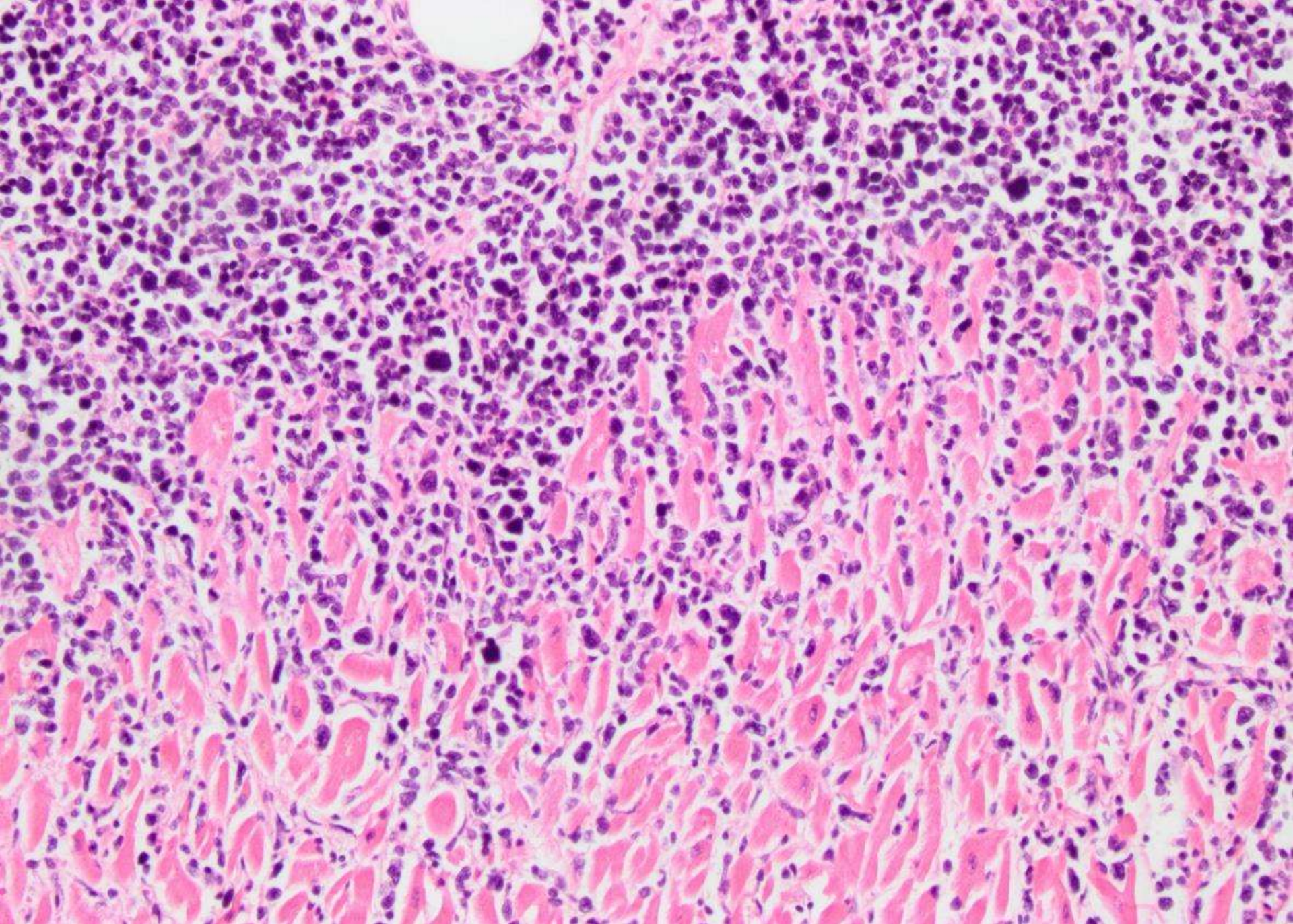
**Dean Fong; VA Palo Alto**

61-year-old F with DM type 2, presented acutely to the ER with chest pain and SOB. She was found to have a large intracardiac mass with right pleural effusion, pericardial effusion, and bilateral pulmonary emboli. She was taken to the OR for drainage of effusions and a pericardial window with biopsy. Several hours after surgery, she suddenly decompensated and multi-organ failure ensued. Upon autopsy, a large tumor encasing the inferior vena cava and right pulmonary artery with involvement of the right mainstem bronchus, and extensive involvement of bilateral posterior atria and ventricles of the heart was found.

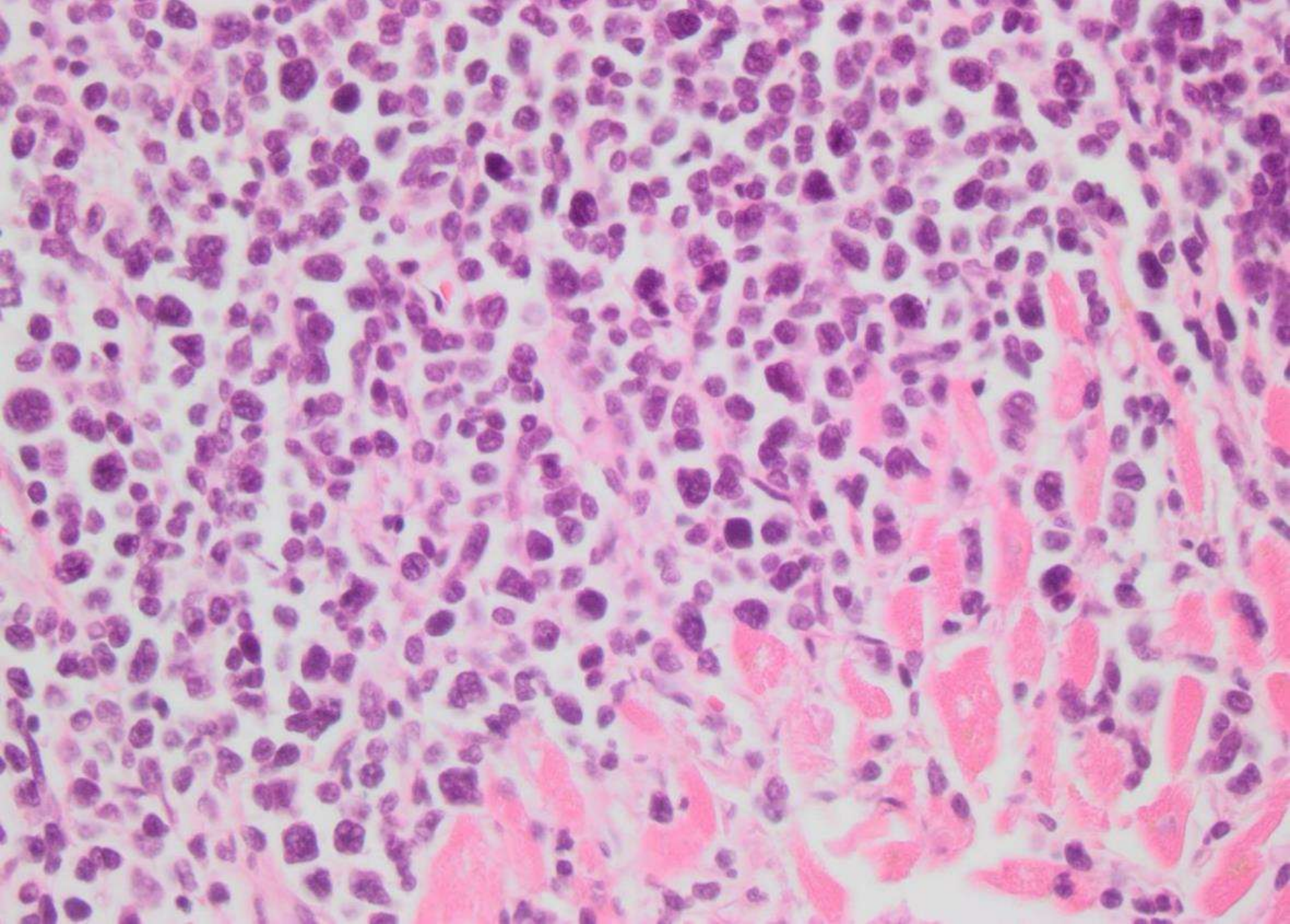




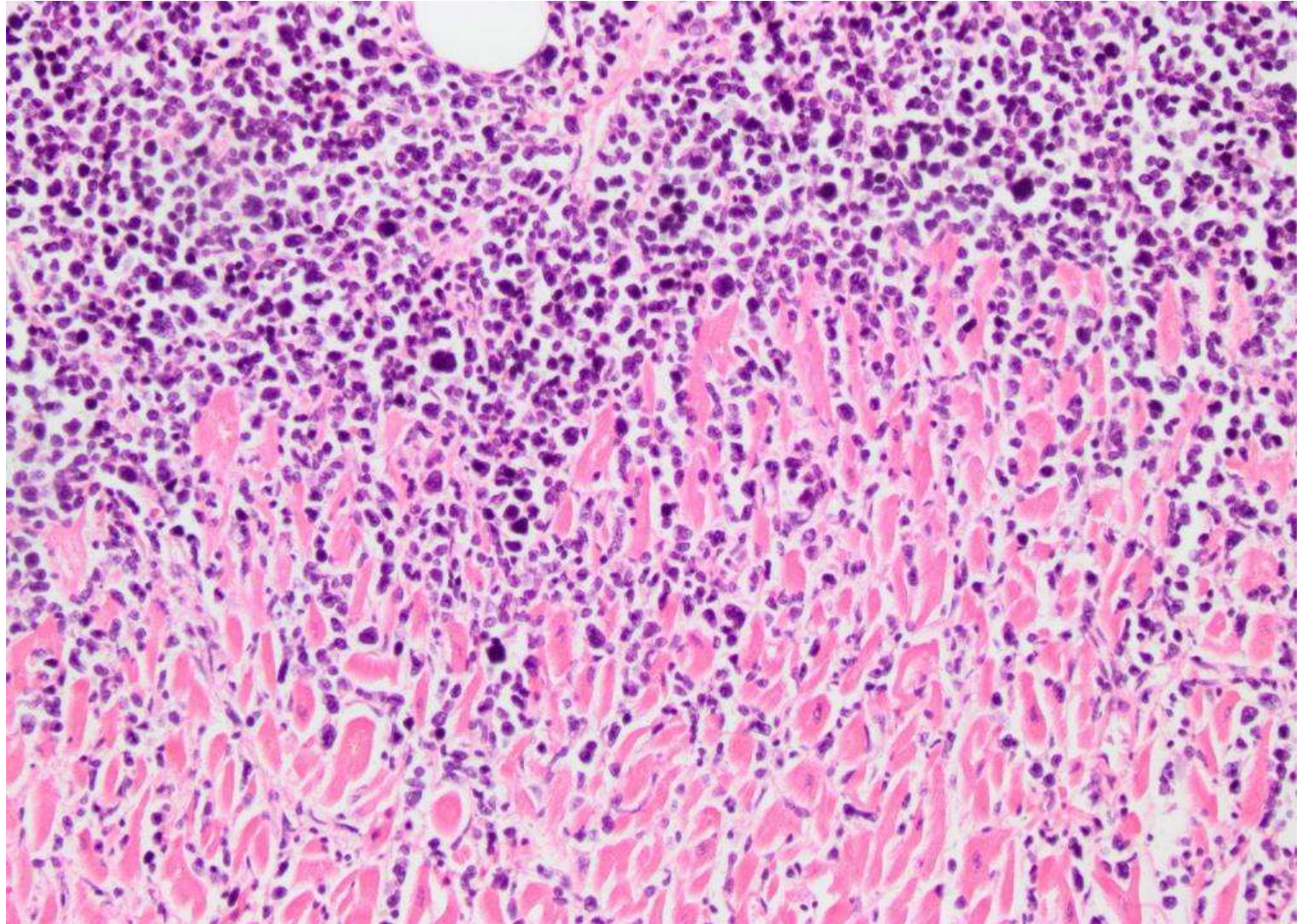






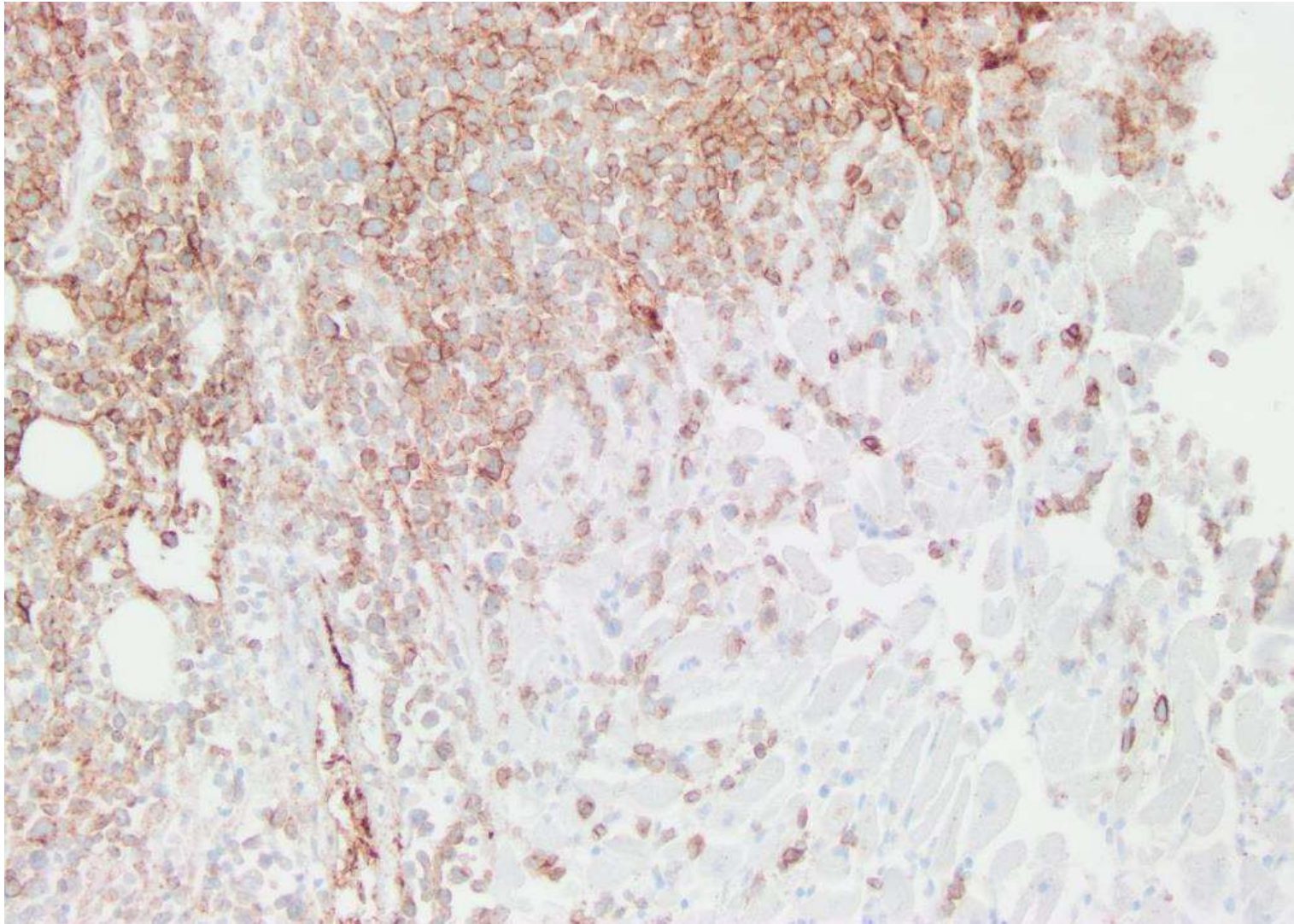






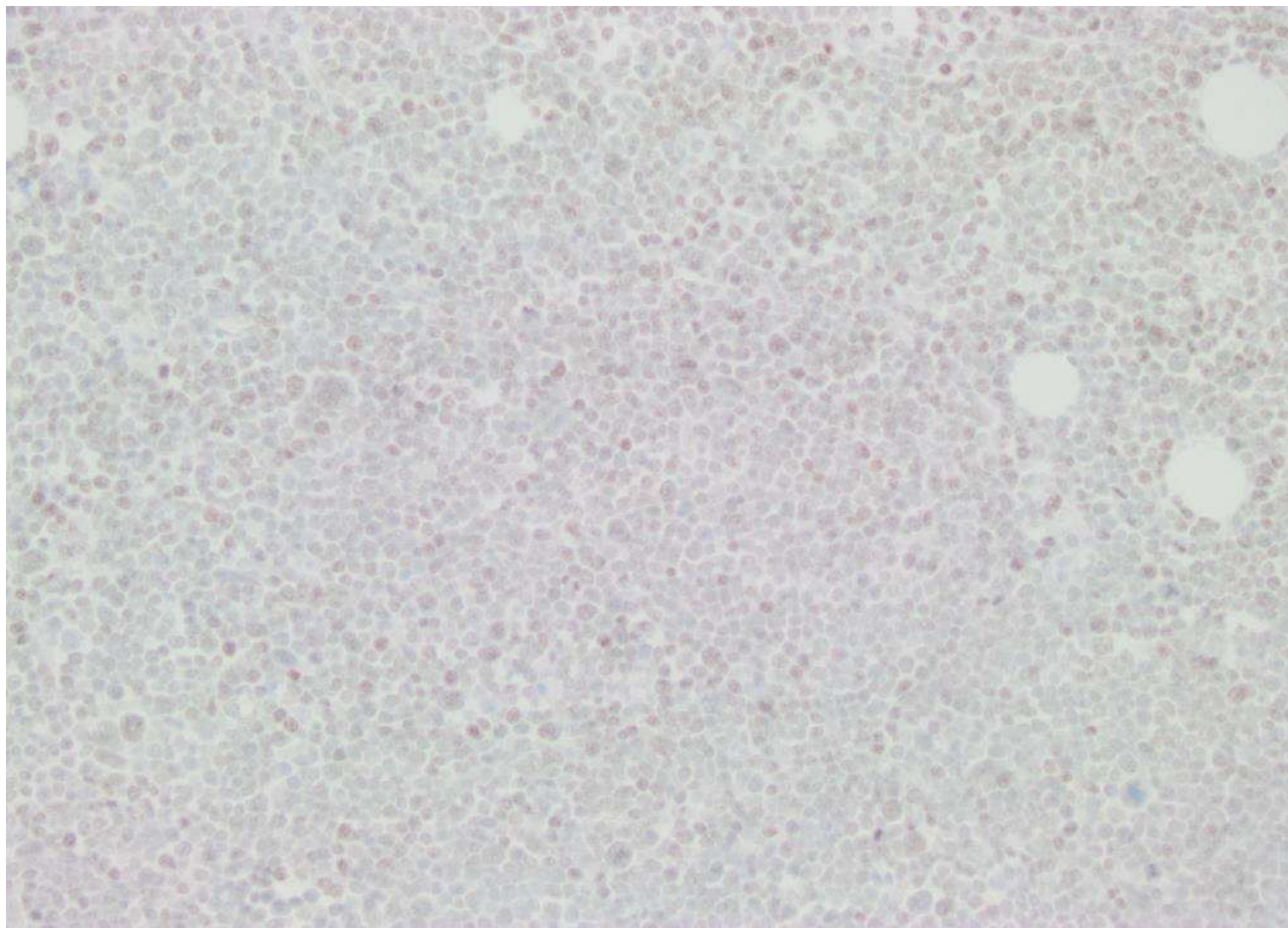


CD20

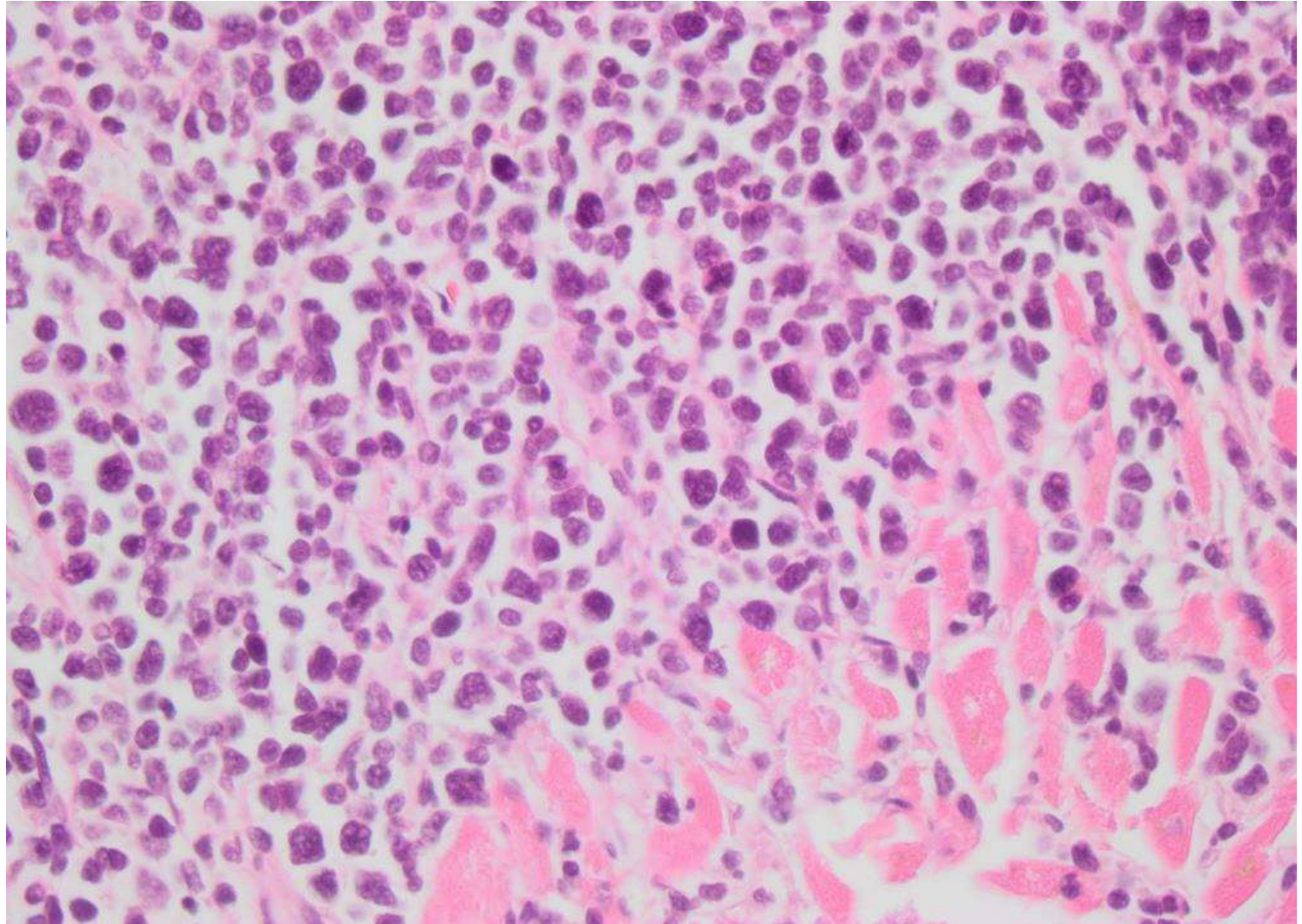




Pax5

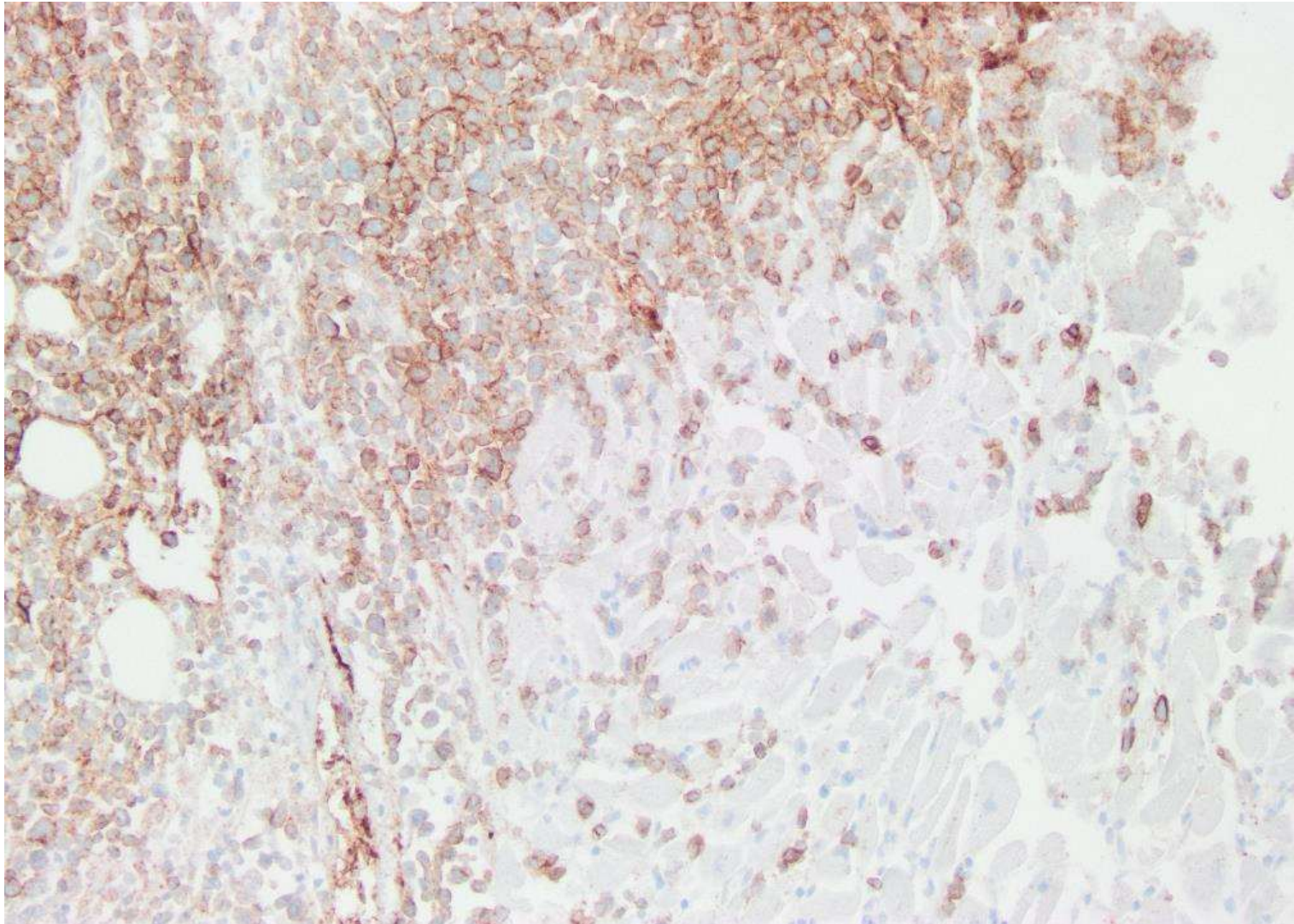




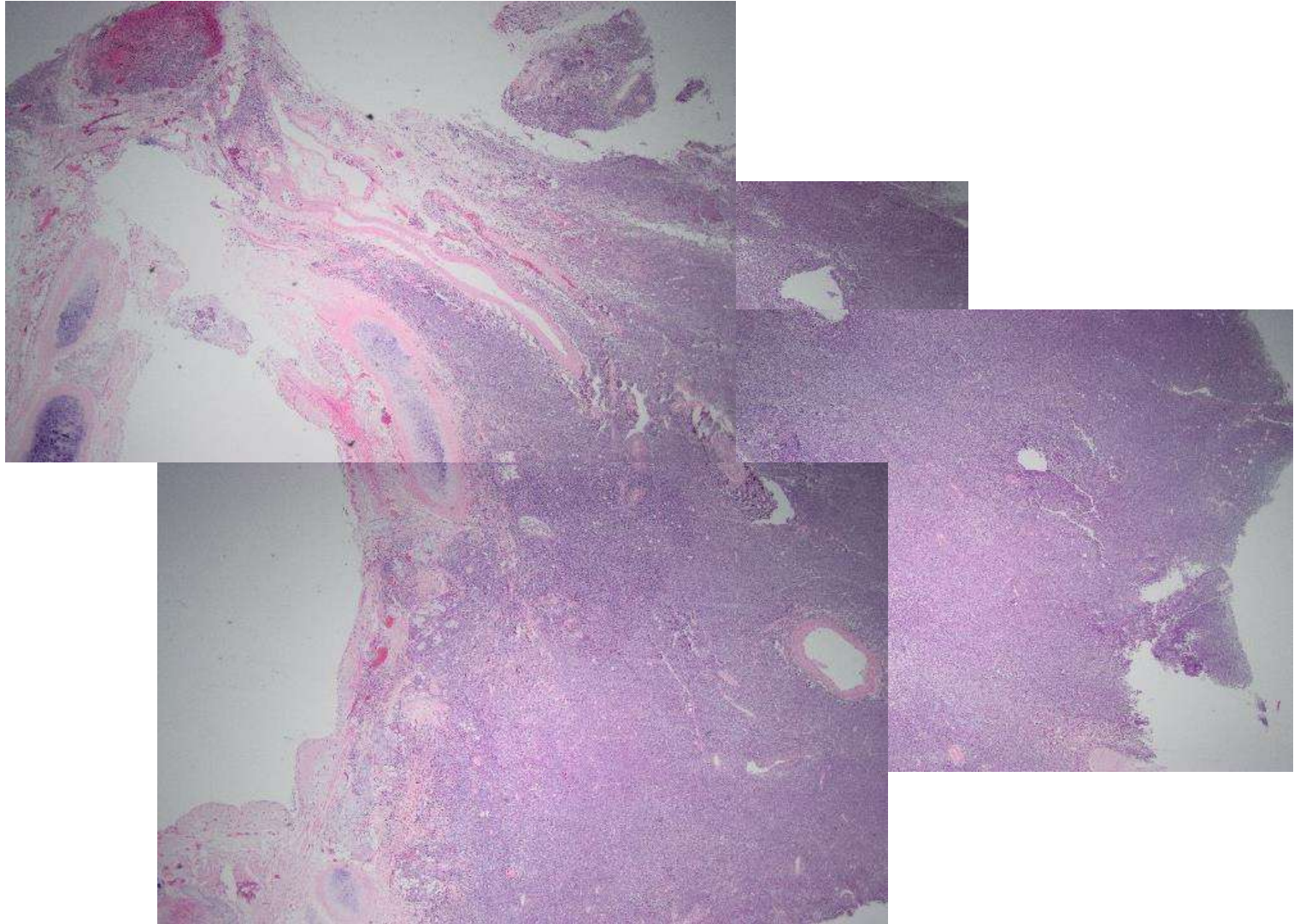




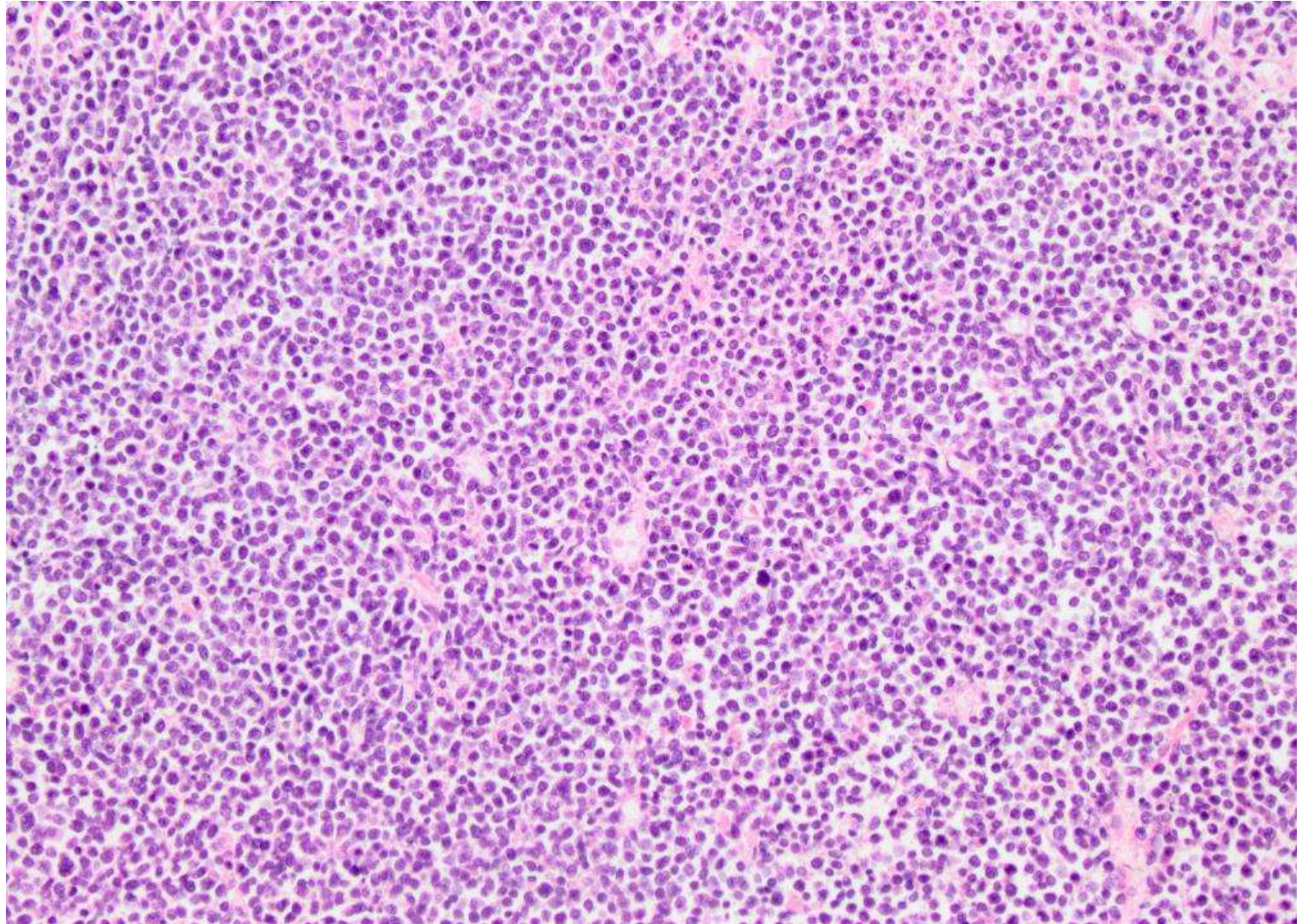
CD20





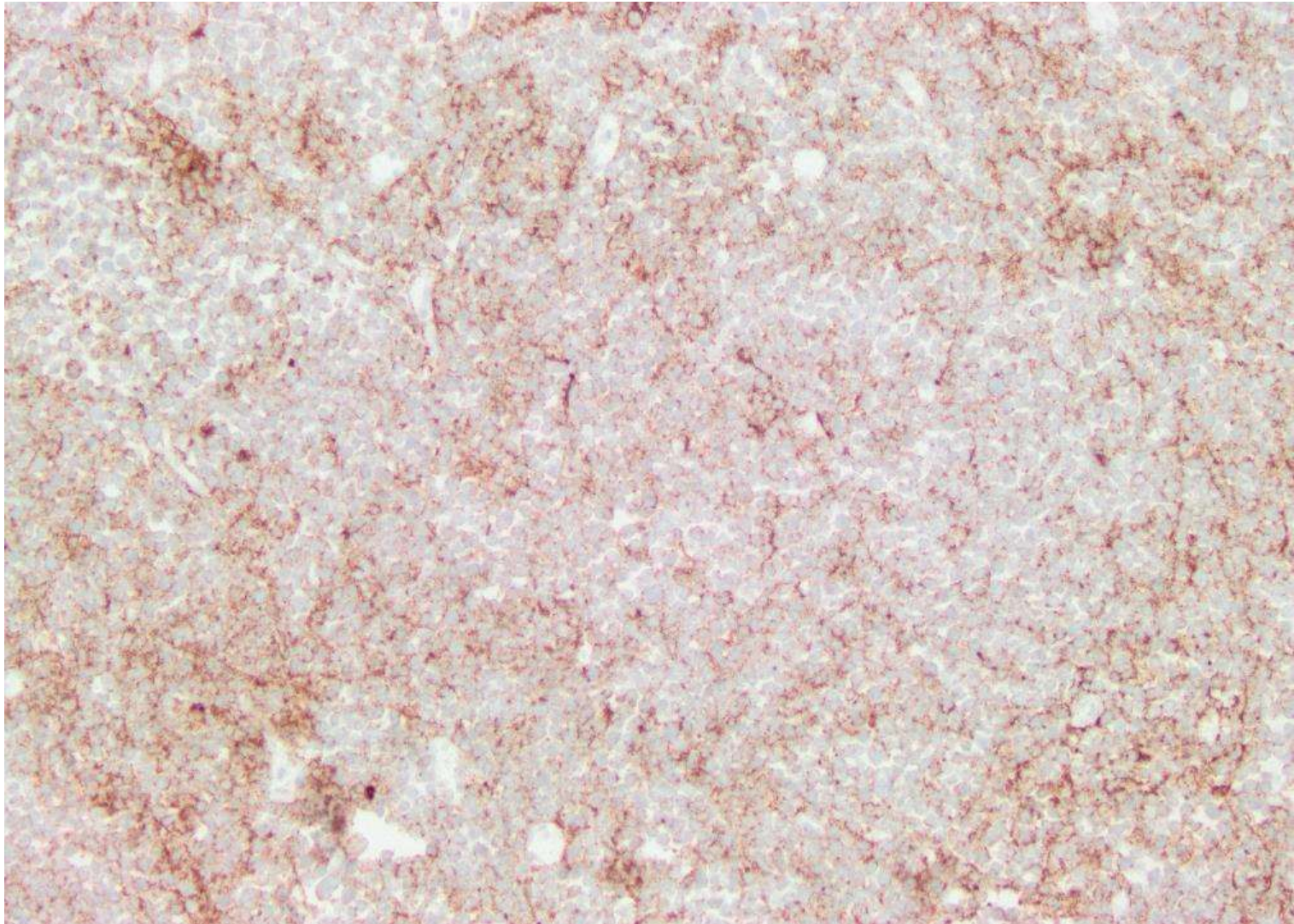








CD20





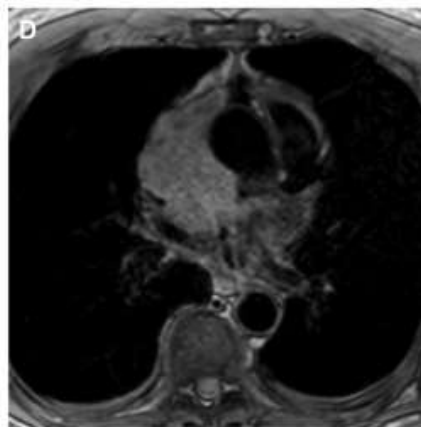
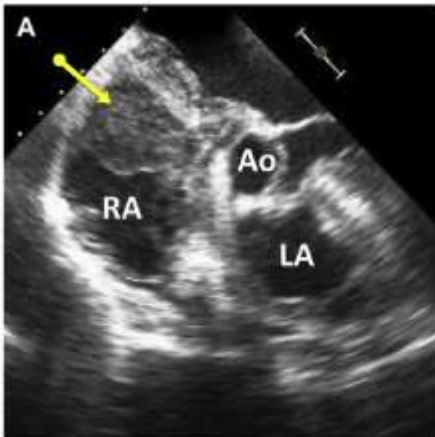# Diagnosis

- Diffuse Large B-Cell Lymphoma of the Heart
- Positive for BCL2
- Negative for CD5, CD10, CD23, CD30, BCL6
- EBER(EBV) Negative
- No other enlarged lymphadenopathy found during autopsy



# Cardiac Involvement by Lymphoma

- B-lineage → DLBCL most common
  - Immunocompromised → PEL, EBV-associated PTLD
- Primary → rare, 0.1% of cases in a series of 12,000 autopsies
  - < 0.5% of extra nodal lymphomas and < 2% of resected cardiac tumors
  - Involves right heart
  - Case reports → presents as a cardiac mass



## Cardiac Lymphoma

Jean Jeudy, MD<sup>a</sup>, Allen P. Burke, MD<sup>b</sup>, Aletta Ann Frazier, MD<sup>a,c,\*</sup>

Radiol Clin N Am 54 (2016) 689–710



# Cardiac Involvement by Lymphoma

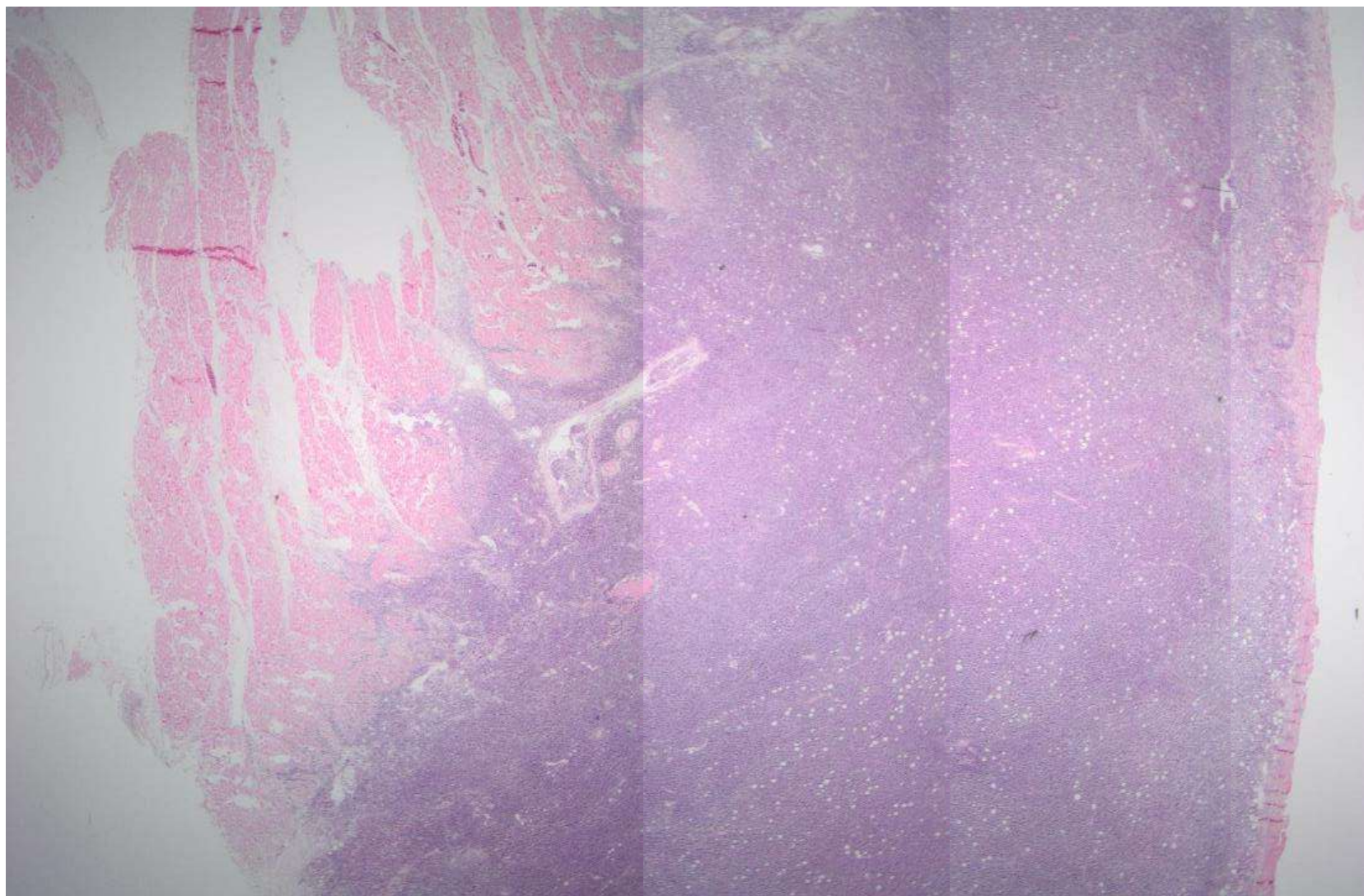
- Secondary → 8.7-25% of pts in autopsy studies and accounting for 9% of the total metastasis to the heart
  - Widespread → affecting epicardium and myocardium diffusely
  - LV → 55%; RA → 54%
  - Late manifestation
  - Direct extension from mediastinal tumor, hematogenous spread, lymphatic spread
  - Frequently undetected



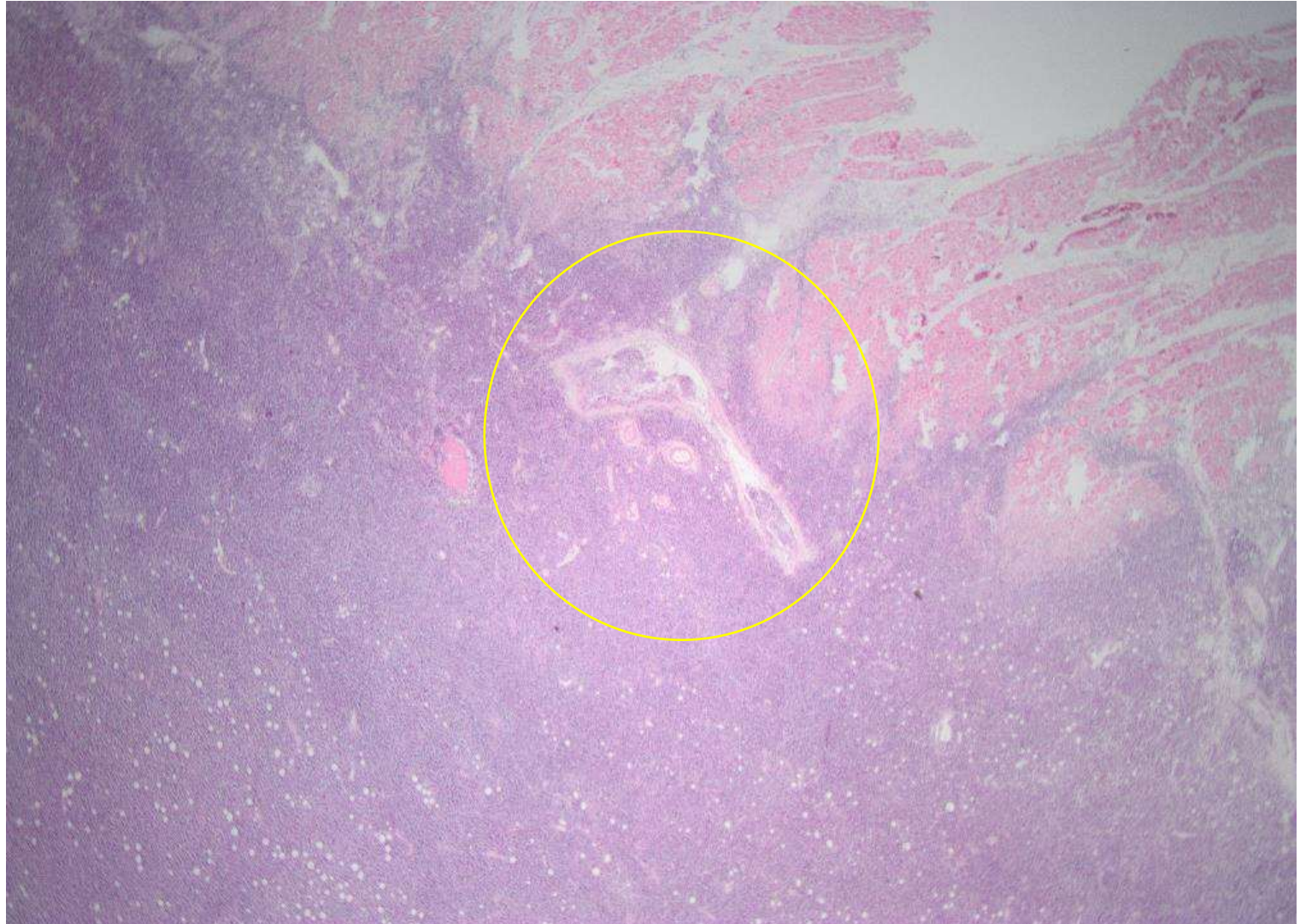
# Cardiac Involvement by Lymphoma

- Pre-Rituximab data
  - Median Survival 3 months (94 cases)
    - Worse outcomes with heart failure, T-cell lymphoma and aggressive B-cell lymphoma
  - 197 cases primary cardiac lymphoma
    - 1 month in pts with LV involvement
    - 22 months in pts free from LV disease
- DLBCL → sensitive to R-CHOP
  - Cardiac rupture from rapid tumor destruction
- High mortality rate











# References

**Cardiac involvement in disseminated diffuse large B-cell lymphoma, successful management with chemotherapy dose reduction guided by cardiac imaging: A case report and review of literature**

Rabah Al-Mehisen, Maha Al-Mohaissen, Hisham Yousef

*World J Clin Cases* 2019 January 26; 7(2): 191-202

Diagnosis and treatment complications of primary cardiac lymphoma in an immunocompetent 28-year old man: a case report

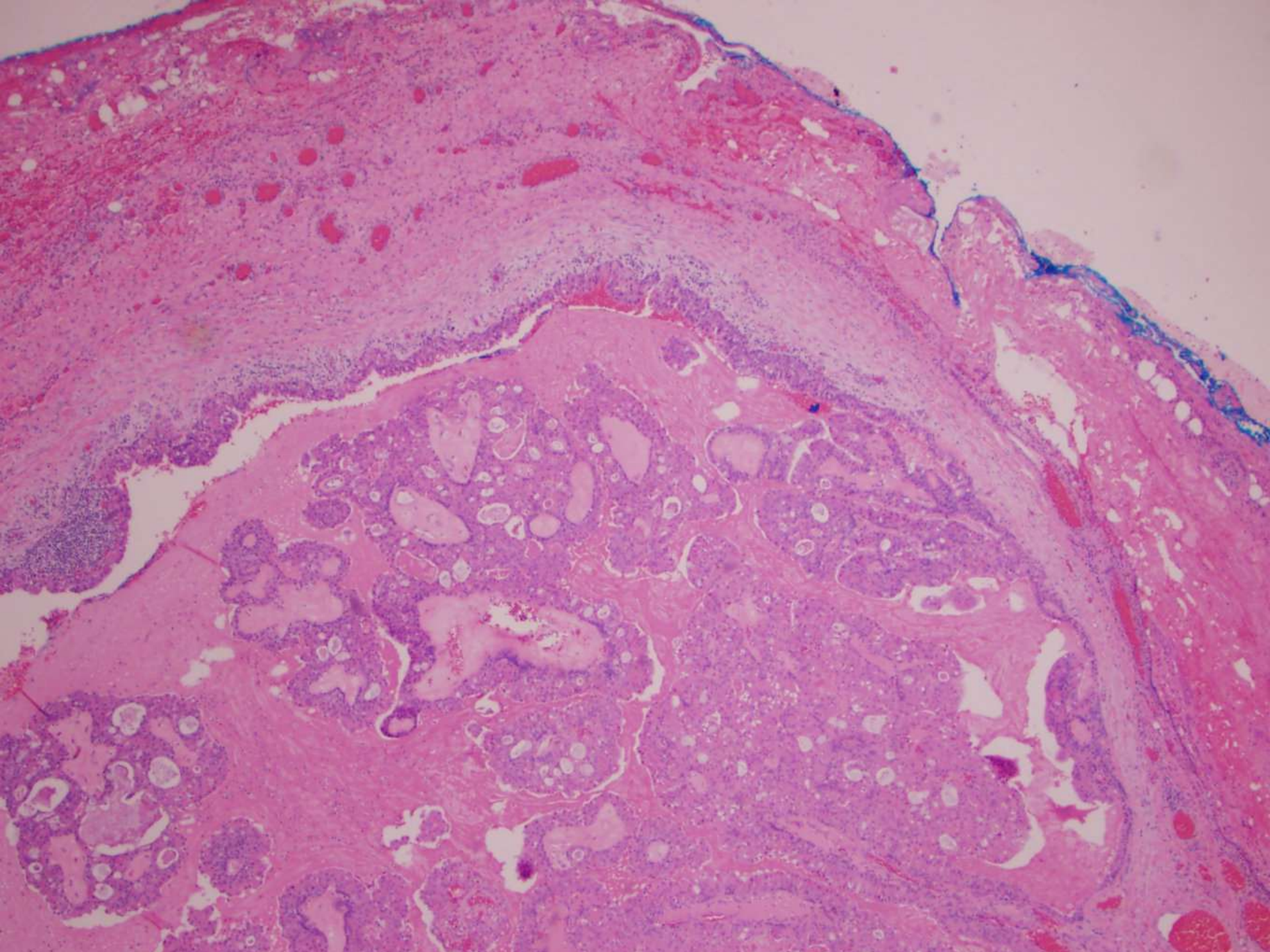
Bonou et al. *BMC Cancer* (2019) 19:191



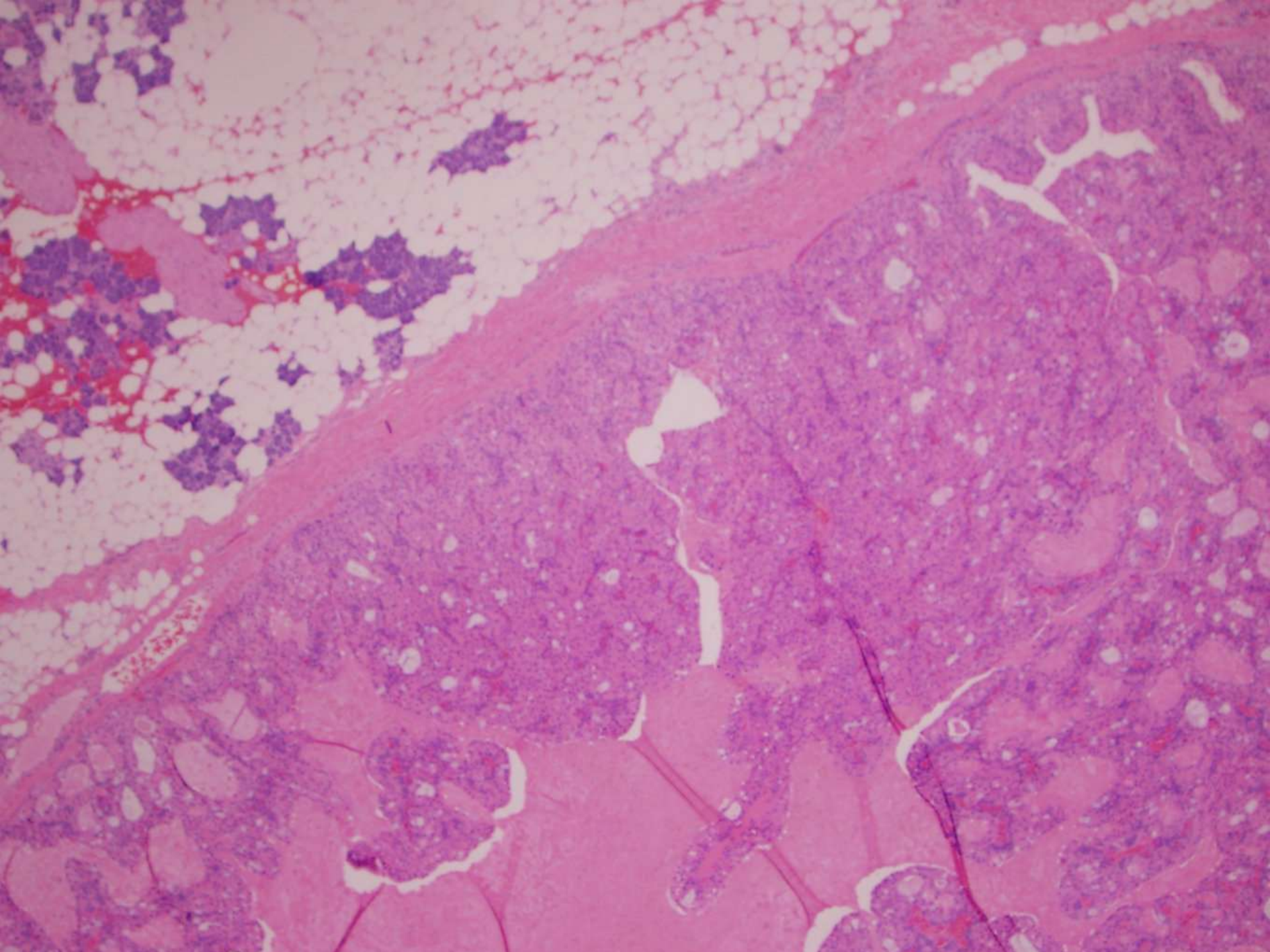
20-1104

**Greg Rumore; Kaiser Diablo**

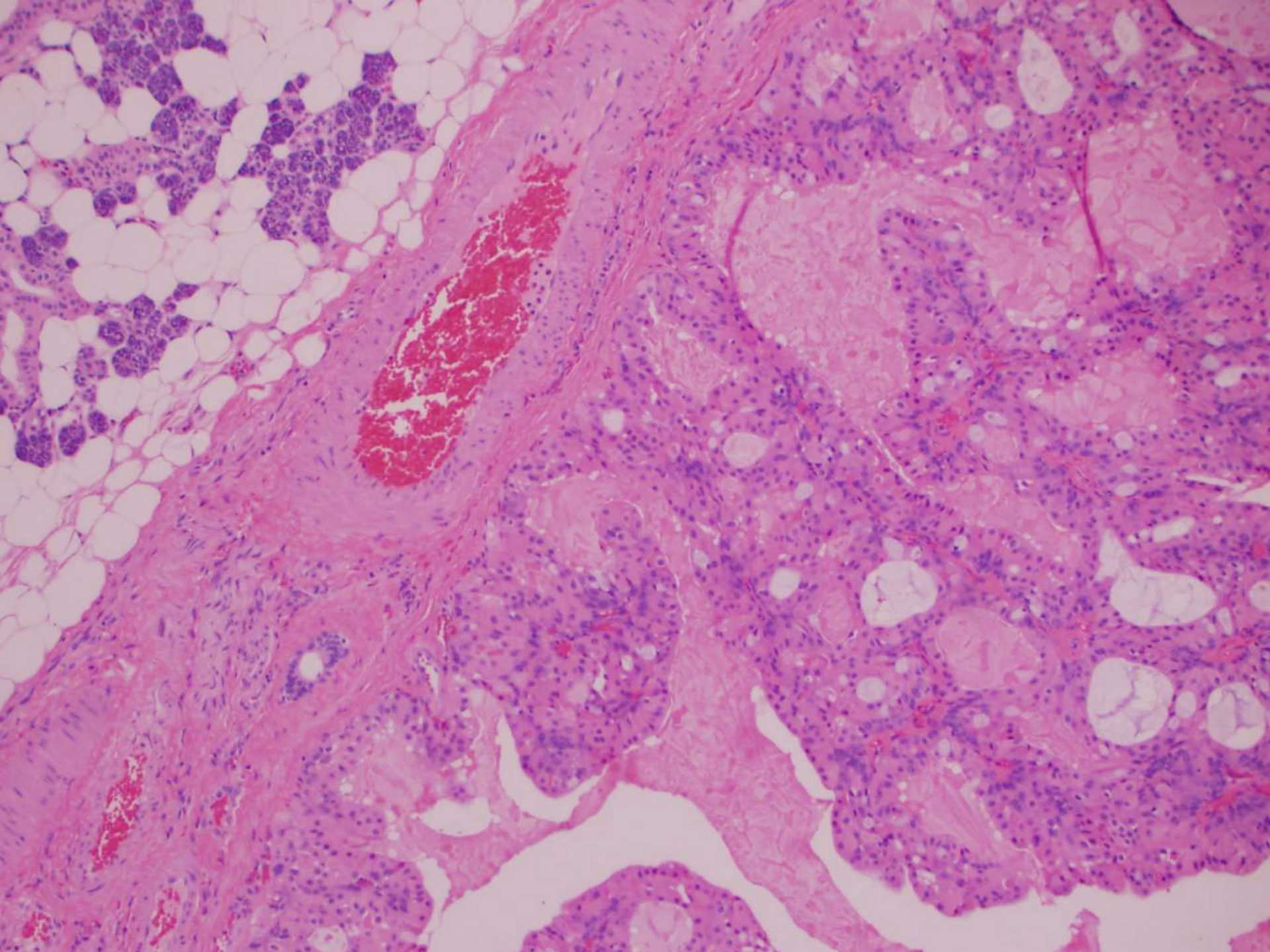
70-year-old F with left parotid mass.



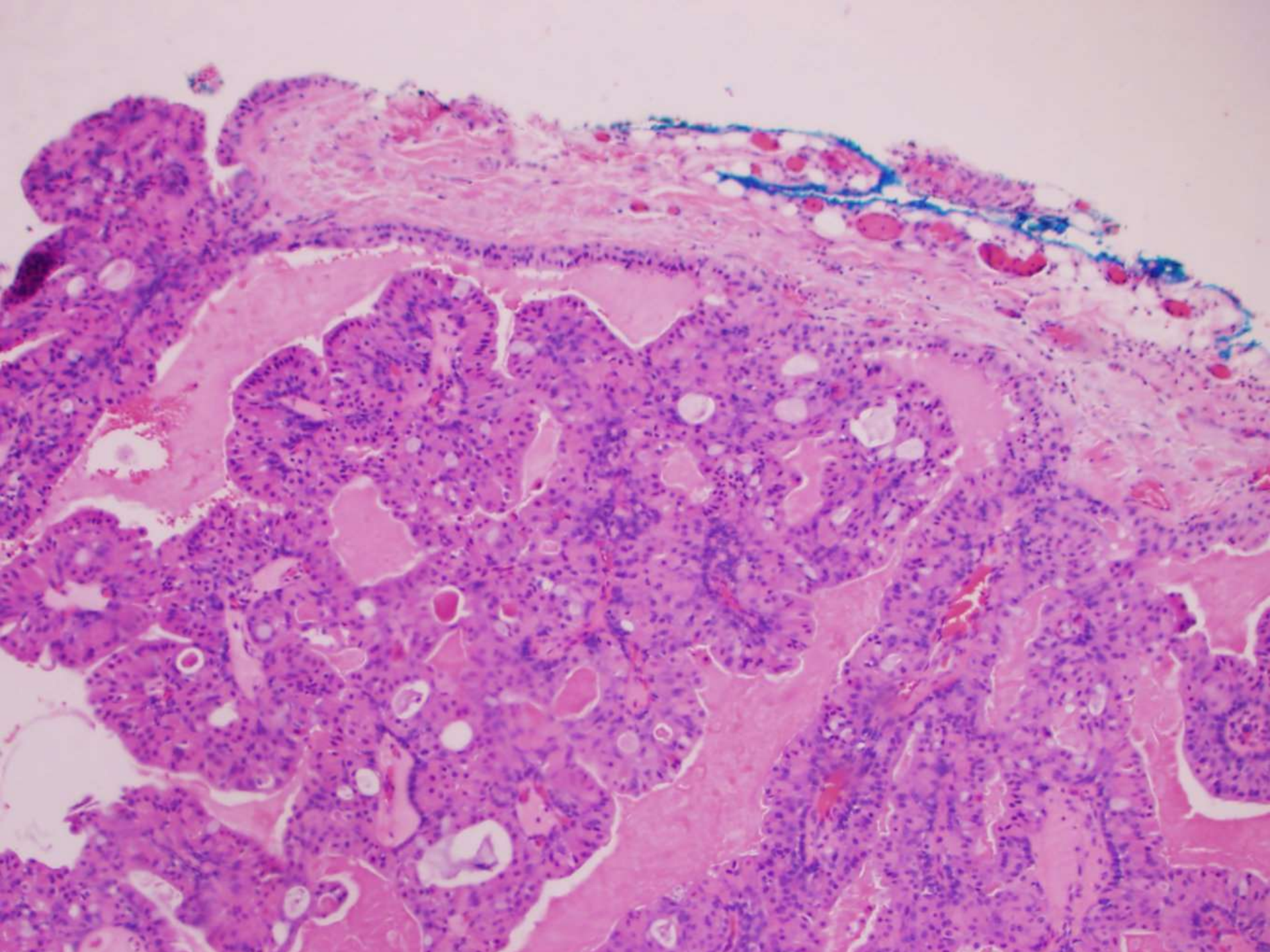




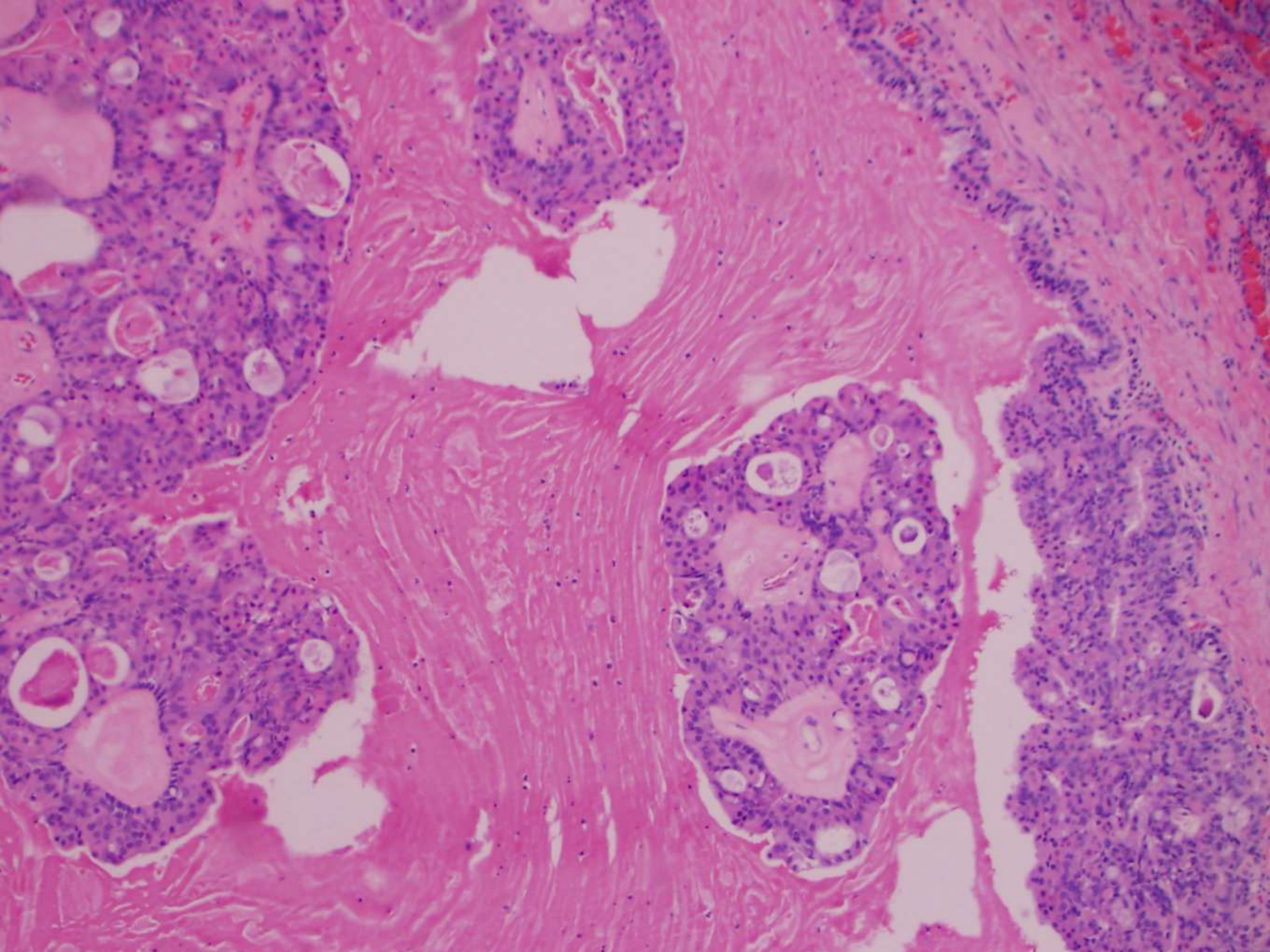




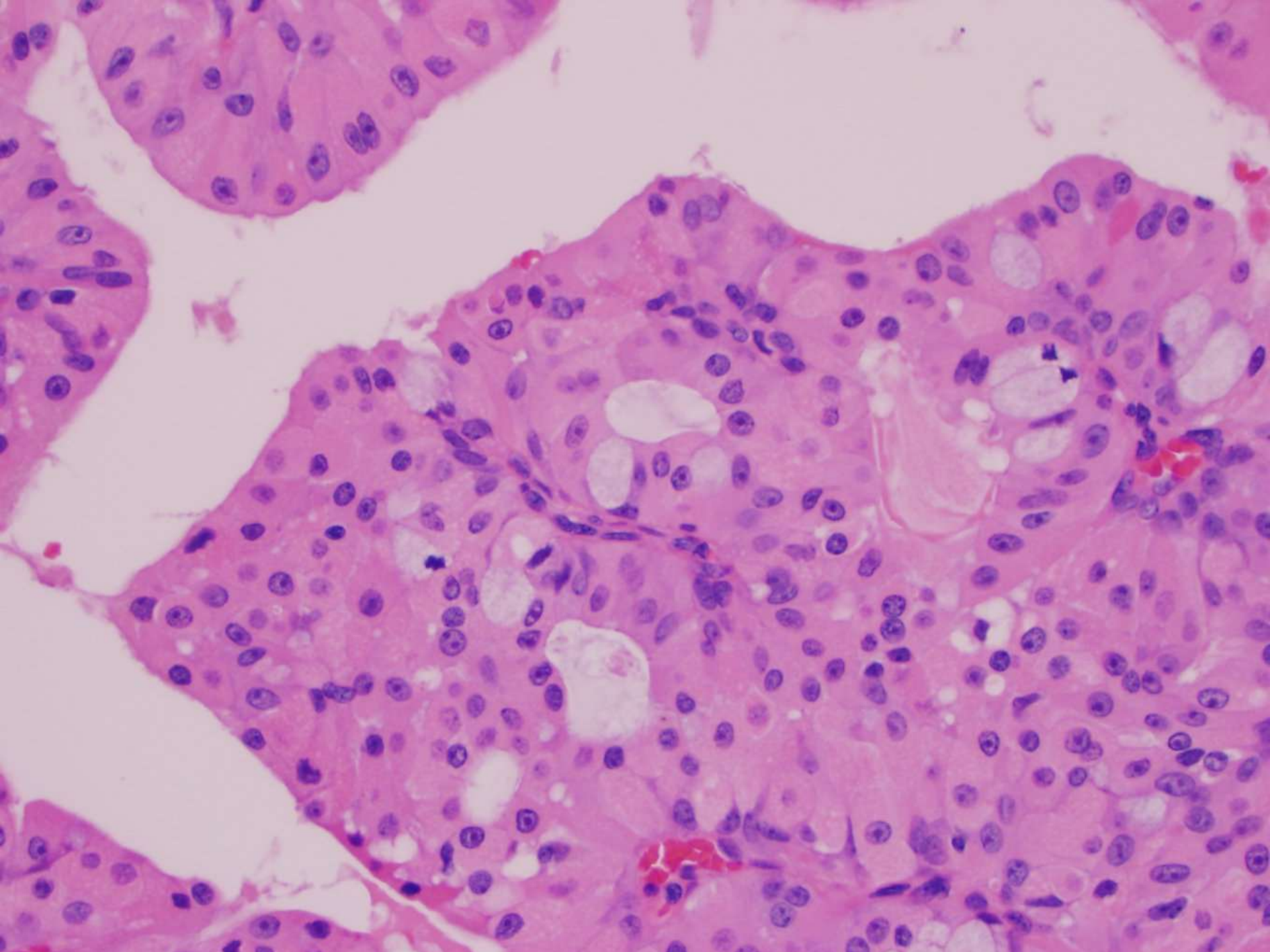




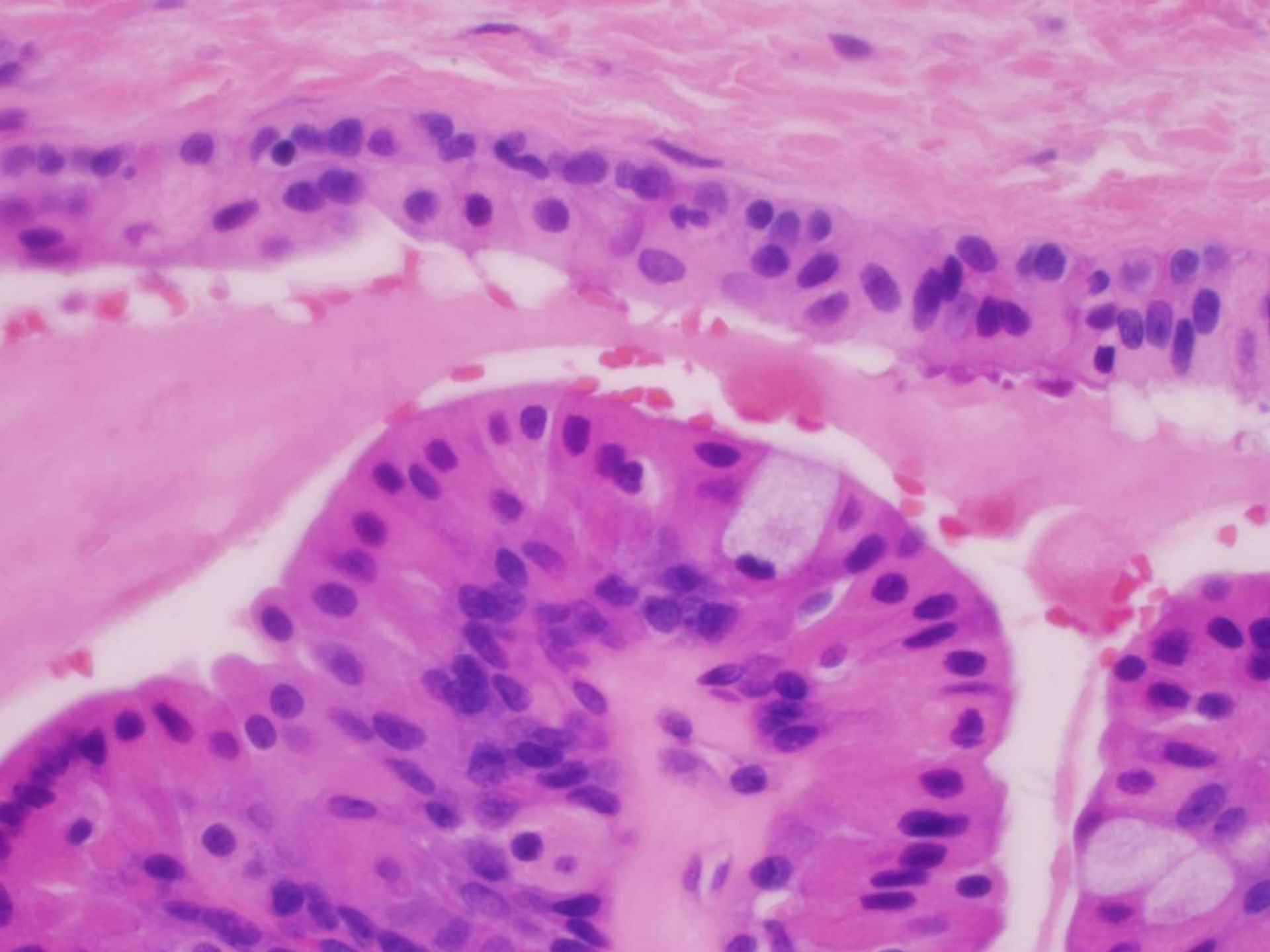




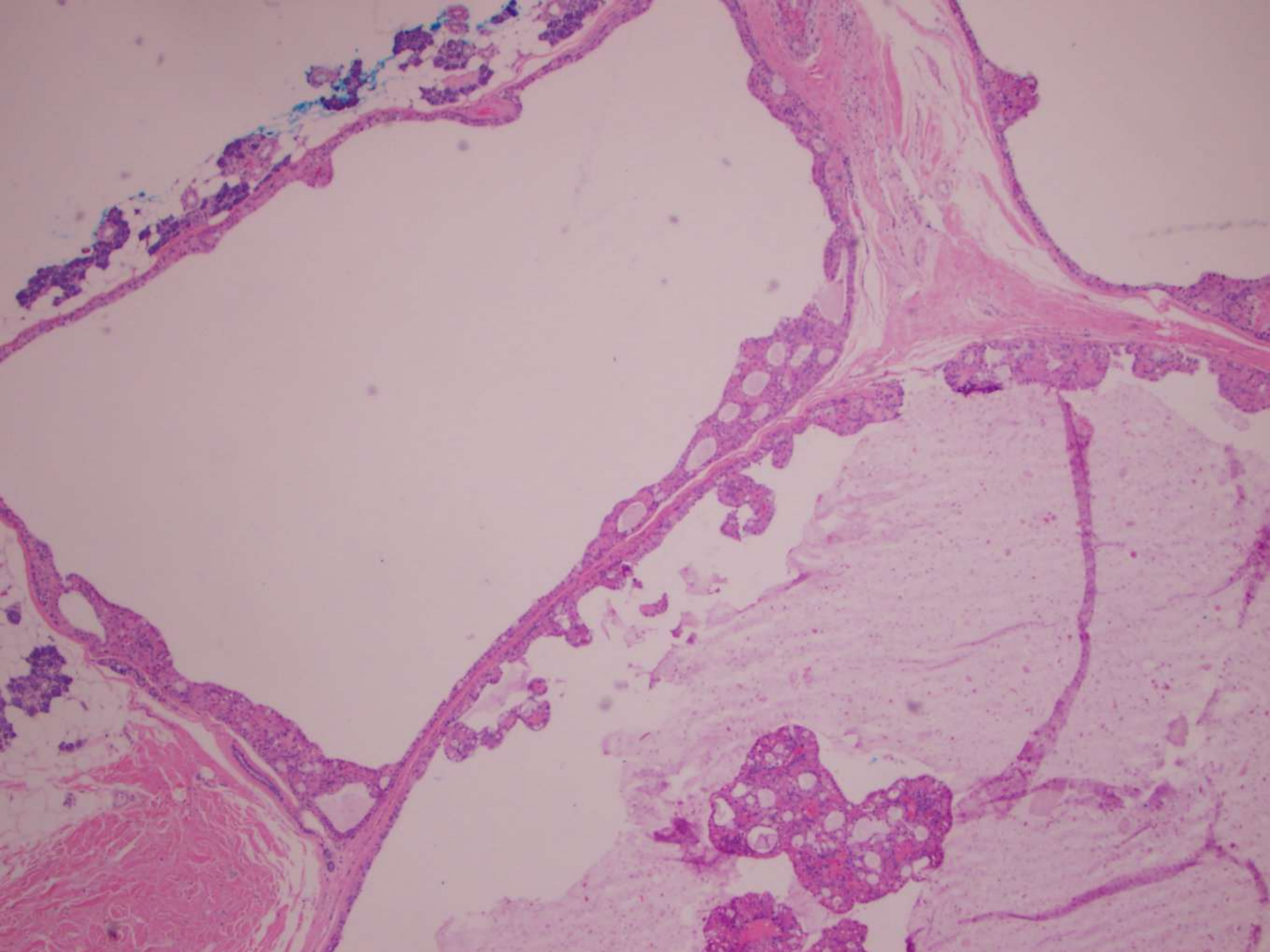




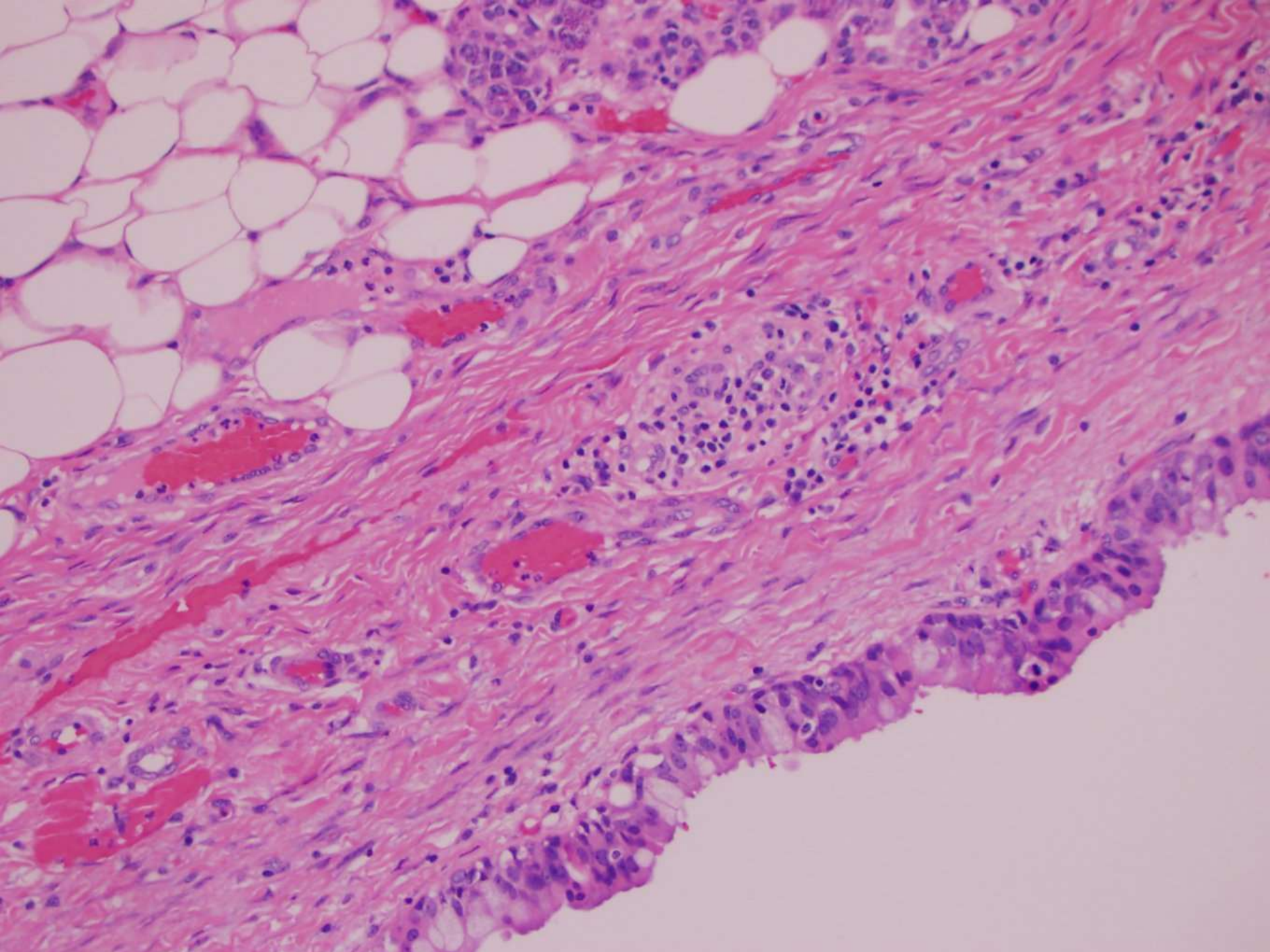








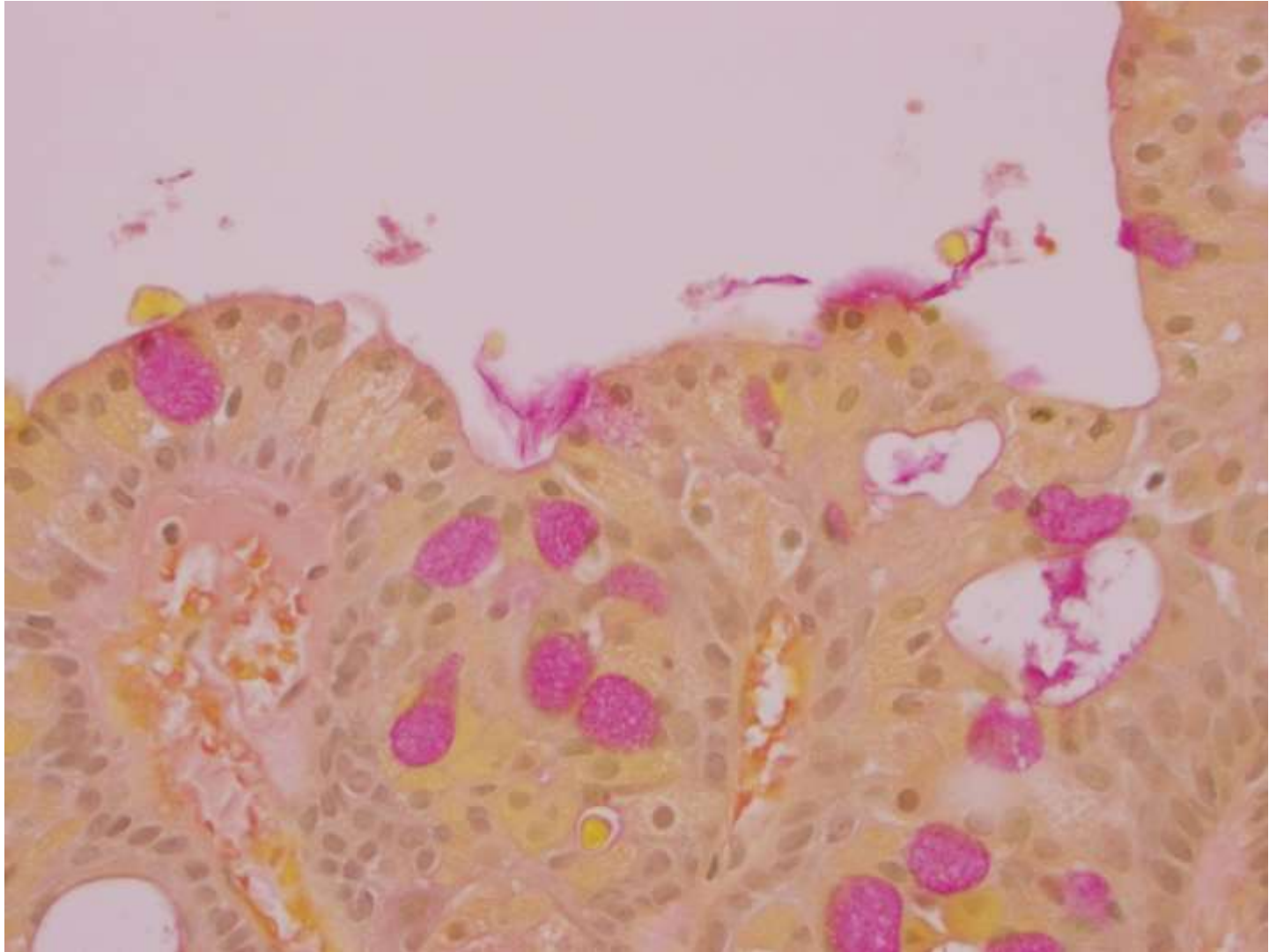


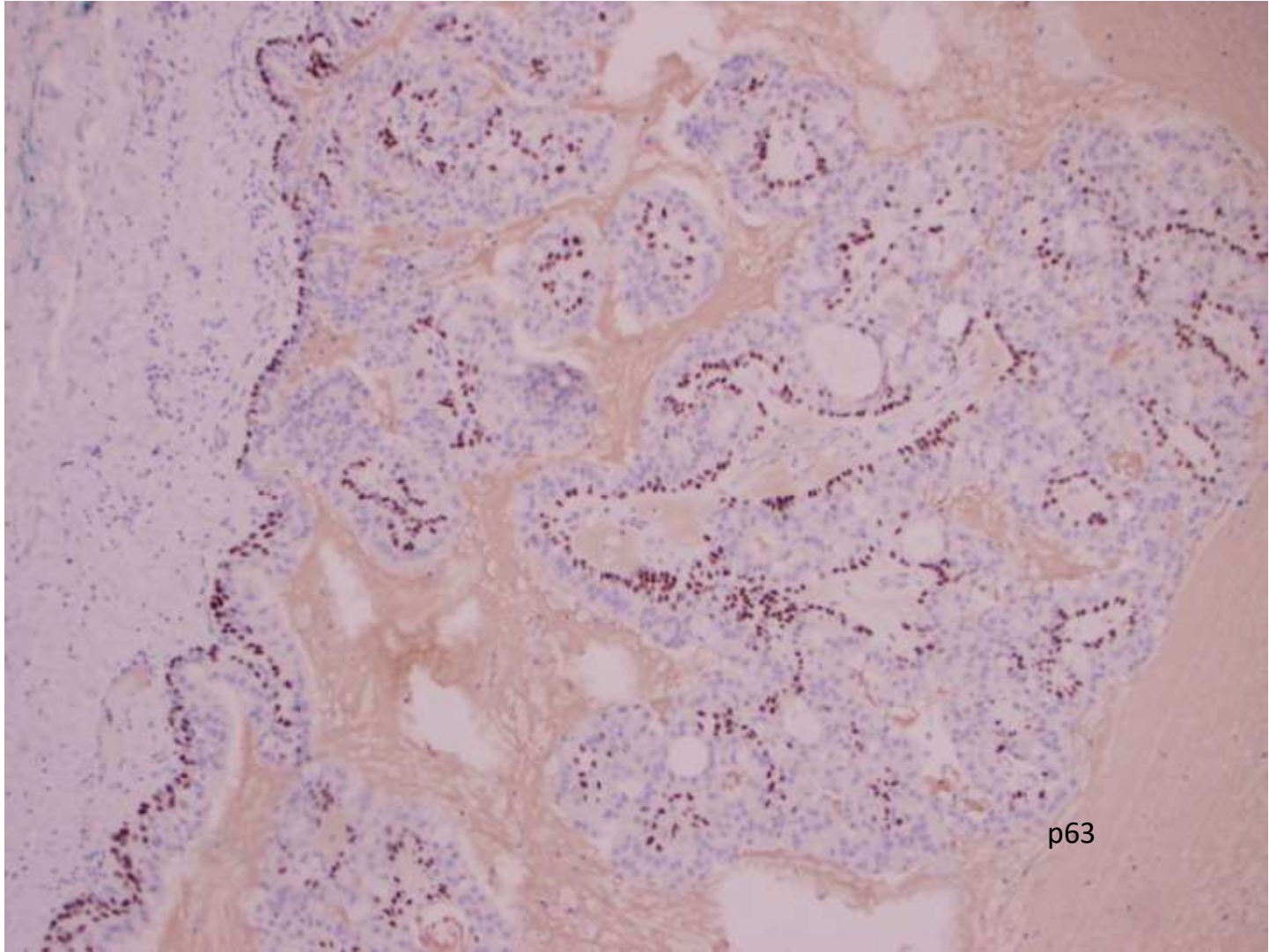


# Differential Diagnosis

- Oncocytic variant of mucoepidermoid carcinoma
- Intraductal papilloma
- Warthin's tumor
- Oncocytoma
- Oncocytic papillary cystadenoma

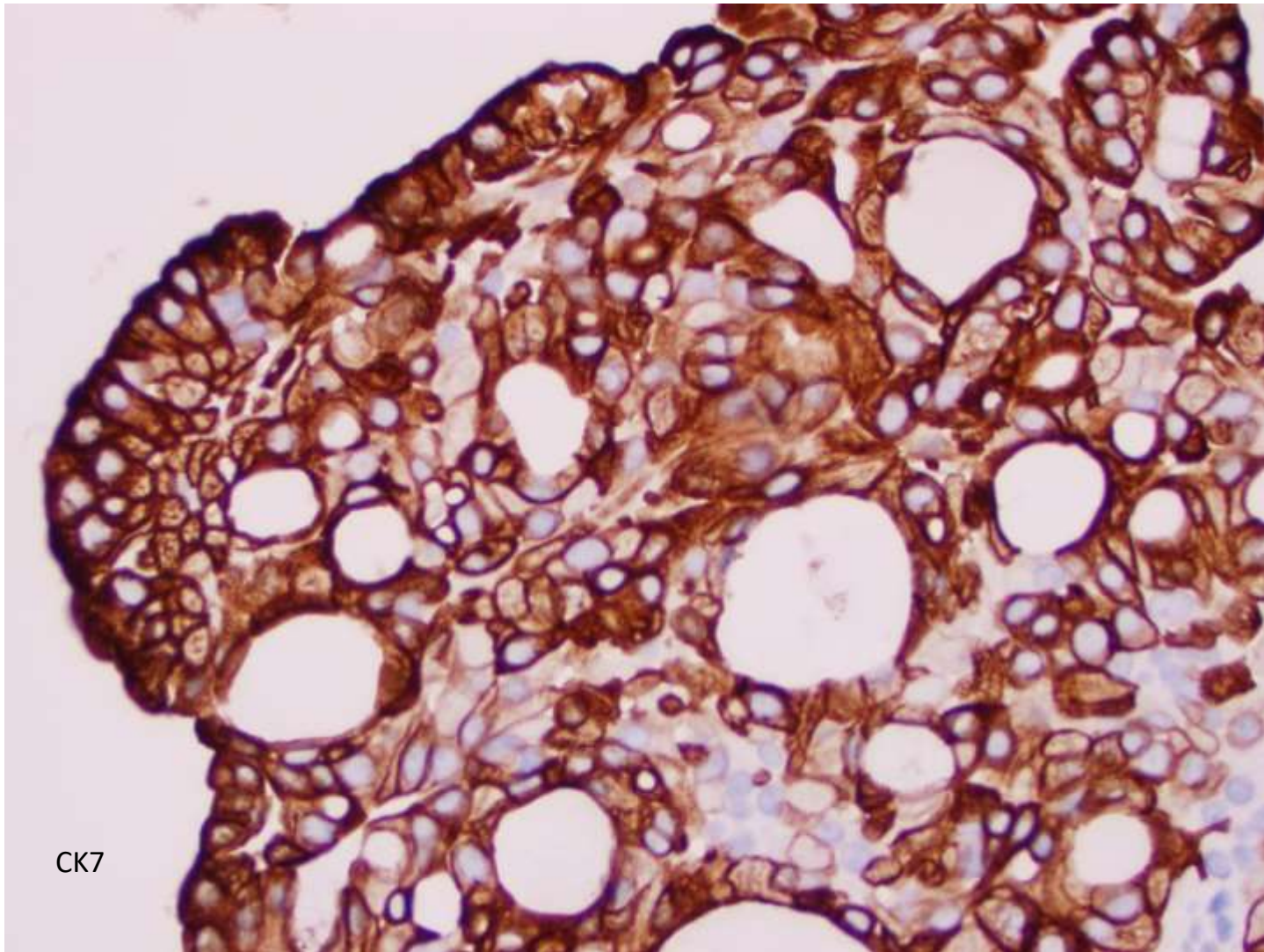






p63





# Oncocytic Papillary Cystadenoma with Mucinous Differentiation

- Cystadenomas are uncommon benign neoplasms
- Usually occur in minor salivary glands
- Extremely rare in major salivary glands
- Multilocular cystic neoplasm with papillary projections
- May have oncocytic features
- Mucinous differentiation rarely reported in association with oncocytic features



# Most important mimic=oncocytic mucoepidermoid carcinoma

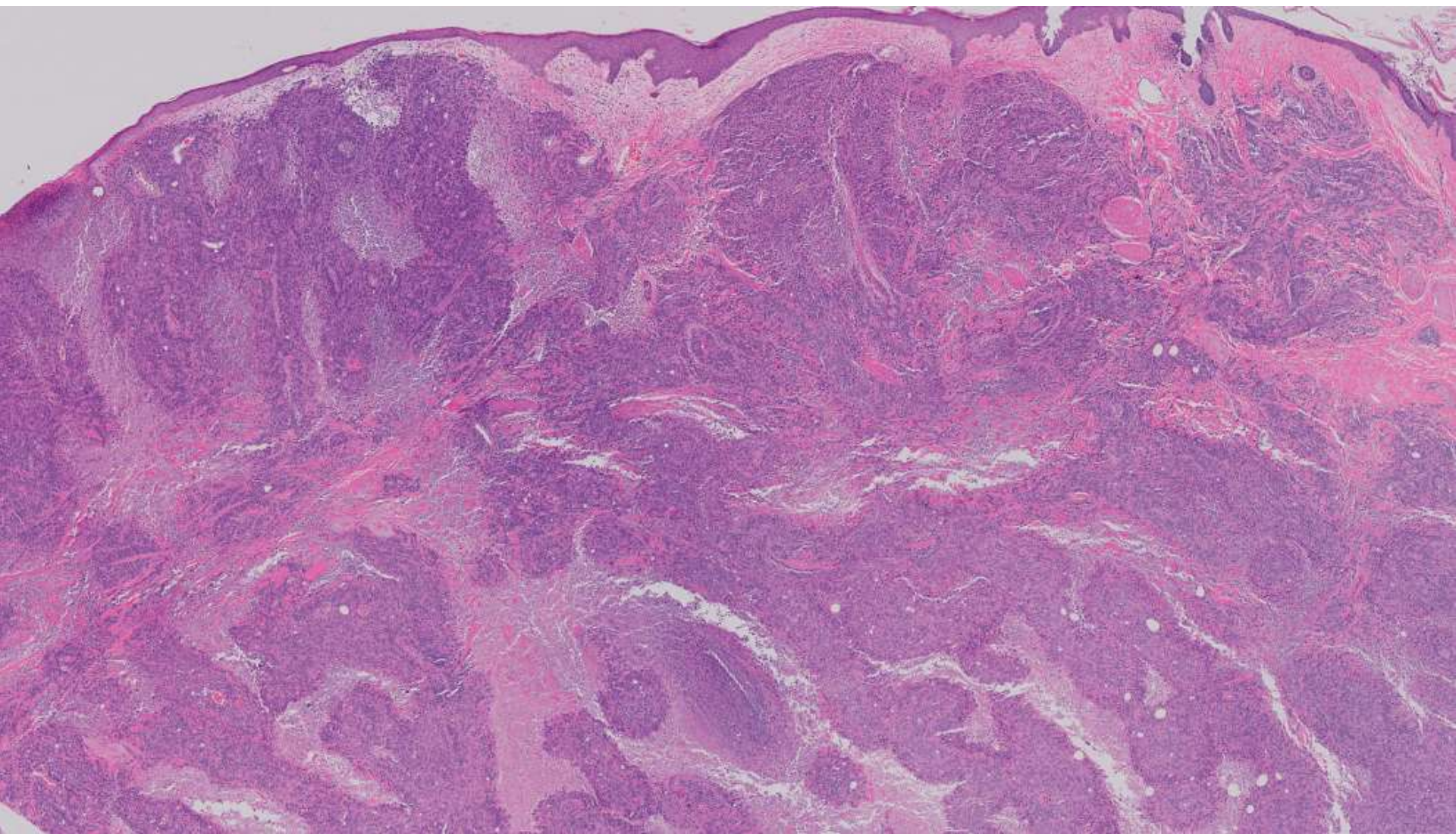
- OPC lacks aggressive growth pattern
- No clearcut squamous differentiation
- No rearrangement of MAML2 gene region

# 20-1105

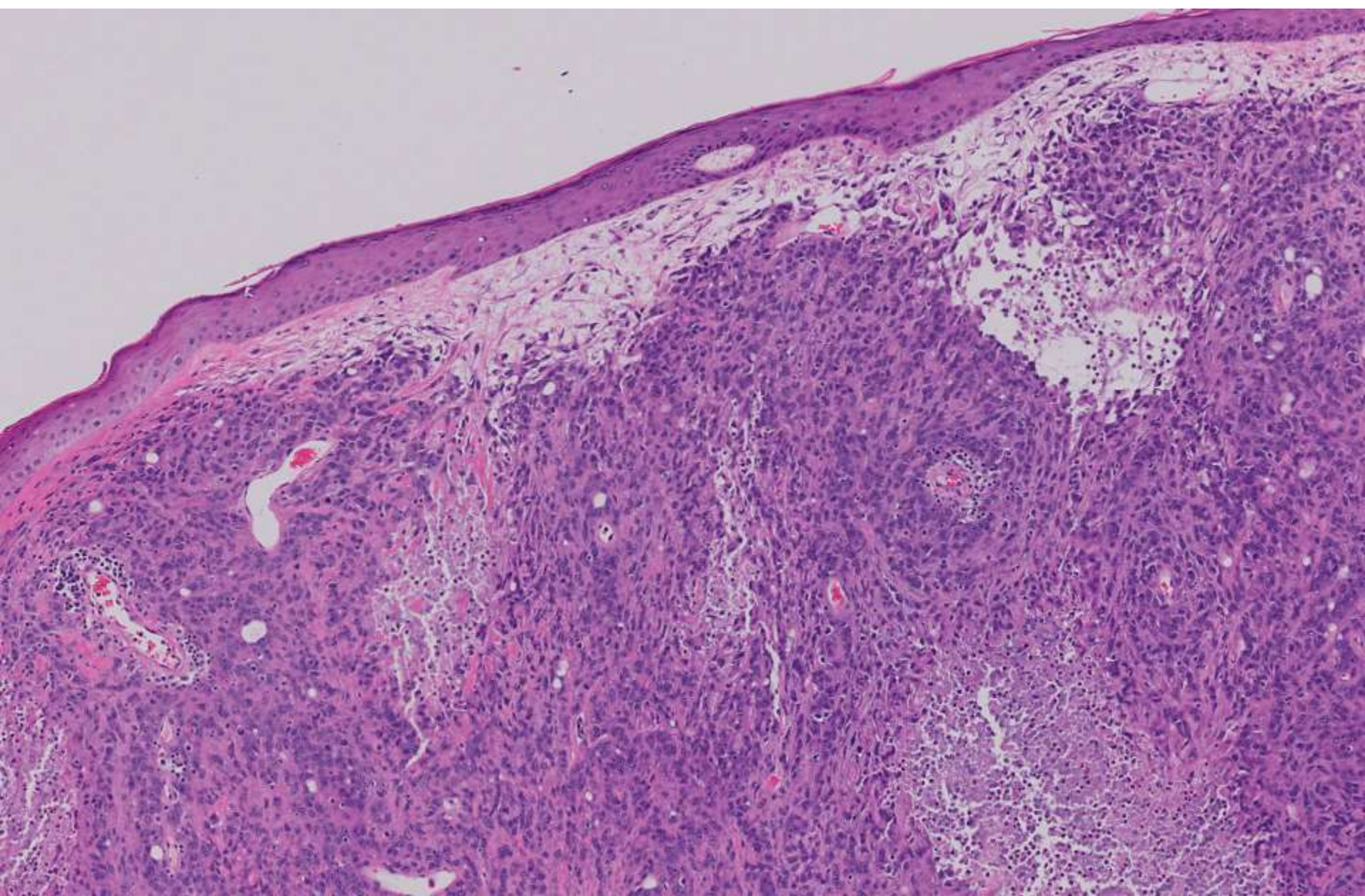
**Angus Toland/Hannes Vogel; Stanford**

87-year-old F with h/o occipital tumor arising from falx and invading overlying skin. Dural component has been stable since 2018 with increased nodularity and dehiscence of the dermal component.

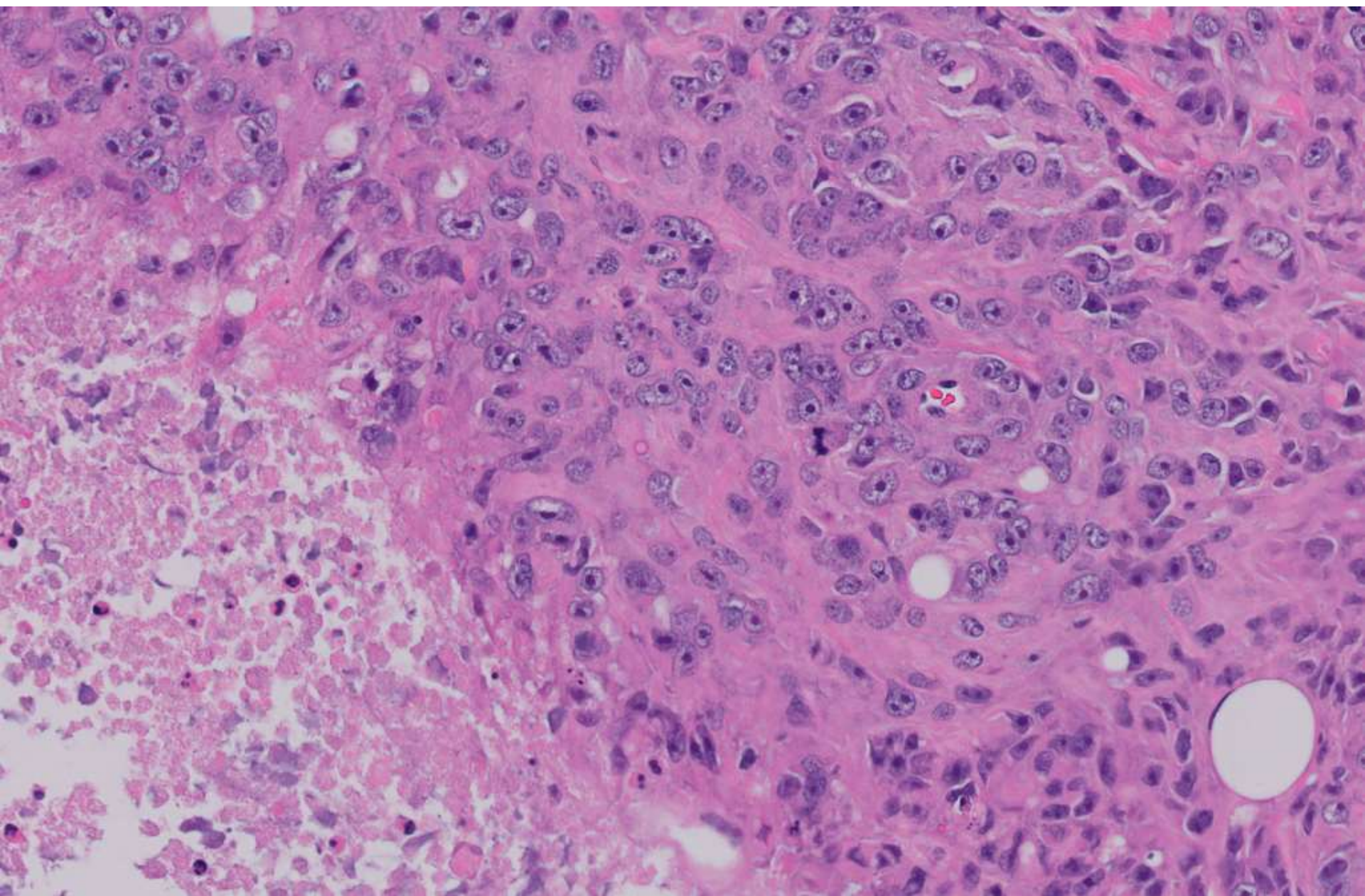




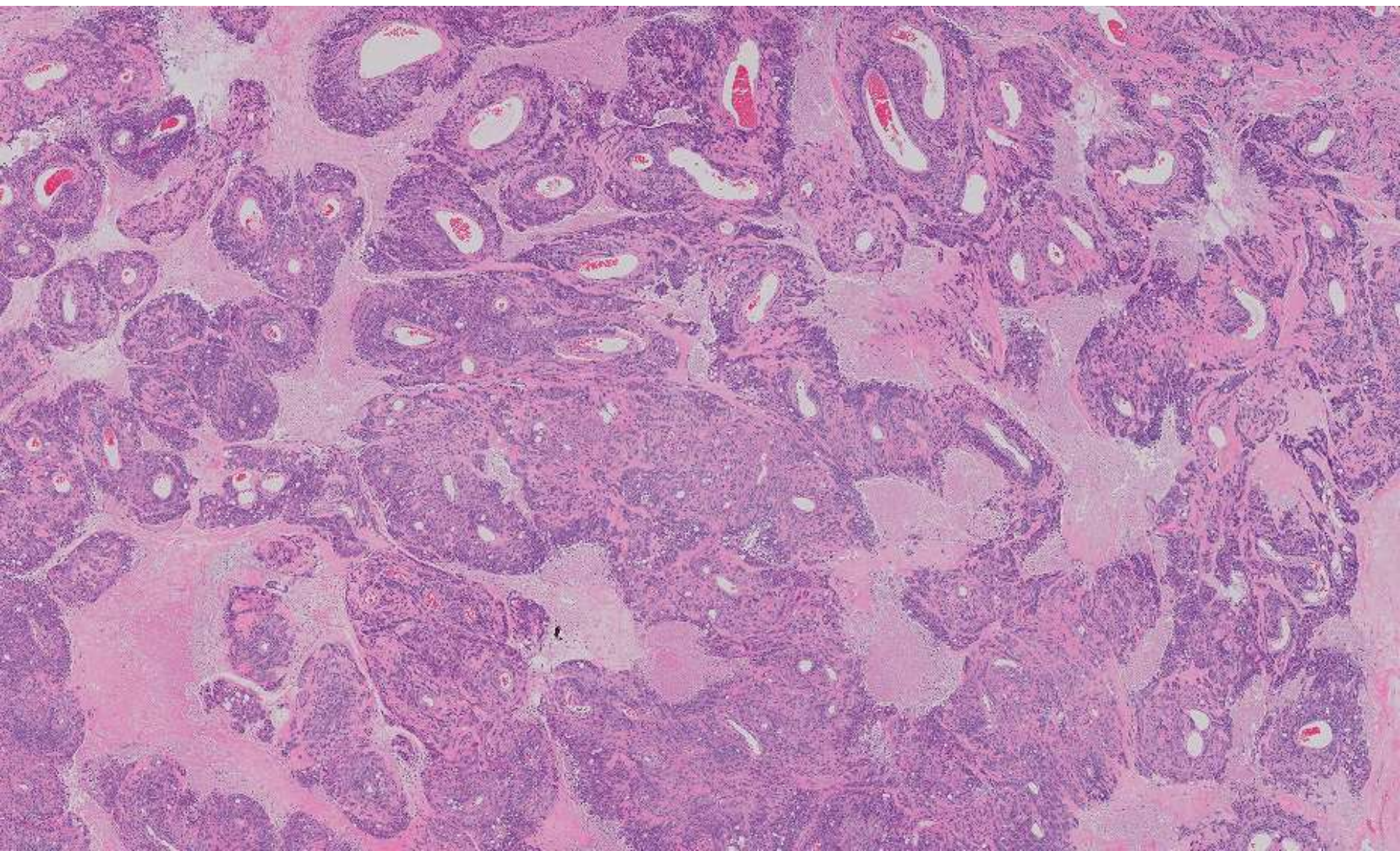




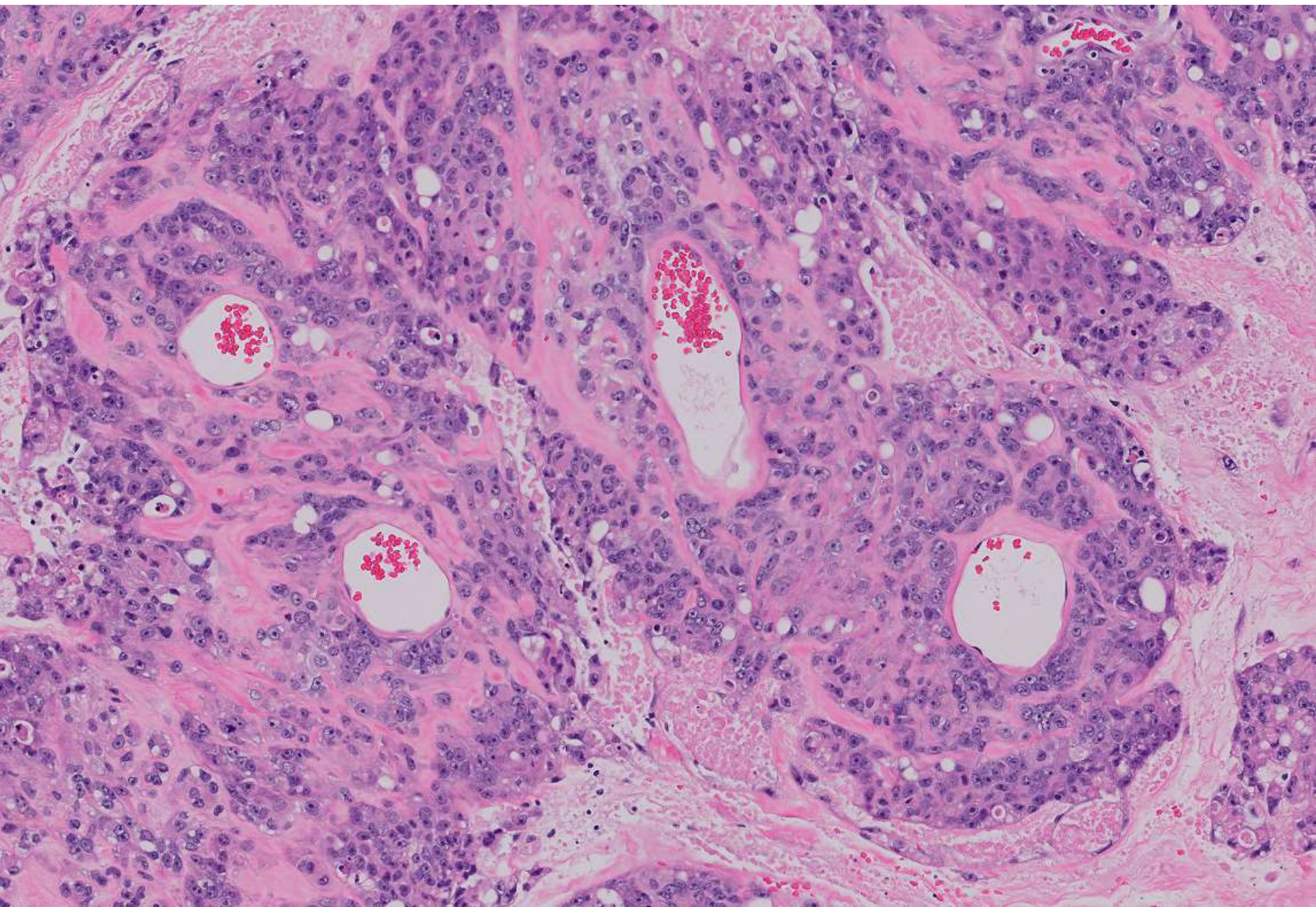








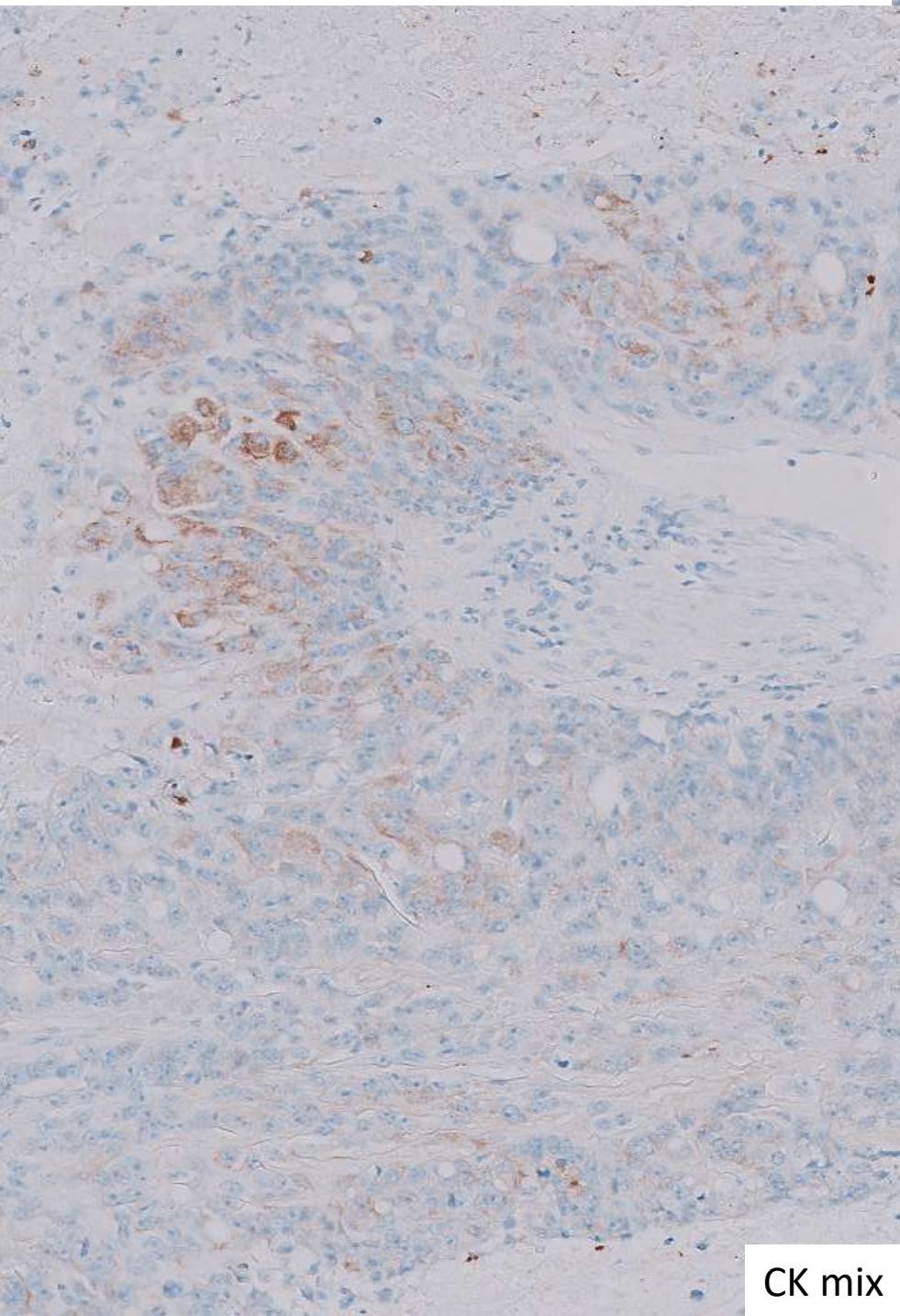




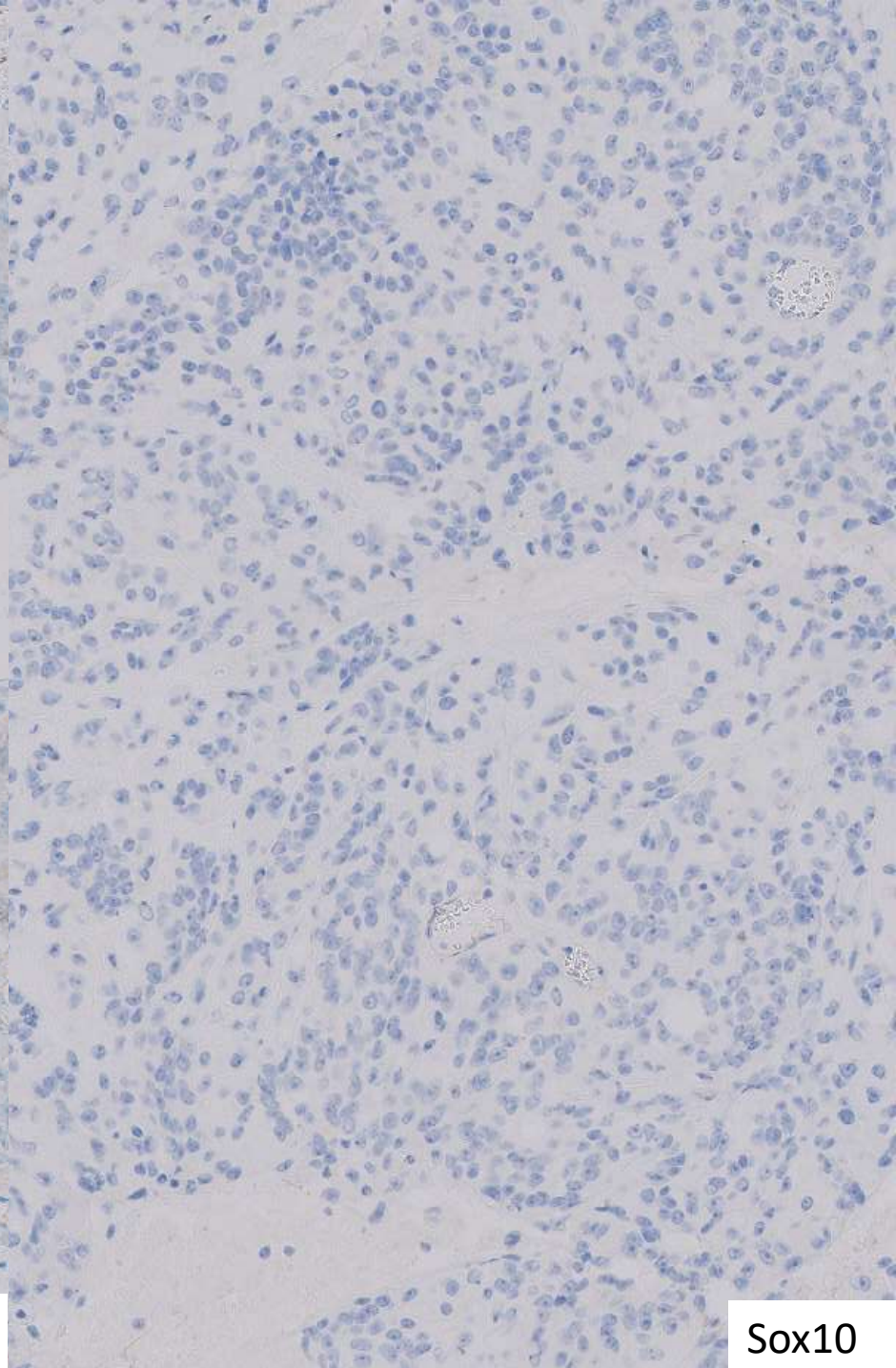






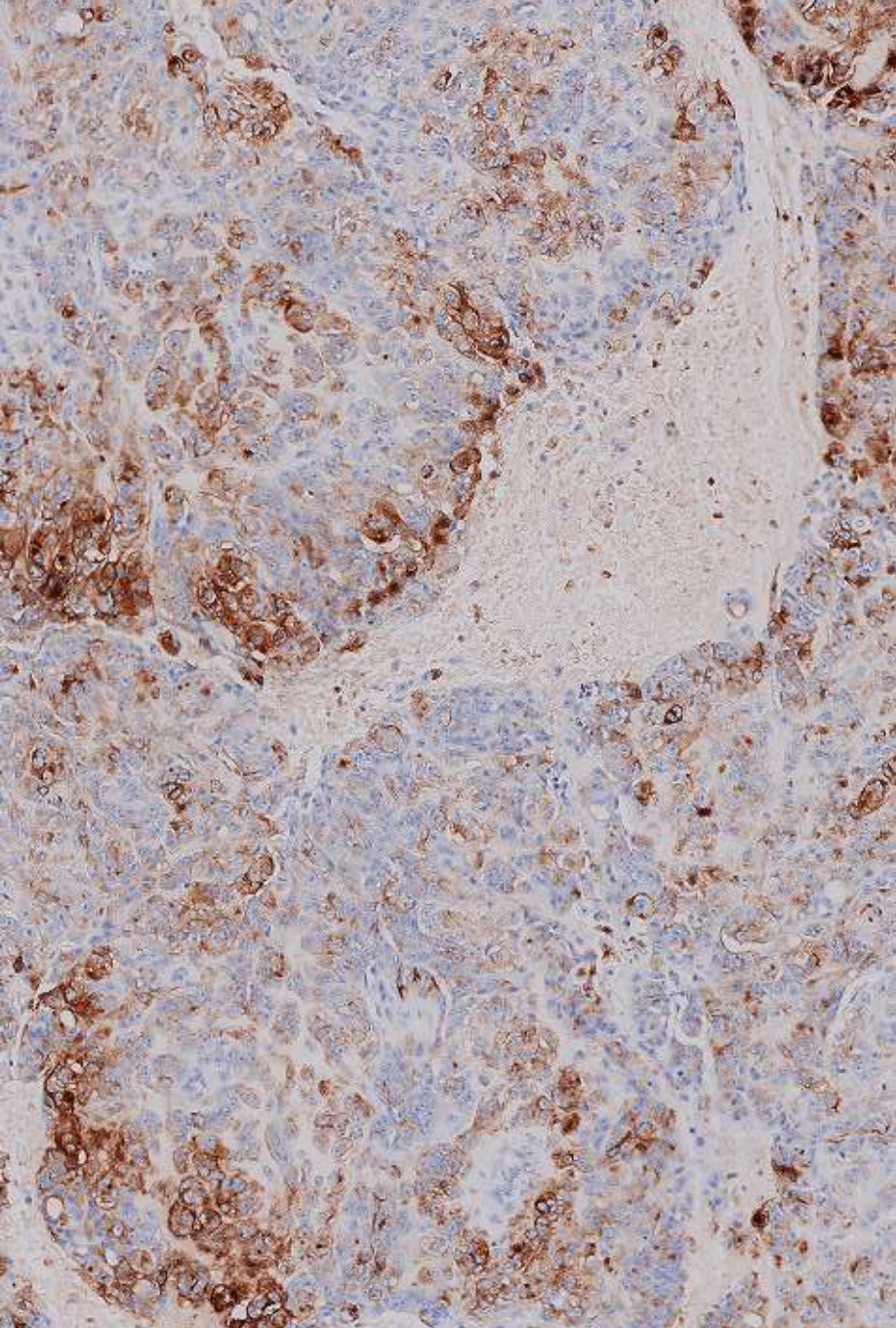


CK mix

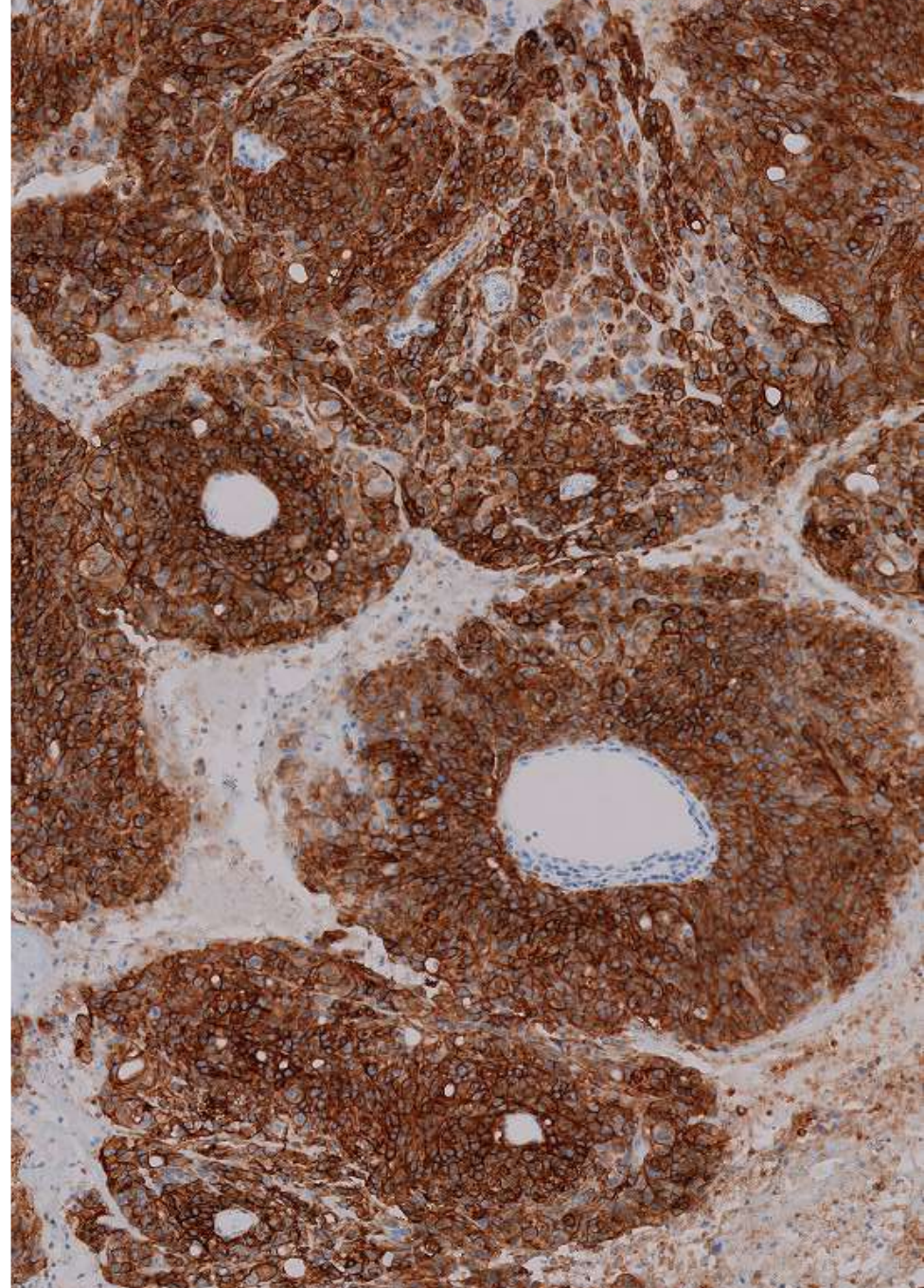


Sox10





EMA



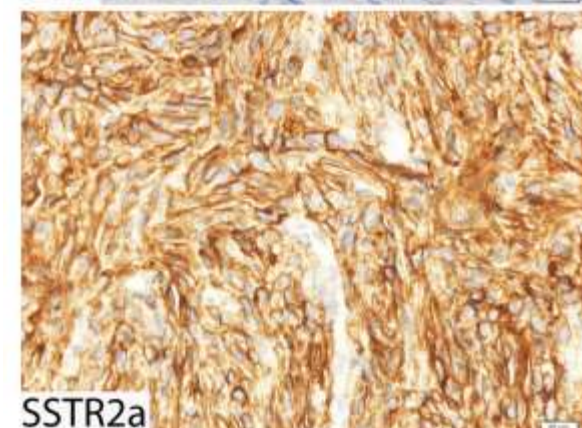
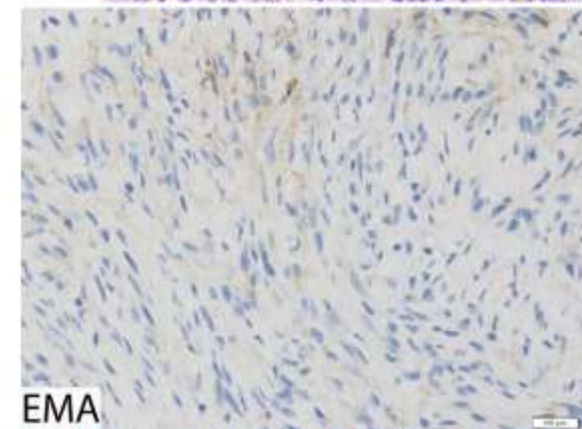
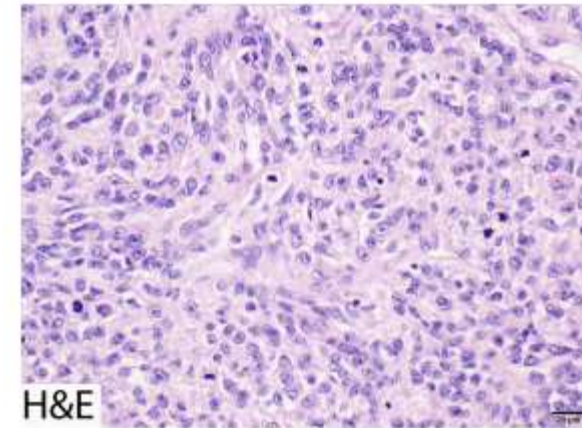
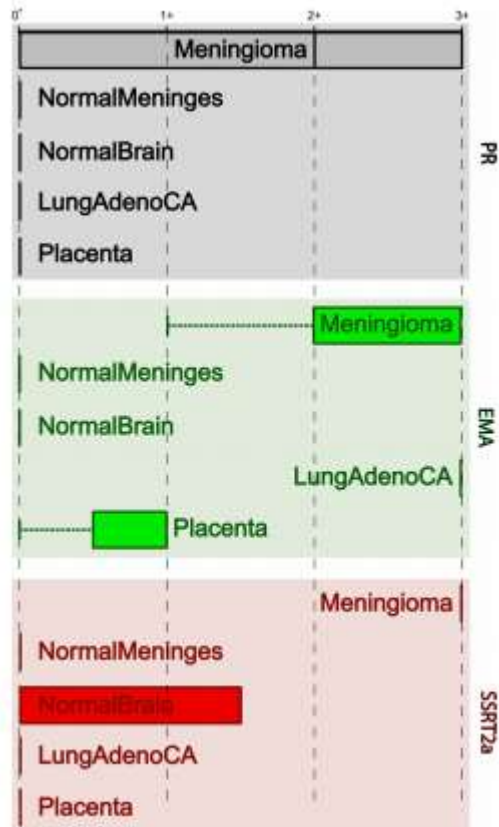
SSTR2



CORRESPONDENCE

# Somatostatin receptor 2a is a more sensitive diagnostic marker of meningioma than epithelial membrane antigen

Joshua R. Menke<sup>1</sup> · David R. Raleigh<sup>2</sup> · Allen M. Gown<sup>4</sup> · Sean Thomas<sup>3</sup> ·  
 Arie Perry<sup>1</sup> · Tarik Tihan<sup>1</sup>



# Papillary meningioma, WHO grade 3

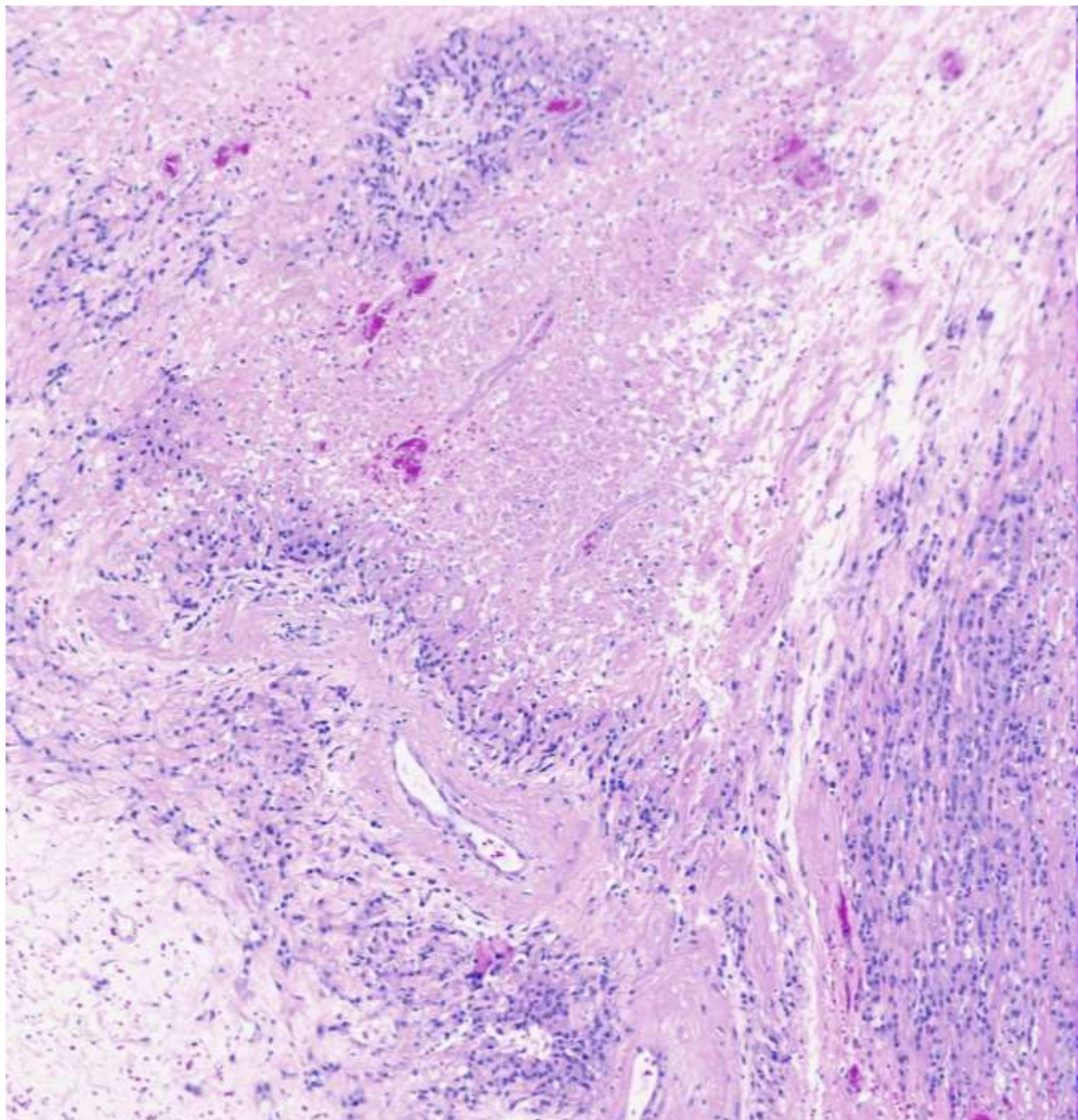
- Rare, aggressive grade-defining subtype of meningioma
- Characterized by fibrovascular cores with surrounding neoplastic cells (predominant pattern)
  - Often demonstrates other high-grade features such as increased mitotic activity, necrosis, prominent nucleoli, and rhabdoid morphology
- ~20% metastasize; ~50% of all patients succumb to disease



2011-Atypical  
meningioma, WHO grade 2

2014-Atypical  
meningioma, WHO grade 2  
with focal rhabdoid  
features

2015-Atypical  
meningioma, WHO grade 2





## RESEARCH ARTICLE

# High Incidence of Activating *TERT* Promoter Mutations in Meningiomas Undergoing Malignant Progression

Stéphane Goutagny<sup>1,2\*</sup>; Jean C. Nault<sup>2\*</sup>; Maxime Mallet<sup>2</sup>; Dominique Henin<sup>3,4</sup>; Jessica Z. Rossi<sup>2,5,6</sup>; Michel Kalamarides<sup>2,7,8</sup>

<sup>1</sup> Assistance Publique-Hôpitaux de Paris, Department of Neurosurgery, Hôpital Beaujon, Clichy, <sup>2</sup> INSERM, Génomique Fonctionnelle des Tumeurs Solides, IUH, <sup>3</sup> Assistance Publique-Hôpitaux de Paris, Department of Neuropathology, Hôpital Bichat, <sup>4</sup> Faculté de Médecine, Université Paris Diderot, <sup>5</sup> Labex Immuno-oncology, Sorbonne Paris Cité, Faculté de Médecine, Université Paris Descartes, <sup>6</sup> Assistance Publique-Hôpitaux de Paris, Hôpital Européen Georges Pompidou, <sup>7</sup> Assistance Publique-Hôpitaux de Paris, Hôpital Pitié Salpêtrière, <sup>8</sup> Faculté de Médecine, Université Pierre et Marie Curie, Paris, France.

**Table 2.** Comparison between *TERT*-mutated and nonmutated meningiomas. Abbreviation: WHO = World Health Organization.

	<i>TERT</i> promoter-mutated patients n = 6	<i>TERT</i> promoter nonmutated patients n = 67	Statistical test	<i>P</i>
Progression (yes/no)	5/1 (83%)	13/54 (19%)	Fisher's exact	0.0029
Recurrence (yes/no)	5/1 (83%)	33/34 (49%)	Fisher's exact	0.2
Mean age at surgery (years)	55 ± 14	51 ± 17	Mann-Whitney	0.6
Gender (female/male)	4/2 (67%)	36/31 (54%)	Fisher's exact	0.68
Localization (skull base/nonskull base)	1/5 (17%)	15/50 (23%)	Fisher's exact	1.0
22q loss (yes/no)	5/1 (83%)	48/12 (80%)	Fisher's exact	1.0
<i>NF2</i> mutated	5/1 (83%)	38/19 (67%)	Fisher's exact	0.65
WHO grade (I/II/III)	1/5/0 (17/83/0%)	18/39/10 (27/58/15%)	$\chi^2$	0.2
Brain invasion (yes/ no/no visible brain)	1/2/3 (17/33/50%)	15/16/36 (22/24/54%)	$\chi^2$	0.9
Mitosis (mean ± SD)	5.0 ± 4.7	6.0 ± 10	Mann-Whitney	0.97
Mean fractional allele loss (14)	0.29 ± 0.07	0.21 ± 0.13	Mann-Whitney	0.05



## • References:

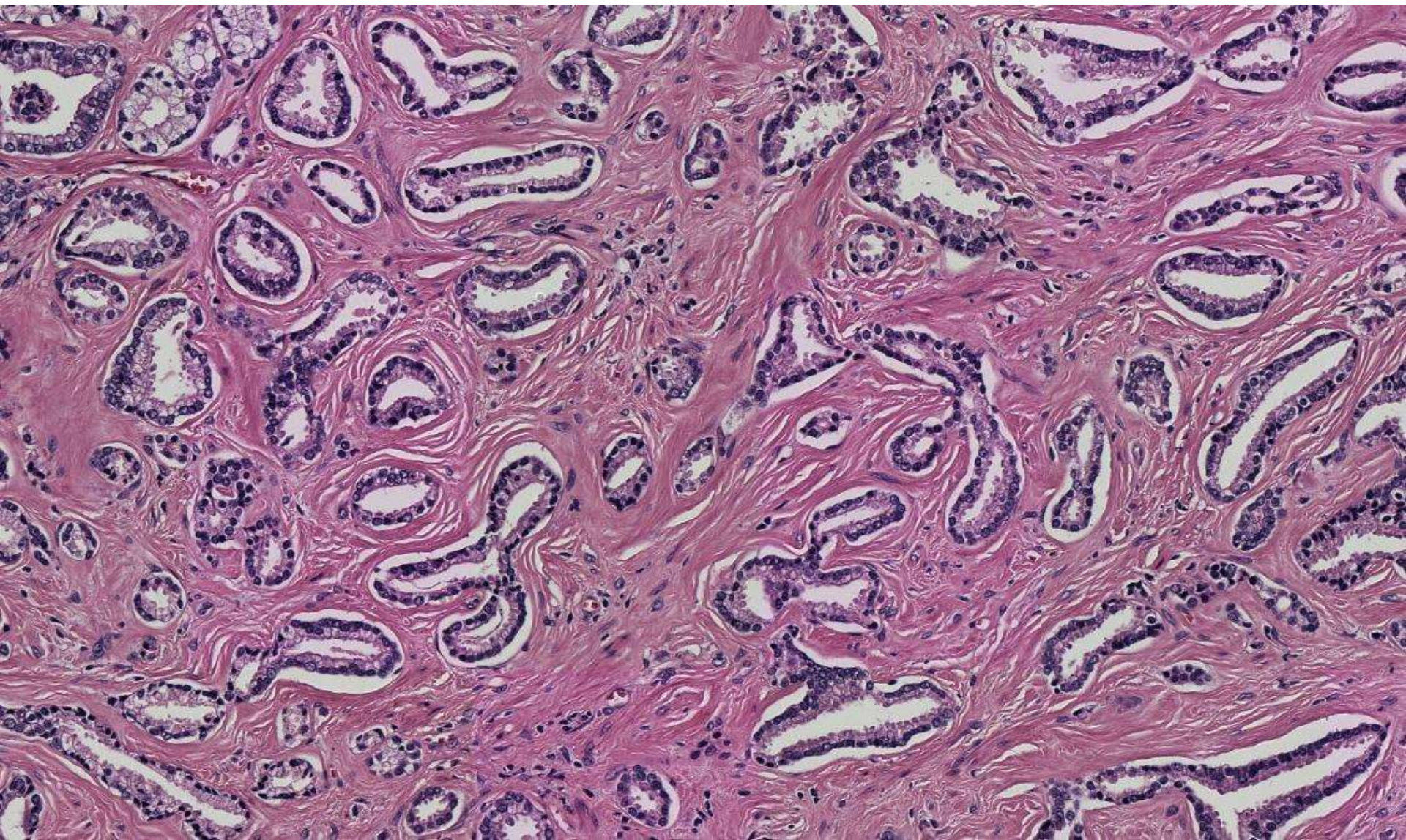
1. Menke JR, Raleigh DR, Gown AM, Thomas S, Perry A, Tihan T. Somatostatin receptor 2a is a more sensitive diagnostic marker of meningioma than epithelial membrane antigen. *Acta Neuropathol.* 2015 Sep;130(3):441-3. doi: 10.1007/s00401-015-1459-3. Epub 2015 Jul 21. PMID: 26195322.
2. Goutagny S, Nault JC, Mallet M, Henin D, Rossi JZ, Kalamarides M. High incidence of activating TERT promoter mutations in meningiomas undergoing malignant progression. *Brain Pathol.* 2014 Mar;24(2):184-9. doi: 10.1111/bpa.12110. Epub 2013 Dec 23. PMID: 24261697.

# 20-1106

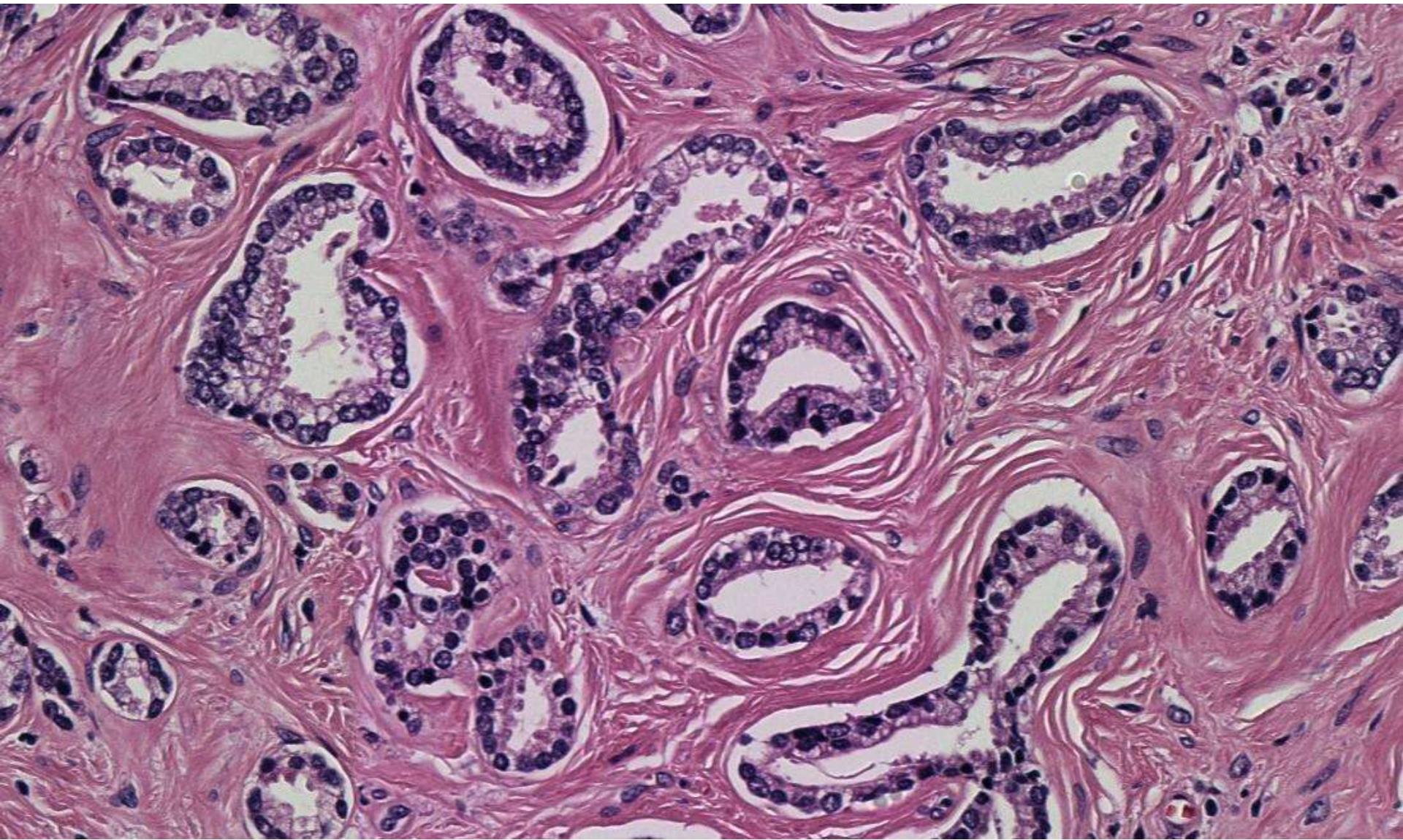
**Ankur Sangoi; El Camino Hospital**

Adult M, elevated PSA, prostate biopsy performed. Based on the images shown of the biopsy, what would be the expected outcome at the time of radical prostatectomy?

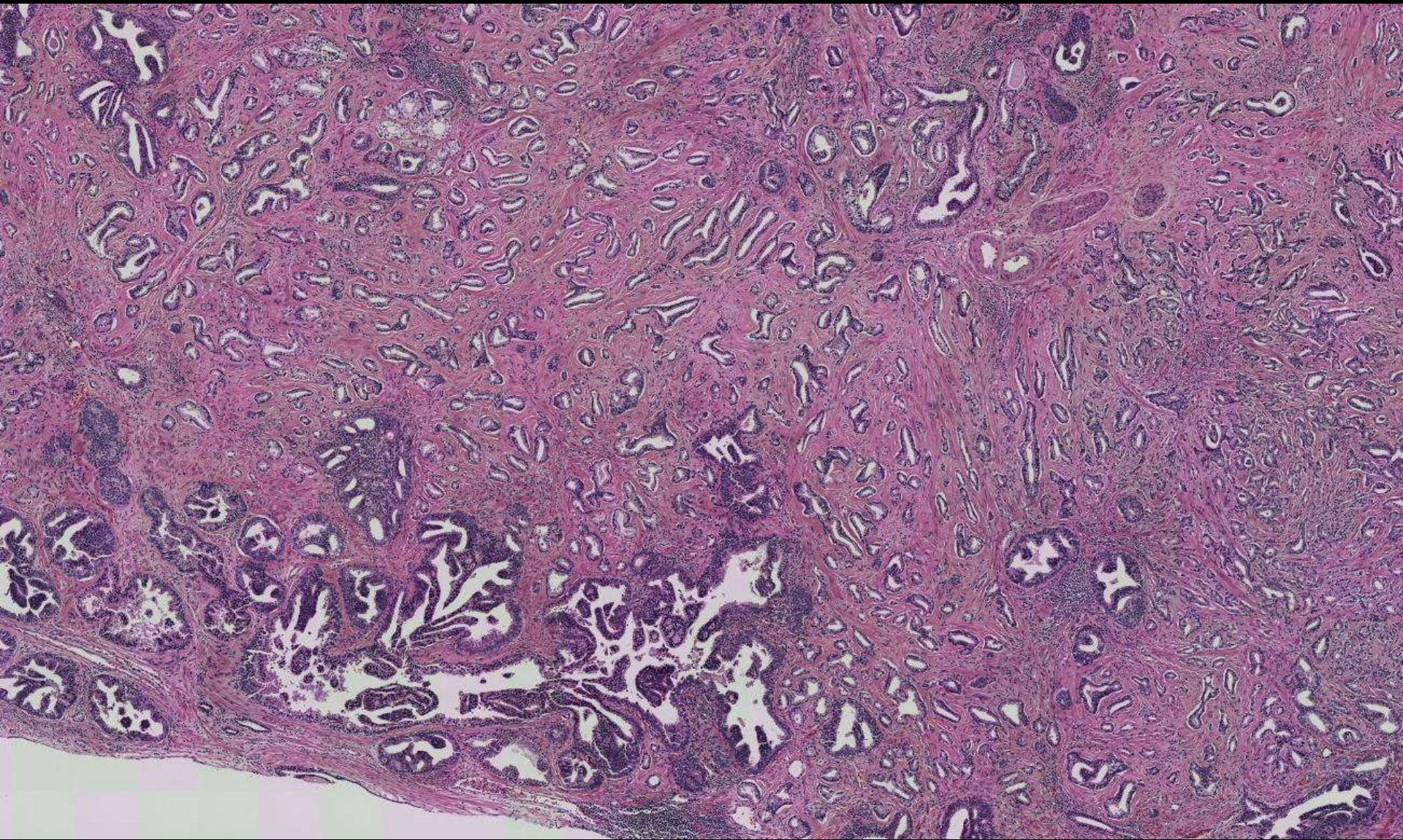




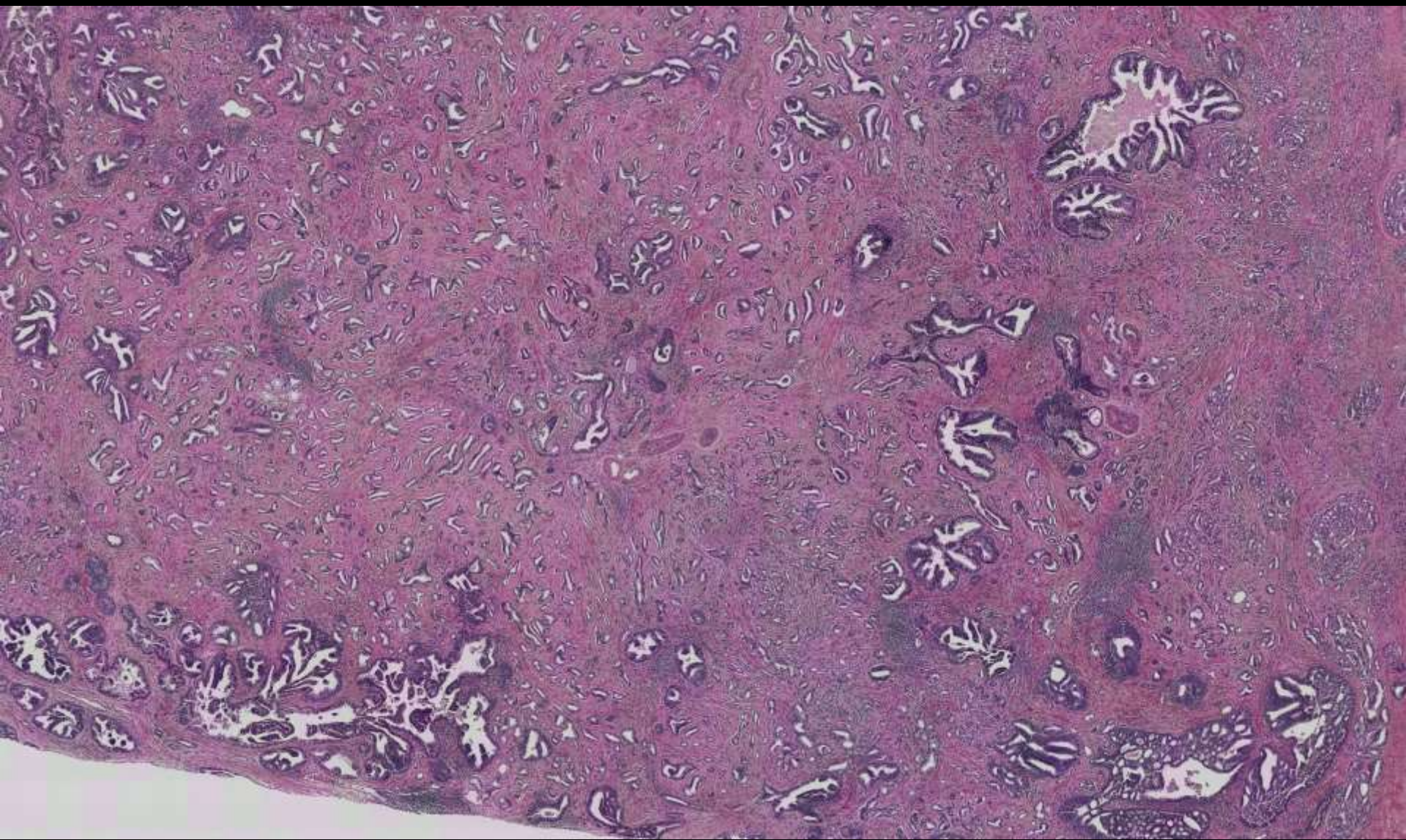




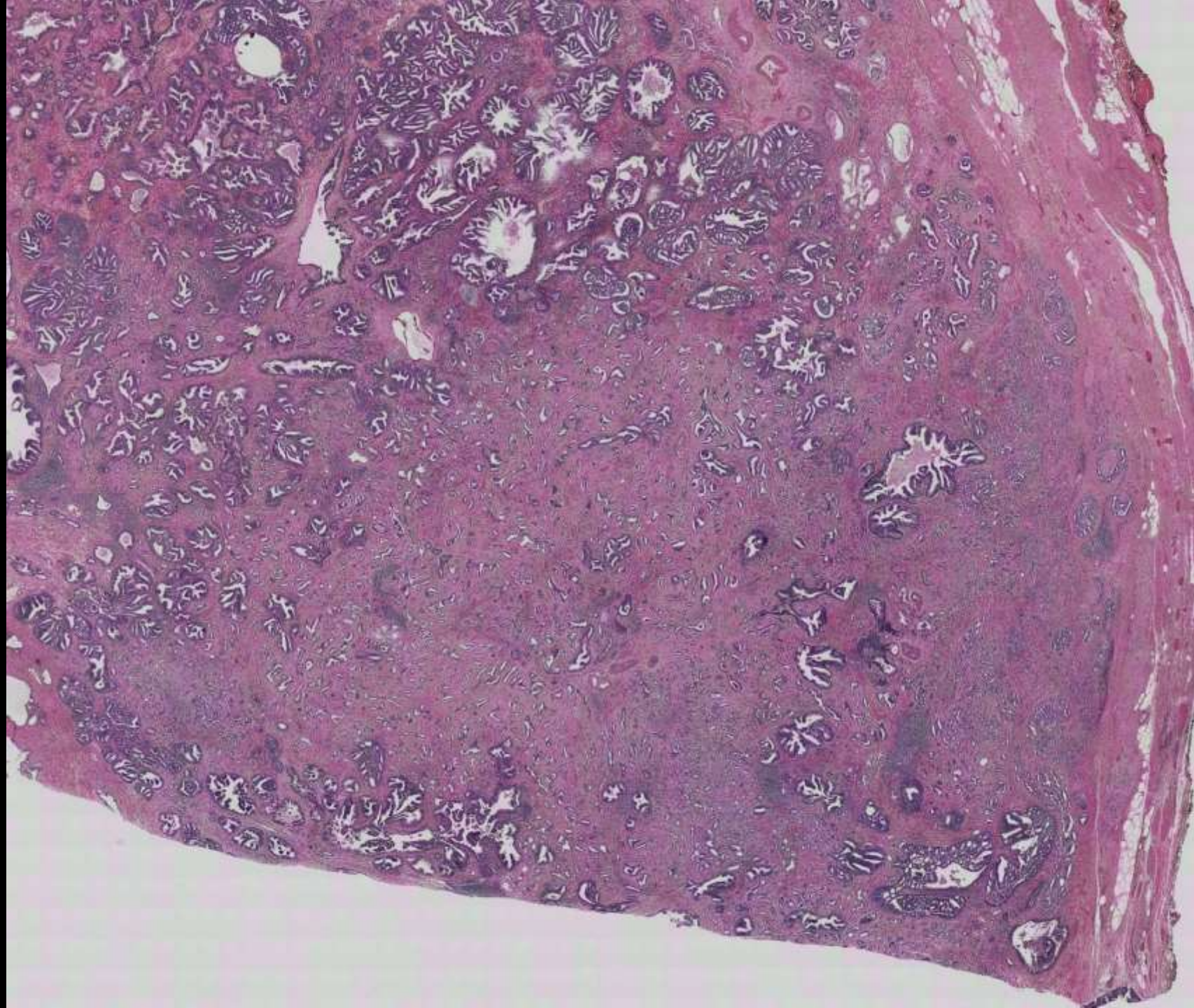




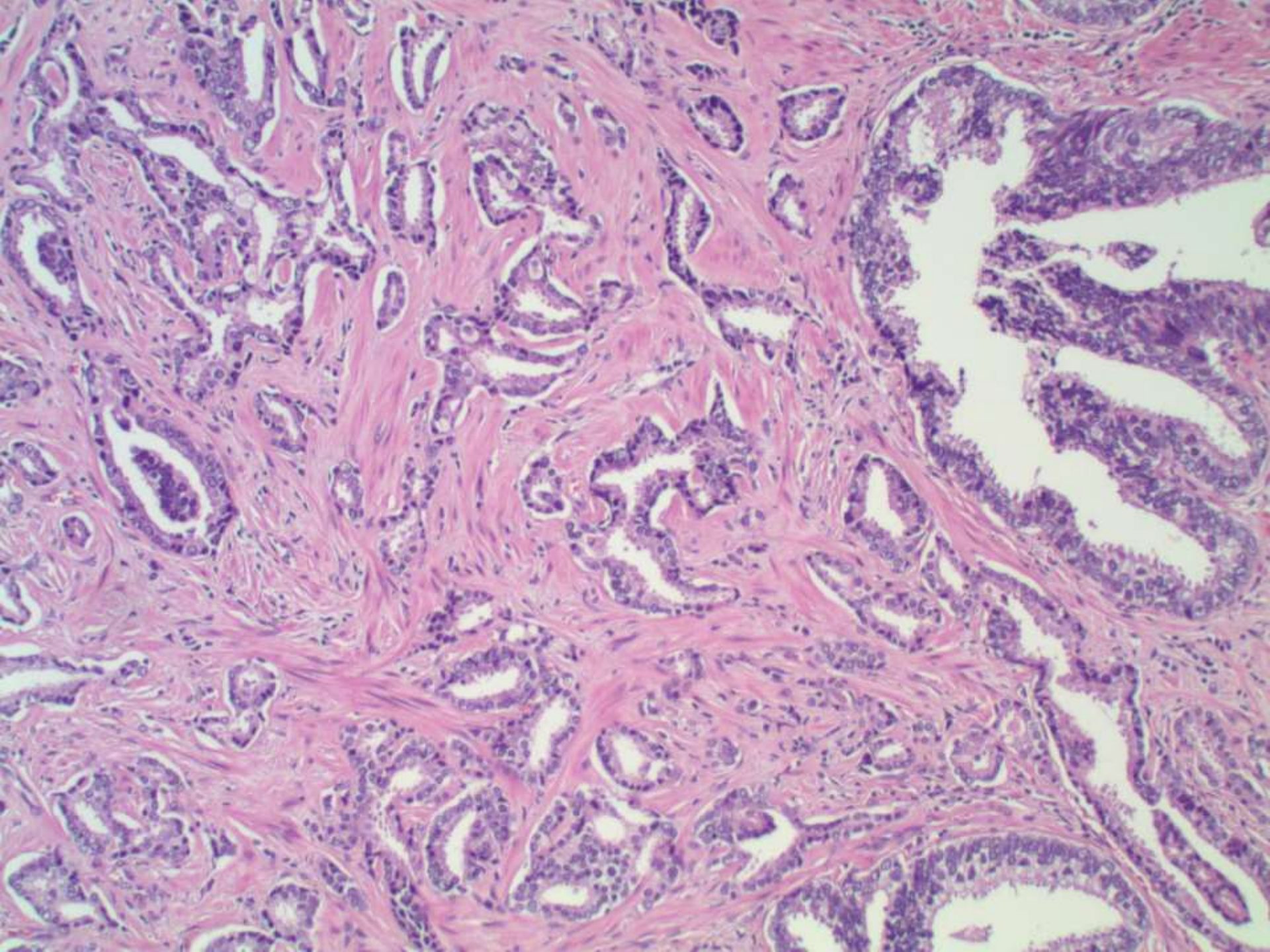






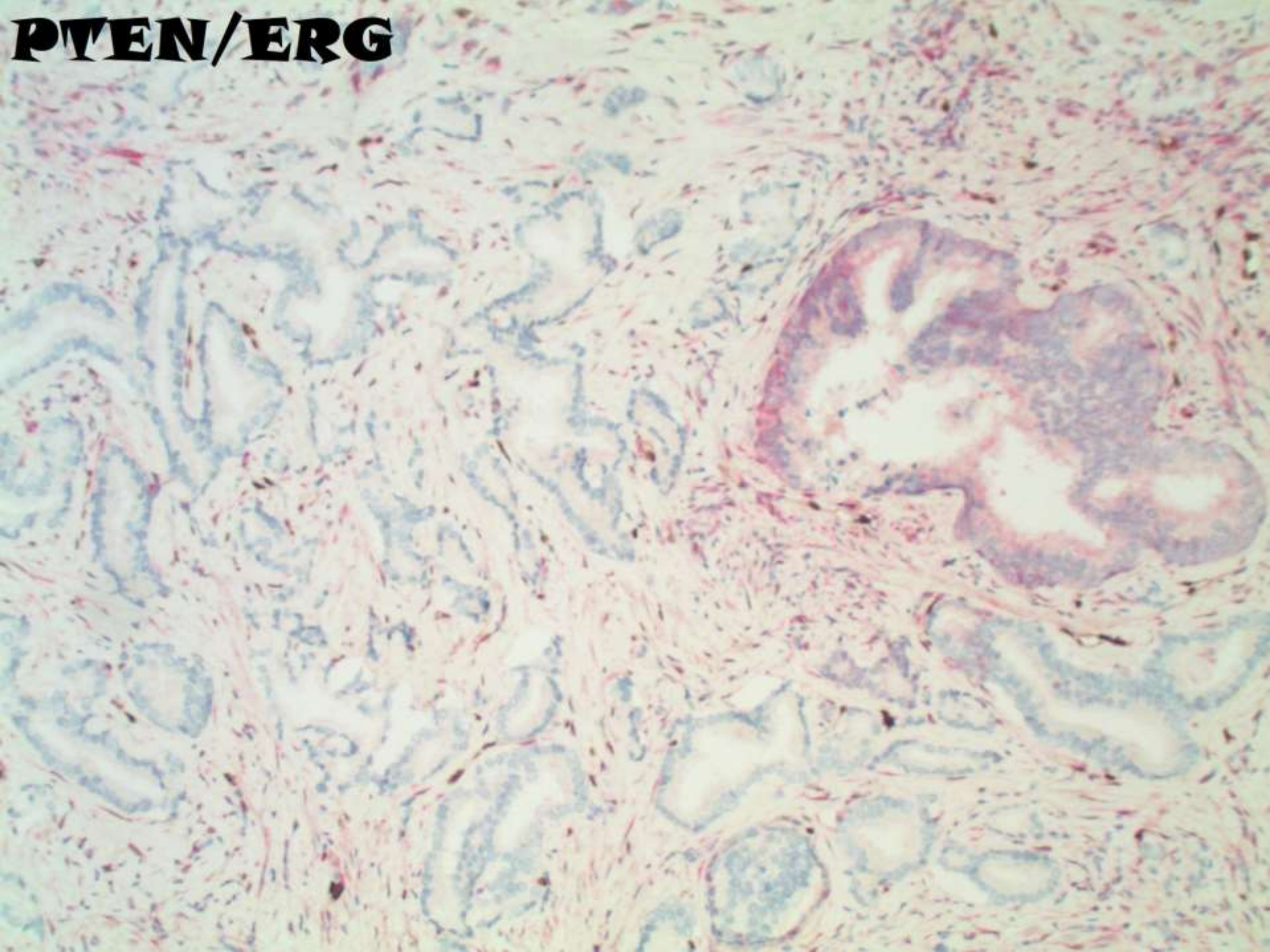








**PTEN/ERG**





# Dx

- Prostate cancer with florid stromal response
  - “stromogenic” prostate ca
    - Worse outcome than conveyed by Gleason grade alone
    - Frequent PTEN loss
      - Bad prognostic finding



# Histologic Grading of Prostatic Adenocarcinoma Can Be Further Optimized

## *Analysis of the Relative Prognostic Strength of Individual Architectural Patterns in 1275 Patients From the Canary Retrospective Cohort*

*Jesse K. McKenney, MD,\* Wei Wei, MS,† Sarah Hawley, MS,‡ Heidi Auman, PhD,‡  
Lisa F. Newcomb, PhD,§|| Hilary D. Boyer, BSc,§ Ladan Fazli, MD,¶|| Jeff Simko, MD, PhD,‡  
Antonio Hurtado-Coll, MD,¶|| Dean A. Troyer, MD, PhD,\*\* Maria S. Tretiakova, MD, PhD,||  
Funda Vakar-Lopez, MD,|| Peter R. Carroll, MD, MPH,‡|| Matthew R. Cooperberg, MD, MPH,‡  
Martin E. Gleave, MD,¶|| Raymond S. Lance, MD,\*\* Dan W. Lin, MD,§|| Peter S. Nelson, MD,§||  
Ian M. Thompson, MD,†† Lawrence D. True, MD,|| Ziding Feng, PhD,† and James D. Brooks, MD,‡†*

**Abstract:** Histologic grading remains the gold standard for prognosis in prostate cancer, and assessment of Gleason score plays a critical role in active surveillance management. We sought to optimize the prognostic stratification of grading and developed a method of recording and studying individual architectural patterns by light microscopic evaluation that is independent of standard Gleason grade. Some of the evaluated patterns are not assessed by current Gleason grading (eg, reactive stromal response). Individual histologic patterns were correlated with recurrence-free survival in a retrospective post-radical prostatectomy cohort of 1275 patients represented by the highest-grade foci of carcinoma in tissue microarrays. In univariable analysis, fibromucinous rupture with varied epithelial complexity had a significantly lower relative risk of recurrence-free survival in cases graded as  $3+4=7$ . Cases having focal "poorly formed glands," which could be designated as pattern  $3+4=7$ , had lower risk than cribriform patterns with either small cribriform glands or expansile cribriform growth.

In separate multivariable Cox proportional hazard analyses of both Gleason score  $3+3=6$  and  $3+4=7$  carcinomas, reactive stromal patterns were associated with worse recurrence-free survival. Decision tree models demonstrate potential regrouping of architectural patterns into categories with similar risk. In summary, we argue that Gleason score assignment by current consensus guidelines are not entirely optimized for clinical use, including active surveillance. Our data suggest that focal poorly formed gland and cribriform patterns, currently classified as Gleason pattern 4, should be in separate prognostic groups, as the latter is associated with worse outcome. Patterns with extravasated mucin are likely overgraded in a subset of cases with more complex epithelial bridges, whereas stromogenic cancers have a worse outcome than conveyed by Gleason grade alone. These findings serve as a foundation to facilitate optimization of histologic grading and strongly support incorporating reactive stroma into routine assessment.

**Key Words:** prostate, adenocarcinoma, Gleason, grade, cribriform, stromal reaction, mucin, stromogenic



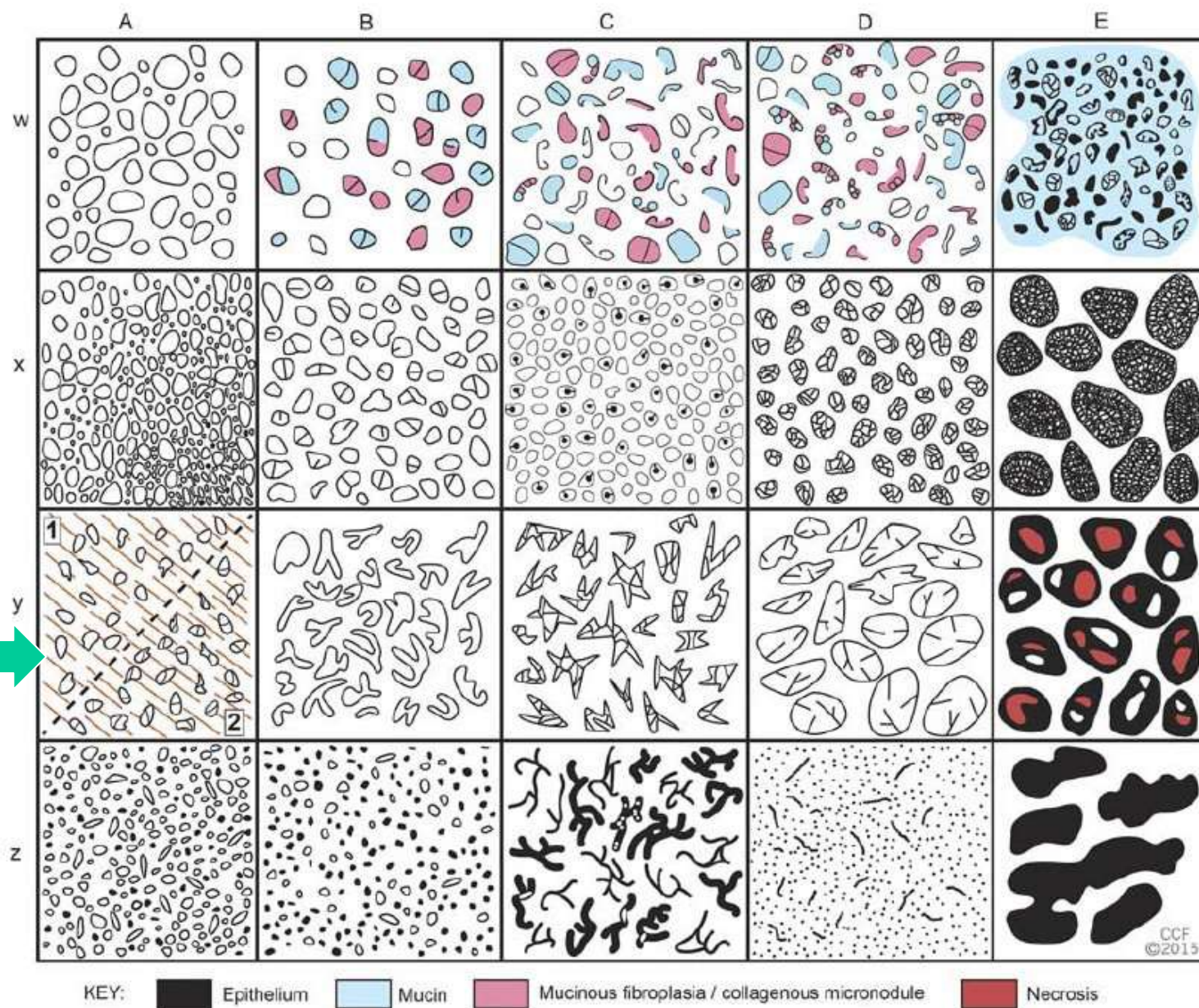
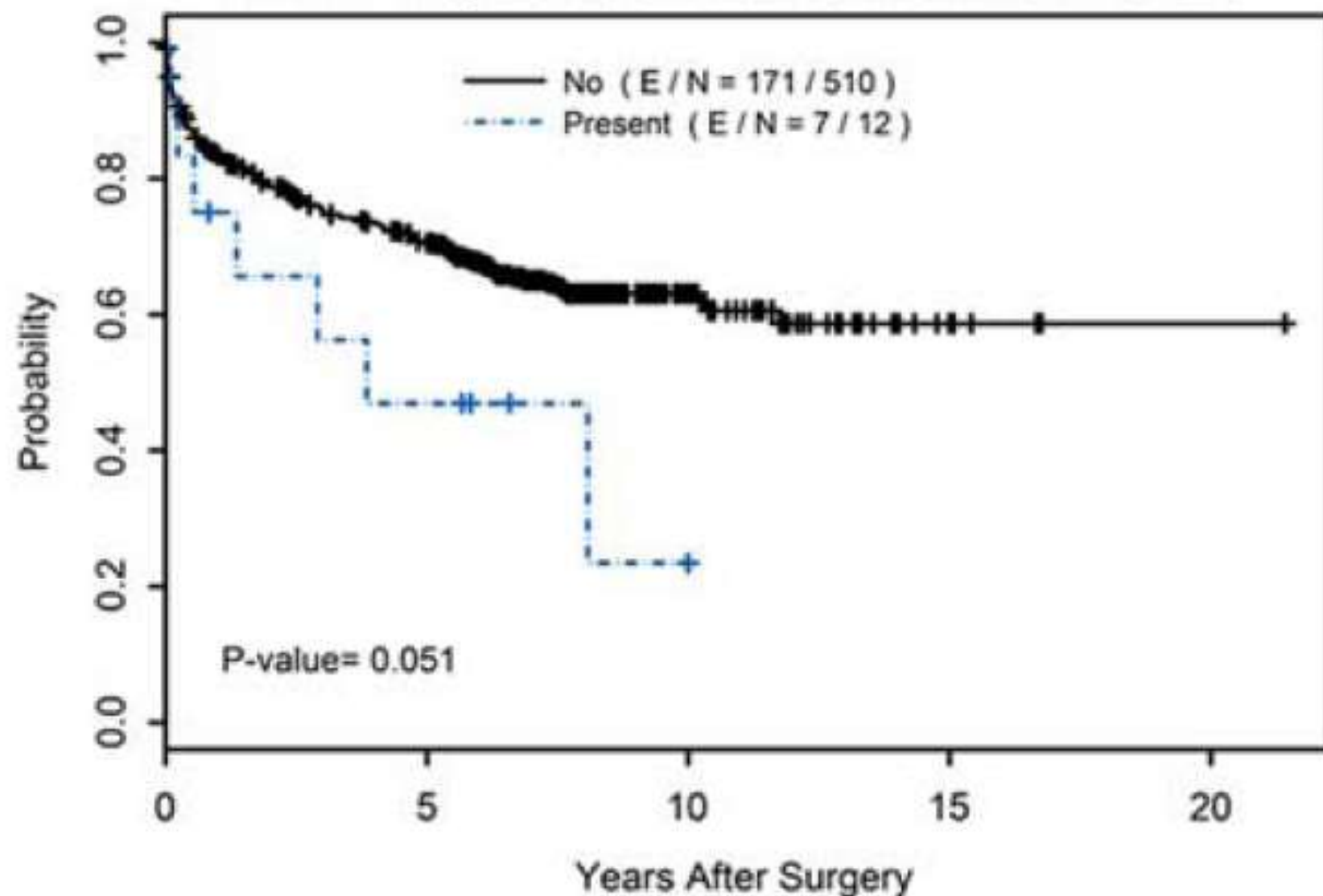


FIGURE 1. Digital schematic for recording histologic patterns.




Recurrence-free Survival by HistAy1 , MaxGleason = 6  
Event = Any Recur/Mets/Prostate Cancer Death

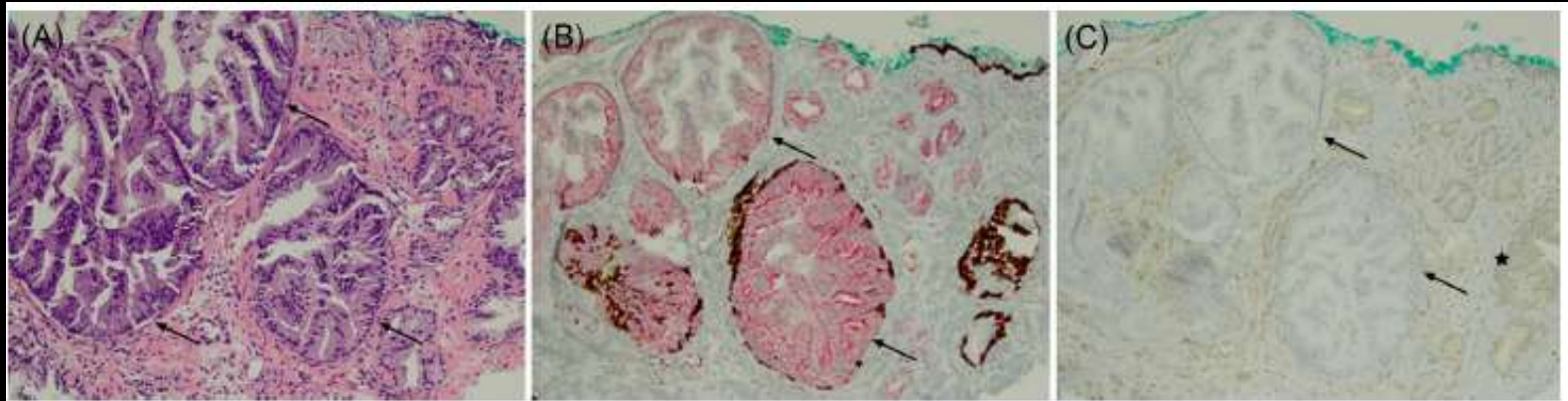




# PTEN loss in prostatic adenocarcinoma correlates with specific adverse histologic features (intraductal carcinoma, cribriform Gleason pattern 4 and stromagenic carcinoma)

Rajal B. Shah MD<sup>1,2</sup>  | Karen T. Shore<sup>3</sup> | Jiyeon Yoon MD<sup>1</sup> | Savvas Mendrinos MD<sup>1</sup> |  
Jesse K. McKenney MD<sup>2</sup> | Wei Tian MD<sup>1</sup>

*The Prostate.* 2019;79:1267-1273.






	PTEN loss status		P value
	Loss (n = 88)	Intact (n = 172)	
	No (% of total with loss)	No (% of total intact)	
Morphological features			
Epithelial features <sup>a</sup>			
Gland size			
Small	80 (91)	157 (91)	0.921
Large	38 (43)	37 (22)	0.001
Architecture			
Well-formed	68 (77)	142 (83)	0.306
Poorly formed	65 (74)	85 (49)	<0.001
Cribriform	33 (38)	18 (10)	<0.001
Solid	9 (10)	5 (3)	0.013
Mucin			
Intraluminal	5 (7)	11 (6)	0.545
Extravasated (mucinous fibroplasia)	3 (3)	1 (0.58)	
Intraductal carcinoma	61 (69)	20 (12)	<0.001
Stromal features			
Nonstromogenic	68 (77)	162 (94)	<0.001
Stromogenic	20 (23)	10 (6)	<0.001



**TABLE 3** Best model for morphological features associated with PTEN loss prostate cancer (PCa)

Morphological feature	Relative risk	95% CI lower	95% CI upper	P value
IDC-P	4.993	3.451	7.223	<0.001
Cribriform Gleason pattern 4	2.459	1.814	3.333	<0.001
Stromogenic PCa	2.255	1.634	3.112	<0.001



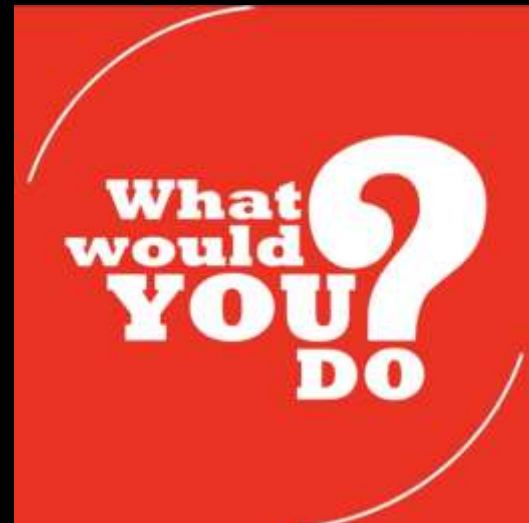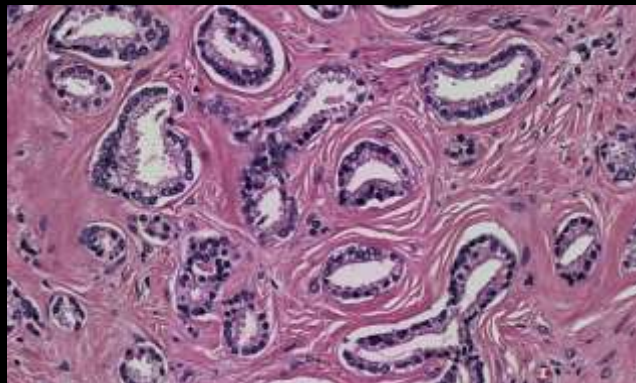
**TABLE 4** Univariate logistic regression of best morphological model based on presence or absence of three architectural features (intraductal carcinoma, cribriform Gleason Pattern 4, and stromogenic prostate cancer)

Number of features	PTEN loss	PTEN intact	Relative risk	95% CI lower	95% CI upper	P value
0	16	136	Ref	–	–	–
1	37	27	5.4922	3.3028	9.1329	<0.0001
2	35	9	7.5568	4.6429	12.2995	<0.0001
3	7	3	6.6500	3.5916	12.3126	<0.0001

# How to approach on a bx?

I put a comment saying:

- 1) although debated, data suggests more aggressive than typical 3+3
- 2) not currently part of grading criteria
- 3) no guidelines for AS

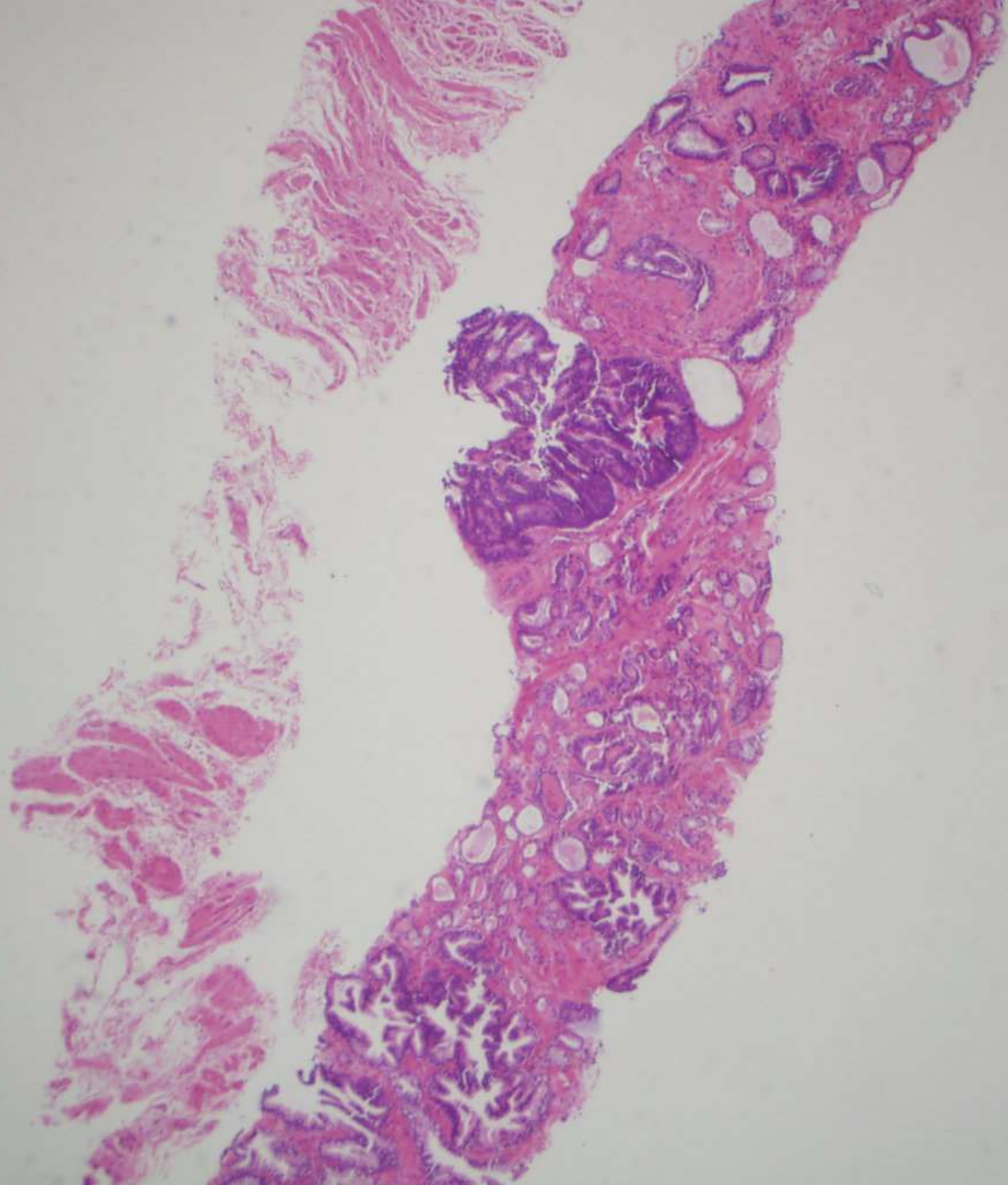




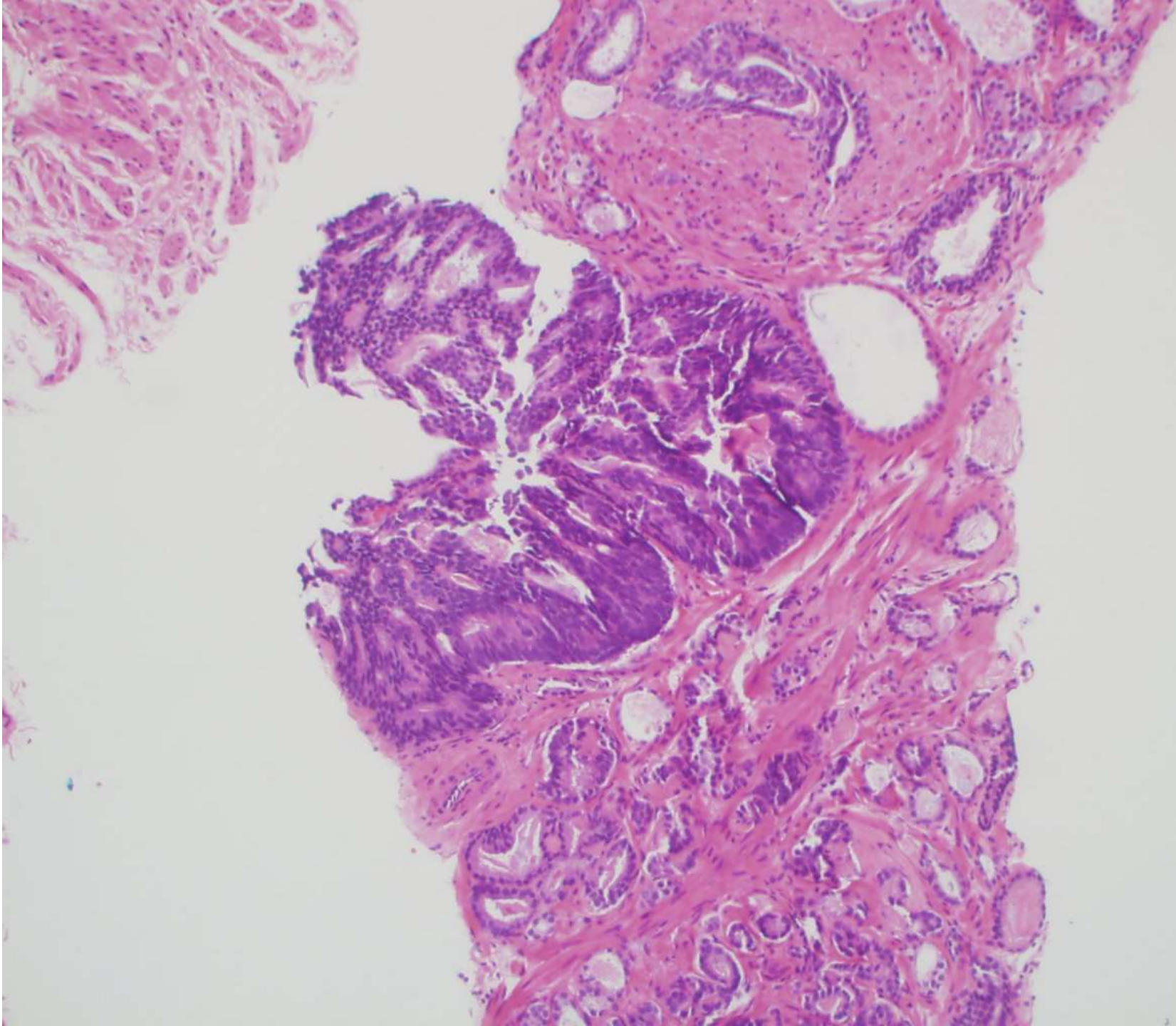
# 20-1107

**Ankur Sangoi; El Camino Hospital**

Adult M, elevated PSA, prostate biopsy performed. On this atypical focus was found among the set of biopsies. Next step? Would you stain this biopsy? Gleason grade?









# The 2019 International Society of Urological Pathology (ISUP) Consensus Conference on Grading of Prostatic Carcinoma

*Geert J.L.H. van Leenders, MD,\* Theodorus H. van der Kwast, MD,† David J. Grignon, MD,‡ Andrew J. Evans, MD,§ Glen Kristiansen, MD,|| Charlotte F. Kweldam, MD,\* Geert Litjens, PhD,¶ Jesse K. McKenney, MD,# Jonathan Melamed, MD,\*\* Nicholas Mottet, MD,††‡‡ Gladell P. Paner, MD,§§ Hemamali Samaratunga, FRCPA,||| Ivo G. Schoots, MD,¶¶ Jeffry P. Simko, MD,## Toyonori Tsuzuki, MD,\*\*\* Murali Varma, MD,††† Anne Y. Warren, MD, FRCPath,‡‡‡ Thomas M. Wheeler, MD,§§§ Sean R. Williamson, MD,||| ISUP Grading Workshop Panel Members, and Kenneth A. Iczkowski, MD,¶¶¶*

**Abstract:** Five years after the last prostatic carcinoma grading consensus conference of the International Society of Urological Pathology (ISUP), accrual of new data and modification of clinical practice re-

quire an update of current pathologic grading guidelines. This manuscript summarizes the proceedings of the ISUP consensus meeting for grading of prostatic carcinoma held in September 2019, in Nice, France. Topics brought to consensus included the following: (1) approaches to reporting of Gleason patterns 4 and 5 quantities, and minor/tertiary patterns, (2) an agreement to report the presence of invasive cribriform carcinoma, (3) an agreement to incorporate intraductal carcinoma into grading, and (4) individual versus aggregate grading of systematic and multiparametric magnetic resonance imaging-targeted biopsies. Finally, developments in the field of artificial intelligence in the grading of prostatic carcinoma and future research perspectives were discussed.

**Key Words:** prostate cancer, grading, ISUP grade group, consensus, minor grades, intraductal carcinoma, targeted biopsies

(*Am J Surg Pathol* 2020;00:000–000)

From the Departments of \*Pathology; ¶¶Radiology and Nuclear Medicine, Erasmus MC, University Medical Center, Rotterdam; ¶¶Diagnostic Image Analysis Group and the Department of Pathology, Radboud University Medical Center, Nijmegen, The Netherlands; †Department of Pathology, Princess Margaret Cancer Center; §Department of Laboratory Information Support Systems, University Health Network, Toronto, ON, Canada; ‡Department of Pathology and Laboratory Medicine, Indiana University School of Medicine, Indianapolis, IN; ||Institute of Pathology of the University Hospital Bonn, Bonn, Germany; #Department of Pathology, Cleveland Clinic, Cleveland, OH; \*\*Department of Pathology, New York University Langone Medical Center, New York, NY; ††Urology Department, University Hospital; ‡‡Department of Surgery, Jean Monnet Uni-



**TABLE 2.** Summary of ISUP 2019 Modifications to Prostate Cancer Grading

Report in biopsies the percentage Gleason pattern 4 for all GS 7 (ISUP GG 2 and 3)

For radical prostatectomies, include the presence of tertiary/minor Gleason patterns 4 and 5 in the GS, if constituting >5% of the tumor volume

Report in radical prostatectomies presence of tertiary/minor Gleason patterns 4 and 5

Do not grade IDC without invasive cancer

**Incorporate the grade of IDC into the GS when invasive cancer is present**

Comment on the presence and significance of IDC in biopsies and radical prostatectomy specimens

Comment on the presence and significance of invasive cribriform cancer in biopsies and radical prostatectomy specimens

Report in systematic biopsies a separate GS (ISUP GG) for each individual biopsy site

Report in mpMRI-targeted biopsies a global (aggregate) GS (ISUP GG) for each suspicious MRI lesion

Report specific benign histologic findings in suspicious (PIRADS 4-5) MRI-targeted biopsies without cancer

**TABLE 4.** IDC and Tumor Growth Pattern Voting Results

Statement	Voting Result
Pure IDC should not be graded	91% agree
In cases with invasive carcinoma, IDC should be incorporated into the GS	76% agree
If IDC is incorporated into the GS, then its presence and significance should be commented on	83% agree
Cribriform Gleason pattern 4 has worse prognosis than poorly formed or fused pattern 4	93% agree
Presence of invasive cribriform cancer should be commented on in GS 7 cases	97% agree
Presence of invasive cribriform cancer should be commented on in GS 8 cases	84% agree





# The 2019 Genitourinary Pathology Society (GUPS) White Paper on Contemporary Grading of Prostate Cancer

Jonathan I. Epstein, MD; Mahul B. Amin, MD; Samson W. Fine, MD; Ferran Algaba, MD, PhD; Manju Aron, MD; Dilek E. Baydar, MD; Antonio Lopez Beltran, MD, PhD; Fadi Brimo, MD; John C. Cheville, MD; Maurizio Colecchia, MD; Eva Comperat, MD, PhD; Isabela Werneck da Cunha, MD, PhD; Warick Delprado, MD; Angelo M. DeMarzo, MD, PhD; Giovanna A. Giannico, MD; Jennifer B. Gordetsky, MD; Charles C. Guo, MD; Donna E. Hansel, MD, PhD; Michelle S. Hirsch, MD, PhD; Jiaoti Huang, MD, PhD; Peter A. Humphrey, MD, PhD; Rafael E. Jimenez, MD; Francesca Khani, MD; Qingnuan Kong, MD; Oleksandr N. Kryvenko, MD; L. Priya Kunju, MD; Priti Lal, MD; Mathieu Latour, MD; Tamara Lotan, MD; Fiona Maclean, MD; Cristina Magi-Galluzzi, MD, PhD; Rohit Mehra, MD; Santosh Menon, MD; Hiroshi Miyamoto, MD, PhD; Rodolfo Montironi, MD; George J. Netto, MD; Jane K. Nguyen, MD, PhD; Adebayo O. Osunkoya, MD; Anil Parwani, MD; Brian D. Robinson, MD; Mark A. Rubin, MD; Rajal B. Shah, MD; Jeffrey S. So, MD; Hiroyuki Takahashi, MD, PhD; Fabio Tavora, MD, PhD; Maria S. Tretiakova, MD, PhD; Lawrence True, MD; Sara E. Wobker, MD; Ximing J. Yang, MD, PhD; Ming Zhou MD, PhD; Debra L. Zynger, MD; Kiril Trpkov, MD

**Context.**—Controversies and uncertainty persist in prostate cancer grading.

**Objective.**—To update grading recommendations.

**Data Sources.**—Critical review of the literature along with pathology and clinician surveys.

**Conclusions.**—Percent Gleason pattern 4 (%GP4) is as follows: (1) report %GP4 in needle biopsy with Grade Groups (GrGp) 2 and 3, and in needle biopsy on other parts (jars) of lower grade in cases with at least 1 part showing Gleason score (GS)  $4 + 4 = 8$ ; and (2) report %GP4: less than 5% or less than 10% and 10% increments thereafter. Tertiary grade patterns are as follows: (1) replace “tertiary grade pattern” in radical prostatectomy (RP) with “minor tertiary pattern 5 (TP5),” and only use in RP with GrGp 2 or 3 with less than 5% Gleason pattern 5; and (2) minor TP5 is noted along with the GS, with the GrGp based on the GS. Global score and magnetic resonance imaging (MRI)-targeted biopsies are as follows: (1) when multiple undesignated cores are taken from a single MRI-targeted lesion, an overall grade for that lesion is given as if all the involved cores were one long core; and (2) if providing a global score, when different scores are found in the standard and the MRI-targeted biopsy, give a single global score (factoring both the systematic standard and the MRI-targeted positive cores). Grade Groups are as follows: (1) Grade Groups (GrGp) is the terminology adopted by major world organizations; and (2) retain GS  $3 + 5 = 8$  in GrGp 4. Cribriform carcinoma is as follows: (1) report the presence or absence

of cribriform glands in biopsy and RP with Gleason pattern 4 carcinoma. Intraductal carcinoma (IDC-P) is as follows:

(1) report IDC-P in biopsy and RP; (2) use criteria based on dense cribriform glands ( $>50\%$  of the gland is composed of epithelium relative to luminal spaces) and/or solid nests and/or marked pleomorphism/necrosis; (3) it is not necessary to perform basal cell immunostains on biopsy and RP to identify IDC-P if the results would not change the overall (highest) GS/GrGp part per case; (4) do not

include IDC-P in determining the final GS/GrGp on biopsy and/or RP; and (5) “atypical intraductal proliferation (AIP)” is preferred for an intraductal proliferation of

prostatic secretory cells which shows a greater degree of architectural complexity and/or cytological atypia than typical high-grade prostatic intraepithelial neoplasia, yet falling short of the strict diagnostic threshold for IDC-P. Molecular testing is as follows: (1) Ki67 is not ready for routine clinical use; (2) additional studies of active surveillance cohorts are needed to establish the utility of PTEN in this setting; and (3) dedicated studies of RNA-based assays in active surveillance populations are needed to substantiate the utility of these expensive tests in this setting. Artificial intelligence and novel grading schema are as follows: (1) incorporating reactive stromal grade, percent GP4, minor tertiary GP5, and cribriform/intraductal carcinoma are not ready for adoption in current practice.

(Arch Pathol Lab Med. doi: 10.5858/arpa.2020-0015-RA)



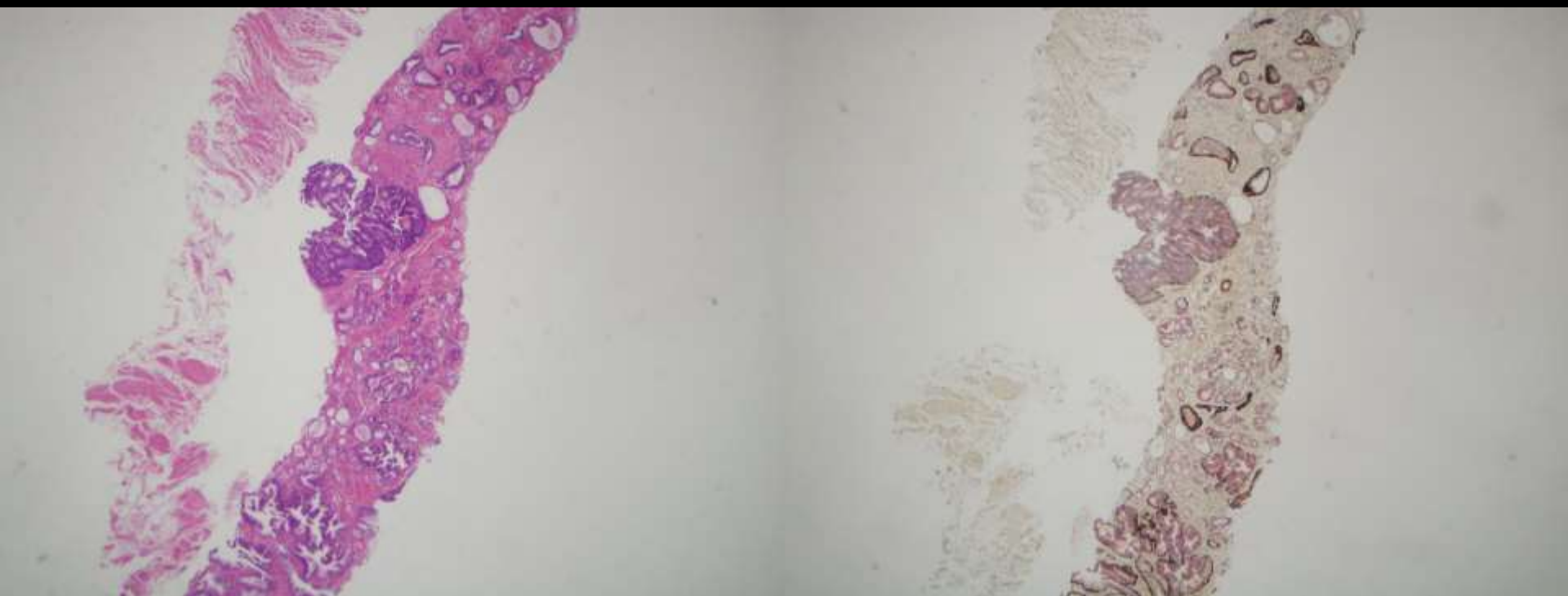**Table 8. Summary of Recommendations on Intraductal Carcinoma (IDC-P)**

- 1 Report the presence of IDC-P in biopsy and radical prostatectomy specimens
- 2 Use criteria based on dense cribriform glands and/or solid nests and/or marked pleomorphism/necrosis. Dense cribriform glands are defined >50% of the gland composed of epithelium relative to luminal spaces; where the ratio is approximately equal, it is prudent to be conservative and diagnose the lesion as not meeting full criteria for IDC-P
- 3 When IDC-P is identified on prostate biopsy without concomitant invasive adenocarcinoma, add a comment stating that IDC-P is usually associated with high-grade prostate cancer
- 4 **Perform IHC for basal cell markers when the biopsy shows Gleason score 6 cancer and cribriform glands that include a differential diagnosis of IDC-P versus Gleason pattern 4 cancer**
- 5 **It is not necessary to perform basal cell IHC on needle biopsy and radical prostatectomy to identify IDC-P if the results of the stains would not change the overall highest Gleason score/Grade Group for the case**
- 6 **Do not include IDC-P in determining the final Gleason score on biopsy and/or radical prostatectomy**

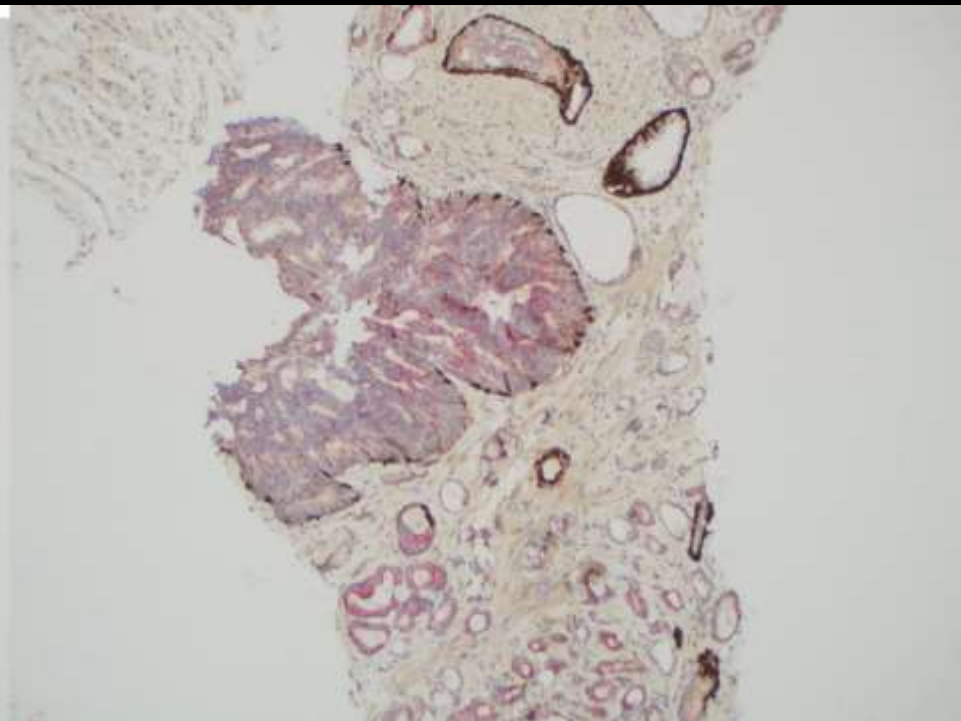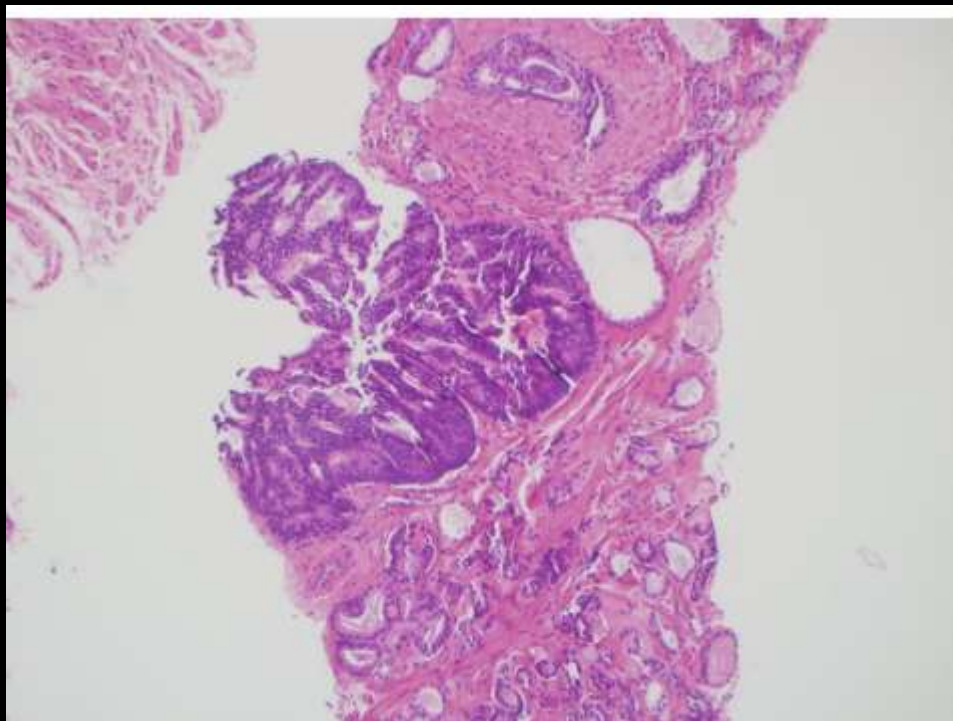
Abbreviations: IHC, immunohistochemistry.

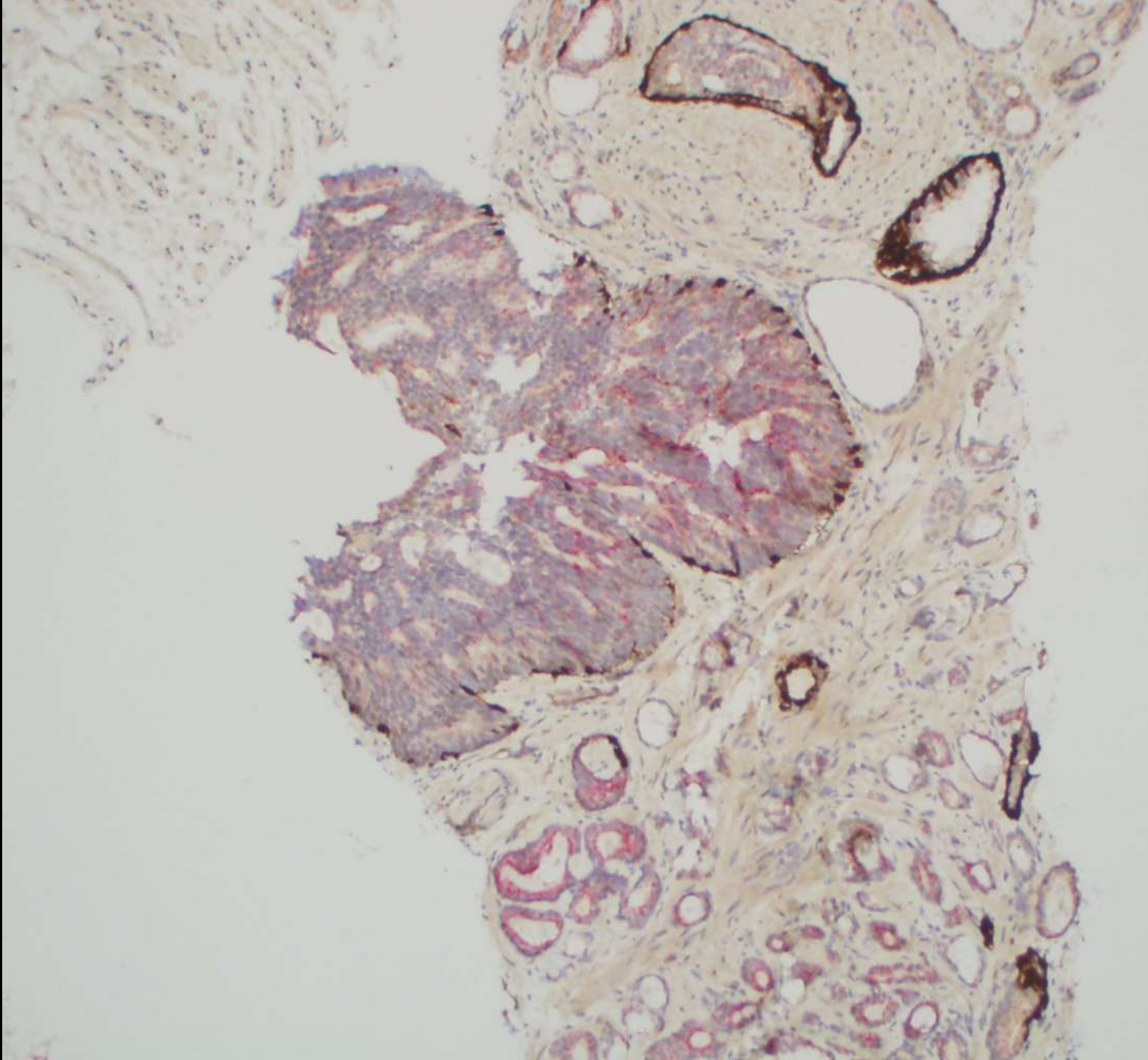
Bold items reflect first time recommendations by the Genitourinary Pathology Society.

*(Arch Pathol Lab Med. doi: 10.5858/arpa.2020-0015-RA)*











# 2019 GUPS vs ISUP consensus comparison of prostate bx grading

## GUPS

## ISUP

IDCP admixed with  
invasive carcinoma

Do not include IDCP in determining the final  
Gleason score  
Report the presence of IDCP

IDCP should be incorporated into  
the Gleason score  
If IDCP is incorporated into the  
Gleason score, its presence and  
significance should still be  
commented on

**Major disagreement**

(Agreement on  
reporting)

IDCP with invasive  
carcinoma, IHC use

Perform IHC for basal cell markers if a biopsy  
shows Gleason score 6 carcinoma and cribriform  
glands that might represent cribriform carcinoma  
*versus* IDCP  
Not necessary to perform basal cell IHC to identify  
IDCP if the results of the stains would not change  
the overall highest Gleason score/Grade Group  
for the case

Unnecessary, as IDCP should be  
incorporated into the Gleason  
score assigned

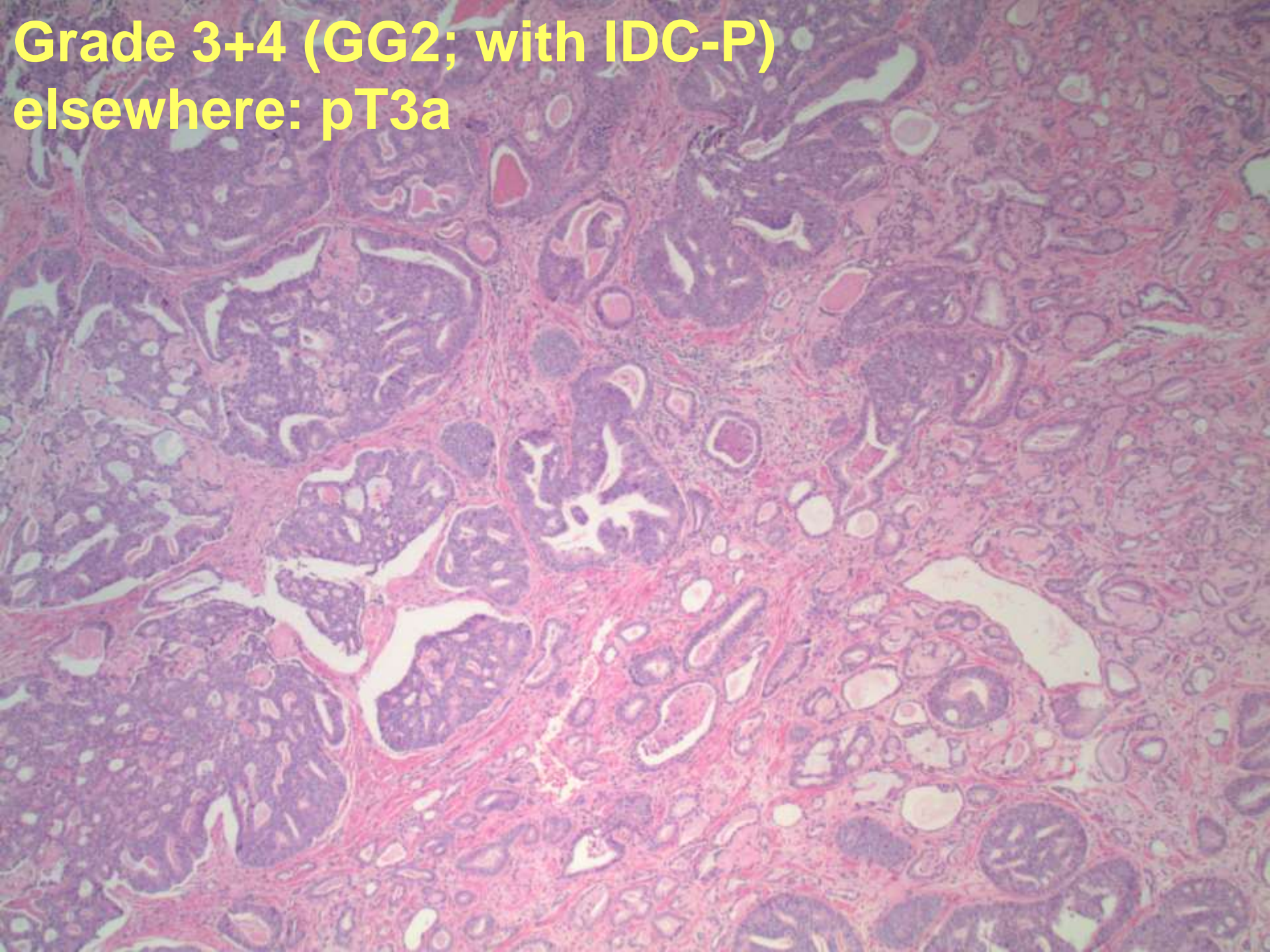
**Major disagreement**

# Final Dx

- **GUPS:**
  - Grade 3+3 (GG1), with IDC-P
- **ISUP:**
  - Grade 3+4 (GG2; IDC-P present & incorporated into score)

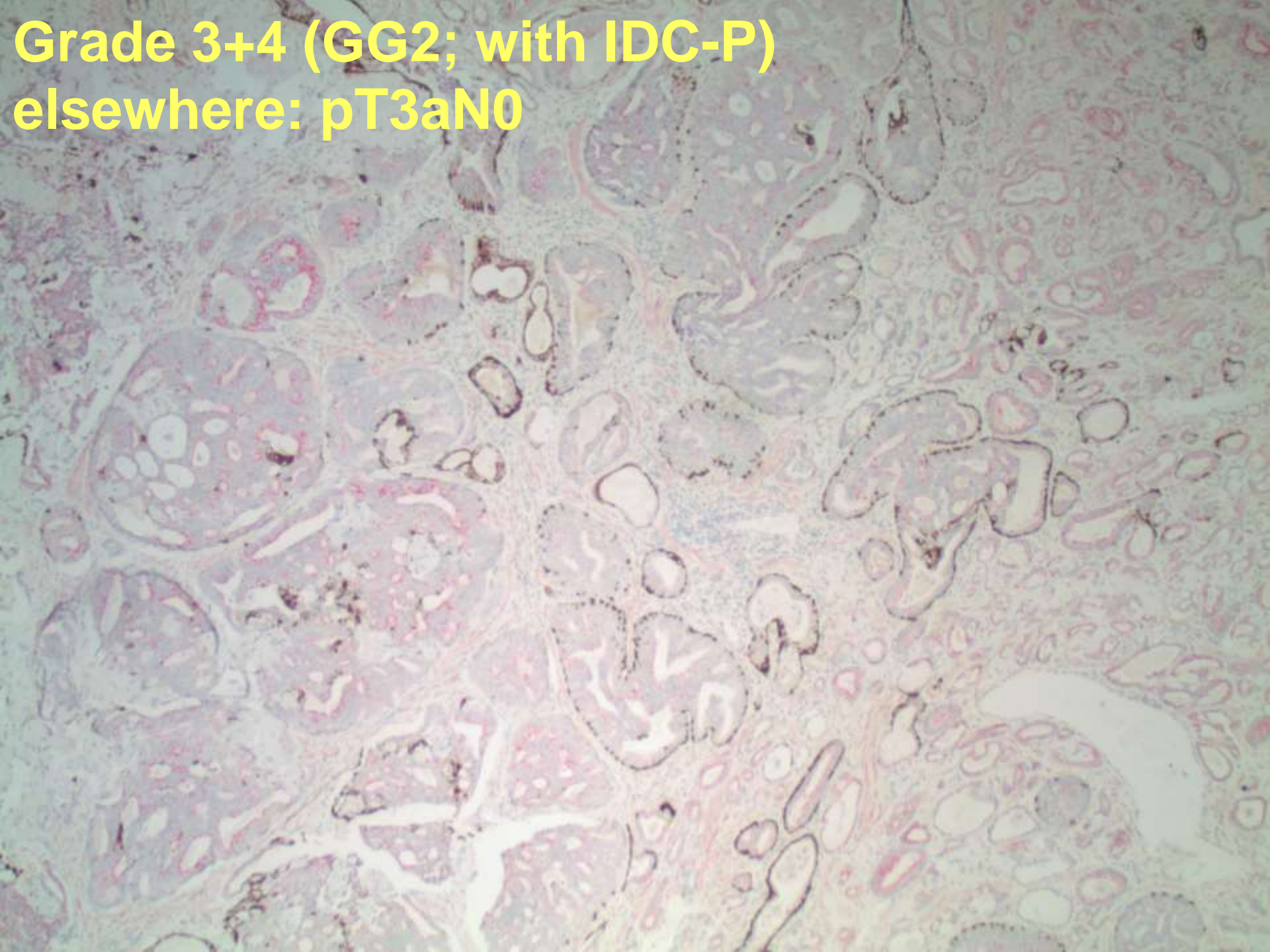


**Grade 3+4 (GG2; with IDC-P)  
elsewhere: pT3a**



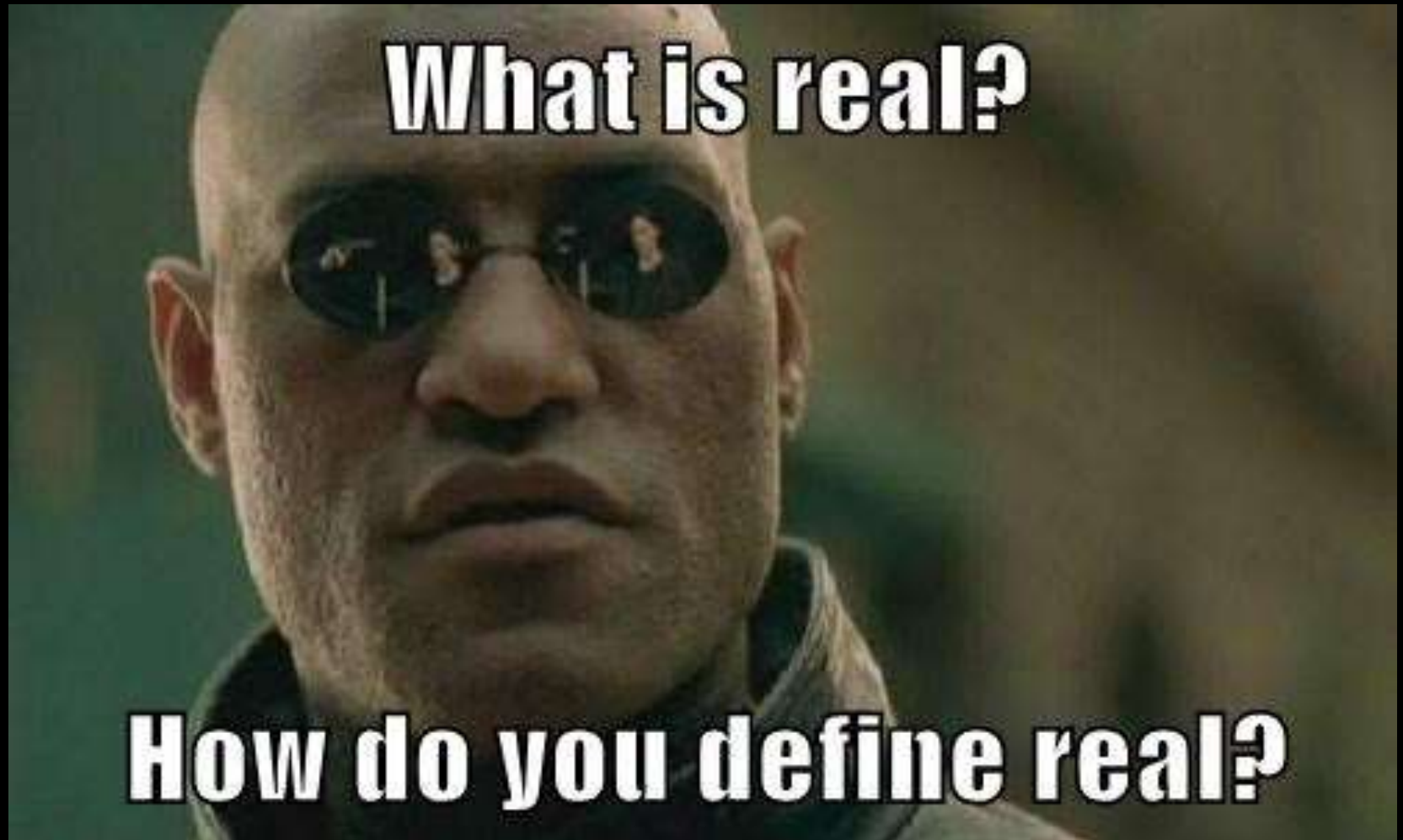


**Grade 3+4 (GG2; with IDC-P)  
elsewhere: pT3aN0**





**How do we define “IDC-P”?**



# Intraductal carcinoma of the prostate on needle biopsy: histologic features and clinical significance

Charles C Guo<sup>1</sup> and Jonathan I Epstein<sup>1,2,3</sup>

<sup>1</sup>Department of Pathology, The Johns Hopkins University School of Medicine, Baltimore, MD, USA;

<sup>2</sup>Department of Urology, The Johns Hopkins University School of Medicine, Baltimore, MD, USA and

<sup>3</sup>Department of Oncology, The Johns Hopkins University School of Medicine, Baltimore, MD, USA

Intraductal carcinoma of the prostate (IDC-P) has been described in radical prostatectomies. However, there is limited information as to its histologic features and clinical significance when seen on prostate biopsy. A total of 27 cases of prostate biopsies with only IDC-P (ie no infiltrating cancer anywhere on the biopsy) were studied from the consult files of one of the authors. IDC-P was defined as malignant epithelial cells filling large acini and prostatic ducts, with preservation of basal cells forming either: (1) solid or dense cribriform patterns or; (2) loose cribriform or micropapillary patterns with either marked nuclear atypia (nuclear size  $6 \times$  normal or larger) or comedonecrosis. The numbers of cores involved by IDC-P in the biopsies ranged from 1 to 7, with  $>1$  core involved in 17 cases. The architectural patterns of IDC-P were solid (12), dense cribriform (19), loose cribriform (17), and micropapillary (5). More than one pattern was present in 24 of 27 cases. The cytological features frequently observed in IDC-P were marked pleomorphism (18), non-focal comedonecrosis (22), and mitoses (20). Basal cells were observed on regular hematoxylin and eosin stained slides in 14 cases; in all the cases, basal cells were confirmed by immunohistochemical stains for high molecular weight cytokeratin ( $n=25$ ) and/or p63 ( $n=4$ ). After the diagnosis of IDC-P on prostate biopsies, patients were treated by radical prostatectomy (6), radiation (7), hormone (5), combined radiation and hormone (1), or watchful waiting (2). The follow-up information was not available for six patients. The follow-up times ranged up to 4 years with an average of 2.1 years. In all six radical prostatectomy specimens, high-grade infiltrating carcinoma with Gleason score 8 or 9 was present with five cases also revealing prominent IDC-P. Non-focal extraprostatic extension of carcinoma was observed in five of the six prostatectomy cases with two cases also demonstrating vascular invasion. Three of 16 patients who did not receive radical prostatectomy developed bone metastases. Our study indicates that IDC-P on prostate biopsies is frequently associated with high-grade cancer and poor prognostic parameters at radical prostatectomy as well as potentially advanced disease following other therapies. These findings support prior studies that IDC-P represents an advanced stage of tumor progression with intraductal spread of tumor. Consideration should be given to treat patients with IDC-P on biopsy aggressively even in the absence of documented infiltrating cancer.

*Modern Pathology* (2006) 19, 1528–1535. doi:10.1038/modpathol.3800702; published online 15 September 2006



## Table 1 Definition of IDC-P

Malignant epithelial cells filling large acini and prostatic ducts, with preservation of basal cells and:

- Solid or dense cribriform pattern
- or
- Loose cribriform or micropapillary pattern with either
  - Marked nuclear atypia: nuclear size  $6 \times$  normal or larger
  - Non-focal comedonecrosis



# Atypical intraductal proliferation detected in prostate needle biopsy is a marker of unsampled intraductal carcinoma and other adverse pathological features: a prospective clinicopathological study of 62 cases with emphasis on pathological outcomes

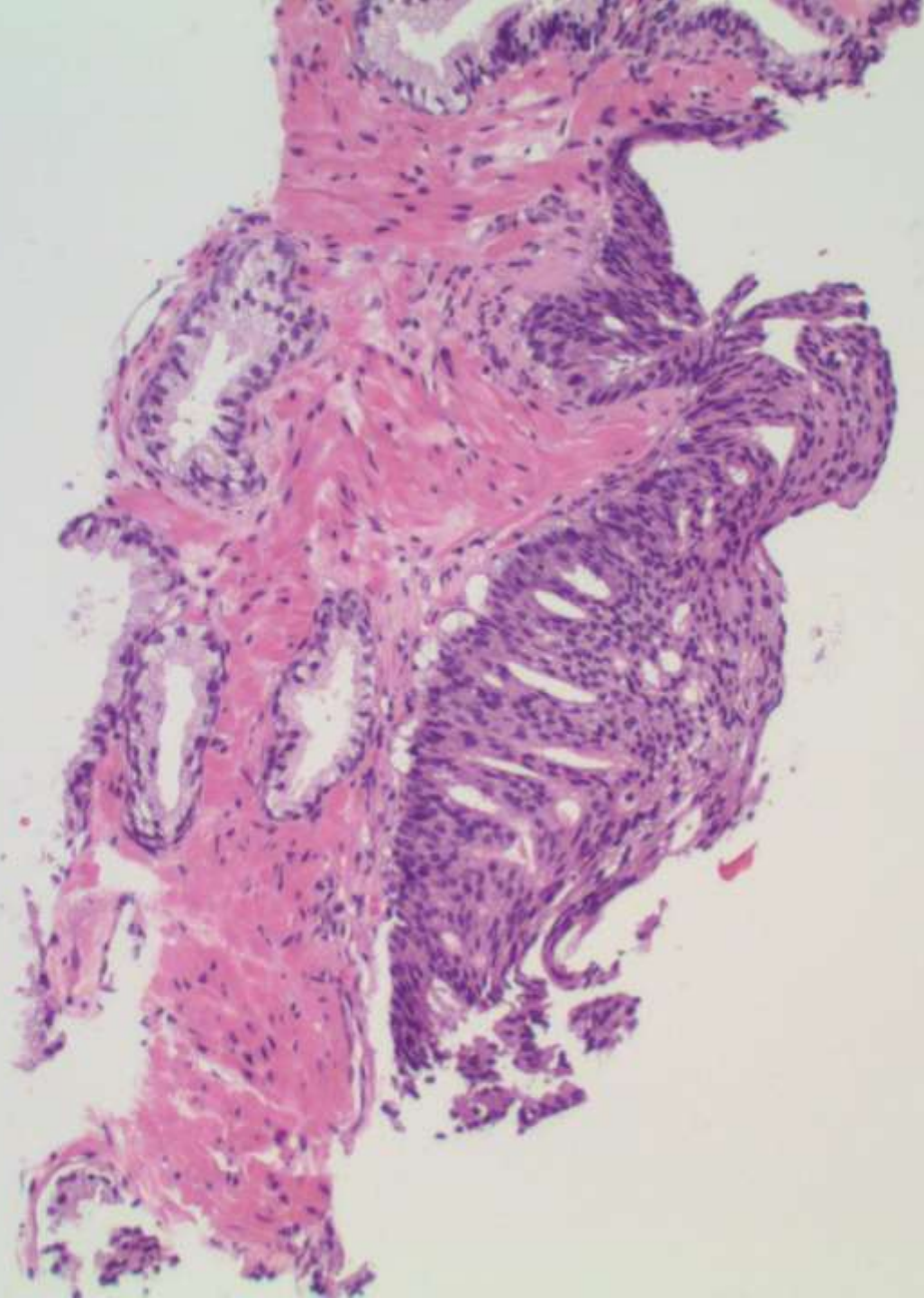
Rajal B Shah<sup>1</sup>  Jane K Nguyen,<sup>1</sup> Christopher G Przybycin,<sup>1</sup> Jordan P Reynolds,<sup>1</sup> Roni Cox,<sup>1</sup> Jonathan Myles,<sup>1</sup> Eric Klein<sup>2</sup> & Jesse K McKenney<sup>1,2</sup> 

<sup>1</sup>Robert J. Tomsich Pathology and Laboratory Medicine Institute, and <sup>2</sup>Glickman Urological and Kidney Institute, The Cleveland Clinic, Cleveland, OH, USA

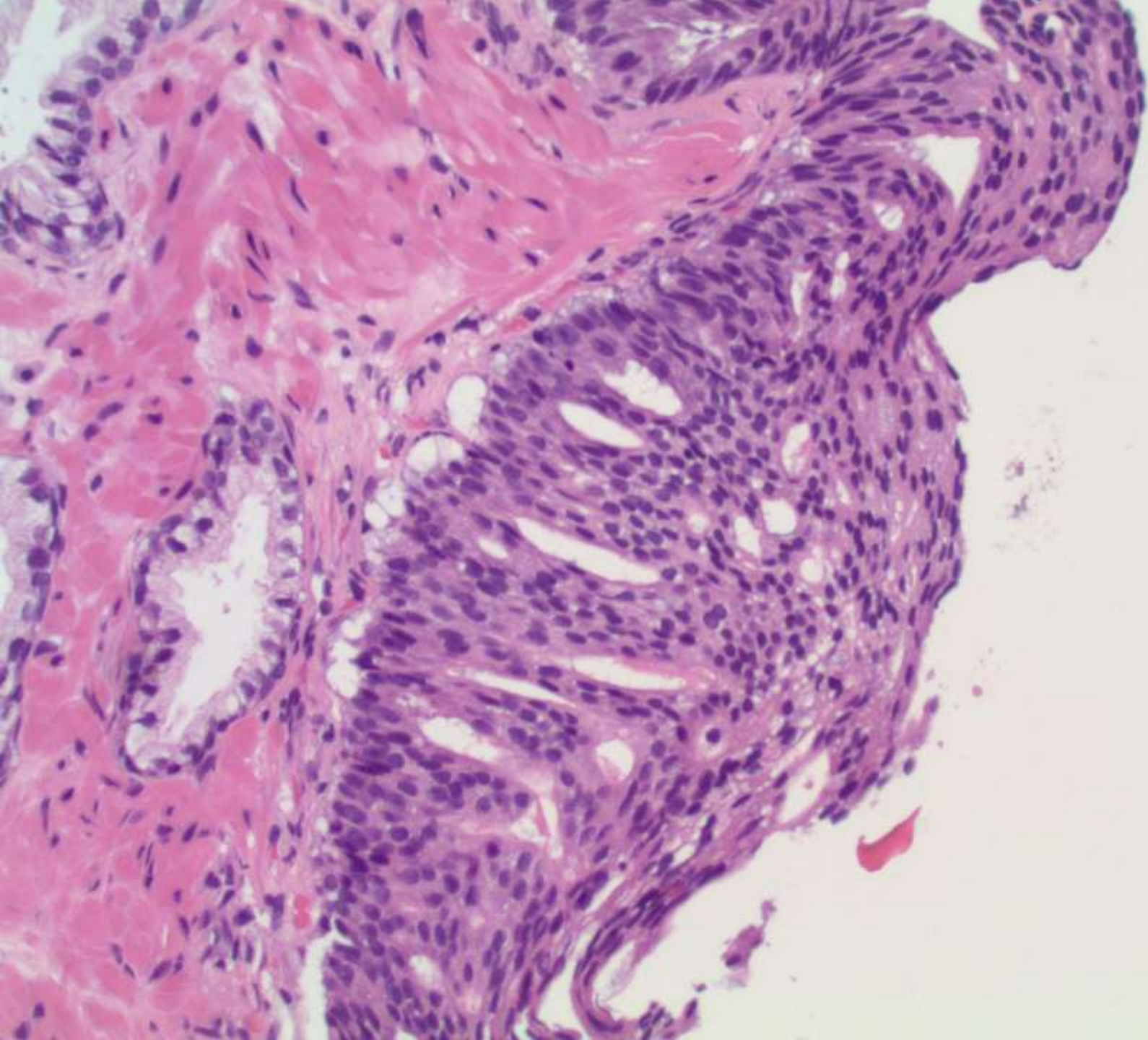
## Utility of PTEN and ERG Immunostaining for Distinguishing High-grade PIN From Intraductal Carcinoma of the Prostate on Needle Biopsy

*Carlos L. Morais, MD,\* Jeong S. Han, MD,\* Jennifer Gordetsky, MD,\* Michael S. Nagar, MD,† Ann E. Anderson, MD,† Stephen Lee, MD,\* Jessica L. Hicks,\* Ming Zhou, MD, PhD,‡ Cristina Magi-Galluzzi, MD, PhD,‡ Rajal B. Shah, MD,§ Jonathan I. Epstein, MD,\* ||¶ Angelo M. De Marzo, MD, PhD,\* ||¶ and Tamara L. Lotan, MD\* ||*

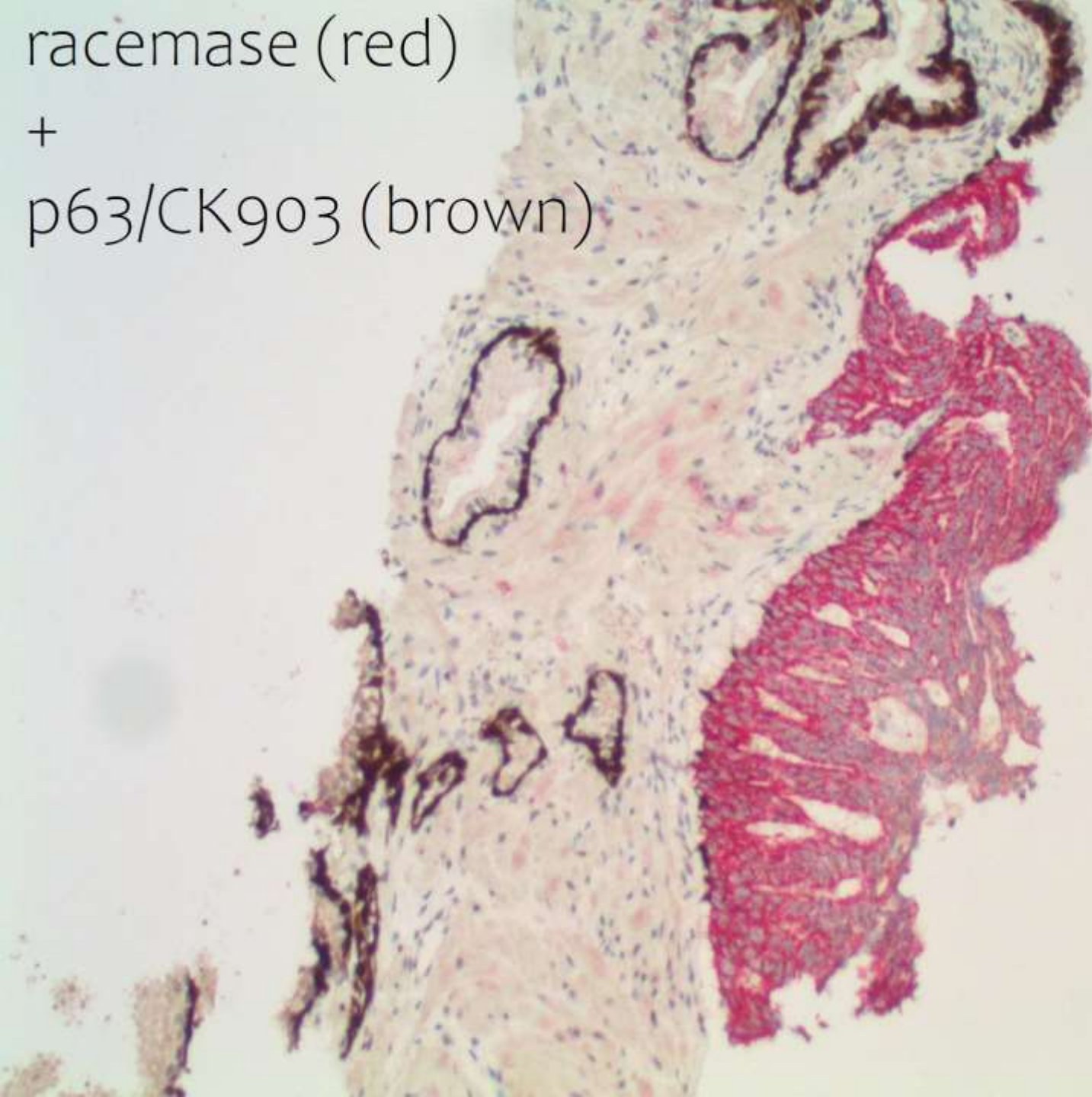
(*Am J Surg Pathol* 2015;39:169–178)





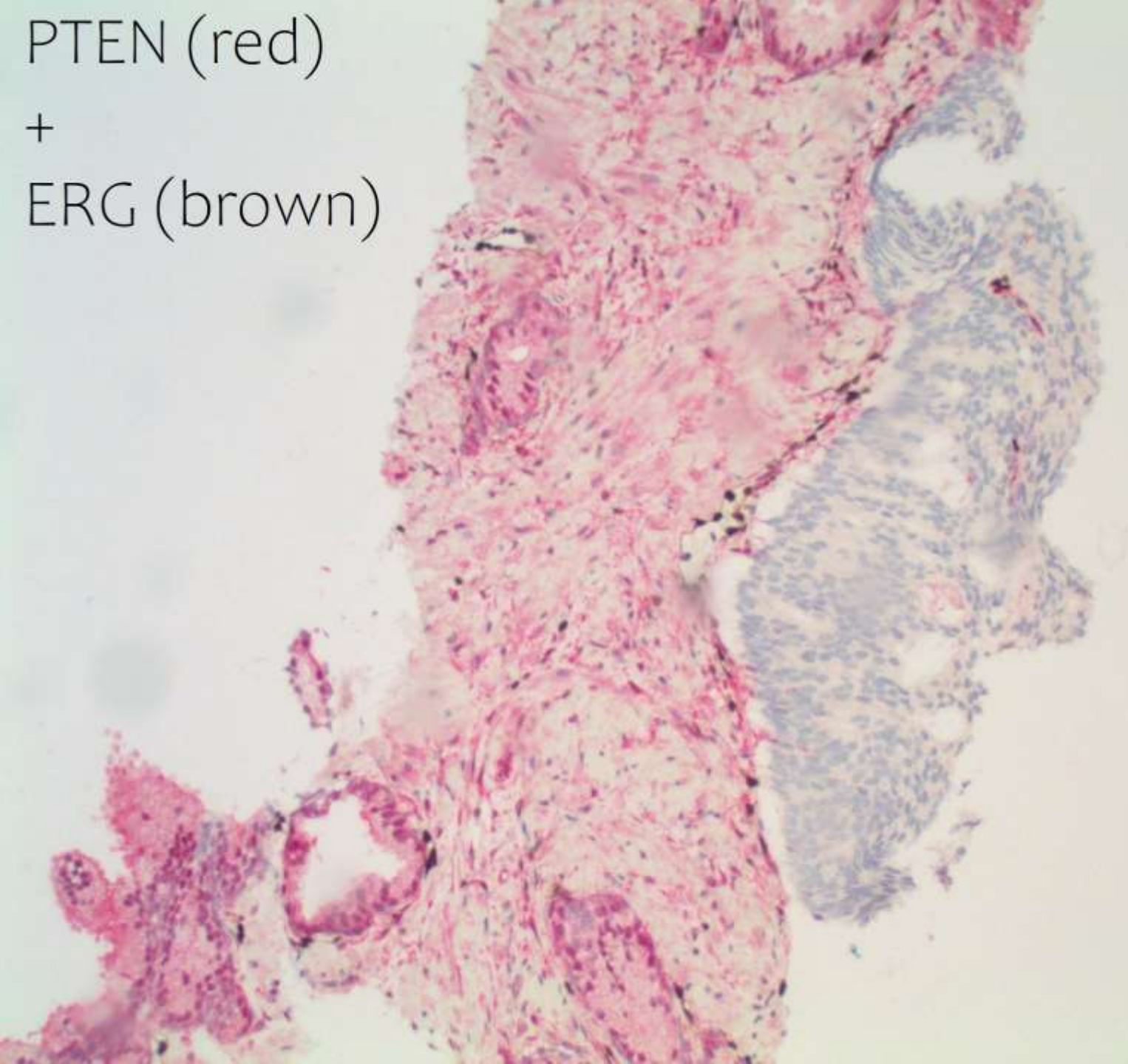


racemase (red)  
+  
p63/CK903 (brown)



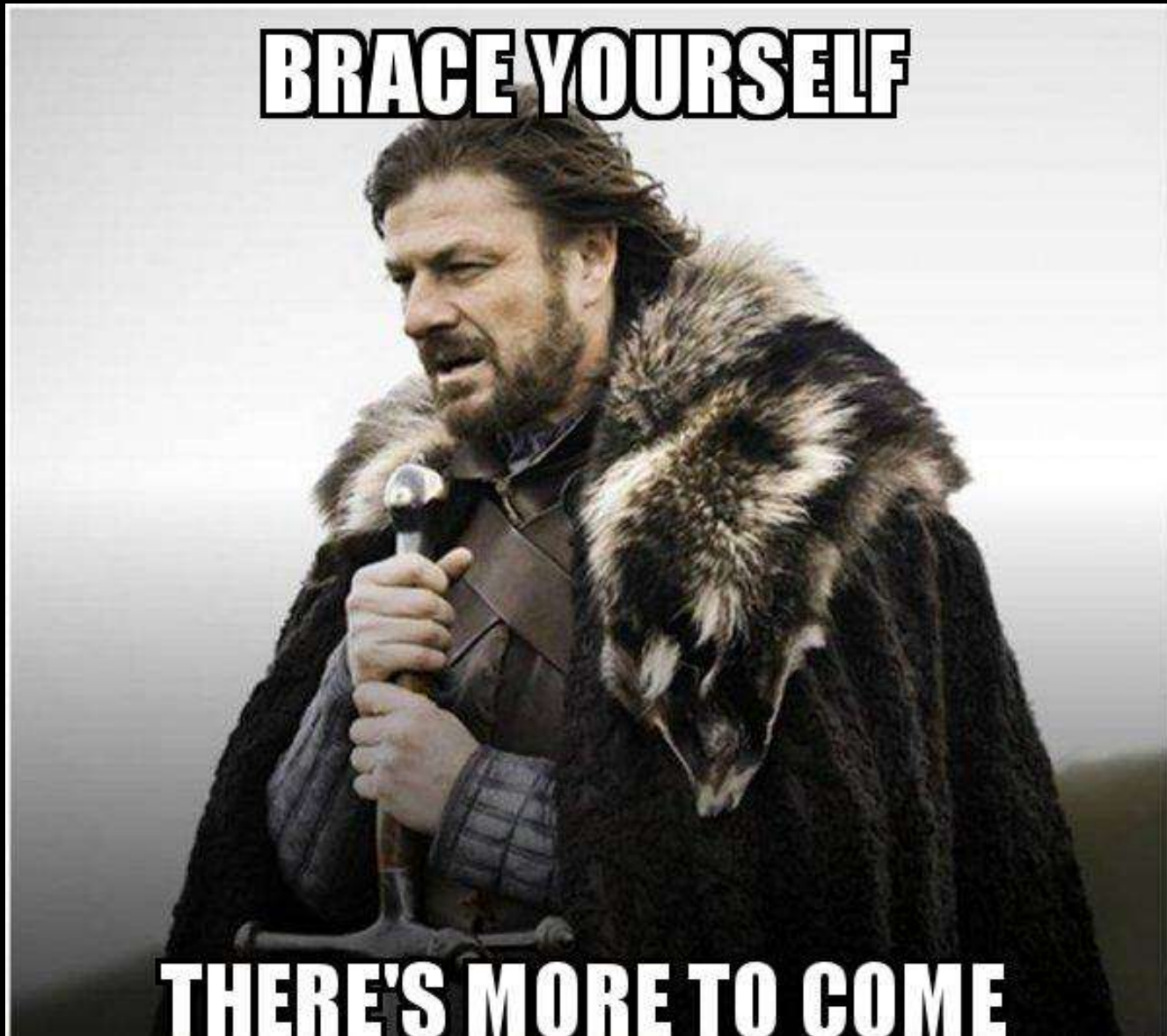

PTEN (red)  
+  
ERG (brown)



# AIP vs IDC-P; grade?

**BRACE YOURSELF**



**THERE'S MORE TO COME**