

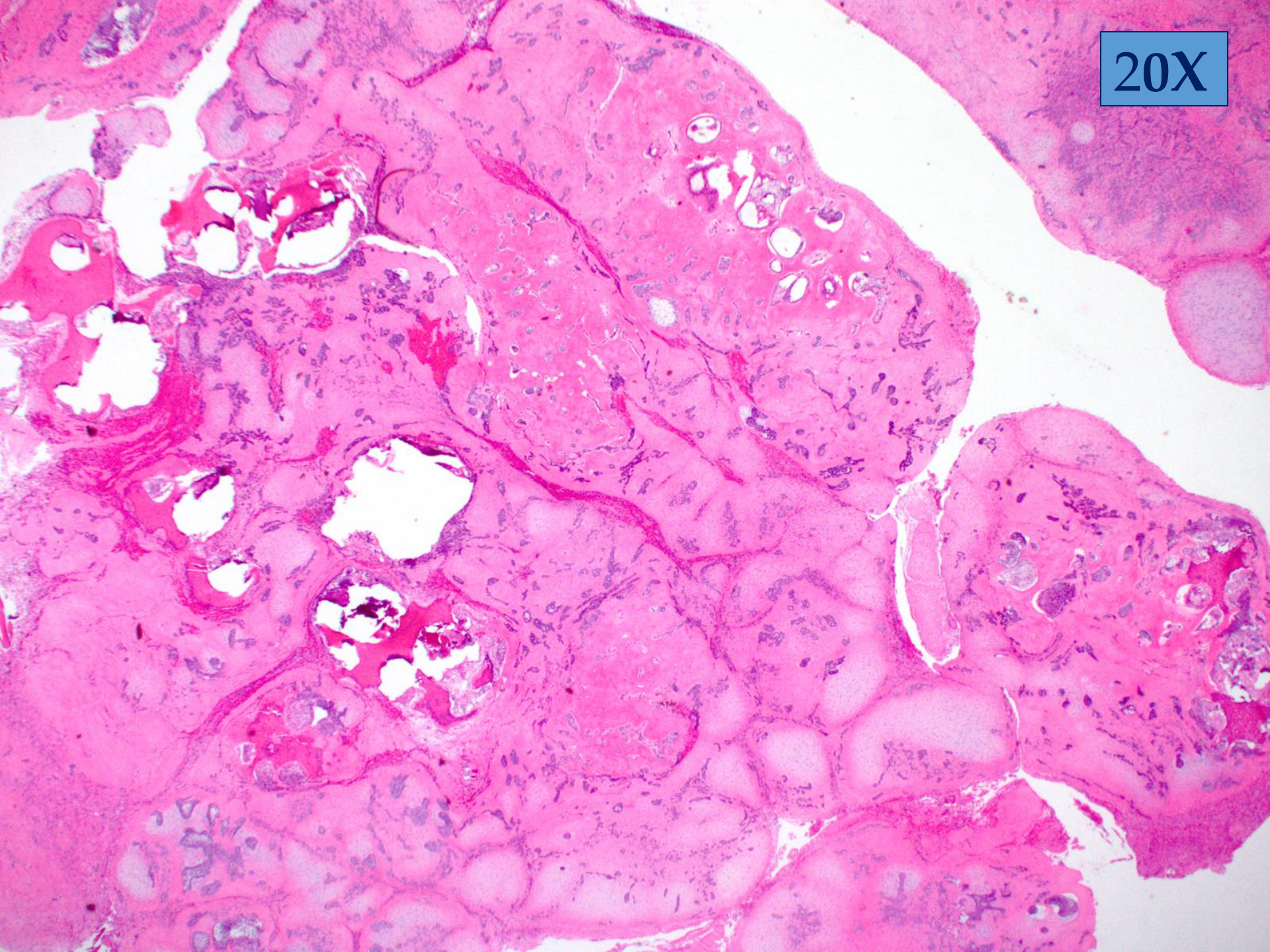
Case 8

- 10 year old male with radiolucent lesion in the right mandible in the vicinity of the 3rd molar
 - Initially seen by orthodontist with X-ray; Panorex showed improper eruption of right mandibular 12-year molar
 - Multiloculated mixed radiodense lesion in the anterior ascending ramus adjacent to impacted tooth #31

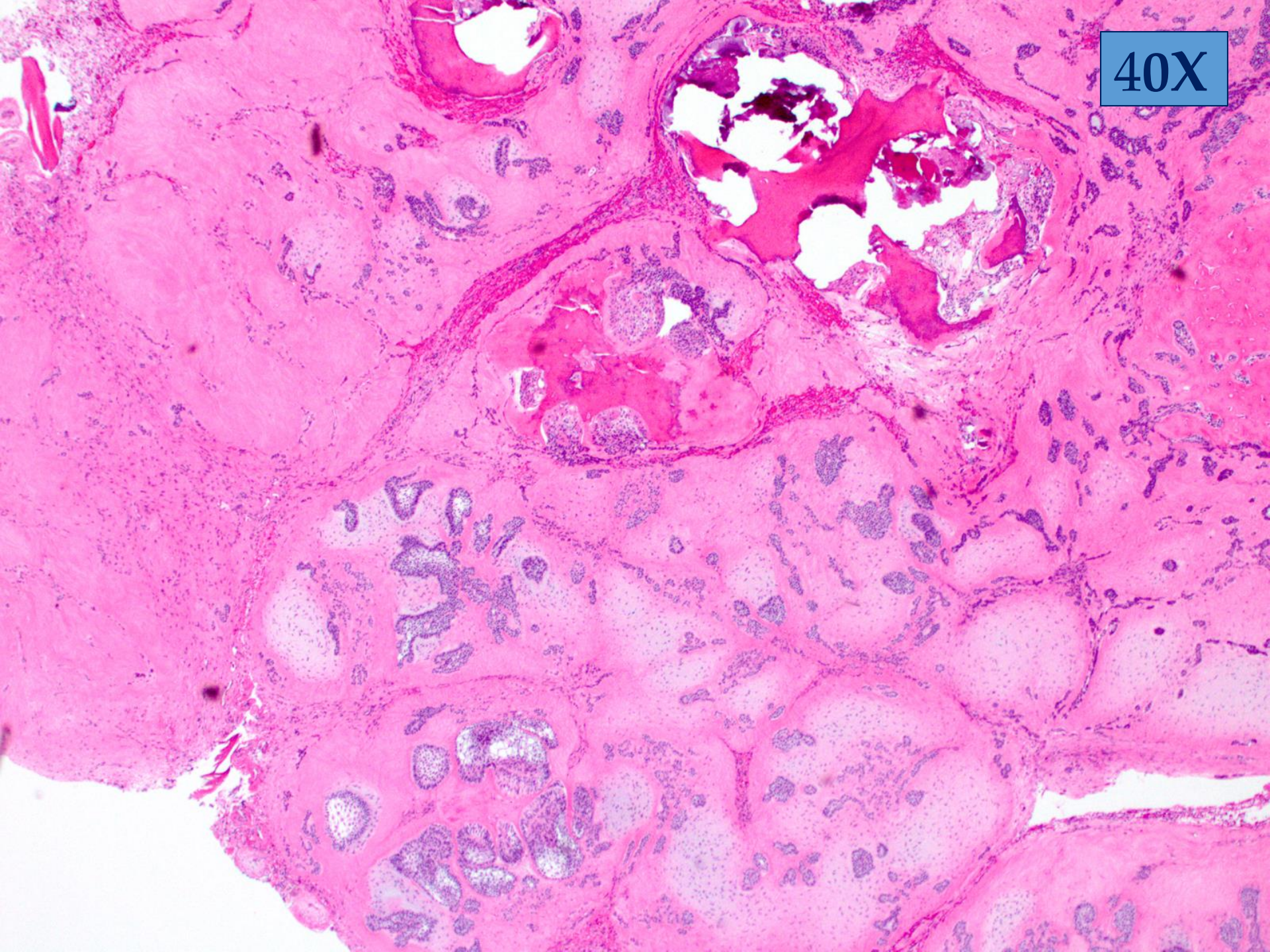
Case 8 cont.

- 10 year old male with radiolucent lesion in the right mandible in the vicinity of the 3rd molar
 - Patient had no pain or jaw symptoms, no numbness
 - Presumptive complex/compound odontoma
 - No other relevant symptoms
- Images demonstrate the histology from right mandibular peripheral osteotomy

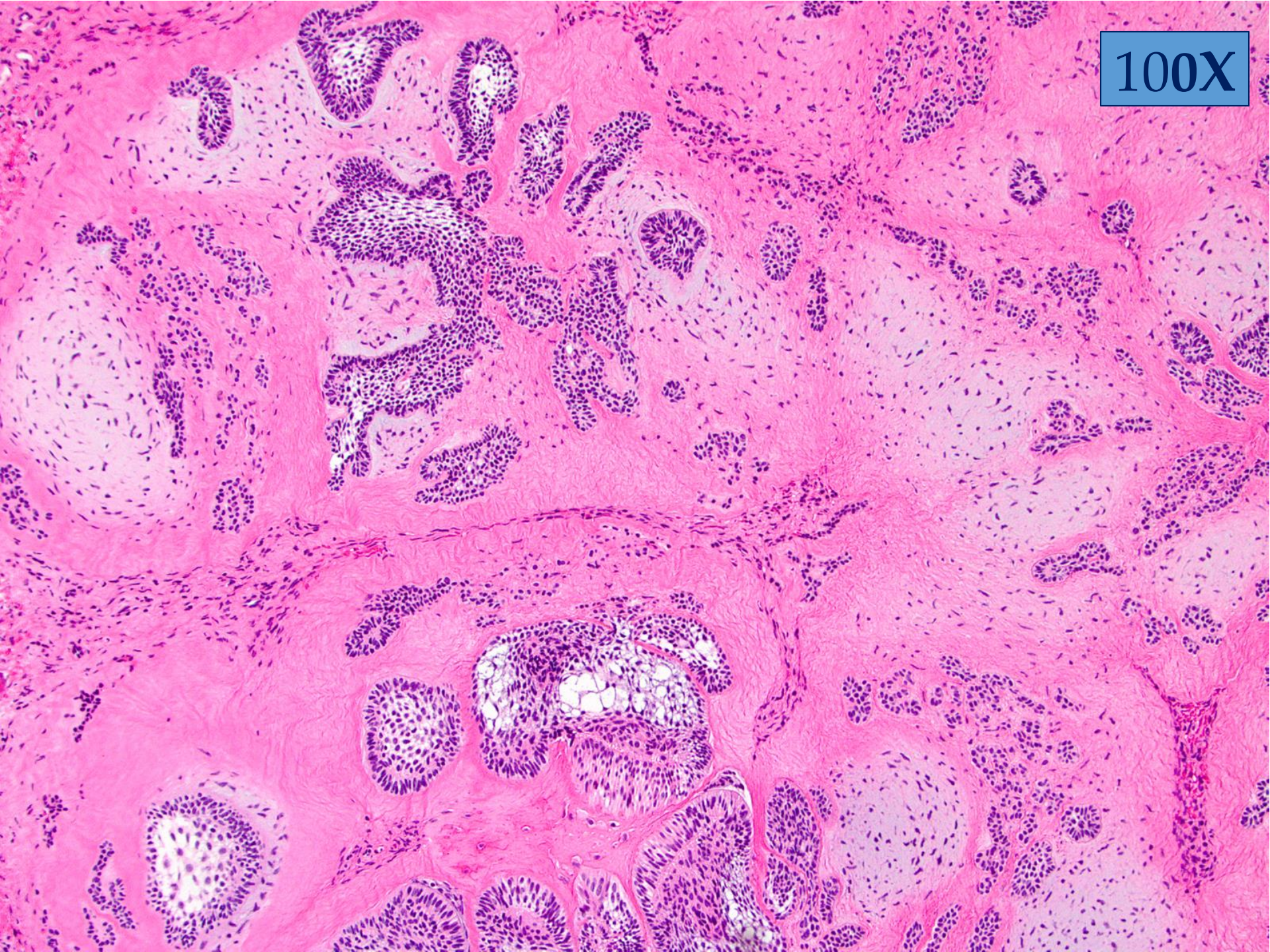
20X



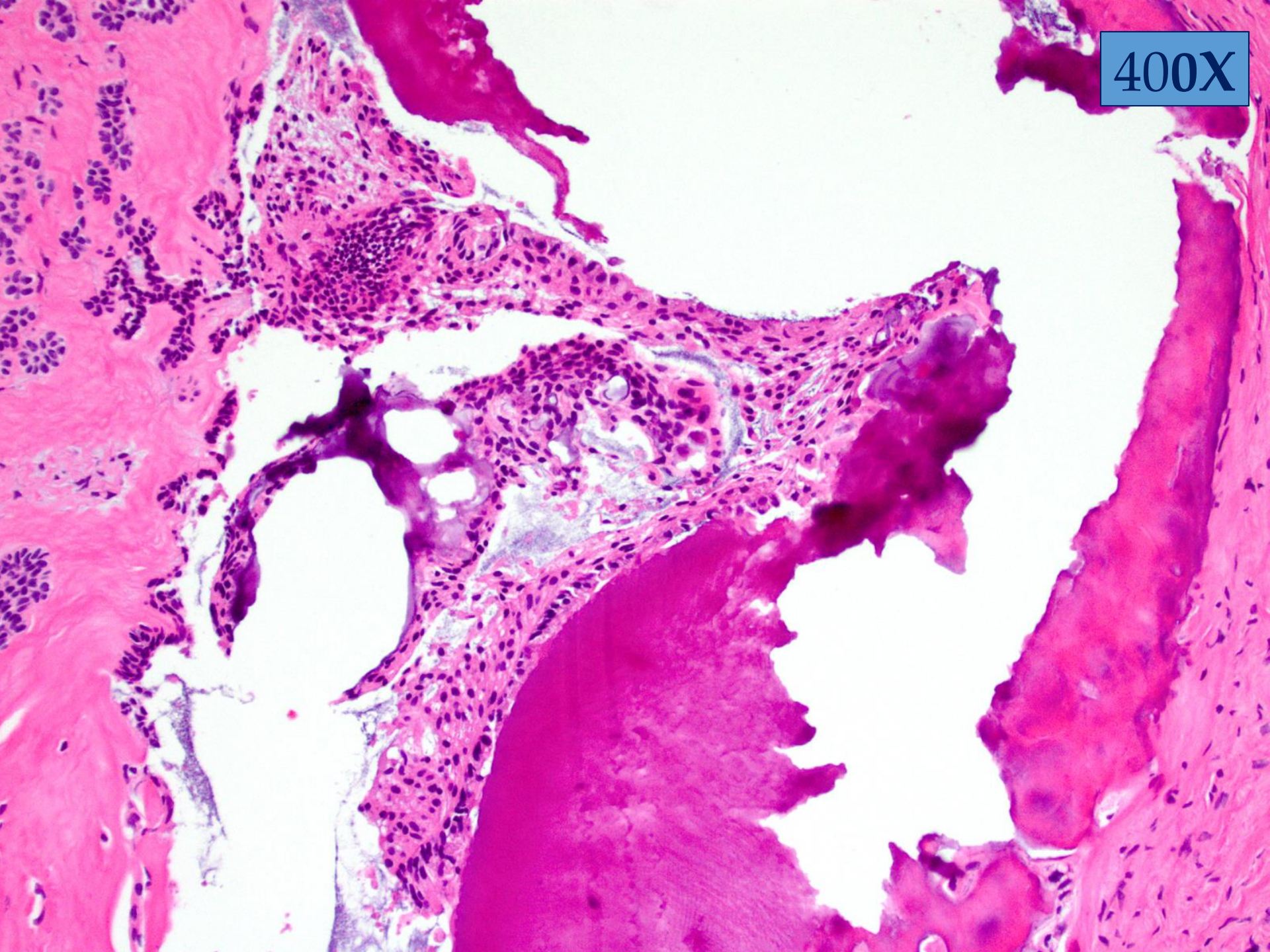
40X



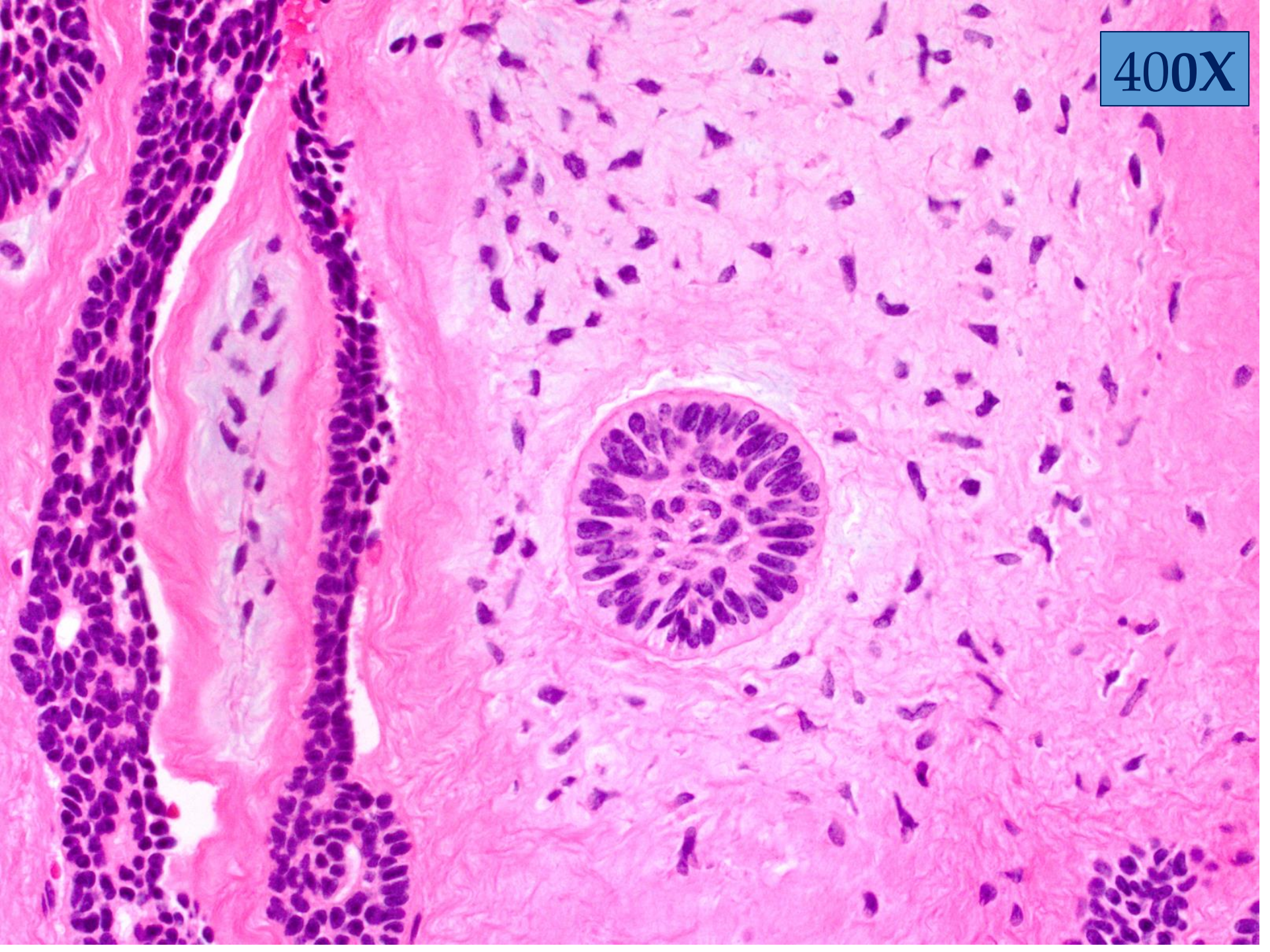
100X



400X



400X



1000X

