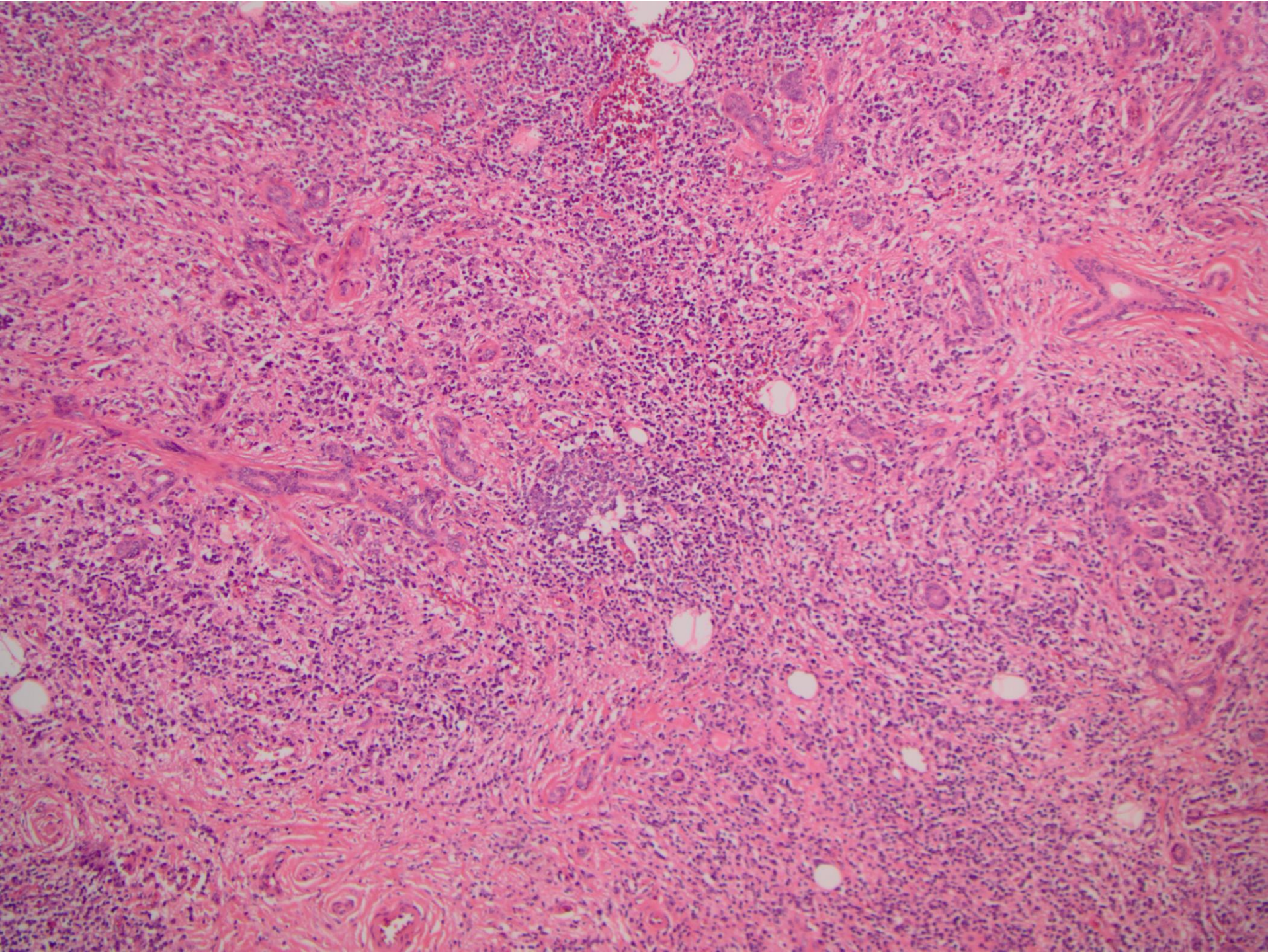
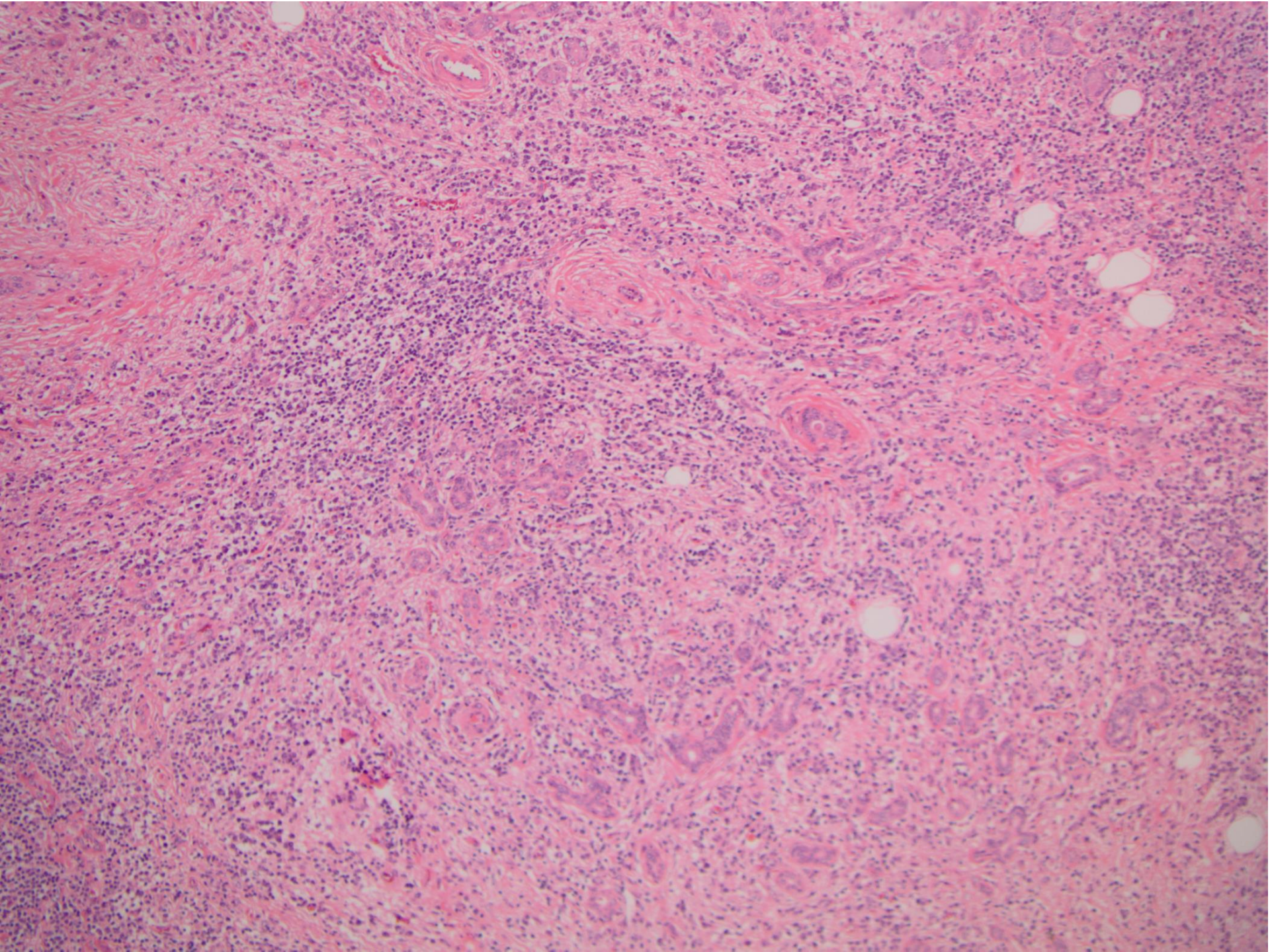


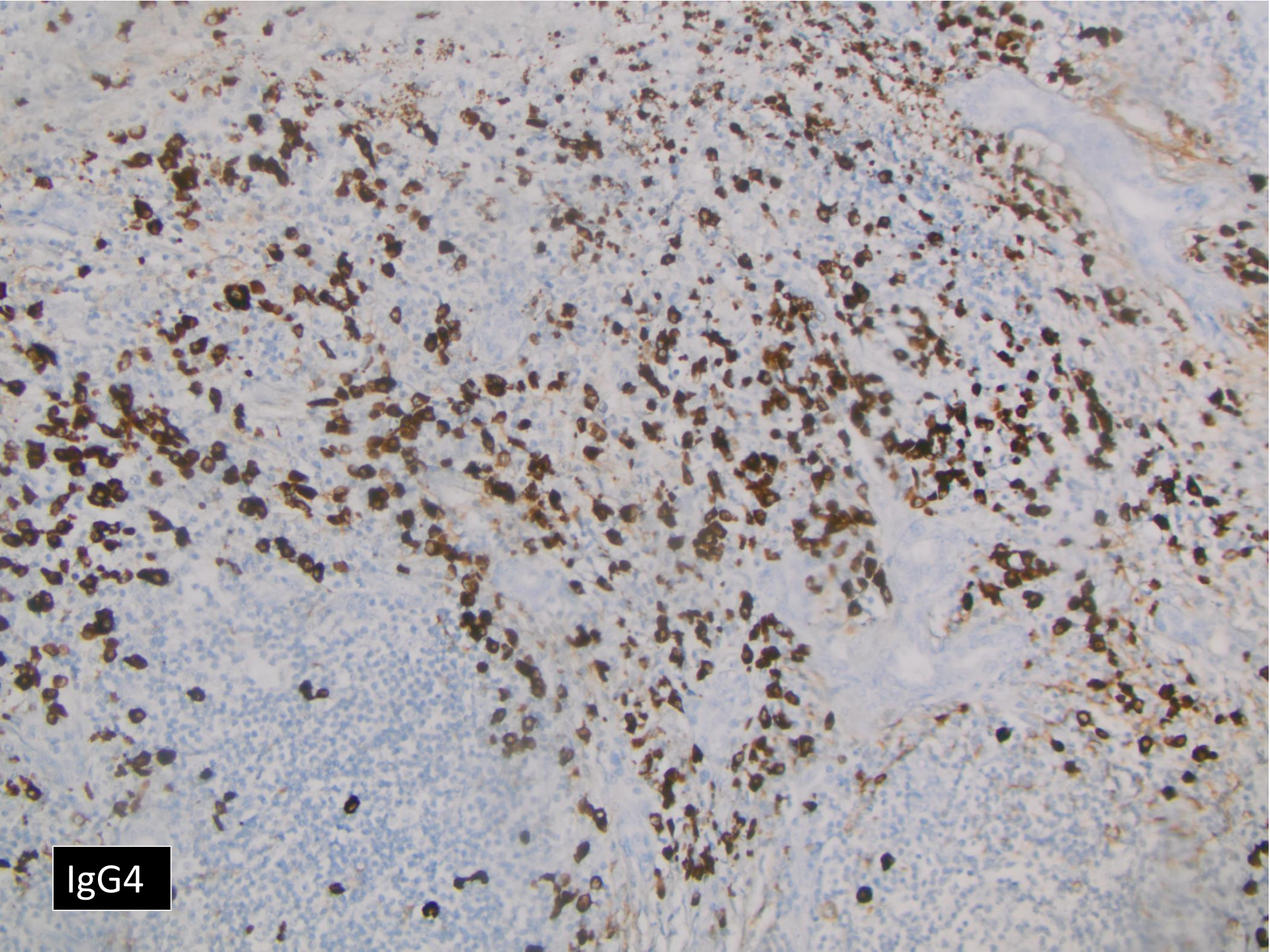
Case 7

- 38 year old female with bilateral parotid gland swelling
 - No other relevant symptoms

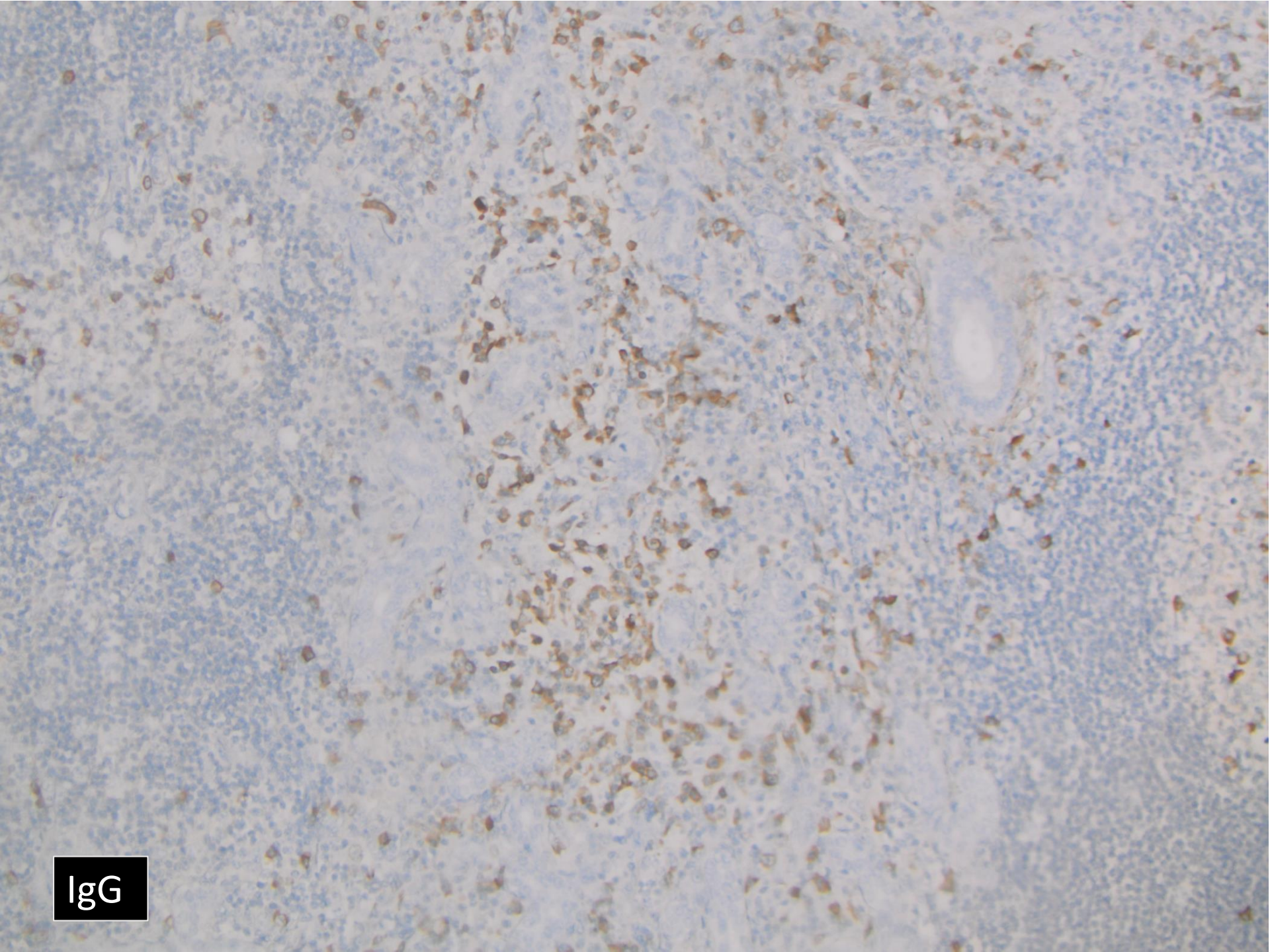
- Images demonstrate the histology from parotidectomy







IgG4



IgG