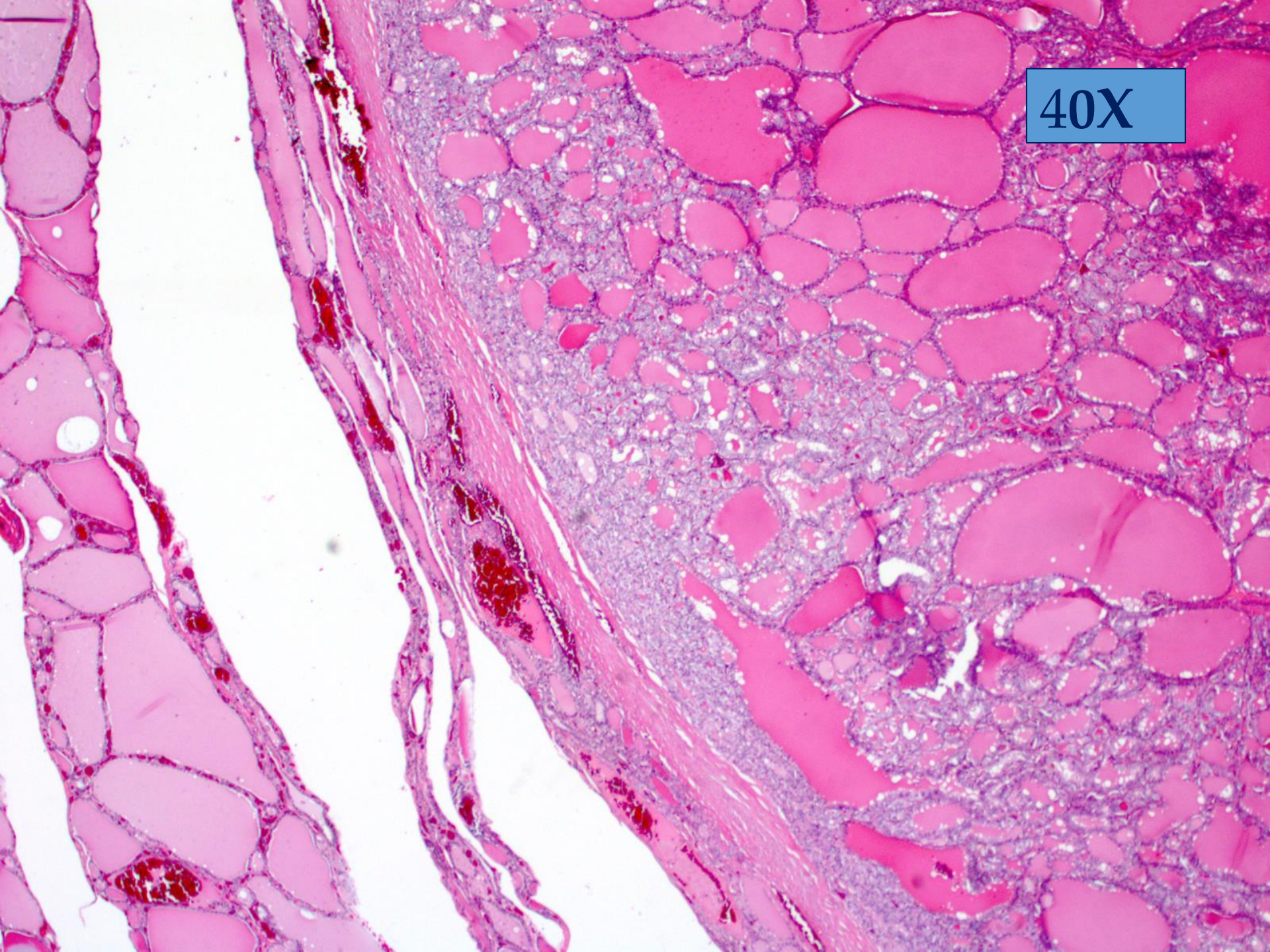


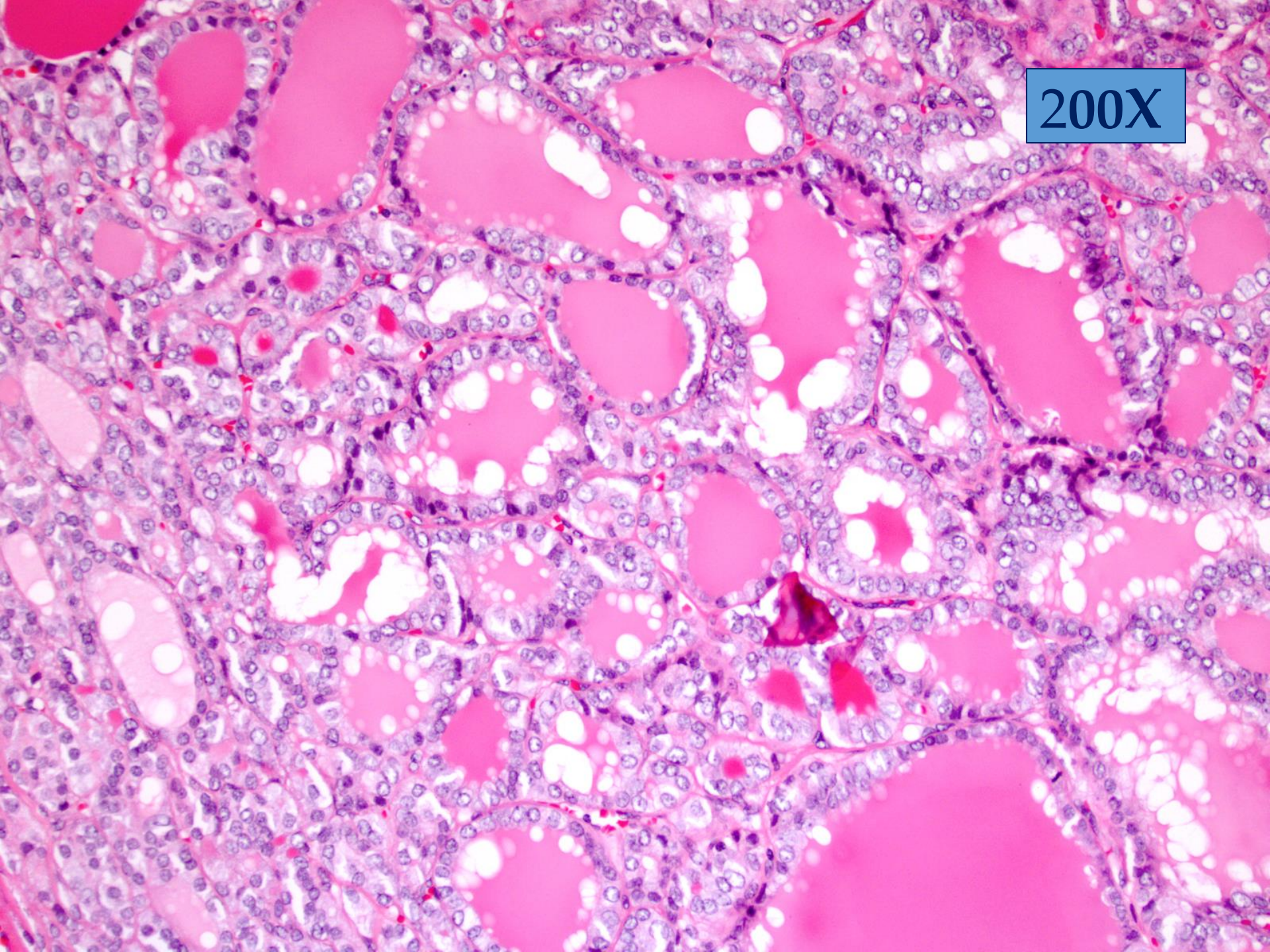
Case 6

- 46 year old male with 2.2 cm right thyroid nodule
 - FNA was called follicular lesion of undetermined significance
 - Pre-operative molecular testing revealed H-RAS mutation
 - Quoted 50-60% risk of malignancy
- Images demonstrate the histology from right thyroid lobectomy

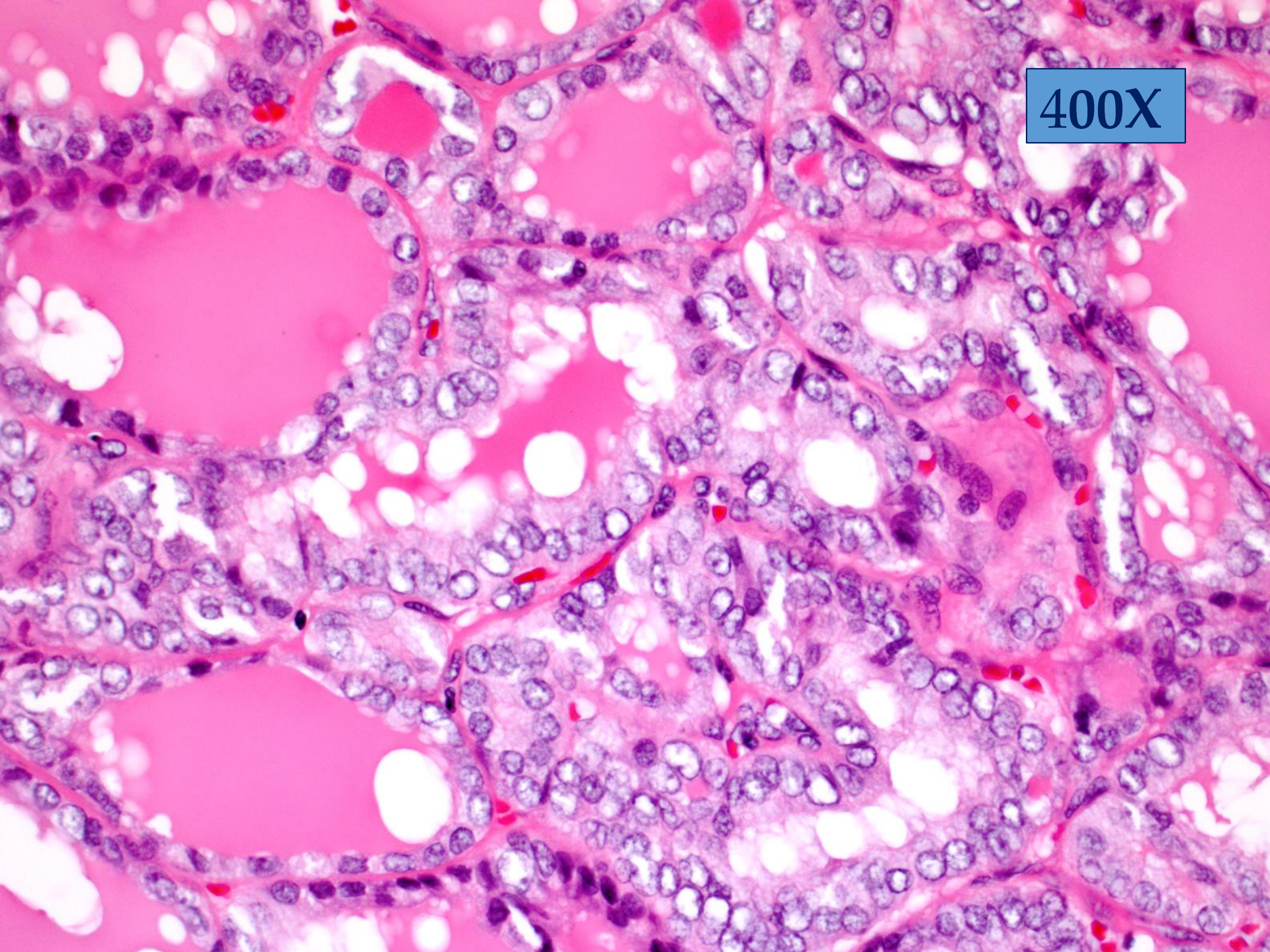
40X



200X



400X



BRAFVE

40X

