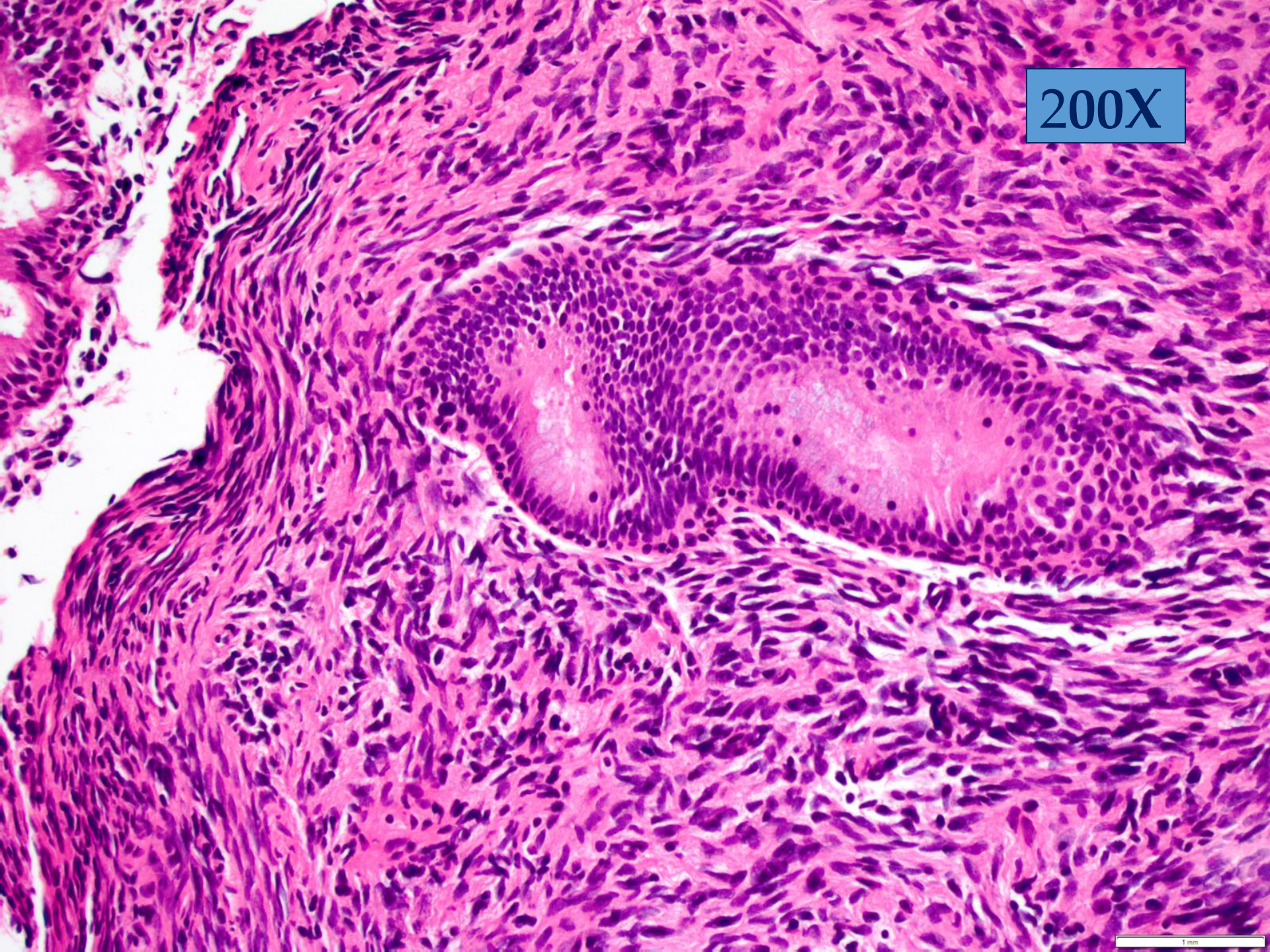


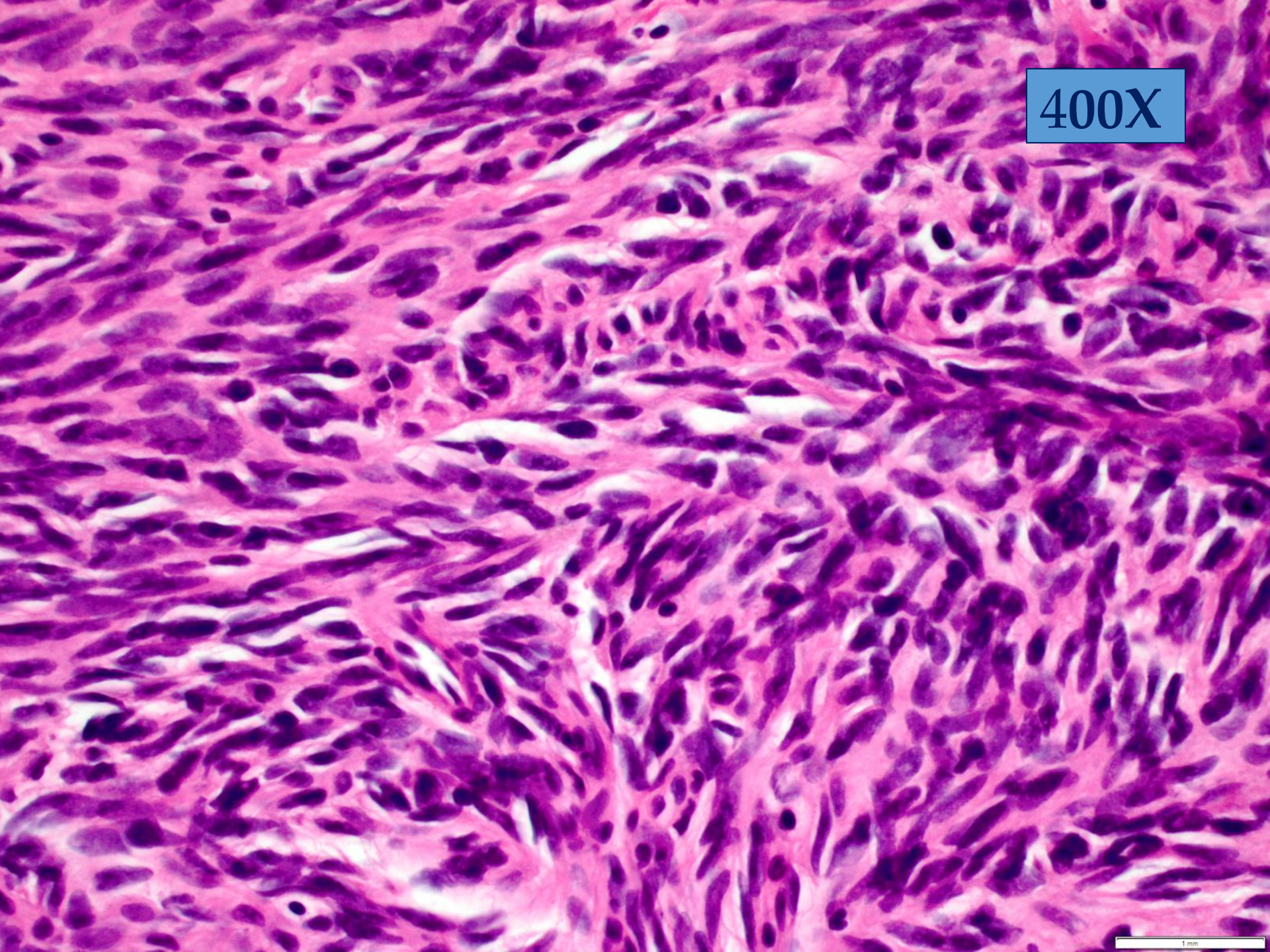
Case 3

- 60 year old female with right nasal obstruction
 - No prior history
 - Congestion in summer 2016, progressing into fall and then winter, worsened after cold in December 2017 until barely able to breathe
 - Endoscopic exam revealed middle meatus polyp arising from anterior ethmoid
- Images demonstrate the histology from round 2 of biopsies

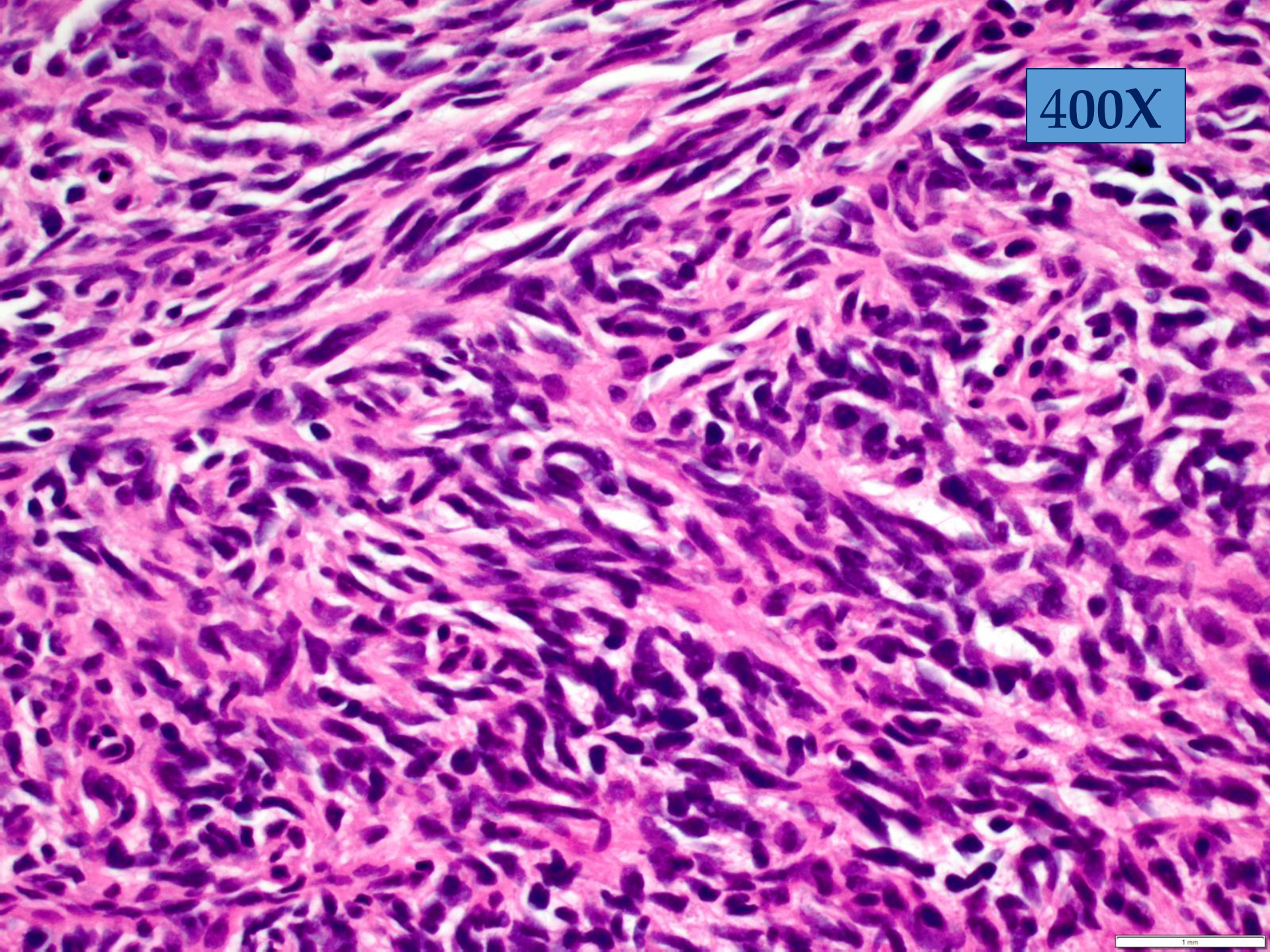
200X



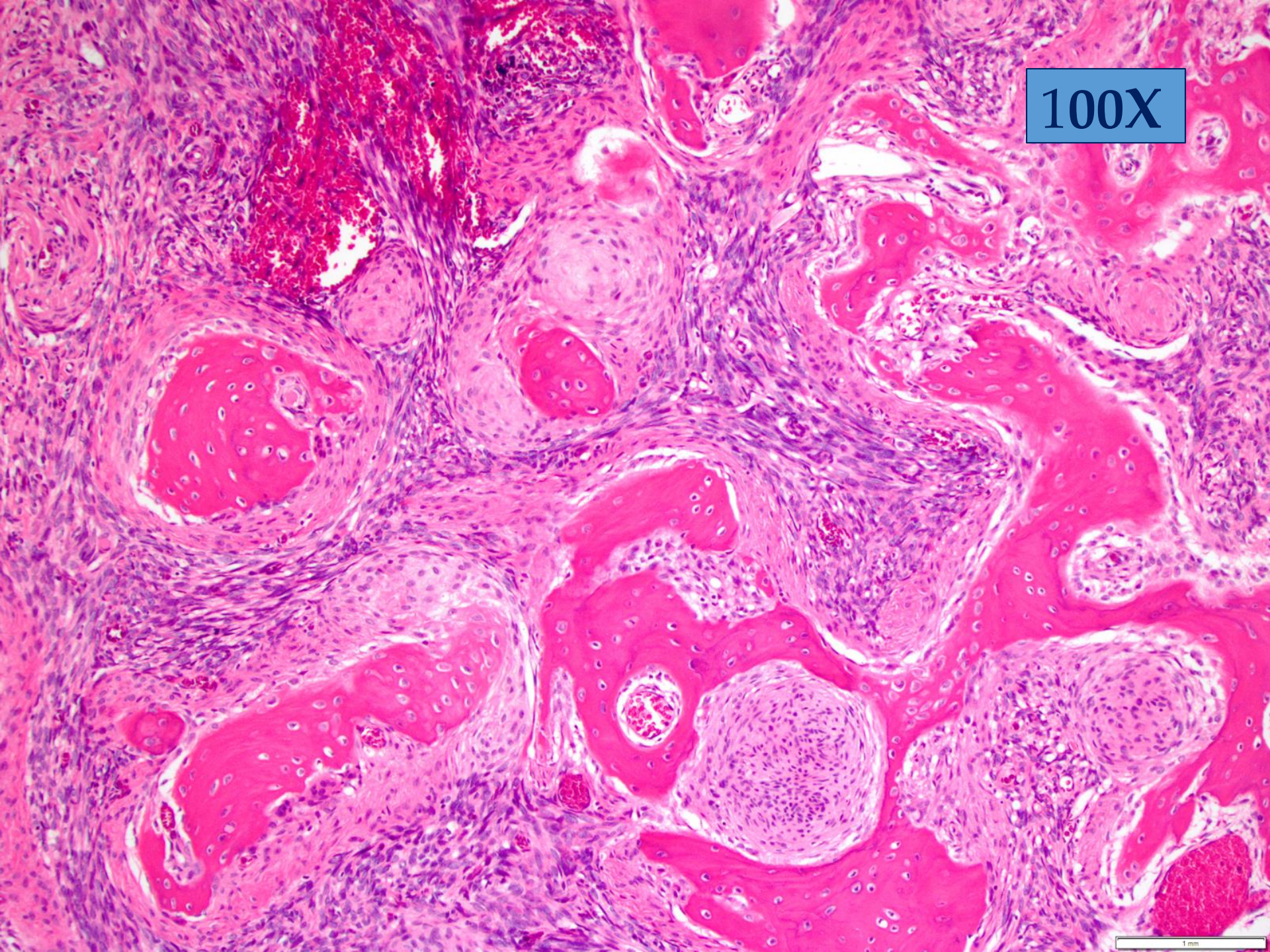
400X



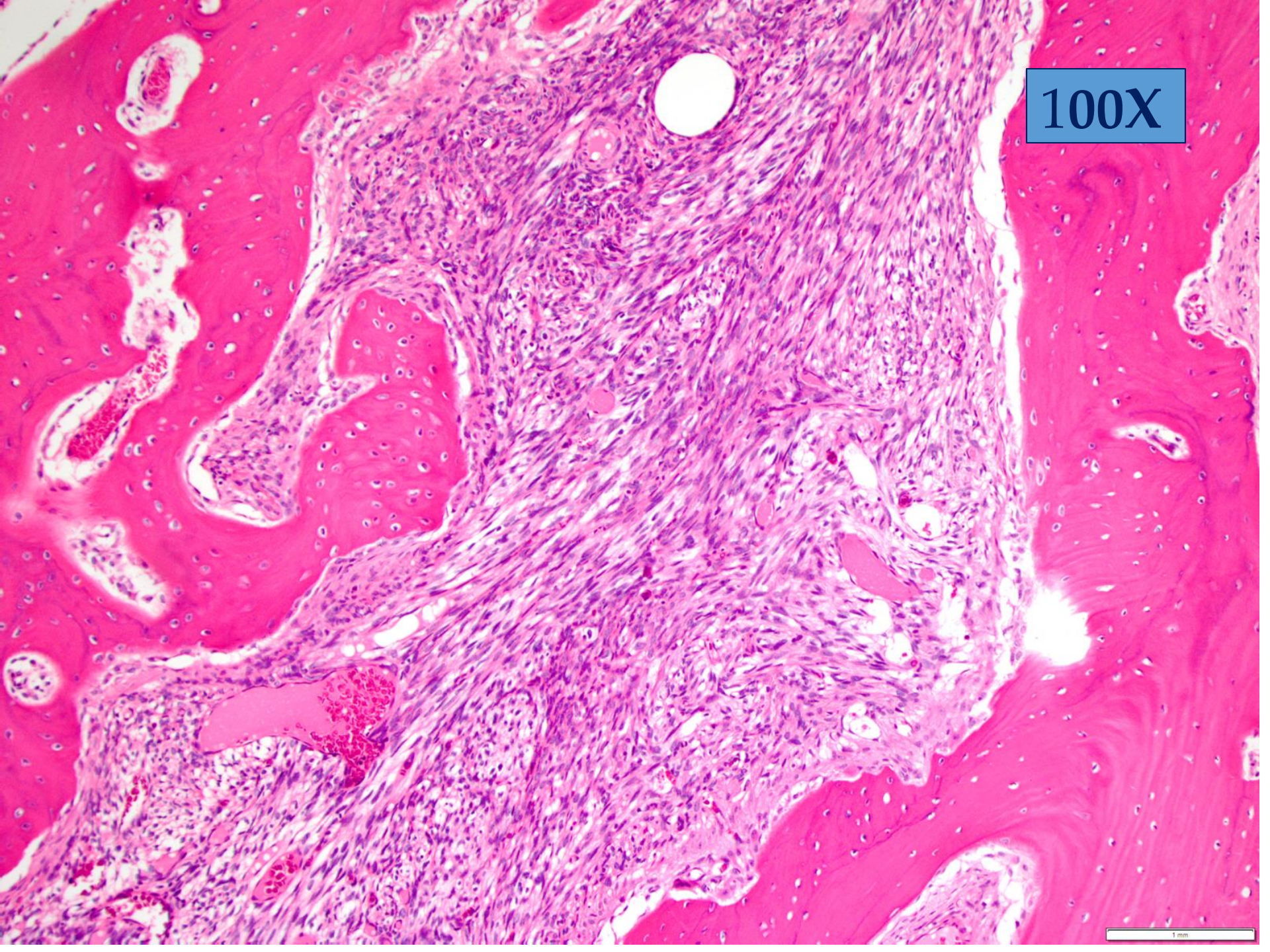
400X



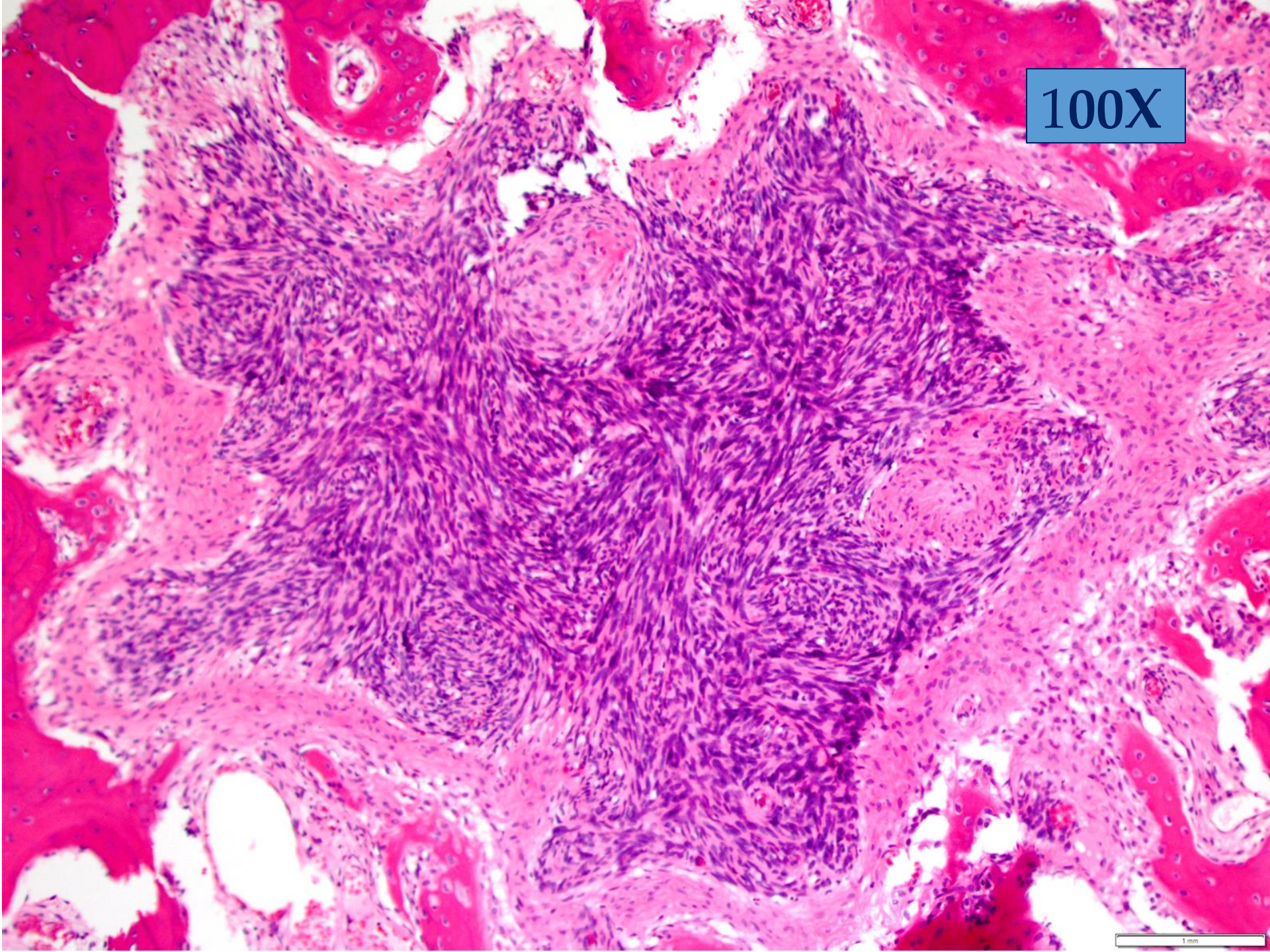
100X



100X



100X



S100

400X

SMA

MyoD1

