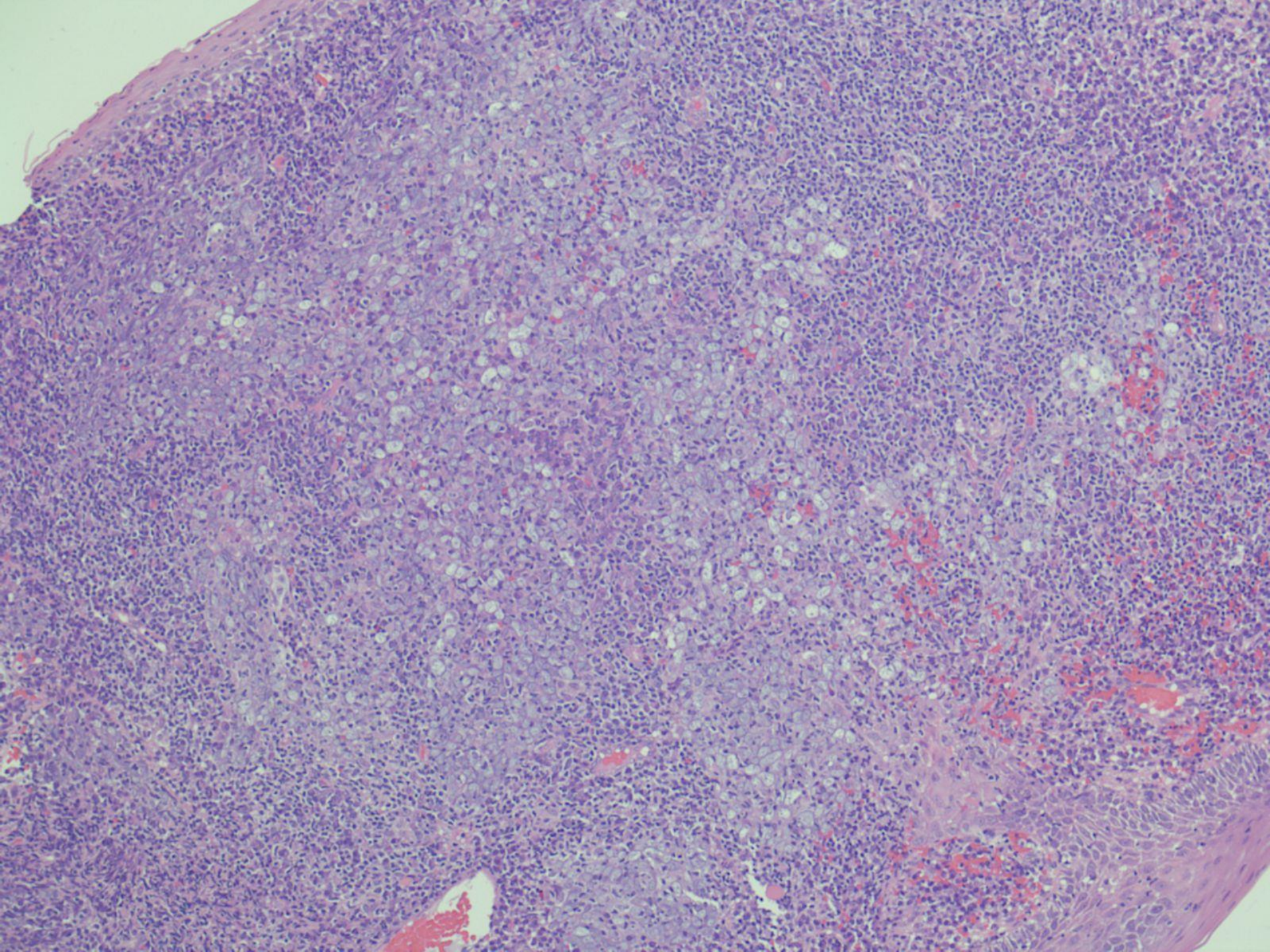
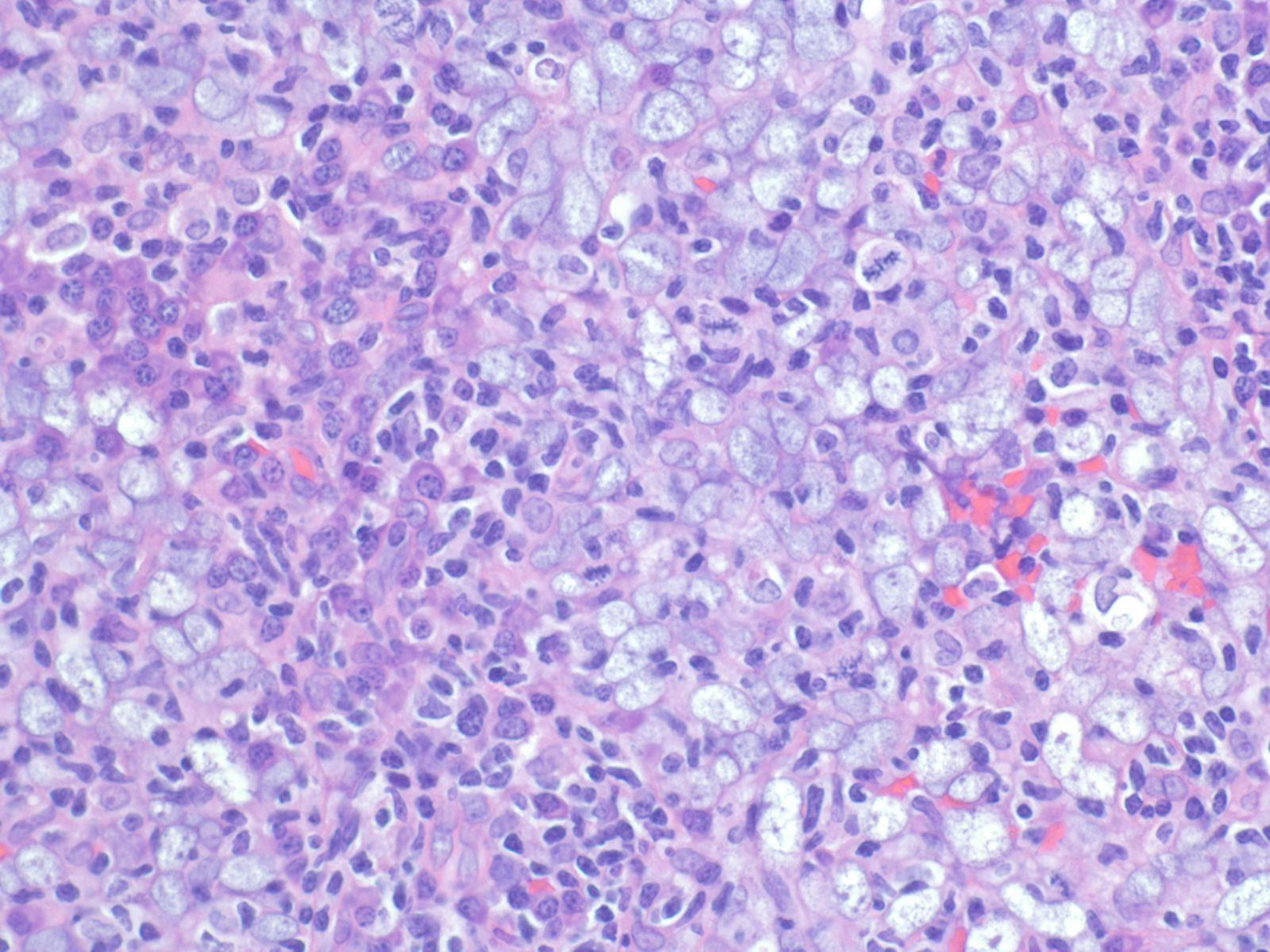
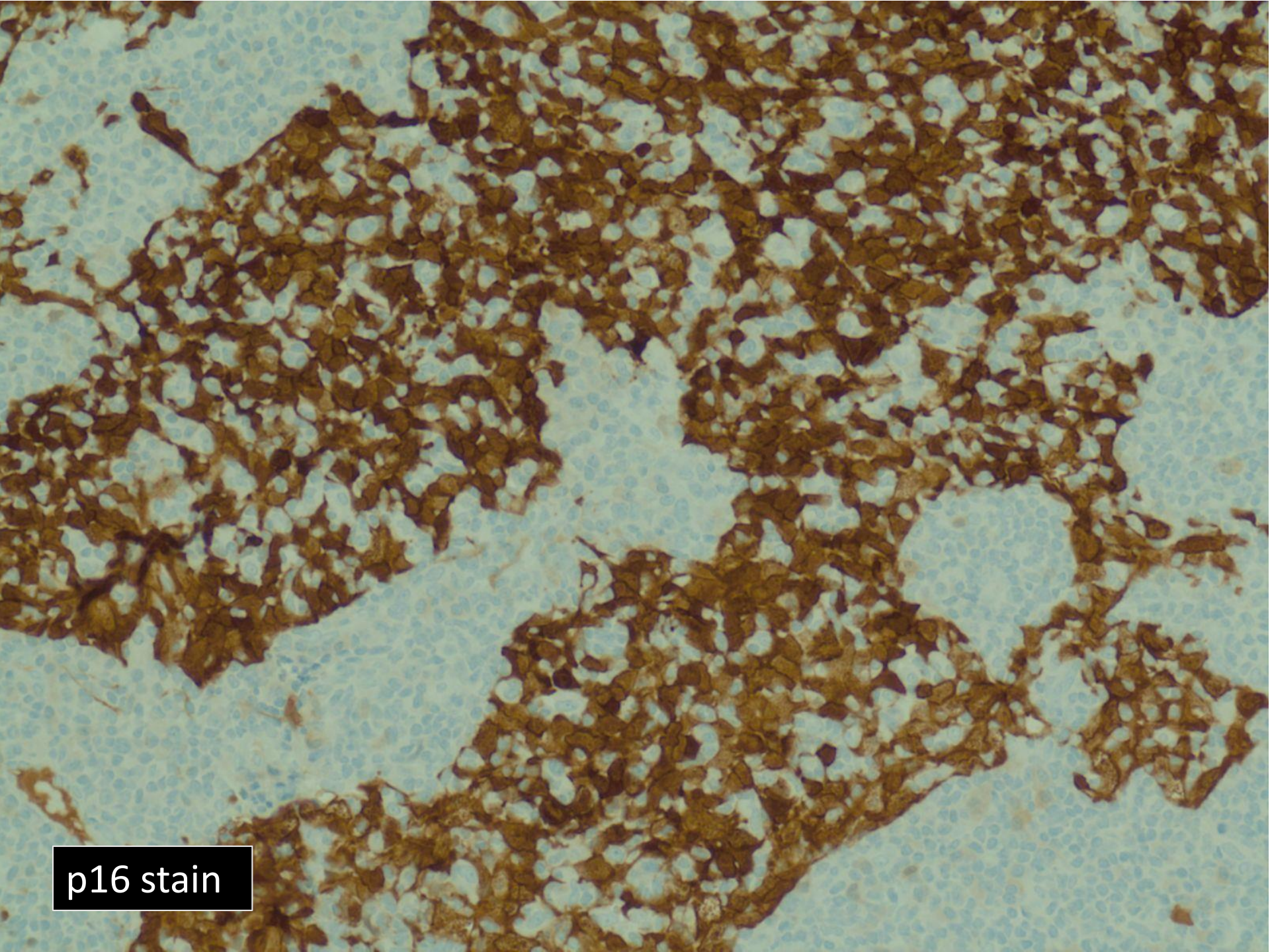


# Case 2

- 48 year old female with tonsillar tumor and enlarged neck node
  - Non-smoker
  - Non-drinker
  - No other relevant symptoms
- Images demonstrate the histology from biopsies







p16 stain