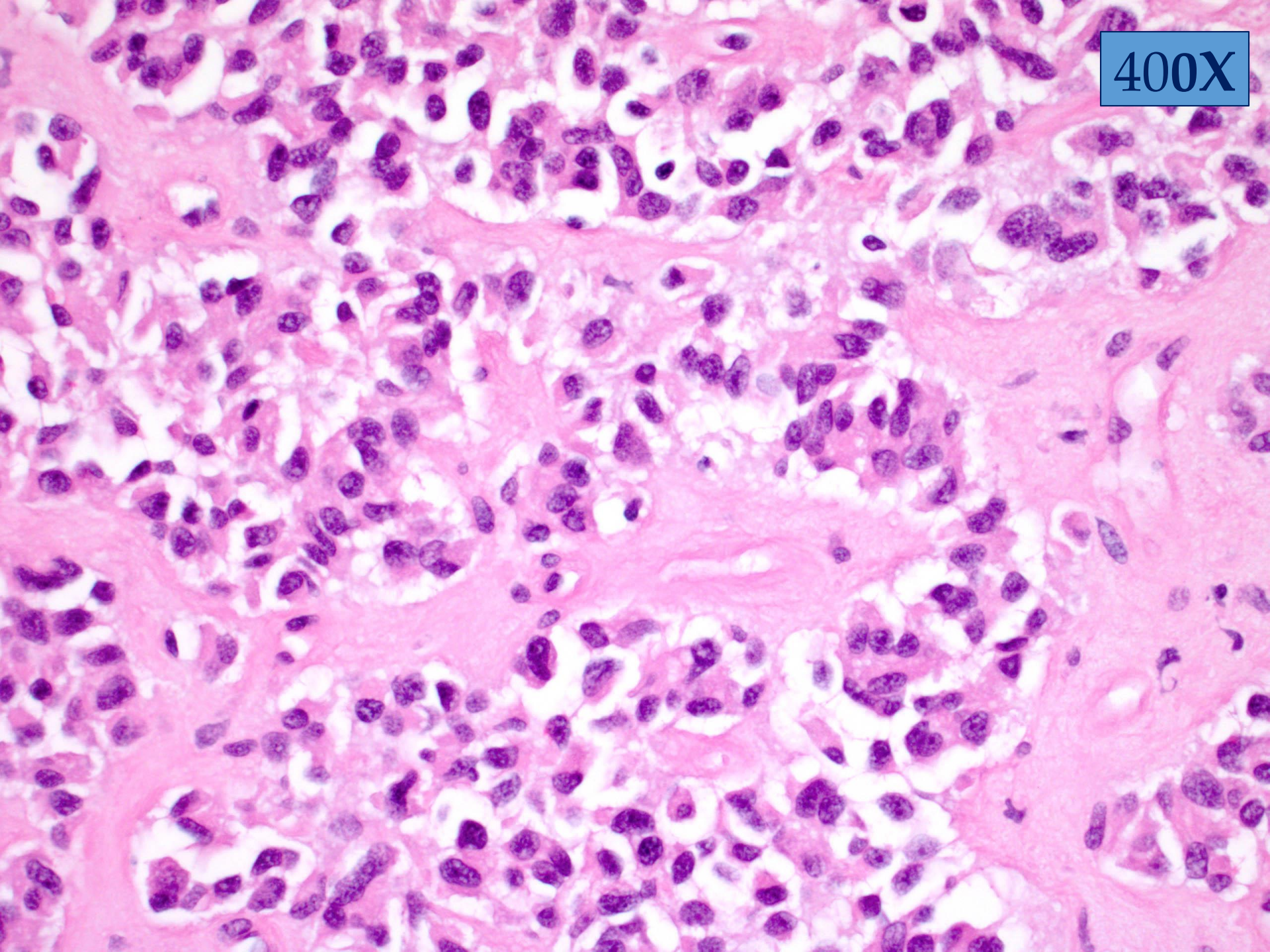


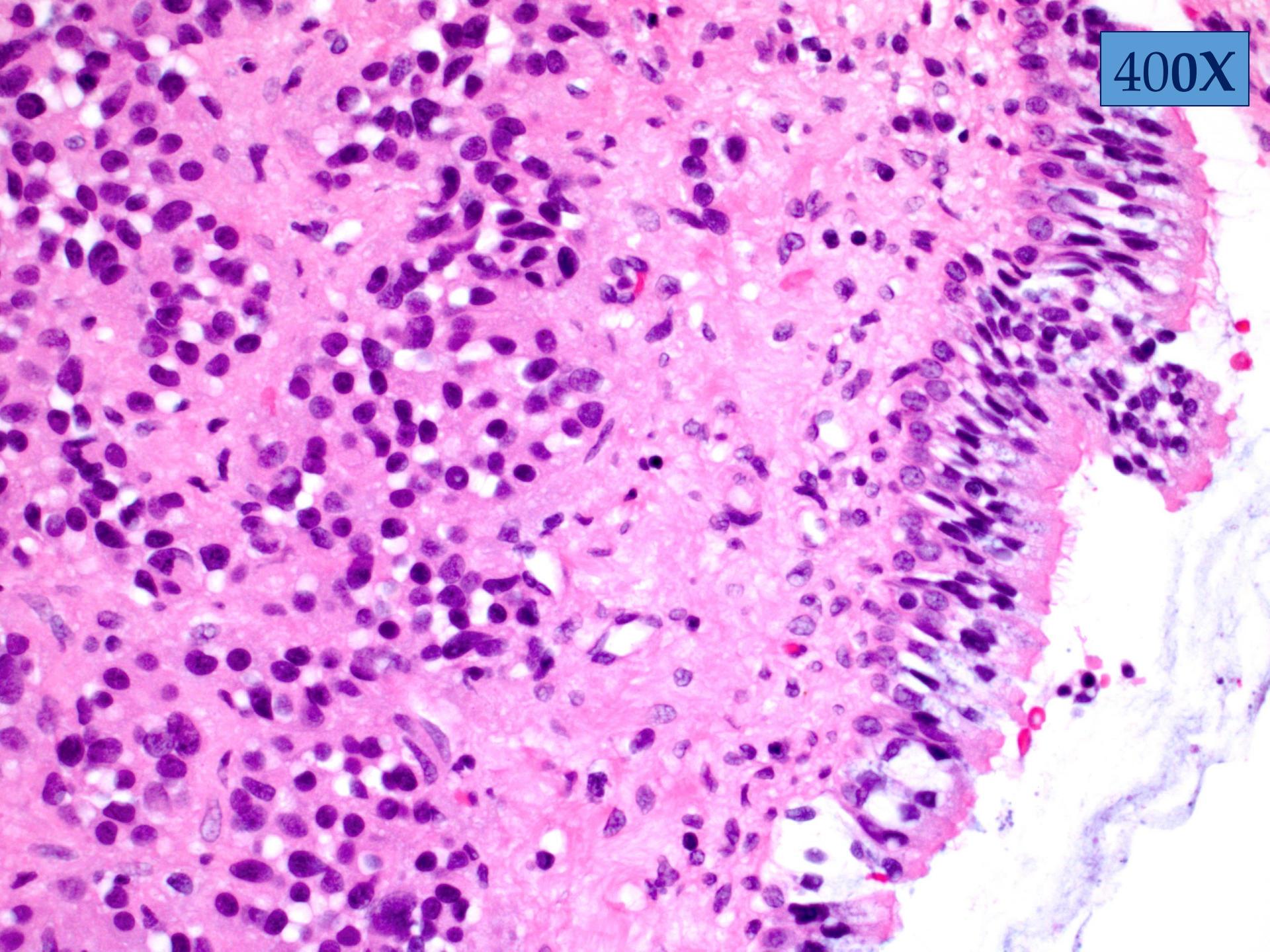
Case 10

- 46 year old male with a skull base mass
 - MR exam is significant for findings that will be discussed at the base of skull
- Images demonstrate the posterior ethmoid mass

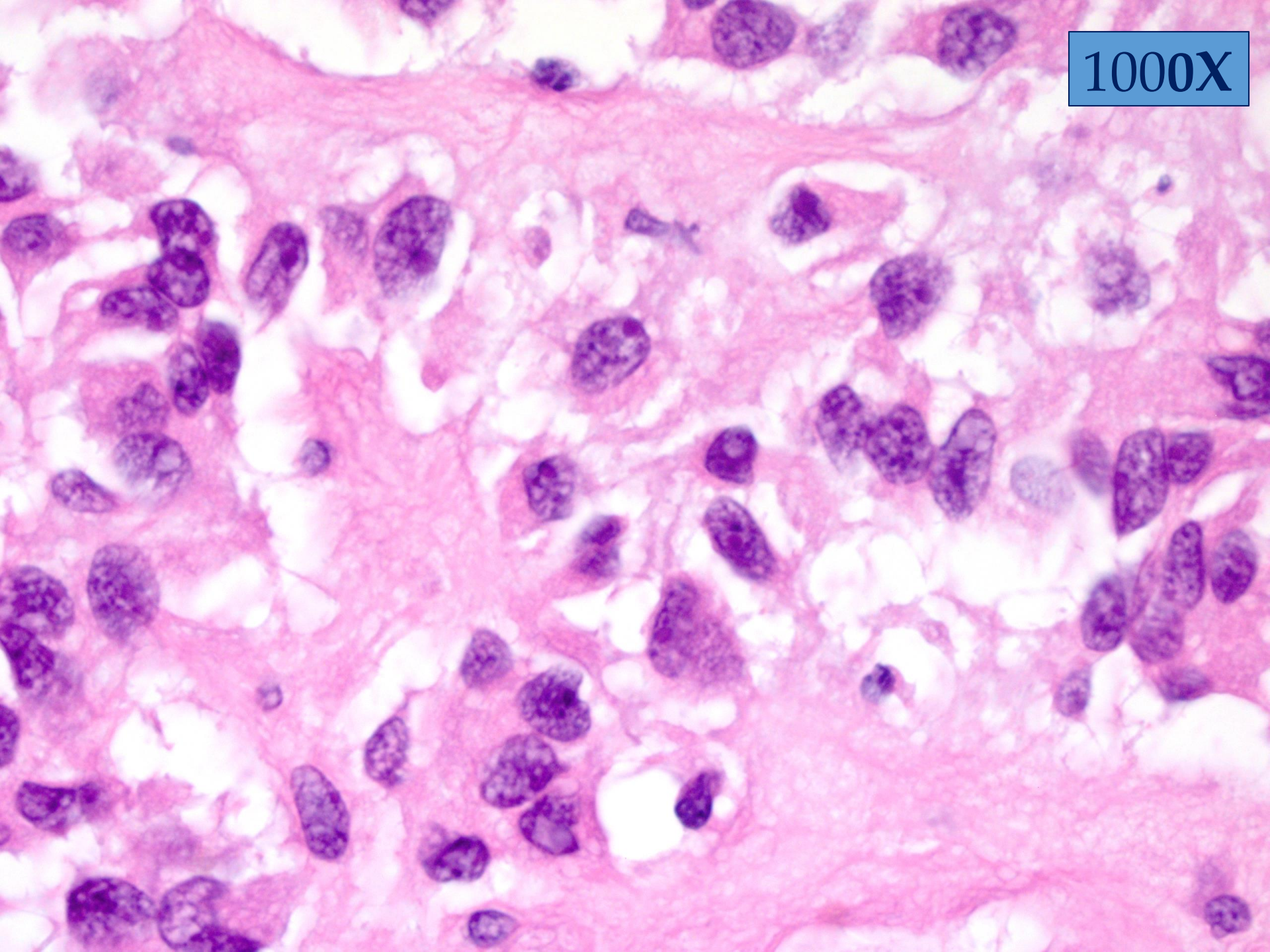
400X



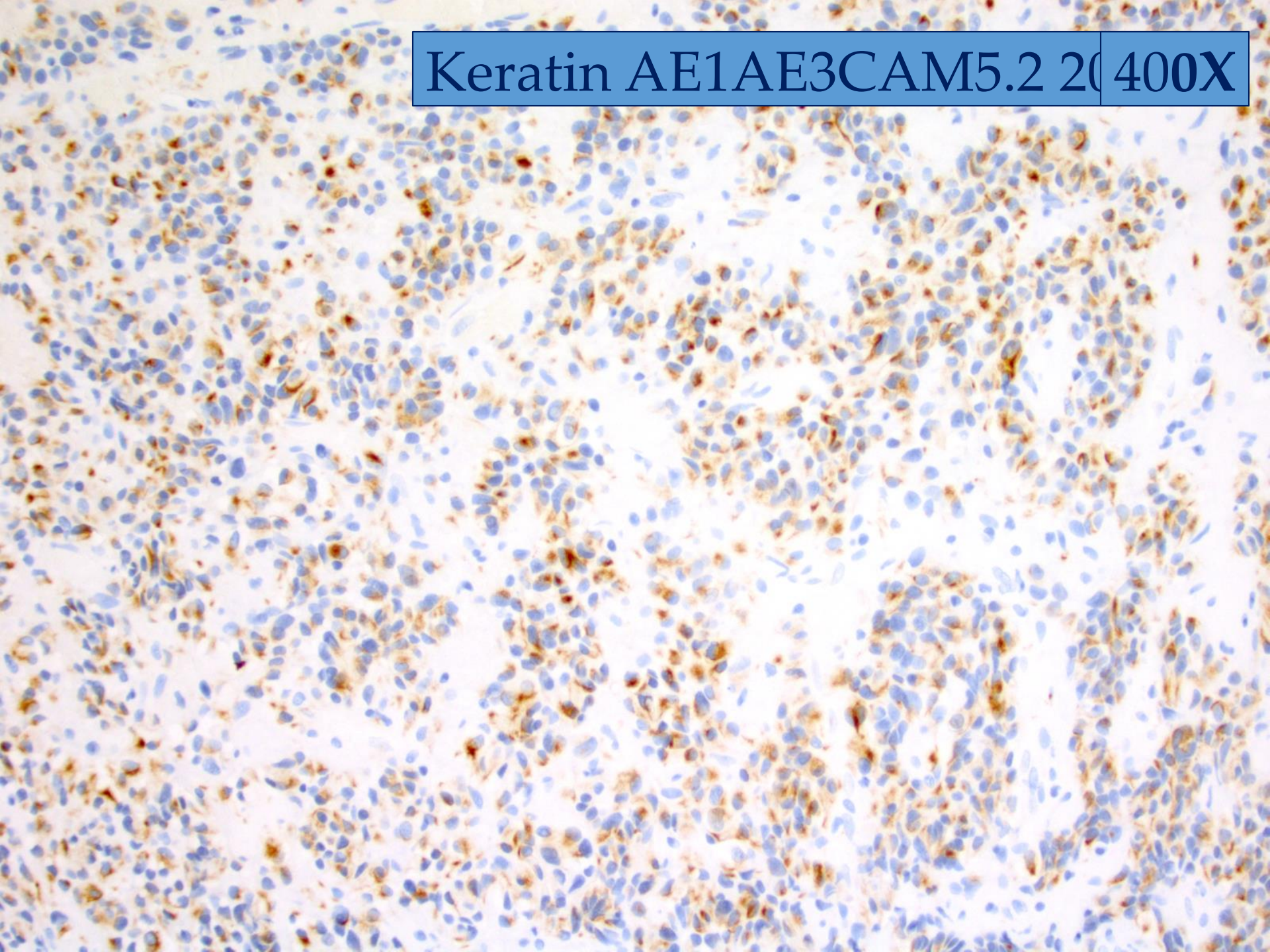
400X



1000X



Keratin AE1AE3CAM5.2 20 400X



Synaptophysin 200X

