

## Case 8

65-year old male presented with generalized abdominal pain

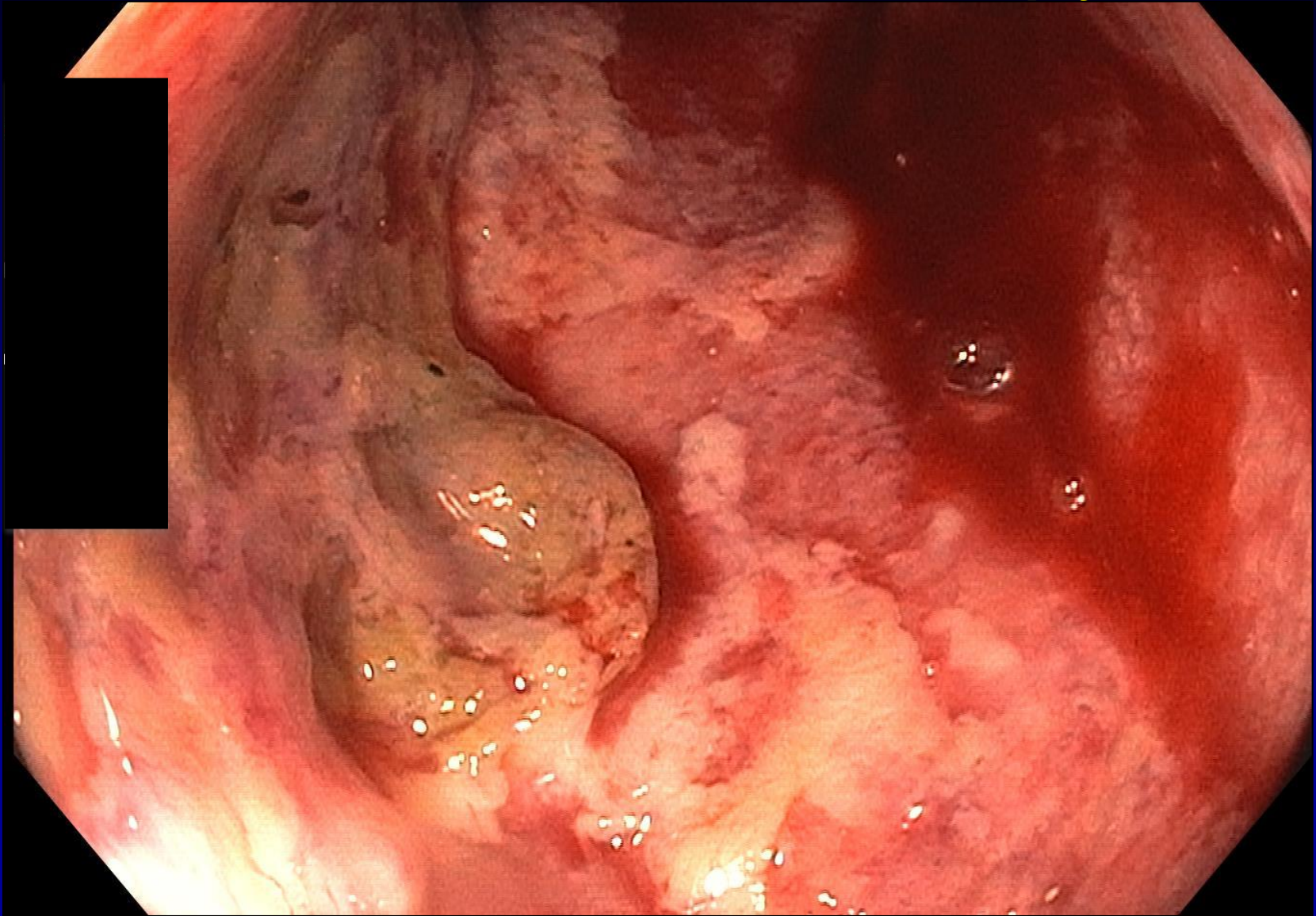
Perianal skin tags

Endoscopically severe colitis

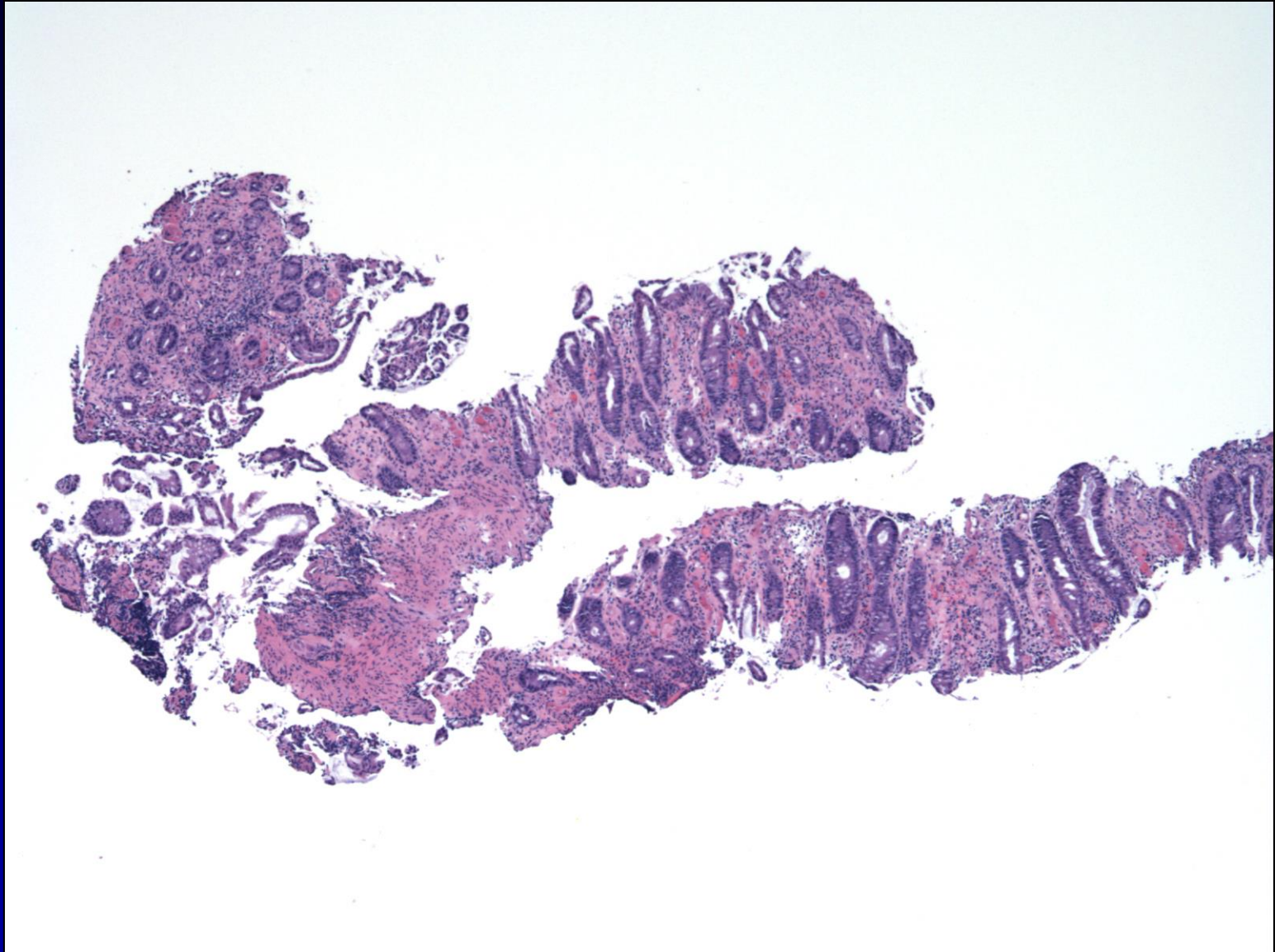
- Friable, ulcerated mucosa in rectum and sigmoid colon
- Sloughing mucosa
- Skip areas in rectosigmoid colon
- Normal colon above 40 cm

Sigmoid colon rigid, so procedure aborted before right colon examined

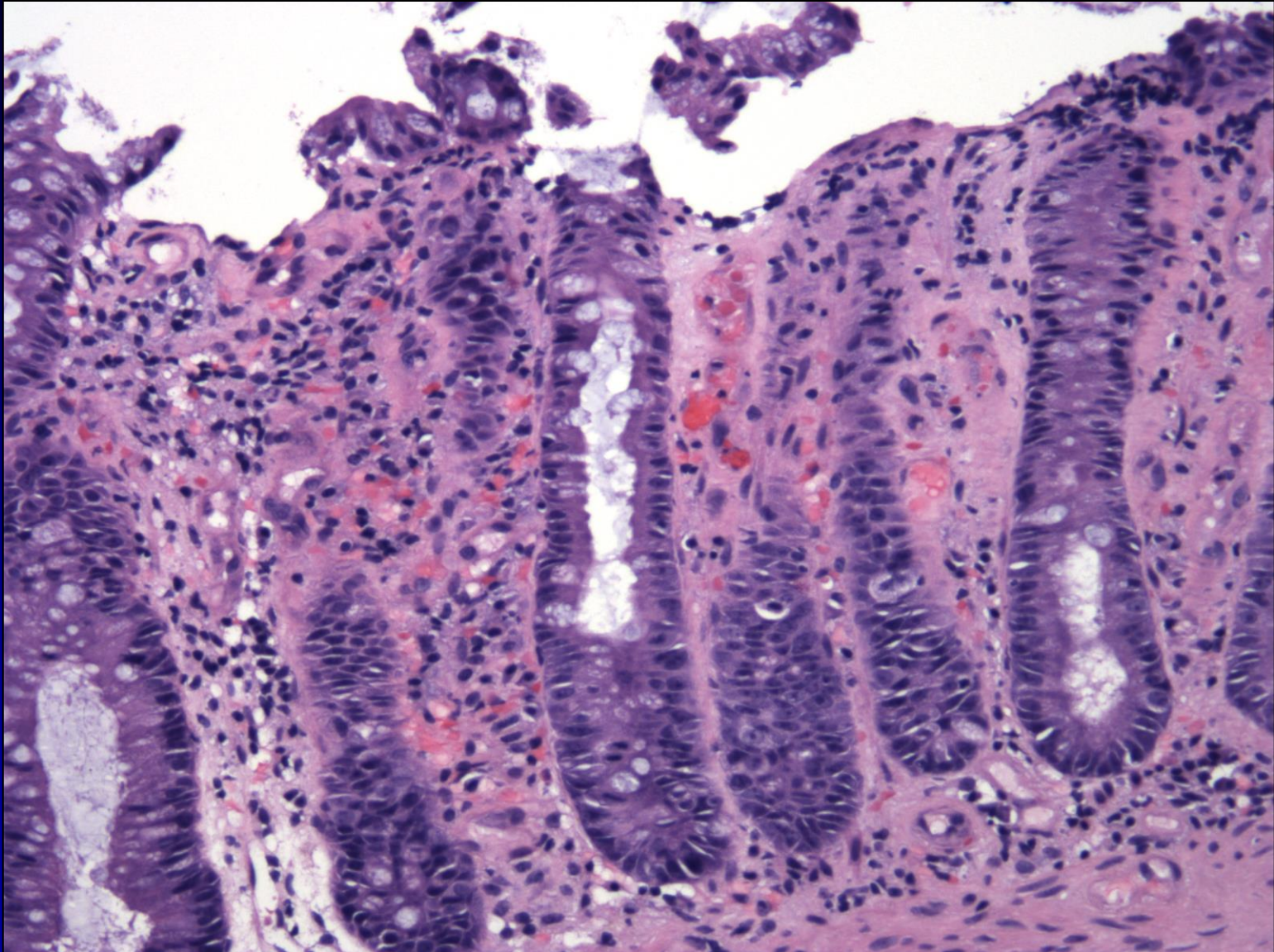
# Case 8-Colonoscopy



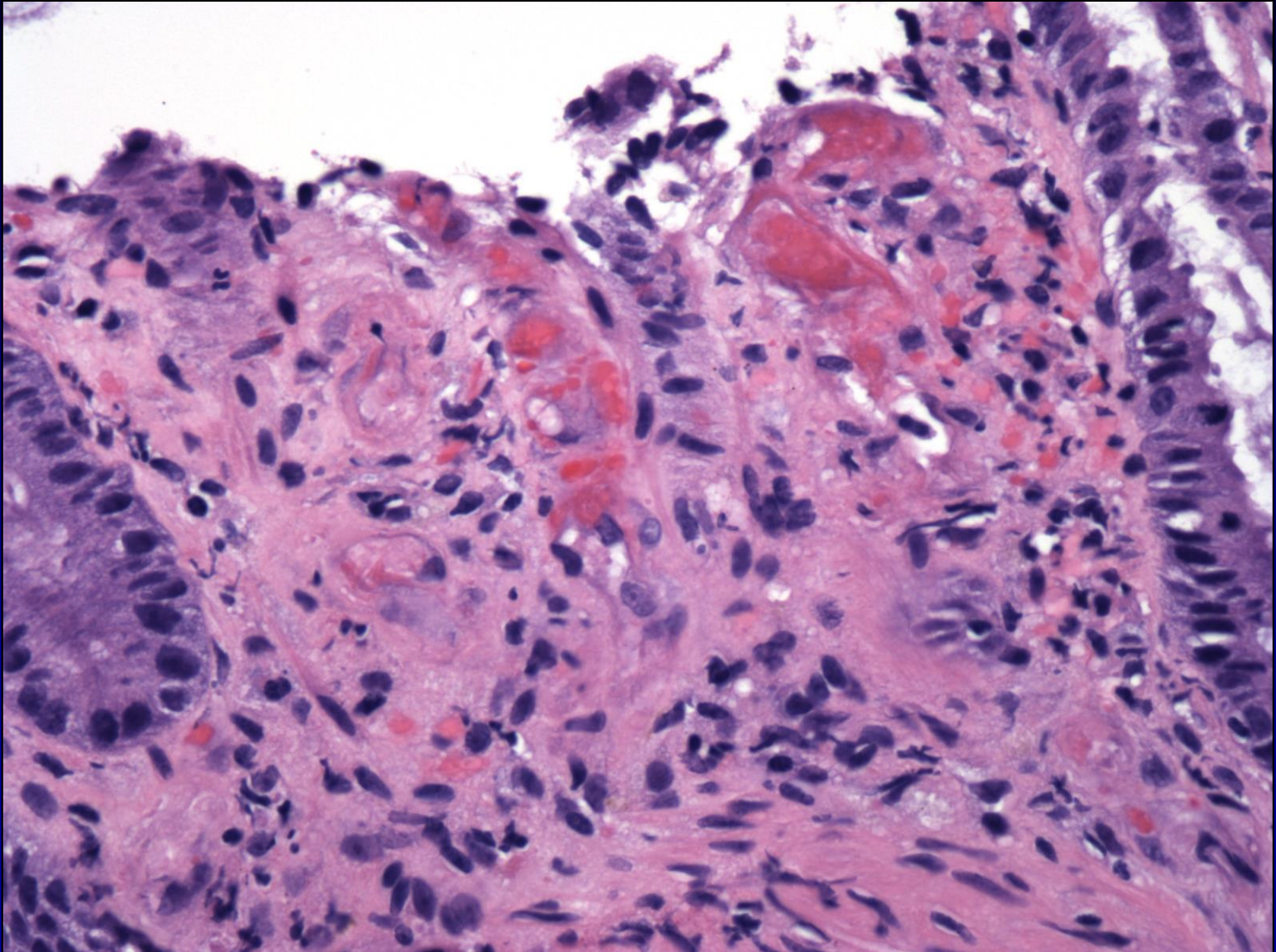
# Case 8-Colonic Biopsy Samples



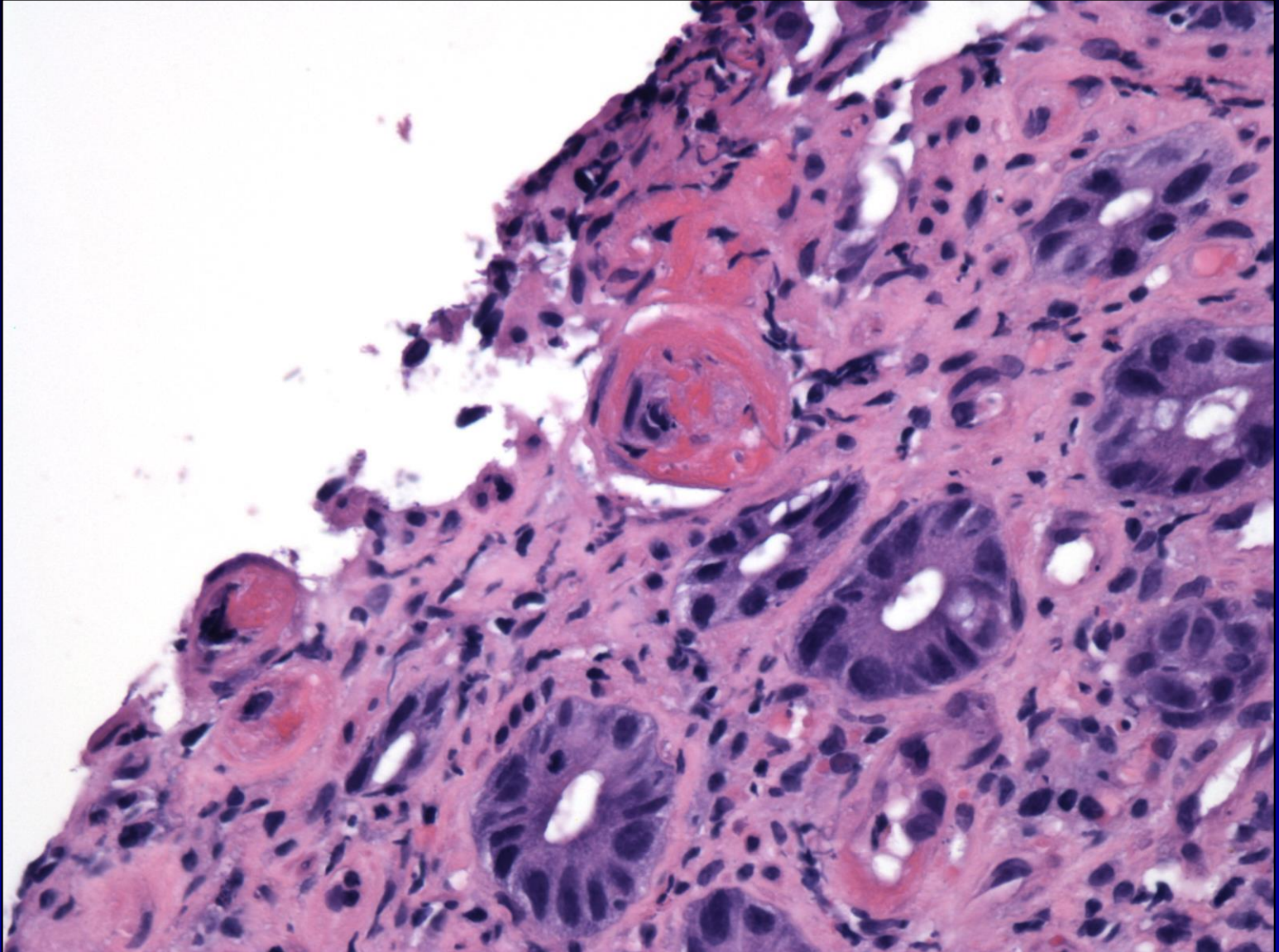
# Case 8-Colonic Biopsy Samples



# Case 8-Colonic Biopsy Samples



# Case 8-Colonic Biopsy Samples



# Case 8-Colonic Biopsy Samples

