

Case 6

22-year old woman with recent diagnosis of ulcerative colitis

Initial response to corticosteroid therapy

Developed diarrheal symptoms and abdominal pain

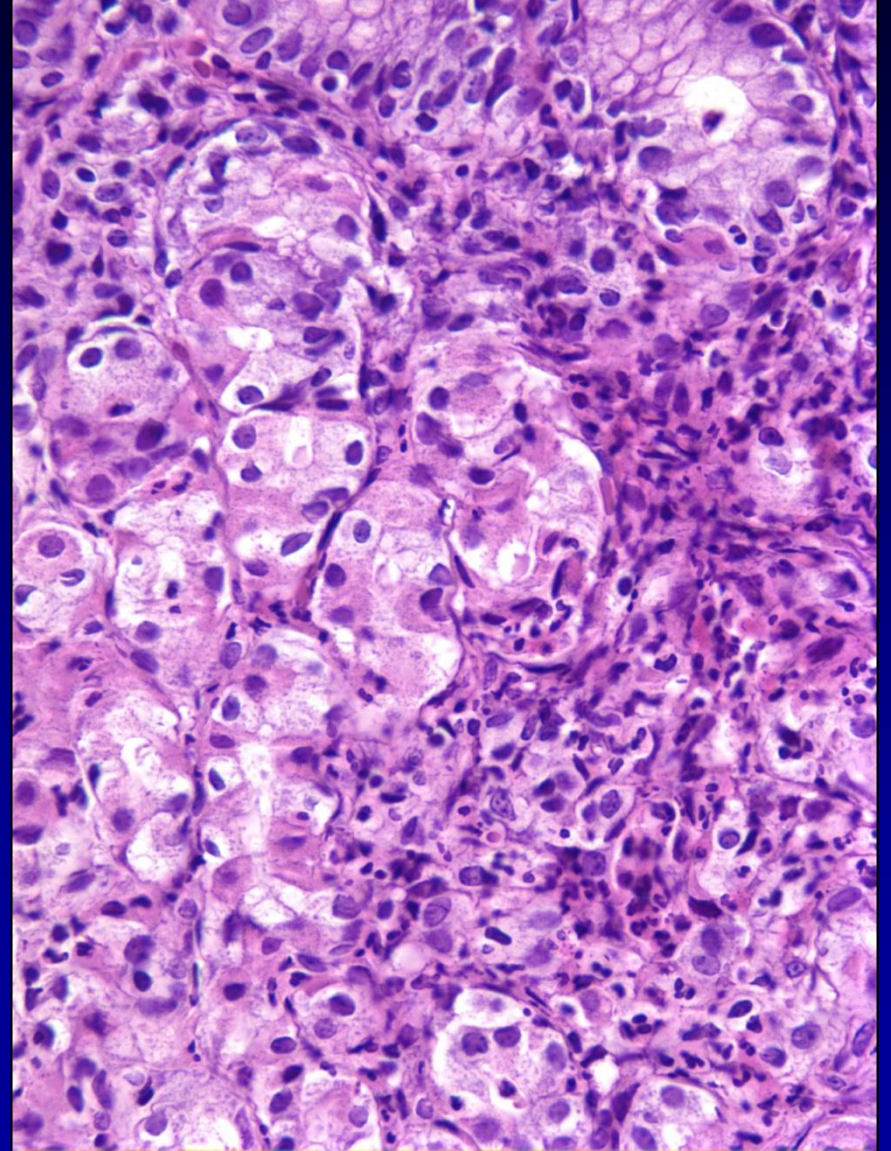
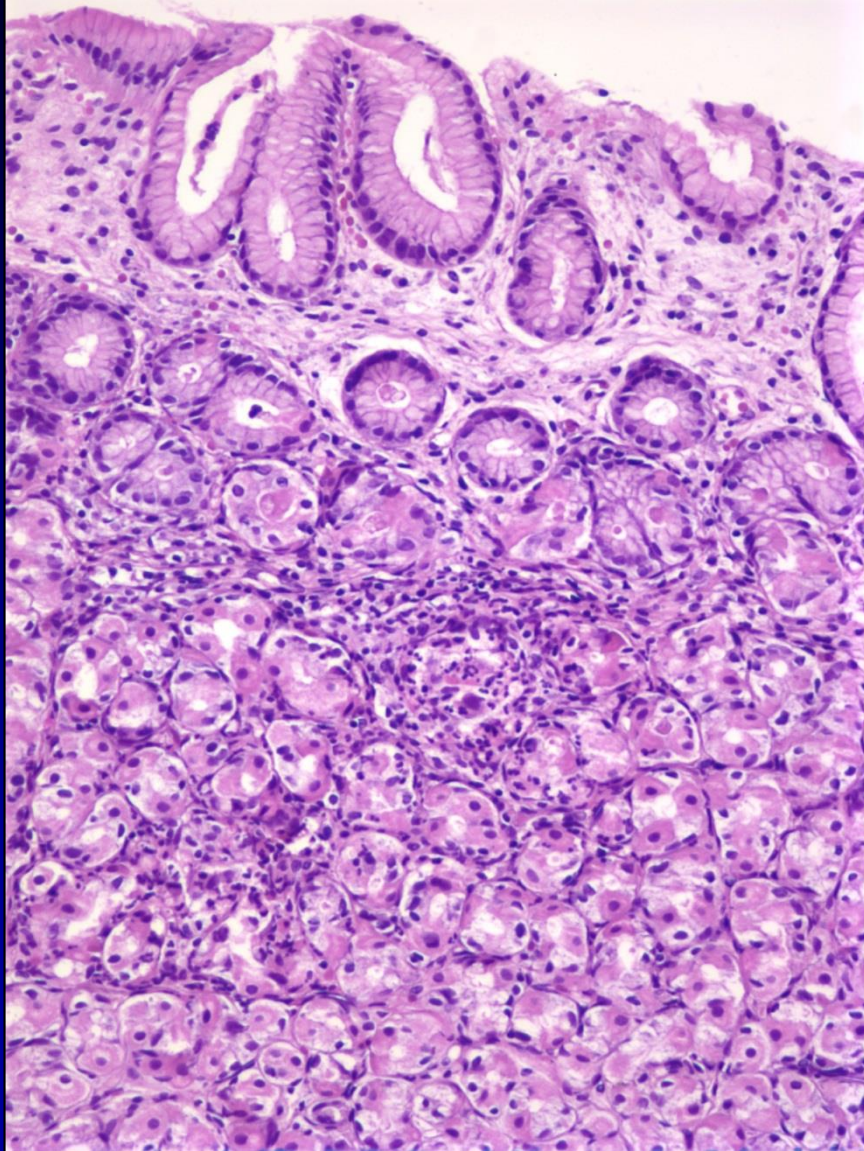
Colonoscopy

- Mildly active colitis

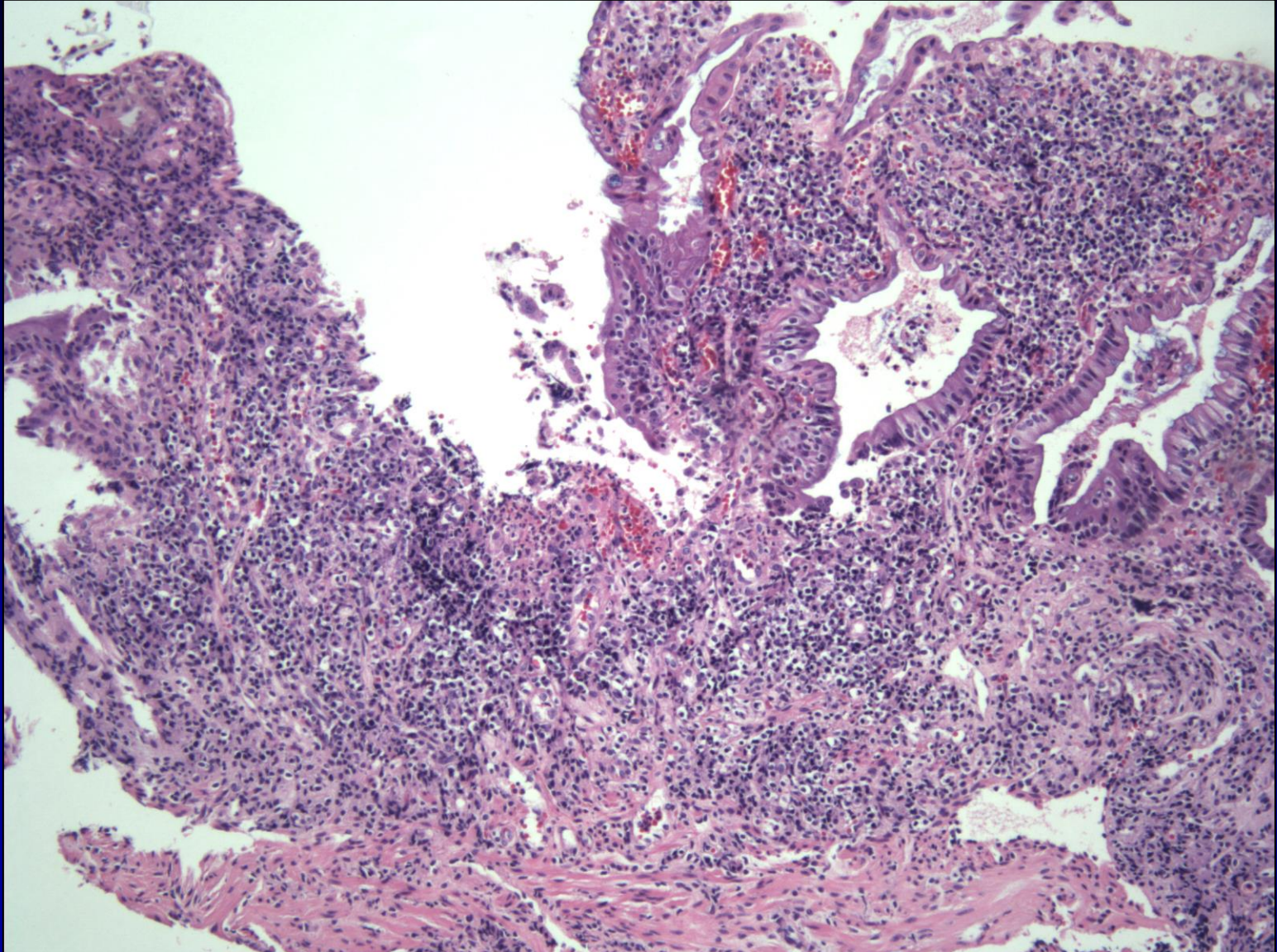
Upper endoscopic examination

- Erythematous gastric mucosa
- Severe duodenitis with ulcers

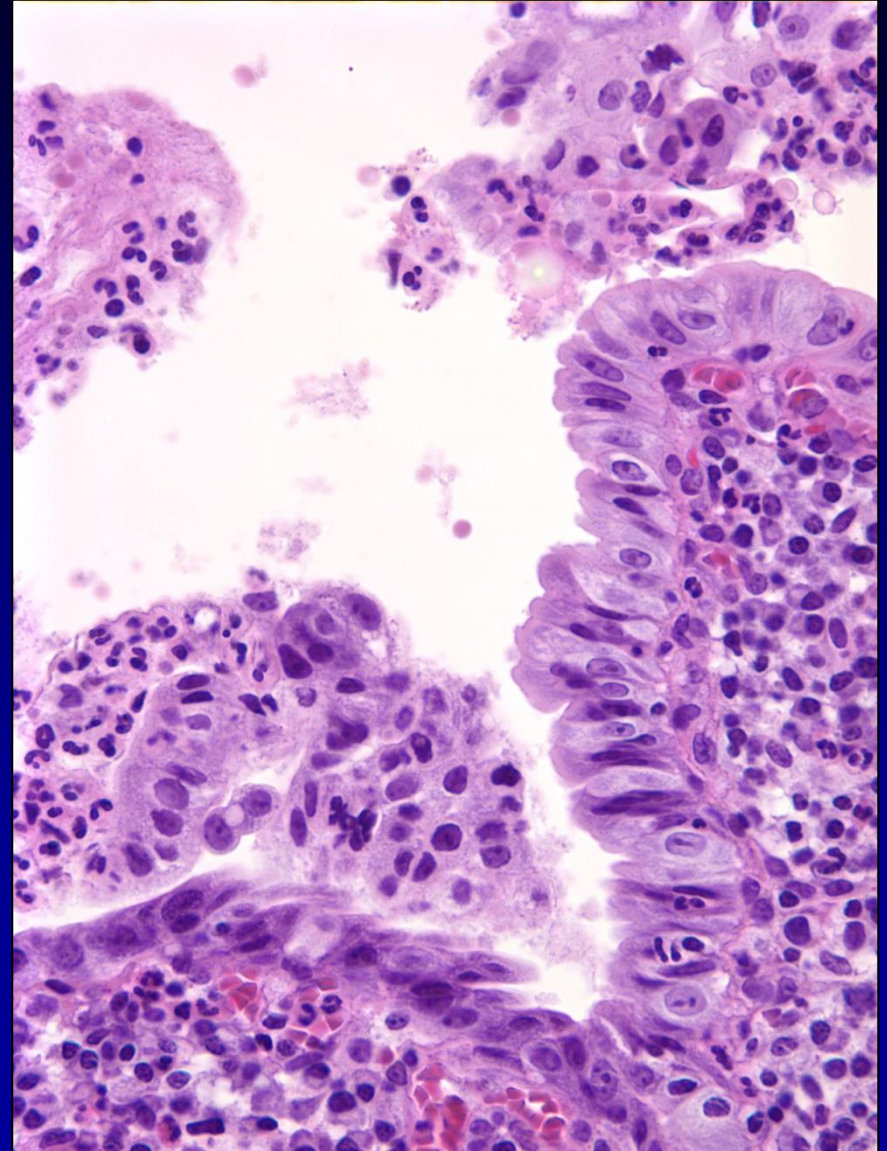
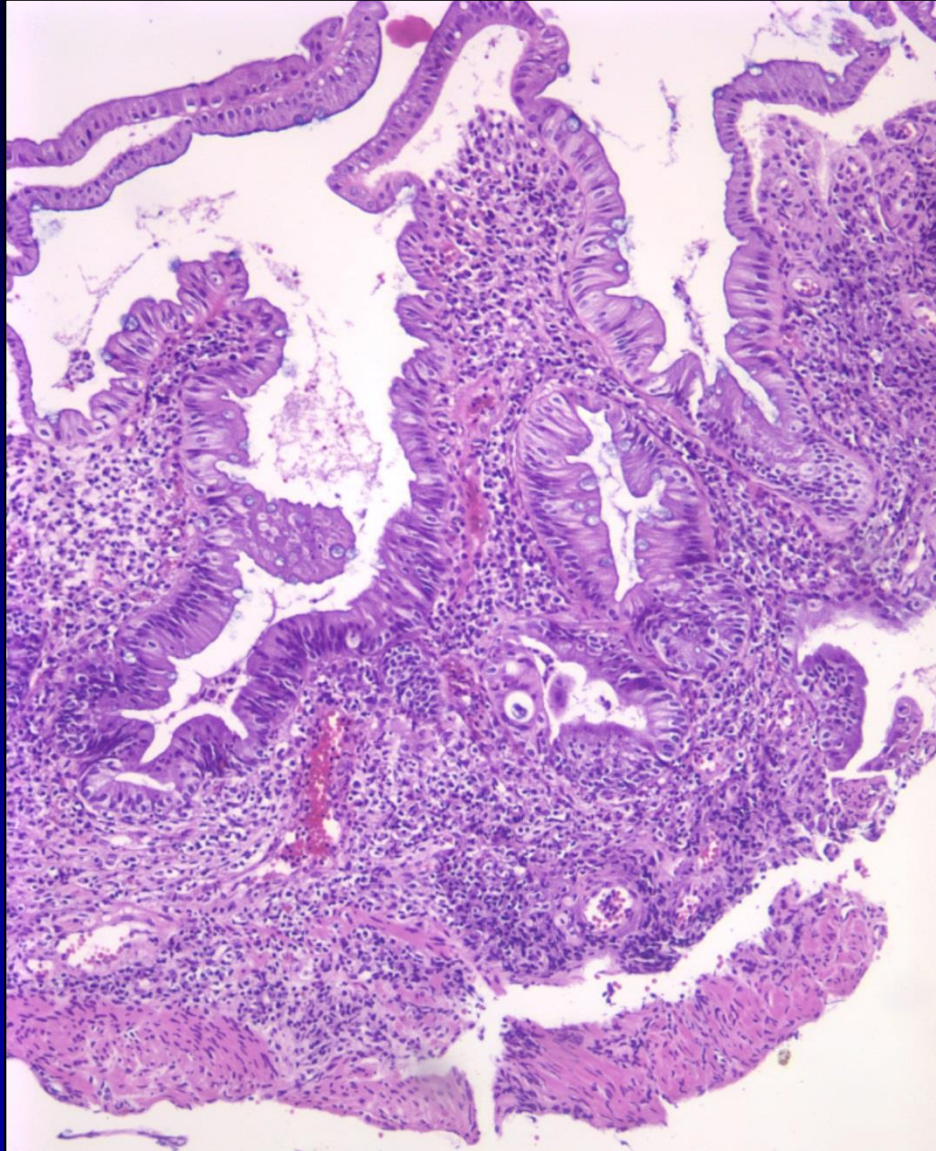
Case 6-Stomach



Case 6-Duodenum



Case 6-Duodenum



Case 6-Duodenum

