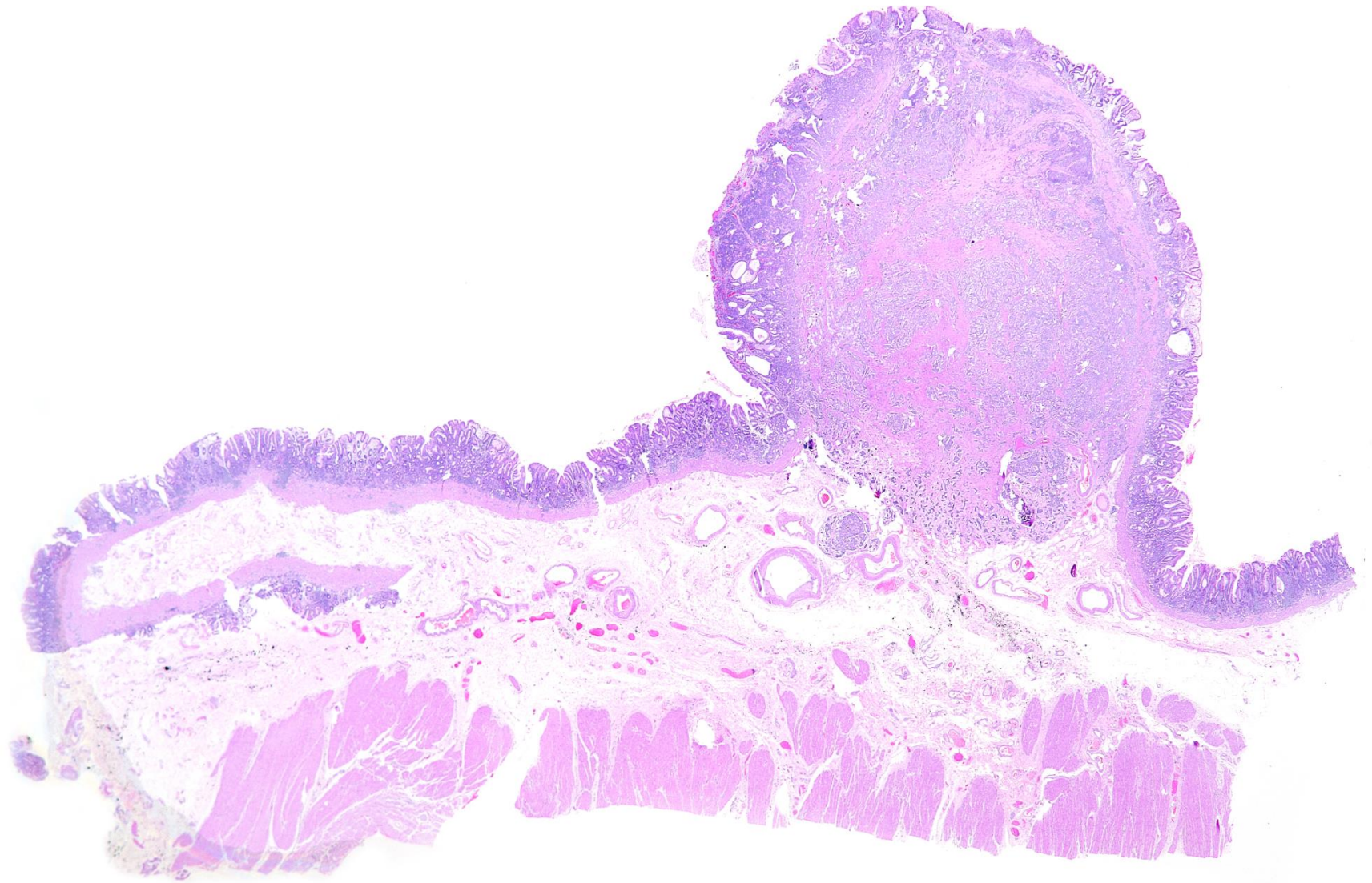
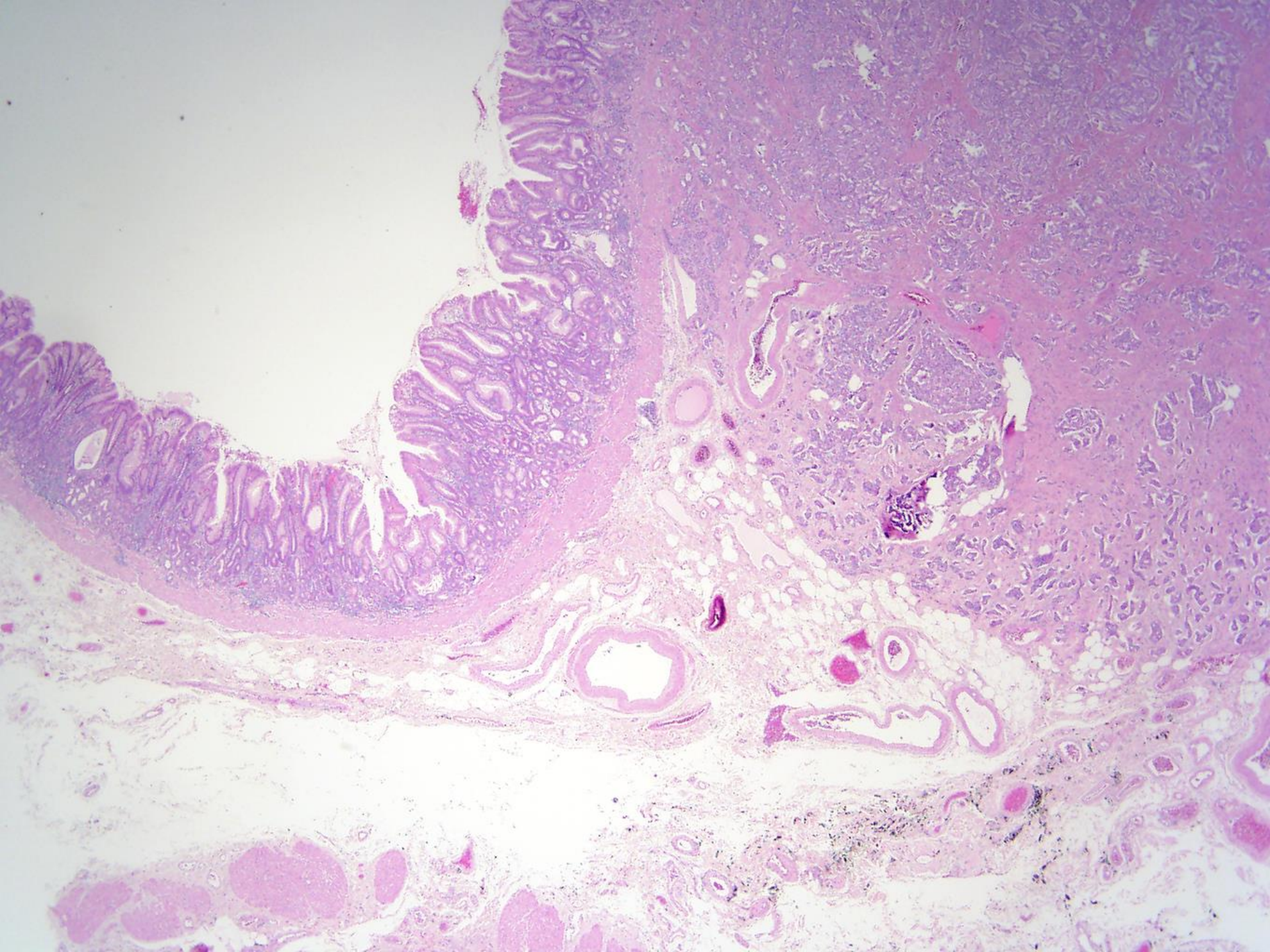
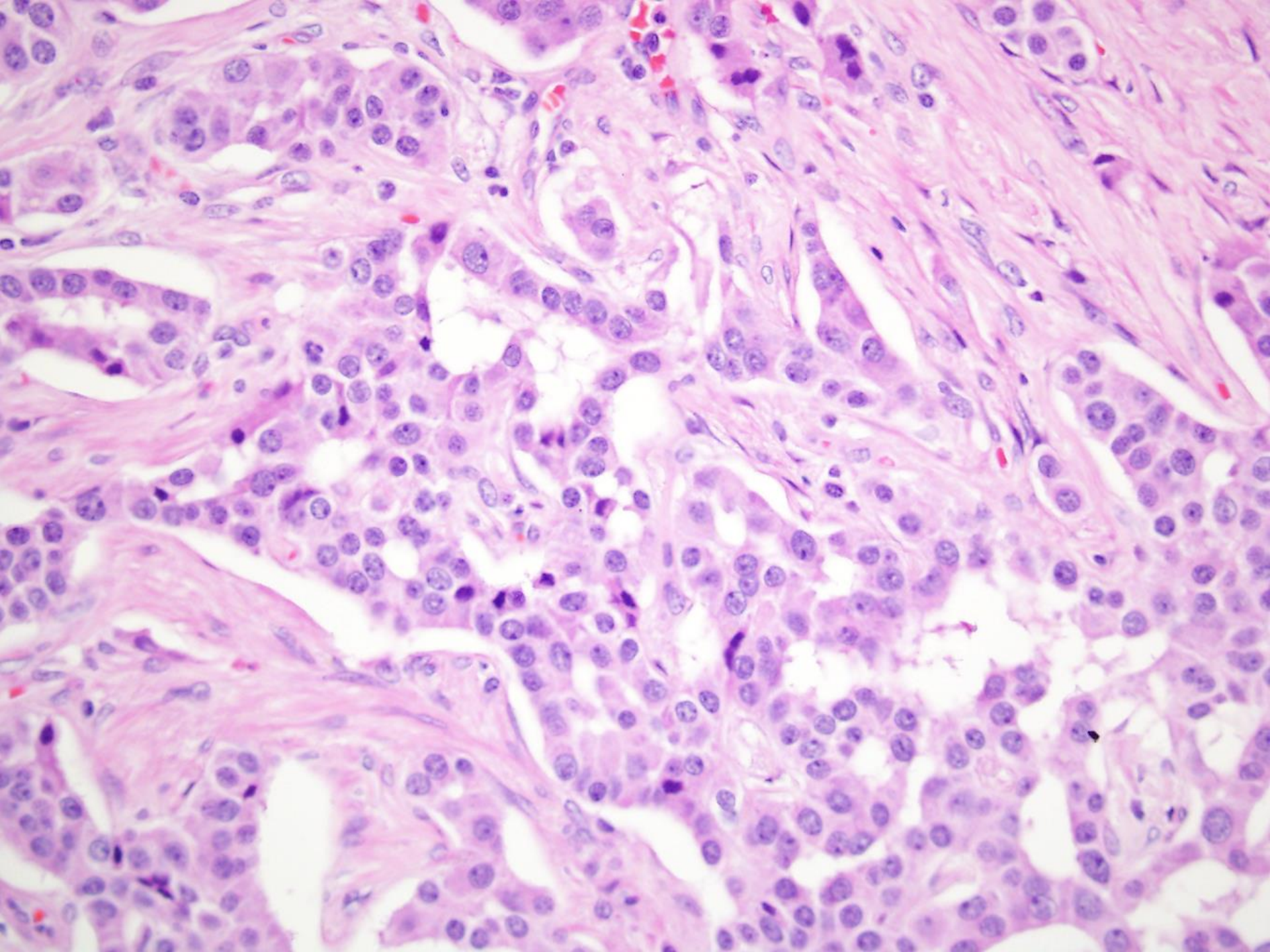


Case 3

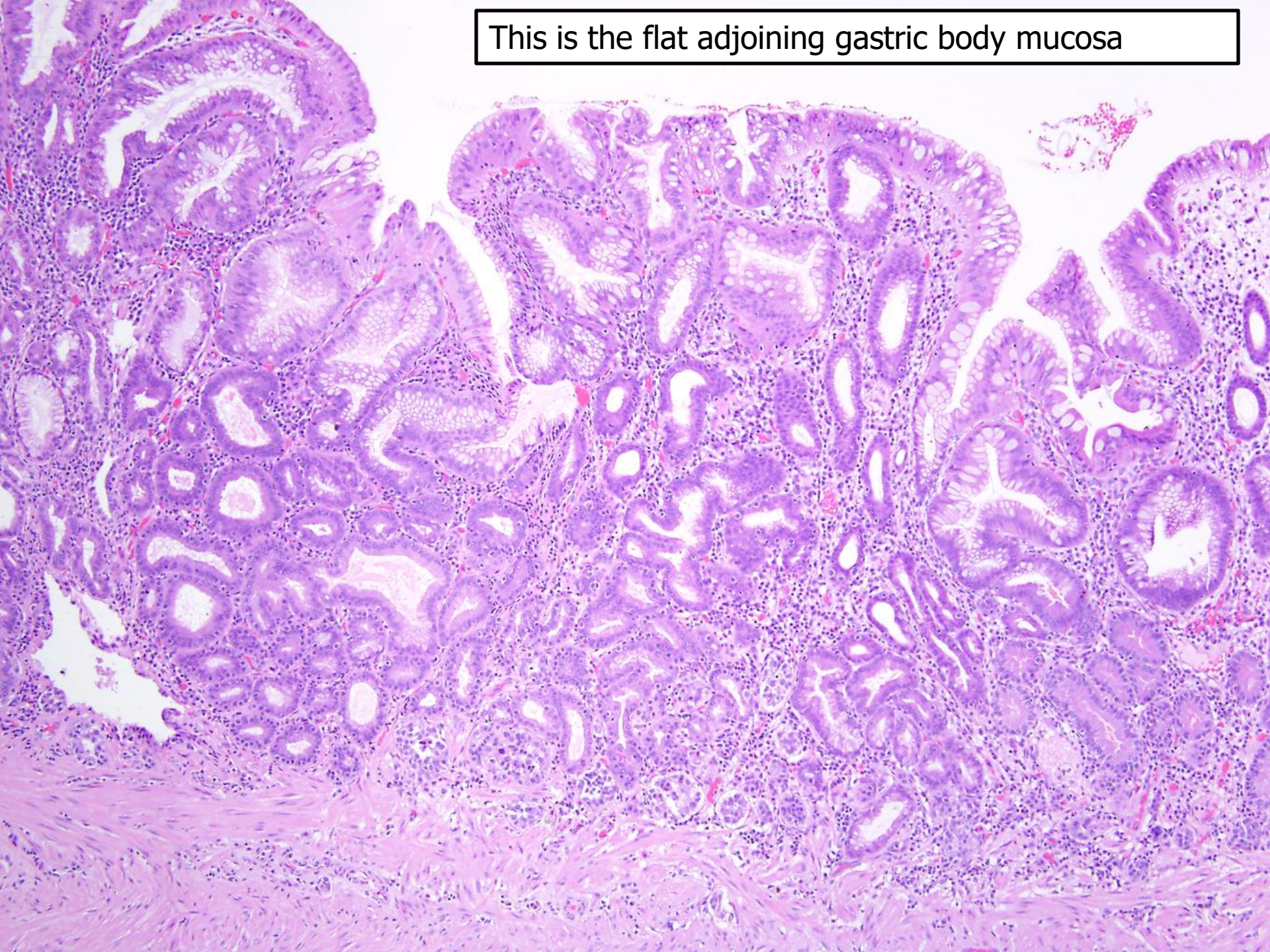
A 51 year old woman with a history of type 1 diabetes underwent a partial gastrectomy for a gastric body cancer. The surgeon asked for HER2 testing since there was a potential positive lymph node.

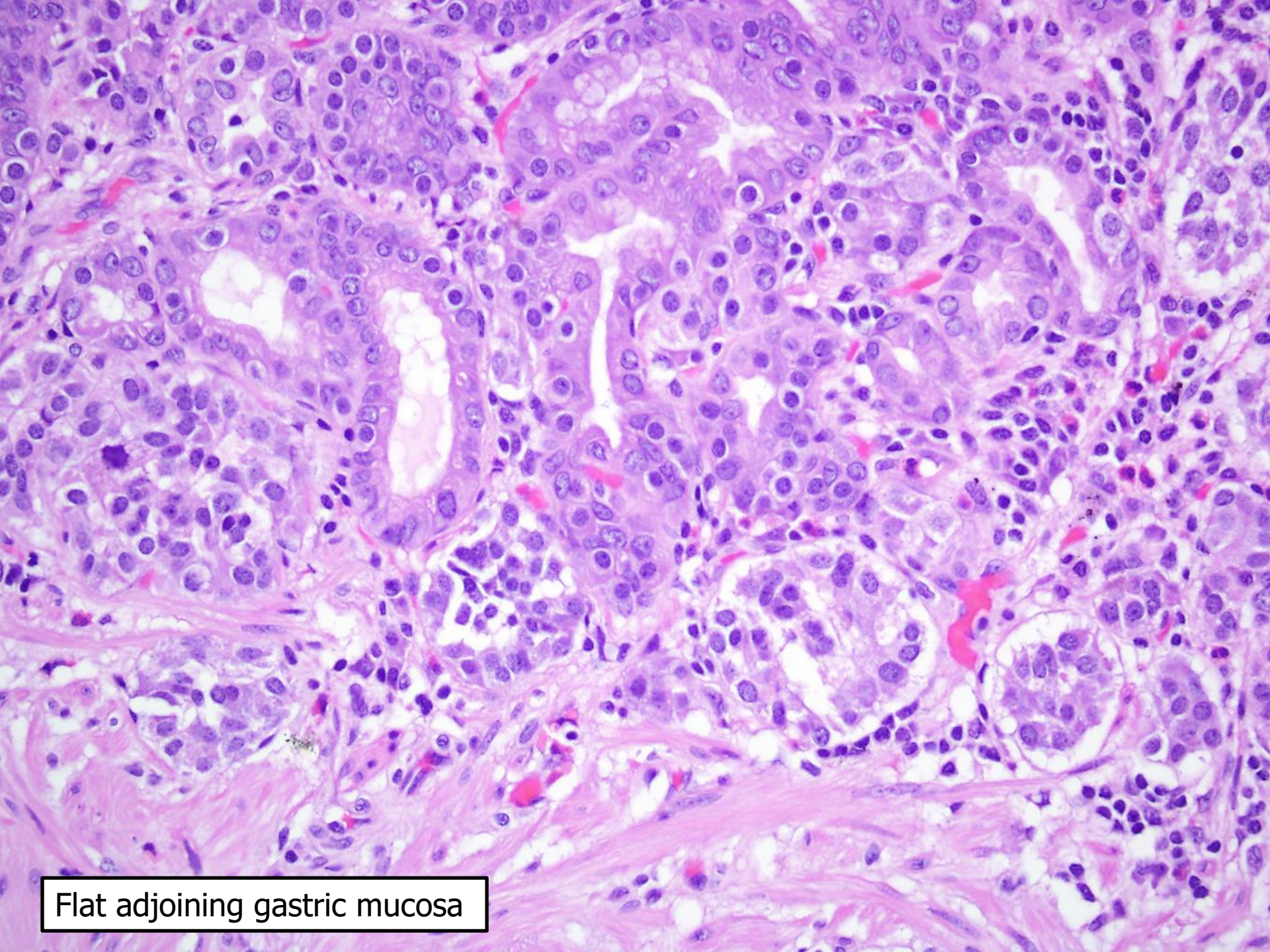






This is the flat adjoining gastric body mucosa





Flat adjoining gastric mucosa