

Case 10

75-year old man underwent colonoscopy for clinical history of polyps

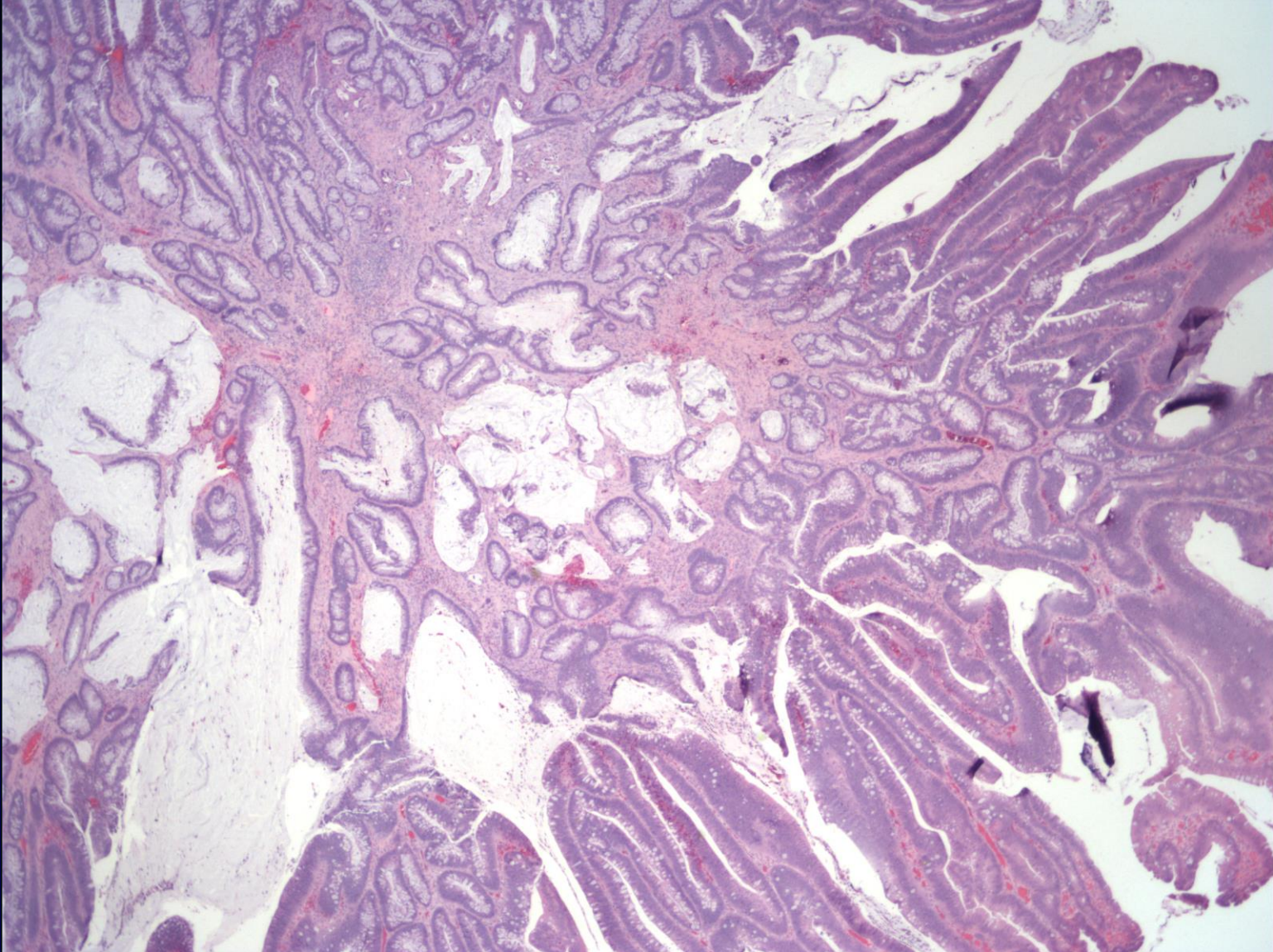
Found to have a 3 cm sessile polyp in the right colon

Mostly (70%) resected to reveal tubulo-villous adenoma with low-grade dysplasia

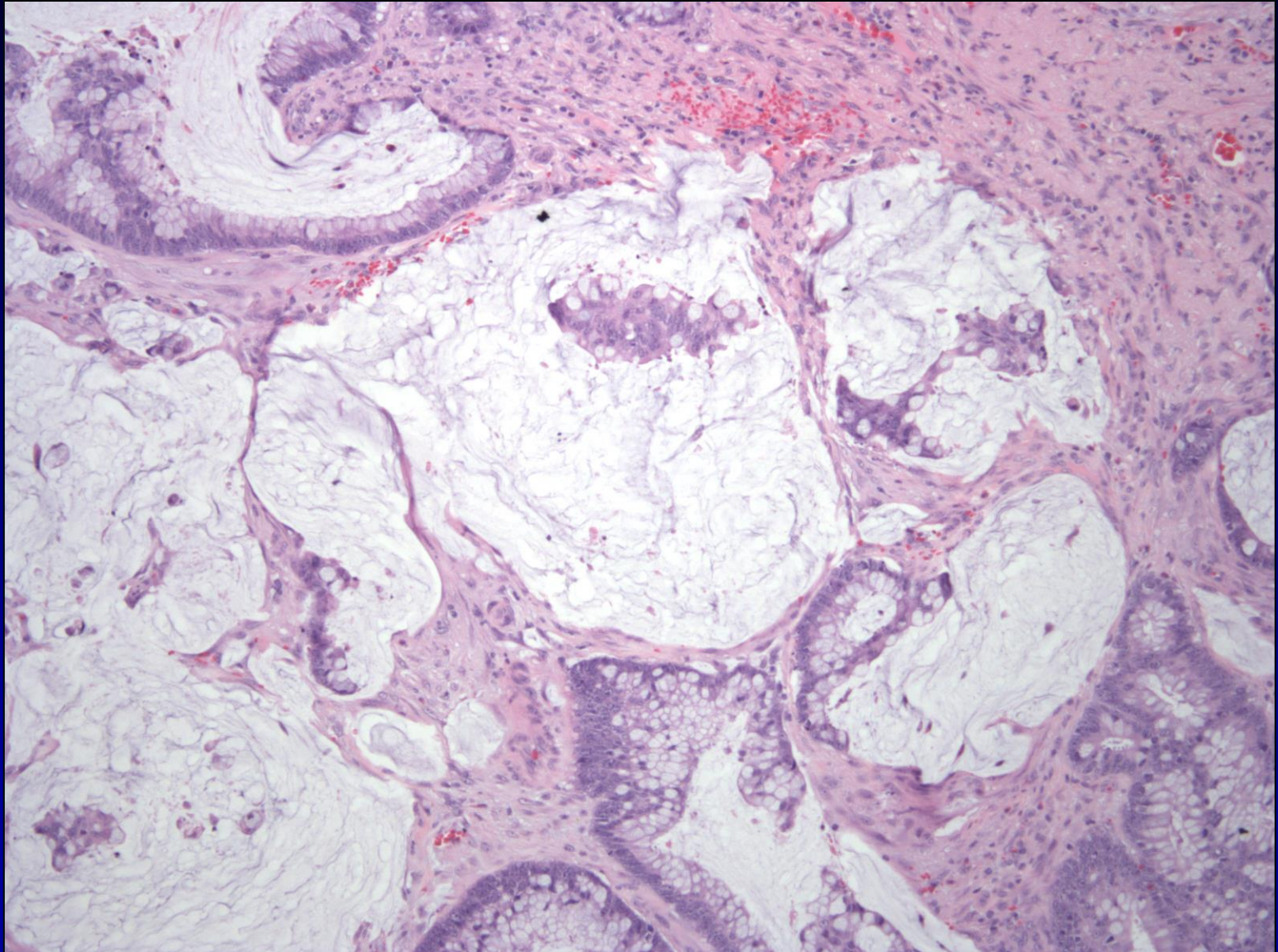
Patient underwent surgical resection 35 days after initial colonoscopy and biopsy

- 14 negative lymph nodes
- Margins free of adenoma

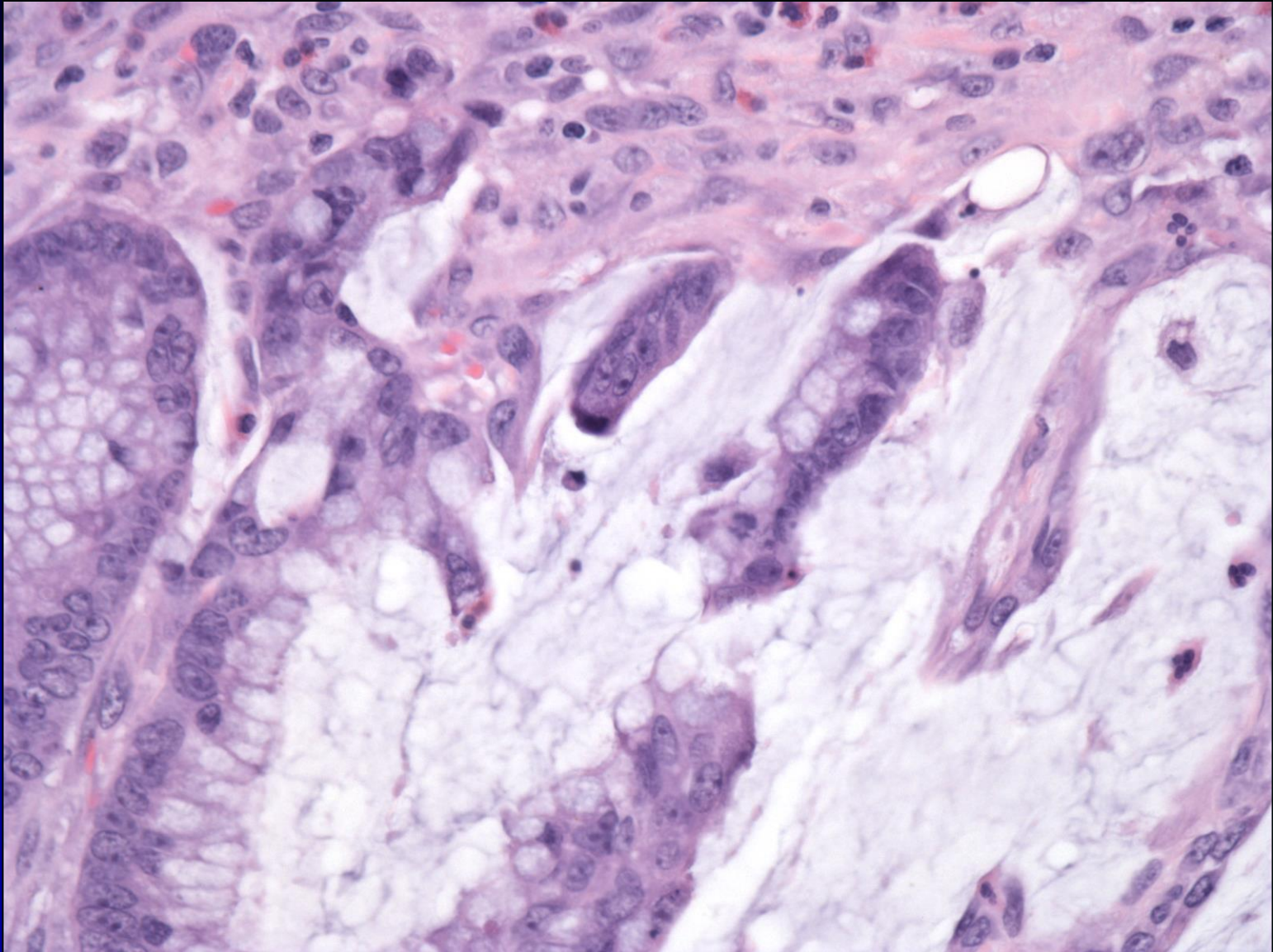
Case 10



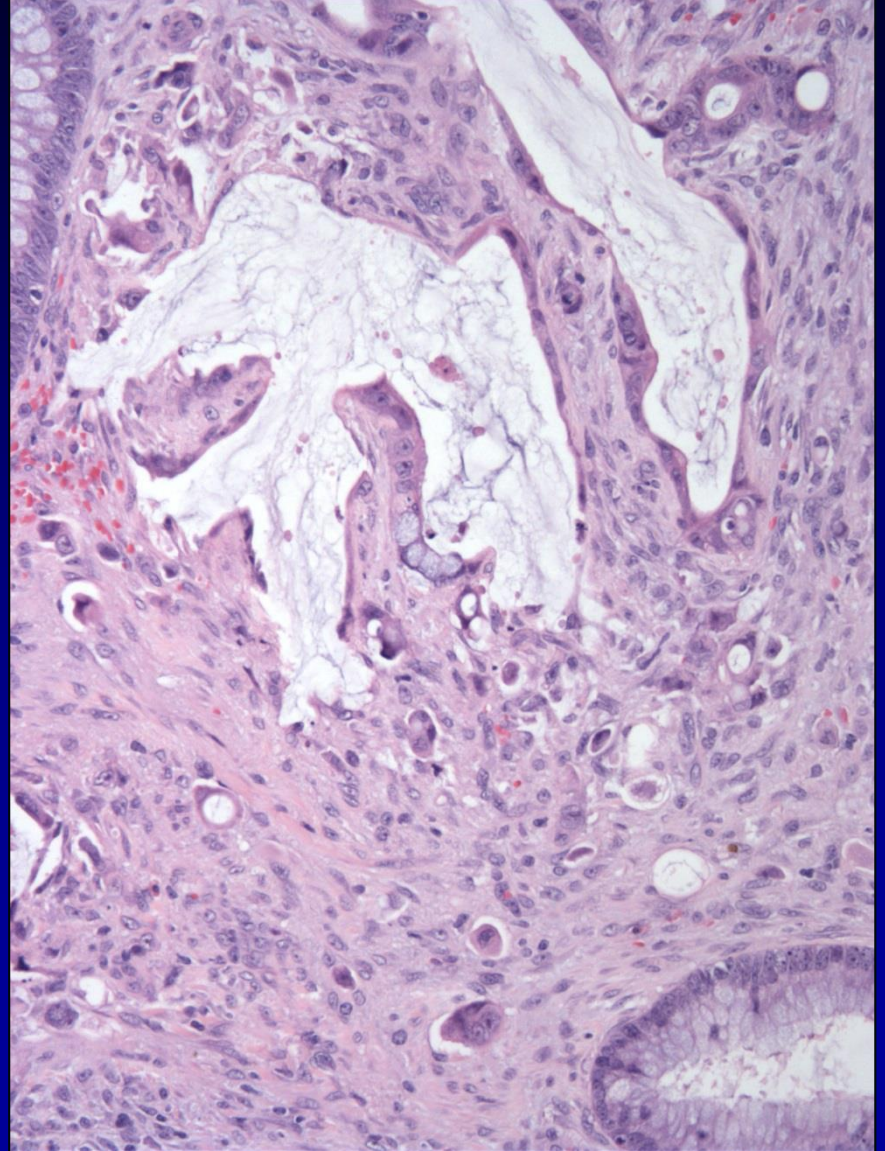
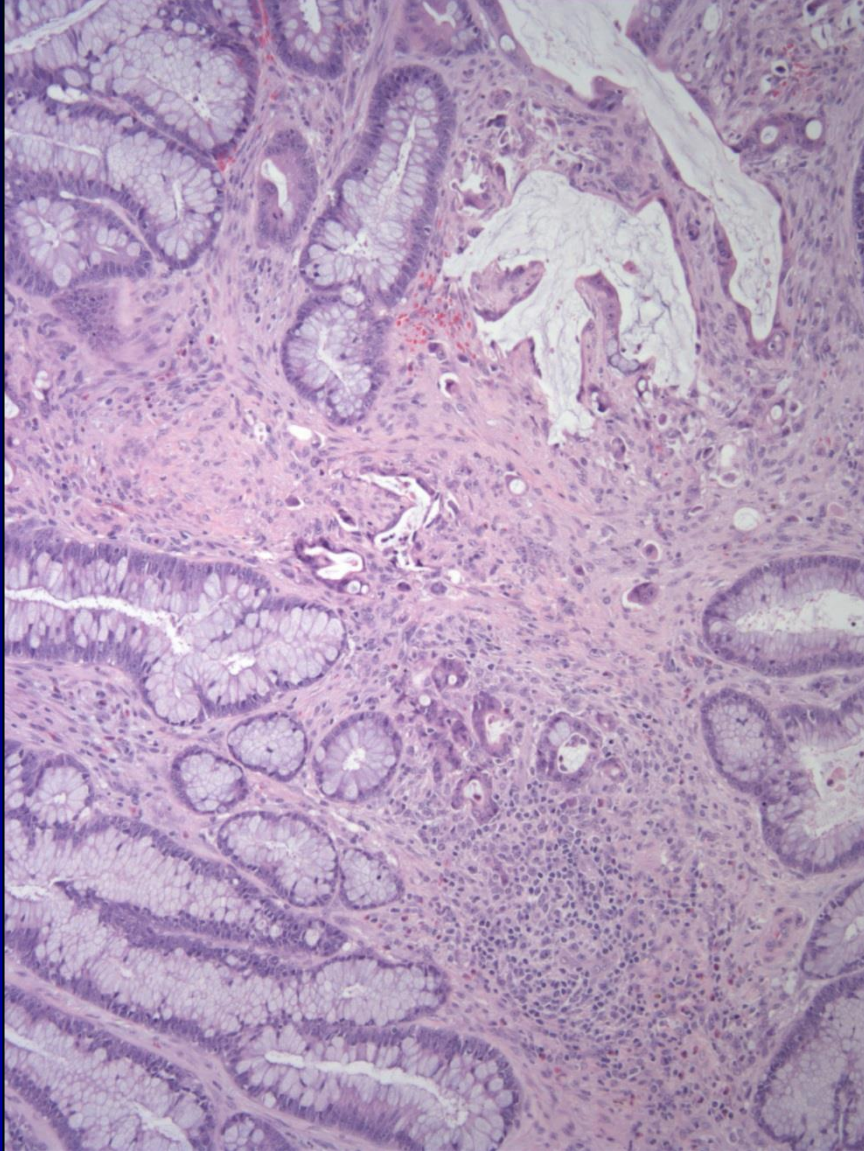
Case 10



Case 10



Case 10



Case 10

