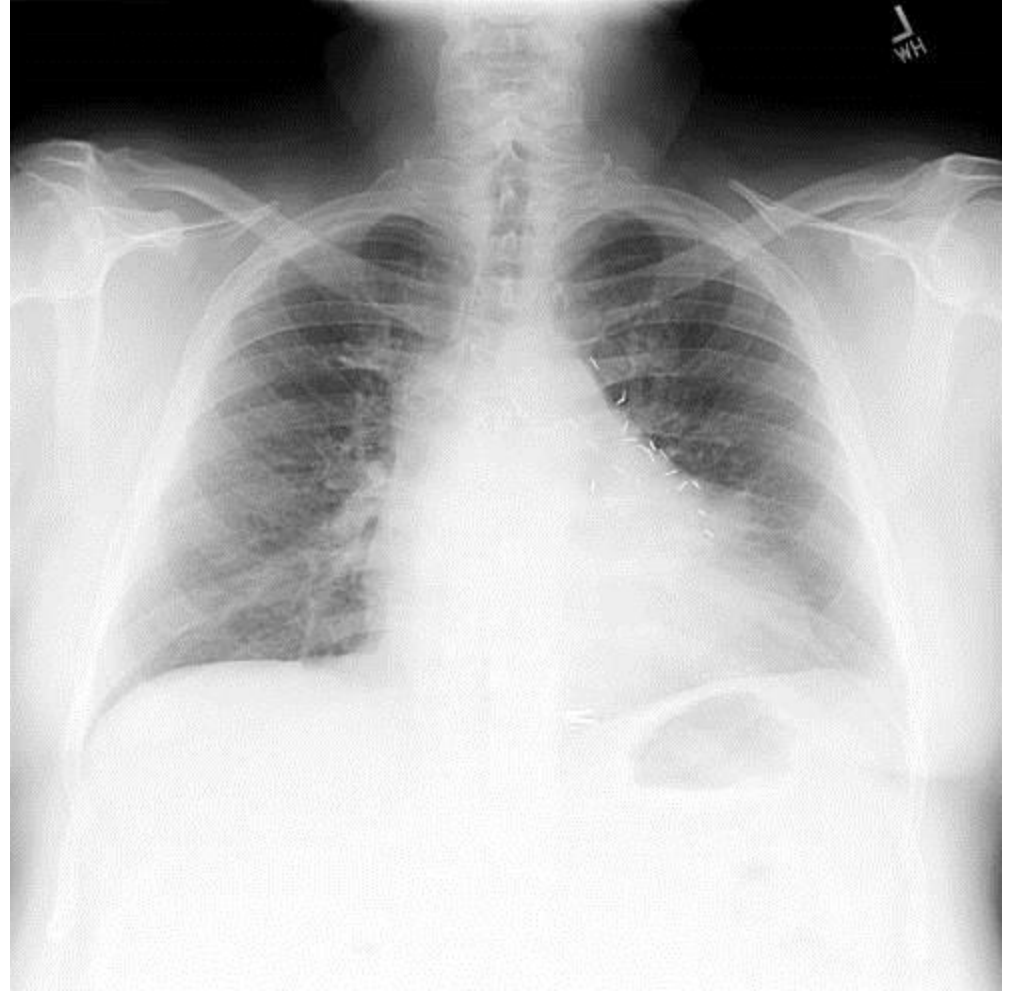
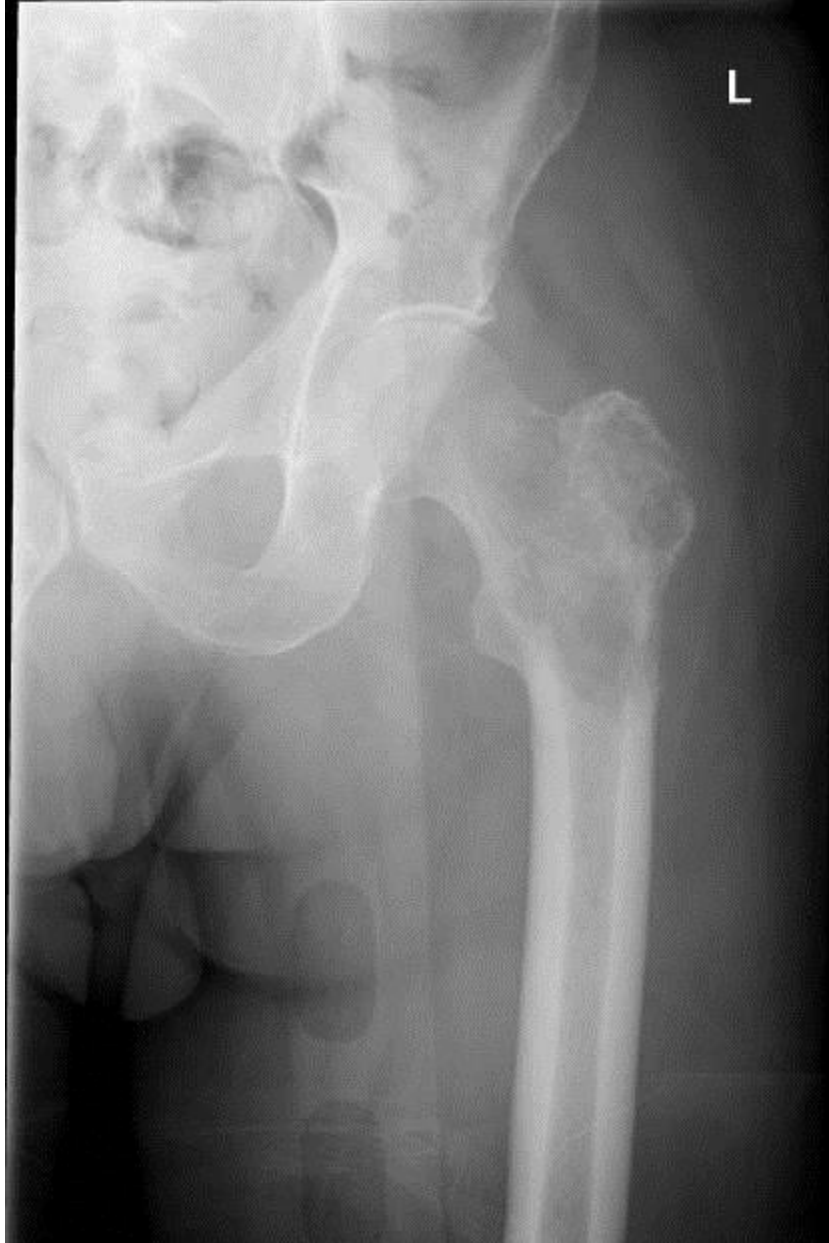
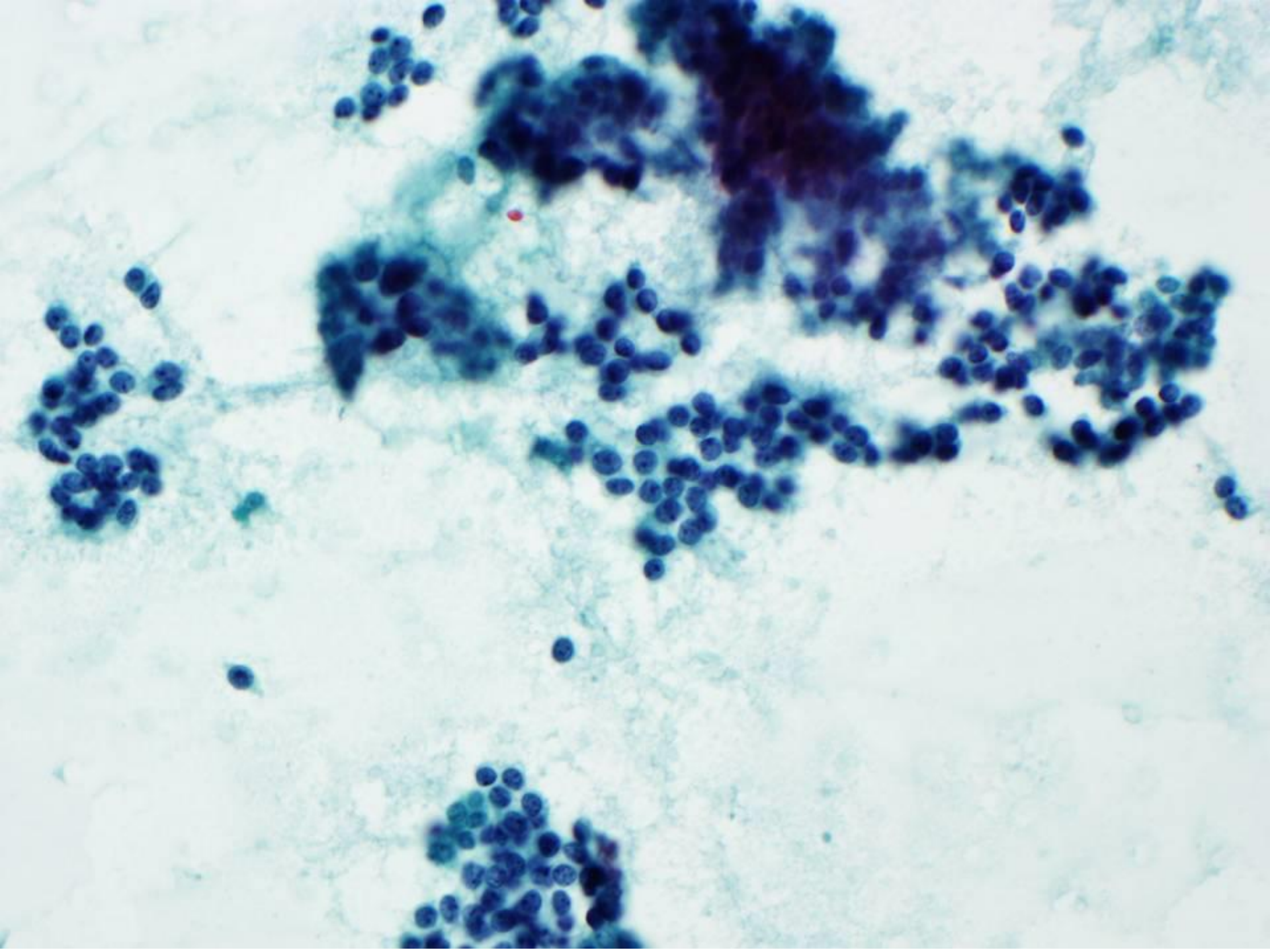
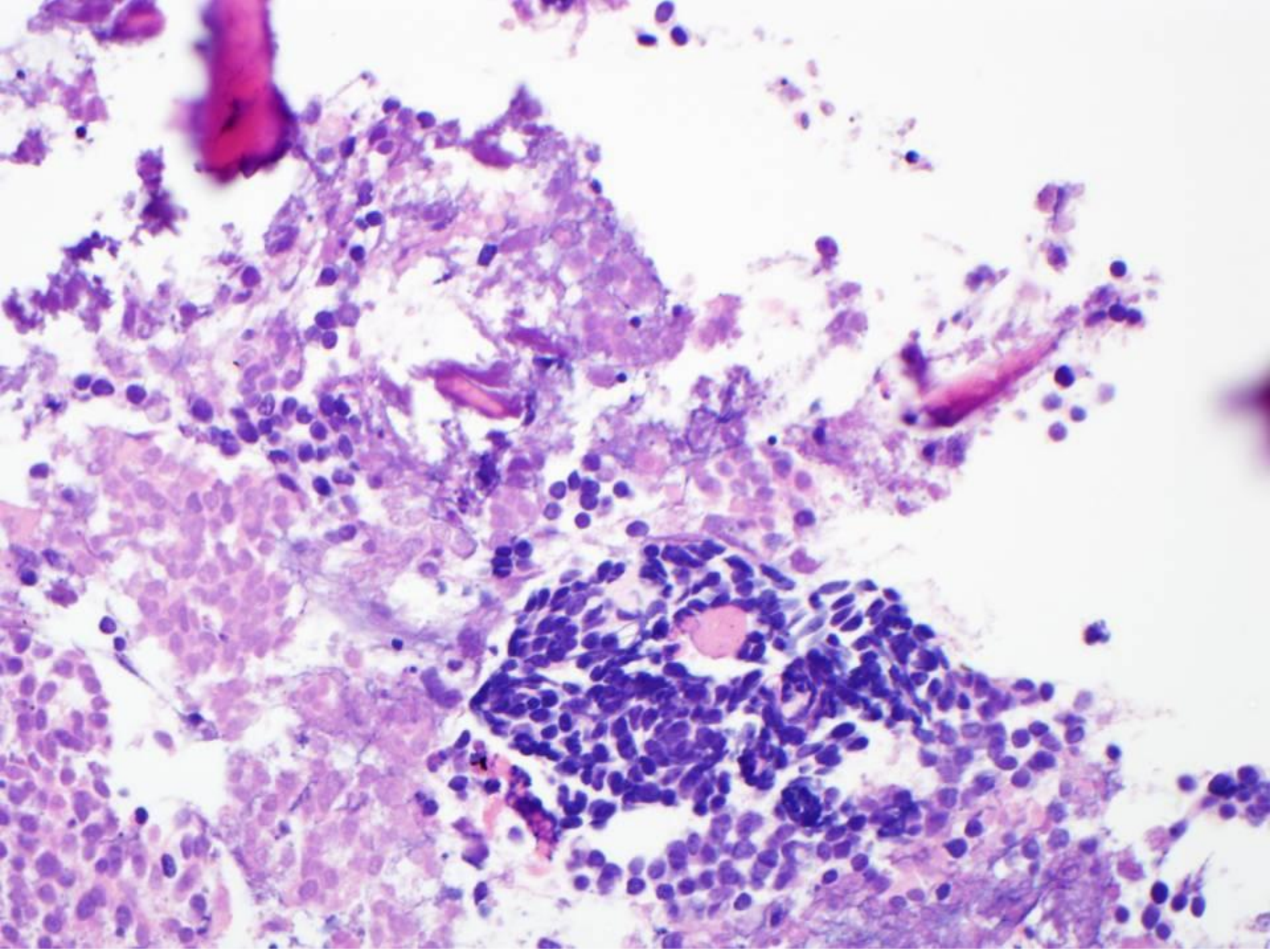


# Horvai8

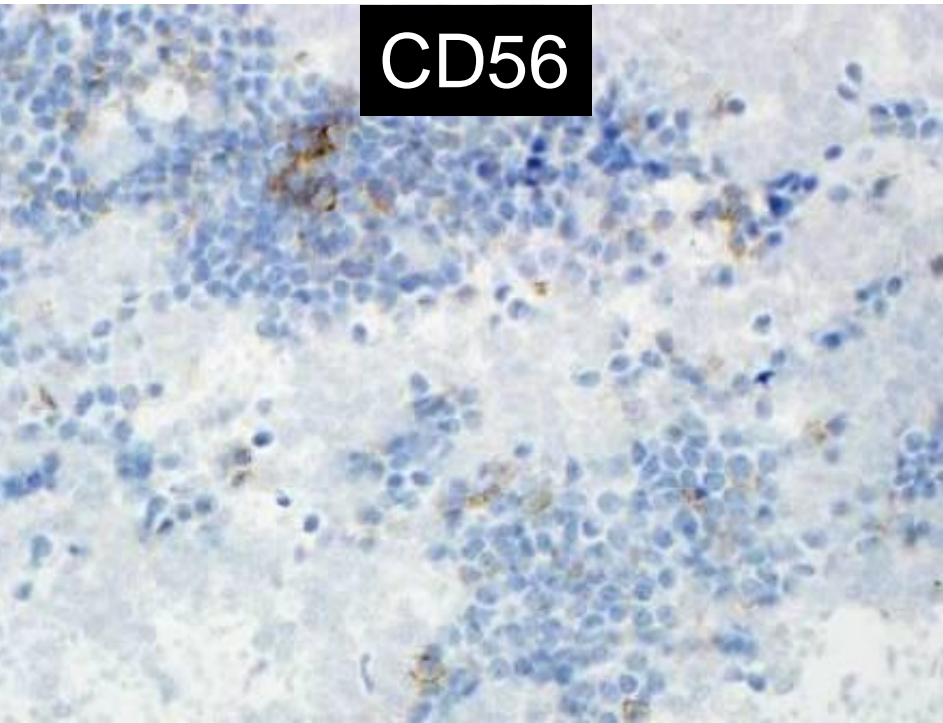
A 77 year old man, remote history of CABG, heavy smoker with a cough and left hip pain. Imaging revealed both an ill-defined left lung opacity and a lesion of the left proximal femur. A chest CT and femur biopsy were obtained.



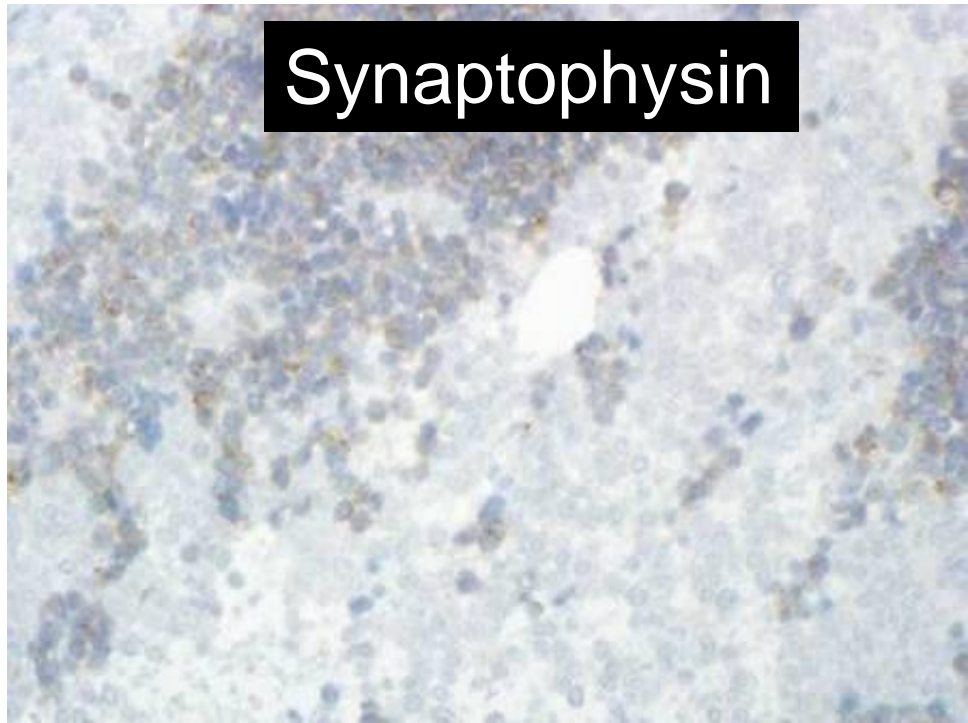




CD56



Synaptophysin



CD99

